

MJA

Macedonian Journal of Anaesthesia

A Journal on Anaesthesiology, Resuscitation, Analgesia and Critical Care

Number 5. December 2018

CASE REPORTS

Journal of the Macedonian Society of Anaesthesiologists
and Macedonian Society of Critical Care Medicine

Publisher:

Department of Anaesthesia and Reanimation, Faculty of Medicine,
"Ss. Cyril and Methodius" University, Skopje, Macedonia

Apotel® 1000mg / 6.7ml

I.V. Paracetamol

БЕЗБЕДНА АНЕЛГЕЗИЈА

менаџирање на болка кога сте загрижени за безбедноста



I.V. paracetamol за прв пат во Европа е применет во 2001 година, а денес поради неговата докажана безбедност и ефикасност е прв од избор **аналгетик и антипиретик**.

Предоперативна и Интраоперативна Аналгезија:

Предоперативна аналгезија е дефинирана како третман кој што започнува пред оперативниот зафат се со цел да се превенира воспоставувањето на централна сензибилизација на болка.

i.v. paracetamol е безбеден, добро толериран лек со докажана ефикасност како **предоперативна и интраоперативна аналгезија** за умерена до средна болка при оперативни зафати.

Голем број на клинички студии ја докажуваат ефикасноста на i.v. paracetamol како **предоперативна и интраоперативна аналгезија**.

КЛИНИЧКА СТУДИЈА:

Ефект од **предоперативен i.v. paracetamol** за постоперативни аналгетски потреби кај пациенти кои се подложни на оперативни зафати. A Sreenivasulu, R Prabhavathi, 2015

Цел: Да се утврди ефикасноста на **предоперативната употреба на 1000mg i.v. paracetamol** кај постоперативните болки и аналгетски потреби кај пациенти подложни на хируршки зафати.

Метод: 60 пациенти беа поделени во две рандомизирани групи од по 30 пациенти.

На I. Група им беше администрирано **ампула од 1000mg i.v. paracetamol разредена 0,9%NaCl** p-ор 30 минути пред индукција (**ГРУПА П**),

На II. Група им беше администрирано **i.v. 0,9% NaCl** p-ор **100мл** 30 минути пред индукција (**ГРУПА НС**)

Сите пациенти беа индуцирани со i.v. thiopentone 5mg/kg, i.v. fentanyl 2µg/kg, i.v. vecuronium 0.1mg/kg

Постоперативниот резултат на болка беше мерен со **Визуелна Аналогна Скала (ВАС) од "0-10"**. Исто така беше забележувана и **постоперативната употреба на tramadol** како спасувачки аналгетик. Инциденцата на **постоперативно гадење и повраќање (ПОПП)** и други компликации исто така беа забележувани во пост оперативниот период.

Резултатот на постоперативната болка беше забележуван во интервали 15 мин, 30 мин, 1 час, 2 часа, и 6 часа.

Заклучок: Предоперативна администрација на **1000mg i.v. paracetamol** кај пациенти подложни на оперативен зафат обезбедува **статистички задоволителна аналгезија**, и ја **намалува постоперативната употреба на tramadol**. Оттука **1000mg i.v. paracetamol** може безбедно да се администрира како превенција при оперативни зафати.

Резултат:

Табела 1: Споредба на средниот резултат на болка (ВАС) помеѓу двете групи

Интервали	I Група П	II Група НС	P вредност
15 мин	2.06 ± 0.63	2.61 ± 0.56	0.0006
30 мин	2.35 ± 1.17	3.84 ± 1.55	0.0001
1 час	2.42 ± 1.12	2.87 ± 0.99	0.0989
2 часа	2.13 ± 1.06	2.52 ± 0.89	0.1219
6 часа	2 ± 0.52	2.52 ± 0.89	0.0549

Табела 2: Споредба за потребите од tramadol помеѓу двете групи

Интервали	I Група П	II Група НС	P вредност
До 1 час	4 (12.90%)	15 (50%)	0.0002
1-2 часа	3 (9.68%)	2 (6.45%)	0.64
2-6 часа	1 (3.23%)	3 (9.68%)	0.301
Вкупно	8 (25.81%)	20 (64.52%)	0.002

Табела 3: Споредба на ПОПП помеѓу двете групи

ПОПП	
I Група П	II Група НС
0	4

i.v. Paracetamol + јак опоид	МНОГУ ЈАКА БОЛКА
i.v. Paracetamol + слаб опоид	ЈАКА БОЛКА
i.v. Paracetamol + NSAID i.v. Paracetamol + rescue medicine	УМЕРЕНА БОЛКА
i.v. Paracetamol + rescue medicine	СЛАБА БОЛКА

Мултимодално менаџирање на постоперативна болка
I.V. Paracetamol е атрактивна компонента за мултимодално менаџирање на болка.

- Синергистичко делување
- Зголемување на аналгетски ефект
- Значително намалување на болка
- Редукција на дозата на опоидни лекови за - 40% во првите 24 часа
- Намалување на несаканите ефекти поврзани со монотерапија на NSAID и опоидни лекови
- Ублажување на акутна и хронична болка

Macedonian Journal of Anaesthesia

A Journal on Anaesthesiology, Resuscitation, Analgesia and Critical Care

Editor-in-Chief

Mirjana Shosholcheva

Deputy Editors:

Andrijan Kartalov

Biljana Kuzmanovska

Associate Editor

Marija Jovanovski-Srceva

Editorial Board:

Marija Sholjakova (Macedonia)

Nikola Jankulovski (Macedonia)

Karin Khuenl-Brady (Austria)

Quirino Piacevoli (Italy)

Zorka Nikolova-Todorova (Macedonia)

Radmilo Jankovic (Serbia)

Olegs Sabelnikovs (Latvia)

Jannicke Mellin-Olsen (Norway)

Meral Kanbak (Turkey)

Nebojsa Ladjevich (Serbia)

Zoran Karadjov (Macedonia)

Hristo Bozov (Bulgaria)

Zuhal Aykaç (Turkey)

Katarina Sakic (Hrvatska)

Jasmina Jakupovich-Smajich (BIH)

Jasminka Nancheva (Macedonia)

Vojislava Neskovic (Serbia)

Daniela Miladinova (Macedonia)

Jordan Nojkov (Macedonia)

Paul Zilberman (Israel)

Antigona Hasani (Kosovo)

Biljana Shirgovska (Macedonia)

Atanas Sivevski (Macedonia)

Hülya Bilgin (Turkey)

Production Editor

Vanja Gievski

Publisher:

Department of Anaesthesia and Reanimation, Faculty of Medicine, "Ss. Cyril and Methodius"

University, Skopje, Macedonia

Proofreading Daniela Nacevska Stojcevska

Printed by ASKOLOR

FIRST ANNOUNCEMENT FOR THE FOLOWING CONGRESS

Dear Colleagues, friends and collaborators,

On the behalf of the of Macedonian Society of Anesthesiologist and as a President of the Board of the Organizing committee of the “**VI Congress of Macedonian anesthesiologist and intensivist with international participation**” it is a great honor, to make the first announcement for the following congress and to invite You to take participation.

This congress has a goal to encourage, implement, promote and exchange knowledge between the Macedonian and international anesthesiologist, intensivists, emergency medicine doctors as well as doctors and nurses from all different medical areas.



The “**VI Congress of Macedonian Anesthesiologist and Intensivist with International participation**” will be held in Ohrid, Hotel Bellevue, from 24-27th October 2019.

Besides knowledge, science and medicine promotion, we are glad that this congress will be held in the city of Ohrid-The city of UNESCO, that lies on the Lake Ohrid region which is a mixed World Heritage Property and a superlative for cultural and natural values so incorporating knowledge, pleasure and tourism is obligatory.

Preliminary timetable and scientific program will be announced soon!

We are looking forward to welcoming you in Ohrid!

On behalf of the Organizing and Scientific Committee:

Prof. Kartalov Andrijan, MD, MSC, PhD, *President of the Macedonian Society of Anesthesiologist and President of the Organizing Committee*

Prof. Shosolceva Mirjana. MD, MSC, PhD, Vice-president of the Organizing Committee

Prof. Kuzmanovska Biljana. MD, MSC, PhD, President of the Scientific Committee

CONTENT

EDITORIAL

CASE REPORTS AND CASE SERIES.....	7
Cvetkovska E	

CASE REPORT

SPINAL ANESTHESIA IN PARTURIENT WITH SEVERELY SCOLIOTIC SPINE	8
Sivevski A, Ivanov E, Karadjova D, Veninov F, Spasovski S, Popovska R	

CASE REPORT

PREOPERATIVE MAGNESIUM SULPHATE USAGE AS A MEDICAL CHALLENGE IN POSTOPERATIVE PAIN MANAGEMENT	15
Panovska-Petrusheva A, Mojsova Miovska M, Jovanovski-Srceva M, Toleska M, Gavrilovska A, Dimitrovski A, Mikjunovikj Lj, Golubikj-Nichevska S, Zafirova D	

CASE REPORT

CHALLENGES IN DIFFICULT AIRWAY MANAGEMENT - AIRWAY MANAGEMENT IN A CASE OF PROLONGED ENLARGED THYROID GLAND (STRUMA PERMAGNA)	18
Trposka A, Stojkovska A, Kartalov A, Kuzmanovska B, Jovanovski-Srceva M, Kokareva A, Naumovski F, Cholancheski R	

CASE REPORT

ANESTHETIC MANAGEMENT FOR PATIENT WITH TRACHER COLLINS SYNDROME SCHEDULED FOR ELECTIVE CESAREAN DELIVERY	23
Zlatkova M, Karagova D, Ivanov E, Popovska R	

CASE REPORT

- TACHYCARDIA - BRADYCARDIA SYNDROME IN A PATIENT UNDERGOING PERTROCHANTERIC FRACTURE REPAIR UNDER SPINAL ANESTHESIA** 28
Naumovski F, Kartalov A, Kuzmanovska B, Shosholcheva M, Trposka A, Dimitrovski A, Petrusheva A, Toleska D.M

CASE REPORT

- ANKLE BLOCK AN ALTERNATIVE OF ANESTHETIC MANAGEMENT OF MYASTHENIA GRAVIS (CASE REPORT)** 36
Burmuzoska M, Jovanovski – Srceva M, Kokareva A, Petrusheva A, Kartalov A, Kuzmanovska B, Simeonova A, Josifov A

CASE REPORT

- APPROACH TO ONE LUNG VENTILATION DURING SURGICAL REMOVAL OF ASPIRATED LIGHT BULB IN A CHILD** 41
Gjorchevska E, Gavrilovska-Brzanov A, Dimitrova M, Donev Lj, Simeonov R, Ristovski T

WORKSHOP

- A LETTER TO THE EDITOR**
REMOTE WORKSHOP FOR LOW FLOW ANESTHESIA 48
Zilberman P, Malinovska-Nikolovska L

IMPRESSIONS FROM MEETINGS

- DOJHRAN 2018 - THORAX AND RESPIRATION** 54
Adramanova D, Pavlova M

- GUIDELINES FOR AUTHORS** 55

CASE REPORTS AND CASE SERIES

Case reports and case series are descriptive studies to detail symptoms, diagnoses, courses, and treatments of patients in their natural clinical setting. Case reports generally consist of three or fewer patients, and the case studies involve multiple patients. They are well known form of medical communication, although, lately, they have been viewed as less scientific than research articles. And while randomized controlled trials provide strong evidence of treatment efficacy, case reports serve for different purposes: communicating the discovery of new diseases, disease mechanisms or therapeutic approaches; alerting the medical community to adverse or beneficial effects of drugs; and generating new hypotheses to be tested by studies that employ more scientifically rigorous research designs (Vandenbroucke, 1999; Akers, 2016). The case reports and case series have also educational value, giving an opportunity to readers to reflect on their own clinical practice. Over the last several years, a vast number (~160) of new peer-reviewed journals have emerged that focus on publishing case reports (Akers, 2016). Case reports are also published regularly in many high-impact journals, The Lancet being prominent example. They describe them, so the journal instructs their authors, as “a single interesting case, which should not be a rarity, but one that a general physician might encounter, in which there was some difficulty in reaching a diagnosis, and that provides a teaching point”. Case reports and case series from Lancet had significant impact on medical literature, being cited in average 17 times (Albrecht et al., 2005). A number of follow-up trials were identified, disclosing their significant influence on the subsequent literature and possibly on clinical practice.

In conclusion, although the randomized trials excellently meet requirements of evidence-based medicine, case reports and case series have other remarkable goals in the progress of medical science and education. These goals are indispensable complement to the aims of evidence-based medicine. Dedicating a whole issue of Macedonian Journal of Anesthesiology to case reports is an excellent idea and valuable contribution to the medical literature.

Albrecht J., Meves A., Bigby M. Case reports and case series from Lancet had significant impact on medical literature. *J Clin Epidemiol* 2005; 58: 1227–32.

Akers K. New journals for publishing medical case reports. *J Med Libr Assoc* 2016; 104(2): 146-49.

Vandenbroucke JP. Case reports in an evidence-based world. *J R Soc Med* 1999; 92(4):159–63.

Emilija Cvetkovska, MD, PhD

University Clinic of Neurology, Faculty of Medicine, Skopje, R. Macedonia

SPINAL ANESTHESIA IN PARTURIENT WITH SEVERELY SCOLIOTIC SPINE

Sivevski A¹, Ivanov EI, Karadjova DI, Veninov F I, Spasovski SI, Popovska R¹.

¹ University Clinic for Gynecology & Obstetrics, Anesthesia Dept., Clinical Center Mother Teresa, Skopje, R. Macedonia

Abstract:

The choice of anesthesia in parturients with severe scoliosis undergoing an elective cesarean section (C-section) is associated with potential risks for both mother and fetus and presents a challenge for the anesthesiologist when considering the type of anesthesia that should be used. Alterations in the maternal physiology and potential perioperative complications associated with this comorbidity can cause difficulties when both general and spinal anesthesia are used. After reviewing all risk factors associated with both types of anesthesia, we consider that a single shot spinal anesthesia can be a successful type of anesthesia in severely scoliotic individuals, especially in those with pulmonary compromise. Here we present a successful case of parturient undergoing a spinal anesthesia for C-section performed at the University Hospital for Genecology in Skopje.

Key words: anesthesia, C-section, severe scoliosis, spinal.

Corresponding author: Atanas Sivevski, University Hospital for Genecology, Skopje, Macedonia

Case Report:

A 144 cm, 43 kg, 26-year old 36-week and 6-day pregnant woman diagnosed with scoliosis was scheduled for an elective C- section. She gave a past history of 3 prior surgeries on her spine for correction of scoliosis and one at an infant age for correction of meningocele. The patient had been previously hospitalized twice for the treatment of meningitis. The patient had a severe restrictive lung disease as a result of the scoliosis, which made her the oxygen dependent.

The examination of the spine revealed a severe right-sided lateral curvature along with an incision scar extending from the thoracic down to the right ileosacral region (Figure1,2). Upon chest examination the breath sounds were diminished with lower intensity bilaterally.

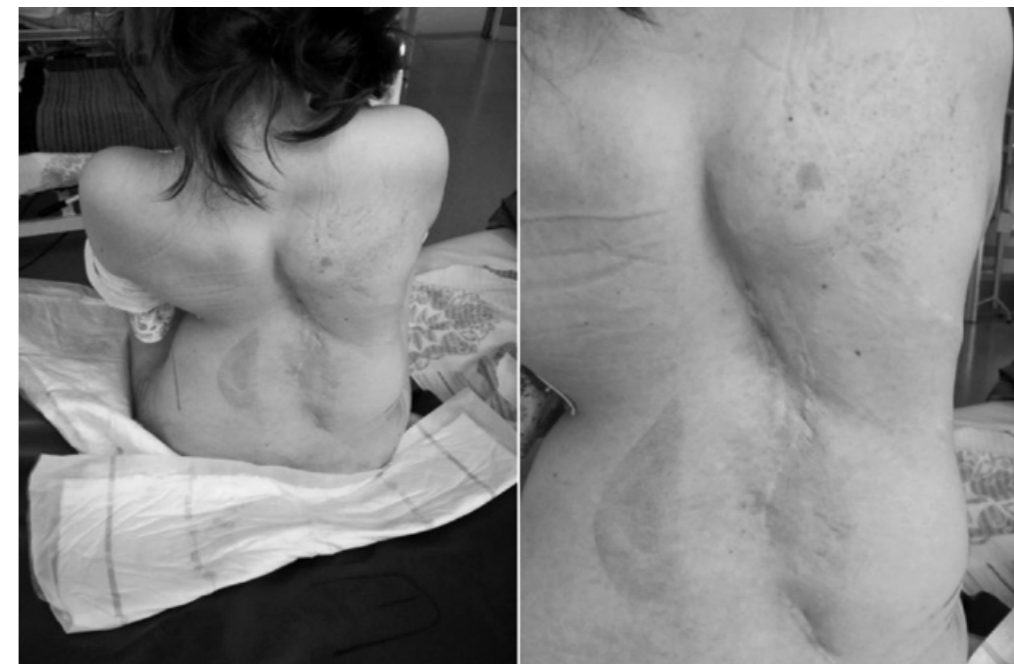

Fig. 1. Scoliotic spine in parturient Fig. 2. Scoliotic spine in parturient (larger view)

The patient's blood investigations revealed a slight anemia: Rbc- $3.77 \times 10^{12}/l$, Hgb-116 g/l, Hct-0.342 l/l, Tr-294, Le-6.6; the ECG showed a negative "p" wave in V1 and a negative "t" wave in V1 and V3 (which corresponds to the echocardiographic results from 1 year prior to the admission, in which an asymptomatic mitral valve prolapse was confirmed).

For assessment of the respiratory function in the patient, a spirometry and capillary blood tests were done which revealed restrictive lung disease (FEV1-34%, FVC- 36%, FEV1/FVC-107 (89.8)%, and FEF2575-27%) and moderate respiratory insufficiency of combined type with low grade of hypoxemia (pH -7.34, pO2-9.05, pCO2-9.05, HCO3-23.4 mmol/L, a BE ecf -6.1 mmol/L and BEb-4.7 mmol/L, SatO2-93.5%).

After considering the patient's condition, keeping in mind her pulmonary status, SA was considered as the superior option over GA. This was discussed with the patient and written informed consent was obtained.

On admission to the OR, the BP was 120/80mmHg, the pulse was 70 bpm and the SpO₂ 96%. The patient was seated and in that position under aseptic conditions, the lumbar puncture was carried out using a 26 G Pencan spinal needle at the level L3-L4. An intermediate approach was used, and the spinal needle was slowly advanced toward the dura; after 3.5 cm the subarachnoid space was reached. Dura puncture was achieved in the second attempt. After confirmation of free flow of cerebrospinal fluid, 6 mg of 0.5% isobaric Bupivacaine and 20 µg Fentanyl (total 1.6 ml) was injected intrathecally slowly. The patient was then immediately placed in a supine position. The sensory block was tested with a pinprick and Th4 sensory level was achieved. Adequate surgical anesthesia was achieved during the 45 min procedure, which was uneventful (Figure 3).

During the procedure the patient's vital signs were stable. Her blood pressure was in the range of 110/60 -140/70 mmHg and no hypotension (SBP<100 mmHg) was observed during the surgery. SpO₂ < 93% was not seen during the procedure; during this time the patient was breathing O₂ 4 l/m via face-mask.

After the surgery the patient was moved to the postoperative ward, where she was monitored. She was hemodynamically stable, and no complications were noticed. About 120 minutes after the intrathecal injection, sensory and motor functions were completely restored. She was discharged from the hospital in stable condition after a seven-day medical treatment.

Discussion:

Pregnancy induces physiological changes, which affect many organic systems, including the cardiovascular system, the respiratory system, the central nervous system, and the gastro intestinal system. These changes make parturients a higher risk group for anesthesia, especially when general anesthesia (GA) is applied. Scoliosis primarily affects the anatomy of the spine by lateral curvature and rotation of the vertebrae. Depending on the severity of the spinal deformity, this can cause a different degree of deformity on the rib cage, and secondarily can affect all organs, including having serious effects on the cardiopulmonary system.

The choice of anesthesia in parturients with a severely scoliotic spine is difficult because of the potential complications caused by both general and spinal anesthesia. In patients with severe scoliosis undergoing C-section, maternal morbidity and mortality are higher under GA compared to under neuraxial anesthesia (NA), as a result of the increased risk of perioperative complications (1). While NA might be a preferred type of anesthesia in scoliosis where respiratory compromise exists, the technique nonetheless involves technical unpredictability.

Hereby we present a successful case of parturient undergoing a spinal anesthesia for C-section performed at the University Hospital for Gynecology in Skopje. After reviewing the risks associated with each type of anesthesia, it was decided that SA was a feasible choice with lower risk for complications when compared to GA.

Scoliosis can have different etiologies. In the majority of cases it is an idiopathic disease present from birth. In fewer cases scoliosis can be caused by degenerative, neuromuscular and

vascular diseases. Scoliosis is diagnosed when the Cobb angle is over 10° (2,3). Mild scoliosis is when the angle is 11–25°, moderate scoliosis when the angle is 25–50° and severe scoliosis is when the Cobb angle is >50.

When talking about NA in parturients with scoliosis, an algorithm based on the severity of the scoliosis has been suggested (Table 1). In accordance with this category, the patient in our case was severely scoliotic.

Table 1. Degree of scoliosis with neuroaxial technique suggestions.

Mild (Cobb angle 11-25°)	If the provider is confident with the anatomy, proceed cautiously with good positioning.
Moderate (Cobb angle 25-50°)	Proceed with either: 1) A paramedian approach on the convex side; 2) A midline approach with angulation towards the convex side; 3) An imaging technique such as ultrasound proceed cautiously with good positioning.
Severe (Cobb angle >50°)	Imaging such as ultrasound or fluoroscopy should be used to assist in safe placement with a low threshold for alternative pain management options.

No matter what anesthesia is chosen for patients with (severe) scoliosis, early preoperative evaluations are important to identify musculoskeletal and cardiopulmonary disease. Additionally, spinal imaging is suggested as a preoperative evaluation in these patients.

Severe scoliosis can affect every organ's function, but primary importance from anesthesiologists' perspective is the pulmonary and cardiovascular systems. During pregnancy, these systems can be additionally compromised, so the combination with scoliosis might be detrimental. In the following text these interactions and influence on several anesthesia aspects and organs are going to be discussed.

For the airway assessment altered anatomy of the airway, causing difficulty in laryngoscopy and intubation in severe scoliosis may be leading to hypoxia. Additionally, devices like halo traction may interfere with securing the airway.

For the pulmonary system the focus is on the pulmonary system assessment, evidence of pre-existing lung injury or pulmonary disease. Patients with severe scoliosis have a greater risk of developing chronic respiratory failure and pulmonary hypertension (4). For these patients, the alveoli in compressed lung regions become smaller than at residual volume, shunting the blood flow in extra alveolar vessels with a higher resistance, thus accentuating the pulmonary hypertension. In many cases, the deformity of the thoracic cage makes the lungs less compliant which leads to increase work of breathing even when the lungs are healthy. Restrictive lung disease, characterized by a decreased compliance and total lung capacity, may cause serious problems during perioperative mechanical ventilation (4).

Severe involvement of the cardiovascular system is seen when the structures of the mediastinum are shifted from their normal position, causing restrictive pericarditis and can limit any

potential increase in cardiac output. Moreover, the displacement or compression of the heart due to thoracic deformity may not allow increase in stroke volume, necessary during compromising conditions, such as surgery or late third trimester of pregnancy. At this point cardiac reserves are limited and may not be able to withstand the increased hemodynamic demand (4,5).

Scoliotic patients may also have higher incidence of congenital heart disease such as ventricular or atrial septal defects (mitral valve prolapse, like the one in our patient), ductus arteriosus, tetralogy of fallot or other defects. From this point of view, in severely scoliotic parturients, it is of critical importance to perform a preoperative assessment of the cardiovascular system, taking into consideration all of these factors. Minimum preoperative investigations include an electrocardiogram and echocardiography to assess cardiac morphology and evaluation of left ventricular function and pulmonary artery pressures. (4,5)

In serious scoliotic cases, such as in our case, the anesthesiologist should use the most appropriate type of anesthesia compatible with this disease. Generally, the risk of maternal mortality is higher with C-section under GA compared with NA, although the difference between the two is decreasing (5). During GA, care should be taken to avoid hypoxia, hypercapnia, acidosis, and anesthetic gases such as nitrous oxide as they increase pulmonary vascular resistance (6). Because of the decreased oxygenation, problems may arise during extubation, which may lead to the need for prolonged postoperative mechanical ventilation. Factors associated with increased risk of postoperative mechanical ventilation in scoliotic include: pre-existing neuromuscular disease, severe restrictive pulmonary dysfunction with a decreased vital (VC) and total lung capacity (TLC), congenital heart defects, right ventricular failure and pregnant obesity. There are some instances where GA may be a more appropriate choice, such as: maternal preference, severe maternal cardiopulmonary disease and unsuccessful NA technique.

On the other hand, the problems associated with NA are not negligible. The spine in patients with severe scoliosis is anatomically changed firstly because of the vertebral curvature and secondly because of the scar tissue and adhesions that are present due to previous surgeries. The anatomical landmarks are distorted which makes the identification of the midline of the back and the lumbar spinal levels more difficult. The interspinous space is harder to identify and the insertion of the spinal needle and the identification of the subdural space is more challenging, which can increase the number of required attempts and may lead to longer insertion time. Difficulty in performing NA may result in neural injury, spinal hematoma, post-dural puncture headache, or infection (7,8,9,10).

The injection of the local anesthetic can cause an unpredictable and patchy block and inadequate analgesia. Further, the subarachnoid space in pregnancy is decreased as a result of the increased intra-abdominal pressure and the presence of engorged veins in the epidural space, and as a result normal doses of local anesthetic can lead to higher levels of block which may lead to cardio-respiratory compromise - this is even more manifested as a result of the decreased cerebrospinal fluid volume that is associated with severe scoliosis (11). Baricity is suggested as

an important determinant in the spread of the local anesthetic in patients with scoliosis. When using a hyperbaric local anesthetic, the changes in the lumbar curvature can cause an asymmetrical spread of the solution, thus altering the normal distribution of the solution and causing an inadequate block. In that case, some studies also report successful SA in patients with severe scoliosis, when using isobaric Bupivacaine (12).

Due to the above discussed, for our case we used single-shot spinal anesthesia. Keeping this case in mind, we applied the following in accordance with this concept: 1. We used isobaric Bupivacaine because its dynamics in the cerebral liquor is less dependent on the spinal curve compared to the hyperbaric Bupivacaine that might show an uncertain spinal block, depending on the spinal curvature; 2. Taking into account an unexpected spreading of the blockade which is particularly risky in this case we use low dosage concept of local anesthetic combined with lipophilic Fentanyl as adjuvant (6 mg 0.5% Bupivacaine); 3. Given the time required (10 sec/1ml) for the application of the spinal injection, we provide an adequate sensory level and the satisfied surgical analgesia.

Conclusion:

We consider that severe scoliosis and previous surgery for scoliosis is not an absolute contraindication in parturients undergoing C-section under spinal anesthesia. Anesthesiologists should not be discouraged to use NA in such cases despite the challenges involved, these parturients are likely to benefit from single-shot spinal anesthesia. We consider that this technique offers some unique advantages over GA which could be riskier technique with this population, especially with patients with compromised pulmonary function. In addition, one must have an awareness of the proper treatment of unwanted side effects, which could be more pronounced when compared with healthy parturients.

References:

1. Ko J, Leffert L. Clinical implications of neuraxial anesthesia in the parturient with scoliosis. *Anesth Analg* 2009;109:1930-1934.
2. Kulkarni AH, Ambareesha M. Scoliosis and anesthetic considerations. *Indian J Anaesth.* 2007; 51(6): 486-495.
3. Gupta S, Singariya G. Kyphoscoliosis and pregnancy - A case report. *Indian J Anaesth.* 2004; 48(3): 215-220.
4. Cooper DM, Rojas JV, Mellins RB, et al. Respiratory mechanics in adolescents with idiopathic scoliosis. *Am Rev Respir Dis.* 1984; 130(1): 16-22.
5. Hawkins JL, Chang J, Palmer SK, et al. Anesthesia-related mortality in the United-States 1997-2002. *Anesthesiology* 2008;109: A206.
6. Goodman S. Anesthesia for non-obstetric surgery in the pregnant patient. *Semin Perinatol.* 2002;26:136-45.

7. Flaatten H, Berg CM, Brekke S, et al. Effect of experience with spinal anaesthesia on the development of post-dural puncture complications. *Acta Anaesthesiol. Scand.* 1999; 43(1):37-41.
8. Horlocker TT, McGregor DG, Matsushige DK, et al. A retrospective review of 4767 consecutive spinal anesthetics: central nervous system complications. *Anesthesia Analg.* 1997; 84(3): 578-84.
9. Horlocker TT, Wedel DJ. Infectious complications of regional anesthesia. *Best Pract Res ClinAnesthesiol.* 2008; 22(3): 451-75.
10. Auroy Y, Benhamou D, Bargues L, et al. Major complications of regional anesthesia in France: the SOS regional anesthesia hotline service. *Anesthesiology* 2002; 97(5): 1274-80.
11. Kardash K, King BW, Datta S. Spinal anaesthesia for Caesarean section after Harrington Instrumentation. *Can J Anaesth.* 1993;40(7): 667-9.
12. Gurayten Ozyurt, Elif Basagan - Mogol, Hulya Bilgin, et al. Spinal anesthesia in a patient with severe thoracolumbar kyphoscoliosis. *Tohoku J. Exp. Med.* 2005; 207, 239-242.

Апстракт

Изборот на анестезија кај родилки со сколиоза подложни на царски рез е поврзан со потенцијални ризици за мајката и плодот и како таков претставува предизвик за анестезиологот. Алтерацијата на мајчината физиологија и потенцијалните компликации поврзани со овој коморбидитет можат да предизвикаат потешкотии со општата, но и регионалната (спиналната) анестезија. Врз база на сите претходни согледувања, се смета дека еднократната спинална анестезија може да биде успешен тип на анестезија при тешкосколиотични родилки, особено кај оние со придружни респираторни болести. Во трудот се опишува случај на родилка со тешка форма на сколиоза која прима успешна еднократна спинална анестезија за ЦР на нашата клиника.

Клучни зборови: анестезија, спинална, Царски рез, тешка сколиоза.

PREOPERATIVE MAGNESIUM SULPHATE USAGE AS A MEDICAL CHALLENGE IN POSTOPERATIVE PAIN MANAGEMENT

Panovska-Petrusheva A¹, Mojsova Miovska M¹, Jovanovski-Srceva M¹, Toleska M¹, Gavrilovska A¹, Dimitrovski A¹, Mikjunovikj Lj¹, Golubikj-Nichevska S¹, Zafirova D¹

¹ Clinic for Anesthesia Reanimation and Intensive Care, Skopje, R. Macedonia

Abstract

Background: Magnesium is the fourth commonest mineral salt in the human organism and plays a fundamental role in many physiological processes, such as neuronal activity, muscular contraction, control of vasomotor tone and postoperative pain and hyperalgesia. We present a case of a 62-year-old man with a giant renal cyst (diameter of 25 cm), with enlarged abdomen and compression of the abdominal aorta and vena cava. The major challenge for us was to accomplish hemodynamic stability, as well as effective analgesia during the perioperative and postoperative period because of the severity of the case. Anesthetic management during induction and perioperative period was managed with Fentanyl, Rocuronium and Sevoflurane. The patient received 30 mg/kg MgSO₄ (total 3 gr) in 100 ml of isotonic saline solution over 15 minutes immediately after induction, before the surgical incision. During the procedure, the patient was hemodynamically stable. Before abdominal wall closure, the patient received 2 g Paracetamol i.v. and 100 mg Tramadol. After the surgery we analyzed the level of pain by a 10-point Visual Analogue Scale in the recovery room starting from the time of tracheal extubating and in the next 6-hour intervals, during the first 24 hours after extubation.

Conclusion: Intravenous magnesium sulphate, associated with balanced analgesia, reduces the postoperative pain and consumption of tramadol. In our opinion this combination can be a suitable multimodal technique for postoperative pain management.

Key words: Magnesium Sulphate, perioperative pain management, postoperative pain management.

Corresponding author: *Panovska-Petrusheva Aleksandra, Clinic for Anesthesia Reanimation and Intensive Care unit, Skopje, Macedonia .panovska_petrusheva@yahoo.com*

Background

Magnesium is the fourth commonest mineral salt in the human organism and plays a fundamental role in many physiological processes, such as neuronal activity, muscular contraction, control of vasomotor tone. It also has muscle relaxing effects, mostly by reducing the release of acetylcholine. (1) Magnesium is also a physiological blocker of the N-methyl-D-aspartate (NMDA) receptors and it can play a key role in postoperative pain and hyperalgesia. (2)

Case Report

We present a case of a 62-year-old man with a giant renal cyst (diameter of 25 cm), with enlarged abdomen and compression of the abdominal aorta and vena cava. The major challenge for us was to accomplish hemodynamic stability, as well as effective analgesia during the perioperative and postoperative period because of the severity of the case. We discussed couple of options for regional techniques for perioperative pain management, management of postoperative pain (such as placing an epidural catheter, TAP block etc.), but because of the enlarged abdomen, obesity of the patient and difficulty in obtaining adequate position, we were not able to place an epidural catheter. Our patient received diazepam 5 mg orally 2 hours prior to surgery. Before induction of anesthesia standard monitoring (pulse oximetry (SpO₂), NIBP, ECG and HR) were implemented with following measurements: NIBP=184/78, HR= 84; SpO₂=95. Anesthesia was induced using i.v. Midazolam 2 mg, 0,2 mg Fentanyl, and Propofol 200 mg. Tracheal intubation was facilitated with Rocuronium 50 mg. The patient received 30 mg/kg MgSO₄ (total 3 gr) in 100 ml of isotonic saline solution for 15 minutes immediately after induction, before the surgical incision. Anesthesia was maintained with end-tidal Sevoflurane concentration of 1,7-2,5%. Neuromuscular block was achieved with continuous infusion of 10 mg Rocuronium on every 40 minutes (approx.). The patient was mechanically ventilated with a mixture of air-oxygen 50% and ventilation was adjusted to keep end-tidal PCO₂ between 35-40 mmHg. The surgical team removed approximately 14 L of hemorrhagic fluid from the cystic formation. During the procedure the patient was hemodynamically stable, the blood pressure was maintained between 120-130/60-80; HR between (68-80 bpm). During perioperative period he received in total 0,35 mg Fentanyl. At the time of abdominal wall closure, which was about 30 minutes before the end of surgery an i.v. infusion of Paracetamol 2 g and a bolus dose of Tramadol 100 mg were infused over 10 minutes period. The level of pain was assessed by a 10-point Visual Analogue Scale in the recovery room starting from the time of tracheal extubation and in the next 6-hours intervals during the first 24 hours after extubation. VAS scale measurements were the following: Extubation VAS=0; 6 hours after extubation= VAS=0; 12 hours after extubation VAS=2; 16 hours after extubation VAS=2; 24 hours after extubation VAS=2/3. The patient did not receive any postoperative analgesia medications in the first 24 hours.

Discussion

Abdominal urologic surgery is associated with intense postoperative pain and a large amount of opioid analgesic drugs is often needed during the postoperative period for adequate pain relief.

However, opioids are associated with side-effects such as respiratory depression, ileus, nausea and vomiting, pruritus and urinary retention (1). So, we proposed one multimodal approach combining the effects of intravenous magnesium sulphate, tramadol and paracetamol. Magnesium sulphate has an analgesic effect by interference with calcium channels N-methyl D-aspartate receptors. It could be proved to be of vital significance in relation to postoperative pain, sensitization process and hyperalgesia, and that it is able to block the NMDA receptors during the entire postoperative period. (4) Pain relief after surgery continues to be a major medical challenge. Poorly managed postoperative pain may delay the discharge and recovery. A European survey which included 746 hospitals concluded that the management of postoperative pain was suboptimal. Meta-analyses have shown beneficial analgesic effects when opioids are combined with nonopioid drugs such as Paracetamol, NSAIDs, Ketamine and Magnesium. Analgesia from a bolus dose of Magnesium might result from its action as non-competitive NMDA receptor antagonist. While opioids can produce an antinociceptive effect, they can also alter central NMDA receptors which in turn lead to hyperalgesia and acute opioid tolerance. NMDA receptor antagonists such as ketamine or magnesium have been demonstrated to increase the analgesic effect of opioids probably by limiting the NMDA mediated facilitating processes. (1) Further on, Magnesium can bring about reduced postoperative pain and lower analgesic use. Tramadol consumption remained significantly lower in this patient who received magnesium. The role of NMDA receptor antagonists in the management of postoperative pain remains controversial. However, intravenous magnesium sulphate, associated with balanced analgesia, reduces postoperative pain and consumption of tramadol. In our opinion this combination can be a suitable multimodal technique for postoperative pain management.

Learning points

The management of postoperative pain should begin well before the patient undergoes surgery. The analgesic benefits of controlling the postoperative pain are generally maximized when a multimodal strategy to facilitate the patient's convalescence is implemented. The concurrent use of more than one class of analgesic drug or technique to target different mechanisms of analgesia has been advocated in order to improve analgesia through additive or synergistic effects while reducing opioid side-effects.

References:

1. Younes Aissaou, Youssef Qamous, Issam Serghini, et al. Magnesium sulphate: an adjuvant to tracheal intubation without muscle relaxation. *EJA* 2012.
2. P. Tauzin-Fin, M. Sesay, S. Delort-Laval et al. Intravenous magnesium decreases postoperative tramadol consumption after radical prostatectomy. *EJA* 2006.
3. Narinder Rawal. Current issues in postoperative pain management, review. *EJA* 2016
4. Tramer MR, Schneider J, Marti RA, et al. Role of magnesium sulfate in postoperative analgesia. *Anesthesiology* 1996; **84**: 340-347.

CHALLENGES IN DIFFICULT AIRWAY MANAGEMENT - AIRWAY MANAGEMENT IN A CASE OF PROLONGED ENLARGED THYROID GLAND (STRUMA PERMAGNA)

Trposka A¹, Stojkovska A¹, Kartalov A¹, Kuzmanovska B¹, Jovanovski-Srceva M¹, Kokareva A¹, Naumovski F¹, Cholancheski R²

¹ University Clinic for Anesthesia, Reanimation and Intensive Care, Skopje, R. Macedonia

² University Clinic for Thoracic and Vascular surgery, Skopje

ABSTRACT

Preoperative identification of patients with difficult airway is of vital importance in order to avoid unnecessary risks posed - to patients. Tracheal intubation in a patient with tracheal deviation and/or compression is challenging.

Difficult airway management is of paramount priority to the anesthesiologist and also to the surgeon. Failure to oxygenate or ventilate the patient's lungs during anesthesia can quite rapidly and predictably lead to brain damage or death.

Proper preoperative airway assessment, preparation and skillful management reduce the morbidity and mortality in difficult airway cases involving thyroid enlargement.

Key words: airway assessment, difficult airway, tracheal intubation.

Corresponding author: Angela Trposka, University Clinic for Anesthesia, Reanimation and Intensive Care, Skopje, R. Macedonia; +38975546213; e-mail: trposkaa@hotmail.com

Introduction

Appropriate airway management is an essential part of the anesthesiologist's role. It is claimed that thyroid surgery is associated with difficult airway and according different studies, from 5.3% to 11.6% of tracheal intubations for thyroid surgery are difficult (1). Thyroid gland diseases often are associated with thyromegaly, which, on one hand, lead to increased neck size, especially its circumference that is a known predictor of difficult intubation.

On the other hand, enlarged thyroid can compress the trachea and lead to its deviation and/or stenosis. Severe tracheal stenosis (over 70% of its normal lumen width) results in progressive steady-state dyspnea and such patients are at greatest risk of various complications during airway management, including total airway obstruction (2,3). Several techniques are available in order to select the level of obstruction. However, it depends on the anesthesiologist's expertise and familiarity. Tracheal intubation in a patient with tracheal deviation and/or compression is challenging. The distorted airway anatomy makes orotracheal intubation with rigid laryngoscopy difficult (4). Preoperative identification of patients with difficult airway is of vital importance in order to avoid unnecessary risks posed on to patients, but there is no ideal or precise scoring system by which difficulty of ventilation, laryngoscopy or intubation can be predicted (5).

Hereby, we present a case in which this technique allowed the safe management of a patient with a known difficult airway due to a massive thyroid tumor complicated by obesity and a short neck.

Case Report

A 63 years old man was presented with complaints of gradually increasing swelling on the left side of the neck for past 20 years. Since last six months, goiter hugely increased with subsequent development of shortness of breath and hoarseness of voice. He was known as hypertensive in a steady state with no other systemic disease. Physical examination revealed a man who was severely obese BMI > 35, with blood pressure 150/90 and HR in normal range. Chest auscultation revealed normal vesicular breathing with no abnormal sounds. Other systemic examination did not reveal any abnormality.

He had an obvious neck swelling on the left side, measured approximately 96×71 mm broadly extending to the anterior and right lateral aspect of the neck. The thyromental distance was <6,5 cm, neck mobility was restricted, and neck extension was severely impaired.

Mouth opening was adequate with Mallampati grade scale 4. A thyroid hormone profile confirmed the euthyroid status of the patient during routine preoperative test. Direct laryngoscopy revealed swelling of the epiglottis and mild restriction of the vocal cords mobility. A huge tumor mass in the whole neck compartment, between trachea - medially and v. jugularis interna, a carotid m. sternocleidomastoideus laterally was shown on computer tomography scan examination. The mass was extended into the superior mediastinum compressing trachea to the right with a little decrease in tracheal lumen.

Because of the anticipated difficult mask ventilation due to the huge size of the tumor and difficult laryngoscopy and intubation, awaken fiber-optic intubation was planned. Because the patient didn't cooperate during the intubation, anesthetizing him was necessary. Patient was administered 3 mg Midazolam, 150µg Fentanyl, 50 mg Rocuronium and 250 mg Propofol. The fiberoptic - bronchoscope was inserted through one of the nostrils and advanced towards the laryngeal inlet and then positioned above the carina. Endotracheal tube 7,5 mm was then threaded over the FOB and FOB was removed. The breathing circuit was attached and was maintained with Propofol infusion 40 ml/h, Remifentanyl 20 ml/h and Rocuronium. During the intervention was also given 200 mg Hydrocortisone. Total thyroidectomy was performed. The patient remained hemodynamically stable throughout the procedure. After careful consideration of the fact that problems with extubation were possible due to the longer duration of the intervention, the edema of the larynx and the possible postoperative bleeding, it was decided that a tracheostomy should be done before awaking the patient from anesthesia. A tracheostomy tube was inserted through the stoma. Patient stayed in the ICU for two days on the mechanical ventilation. After two days we had successful weaning from the ventilator.

Discussion

There are multiple modalities to manage the difficult airway in the patient with thyroid enlargement. However, it depends on the anesthesiologist's expertise and familiarity. If the enlargement is small, and there is no deviation or compression, and if the airway examination is normal, then we would proceed for a normal airway management. Bouaggad et al. found in his study that there was an easy tracheal intubation in 36.9% of the patients and mild tracheal difficult intubation in 57.8% of the patients.

However, 5.3% patients have moderate to major difficult airway (6,7). In order to anticipate and manage patients with difficult airways, a strategy needs to be developed. This includes identifying the potential problem, considering different options, and selection of an appropriate plan in the particular scenario of the individual patient. The patient should be informed about the options and the advantages and disadvantages of each one. Finally, there should be alternative plans in case of failure of the initial one. Thyroidectomy is indicated with the aim of securing the airway to avoid respiratory distress. Thyroidectomy in such difficult circumstances is associated to difficulties in airway management during and after surgery. Some of these difficulties are due to trachea obstruction, tracheomalacia and injuries to the vocal cords.

Difficult airway management is of paramount priority to the anesthesiologist and also to the surgeon. Failure to oxygenate or ventilate the patient's lungs during anesthesia can quite rapidly and predictably lead to brain damage or death. Comorbid conditions and some patient characteristics, such as laryngeal edema, anterior neck swellings, short neck and obesity, might further aggravate the airway difficulties. In such circumstances, difficulty in intubation is expected (8,9). Significant increase in incidence of difficulty in endotracheal intubation in patients presenting

with Mallampati class 3/4 airway and neck mobility less than 90° has been demonstrated during thyroid surgeries (7). Our circumstances were in line with this finding as the patient presented with Mallampati grade 4 and restricted neck extension and mobility during preoperative anesthetic assessment.

Preoperative imaging studies give us details of the tracheal deviation and a light degree of tracheal compression. Keeping the clinical symptoms in mind and imaging studies, induction of general anesthesia could be risky because it may precipitate complete airway closure and make facemask ventilation and tracheal intubation impossible due to chronic pressure. (9) Keeping in mind the advantages and drawbacks of all procedures for management of the difficult airway, the first choice in this case was an awaken fiber-optic intubation. This can prevent conditions like "can't ventilate and can't intubate" scenarios occurring after induction of anesthesia due to a complete tracheal collapse. Tracheostomy was the second choice.

Sendasgupta et al. and Tan and Esa stated in their studies, that awaken fiber-optic intubation offers more hemodynamic stability, better patient tolerance and patency of the airway. (10) Eldawlatly et al. stated that the success of awake fiberoptic is based on preoperative airway assessment that predicts difficult airway, proper planning, and it is well-tolerated if explanation is given to the patient about procedure, risk and comorbidities. (11)

Our patient did not tolerate well the awaken fiber-optic intubation and we couldn't secure a good cooperation. We had to give him anesthesia in order to have a successful intubation, minimizing the possible risks during this procedure. An awaken extubation is of high importance in the cases like this one. Considering the possible problems with the extubation due to the longer duration of the intervention, the fact that the supraglottic swelling started to go down after thyroidectomy and the high intraoperative blood loss, it would be insufficient to keep this explanation and not having the equipment for fiberoptic bronchoscopy within reach in case of a need of a reintubation. Thereby, it was decided that a tracheostomy should be done before awaking the patient from anesthesia.

Conclusion

Proper preoperative airway assessment, preparation and skillful fiberoptic bronchoscopy management reduce the morbidity and mortality in difficult airway cases involving thyroid enlargement.

References:

1. Loftus PA, Ow TJ, Siegel B, et al. (2014) Risk Factors for Perioperative Airway Difficulty and Evaluation of Intubation Approaches Among Patients With Benign Goiter. *Annals of Otology, Rhinology & Laryngology* 123: 279-285.).
2. Dy B, Wise K, Farley D, et al. Extreme tracheal compression due to substernal goiter: surgical and anesthetic management. *World J Endocr Surg.* 2012;4(2):71-3.

3. Piao M, Yuan Y, Wang Y, et al. Successful management of trachea stenosis with massive substernal goiter via tracheobronchial stent. *J Cardiothorac Surg.* 2013;15(8):212. doi: 10.1186/1749-8090-8-212.
4. Chetankumar B. Raval, Syed Abdul Rahman. Difficult airway challenges-intubation and extubation matters in a case of large goiter with retrosternal extension. *Anesth Essays Res.* 2015 May-Aug; 9(2): 247–250.
5. Amare Gebregzi Hailekiros*, SleshiWorknehAbiy and HabtamuKassahunGetinet. Magnitude and Predictive Factors of Difficult Airway in Patients Undergoing Thyroid Surgery, From a Goiter Endemic Area. *J AnesthClin* 2015; 6:584).
6. Bartolek D, Frick A. Huge multinodular goiter with mid trachea obstruction: Indication for fiberoptic intubation. *Acta Clin Croat* 2012;51:493-8.
7. Bouaggad A, Nejmi SE, Bouderk MA, et al. Prediction of difficult tracheal intubation in thyroid surgery. *AnesthAnalg* 2004;99:603-6.
8. Farling PA. Thyroid disease. *Br J Anaesth.* 2000; 85:15-28.
9. Lacoste L, Gineste D, Karayan J, et al. Airway complications in thyroid surgery. *Ann OtolRhinolLaryngol.* 1993; 102:441-6.
10. Tan PC, Esa N. Anesthesia for massive retrosternal goiter with severe intrathoracic tracheal narrowing: The challenges imposed - A case report. *Korean J Anesthesiol* 2012;62:474-8.
11. Eldawlatly A, Alsaif A, AlKattan K, et al. Difficult airway in a morbidly obese patient with huge goiter: A case report and review of literature. *Internet J Anesthesiol* 2006;13:1. Available from: <https://www.ispub.com/IJA/13/1/8490>. [Last accessed on 2015 Feb 08].

СЛИКА

АПСТРАКТ

Предизвици при тежок ервеј кај пациент со голема струма пер магна

Предоперативната проценка кај пациент со тежок дишен пат е од витално значење со цел да се избегнат непотребните ризици кои може да настанат. Трахеалната интубација кај пациент со трахеална девијација и/или компресија претставува предизвик. Тежок дишен менаџмент е најважен приоритет за секој анестезиолог. Неуспехот да се вентилира пациентот за време на општата анестезија, многу бргу може да доведе до оштетување на мозокот или смрт. Правилната предоперативна процена на дишниот пат, препознавањето, подготовката и менаџирањето на потенцијалните потешкотии, како и вештото управување, го намалуваат морбидитетот и морталитетот во случаи кај пациенти со тежок дишен пат.

ANESTHETIC MANAGEMENT FOR PATIENT WITH TRACHER COLLINS SYNDROME SCHEDULED FOR ELECTIVE CESAREAN DELIVERY

M. Zlatkova¹, D. Karagova¹, E. Ivanov¹, R. Popovska¹.

¹ University Clinic of Gynecology and Obstetrics, University “Saints Cyril and Methodius “, Medical Faculty, Skopje, Republic of Macedonia

Abstract

Tracher Collins Syndrome is an autosomal dominant genetic disorder, as a result from mutation in TCOF1 gene. Other names for Treacher Collins Syndrome include Franceschetti-Zwahlen-Klein syndrome, mandibulofacial dysostosis (MFD), zygo-auro-mandibular dysplasia and Treacher Collins Franceschetti syndrome. These changes cause deformities of the facial bones and occurrence at antimongoloid slant of the eyes, micrognathia and deformity of the ears. Complications may include breathing problems, seeing problems, cleft palate and hearing lost. Diagnosis of TCS is made through clinical evaluation, radiographic examination and molecular genetic analysis. Treatment is tailored to the specific needs of each individual by a multidisciplinary craniofacial management team. We report a case of TCS with second twin pregnancy achieved with IVF. The first pregnancy ended with c-section (and death of the newborn after 23 days of delivery due to dysmorphia – TCS on the fetus). The patient was hospitalized at our clinic for evaluation and ending of pregnancy with elective section cesarean. The patient was managed successfully under regional anesthesia which is generally preferred technique to general anesthesia, in order to avoid potential complications associated to difficult airway management. The patient was left home on the fifth postoperative day with her two healthy children.

Keywords: genetic disorder, C-section, spinal anesthesia, Tracher Collins Syndrome

Correspondence author: Milica Zlatkova, University Clinic of Gynecology and Obstetrics, University “Saints Cyril and Methodius “, Medical Faculty, Skopje, Republic of Macedonia, milica.zlatkova@gmail.com

Case Report

A 33-years old woman with Tracher Collins syndrome (TCS) with second gravidity was hospitalized in our clinic. She was in 36th week of gestation when hospitalized, following in vitro fertilization (IVF) and embryo-transfer (ET) pregnancy. She had an absolute indication for cesarean delivery, because her IVF finished with twin pregnancy and also the patient had previous C-section.

A pre-anesthetic evaluation showed patient's pulse rate of 86/beats/min, blood pressure of 135/85 mmHg and oxygen saturation (SpO₂) of 97%. Patient had eyes that slant downwards, sparse eyelashes, unusually formed ears, deformities of the bones of the face, very small jaw and chin (micrognathia), bad occlusion on the teeth, a Mallampati IV and a normal range of neck motion.



Figure 1

The electrocardiograph displayed no abnormalities, systolic and diastolic blood pressure was in the normal range. Laboratory tests including a full blood-count were normal, renal function tests were normal, while screening for gestational diabetes was negative. The blood coagulation tests showed that the prothrombin time (PT) and activated partial thromboplastin time (APPT) were within the normal range. Due to the specifics of the patient's state a decision for spinal anesthesia was made.

Routine preoperative care included anesthesia consent, one dose of Ranitidine and Metoclopramide on the day of the surgery, six hours of fasting, 18-gauge cannula intravenous access was obtained, volume preloading with 500 ml of normal saline was done and standard anesthetic monitoring. The difficult airway cart was immediately available. Under septic conditions, spinal anesthesia was performed in the sitting position. The subarachnoid space was located using a pencil-point spinal needle (27-gauge), by needle-through needle technique. After the onset of a clear cerebrospinal fluid, 0,5% Bupivacaine 2 ml with 20 micrograms of Fentanyl was administered intrathecally.

The patient was placed in left side position, oxygen supplementation was administered via a Ventura mask, while SpO₂ remained in the range of 98-100%. After 5-6 minutes a sensory block is provided to the level Th4. All cardiovascular parameters remained stable during block development and surgery. A healthy girl, weighted 2000 gr and a boy weighted 2170 gr with normal Apgar scores in the first and in the fifth minute were delivered.

Adequate uterine contraction was achieved with oxytocin infusion after delivery of the placenta. Blood loss was approximately 300-400 ml and urine output 400 ml. After recovery room criteria were met, the patient was transferred to the ward. Postoperative analgesia was achieved with a regular intravenous analgesia regimen. She was discharged home on the fifth day after the operation.

Discussion

Tracher Collins Syndrome is genetic disorder of neural crest cell proliferation, involving the first and the second branchial arches. This syndrome affects the development of bones and other tissues of the face. TCS is also known as mandibular-facial dysostosis, characterized by hypoplasia of the maxillary, zygomatic and mandibular bone (1,2).

The signs and symptoms of this disorder vary greatly ranging from almost unnoticeable to severe. While some individuals may experience very mild symptoms, others have extremely severe symptoms that may have serious consequences, such as life-threatening airway problems. Otherwise, these people usually have normal intelligence. Tracher Collins Syndrome affects 1 in 50000 people. Approximately 40% of people with TCS have a parent, or rarely two parents who carry affected genes. In this case the gene abnormality causing TCS is inherited. The remaining 60% of the people develop TCS as the result of a new mutation – a mutation for the first time. It is named after an English surgeon and ophthalmologist called Edward Treacher Collins who was the first to explain its essential traits in 1900. The Treacher Collins Syndrome is often caused by a mutation in TCOF1 gene, which accounts for 81-93% of the cases, but can also be a result of POLRIC1 or POLRID mutations, which account 2% of all cases (3,4).

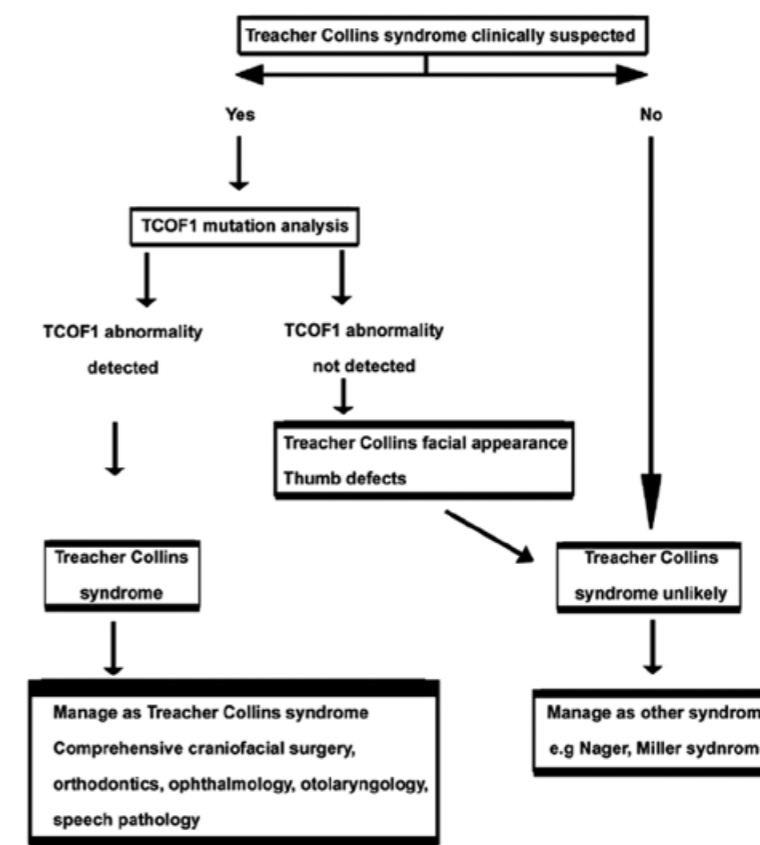


Figure 2. Diagnostic algorithm of TCS and its subsequent management.

The diagnosis of TCS is made through clinical evaluation, radiographic examination and molecular genetic analysis. Craniofacial deformities in pregnancy can be detected using

ultrasonography (5,6,7). There is no cure, but skull and face surgery can improve speech and create a more normal appearance. Treatment is tailored to the specific needs of each affected person. Ideally the treatment is managed by a multidisciplinary team of craniofacial specialists [figure 2].

Craniofacial abnormalities often affect airway management, making mask ventilation and tracheal intubation difficult or even impossible to achieve, if there are temporomandibular joint abnormalities present. Therefore regional anesthesia may be more preferable than general anesthesia in these patients.

Because of that, in our case we decided to perform spinal anesthesia for C-section. Neuraxial anesthesia is generally preferred over the general anesthesia in a parturient with Treacher Collins syndrome. The difficulty for intubation increases as the patient with Treacher Collins Syndrome ages and requires re-evaluation of the airway prior each anesthetic decision (8,9).

If general anesthesia is performed, alternatives to tracheal intubation should be considered. Classical laryngeal mask airway (LMA) can provide an adequate airway including the urgent C-section (10). Ferson et al. reported the use of LMA-Fastrach as a conduit for blind intubation in 254 patients with difficult – to-manage airways and showed a success rate for this device of 75,5% on the first attempt with the added use of fiber-optic bronchoscope (10,11,12). A fiber-optic endoscope and surgical airway equipment should be readily available to. In these patients, previous preoperative assessments together with a complete clinical history are very important in order to get the best anesthetic strategy and airway management.

The conclusion in our case report is that for the pregnant women with TCS, where the pregnancy should be completed with elective c-section, spinal anesthesia is a method of choice because of possible troubles with intubation. These pregnancies are classified as high-risk, and can be managed successfully under spinal anesthesia.

References

1. Fazen LE, Elmore J, Nadler HL. Mandibulo-facial dysostosis (Treacher Collins syndrome) *Am J DisChild* 1967; 113:405-410.
2. Dixon J, Trainor P, Dixon MJ. Treacher Collins syndrome. *Orthod. Craniofac. Res.* 2007, 10(2):88-95.
3. The Treacher Collins Collaborative Group Positional cloning of a gene involved in the pathogenesis of TCS *Nat.Genet.* 1996;12(2):130-136.
4. Poswillo D. The pathogenesis of the Treacher Collins syndrome (mandibulo-facial dysostosis) *Br J Oral Surg.* 1975;13:1-26.
5. Edwards SJ, Fowle A, Cust MP, et al. Prenatal Diagnosis in Treacher Collins syndrome using Linkage analysis and ultrasound imaging. *J Ned Genet.* 1996;33:603-606.
6. Pereira DC, Bussamra LC, Araujo Junior E, et al. Prenatal diagnosis of a Treacher Collins syndrome using three-dimensional ultrasonography and differential diagnosis with other

acrofacial dysostosis syndromes. *Case rep. Obstet. Gynecol.* 2013; 2013:203976 doi:10.1155/2013/203976.2013apr4.

7. Jurcovic D, Grubocak K, Campell S. Ultrasound features of normal early pregnancy development. *Curr Opin Obstet Gynecol.* 1995;7:493-504.
8. Inagawa G, Miwa T, Hiroki K. The change of difficult intubation with growth in a patient with TCS. *Anesth. Analg.* 2004;99:1874.
9. Nargoziari C. The airway in patient with craniofacial abnormalities. *Pediat. Anesth* 2004;14:53-9.
10. Ferson DZ, Rosenblatt WH, Johansen MJ, et al. Use of the intubating LMA-Fastrach in 254 patient with difficult-to – manage airways. *Anesthesiology* 2001;95:1175-81.
11. Takita K, Kobayashi S, Kozu M, et al. Successes and failures with the laryngeal mask airway (LMA) in patient with TCS-a case series. *Can J Anaesth* 2003;50:969-70.
12. Paloma Morillas; Inocencia Fornet; Isabel De Miguel. Airway Management in a Patient with Treacher Collins syndrome Requiring Emergent Cesarean Section. *Anesth. Analg.* Jul 2007.105(1): 294.

TACHYCARDIA - BRADYCARDIA SYNDROME IN A PATIENT UNDERGOING PERTROCHANTERIC FRACTURE REPAIR UNDER SPINAL ANESTHESIA

Naumovski F¹, Kartalov A¹, Kuzmanovska B¹, Shosholcheva M², Trposka A¹, Dimitrovski A¹, Petrusheva A¹, Toleska D. M¹

¹ PHI University Clinic of Anesthesia, Reanimation and Intensive Care – Skopje

² PHI University Clinic for Surgical Diseases St. Naum Ohridski - Skopje

ABSTRACT

Background: Sick sinus syndrome (SSS) is an abnormality of a cardiac impulse formation as a result of sinus node dysfunction that could be presented as a diverse heart rate and rhythm abnormalities. SSS is the most common in the elderly people. In most of the cases the etiology of the SSS remains unknown, but the majority of the patients are experiencing some stage of coronary artery disease (1).

Case Report: We present an 89 years old female patient undergoing pertrochanteric fracture repair under spinal anesthesia. Her preoperative evaluation did not reveal any pathologic findings. All vital signs were stable prior to the surgery. The patient has received 2.4 ml of Bupivacaine 0.5% and 10 mcg of Fentanyl. Dural puncture was done in an aseptic technique at the L3-L4 level and clear liquor was seen prior to the anesthetic application. The first hour of the surgery went uneventful, after what abrupt onset of tachycardia of 109bpm was seen followed by bradycardia of 48bpm. The episodes of tachycardia followed with bradycardia were repeating till the patient entered a bigeminy rhythm with the lowest hearth rate of 45, after what 0.5 mg of atropine was given and restoration of normal sinus rhythm was seen. The patient was monitored postoperatively in PACU and followed up at the Traumatology ward while there were not seen any vital signs deterioration.

Discussion: We've researched PubMed from 1994-2017 and we've found 8 case reports in patients undergoing general anesthesia, one undergoing general and epidural anesthesia and one under spinal anesthesia. Eight of 10 patients were previously healthy without known cardiac disease and one with peripheral artery disease. Different types of conduction and heart rate abnormalities, including asystole, were seen in all of the cases after induction of the patients under anesthesia. In our case during the surgery the patient developed multiple episodes of tachycardia followed with bradycardia without subjective discomfort. The resolution of the tachycardia-bradycardia syndrome after giving the 0.5 mg of atropine shows a possible relationship between the local anesthetic application and the onset of the SSS manifestation.

References: 1. Brignole M1.; Sick sinus syndrome; Clin Geriatr Med. 2002 May;18(2):211-27.

Learning points: SSS can be precipitated perioperatively because of increased vagal tone caused by anesthesia or surgical intervention. As general anesthetics, local anesthetics could also trigger intraoperative manifestation of SSS.

Key words: anesthesia, sick sinus syndrome.

Corresponding author: Filip Naumovski PHI University Clinic of Anesthesia, Reanimation and Intensive Care – Skopje. E-mail: fnaumovskimd@gmail.com

Introduction

Sick sinus syndrome is a conduction abnormality of the heart with the most frequent incidence in the elderly patients. In most of the cases is latent and unrecognized till the abrupt onset of the symptoms. Sick sinus syndrome can be presented as a different kind of conduction disorder including: sinus bradycardia, sinoatrial block, tachycardia-bradycardia syndrome, or unexpected sinus arrest. Symptoms are often intermittent, changeable, and unpredictable. The term sick sinus syndrome should be reserved for patients with symptomatic sinus-node dysfunction. Sinus-node dysfunction is associated frequently with diseases of the autonomic nervous system, and autonomic reflexes play a major role in the genesis of the syncope (1). Sick sinus syndrome could be a co-morbidity in a patient with well established diagnosis of CAD (coronary artery disease), but it can be present in patients without any previous history of cardiac disease as well. The latent form, in patients without any previous history of cardiac disease, passes unrecognized in most of the cases. The electrocardiogram and 24-hour Holter monitoring are the diagnostic settings needed for establishing the diagnosis of Sick sinus syndrome. Atrial pacing is the most superior therapeutic measure in treating Sinus node dysfunction. Because of the sinus node dysfunction, the patients with Sick sinus syndrome and especially the undiagnosed forms of this conduction abnormality could be an enormous challenge for the anesthesiologist in the daily practice, putting the patients at risk. The tendency of having sinus bradycardia or sinoatrial block could be precipitated with the usage of the parasympathomimetic drugs, hypnotics, opioids and volatile anesthetics while patient with Sick sinus syndrome is undergoing general anesthesia.

Case Report

We present an 89 years old female patient undergoing pertrochanteric fracture repair under spinal anesthesia. The patient has previous history of Hypertension treated with Enalapril 10 mg (twice daily) and Dementia which is treated with Donepezil. There were no data for any other comorbidities, or previous diagnosis of any cardiac disease. The patient never has had any type of surgical intervention. There was no history of allergy and she was a non-smoker. The patient underwent the regular pre-operative evaluation and medical check up. Standard laboratory analysis and ECG were done preoperatively. She had a BP of 135/85 and normal chest and heart sounds.

Lab results were without any serious deviations except the finding of leukocytosis. 12 channel ECG has been done and has shown: sinus rhythm, with HR of 60 and normal morphology of the P wave, QRS complex and the ST-T segment in all leads.

At the day of the surgery the patient was monitored with ECG, intermittent blood pressure measurement and pulse oxymetry. All the vital signs were stable prior to surgery. The patient has received 2.4 ml of Bupivacaine 0.5% and 10 micrograms of Fentanyl. Dural puncture was done at the L3-L4 level in an aseptic technique, and clear liquor was seen prior to application of the anesthetic. The 22G spinal needle was used. After 10 minutes of giving the spinal anesthetic the BP fall from 145/95 to 115/75 was noted. The first hour after the application of the anesthetic went uneventful, the patient has been hemodynamically stable without any vital signs deviations. One hour after application of the anesthetic, there was sudden onset of rapid heart rate rise from 58 to 112 and after that abrupt spontaneous resolution of the tachycardia from 112 to 54 bpm. The patient was awake and not experiencing any pain, nor breathing difficulties. After the resolution of the first episode of tachycardia, the patient had experienced another episode of abrupt rise of the heart rate from 54 to 109 followed with spontaneous falling of the heart rate to 48 bpm. The episodes of rapid and abrupt onset of changes in heart rate have continued without any significant changes in the blood pressure levels, neither any electrocardiographic changes in the P, QRS and ST-T segment morphology. The highest seen heart rate value was 113 and the lowest one was 45. The time duration of the episodes of spontaneous tachycardia followed by bradycardia was approximately 25 minutes. At the end of the episode of heart rate disturbances, when the lowest value of 45bpm was reached, the onset of bigeminy was noted on the ECG. 0.5 mg of Atropine was given to the patient immediately, after what restoration of normal sinus rhythm and termination of the episodes of tachycardia and bradycardia was seen. After giving the Atropine, there were not any deviation in the heart rate and other vital signs till the end of the surgery. After the termination of the surgery the patient was transferred to the PACU to be monitored postoperatively in the following 2 hours. During the PACU stay the patient has not experienced any kind of vital signs deterioration. Postoperative ECG in PACU has been made without any signs of cardiac suffering, or conduction abnormalities. Because of the evident intra-operative presentation of tachycardia – bradycardia syndrome and suspicion of an existing Sinus sick syndrome, we've ordered a Cardiology consultation to reveal the cause of the heart rate and conduction disturbances. After the PACU stay the patient in a hemodynamically stable state was transferred to the Traumatology ward for further medical care.

Discussion:

We present a case report of patient who showed typical clinical features of sick sinus syndrome (even though we didn't have cardiological confirmation of the same) and therefore in the text that follows, we are going to elaborate and discuss the physiological aspects and the importance of these aspects on anesthesia and anesthesiology practice.

Sick sinus syndrome as an abnormality of a cardiac impulse formation resulting from sinus node dysfunction is a cause of impaired pacemaking function. The impaired pacemaking function of the sinus node could be presented as diverse abnormalities in the heart rate and rhythm with or without any symptoms. Rhythm abnormalities in patients with this syndrome could include sinus bradycardia, sinus arrest or combinations of sino-atrial and atrioventricular nodal conduction impairment, but also atrial tachyarrhythmia could be present. Sick sinus syndrome is not a disease with a single etiopathogenesis, but rather a collection of cardiac conditions in which the electrocardiogram (ECG) show presence of sinus node dysfunction (2). Sinus node dysfunction with an atrial heart rate inappropriate for the physiologic requirements is typical finding in patients with SSS. Sinus sick syndrome (SSS) occurrence is the most common in the elderly patients, where the mean age of patients with this condition is 68 years. The syndrome occurs in one of every 600 cardiac patients older than 65 years (2). In most of the cases the etiology of the SSS remains unknown. Despite the idiopathic SSS, a lot of patients presented with sinus node dysfunction are having some stage of coronary artery disease, are experiencing acute myocardial infarction, or have experienced a myocardial infarction in the past. SSS occurring during an acute myocardial infarction could have a transient character. In patients with well known coronary artery disease chronic ischemia may lead to fibrosis and might be a cause for symptoms of sick sinus syndrome for months to years after myocardial infarction.

In most of the cases this condition is asymptomatic unless they are some trigger factors that could precipitate the onset of impaired generation and conduction of cardiac impulses that could lead to impaired cardiac output and decreased cerebral perfusion. SSS could be presented with symptoms like syncope, dizziness or palpitations, as well as symptoms caused by complications, such as congestive heart failure, angina pectoris and cerebral vascular accident. Peripheral thromboembolism and stroke could occur in a patient with bradycardia-tachycardia syndrome and may be related to dysrhythmia-induced genesis of emboli (2). Patients with left ventricular failure or pulmonary edema presented with bradycardia, may be highly suggestive of existence of a sick sinus syndrome. Some patients can experience tachycardia followed with flushing of the face, palpitations and retrosternal pressure. Lethargy, irritability, nocturnal wakefulness, errors in judgement, memory loss, fatigue and lightheadedness could also be present in patients with SSS. Sinus-node dysfunction frequently is associated with diseases of the autonomic nervous system, and autonomic reflexes play a major role in the genesis of syncope (1). Medications such as digoxin, beta-blockers, and calcium blockers may initiate or worsen the manifestations of SSS (3). There is diversity in the electrocardiographic manifestations of sinus node dysfunction, so the presence of atrial tachyarrhythmia, atrial bradyarrhythmia or even alternating bradyarrhythmia and tachyarrhythmia can be found on the ECG trace. Patients with SSS may experience sinus bradycardia, sinus arrest with or without junctional escape, ectopic atrial bradycardia, sinoatrial block and atrial fibrillation with slow ventricular response as a form of supraventricular bradyarrhythmia due to sinoatrial node dysfunction. They also can experience some sort of

supraventricular tachyarrhythmias as paroxysmal supraventricular tachycardia, atrial flutter or fibrillation, and atrial tachycardia. The most common tachydysrhythmia in patients with sinoatrial node dysfunction is atrial fibrillation. In older patients with advanced form of sick sinus syndrome tachycardia-bradycardia syndrome is more common finding (2). SSS associated symptoms may be worsened in patients receiving digitalis, beta blockers, verapamil, methyldopa, clonidine or any antiarrhythmic agents (3). Clinical manifestation of sinoatrial node dysfunction could be precipitated perioperatively also, because of increased vagal tone due to practicing anesthesia or because of the surgical intervention (4).

Because of the unspecific symptomatology the diagnosis of the SSS could be made only with concordance of the onset of the symptoms and 12 channel ECG or Holter findings. Cardiac pacing is the most powerful therapy; physiologic pacing (atrial or dual-chamber) has been shown definitively to be superior to ventricular pacing (1). Atrial pacing is a preferred therapeutic measure because is associated with a lower incidence of thromboembolic complications, atrial fibrillation, heart failure, cardiovascular morbidity and mortality comparing with the ventricular pacing (2). Progression of SSS is the mostly dependent on the presence and severity of associated coronary or hypertensive heart disease.

According to Thomas A. Csepe et al., the process of intranodal fibrosis could be a serious modulator of the sinoatrial function as important as in sinoatrial dysfunction. In their study they have reached to a conclusion that the intranodal fibrosis is a physiologic process that starts in an infant heart and has a protective effect of normal cardiac function unless it is up-regulated and precipitated from some cardiac disease. Heterogeneous distribution of fibrosis within and around the sinoatrial node (SAN)pacemaker complex plays a crucial role in proper SAN function by providing: structural and functional integrity and stability of the SAN, electrical insulation of SAN myocyte clusters and the entire SAN complex, preventing depression of pacemaker automaticity from the hyperpolarizing effect of the surrounding atria and mechanical protection from pathophysiological heart rate changes due to stretch and pressure from the contractile force of the atria (5). In cardiac diseases the up-regulation of the fibrosis could lead to slowed SAN rhythm due to fibrotic replacement of pacemaker cells, beat-to-beat variability and slowed intranodal conduction, due to decreased electrical coupling between SAN myocytes and pacemaker cell clusters and long pauses due to source-sink mismatch causing exit block and SAN reentry due to fibrosis-induced conduction dissociation in the SAN. All of the above mentioned pathological changes can lead to arrhythmias such as tachycardia-bradycardia syndrome and atrial fibrillation. The amount and severity of fibrosis in the sinoatrial node is inversely correlated to the heart rate, while there is positive correlation of the age and the heart size, on one hand and the fibrosis, on the other (5). Increasing the fibrotic process with age could be a reasonable explanation why sick sinus syndrome occurs dominantly in elderly patients and in patients with previous cardiac disease, as in our case.

We've made a research on Pub Med Central for case reports of manifestation of Sick sinus syndrome in a patient under anesthesia. We've found eight case reports from 1994 to 2017 in

patients undergoing general anesthesia and one undergoing mixed general and epidural anesthesia. We've not found any case report of presentation of Tachycardia-bradycardia syndrome in a patient under spinal anesthesia. Seven of eight presented patients were previously healthy without any known cardiac disease, except one who had well established diagnosis of ischemic cardiac disease. All of them had normal preoperative ECG findings, except two patients presented with sinus bradycardia due to increased intracranial pressure. Different types of conduction and heart rate abnormalities, including asystole, were presented in all of the cases after induction of the patients under general anesthesia. The diagnosis of SSS was ruled out postoperatively due to cardiology consult. During the anesthetic management of intra and postoperative period in 4 of 8 patients temporary or permanent pacing was performed as a therapeutic measure. Temporary pacing is mandatory when anesthesia is given to surgical patients with latent sick sinus syndrome (6,7).

Lacking the diagnosis of SSS confirmation by the cardiologist, due to health care system insufficiency, left us to assume that in our patient the episodes of tachycardia and bradycardia were caused by eventually present underlying SSS. In our case during the surgery the patient developed multiple episodes of abrupt tachycardia immediately followed by an episode of bradycardia without subjective discomfort of the patient. She was awake and not experiencing any breathing difficulties or oxygen desaturation during the period of heart rate deviations, which excludes the possibility of high spinal block. The time of onset of the tachycardia – bradycardia syndrome after 60 minutes of the application of the anesthetic, also denies the possibility of high spinal block. The resolution of the tachycardia-bradycardia syndrome after giving the 0.5 mg of atropine because of the onset of bigeminy at 45bpm shows a possible relationship between the local anesthetic induced temporary sympathectomy and parasympathetic predominance, on one hand and the onset of tachycardia-bradycardia syndrome as a form of SSS, on the other hand. This means that not only anesthetics used during general anesthesia, but also local anesthetics could be involved in the process of triggering the onset of clinical manifestation of previously clinically silent sick sinus syndrome. Obviously, the spinal anesthetic induced parasympathetic predominance and sympatholysis lead to peripheral vasodilatation, decreased venous preload and decreased cardiac output, which together with the decreased atrial stretching due to decreased venous preload were the main factors that triggered the onset of sinus node failing presented as a tachycardia-bradycardia syndrome.

From an anesthesiologist's point of view, detailed preoperative assessment and medical check up are essential for triaging the patients with possible cardiac conduction abnormalities. Detailed examination of an ECG is must. All patients with well known history of already existing coronary artery disease or another cardiac disease should be referred to a detailed cardiology consultation. All patients who had experienced episodes of syncope or presyncope should be referred for a cardiology consult as well. Because of the non-specific and absent symptoms in most of the patients, developing a sever bradycardia, bradyarrhythmia or tachycardia-bradycardia

syndrome during the intraoperative period could be the first manifestation of SSS that has to be treated promptly. If the present actual conduction abnormality is indolent to pharmacological treatment, temporary pacing in the intraoperative and postoperative period must be done.

Conclusion:

The impaired pacemaking function of the sinus node could be presented as diverse abnormalities in the heart rate and rhythm with or without any symptoms. Sinus sick syndrome (SSS) occurrence is the most common in the elderly patients, where the mean age of patients with this condition is 68 years. In most of the cases this condition is asymptomatic unless there are some trigger factors that could precipitate the onset of impaired generation and conduction of cardiac impulses which could lead to impaired cardiac output and decreased cerebral perfusion. There is diversity in the electrocardiographic manifestations of the sinus node dysfunction, which includes atrial bradyarrhythmia, atrial tachyarrhythmia, and even alternating tachyarrhythmia and bradyarrhythmia. Clinical manifestation of sinoatrial node dysfunction could be precipitated perioperatively also, because of increased vagal tone due to practicing anesthesia or because of the surgical intervention. Not only the medications used for performing general anesthesia, but also local anesthetics could trigger intraoperative manifestation of sinus node dysfunction. The underlying pathophysiological mechanism that leads to sinus node dysfunction is the upregulated process of fibrosis which is precipitated with coexisting chronic coronary artery disease and aging also. The unknown SSS in daily anesthesiology practice could be harmful for the patient due to the possibility of anesthetic induced triggering of sinus node dysfunction presenting in a diverse way of conducting and heart rate abnormalities. Obviously, spinal anesthesia could be as much potent triggering factor for sinus node dysfunction as general anesthesia is. Detailed pre-operative assessment of every patient, especially the elderly and those ones with well known cardiac disease is a must. Intraoperative treatment of SSS could be pharmacological or interventional with temporary pacing.

References:

1. Brignole M1.; Sick sinus syndrome.; *Clin Geriatr Med.* 2002 May;18(2):211-27.
2. Adán V1, Crown LA; Diagnosis and treatment of sick sinus syndrome.; *Am Fam Physician.* 2003 Apr 15;67(8):1725-32.
3. Rodriguez RD1, Schocken DD.; Update on sick sinus syndrome, a cardiac disorder of aging. *Geriatrics.* 1990 Jan;45(1):26-30, 33-6.
4. Hollenberg SM, Dellinger RP. Noncardiac surgery: postoperative arrhythmias. *Crit Care Med.* 2000;28 (10 suppl): N145–50.
5. Csepe TA1, Kalyanasundaram A1, Hansen BJ1, et al.; Fibrosis: a structural modulator of sinoatrial node physiology and dysfunction. *Front Physiol.* 2015 Feb 12; 6:37. doi: 10.3389/fphys.2015.00037. eCollection 2015.
6. Murakawa T1, Ishihara H, Matsuki A; Marked bradycardia during anesthetic induction treated with temporary cardiac pacing in a patient with latent sick sinus syndrome. *Masui.* 2001 Jan;50(1):65-8.
7. Nakamura S1, Nishiyama T, Hanaoka K.; General anesthesia for a patient with asymptomatic sick sinus syndrome. *Masui.* 2005 Aug;54(8):912-3.
8. Choi SH1, Choi SL1, Lee BY1, et al.; Tachycardia-bradycardia syndrome in a patient with atrial fibrillation: a case report.; *Korean J Anesthesiol.* 2015 Aug;68(4):415-9. doi: 10.4097/kjae.2015.68.4.415. Epub 2015 Jul 28.
9. Hirata A1, Kitagawa H, Komoda Y, et al. Sick sinus syndrome discovered after induction of general anesthesia in a patient with normal preoperative Holter ECG.; *Masui.* 1994 Jul;43(7):1048-52.
10. Ishida R1, Shido A, Kishimoto T, et al. Prolonged cardiac arrest unveiled silent sick sinus syndrome during general and epidural anesthesia.; *J Anesth.* 2007;21(1):62-5. Epub 2007 Jan 30.
11. Moghtadaei M1, Jansen HJ1, Mackasey M1, et al. The impacts of age and frailty on heart rate and sinoatrial node function.; *J Physiol.* 2016 Dec 1;594(23):7105-7126. doi: 10.1113/JP272979. Epub 2016 Oct 17.
12. Ravi Dadlani, Koli Challam, I Amit Garg, et al. Can bradycardia pose as a “red herring” in neurosurgery? Surgical stress exposes an asymptomatic sick sinus syndrome: Diagnostic and management dilemmas; *Indian J Crit Care Med.* 2010 Oct-Dec; 14(4): 212–216.
13. Shirasaka W, Ikeshita K, Toriyama S, et al. Intraoperative asystole in a patient with concealed sick sinus syndrome: a case report.; *Masui.* 2014 Mar;63(3):338-41.
14. Takayama K1, Takahata O, Sengoku K, et al. Sick sinus syndrome (SSS) after induction of anesthesia in a patient with increased intracranial pressure and ischemic heart disease.; *Masui.* 2000 Mar;49(3):289-91.
15. Arxer A1, Novoa L, Vieito Amor M, et al. Bradycardia-tachycardia syndrome during spinal anesthesia. *Rev Esp Anesthesiol Reanim.* 2003 Oct;50(8):414-7.

ANKLE BLOCK AN ALTERNATIVE OF ANESTHETIC MANAGEMENT OF MYASTHENIA GRAVIS (CASE REPORT)

Burmuzoska M¹, Jovanovski – Srceva M¹, Kokareva A¹, Petrusheva A¹, Kartalov A¹, Kuzmanovska B¹, Simeonova A², Josifov A²

¹PHI University Clinic of Anesthesiology, Reanimation and Intensive Care – Skopje

²PHI University Clinic of Thoracic and Vascular Surgery – Skopje

ABSTRACT

INTRODUCTION:

Myasthenia gravis (MG) is a chronic autoimmune disease characterized by a decrease in acetylcholine receptors at the neuromuscular junction, secondary to destruction or inactivation by circulating antibodies. In patients with MG, perioperative issues remain unclear, especially the use of regional anesthetic techniques, while the perioperative and postoperative complications are numerous. Preoperative evaluation is crucial for choosing the modality.

CASE REPORT:

A 52 years old female patient with 16 years history of myasthenia gravis was admitted for Lisfranc amputation. Preoperative examination was made, and many comorbidities were noted (Myocardial infarction with stenting, CVI, Diabetes mellitus type II, many respiratory infections). The severity was estimated by Osserman classification as type III B, a severe stadium with ptosis, respiratory dysfunction and generalized weakness. According to all preoperative evaluations, treatment regiment and in collaboration with the surgeon, it was decided to apply regional anesthesia. Ankle block was administered, with 25 ml 0.5% Bupivacaine. Good perioperative analgesia was provided.

DISCUSSION AND CONCLUSION:

The potential for respiratory compromise in patients with myasthenia gravis requires the anesthesiologist to be familiar with the underlying disease state, as well as the interaction of anesthetic and nonanesthetic drugs. When possible, regional anesthetic techniques are preferred by many anesthesiologists. Ester anesthetics, which are metabolized by cholinesterase, may present particular problems in patients taking anticholinesterases. That's why regional and local anesthesia should be performed using reduced doses of amide (rather than ester).

KEYWORDS: ankle block, myasthenia gravis.

Corresponding author: Burmuzovska Marijana, University Clinic of Anesthesiology, Reanimation and Intensive Care – Skopje, Macedonia

CASE PRESENTATION

A 52 years old female patient with 16 years history of Myasthenia gravis (MG) was admitted for Lisfranc amputation. Preoperative examination was made, and many comorbidities were notified. The patient had myocardial infarction with percutaneous stent insertion, cerebrovascular insult (CVI), Diabetes mellitus type 2, hypertension and many previous respiratory infections, estimated as ASA status of 3. Her drug history despite Imuran 50 mg/12 h, Mestinon 60mg/4h and Decortin, included Sintrom, Spironolactone, Lanitop, Torvex, Lanzul, Aminophylline and Insulin. One year ago, she was omitted to thrombendarterectomy and patch plastic of common femoral artery, deep and superficial femoral artery in general anesthesia.

Preoperative lab examination showed anemia, leukocytosis and thrombocytosis with hypoproteinemia and hypocalcaemia.

The severity of MG was estimated by Osserman classification as type III, a severe stadium with ptosis, respiratory dysfunction and generalized weakness (Table no. 1). According to all preoperative evaluations of her physical condition, her treatment regiment and in collaboration with the surgeon, it was decided to apply the regional anesthesia.

OSSERMAN Classification

1.	Class I	Any ocular muscle weakness
2.	Class II	Mild weakness other than ocular
	IIa	Predominantly limb, axial, or both
	IIb	Predominantly oropharyngeal/respiratory
3.	Class III	Moderate weakness other than ocular
	IIIa	Predominantly limb, axial, or both
	IIIb	Predominantly oropharyngeal/respiratory
4.	Class IV	Severe weakness other than ocular
	IVa	Predominantly limb, axial, or both
	IVb	Predominantly oropharyngeal/respiratory
5.	Class V	Intubation with/without ventilation

Table No. 1.

Her preoperative heart rate was 110/min, blood pressure 150/90 mmHg, oxygen saturation on room air was 94%. After careful consideration the patient was informed that her intervention is going to be performed in ankle block regional technique. Ankle block technique was performed as it is described bellow in the text.

Ankle block provided good perioperative analgesia with 25 ml 0.5% Bupivacaine. The surgery lasted almost 2 hours without any complication and after one hour in PACU the patient was transferred to the ward. She was recovering without any additional complication and after two days she was transferred to Clinic of Neurology for further treatment.

Ankle Block Technique

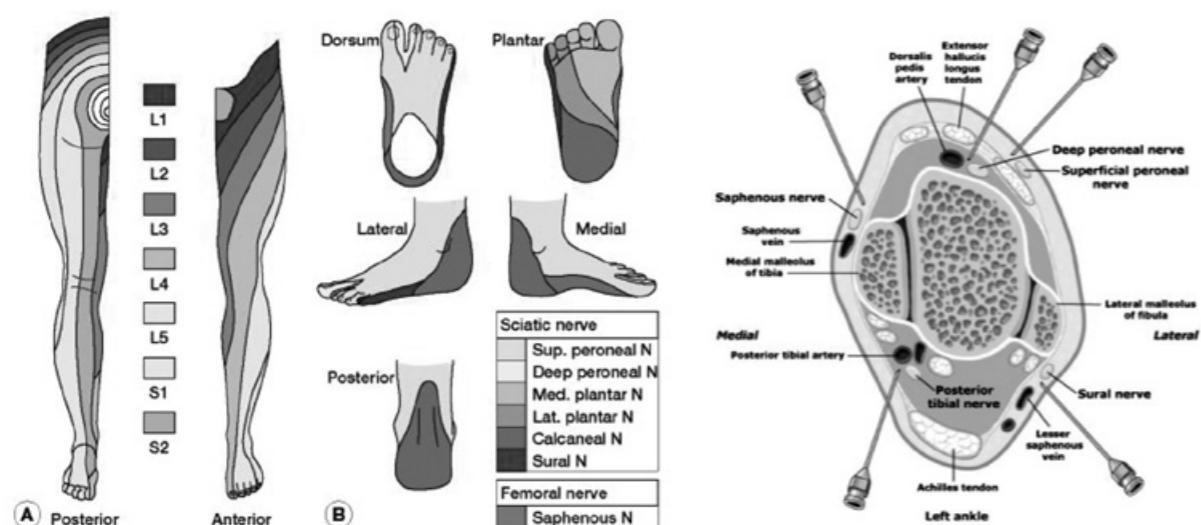
Ankle block, as a regional anesthesia technique, is used in surgical procedures on the foot, especially in ones without requirement of high lower-leg tourniquet pressure. Usually there is need of only sensory blockade, so lower concentrations of local anesthetics are used, like 1% Lidocaine, 0.25-0.5% Bupivacaine or 0.2-0.5% Ropivacaine. Epinephrine as an adjuvant is not recommended.

Five peripheral nerves are blocked, four of them are terminal branches of the sciatic nerve and only saphenous nerve is a branch of the femoral nerve. They are all arranged superficially around the ankle. Patient can be positioned in supinated position with leg on padded support.

Landscapes for every nerve included in the ankle block:

1. Tibial nerve: It is located medially to the Achilles tendon, behind the posterior tibial artery and between the tendons of flexor digitorum longus and flexor hallucis longus. If paresthesia is obtained, 3 to 5 ml of local anesthetic are infiltrated.
2. Sural nerve: It descends behind the lateral malleolus. The needle is inserted 4 cm deep just laterally to the Achilles tendon and another 5 ml of local anesthetic are infiltrated.
3. Deep Peroneal, Superficial Peroneal and Saphenous nerves: In supine position, the anterior tibial artery pulsation is located. In fan like manner from this midline skin wheal, the needle is advanced subcutaneously laterally and medially and are injected 3 to 5 ml of local anesthetic in every direction.

This block can be painful and uncomfortable for the patient, so adequate sedation is recommended. The onset time for this block is 10 to 25 minutes, depending of the volume and concentration of local anesthetic.



DISCUSSION

Myasthenia gravis (MG) is a neuromuscular disorder caused by decreased acetylcholine receptor availability at the postsynaptic muscle membrane, due to antibody mediated autoimmune attack. This condition results in decreased efficiency of neuromuscular transmission, despite normal release of acetylcholine in the neuromuscular cleft. The incidence is 50 to 142 cases per million, mainly women 20 to 30 years old.

Clinically it is manifested with muscle fatigability and weakness, which improves during rest period. Usually it affects ocular muscles, manifested early as ptosis and diplopia, and later with bulbar and facial muscles as difficult swallowing with possibility of aspiration. Generalized

weakness develops in 85% of patients, with possibility of crisis manifested as respiratory insufficiency and need for mechanical ventilation.

Preoperative evaluation and preparation should be individualized to the severity of the disease and to the type of surgery. Compromisation of the respiratory muscles should be evaluated by pulmonary function tests, particularly of negative inspiration pressure and forced vital capacity.

The potential for respiratory compromise in patients with MG requires the anesthesiologist to be familiar with the underlying disease state and good preoperative evaluation and preparation are crucial. Evaluation of the parameters for post-operative mechanical ventilation, like disease duration longer than 6 years, associated lung disease, pyridostigmine dose higher than 750 mg/day and vital capacity lower than 2.9 L, should be primary point in the perioperative course planning.

Regional anesthetic techniques, like neuroaxial blocks or peripheral nerve blocks, should be chosen every time when the condition and type of surgery allows. According to the study of Aykut Urfalioglu (in 2015) regional anesthesia with ankle block compared to spinal anesthesia has many advantages like reduced need of vasopressor drugs, with low incidence of cardiovascular instability. The first analgesic requirement time is longer and the total analgesic consumption decreased considerably. The only disadvantage is the onset of block formation.

Detailed pharmacological history reveals the possibilities for unwanted drug to drug inter-reaction between anesthetics and non anesthetic drugs. Ester group of local anesthetics should be avoided, because of their metabolism by cholinesterase, whose activity is reduced by anticholinesterase inhibitors. Reduced doses of amide local anesthetic are generally recommended, so potentiation of blocks could be minimized.

CONCLUSION

The goal of this case presentation is to encourage anesthesiologists to explore new possibilities for difficult and complicated patients with neurologic diseases. Regional anesthesia is becoming more commonly used technique, especially with the advantages offered by using ultrasound guidance. After the operative procedure, the patients are awake, pain free, without side effects like the one from general anesthesia, so they can recover faster and be discharged sooner.

REFERENCE:

1. Postevka E. Anesthetic implications of Myasthenia Gravis: A case report. AANA Journal. Vol. 81, No. 5; October 2013.
2. Abel M., Eisenkraft J.B. Anesthetic implications of Myasthenia Gravis. The Mountsinai Journal of Medicine. Vol. 69, No's. 1&2, January/March 2002.
3. Brown, D.L. Atlas of regional anesthesia, 4th edition. Philadelphia: Saunders Elsevier; 2010. P 135-138.
4. Aykut Urfalioglu, Onur Gokdemir, Onur Hanbeyoglu, et al. A comparison of ankle block and spinal anesthesia for foot surgery; Int J Clin Exp Med 2015;8(10):19388-19393

Апстракт

Миастенија гравис е хронично автоимуно заболување кое се карактеризира со намалување на ацетилхолинските рецептори во неуромускуларната плоча, секундарно поради уништување или инактивација со циркулирачки антители. Кај пациентите со Миастенијагравис, остануваат сè уште неразјаснети многу периперативни прашања, особено за употребата на регионалните анестезиолошки техники, додека и периперативните и постоперативните компликации се многубројни. Преоперативната евалуација е пресудна за одбирање на типот на анестезија.

Пациентка на 52 годишна возраст, со 16 годишна историја за Миастенија гравис, беше примена за Лисфранкова ампутиација. При преоперативниот преглед беа нотирани бројни коморбидитети како миокарден инфаркт со поставен стент, CVI, Diabetes mellitus тип 2, бројни респираторни инфекции. Тежината на болеста беше проценета според Osserman класификацијата како тип 3б, тежок стадиум пропратен со птоза, респираторна дисфункција и генерализирана слабост. Земајќи ги предвид сите преоперативни анализи, терапискиот режим, како и во консултација со хирургот, беше донесена одлука за регионална анестезија. Ankle блок беше изведен со аплицирање на 25 ml 0,5% Bupivacaine. Беше обезбедена добра периперативна аналгезија.

Можноста за респираторно компромитирање кај пациентите со Миастенијагравис е причината поради која анестезиологот треба да е добро запознаен со состојбата на болеста, како и интерреакциите на анестетиците со останатите лекови. Кога е возможно, се преферира регионалната наспроти општата анестезија од страна на голем број анестезиолози. Естерскиот тип на локални анестетици, кои метаболизираат со помош на холинестераза, може да претставуваат проблематичен избор кај пациентите кои користат антихолинестеразни лекови. Поради ова при аплицирање на регионална анестезија пожелно е да се употребуваат редуцирани дози на локални анестетици од амидна група.

APPROACH TO ONE LUNG VENTILATION DURING SURGICAL REMOVAL OF ASPIRATED LIGHT BULB IN A CHILD

Gjorchevska E¹, Gavrilovska-Brzanov A¹, Dimitrova M¹, Donev Lj¹, Simeonov R², Ristovski T²

¹ PHI University Clinic of Anesthesia, Reanimation and Intensive Care – Skopje

² PHI University Clinic for Pediatric Surgery - Skopje

Abstract:

The management of complications due to foreign body (FB) aspiration in children is challenging and sometimes it requires thoracic surgery. It is up to the anesthesiologist then to think of creative solutions for one lung ventilation (OLV). Airway FB aspiration is more common in younger children under three years of age and usually the FB is of organic nature. We present a case of OLV in an eight year old boy undergoing thoracotomy, after developing a clinical picture of severe complications as a result of a Christmas tree light bulb aspiration in the bronchi of the right lower lobe. Strategic planning of anesthesia and the availability of Right-sided Double lumen tube of the smallest size 26 F for right thoracotomy were decisive in managing the airway intra-operatively and successful removal of the FB.

Keywords: Aspiration, Foreign body, One lung ventilation (OLV), Pediatric, R-sided DLT, Right thoracotomy.

Corresponding author: Elena Gjorchevska, PHI University Clinic of Anesthesia, Reanimation and Intensive Care – Skopje. E-mail: elena.gjorchevska@gmail.com

Introduction

Accidental aspiration of a foreign body (FB) is a very common life-threatening emergency in the pediatric age group. Delay in its treatment results in serious morbidity and mortality (1). This usually happens in children up to three years of age. Food is the most frequently aspirated object (1-4). Given the anatomical characteristics of the relatively narrow airway with high position of the larynx and immature protective mechanisms, complications and mortality rates are higher in this age group of children. Aspiration of inorganic objects in older children is very rare. Diagnosis mainly relies on medical history and bronchoscopy for differential diagnosis in order to eliminate other common pediatric concerns. The gold standard for treatment is flexible fiber-optic bronchoscopy, whereas inhaled objects are the best retrieved by rigid bronchoscopies (2-5). Unsuccessful attempts of rigid bronchoscopy that lead to thoracotomy and possible lobectomy in order to remove an object are very rarely reported in the literature (1-5). Usually, these complications that require thoracic surgery treatment occur due to late diagnosis. Thoracic surgery is characterized by the need of motionless operative field, facilitated by one lung isolation and one lung ventilation (OLV). Arterial hypoxemia occurs during OLV due to continued shunting of blood through the non-ventilated lung and ventilation-perfusion abnormalities in the ventilated lung (6). Anesthetic management in such cases is challenging and requires experienced teams with an efficient method of intercommunication as well as planning safe anesthesia and surgery management.

Case Report

Hereby we report a case of an eight-year old boy with aspiration of a small Christmas tree light bulb in the right bronchi of the right lower lobe. We performed a series of investigations to obtain the diagnosis. Hetero-anamnesis suggests that the patient had swallowed the light bulb one month before his admission to the University Clinic for Pediatric Surgery in Skopje. He was treated by a general physician and Ear Nose and Throat (ENT) specialist before coming to our clinic. Five days after the event, the boy was taken to the ENT clinic in a poor condition: somnolence with severe prostration and dyspnea. A series of chest X-rays and five rigid bronchoscopies followed.

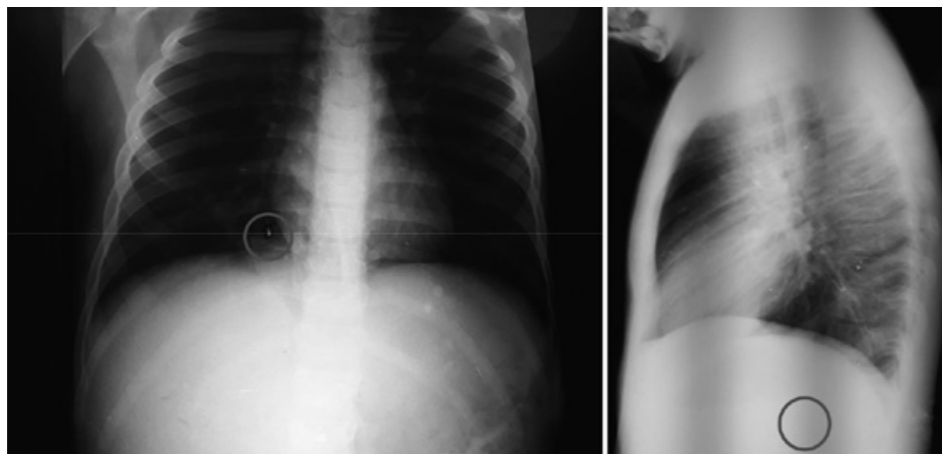


Fig. 1 – Chest X-ray showing the FB in the right lower lobe (AP and Lateral view)

The first X-ray revealed a metal lengthy shadow in projection of the bronchi in the right lobe (Fig. 1) with aspiration pneumonia. The later X-rays control, showed an inflammatory reaction and atelectasis in the posterior segment of the right lobe. All five attempts of rigid bronchoscopy (one of them under general anesthesia) were unsuccessful. We extracted only a fragment of the FB and the other part was pushed more distally, impossible to retrieve.

Assessment by a pediatric surgeon indicated thoracotomy with possible lobectomy. The patient was then transferred to the University Clinic for Pediatric Surgery. After 6 days of preparation and obtaining written informed consent by the parents, the patient was prepped for surgery. We premedicated him with Midazolam 0.5 mg/kg PO half an hour before surgery onward. In the operating room standard hemodynamic monitoring was placed and the vitals were recorded. We induced anesthesia with Fentanyl 2 mcg/kg IV, Lidocaine 2 ml 1%, Propofol 3 mg/kg IV and Rocuronium 0, 6 mg/kg IV for neuromuscular blockade. After 2 minutes of bag and mask ventilation, we performed laryngoscopy with Macintosh laryngoscope and Macintosh blade size 3. The patient was then intubated with *Right-sided Double-lumen endotracheal tube (R-DLT) 26 French* in size, which is the smallest commercially available DLT. Although, R- DLTs are usually used for left thoracotomies, we used it for right thoracotomy due to the fact that Left-sided Double lumen endotracheal tube (L-DLT) of the smallest size wasn't available in our department at that moment. This way we collapsed the right lung clumping the bronchial lumen, leaving the tracheal lumen for ventilation of the left lung.

We used the blind technique for insertion of the R-DLT, because a fiber-optic bronchoscope was not available in our institution. According to our institutional protocol we checked both cuffs, lubricated the inside and outside of the tube and placed a stylet prior to insertion of the DLT. We inserted the endotracheal tube with its bronchial concave curve facing anteriorly and once the tip was past the glottis, we partially withdrew the stylet and rotated the tube 90 degrees to the right to bring the oropharyngeal curve into the sagittal plane. Then we turned the patient's head to the left and gently slid the tube down the trachea until resistance was met. The distal tip of the bronchial part of the DLT was positioned into the right mainstem bronchus. Once we cannulated the trachea and the tracheal cuff just below the vocal cords, we inflated the tracheal cuff and ensured ventilation of both lungs via inspection and auscultation. Next, we clamped the tracheal lumen and checked ventilation through bronchial lumen (clamped off the gas flow to tracheal lumen at Y connector and opened the sealing cap to air). We slowly inflated the endobronchial cuff until the leak stopped. After that, we checked whether we could isolate the other lung via tracheal lumen – we closed the sealing cap, unclamped the Y connector and ventilated the patient. The position was confirmed clinically.

After verifying the position of the DLT, the patient was placed in lateral decubitus position for right thoracotomy. We affirmed the position of the DLT once more after changing the position. Afterwards we placed an arterial cannula in the left radial artery and drew a sample for gas analysis. The patient had PaO₂ of 247 mmHg and SaO₂ 100%. The oxygenation index (OI) (fraction of inspired oxygen × mean airway pressure / partial pressure of oxygen) was 6.07.

Because of the vasoconstriction to the artery, we could not make more ABG during the surgery. We continued measuring oxygen saturation with peripheral pulse oximeter (SpO₂). During the time the patient was under general anesthesia, oxygen saturation had not dropped below 97%.

We maintained the anesthesia with 50% oxygen in 3.5 L air flow, Propofol 0.2 mg/kg/min IV=20 mCg/mL. He received Acetaminophen 15 mg/kg perioperatively for analgesia and to prevent bronchospasm we administered Dexamethasone 2,5 mg, Urbason 40 mg and two puffs of Salbutamol. For antibacterial protection we used Amikacin, whereas for antiemetic prophylaxis we administered Ranitidine.

The collapsed right lung allowed indirect palpation of the foreign body. Lobectomy or bronchotomy were not necessary. Instead, we performed a small incision in the collapsed bronchi of the right lower lobe and extracted the FB (Fig. 2). We repaired the bronchi immediately using non-absorbable monofilament sutures. After the intracorporeal suturing was finished, we unclamped the bronchial tube to allow gas flow through the bronchial lumen and checked for air leak.

After confirming absence of air leakage, we re-expanded the lung. We placed a chest tube in the right chest cavity. Complete re-expansion of all lobes was observed before chest closure. We reversed the neuromuscular blockade with Neostigmine 0.05 mg/kg IV and Atropine 0.02 mg/kg IV, and extubated the trachea. The patient was sent to the ICU for observation. The post-operative period remained uneventful. There was no air leak in the chest tube and postoperative chest X-ray showed good lung expansion. The chest tube was removed on the third day and the patient was discharged on oral antibiotics and pain killers. The patient was in good condition after control examination.

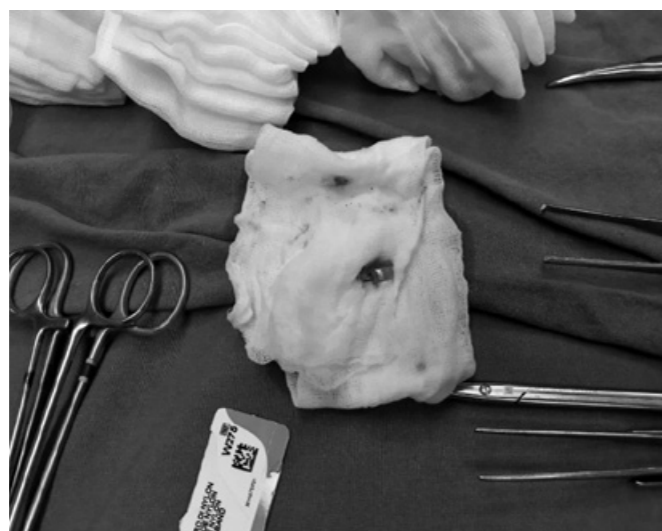


Fig. 2 – Part of the light bulb after being extracted

Discussion

To our knowledge this is the first case that includes the use of an R-sided DLT for right thoracotomy and a blind technique for its insertion, with clinical confirmation alone, along with the specific surgical approach for retrieval of the FB in a child.

Foreign body aspiration in the airway of children is still considered one of the most important diagnostic and therapeutic issues for physicians. The risk of foreign body aspiration is more frequent in boys compared to girls, due to overactivity and loss of concentration during running or jumping while eating. Most of the cases with tracheobronchial FB aspiration are children under the age of 5, with organic foreign bodies (1-6). The signs and symptoms of the FB depend on their type and location in the respiratory tract. Organic substances induce more severe inflammation of the mucosa. On the other hand, patients who aspirate small inorganic bodies tend to be asymptomatic for long periods, if full obstruction of the airway is absent (6-8). Inorganic FB aspiration is more difficult for diagnosis and management, especially if the event is not witnessed by a parent or guardian. The difference in this case is due to the age of the boy, and the fact that he became symptomatic only when complications developed.

Retrospective studies with large number of patients showed that early diagnosis within the first 24 hours using rigid bronchoscopy as a golden standard is the most successful management of the FB in the pediatric population (2-5). Development of complications is connected with late diagnosis, followed by high morbidity and mortality (2-4). Zhang et al. (2004) report that out of 7,260 cases, 7,007 (96 - 4%) patients were diagnosed and received bronchoscopic foreign body removal within 24 hours and only 12 cases received chest surgery for foreign body removal (2). In another study, Zhang et al. (2015) during a 20 years studied period discovered 9% overall rate of severe postoperative complications related to severe hypoxemia, laryngeal edema, complete laryngospasm, pneumothorax, total segmental atelectasis, and death (3). However, our patient is a rare case with severe complications due to late diagnosis and followed by complicated perioperative treatment, but with successful outcome.

Oliveira CF reports a very similar case in a 5 years old child that complained of swallowing a lamp, but his parents only took him to the hospital after 5 days when he became symptomatic (8). In our case the child is older and the prognosis after thoracotomy is better, due to different anesthetic approach.

Right DLTs are usually used for left-sided thoracotomies, but they have a bad reputation in the field of thoracic anesthesia. According to Slinger P., many experts regard them as difficult to position, with small margin of safety for correct placement and prone to intraoperative malpositioning. The majority of anesthesiologists still tend to use left DLTs, for left-sided thoracotomy whenever possible (9). The peculiar aspect of this case is that we used Right-DLT tube, for right thoracotomy. The bronchial side of the tube was used for intubation of the right main bronchus and right lung collapse suitable for right thoracotomy after clamping its lumen, whereas the tracheal side of the tube was used for left side one lung ventilation (OLV).

During one lung ventilation (OLV) there is a cessation of ventilation of the lung within the operative hemithorax with an increase shunt fraction, mitigated partially by hypoxic pulmonary vasoconstriction and increased alveolar-arteriolar gradient with periods of hypoxemia. Also, the airway pressure is increased with the dependent lung solely being ventilated, accompanied by

gravitational compression of the mediastinum (10-11). We decided to measure the oxygenation index having in mind that there might be periods of hypoxemia based on the degree of shunting and hypoxic pulmonary vasoconstriction. The oxygenation index was calculated within the first minute after initiation of OLV (OI= mean airway pressure, MAP x FiO₂ × 100: PaO₂). OI value was 6.07 which showed an excellent outcome for the patient. Although inflammatory reaction and atelectasis in the posterior segment of the right lobe were present, we didn't have any perioperative or postoperative complications related to hypoxemia respectively. We didn't find any similar articles where the OI is measured for cases of FB aspiration, although it is frequently used in pediatric Intensive medicine, especially in neonates to assess the severity of hypoxic respiratory failure (12). This index is considered to be a better indicator of lung injury compared to the PaO₂/FiO₂ ratio as it includes mean airway pressure (MAP) - an important determinant of oxygenation (12). There is a disadvantage because it's invasive and requires an indwelling arterial line or arterial puncture to obtain a blood gas sample. After vasoconstriction of the artery we couldn't obtain more ABG. We based our diagnosis and monitoring solely on pulse-oximetry and during the surgery there wasn't any drop below 97%. The saturation drop occurred after the first twenty minutes and lasted for five minutes. Oxygen saturation remained 100% for the rest one hour and twenty minutes of the surgery.

Clinical Relevance:

The careful approach to one lung ventilation, the experienced surgical team and strategic planning of anesthesia management are the main highlights in this case report. All of this led to a successful outcome for our patient. Availability of the smallest R-DLT size 26 F for the same side thoracotomy may be a very useful alternative for one lung isolation and ventilation, when other techniques are not available. This might be the treatment and resolution of complications that develop after bronchial aspiration of a FB in children requiring thoracotomy.

References:

1. Pinar Kendigelen. The anaesthetic consideration of tracheobronchial foreign body aspiration in children. *J. Thorac Dis.* 2016 Dec; 8(12): 3803–3807. Doi: 10.21037/jtd.2016.12.69 PMID: 26357477.
2. Zhang J, Zhang YM [How to reduce the incidence of complication and mortality in pediatric tracheobronchial foreign body patients]. *ZhonghuaEr Bi Yan HouKeZaZhi.* 2004 Nov; 39(11):658-62. PubMed PMID: 15835815.
3. Zhang X, Li WX, Cai YR [A time series observation of Chinese children undergoing rigid bronchoscopy for an inhaled foreign body: 3,149 cases in 1991-2010] *Chin Med J (Engl).* 2015 Feb 20; 128(4):504-9. Doi: 10.4103/0366-6999.151104. PubMed PMID: 25673454.
4. Soysal O, Kuzucu A, Ultas H [Tracheobronchial body aspiration: a continuing challenge.] *Otolaryngol Head Neck Surg.* 2006 Aug; 135 (2):223-6. PubMed PMID: 16890072.

5. Jianmin Liang, Juan Hu, Huimin Chang, et al. [Tracheobronchial foreign bodies in children – a retrospective study of 2,000 cases in Northwestern China] *J Thorac Dis.* 2016 Dec; 8(12): 3803–3807. doi: 10.21037/jtd.2016.12.69. PubMed PMID: 26357477.
6. Soudabeh Haddadi, Shideh Marzban, Shadman Nemati, et al. [Tracheobronchial Foreign-Bodies in Children; A 7 Year Retrospective Study] *Iran J Otorhinolaryngol.* 2015 Sep; 27(82): 377–385; PMID: 26568942.
7. Hazem-Saeed Amer, Mohammad-Waheed El-Anwar, Ashraf Raafat, et al. [Laryngo-Tracheo-Bronchial Foreign Bodies in Children: Clinical Presentations and Complications] *Iran J Otorhinolaryngol.* 2017 May; 29(92): 155–159. PMID: 28589109.
8. Oliveira CF, Almeida JF, Troster EJ, et al. [Complications of tracheobronchial foreign body aspiration in children: report of 5 cases and review of the literature]. *Rev Hosp ClinFac Med Sao Paulo.* 2002 May-Jun; 57(3):108-11. PMID: 12118268.
9. Peter Slinger, MD [The clinical use of right-sided double-lumen tubes] *Can J Anesth/J Can Anesth,* 2010 doi: 10.1007/s12630-009-9262-z.
10. Gordana Taleska, Marija Bozhinovska, Aleksandra Gavrilovska- Brzanov, et al. [Hypoxia during one lung ventilation in thoracic surgery] *Signa vitae* 2017; 13(2): 54-62. doi: 10.22514/sv132.112017.8.
11. Naik BI, Colquhoun DA, Shields IA, et al. [Value of the oxygenation index during 1-lung ventilation for predicting respiratory complications after thoracic surgery]. *J Crit Care.* 2017 Feb; 37:80-84. Doi: 10.1016/j.jcrc.2016.09.001.
12. Munmun Rawat, MBBS, Praveen K Chandrasekharan, MBBS, Ashley Williams, MS, et al. [Oxygen Saturation Index and Severity of Hypoxic Respiratory Failure] *Neonatology.* 2015; 107(3): 161–166. Doi: 10.1159/000369774. PMID: 25592054.

Апстракт:

Аспирацијата на туѓо тело е честа патологија во детската возраст, особено кај помалите деца под тригодишна возраст. Вообичаено, туѓото тело е од органска природа, а компликациите кои можат да настанат се прилично комплексни и не ретко изнудуваат торакална операција. Тогаш пред анестезиологот се поставени одредени предизвици за менаџирање на механичката вентилацијата и евентуалната можност за дволуменска интубација и вентилација на едно белодробно крило. Ви претставуваме случај на осумгодишно момче кое беше подложено на торакотомија, по развивање на клиничка слика од тешки компликации поради аспирација на украсна божиќна светилка, во дисталните бронхи на долниот лобус од десното белодробно крило. Достапноста на деснострани дволуменски тубус со најмала големина 26 F, како и стратешкото планирање на анестезијата беа одлучувачки фактор во обезбедувањето на дишен пат со десен дволуменски тубус за десна торакотомија и успешно отстранување на туѓото тело.

A LETTER TO THE EDITOR

REMOTE WORKSHOP FOR LOW FLOW ANESTHESIA

Paul Zilberman¹, Liljana Malinovska-Nikolovska²

¹ Anesthesia Department, Hadassah Medical Center, Mount Scopus Campus, Jerusalem, Israel
Email: paulzi60@yahoo.com

² Department of Anesthesia and Intensive Care, GOB 8-mi Septemvri, Skopje, Macedonia

ABSTRACT:

Started in 1970, telemedicine was defined as:

“The delivery of health care services, where distance is a critical factor, by all health care professionals using information and communication technologies for the exchange of valid information for diagnosis, treatment and prevention of disease and injuries, research and evaluation, and for the continuing education of health care providers, all in the interests of advancing the health of individuals and their communities”.

Diverse ways of information communication exist, with different degrees of sophistication. We explored a simple one, the smart-phone and the laptop to conduct a workshop between Israel and Macedonia.

Using Messenger audio video, we tested the feasibility of an online low flow anesthesia workshop. The Israel side was the “instructor”, the Macedonian part was the “learning” one.

The technical part was excellent. A reliable internet connection allowed the relevant part of the anesthesia to be supervised and conducted from Israel. The practical part was performed by the Macedonian colleagues.

We used the smart-phone on the Macedonian end to visualize the anesthesia machine and monitor, so the Israeli side follows up in real time.

Both “communication ends” were satisfied with the results, thus opening the gates for further workshops and other didactic purposes.

Legal issues may have to be overcome as different authorities may have specific requests concerning patient privacy. End-to-end encryption may be enough.

Corresponding author: Liljana Malinovska-Nikolovska, Department of Anesthesia and Intensive care, GOB, Skopje, Email: liljanamalinovska@yahoo.com

CONFLICT OF INTERESTS:

None.

MATERIALS AND METHODS:

The tele-workshop was done between the “Instructor”, Dr. Paul Zilberman and the “Student”, Dr. Liljana Malinovska with her OR team in the Hospital in Skopje, Macedonia.

The Low Flow Anesthesia (LFA) technique has been theoretically and practically demonstrated live a few years ago in Skopje. As such, the “student” was already skilled in the technique. We tested only the reliability of video and sound transmission, in real time, between two simple electronic devices on a commonly used platform, MESSENGER. The smart-phone was a “SAMSUNG”. The laptop was HP. These devices were used because this is what we had. There is no suggestion, indication or advice whatsoever that only these devices should be used. Any electronic device that supports this type of communication is fit for the task.

The video quality of the connection can be seen in the following photos:

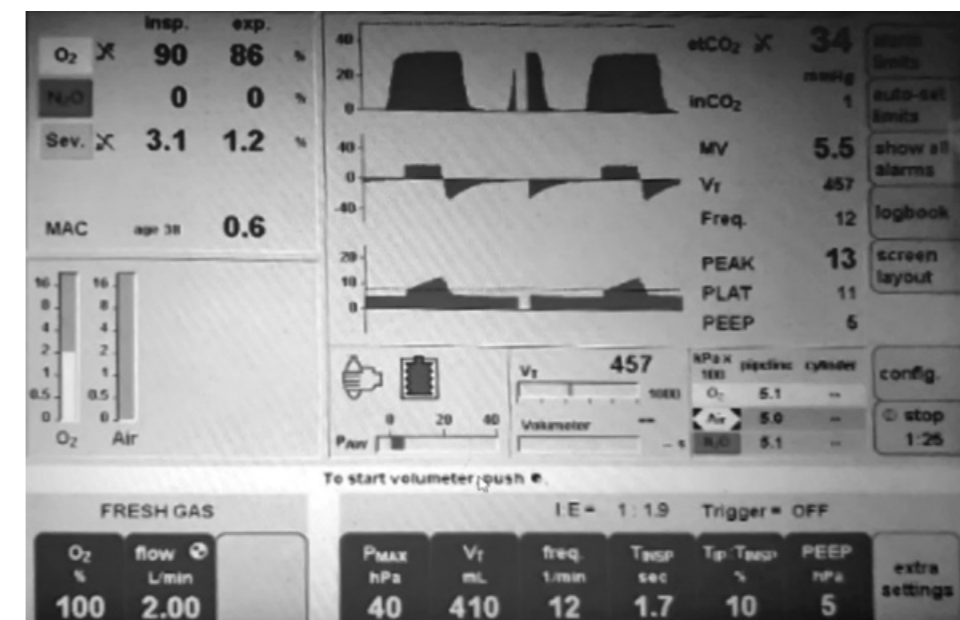


Photo 1. The general view of the computer screen

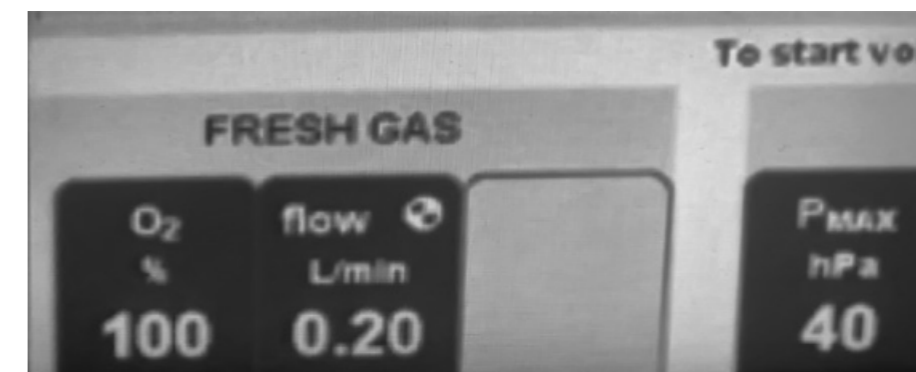


Photo 2. Partial screen

It is easy to notice in that from the photo 1 to photo 2, the difference in total flow as directed by the “instructor” while following in real-time the monitor.

All the images above have been taken with the following set up of the smart-phone mounted on a pole in front of the anesthesia machine screen.



Photo 3. *The Equipment*

Small fine-tunings were done before the real workshop to choose the optimal distance between the smart-phone and the anesthesia machine screen.

The patient was informed about the experiment and asked permission to transmit live screen data. In order to protect the patient’s privacy at no point the patient’s name, surgery details or any other element of identification were pronounced.

The smart-phone was mounted in front of the anesthesia machine and monitor on a commonly available stick. After a few technical adjustments the experiment began.

It consisted in instructing the “student” what parameters to modify on the anesthesia workstation (ventilation, flow, respiratory pressures, and anesthetic agent) upon direct online supervision of the “instructor” at different steps of the anesthesia:

1. The induction of anesthesia as desired by the “student”. In this case it was i.v.
2. After the intubation and connection of the ETT to the breathing circuit the mechanical ventilation was initiated as planned: $FiO_2 = 1$, $RR = 10/min$, $V_t = 6 ml/kg$, $PEEP = 5 cm H_2O$
3. Opening of the vaporizer by the pre-established protocol: $SEV = 8\%$
4. Once the target ETAA was reached (1.5%) the O_2 flow was reduced to match the patient’s consumption plus the machine’s leaks. In this phase a short lowering of the ETAA may be noticed as the uptake process is still going on.
5. However, after a few minutes the ETAA went up again as the uptake was almost completed. When the desired MAC is reached the vaporizer dial can be reduced to the minimum necessary. It is difficult to give an exact number, but only as an orientation the dial can be reduced to the MAC value of the specific AA (in this case SEV) and the following tuning up/down as indicated by the MAC.

After the conclusion of this phase (uptake) the rest of the anesthesia was conducted the usual way with no further interventions from the “instructor’s” side.

COMMENTS

This article, besides describing the initial steps in the LFA technique, has the main purpose to present our experience with a usual communication platform and the potential applications in telemedicine.

The main body of information when writing this article consisted of the WHO report “TELEMEDICINE, Opportunities and developments in Member States”, 2010. The report offers detailed information of the possibilities and challenges in this medical field.

Some parts of the medical activity are more prone to “tele” by the specific nature of each one. The radiology, for example, has been the first one to be introduced. An X-ray was performed in one country and an expert opinion obtained from another country sometimes on the opposite side of the globe. And telemedicine has been gradually expanded to dermatology, psychology, pathology, to name only a few.

For technical purposes telemedicine can be divided into two parts:

1. Store-and-forward, or asynchronous, when medical data is recorded and transmitted to one or more individuals for examination,
2. Real-time, or synchronous (as in our experiment).

The continuous literally explosion of the electronic communication capabilities, with Wi-Fi networks and devices in even the most remote areas, bring medical advice and opinion, sometimes treatment interventions, “from no matter where to no matter where” in the world.

Not every medical activity or procedure can be solved this way. An expert surgeon can recommend a special surgical approach for certain pathology, and can supervise it from a remote

place, but nothing can be done if in that remote area the technical set up cannot allow for the procedure to be performed.

Some technical requirements must be met as well. In the western world things like electricity are considered trivial. Unfortunately, in many other parts of the world the reality is different. A non-reliable Wi-Fi connection precludes the effective use of telemedicine.

Our experiment showed clearly how simple and effective such a communication can be. The present platforms are pretty reliable and safe due to end-to-end encryption.

Let aside the technical part of the subject, some issues may arise due to legal differences between countries. Safety breaches and data theft are, unfortunately, still a reality. From time to time we see in the press that "...in the X hospital the medical information of a ...number of patients has leaked out". While not completely restrictive, the HIPAA regulations are a good source of information in order to keep things safe.

Other concerns may arise in case something goes wrong with the patient: the consultant doctor was in one country and the patient in another. In the case of a mishap who is legally responsible? The remote doctor or the local one?

Co-payment and insurance coverage are still in constant development.

It is easy to understand that Telemedicine, while offering exceptional advantages poses some difficult questions too. But the road has been opened and the present difficulties will be overcome.

An important issue that Telemedicine may help solve is the uneven, sometimes critical, distribution of medical personnel in the world or even within one specific country. If we close in to our field, anesthesia, it may be perfectly feasible to have one senior doctor in an office within the OR area supervising by one specific platform what happens in several ORs where anesthesia would be provided by anesthesia nurses and/or residents. Many times, anesthesia has been compared to airplane flying. We can imagine the senior supervisor as the flight controller in tower watching the "flight" of the patients in several rooms and intervening only in case of need. The possibilities are still under evaluation. The Pandora box has only been opened.

CONCLUSIONS

Our experiment, although a very simple one, offers the tools and the ways to teach (in the first phase) and control (later on) anesthesia in virtually any location. More sophisticated equipment, even professional one, can be used, but our experiment intentionally chose the one described here. Thus, even in the most remote areas, as long as a reliable Wi-Fi network exists, telemedicine anesthesia may be a viable solution.

The advent of modern communication technology transformed the whole world into a small town. A doctor can be physically thousands of kilometers away, but digitally next to the patient. The therapeutically and teaching possibilities are endless. While further improvements in technical realities on the ground are still needed, the process has been started. And it's rewarding.

SELECTIVE LITERATURE

1. TELEMEDICINE, Opportunities and developments in the Member States, Report on the second global survey on eHealth, Global Observatory for eHealth series – Volume 2, 2010.
2. Eric Topol, M.D.: "The Creative Destruction of Medicine – How the Digital World will create a better health care", Basic Books, 02.2012.
3. Robert Wachter: "The Digital Doctor – Hope, Hype and Harm at the dawn of Medicine's Computer Age", McGraw-Hill Education, 1st Edition, March 31 2017.
4. Everett M. Rogers: "Diffusion of Innovations", 5th edition, Free Press, 2003.
5. HIPAA – Health Insurance Portability and Accountability Act.
6. Gas Man[®], www.gasmanweb.com.

DOJRAN 2018 - THORAX AND RESPIRATION

Adramanova D, Pavlova M

Dear colleagues in the world of Anesthesia,

It's our honor to announce that this year we have had a fruitful program at the first course from the fourth cycle of CME (Continuous Medical Education) for postgraduate education in Anesthesiology and Reanimation under the CEEA (Committee for European Education in Anesthesiology) / ESA (European Society of Anesthesiology).

The course was held at the educational center "Alkaloid" Dojran, Macedonia during the period from 28th to 30th of September 2018. The theme of the course was "Thorax and Respiration". 103 participants attended the course, including anesthesiologists and anesthesia trainees. There were 18 lecturers, among them five international lecturers (from USA, Serbia and Kosovo) invited as guest speakers. The course was organized by the Department of Anesthesiology and Reanimation, at the Faculty of Medicine, "Ss. Cyril and Methodius" University, Skopje, Macedonia and the Macedonian Society of Anesthesiologists and Intensive Care Medicine (MSA). The Scientific Board consisted of nine members, experienced professionals in Anesthesiology, Reanimation and Intensive care medicine.

The scientific program included interactive lectures and panel discussions. There were 20 lectures by the national and international lecturers, including different topics in the area of thorax, respiration and perioperative medicine - basic principles and new concepts. Respiratory physiology, mechanical ventilation, perioperative considerations for patients with respiratory diseases, respiratory insufficiency, acute respiratory distress syndrome (ARDS), extracorporeal organic support for cardiopulmonary insufficiency, anesthesia and analgesia for thoracic surgery, perioperative safety, were some of the topics. At the end of the course there was an exam for the participants. Each of the participants was awarded with the certificate of participation which is a great reference for their career.

All participants and international lecturers have given their highest remarks for the scientific content and organization of the course. Overall, the course was appreciated well by the participants. The lectures were very useful, especially for the anesthesia residents. As every year, the course was very well organized, with excellent lectures that contributed to better education and sharing of experiences.

Dr. Dona Adramanova

Dr. Marija Pavlova

Residents in Anesthesiology and Intensive Care Medicine

Guidelines for Authors

Macedonian Journal of Anaesthesia (MJA) is a scientific journal of the Macedonian Society of Anaesthesia (MSA) and Macedonian Society of Critical Care Medicine (MSCCM). The aim of this specialized medical journal is to speed and promote scientific achievements, novelties', clinical experience's, reviews, controversial topics in anesthesia, reanimation and intensive care.

The Journal is published twice a year (April and November), but additional supplements might be published when needed. MJA publishes original (professional and scientific) articles, review articles, case reports, therapeutic and technological innovation, discussions, critics, impressions from meetings, information for international conferences and reviews of new books or variate.

Manuscripts that are published should have not been published previously. Manuscripts that have been previously published only in form of abstracts are eligible for publishing in the journal but should be followed by additional letter send to the Editor, where the abstract details are noted (abstract number, which book of proceeding or doi, date and place).

The authors are responsible for respecting the ethical guidelines for medical researches, as well as for all that is explained, attitudes, analyses and shown results.

The redaction sends the manuscripts to anonymous reviewing process from international or domestic reviewers and the Editors determine the definitive categorization of the manuscript. Once reviewed manuscript together with the reviewers' remarks is send back to the corresponding author, after what the author is omitted to deliver the final form of the manuscript to the Editorial board within one week.

Editorial board has the right to publish the manuscripts according to the reviewer's priority. The order in which the manuscripts are published does not reflect the scientific value of the article. The Editorial board keeps the rights to make changes to the manuscript to fulfil the criteria.

MANUSCRIPT PREPARATION

Manuscript should be sent together with the accompanying letter from the corresponding authors where declaration that the text has not been published previously is signed. Additional conflict of interests and confirmation by all the authors should be declared in this letter (example: Annex no.1).

The guidelines for authors adhere to the uniform Requirements for Manuscripts submitted to Biomedical Journals: www.nlm.nih.gov.

Language and style of the manuscripts should be clear, simple to according the language, anesthesiological and medical taxonomy.

The manuscript has to be written in **English**, followed by an abstract in Macedonia (after the references section).

Manuscripts should be written in **Microsoft Word** (*.doc format) with **Times New Roman** font and **size 12**. Margins on left, up and bottom should be 3cm and right margin should be 2,5cm.

the inline space should be 2. Do not use Bold or Italic letters for the whole text (only for parts that have to be emphasized). Manuscript should not exceed 10 pages (without the references).

Abbreviations and correct medical terms should be used according to the International Committee of Editors of Medical Journals (<http://www.icmje.org>). Use only standard abbreviations; use of nonstandard abbreviations can be confusing to readers. Avoid abbreviations in the title of the manuscript. The spelled-out abbreviation followed by the abbreviation in parenthesis should be used on first mention unless the abbreviation is a standard unit of measurement.

MANUSCRIPT SECTIONS

- Manuscript should be organized in:
- Title page
- Text organized in IMRaD
- Acknowledgments
- Authors Contribution
- References
- Abstract in Macedonian only (For Macedonian Natives)

Review articles, case reports, therapeutic and technological innovation, discussions, critics, impressions from meetings, information for international conferences and reviews of new books or variate may be written in different sequences and manners.

TITLE PAGE

The title of the manuscript written in CAPITAL LETTERS.

Authors Surname and Name initial (Jovanov.J), without academic or other titles.

Name and address of the institution where the authors come from whit the subscribed digits

Abstract in English. Abstract should include up to 250 words and should contain goals of the paper, important elements from the methodology, concisely displayed results and conclusion. Each abstract at the end must have **Key words:** in alphabetical order.

TEXT

- Introduction,
- Matherial and Method,
- Results
- Discussion
- Conclusion

Review articles, case reports, therapeutic and technological innovation, discussions, critics, impressions from meetings, information for international conferences and reviews of new books or variate may be written in different sequences and manners.

Introduction section should include a literature overview in relevance to the elaborated problem. In this sections 3-5 key references are cited and this section should not be longer than 2 pages.

Material and method sections includes detailed description of the performances in the research as well as the statistical analyses used. This section should include: time during what the research was conducted, type of the study, place of where the research was undertaken, randomization or stratification used (clear description of the examined groups), exclusion and inclusion criteria, method, analysis types, apparatus and instruments used and referent values of the examined features (in SI-International System units).

Results are displayed in simple manner with text, images, tables and charts that are submitted in the text where author wants to stand, titled and numbered appropriately. Additionally, on separate document all carts images and tables are send together with the manuscript.

Title and the number of the charts and tables are placed above them while the explanations, abbreviations and comments are placed below. Images title and number is placed below and the image should include proper explanation.

Discussion section emphasize the key finding of the actual research and compares these result to other relevant literature data.

Conclusion section should not include more than 150 words and shoul be drown from the relevant elaborated results.

Acknowledgment and Author contributions sections are displayed after the conclusion and before the reference section.

REFERENCES

This sections include only the cited references. **The references** are listed in order of appearance in the paper and the citation is standard numbers enclosed in small brackets in the same line with the text ().

For each reference if more than three authors appear provide the names of the first three authors and followed by **et al**.

Examples:

Journal references:

Nirmala BC, Kumari G. Foot drop after spinal anaesthesia: a rare complication. Indian J Anaesth. 2011; 55: 78–79.

Lynch EP, Lazor MA, Gellius JE, et al. The Impact of Posoperative Pain on the Development of Postoperative Delirium. Anesth Analg 1998; 86:781-785.

2. Journal supplements:

AzmanJ, Frkovic V, Bilic L, et al. Korelacija I regresija. Acta Med Croat 2006;60 (suppl I):81-89.

3. Books

Brown, D.L. Spinal, epidural, and caudal anesthesia. In R.D. Miller Miller's Anesthesia, 6th edition. Philadelphia: Elsevier Churchill Livingstone; 2005.p 98-198

4. Doctoral or master thesis

Jelisavac Cosic S.Urokinazni I tkivni aktivator plazminogena i njihov inhibitor u raku dojke (Master thesis).Zagreb: Farmaceutsko-biohemijski fakultet 2004, p.50

5. Electronic reference

Dag Stat. Mackinnon A. Available from :<http://www.mhri.cdu.au/biostats>.Accessed May 5th 2006.
Webster NR. The anaesthetist as peri-operative physician.Anaesthesia. <http://dx.doi.org/10.1046/j.1365-2044.2000.01722.x>

References used from abstracts are marked as **(abstr)**., and from letters with **(letter)**

АПСТРАКТ НА МАКЕДОНСКИ

Macedonian abstract should include title (in capital letters) and all the needed features as the English abstract only written in Macedonian with Times New Roman, font size 12 with Macedonian support in Microsoft Word.

Prepared manuscript should be submitted electronically to **macedoniananesthesiology@gmail.com**.

All manuscripts that don't fulfil the above criteria will not be accepted for reviewing

Accompany letter ANNEX no.1

I _____ . Here by declare that the article _____ (NAME OF THE ARTICLE) has not been previously published (fully or partialy) previously.

We autors _____
_____ (FULL NAME AND SURNAMES OF THE AUTORS AND SIGNATURES) are responsible for the etic, profesional and scientific content of the study.

I _____ (THE FIRST AUTHOR FULL NAME) declare Conflict of interest or declare non Conflict of interest.

_____ (FIRST AND SURNAME OF THE CORESPONDING AUTHOR, (ADRESS), (TELEPHONE NUMBER), E-MAIL

Здружение на лекарите по
анестезија, реанимација
и интензивно лекување



Macedonian Society of Anesthesiologists
and Intensive Care Medicine



Здружение на лекари за
критично болни пациенти