

SPONTANEOUS VISUAL RECOVERY FOLLOWING COMBINED CENTRAL RETINAL VEIN AND CILIORETINAL ARTERY OCCLUSION – CASE REPORT

Natasa Trpevska Shekerinov^{1,2}, Andrijana Petrushevska^{1,2}, Emilija Gjoshevska Dashtevska^{1,2}

¹University Clinic for Eye Diseases, Skopje, North Macedonia

² Faculty of Medicine, University "St. Cyril and Methodius" in Skopje, North Macedonia

Abstract

Combined central retinal vein occlusion and cilioretinal artery occlusion is a rare variant of retinal vascular disease, which causes sudden unilateral visual acuity loss.

The most important risk factors are the same as those for atherosclerosis (advanced age, hypertension, hyperlipidemia, diabetes, cigarette smoking, positive family history). The purpose of this paper is to describe a 41-year-old patient with reduced vision in the right eye with this condition, who had spontaneous improvement in visual acuity.

Keywords: central retinal vein occlusion; cilioretinal artery occlusion; spontaneous visual recovery.

Introduction

Combined central retinal vein occlusion (CRVO) and cilioretinal artery occlusion (CLRAO) is a rare variant of retinal vascular disease, which causes sudden unilateral visual acuity loss [1].

The most important risk factors are the same as those for atherosclerosis (advanced age, hypertension, hyperlipidemia, diabetes, cigarette smoking, positive family history). Other systemic predisposing factors include inherited and acquired thrombophilia, high blood viscosity, systemic vasculitis, and autoimmune disease. The most common hematologic abnormalities among young individuals are hyperhomocysteinemia and antiphospholipid antibodies [2,3].

Combined CRVO and CLRAO comprises 27% to 62% of all CLRAOs [4].

The pathomechanism of combined CRVO/ CLRAO still remains unclear. It is usually suggested that this phenomenon should be interpreted as a hemodynamic block [5].

There are some controversies regarding antithrombotic therapy for CRVO. No benefit from treatment with antiplatelets or anticoagulants was observed. Moreover, a significantly greater severity of retinal hemorrhages was reported among aspirin users than among nonusers [6].

Further long-term treatment with acetylsalicylic acid should be based on individual indications for primary or secondary prevention of cardiovascular disease[7].

It is essential that young patients with the combined occlusion of retinal artery and vein should be evaluated in detail because the differentiation between thrombotic and inflammatory etiology is crucial for proper management [7].

The prognosis for combined CRVO/ CLRAO is generally good. During follow-up, VA as well as visual field improvement is common in the non-ischemic CRVO/ CLRAO group. However, the involvement of the macula results in a persisting central scotoma even after the resolution of the venous stasis [8].

Case-report

A 41-year-old patient had suddenly reduced vision in the right eye like a cloud, about 10 days ago. He has done LASIK (Laser in situ keratomileusis) on both eyes about 3 years ago in Bulgaria. His visual acuity on right eye was 0.125-0.2 s.c. / sec. Eye pressure was normal, also the anterior segment finding.

The fundus finding was dilated veins, narrowed arteries with glare, a/v bridging, diffuse preretinal hemorrhages in the posterior pole, ischemic retina more in the papillomacular sector and in the lower arcade (Figure 1).

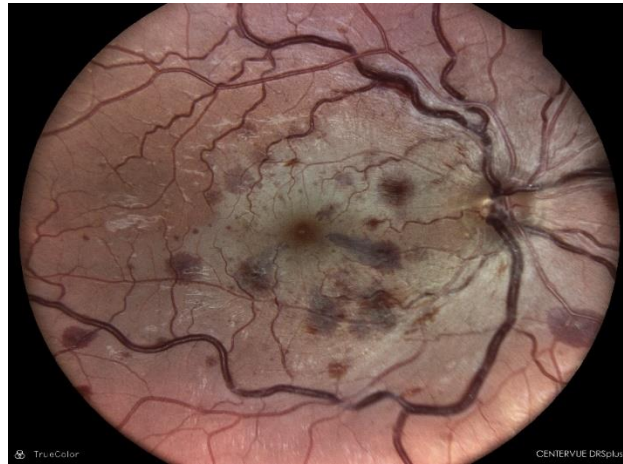

Figure 1. Fundus of the right eye

The carotid doppler was normal, also transfusion and rheumatological findings. Serological tests showed a positive IgG for Cytomegalovirus (CMV). He notes that he has frequent headaches (Cluster migrena in obs.) for which he consulted a neurologist. Denies systemic diseases.

At the scheduled follow-up after one month, the patient did not come due to personal reasons. He came for the next examination after 5-6 months. Visual acuity was 0.63 s.c., intraocular pressure was normal, as was the finding of the anterior segment. PNO was normal, blood vessels tortuotic, dilated veins, narrowed arteries, a/v bridging, macula with weak reflex, towards the upper arcade more ischemic (Figure 2). Perimetry finding was central scotoma with reduced sensitivity diffusely in the upper sector (Figure 5). On optical coherence tomography (OCT), the retinal layers were normal, as was the retinal nerve fiber layer. But the ganglion complex of that eye showed significant thinning (Figure 3,4).

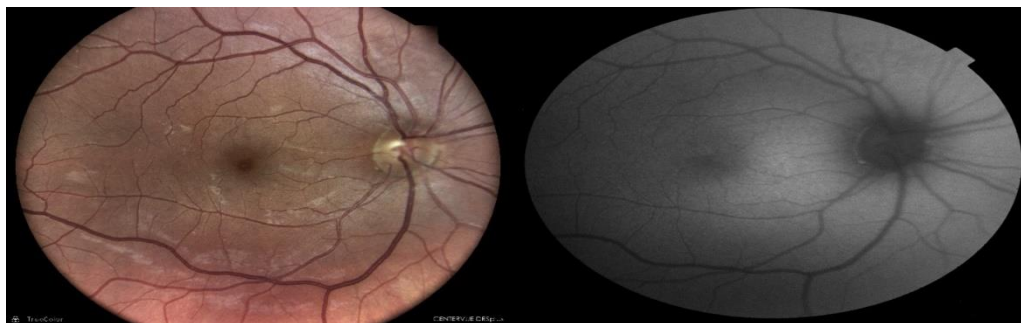

Figure 2. Fundus of the right eye and autofluorescence photography

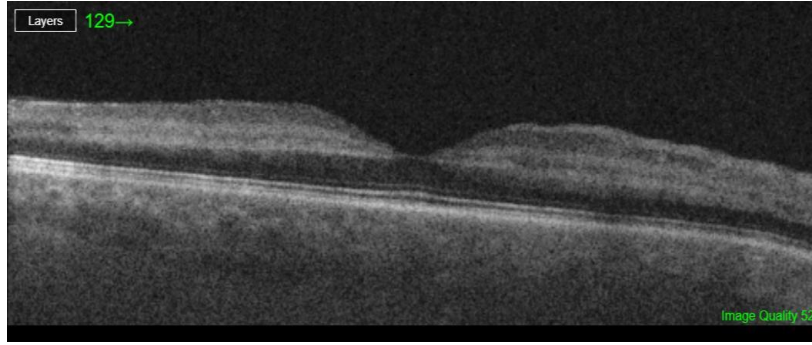


Figure 3. OCT/Macula – B scan

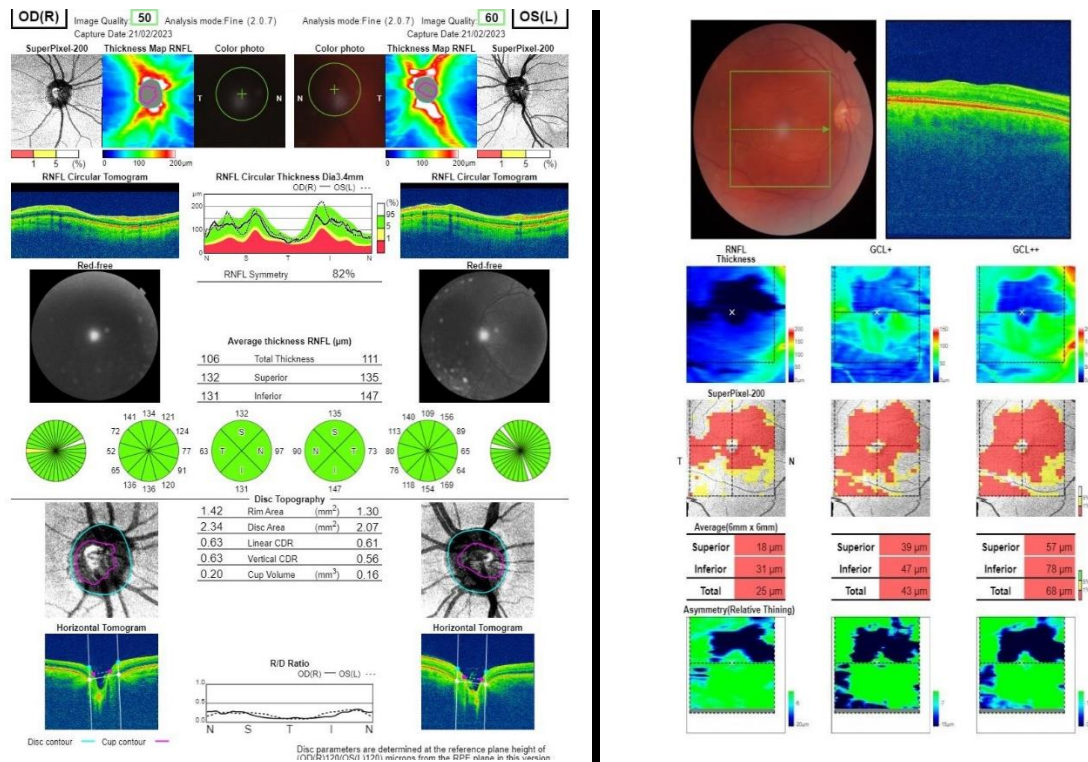


Figure 4. OCT/RNFL and GCL

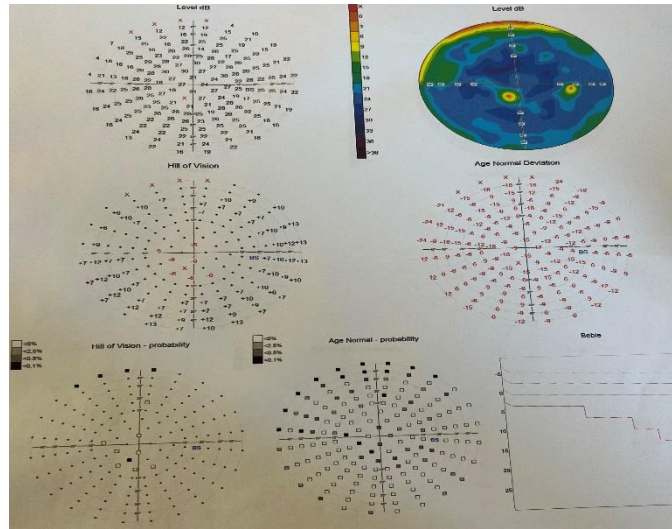


Figure 5. Perimetry

The patient then underwent fluorescein angiography. Slightly dilated and nonreversible FAZ zone with 2-3 microaneurysms. No signs of retinal ischemia (Figure 6). According to this finding there is no indication for additional treatment and the patient was put under observation.

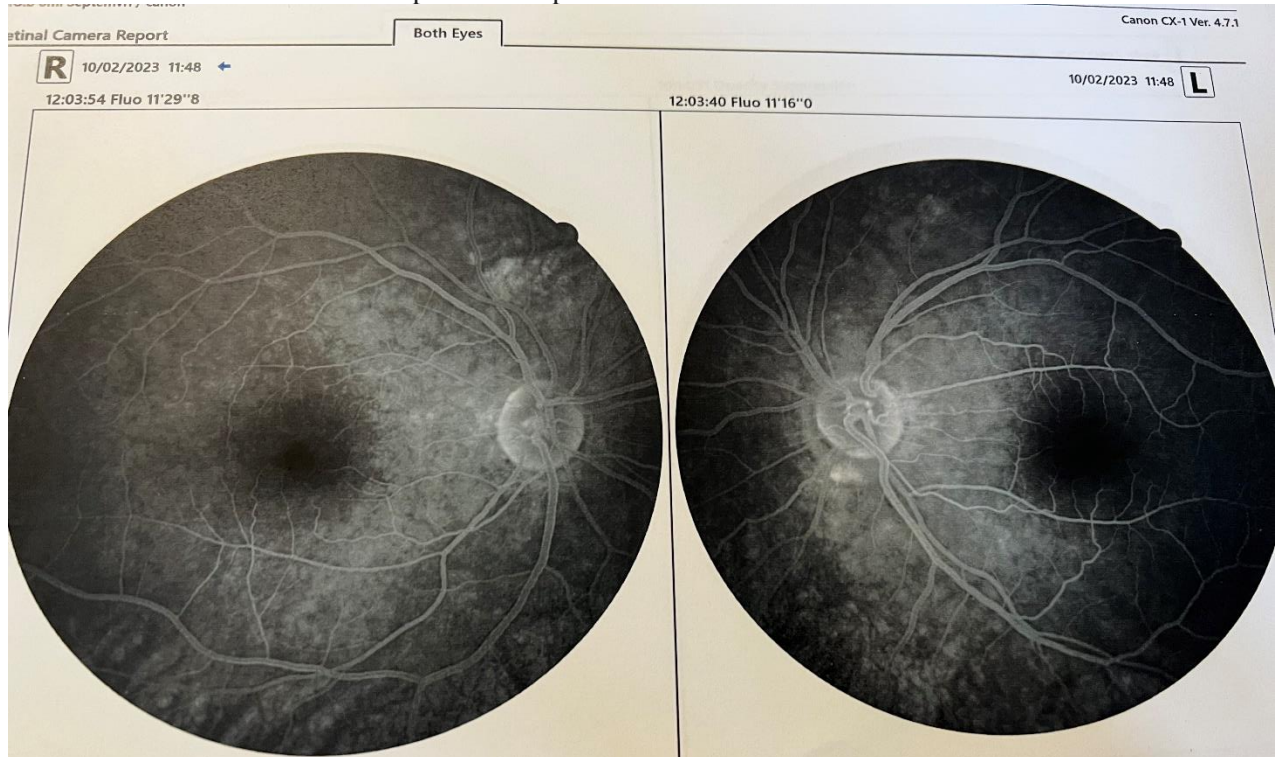


Figure 6. Fluorescein angiography

Discussion

Ocular vascular occlusive disorders collectively constitute the most common cause of visual disability in the middle-aged and elderly population, although no age is immune. For their management, the most important piece of information required, from the points of view of both patient and ophthalmologist, is the natural history of visual outcome [8].

Combined arterial and venous blockage is reported to occur in both young and old people and many of them with systemic comorbidities.

The important systemic association reported with CRAO are advanced age, hypertension, hyperlipidemia, diabetes, and glaucoma in the older age group (>40 years), and inherited and acquired coagulation disorders and hyperviscosity syndrome-related factors in younger age group (<40 years). All these conditions generate one or other factors of Virchow's triad—hypercoagulability, damage to the vessel endothelium, and hemodynamic changes such as venous stasis or turbulence. These features ultimately contribute to venous thrombosis formation thereby causing arterial obstruction by back pressure leading to combined arterial and venous occlusion [9,10,11].

In majority of cases in the elderly population, retinal vein occlusion is the primary pathology. Due to atherosclerotic changes in the arteries, the vein gets compressed usually at arteriovenous crossing leading to turbulent blood flow and dynamic obstruction or actual thrombus formation and mechanical blockage. The increased intravascular pressure may cause back pressure to the arterial circulation leading to artery occlusion [12].

In the younger age group, coagulation disorders like anticardiolipin syndrome, von Willebrand syndrome, protein S deficiency, or Factor V mutation are known risk factors for combined occlusion [13,14].

Keyser et al. have described four healthy men who developed cilioretinal artery occlusion associated with central retinal vein occlusion. Fluorescein angiography showed abnormal central retinal artery inflow, as evidenced by prolonged, irregular filling of the branch retinal arteries. The patients were treated with systemic corticosteroids. All of the patients had initial improvement in vision. However, three of the four patients had recurrent episodes of visual loss [15].

Conclusion

Combined central retinal vein and cilioretinal artery occlusion is a rare emergency leading to acute vision loss. It is a common vascular pathology in young, otherwise healthy patients. Despite the initial alarming symptoms, young patients with this diagnosis should be monitored closely, and intervention should be resorted to when necessary.

References

1. Hayreh SS, Fraterrigo L, Jonas J. Central retinal vein occlusion associated with cilioretinal artery occlusion. *Retina*. 2008;28(4):581–594.
2. Kolar P. Risk factors for central and branch retinal vein occlusion: a meta-analysis of published clinical data. *J Ophthalmol*. 2014;2014:724–780.
3. Lahey JM, Tunç M, Kearney J, Modlinski B, Koo H, Johnson RN, Tanaka S. Laboratory evaluation of hypercoagulable states in patients with central retinal vein occlusion who are less than 56 years of age. *Ophthalmology*. 2002;109(1):126–131.
4. Stoffelns BM, Laspas P. Cilioretinal artery occlusion. *Klin Monbl Augenheilkd*. 2015;232(4):519–524.
5. Sedlak L, Świerczyńska M, Pojda-Wilczek D. Combined central retinal vein and cilioretinal artery occlusion in a 25-year-old woman. *Rom J Ophthalmol*. 2022 Apr-Jun;66(2):178-184.

6. Hayreh SS. Acute retinal arterial occlusive disorders. *Prog Retin Eye Res.* 2011;30(5):359–394.
7. Ageno W, Beyer-Westendorf J, Garcia DA, Lazo-Langner A, McBane RD, Paciaroni M. Guidance for the management of venous thrombosis in unusual sites. *J Thromb Thrombolysis.* 2016;41(1):129–143. [
8. Hayreh SS. Ocular vascular occlusive disorders: natural history of visual outcome. *Prog Retin Eye Res.* 2014;41:1–25.
9. Sengupta S, Pan U. Combined branch retinal vein and branch retinal artery occlusion-clinical features, systemic associations, and outcomes. *Indian J Ophthalmol* 2017;65:238-41.
10. Ratra D, DhupperM. Retinal arterial occlusions in the young: Systemic associations in Indian population. *Indian J Ophthalmol* 2012;60:95-100.
11. Schmidt D. Comorbidities in combined retinal artery and vein occlusions. *Eur J Med Res* 2013;18:27.
12. Kolar P. Risk factors for central and branch retinal vein occlusion: A meta-analysis of published clinical data. *J Ophthalmol* 2014;2014:724780.
13. Desai S, Rai N, Kulkarni P, Natarajan S. Combined CRVO with CRAO in a patient with protein C deficiency. *Retin Cases Brief Rep* 2014;8:145-9
14. Lemos JA, Teixeira C, Carvalho R, Fernandes T. Combined central retinal artery and vein occlusion associated with factor V Leiden mutation and treated with hyperbaric oxygen. *Case Rep Ophthalmol* 2015;6:462-8.
15. Keyser BJ, Duker JS, Brown GC, Sergott RC, Bosley TM. Combined central retinal vein occlusion and cilioretinal artery occlusion associated with prolonged retinal arterial filling. *Am J Ophthalmol.* 1994 Mar 15;117(3):308-13.