

MJA

Macedonian Journal of Anaesthesia

A Journal on Anaesthesiology, Resuscitation, Analgesia and Critical Care

Vol. 7 No 2, October 2023

Journal of the Macedonian Society of Anaesthesiologists
and Macedonian Society of Critical Care Medicine

Publisher:

Department of Anaesthesia and Reanimation Faculty of Medicine,
“Ss. Cyril and Methodius” University, Skopje, R.N.Macedonia

Apotel® 1000mg / 6.7ml

I.V. Paracetamol

БЕЗБЕДНА АНАЛГЕЗИЈА

менаџирање на болка кога сте загрижени за безбедноста



i.v. paracetamol за прв пат во Европа е применет во 2001 година, а денес поради неговата докажана безбедност и ефикасност е прв од избор **аналгетик и антипиретик**.

Предоперативна и Интраоперативна Аналгезија:

Предоперативна аналгезија е дефинирана како третман кој што започнува пред оперативниот зафат се со цел да се превенира воспоставувањето на централна сензибилизација на болка.

i.v. paracetamol е безбеден, добро толериран лек со докажана ефикасност како **предоперативна и интраоперативна аналгезија** за умерена до средна болка при оперативни зафати.

Голем број на клинички студии ја докажуваат ефикасноста на **i.v. paracetamol** како **предоперативна и интраоперативна аналгезија**.

КЛИНИЧКА СТУДИЈА:

Ефект од **предоперативен i.v. paracetamol** за постоперативни аналгетски потреби кај пациенти кои се подложни на оперативни зафати. ASreenivasulu, RPrabhavathi, 2015

Цел: Да се утврди ефикасноста на **предоперативната употреба на 1000mg i.v. paracetamol** кај постоперативните болки и аналгетски потреби кај пациенти подложни на хируршки зафати.

Метод: 60 пациенти беа поделени во две рандомизирани групи од по 30 пациенти.

На I. Група им беше администрирано **ампула од 1000mg i.v. paracetamol** разредена **0,9%NaCl** р-ор 30 минути пред индукција (**ГРУПА П**),

На II. Група им беше администрирано **i.v. 0,9% NaCl** р-ор **100мл** 30 минути пред индукција (**ГРУПА НС**)

Сите пациенти беа индуцирани со **i.v. thiopentone 5mg/kg**, **i.v. fentanyl 2µg/kg**, **i.v. vecuronium 0.1mg/kg**

Постоперативниот резултат на болка беше мерен со **Визуелна Аналогна Скала (ВАС)** од "0-10". Исто така беше забележувана и **постоперативната употреба на tramadol** како спасувачки аналгетик. Инциденцата на **постоперативно гадење и повраќање (ПОПГ)** и други компликации исто така беа забележувани во пост оперативниот период.

Резултатот на постоперативната болка беше забележуван во интервали 15 мин, 30 мин, 1 час, 2 часа, и 6 часа.

Заклучок: Предоперативна администрација на **1000mg i.v. paracetamol** кај пациенти подложни на оперативен зафат обезбедува **статистички задоволителна аналгезија**, и ја **намалува постоперативната употреба на tramadol**. Оттука **1000mg i.v. paracetamol** може безбедно да се администрира како превенција при оперативни зафати.

Резултат:

Табела 1: Споредба на средниот резултат на болка (ВАС) помеѓу двете групи

Интервали	I Група П	II Група НС	P вредност
15 мин	2.06 ± 0.63	2.61 ± 0.56	0.0006
30 мин	2.35 ± 1.17	3.84 ± 1.55	0.0001
1 час	2.42 ± 1.12	2.87 ± 0.99	0.0989
2 часа	2.13 ± 1.06	2.52 ± 0.89	0.1219
6 часа	2 ± 0.52	2.52 ± 0.89	0.0549

Табела 2: Споредба за потребите од tramadol помеѓу двете групи

Интервали	I Група П	II Група НС	P вредност
До 1 час	4 (12.90%)	15 (50%)	0.0002
1-2 часа	3 (9.68%)	2 (6.45%)	0.64
2-6 часа	1 (3.23%)	3 (9.68%)	0.301
Вкупно	8 (25.81%)	20 (64.52%)	0.002

Табела 3: Споредба на ПОПГ помеѓу двете групи

ПОПГ	
I Група П	II Група НС
0	4

i.v. Paracetamol + јак опоид	МНОГУ ЈАКА БОЛКА
i.v. Paracetamol + слаб опоид	ЈАКА БОЛКА
i.v. Paracetamol + NSAID i.v. Paracetamol + rescue medicine	УМЕРЕНА БОЛКА
i.v. Paracetamol + rescue medicine	СЛАБА БОЛКА

Мултимодално менаџирање на постоперативна болка

i.v. Paracetamol е атрактивна компонента за мултимодално менаџирање на болка.

- **Синергистичко делување**
- **Зголемување на аналгетски ефект**
- **Значително намалување на болка**
- **Редукција на дозата на опоидни лекови за - 40% во првите 24 часа**

- **Намалување на несаканите ефекти поврзани со монотерапија на NSAID и опоидни лекови**
- **Ублажување на акутна и хронична болка**

Baxter


WHEN EARLY RECOVERY REALLY MATTERS



Дистрибутер за Македонија



FARMA TREJD



Macedonian Journal of Anaesthesia

A Journal on Anaesthesiology, Resuscitation, Analgesia and Critical Care

Editor-in-Chief

Mirjana Shosholcheva

Deputy Editors

Andrijan Kartalov

Biljana Kuzmanovska

Assistant Editors

Marija Sholjakova

Jordan Nojkov

Statistical revision

Beti Zafirova Ivanovska

Legal and Ethical Issues

Biljana Janeska

Associate Editors

Jasminka Nanceva

Biljana Shirgovska

Atanas Sivevski

Marija Jovanovski-Srceva

Production Editor

Vanja Gievski

Aleksandra Gavrilovska Brzanov

Publisher

Department of Anaesthesia and Reanimation

Faculty of Medicine

“Ss. Cyril and Methodius” University

Skopje, R.N.Macedonia

Editorial Board

Zorka Nikolova-Todorova (R.N. Macedonia)

Nikola Jankulovski (R.N. Macedonia)

Sonja Topuzovska (R.N. Macedonia)

Rozalinda Popova (R.N. Macedonia)

Igor Kaftandziev (R.N. Macedonia)

Karin Khuenl-Brady (Austria)

Quirino Piacevoli (Italy)

Radmilo Jankovic (Serbia)

Olegs Sabelnikovs (Latvia)

Jannicke Mellin-Olsen (Norway)

Meral Kanbak (Turkey)

Nebojsa Ladjevich (Serbia)

Zoran Karadjov (R.N. Macedonia)

Hristo Bozov (Bulgaria)

Zuhal Aykaç (Turkey)

Katarina Shakich (Hrvatska)

Jasmina Jakupovich-Smajich (BIH)

Vojislava Neskovic (Serbia)

Daniela Miladinova (R.N. Macedonia)

Paul Zilberman (Israel)

Antigona Hasani (Kosovo)

Hülya Bilgin (Turkey)

Sinisha Stojanoski (R.N. Macedonia)

Berrin Günaydin (Turkey)

Rudin Domi (Albanija)

Fatma Sarıcaoğlu (Turkey)

Slobodan Ristovski (R.N. Macedonia)

Franceska Rubulotta (UK)


Meri Trajkovska (R.N. Macedonia)

Elizabeta Stojovska Jovanovska

(R.N. Macedonia)

Proofreading

Daniela Nacevska Stojcevska



CONTENT

EDITORIAL

UDK: 616.61-008.64:[616-008.9:577.125

FABRY DISEASE – A CHALLENGE FOR NEPHROLOGIST9
Gjorgjievski N, Karanfilovski V, G. Nikolov I

1. ORIGINAL ARTICLE

UDK: 616-006.6-085.277-089.819.1-06-053.2

**EVALUATION OF EARLY COMPLICATIONS DURING PLACEMENT
OF LONG-TERM CENTRAL VENOUS CATHETERS IN PEDIATRIC
ONCOLOGY PATIENTS.....11**
Donev Lj, Lleshi A, Angjushev D, Litajkovska S, Demjanski V, Mikjunovikj-Derebanova Lj

2. ORIGINAL ARTICLE

UDK: 616.441-008.64:[612.441.084:599.323.4

**INDUCTION OF HYPOTHYROIDISM IN ALBINO WISTAR
RATS - EXPERIMENTAL ANIMAL MODEL.....22**
Stojkovska N, Dimovska I, Ampova H, Nikoloska V, Jovanovski Srceva M, Stojanoski S

3. ORIGINAL ARTICLE

UDK: 616.71-033.2-073.916:616.19-006.6

**BREAST CANCER TUMOR CHARACTERISTICS AND
METASTATIC BONE SCINTIGRAPHY FINDINGS36**
Jankulovska A, Manevska N, Lazareva E, Iljovska M, Jovanovski-Srceva M, Stojanoski S

4. ORIGINAL ARTICLE

UDK: 618.14-006.6-073.432.19:618.173

**DOPPLER ULTRASOUND SCORING SYSTEM FOR IDENTIFICATION
OF ENDOMETRIAL CANCER IN POSTMENOPAUSAL
PATIENTS.....46**
Aleksioska Papestiev I, Antovska V, Sivevski A, Karadzova D, Spasovski S, Ilieva N

5. REVIEW

UDK: 616-008.831-056.7

**FABRY DISEASE – CLINICAL REVIEW
RARE, BUT NOT SO RARE!.....56**
Gjorgjievski N,, Karanfilovski V, G. Nikolov I

6. CASE SERIES

UDK: 616-008.815-074:616.132-089.853

**D DIMERS - A POWERFUL TOOL IN THE DIAGNOSIS OF
AORTIC DISSECTION62**
Jovanoski M, Nikolovski R, Bojovski I, Petkovski D, Boshev M, Georgiev A

7. CASE SERIES	
UDK:616.24-005.98:616.14-089.85	
ACUTE PULMONARY EDEMA ASSOCIATED WITH INTRAVASCULAR ABSORPTION (OHIA) SYNDROME DURING OPERATIVE HYSTEROSCOPY.....	74
Gunaydin DB, Erel S, Koksall N, Buyukgebiz Yeşil BM, Emmez G	
8. CASE REPORT	
UDK: 616.27-006-089.5-053.2	
SUPRAGLOTTIC AIRWAY DEVICE(IGEL) IN A ELEVEN MONTH OLD PATIENT WITH MULTIPLE NECK MASS AND ANTERIOR MEDIASTINAL MASS.....	78
Hernandez AG, Simpao AS	
9. CASE REPORT	
UDK: 618.25-007.274	
A CASE OF TWIN PREGNANCY WITH CONJOINED TWINS	84
Bushinoska Ivanova G, Ivanov J, ,Bushinoska J	
10. CASE REPORT	
UDK: 616.132.3-036.1-02:[613.83:633.888	
MARIJUANA-INDUCED ACUTE CORONARY SYNDROME IN A YOUNG PATIENT	88
Boshev M, Pejkov H, Jovanoski M, Bojovski I, Andov M, Georgiev A	
11. CASE REPORT	
UDK: 616.155.294:616-089.163	
PREOPERATIVE MANAGEMENT OF THROMBOCYTOPENIA AND PSEUDOTHROMBOCYTOPENIA	93
Kraleva S, Petkov N, Trojikj T, Crnusheva S, Markoska V	
12. CASE REPORT	
UDK: 616-001.11:797.215]:615.853.3	
DELAYED TREATMENT OF DECOMPRESSION SICKNESS TYPE II RESPONSIVE TO HYPERBARIC OXYGEN	98
Etemi J, Nacevska Gjorgjeska A, Pejkova S, Peev I, Lleshi A, Cvetkova Mladenovska M	
13. CASE REPORT	
UDK: 616-089.5:616-056.7	
ANESTHESIA IN PATIENT WITH SJÖRGEN’S SYNDROME	106
Trojikj T, Kraleva S, Spasovski Z, Bozinovska Beaka G, Markovska Z, Pavlova Bogoevska N	
14. LETTER TO THE EDITOR	
UDK: 615.816.2:616.22	
THE THREE REVOLUTIONS IN AIRWAY MANAGEMENT	109
Biljana Shirgoska	
GUIDELINES FOR AUTHORS.....	113

FABRY DISEASE – A CHALLENGE FOR NEPHROLOGIST

Authors: Nikola Gjorgjievski^{1,2}, Vlatko Karanfilovski^{1,2}, Igor G. Nikolov^{1,2}

¹ *University Clinic of Nephrology, Skopje, Republic of North Macedonia*

² *Faculty of Medicine, University “Ss. Cyril and Methodius” Skopje, Republic of North Macedonia*

Fabry disease (FD) is a rare disorder of fat metabolism. It is caused by partial or complete inactivity of the lysosomal enzyme α -galactosidase A (α -Gal A), which leads to gradual builds up of glycosphingolipids. It happens in a variety of cells and tissues throughout the body and within a wide range of clinical symptoms (1,2). In adult males with the classic Fabry phenotype, chronic kidney disease (CKD) may appear, and it may progress to end-stage renal disease (ESRD). In these patients, FD may have a significant cause of morbidity and early mortality. It has been shown that FD affects 0.20%–1.2% of male hemodialysis patients, but the prevalence of FD among patients with CKD of unknown origin is believed to be 15–80 times higher (2,3). Hence, the occurrence of unexplained left ventricular hypertrophy in CKD patients of unknown cause may be a clinical rationale to particularly screen for FD (3).

It has been shown that Fabry nephropathy includes an onset of proteinuria in infancy and adolescence, a subsequent deterioration in renal function in early adulthood, and ultimately progression of CKD in the third to fifth decades of life (3). Patients without the neuropathic, cutaneous, or ocular signs of classical FD could nonetheless develop CKD, as well as heterozygous females occasionally present with the typical phenotype of FD, including ESRD (3). The stage of the enzymatic deficit has been linked to the rate of nephropathy progression from the early stages, but this relationship is not fully understood.

The renal symptoms of FD are influenced by the gradual accumulation of globotriaosylceramide (Gb3) in podocytes, endothelial, epithelial and tubular cells. On light microscopy these accumulations typically present as vacuoles in cells cytoplasm. More specific are electron microscopy findings where cellular inclusions within lysosomes surrounded by a single membrane are described as zebra bodies or myelin-like figures (4). Fusion of the podocyte foot processes, focal glomerular and tubular epithelial necrosis and development of segmental and global glomerulosclerosis, tubular atrophy and interstitial fibrosis, might be seen as the condition worsens (4). Finding parapelvic cysts during renal imaging may indicate the presence of FD (3). Hence, in patients with microalbuminuria and CKD of unknown origin presence of parapelvic cysts should raise suspicion for FD. Dialysis or kidney transplantation may be used to treat a sizable portion of FD patients. The patients' survival after kidney transplantation was comparable to that of patients under 55 with standard nephropathies, and graft survival at 3 years was no worse than in patients with other nephropathies (72% versus 69%) (3).

Enzyme replacement therapy (ERT) worked the best for patients who began it at a younger age and with less renal damage. Patients with severe renal disease and/ or older onset of treatment both exhibited less benefit despite the treatment (5). Hence, early diagnosis of FD and prompt initiation of ERT has an important impact on patients' survival.

References:

1. Guo, W., Xie, Y., Ji, P. et al. The evolution of the initial manifestations and renal involvement of chinese patients with classical and late-onset Fabry disease at different sexes and ages. *BMC Nephrol* 24, 90 (2023). <https://doi.org/10.1186/s12882-023-03138-w>.
2. Shih CY, You ZH, Tsai SF, Wu MJ, Yu TM, Chuang YW, Chen CH. Diagnosis and Management of Fabry Disease in High-Risk Renal Disease Patients in Taiwan: A Single Center Study. *Transplant Proc.* 2023 May;55(4):788-791. doi: 10.1016/j.transproceed.2023.03.012. Epub 2023 May 23. PMID: 37230899.
3. Sunder-Plassmann G. Renal manifestations of Fabry disease. In: Mehta A, Beck M, Sunder-Plassmann G, editors. *Fabry Disease: Perspectives from 5 Years of FOS*. Oxford: Oxford PharmaGenesis; 2006. Chapter 21. Available from: <https://www.ncbi.nlm.nih.gov/books/NBK11571/>
4. Santostefano M, Cappuccilli M, Gibertoni D, Fabbrizio B, Malvi D, Demetri M, Capelli I, Tringali E, Papa V, Biagini E, Cenacchi G, Galdi A, Donadio V, Liguori R, Zoli G, La Manna G, Pasquinelli G. Fabry Disease Nephropathy: Histological Changes With Nonclassical Mutations and Genetic Variants of Unknown Significance. *Am J Kidney Dis.* 2023 Jun 9: S0272-6386(23)00655-8. doi: 10.1053/j.ajkd.2023.03.015. Epub ahead of print. PMID: 37301502.
5. Germain DP, Charrow J, Desnick RJ, et al Ten-year outcome of enzyme replacement therapy with agalsidase beta in patients with Fabry disease. *Journal of Medical Genetics* 2015; 52:353-358.

EVALUATION OF EARLY COMPLICATIONS DURING PLACEMENT OF LONG-TERM CENTRAL VENOUS CATHETERS IN PEDIATRIC ONCOLOGY PATIENTS

Donev Lj¹, Lleshi A¹, Angjushev D¹, Litajkovska S², Demjanski V¹, Mikjunovikj-Derebanova Lj¹

¹ University Clinic for Anesthesia, Reanimation and Intensive Care Medicine, University "Ss. Cyril and Methodius", Skopje, Republic of North Macedonia

² University Clinic for Pediatric Surgery, University "Ss. Cyril and Methodius", Skopje, Republic of North Macedonia

ABSTRACT

Introduction: New protocols for the application of chemotherapy in pediatric oncology patients require the use of a central venous catheter. The use of central venous catheters is time-limited and can last from several months to a year. For this purpose, we usually use a long-term central venous catheter, which can be an external tunneling long-term central venous catheter (ETLCVC) and a totally implanted long-term central venous catheter (TILCVC).

Aim: The aim of this study is to determine the advantage of ETLCVC over TILCVC and to compare the incidence of early complications after the implementation of central venous catheters following: migration (malposition) of the catheter tip, pneumothorax and arrhythmias.

Material and Methods: This study is a prospective, interventional clinical study involving a total of 120 pediatric patients aged 2-14 years with leukemia, lymphomas and solid tumors. The patients were divided into two groups (n=60). In patients from group 1, ETLCVC was applied, while in patients from group 2, TILCVC was applied. With the parents of the patients who meet the criteria for inclusion in the study, an informative interview was conducted and an informed written consent for participation in the study was obtained.

Results: In the group of patients in whom a TILCVC was implanted, two patients had an arrhythmia, one patient had catheter malposition, and one patient had a pneumothorax. In the group of patients with an implanted ETLCVC, only one patient had an arrhythmia.

Conclusion: Incidence of early complications (catheter tip malposition, pneumothorax and occurrence of arrhythmias) in our study were more frequent in patients in whom TILCVC was applied, but this difference did not have statistical significance.

Key Words: complications from long-term central venous catheters, long-term implanted central venous catheters, pediatric oncology patients.

Introduction

Malignant diseases in pediatric patients are a rare condition, but every year in our country about 80 pediatric patients are registered in which it is necessary to place a long-term central venous catheter (1). Malignant diseases are indicated as the second most common cause of death in patients older than 12 months (2). Psychological traumas can cause other complications in the future, and hence, how they cope with the illness and how long they are treated for this condition is vital for young patients.

In pediatric hemato-oncology, fully implanted long-term central venous catheters (external tunneling long-term central venous catheters and totally implanted long-term central venous catheters) are used (3). However, for the selection of an appropriate catheter, the needs of the pediatric oncology patient play a significant role. This choice usually depends on a combination of factors, including planned treatment time, anticipated catheter use time, and institutional capacity (4). It is known that cytostatic drugs have a vascular irritating effect, lead to progressive load on the venous system and therefore multiple peripheral venipunctures lead to behavioral and physiological reactions conditioned by pain or anxiety (4).

Because children have an inadequate peripheral venous vascular system, during cytostatic treatment it is necessary to place a long-term central venous catheter to ensure central venous access (5). Since treatment can range from several weeks to several years (for example, in children with leukemia, the process takes an average of two years), long-term central venous catheters can be especially valuable for the daily application of chemotherapy. They are essential tools that enable safe infusions of chemotherapeutic agents, supportive drugs, blood products, hydration and administration of total parenteral nutrition (6). Finally, frequent painful punctures of peripheral veins can be avoided in this way, and long-term central venous catheters are therefore thought to reduce daily stress and improve the quality of life of pediatric patients (7,8).

Pediatric oncology patients with a long-term central venous catheter represent a special entity, as they require special treatment. Central catheters can be placed by different techniques ("blind" percutaneous venipuncture guided by anatomical landmarks, percutaneous puncture using ultrasound and cannulation of peripheral venous line). Catheter placement always carries potential risks and the possibility of complications depending on which vein is used for venipuncture, which technique is applied and which catheter will be used (9,10). The risk of complications is particularly present in immunocompromised pediatric oncology patients (6).

Complications can occur during the application of the catheter itself, immediately after the application, but also after a certain time. Hence, they can be classified as early (≤ 30 days) or delayed (> 30 days) (11).

They can also be classified according to severity, namely: minor and major complications. Minor complications do not require surgical intervention or appropriate medical therapy for less than 24 hours. Major complications include complications that require early surgical intervention or prolonged medical therapy with a stay in hospital for more than 24 hours, and may result in death.

Problems occur at the time of placement of the central venous catheter, which usually consist of injury to surrounding vital structures or incorrect positioning of the catheter tip. The most

common early complications are: cardiac arrhythmia (23% - 25%), accidental arterial puncture (0% - 15%), hemothorax (0.1% - 11%), pneumothorax (1% - 4%) and air embolism (12-15). The most common late complications in the placement of central catheters are: migration, mechanical complications (9%), problems related to the catheter material (2%), infections, thrombosis (50%) and pooling of fibrin in the catheter (14-17).

All these traumatic, infectious or thrombotic complications can be life-threatening, result in prolonged hospitalization and are certainly accompanied by additional costs for prolonged treatment (18,19). In these cases, a non-functional central venous line is simply removed, after which there is a need to place a new central venous catheter (20).

Malposition of the central venous catheter is a common early complication and represents dislocation of the catheter tip. In this complication, the tip of the central catheter is not positioned in the superior vena cava. It can be found the most commonly in the azygos vein, the internal mammary vein, and the left superior intercostal vein. This malposition of the tip of the catheter is demonstrated by the application of lung X-ray.

Hemothorax as an early complication occurs during accidental puncture of intrathoracic arteries or laceration of subclavian vein (21). Each hemothorax can collect a ½ to 1l of blood, enough to cause hemorrhagic shock if the bleeding is not under control.

Another early complication during placement of central catheters is accidental injury to the parietal pleura and the occurrence of pneumothorax (22). This unwanted complication can be prevented by using the ultrasound technique. It has been proven that the use of the ultrasound technique when placing the central venous catheter is a safer method than the technique of anatomical markers.

Arrhythmias occur as a result of placement of the lead wire or the tip of catheter in the heart and their mechanical irritation of the endocardium. The most cases are benign atrial arrhythmias that are reversible, especially with withdrawal of the catheter or guide wire. In some cases, dysrhythmias can be caused, namely complete heart block and the appearance of asystole (23). In these cases, an increased risk of damage to the tricuspid valve, cardiac perforation and cardiac tamponade may occur accidentally. The guide wire can lead to a lesion of the thoracic duct accompanied by the appearance of a chylothorax.

As noted in previous studies, different types of central venous catheters are associated with different levels of infection risk. Lower rates of catheter-related bloodstream infection were observed in patients with indwelling catheters versus tunneled catheters, and the highest incidence of infection was found with external tunneled long-arm central venous catheters (24). Colonizing microorganisms become embedded in a microbial biofilm within 48-72 hours of catheter placement. They can develop resistance to traditional systemic antibiotics, which can be very difficult to eradicate and can become a recurrent cause of infection (25).

Aim of the Study

The primary objective of the study is to determine the incidence of early complications in patients with two types of long-term central venous catheter (1. tunneling – Hickman-monolumen

Broviac-multilumen and 2. totally implanted long-term central venous catheter - Bard-port).

Material and Methods

Our study is prospective, interventional clinical study performed in 120 hemato-oncology pediatric patients scheduled for chemotherapy using a long-term central venous catheter and conducted in the period from January 2021 to January 2023.

The study was performed at the University Clinic for Traumatology, Orthopedics, Anesthesia with Resuscitation and Intensive Care and Emergency Center (UC TOARILUC - KARIL) in collaboration with the University Clinic for Pediatric Surgery and the Clinic for Children's Diseases.

Pediatric patients with acute lymphoblastic leukemia, myeloid leukemia, lymphoma (non Hodgkin and Hodgkin) and solid tumors (CNS tumors, rhabdomyosarcoma and Wilms' tumor and bone tumors) were included in the study. Pediatric patients who meet the criteria for inclusion in the study were included in the same, and those who had elements for exclusion from the study were excluded.

In the study were included pediatric patients from 2 to 14 years old, patients with BMI < 25 kg/m², patients classified according to the American Association of Anesthesiologists (ASA) in class I - III, patients with normal values of infectious markers, neutrophils and platelets and proper hemostasis and patients whose parents or guardians signed an informed written consent to be included in the study.

The patients under 2 years old and older than 14 years, with BMI > 25 kg/m², patients with infection or suspected infection who had previously been treated with a broad-spectrum antibiotic, patients with high infectious parameters, patients with a disorder in hemostasis, thrombocytopenia and neutropenia, patients with anemia (Hb < 100g/l), patients who were allergic to heparin and pediatric patients with kidney or liver disease were excluded from the study.

The patients were randomized into two equal groups. In the first group there were included 60 pediatric oncology patients in whom the totally implanted long-term central venous catheter was applied under general endotracheal anesthesia. In the second group, 60 pediatric oncology patients were included in whom the external tunneling long-term central venous catheter was applied under general endotracheal anesthesia.

In agreement with the colleagues from the Clinic for Children's Diseases and the pre-operative preparation carried out, the date for placing the central venous catheter was determined. One day before performing the procedure, an examination and anesthesiology evaluation of the patients was performed in the anesthesiology outpatient clinic at the UC TOARILUC.

After admission to the Clinic for Pediatric Surgery, the invasive procedure was started. In pediatric patients, standard non-invasive hemodynamic monitoring (ECG, non-invasive blood pressure and pulse oximetry) was performed in the operating room. After induction of inhalation anesthesia (Sevoflurane-O₂), a peripheral venous line was placed through which

muscle relaxants and opioid analgesics were administered. After endotracheal intubation and adequate hemodynamic and respiratory monitoring, the procedure for placing a central venous catheter began. The patient was placed in an adequate position (Trendelenburg position) and the operating field was prepared using aseptic technique. After isolation of the surgical field for port placement, an ultrasound technique was used to identify anatomical structures. We used ultrasound Simens Acuson P500 with linear probe. The placement of the central venous catheter in both studied groups was performed through the vena jugularis interna according to Seldinger's method.

In the patients from the first group, after we punctured v. jugularis interna and we secured venous access, a guide-wire have been placed through which the silicone dilator was pulled, the tip of which should be in the venous blood vessel. In the next step, a subcutaneous pocket was made with a surgical technique in the middle clavicular line, 3-5cm below the right clavicle. After exact hemostasis, the silicone reservoir to which the silicone catheter was connected was placed in the subcutaneous pocket. Then, with a subcutaneous tunneling procedure, communication between the subcutaneous pocket and the puncture site of the blood vessel was established. The catheter was passed through the subcutaneous tunnel using a metal guide to the insertion site of the silicone dilator. In the next step, the catheter was inserted into the venous blood vessel through the placed silicone dilator. The tip of the silicone catheter through the v. jugularis interna was placed in v. cava superior. The height of the silicone catheter was determined by measuring from the insertion site to the sternal angle between the manubrium and the body of the sternum. The subcutaneous pocket was closed with surgical sutures. The position of the fully implanted catheter was checked by an aspiration probe through the silicone reservoir. The test was considered positive if a return of venous blood was obtained. At the end of the procedure, the catheter was injected with 2.5ml of heparin solution (100 IU of heparin in 1ml of physiological solution). The position of the tip of the central catheter was confirmed by a native X-ray of the lungs.

In the second group, in patients where the external tunneling long-term central venous catheter was applied, the initial phase of the procedure was identical to that of patients from group 1. Venous access was secured by puncturing the vena jugularis interna and a guide wire was placed, after which the metal cannula was removed from the blood vessel. The silicone dilator, which acts as a guide and whose tip should be in the venous blood vessel, was pulled over the guide wire. In the middle clavicular line, 3-5cm below the clavicle, a small subcutaneous incision of 1cm was made. After achieving adequate hemostasis, a subcutaneous tunneling procedure was performed from the site of the surgical incision to the insertion site of the silicone dilator. Then, through the created subcutaneous tunnel, the silicone catheter was entered from the site of the surgical incision to the placed dilator with the help of a plastic guide. Through the guide dilator, the tunneling central venous catheter was entered into the venous blood vessel with the tip placed in v. cava superior. The outer part of the catheter was fixed with a surgical suture to the surgical incision. The tunneling central venous catheter has a safety cuff (Surecuff-Tissue Ingrowth cuff) which was placed in the subcutaneous tunnel 1-2cm from the surgical incision. This safety cuff provides fixation of the catheter to the surrounding subcutaneous tissue, but at the same time provides a physical barrier to the transmission of microorganisms. Procedures for verifying the position and height of the catheter were identical to those of patients in group 1.

After finishing the interventional procedure and awakening from general anesthesia, patients from both groups were monitored in the recovery room for one hour, where possible early

complications were monitored. After completion of the stay in the recovery room and X-ray diagnostics performed, the patients were referred to the Children’s Disease Clinic where they were monitored for late complications of the invasive procedure. The prescribed chemotherapy could be started on the same day.

To reduce the possibility of occlusion of the central venous catheter, heparin was applied intraluminally in doses of 10-100 i.e./ml before placing the catheter with a volume of 2.5ml. The occlusion of the central venous catheter could lead to a delay in oncological treatment, as well as to a complete change of the central venous catheter itself if previously thrombolytic therapy did not give the expected results (17).

Results

The results obtained by processing and analyzing data from 120 subjects, hemato-oncology pediatric patients who were to be administered chemotherapy using a long-term central venous catheter, are shown.

The gender structure of the respondents consisted of 68 male patients (56.67%) and 52 female patients (43.33%).

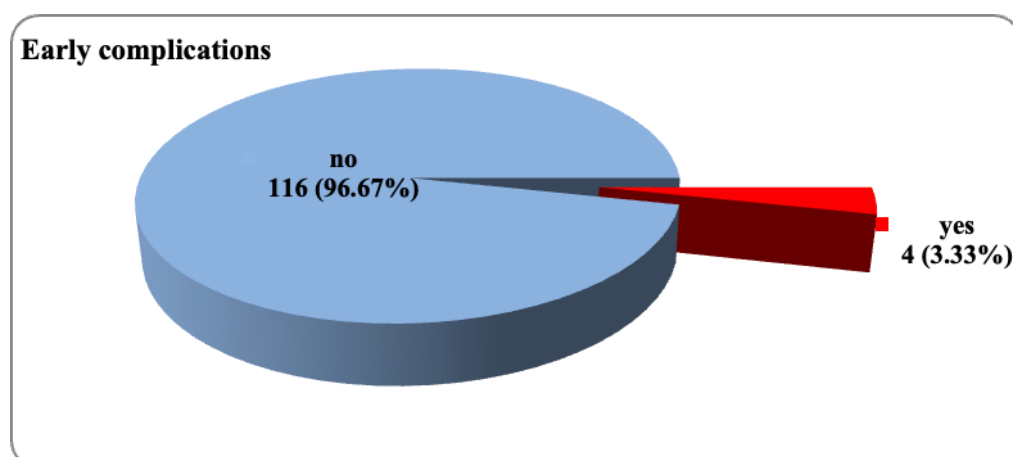
Patients ranged in age from 2 to 14 years, with a mean age of 6.1 ± 3.5 years. Half of the patients were older than 5 years (median=5 years).

Table 1. Characteristics of the sample

Variable		n (%)
Gender	Male	68 (56.67)
	Female	52 (43.33)
Age (years)	(mean \pm SD) (min – max)	(6.1 \pm 3.5) (2 – 14)
	median (IQR)	5 (3 – 9)

Early complications after the application of a central venous catheter were presented by 4 patients, that is, the incidence of early complications was 3.33% (Figure 1).

Figure 1. Percentage of early complications.



Regarding the type of early complications, malposition was noted in 1 patient (0.83%), arrhythmia in 2 patients (1.67%), and pneumothorax in 1 (0.83%) patient.

Early complications were noted in 1 patient (1.67%) from the group with ETLCVC and 3 patients (5%) from the group with TILCVC. The tested difference in the distribution of patients with and without early complications, depending on the type of central venous catheter placed, was not statistically significant ($p=0.31$) (Table 2).

Table 2. Incidence of early complications.

Early complications	n	group 1 n (%)	group 2 n (%)	P - value
Yes	4	1 (1.67)	3 (5)	$X^2=1.0$ $p=0.31$
No	116	59 (98.33)	57 (95)	

group 1 - ETLCVC (external tunneling long-term central venous catheter)

group 2 - TILCVC (a totally implanted long-term central venous catheter)

X^2 (Pearson Chi-square test)

Malposition as an early complication of central venous placement was manifested by 1 patient (1.67%) from the group with applied TILCVC.

The frequency of registered malposition did not differ significantly between the groups with ETLCVC and TILCVC ($p=0.315$) (Table 3).

Table 3. Incidence of malposition of the catheters.

Malposition	n	group 1 n (%)	group 2 n (%)	P - value
Yes	1	0	1 (1.67)	$X^2=1.1$ $p=0.315$
No	119	60 (100)	59 (98.33)	

group 1 - ETLCVC (external tunneling long-term central venous catheter)

group 2 - TILCVC (a totally implanted long-term central venous catheter)

X^2 (Pearson Chi-square test)

Patients with ETLCVC and TILCVC reacted the same during the insertion of the central venous catheter in terms of heart action, i.e. arrhythmia was registered in 1 patient from one and the other group (Table 4).

Table 4. Incidence of arrhythmia.

Arrhythmia	n	group 1 n (%)	group 2 n (%)
Yes	2	1 (1.67)	1 (1.67)
No	118	59 (98.33)	59 (98.33)

group 1 - ETLCVC (external tunneling long-term central venous catheter)

group 2 - TILCVC (a totally implanted long-term central venous catheter)

X^2 (Pearson Chi-square test)

Occurrence of pneumothorax was observed in 1 patient (1.67%) from the group with applied TILCVC.

No statistically significant difference was found in the frequency of pneumothorax between the groups with ETLCVC and TILCVC ($p=0.315$) (Table 5).

Table 5. *Incidence of pneumothorax.*

Pneumothorax	n	group 1 n (%)	group 2 n (%)	P - value
Yes	1	0	1 (1.67)	$X^2=1.0$
No	119	60 (100)	59 (98.33)	$p=0.315$

group 1 - ETLCVC (external tunneling long-term central venous catheter)
 group 2 - TILCVC (a totally implanted long-term central venous catheter)
 X^2 (Pearson Chi-square test)

Discussion

Long-term central venous catheters are commonly used for taking blood samples, intravenous hydration of the patient and for administering medications to patients with various pathologies. The first catheters were described by Broviac in 1973 and later by Hickman in 1979 (26,27). They were tunneled subcutaneously and also had subcutaneous cuff. The advantages of totally implanted long-term central venous catheters are that they do not require external dressings, allow for greater patient activity, and require monthly injections of heparin solution for their maintenance. Therefore, TILCVCs are associated with fewer infections and complications than external tunneling catheters (28). The overall complication rate associated with long-term central venous catheters is estimated to be 10 - 15% (29). In this paper, the focus is on early complications (pneumothorax, malposition of the catheter and arrhythmias) and their relationship with the type of catheter applied (30 - 32).

This study included 120 pediatric oncology patients aged 2-14 years, of which 90 patients had leukemia (75%), 22 patients had solid tumors (18.3%), and 8 patients had lymphoma (6.7%). Most of the patients were diagnosed with acute lymphoblastic leukemia (44%) and 22.5% with lymphoid leukemia. The patients were divided into two groups depending on which long-term central venous catheter was applied for the implementation of cytostatic therapy. Both groups were homogeneous in terms of gender and age. In both groups, the male gender dominated, in the first group 55%, and in the second group 58%. The average age in both groups was 6.1 ± 3.5 years.

The total rate of early complications in this study was 3.33%, that is, early complications were observed in 4 patients out of a total of 120. Pneumothorax was registered in only one patient from the group with TILCVC. In a study by Emine Ozyuvaci and his associates, a pneumothorax rate of up to 4% was cited and this reduction in incidence was the most likely due to the use of ultrasound (33). With the use of ultrasound, the rate of occurrence of pneumothorax is significantly reduced, as well as unsuccessful cannulation of v. jugularis interna and occurrence of hematomas. Malposition of the catheter was registered only in one patient and that in the group with TILCVC. Arrhythmia was registered in two patients, one in the ETLCVC group and

one in the TILCVC group. The frequency of all early complications did not differ significantly between the groups with ETLCVC and TILCVC ($p=0.315$).

Malposition and arrhythmias are related to the accuracy of catheter tip placement. Various techniques have been described in the literature to improve the accuracy of long-term central venous catheter positions, such as intravenous electrocardiography, depth calculation formulas or interventional guidance followed by postoperative chest radiography (34-36). In 2022, a study was published by Yuanzhen Chen and colleagues, where they used transesophageal echocardiography to accurately position the catheter tip in 297 pediatric patients. In their study, 58 cases of catheter tip malposition were recorded. However, transesophageal echocardiography is a tool that takes time to master, and it is difficult to differentiate the catheter tip from cardiac structures. A technique that would the most accurately determine the position of the tip of the catheter has not yet been found, i.e. the occurrence of malposition and occurrence of arrhythmias would be avoided.

Conclusion

Thanks to the long-lasting central venous catheters, reliable, safe and long-lasting venous access is possible for the implementation of invasive chemotherapy in pediatric oncology patients. The incidence of early complications in pediatric oncology patients is very low and does not depend on the type of long-term central venous catheter applied (ETLCVC and TILCVC).

References

1. World Health Organization. Cure All framework: WHO global initiative for childhood cancer: increasing access, advancing quality, saving lives. World Health Organization 2021. DOI: <https://apps.who.int/iris/handle/10665/347370>.
2. Kowalczyk JR, Samardakiwicz M, et al. European Survey on Standards of Care in pediatric oncology centers. *Eur. J. Cancer* 2016; 61:11-19.
3. Orgel E, Ji L, Pastor W. Infectious morbidity bu catheter type in neutropenic children with cancer. *Pediatr. Infect. Dis* 2014;33(3):263-266.
4. Santana FG, Moreira-Dias PL. Central Catheter of Peripheral Insertion in Pediatric Oncology: a Retrospective Study. *Revista Brasileira de Cancerologia* 2018;64(3):339-345.
5. Fadoo Z, Nisar MI, Iftikhar R, et al. Peripherally Inserted Central Venous Catheters in Pediatric Hematology/Oncology Patients in Tertiary Care Setting: A Developing Country Experience. *J. Pediatr. Hematol. Oncol.* 2015;37(7):421-423.
6. Anttilla VJ. Central venous catheter care for children with cancer should focus on early infections. *Acta Paediatrica* 2018;108(2):204-205.
7. Revel – Vilks S, Kenet G, et al. Risk factors for central venous catheter thrombotic complications in children and adolescents with cancer. *Cancer* 2010;116:197-205.
8. Petry J, Rocha KT, Madalosso AR, et al. Cateter venoso central de inserção periférica: limites e possibilidades. *Rev Eletr Enf.* 2012;14(4):937-943.
9. Di Santo MK, Takemoto D, Nascimento RG, et al. Cateteres venosos centrais de inserção periférica: alternativa ou primeira escolha em acesso vascular? *J. Vas.c Bras.* 2017;16(2): 104-112.

-
10. Crocoli A, Tornesello A, et al. Central venous access devices in pediatric malignancies: a position paper of Italian Association of Pediatric Hematology and Oncology. *J. Vasc. Access.* 2015; 16(2):130-136.
 11. Machat S, Eisenhuber E, Pfarl G, et al. Complications of central venous port systems: a pictorial review. *Insights into Imaging* 2019;10:86.
 12. Di Carlo I, Biffi R, Niederhuber JE. Totally implantable venous access devices: Management in mid- and long-term clinical setting. Springer-Verlag Italia 2012. DOI:<https://doi.org/10.1007/978-88-470-2373-4>.
 13. van den Bosch CH, Spijkerman J, et al. Central venous catheter-associated complications in pediatric patients diagnosed with Hodgkin lymphoma: implications for catheter choice. *Support Care Cancer* 2022;30(10): 8069-8079.
 14. Biagi E, Arrigo C, Dell'Orto MG, et al. Mechanical and infective central venous catheter-related complications: a prospective non-randomized study using Hickman and Groshong catheters in children with haematological malignancies. *Support Care Cancer* 1997;5: 228-233.
 15. Fratino G, Mazzola C, Buffa P, et al. Mechanical complications related to indwelling central venous catheter in pediatric hematology/oncology patients. *Pediatr. Hematol. Oncol.* 2001; 18: 317-324.
 16. Mermel LA, Farr BM, Sherertz RJ, et al. Guidelines for the management of intravascular catheter-related infections. *Clin. Infect. Dis.* 2001; 32: 1249-1272.
 17. Journeycake JM, Buchanan GR. Thrombotic complications of central venous catheters in children. *Curr. Opin. Hemato.* 2003; 10: 369-374.
 18. Giordano P, Saracco P, Grassi M, et al. Recommendations for the use of long-term central venous catheter (CVC) in children with hemato - oncological disorders: management of CVC-related occlusion and CVC-related thrombosis. On behalf of the coagulation defects working group and the supportive therapy working group of the Italian Association of Pediatric Hematology and Oncology (AIEOP). *Ann. Hematol.* 2015;94(11): 1765-1776.
 19. Ziegler MJ, Pellegrini DC, Safdar N. Attributable mortality of central line associated bloodstream infection: systematic review and meta-analysis. *Infection* 2015; 43: 29-36.
 20. Ullman AJ, Marsh N, Mihala G, et al. Complications of Central Venous Access Devices: A Systematic Review. *Pediatrics* 2015; 136(5): 1331-1344.
 21. Kusminsky RE. Complications of central venous catheterization. *J. Am. Coll. Surg.* 2007; 204(4): 681-696.
 22. Tsotsolis N, Tsirgogiann K. et al. Pneumothorax as a complication of central venous catheter insertion. *Ann. Transl. Med.* 2015;3(3): 40.
 23. Nazinitsky A, Covington M, Littmann L. Sinus arrest and asystole caused by a peripherally inserted central catheter. *Ann. Noninvasive Electrocardiol.* 2014; 19(4): 391-394.
 24. Mollee P, Jones M, et al. Catheter-associated bloodstream infection incidence and risk factors in adults with cancer: a prospective cohort study. *J. Hosp. Infect.* 2011; 78(1): 26-30.
 25. Raad I, Chaftari AM. Advances in prevention and management of central line-associated bloodstream infections in patients with cancer. *Clin. Infect. Dis.* 2014;59(5): 340-343.
 26. Broviac JW, Cole JJ, Scribner BH. Asilicone rubber atrial catheter for pro longed parenteral alimentation. *Surg Gynecol Obstet.* 1973;136:602-606.
 27. Hickman RO, Buckner CD, Clift RA, et al. A modified right atrial catheter for access to the venous system in marrow transplant recipients. *Surg Gynecol Obstet.* 1979;148:871-875.

28. Moureau N, Poole S, Murdock MA, Gray SM, Semba CP. Central venous catheters in home infusion care: outcomes analysis in 50,470 patients. *J Vasc Interv Radiol.* 2002;13:1009-1016.
29. Kock HJ, Pietsch M, Krause U, et al. Implantable Vascular access Systems: experience in 1500 patients with totally implanted central venous port systems. *World J Surg.* 1998;22:12-16.
30. Orzi LA, Meier RP, et al. Systematic review and metaanalysis of percutaneous subclavian vein puncture versus surgical venous cutdown for the insertion of a totally implantable venous access device. *Br. J. Surg.* 2014; 101(2): 8-16.
31. Di Carlo I, Pulvirenti E, et al. Increased use of percutaneous technique for totally implantable venous access devices. Is it real progress? A 27-year comprehensive review on early complications. *Ann. Surg. Oncol.* 2010; 17(6): 1649-1656.
32. Gibson F, Bodenham A. Mislplaced central venous catheters: Applied anatomy and practical management. *Br. J. Anaesth.* 2013;110(3): 333-346.
33. Ozyuvaci E, Kutlu F. Totally implantable venous access devices via subclavian vein: a retrospective study of 368 oncology patients. *Adv Ther.*2006;23:574-581.
34. Wang YC, Huang CH, Lin FS, et al. Intravenous electrocardiography helps in experienced operators to place totally implantable venous access devices more accurately. *J Surg Oncol.* 2012;105:848-851.
35. Cleff C, Boensch M, Eifinger F, et al. Correct positioning of central venous catheters in pediatrics: are current formular really useful? *Anesthesist.* 2018;67:519-524.
36. Chen Y, Xing D, Wu L, et al. Transesophageal echocardiography-guided implantation of totally implantible venous access devices via the internal jugular vein: retrospective analysis od 297 cases in pediatric patients. *World Journal of Surgical Oncology* 2022;20:272.

INDUCTION OF HYPOTHYROIDISM IN ALBINO WISTAR RATS - EXPERIMENTAL ANIMAL MODEL

Stojkovska N¹, Dimovska I², Ampova H³, Nikoloska V⁴, Jovanovski-Srceva M⁵, Stojanoski S⁶

¹ Ss Cyril and Methodius University in Skopje, Faculty of Medicine, Institute of Histology and Embryology

² Ss Cyril and Methodius University in Skopje, Faculty of Medicine, University clinic for gynecology and Obstetrics

³ Ss Cyril and Methodius University in Skopje, Faculty of Medicine, Institute for Medical and Experimental Biochemistry

⁴ Ss Cyril and Methodius University in Skopje, Faculty of Medicine, University clinic of Neurology

⁵ Ss Cyril and Methodius University in Skopje, Faculty of Medicine, University Clinic for Anesthesia and Reanimation

⁶ Ss Cyril and Methodius University in Skopje, Faculty of Medicine, Institute of Pathophysiology and Nuclear Medicine "Acad. Isak S. Tadzer"

ABSTRACT

Introduction: Altered thyroid function (hypothyroidism / hyperthyroidism) can be considered as a frequent and common medical issue. Due to metabolic changes, almost all systems and functional processes in the human body are. Experimental animal models of thyroid dysfunction are the key for further scientific investigations of the peripheral effects of thyroid hormones at cellular and sub cellular level.

Aim: To establish an experimental animal model of impaired function of the thyroid gland – hypothyroidism.

Materials and methods: 20 Wistar rats (10 males - 350 ± 40 gr and 10 females - 320 ± 40 gr), average age 7 months old, were analyzed in the period of 2 months (treated for 1 month with Propylthiouracil 1 mg/100g body mass in drinking water and 1 following month without treatment). The following basic parameters were determined for each subject (body mass index, temperature, thyroid status). The second group of 10 Wistar rats - (5 males and 5 females) did not receive Propylthiouracil and this was the control group used to obtain normal morphometric and biochemical parameters.

Results: Between the mean values of FT4 and FT3 at the beginning, at the intersection and at the end of the study, there were statistically significant differences with decreased levels at the cross section and no statistically significant difference between the beginning and the end of the examination in the group treated with Propylthiouracil. No statistically significant differences were detected in the control group.

Conclusion: Experimental animal model of impaired function of the thyroid gland – hypothyroidism in Wistar rats was successfully established.

Key words: experimental animal model, hypothyroidism, wistar rats.

Introduction

Thyroid hormones regulate the processes of oxidative, energetic and basal metabolism, thus they have impact on the growth, differentiation and function of the cells and tissues (1). The regulation of the thyroid hormones secretion takes place at two levels - the pituitary gland and the hypothalamus, and it works on the principle of negative feedback loop.

Hypothyroidism, which is characterized with a thyroid hormone deficiency usually considers underactive thyroid gland. When the production of thyroid hormones is insufficient, by the mechanism of negative feedback loop, thyrotropes of the adenohypophysis are activated and induced to produce increased levels of thyroid-stimulating hormone (TSH). Considering the pathogenesis context, hypothyroidism can be divided into: primary hypothyroidism (where the thyroid gland is damaged), secondary (where damaged pituitary gland leads to decreased TSH formation and thus results in insufficient stimulation of thyroid follicular cells for T3 and T4 production) or tertiary. Tertiary hypothyroidism is also known as central hypothyroidism. Depending on the time of occurrence, hypothyroidism is divided into congenital and acquired (2).

The clinical manifestations of hypothyroidism are very diverse, which is explained by the fact that the targets of thyroid hormones are virtually all organs and tissues of the body. The manifestation rate and morphological disorders arising in the structure of organs and tissues is determined by the degree of thyroid hormone deficiency (3).

The aim of our study was to establish an experimental animal model of thyroid dysfunction - hypothyroidism. The amount of published scientific data regarding experimental animal models in the field of thyroid impaired function is an obstacle for sufficient experimental data on peripheral effects on organs, tissues and at cellular level in the state of thyroid hormones deficit. Establishing such experimental models could enable further medical investigations and understanding of the effects of thyroid hormone disturbances.

Materials and methods

We analyzed 30 Wistar rats with an average age of 7 months during the period of 2 months, 50% (10) female (320 ± 40 gr) and 50% (10) male (350 ± 40 gr).

Group 1 – Hypothyroid group: 20 Wistar rats (10 males and 10 females), which were treated for 1 month with pharmacological doses of pure substance Propylthiouracil 1 mg / 100g BM in the drinking water and 1 following month without treatment (follow up). Before the initiation of the administration of Propylthiouracil, the following basic parameters were determined for each rat (under conditions of previous good hydration and nutrition): body mass index (BMI), thyroid status (FT4, FT3), body temperature (°C). The experiment inclusion criteria were: euthyroid condition for each subject. Once a week and at the end of the experiment, the body mass (BMI) of the animal was determined. The next day after the last administration of Propylthiouracil, the thyroid status was determined for the verification of the achieved overt hypothyroidism.

Group 2 - Control group: 10 Wistar rats (5 males and 5 females) did not receive Propylthiouracil and this group was used to obtain normal morphometric and biochemical parameters.

All procedures were in accordance with accepted European and World regulations for working with experimental animals. The individuals were acclimatized at room temperature (18-22 °C). The light regime was a 12/12 hour day/night cycle (6am to 6pm). Access to water was ad libitum, and at the same time the feed was balanced with a complete pelleted feed mixture of the KKS 0 type in composition according to the specification of the Schaumann manufacturer.

The determination of the thyroid status of the experimental animals through the level of FT4 and FT3 in the serum was carried out by DELFIA immunometric methods on the device 1234 DELFIA®Fluorometer, using commercial kits from the manufacturer (PerkinElmer and Analytical Sciences, Wallac Oy, Finland).

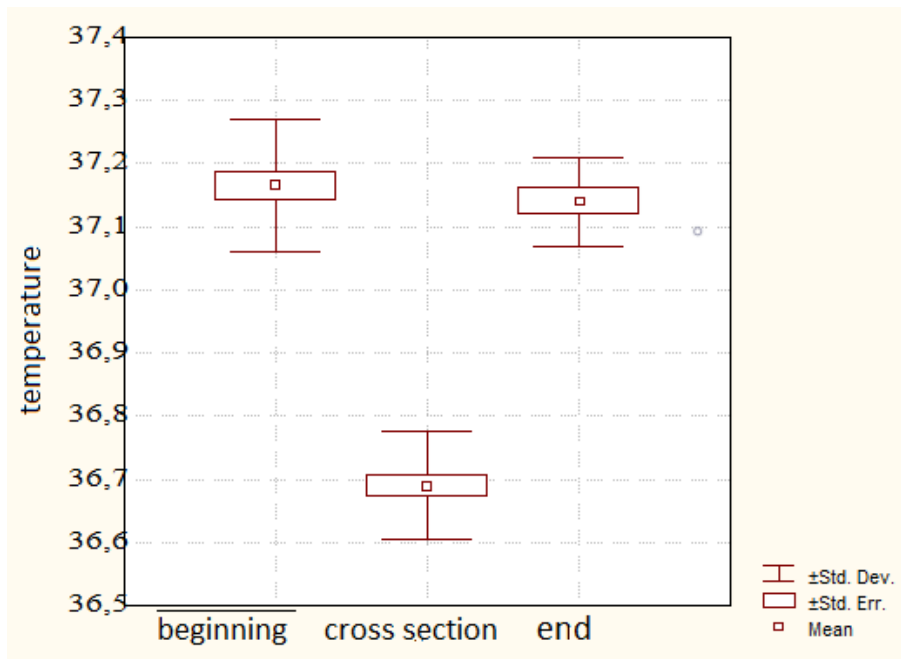
Statistical analysis and presentation of the results

From the descriptive statistics, the measures of central tendency and variability (mean value, standard deviation) were used. Differences between certain time points, as well as differences between groups, were analyzed with the Student's "t" test for dependent and independent samples and the one-factor and multi-factor analysis of variance ANOVA and MANOVA. The correlations between the values of the individual parameters of the test were expressed by the Person correlation coefficient (r). How statistically significant were the differences for $p < 0.05$. Statistical series (all defined variables) were shown tabularly and graphically. The testing of the significance of the differences between two arithmetic means and the dependent samples (in the examined groups) was done with the Student's t - test for dependent samples, and if there was a question of irregular distribution with the non-parametric Wilcoxon - test of equivalent pairs. The testing of the significance of the differences between two arithmetic means and the independent samples between the test groups was done with the Student's t-test for independent samples and if there was a question of irregular distribution with the non-parametric Mann-Whitney U-test. The data were processed with statistical program SPSS 23.0.

Results

Table 1. Mean values of temperature (°C) at the beginning, at the cut point and at the end (hypothyroid) - treated with PTU

Temperature	average	SD	min.	Max.	N
Beginning	37.2	0.10	37.0	37.3	20
Cross section	36.7	0.08	36.5	36.8	20
End	37.1	0.07	37.0	37.2	10

Graphic 1. Mean values of temperature (°C) at the beginning, at the cut point and at the end

There are statistically significant differences between the mean values of the temperatures at the beginning, at the intersection and at the end of the study (Friedman ANOVA Chi Sqr. = 15.79; $p = 0.00037$). Individual differences were tested using Student's t test for dependent samples. The differences in relation to the body temperature are not statistically significant between the beginning and the end of the examination (euthyroidism).

Table 1A. The significance of the differences in the mean values of the temperatures at the beginning, at the cut point and at the end

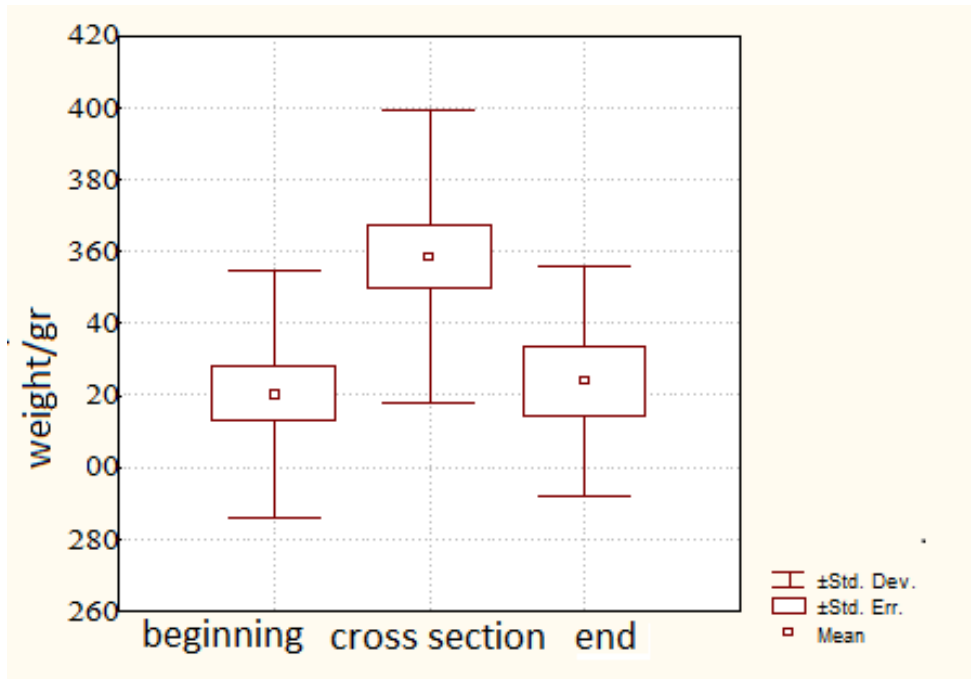
Compared values	Students t test (p)
at the beginning - at cross section	$t = 29.65$ $p = 0.000001^*$
at the beginning - at the end	$t = 0.28$ $p = 0.7794$
at cross section - at the end	$t = 16.51$ $p = 0.00001^*$

* statistically significant difference

Table 2. Mean values of body weight (gr) at the beginning, at the cut and at the end

Weight / gr	average	SD	min.	max.	N
Beginning	320.5	34.3	270.0	370.0	20
Cross section	358.5	40.8	300.0	420.0	20
End	324.0	31.7	280.0	360.0	10

Graphic 2. Mean values of body weight (gr) at the beginning, at the cut and at the end



There are statistically significant differences between the mean values of the body weight at the beginning, at the intersection and at the end (Friedman ANOVA Chi Sqr. = 17.89; $p = 0.00013$). The individual differences were tested using Student's t test for dependent samples and all are statistically significant.

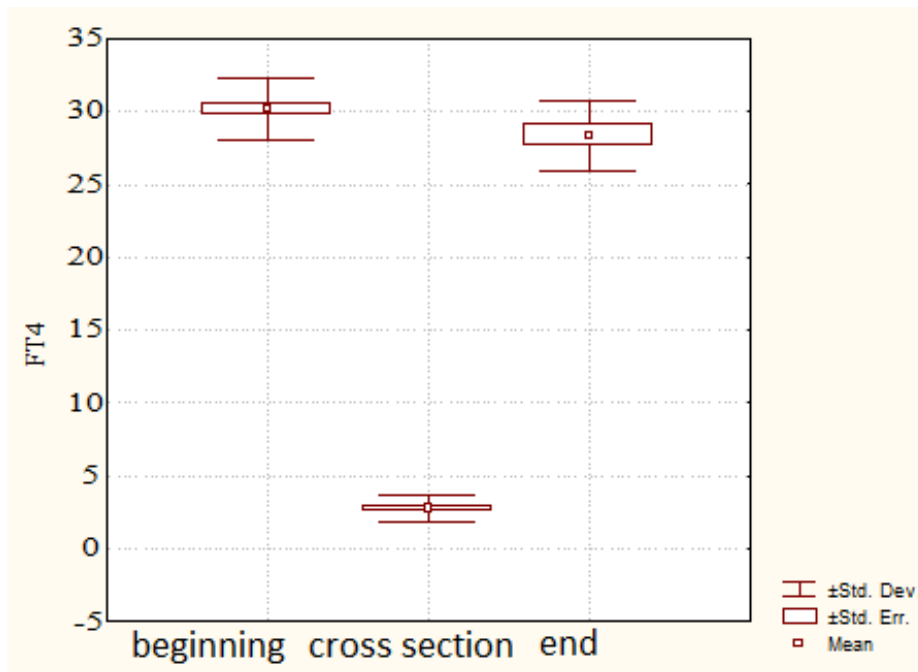
Table 2A. The significance of the differences in the mean values of the body weight at the beginning, at the intersection and at the end

Compared values	Students t test (p)
at the beginning - at cross section	$t = 14.75$ $p = 0.00001^*$
at the beginning - at the end	$t = 3.49$ $p = 0.0067^*$
at cross section - at the end	$t = 6.27$ $p = 0.00014^*$

* statistically significant difference

Table 3. Average values of FT4 at the beginning, at the cut point and at the end

FT4	average	SD	min.	max.	N
Beginning	30.15	2.11	26.80	34.60	20
Cross section	2.80	0.92	1.50	4.48	20
End	28.36	2.41	24.40	32.50	10

Graphic 3. Mean values of FT4 at the beginning, at the cut and at the end

Between the mean values of FT4 at the beginning, at the intersection and at the end of the study, there are statistically significant differences (Friedman ANOVA Chi Sqr. = 15.29; $p = 0.00053$). Individual differences were tested using the Student's t test for dependent samples. The differences in relation to FT4 are not significant between the beginning and the end of the examination.

Table 3A. The significance of the differences in the mean values of FT4 at the beginning, at the intersection and at the end

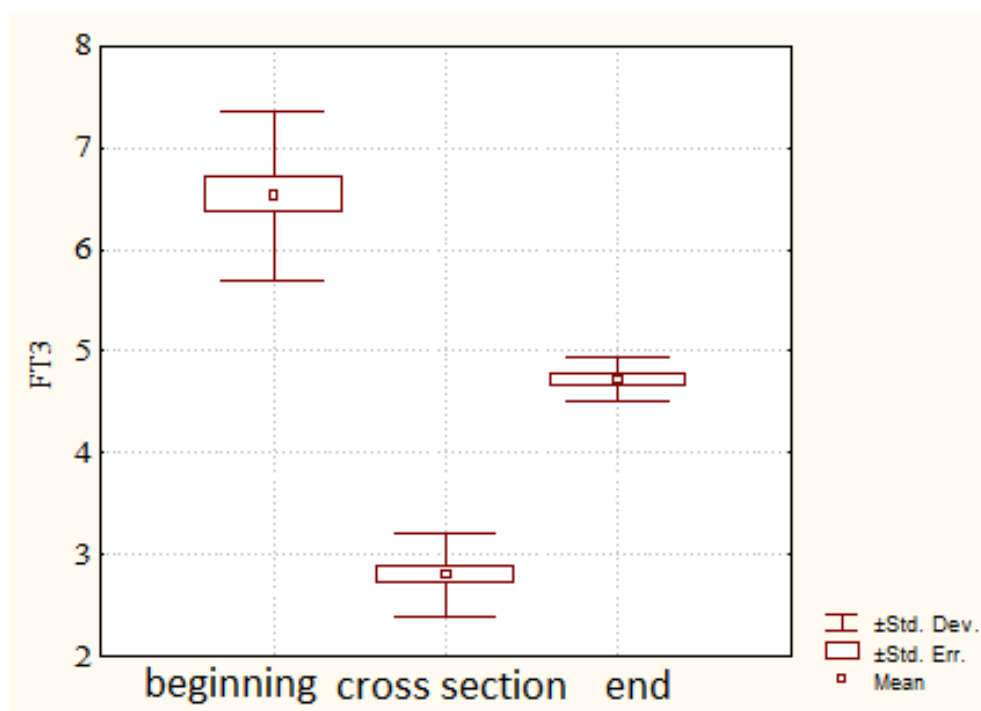
Compared values	Students t test (p)
at the beginning - at cross section	$t = 46.78$ $p = 0.000001^*$
at the beginning - at the end	$t = 1.97$ $p = 0.0798$
at cross section - at the end	$t = 16.51$ $p = 0.00001^*$

* statistically significant difference

Table 4. Mean values of FT3 at the beginning, at the intersection and at the end

FT3	average	SD	min.	max.	N
Beginning	6.53	0.83	5.04	7.81	20
Cross section	2.80	0.40	2.14	3.84	20
End	4.73	0.21	4.41	4.95	10

Graphic 4. Mean values of FT3 at the beginning, at the cut and at the end



Between the mean values of FT3 at the beginning, at the intersection and at the end of the study, there are statistically significant differences (Friedman ANOVA Chi Sqr. = 20.00; $p = 0.00005$). The individual differences were tested using Student's t test for dependent samples and are statistically significant.

Table 4A. The significance of the differences in the mean values of FT3 at the beginning, at the intersection and at the end (hypothyroid)

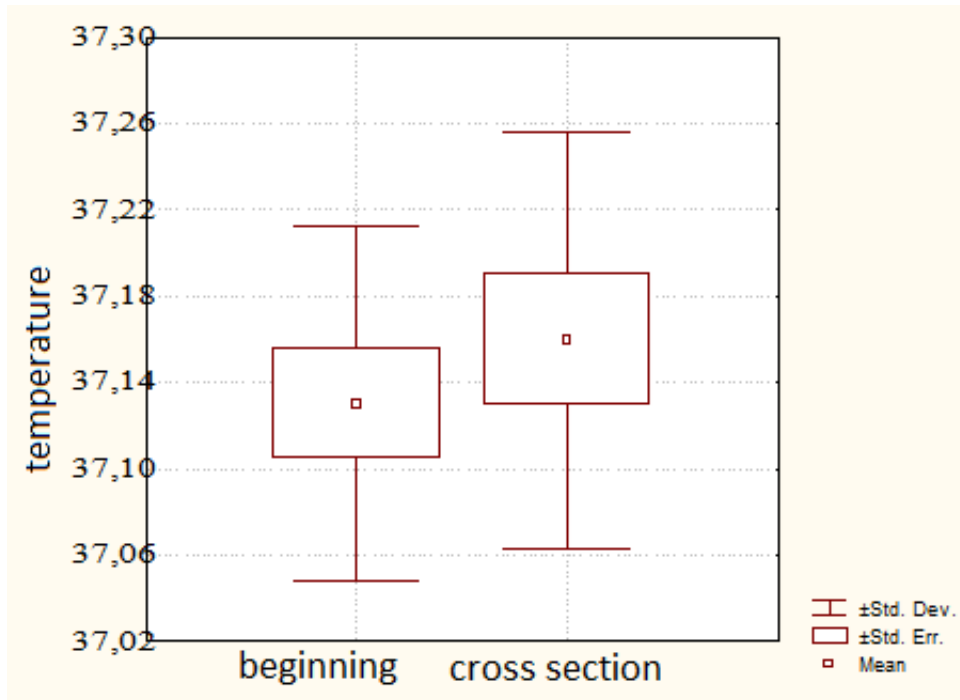
Compared values	Students t test (p)
at the beginning - at cross section	$t = 15.66$ $p = 0.00001^*$
at the beginning - at the end	$t = 7.59$ $p = 0.00003^*$
at cross section - at the end	$t = 11.53$ $p = 0.00001^*$

* statistically significant difference

Table 5. Mean values of temperature ($^{\circ}\text{C}$) at the beginning and at cross section

(control group)

Temperature	average	SD	min.	max.	N
At the beginning	37.1	0.08	37.0	37.2	10
At cross section	37.1	0.09	37.0	37.3	10

Graphic 5. Mean values of temperature ($^{\circ}$ C) at the beginning and at cross section

There are no statistically significant differences (Student's t test for dependent samples) between the mean values of the temperatures at the beginning and at cross section of the research in the control group.

Table 5A. The significance of the differences in the mean values of the temperatures at the beginning and at cross section (control group):

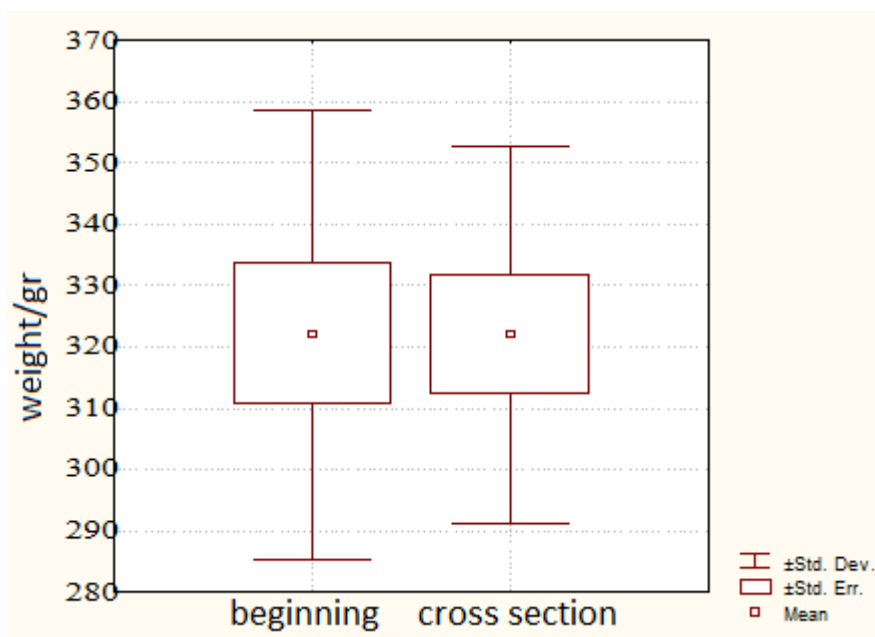
Compared values	Students t test (p)
at the beginning - at cross section	t = 0.63 p = 0.5413

* - statistically significant difference

Table 6. Mean values of body weight (gr) at the beginning and at cross section (control group without drugs);

Body weight	average	SD	min.	max.	N
at the beginning	322.0	36.76	280.0	360.0	10
at cross section	322.0	30.84	290.0	360.0	10

Graphic 6. Mean values of body weight (gr) at the beginning and at cross section (control group without drugs);



There are no statistically significant differences between the mean values of the body weight at the beginning and at cross section of the study (control group without drugs) (Student's t test for dependent samples).

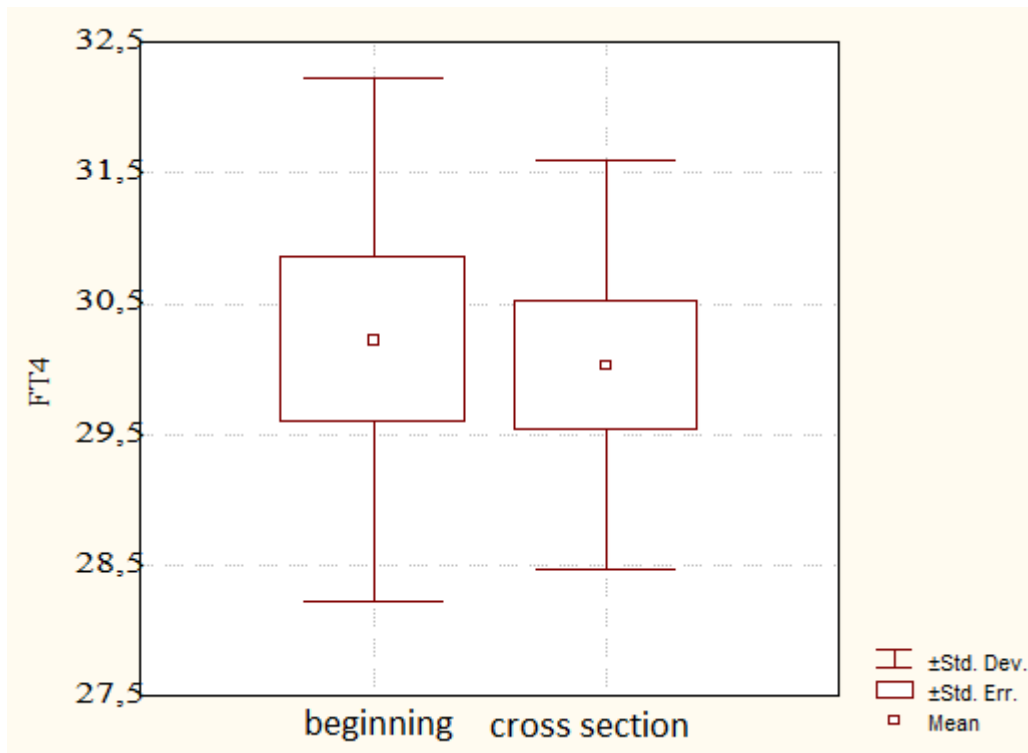
Table 6A. The significance of the differences in the mean values of the body weight at the beginning and at cross section

Compared values	Students t test (p)
at the beginning - at cross section	t = 0.00 p = 1.0

*- statistically significant difference

Table 7. Mean values of FT4 at the beginning and at the cross section

FT4	average	SD	min.	max.	N
beginning	30.22	1.99	27.60	33.70	10
at cross section	30.03	1.56	27.80	32.70	10

Graphic 7. Mean values of FT4 at the beginning and at the intersection

There are no statistically significant differences between the mean values of FT4 at the beginning and at the intersection of the study (control group without drugs) (Student's t test for dependent samples).

Table 7A. The significance of the differences in the mean values of FT4 at the beginning and at the cut-off point (control group without drugs);

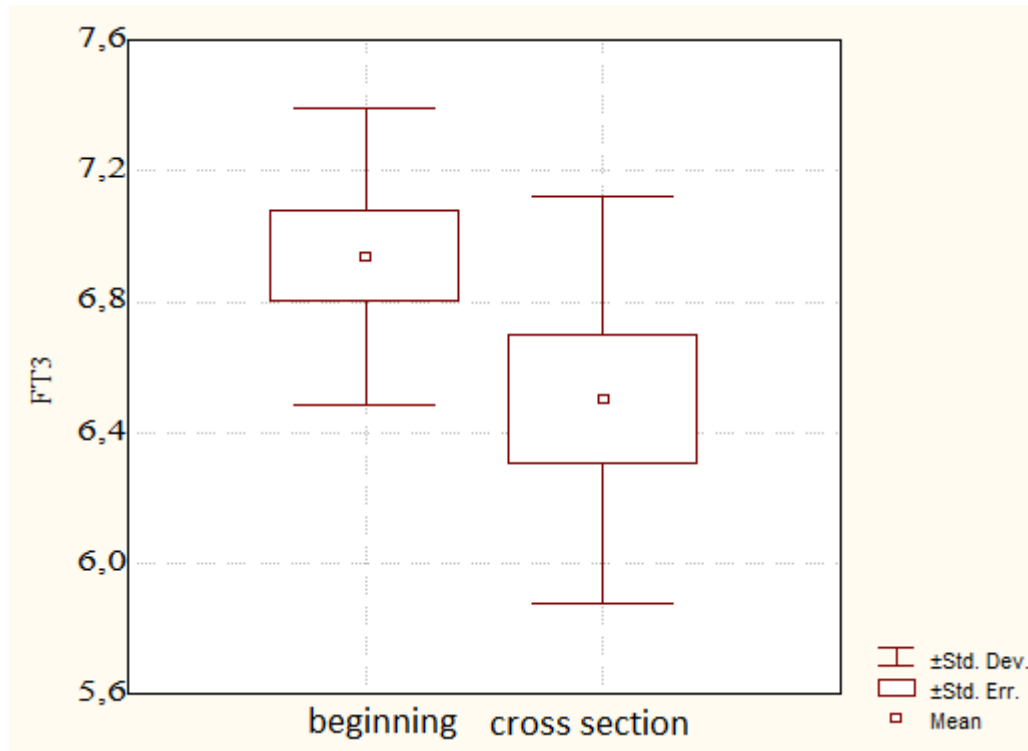
Compared values	Students t test (p)
at the beginning - at cross section	t = 0.36 p = 0.7233

*- statistically significant difference

Table 8. Mean values of FT3 at the beginning and at the intersection (control group)

FT3	average	SD	min.	max.	N
beginning	6.94	0.45	6.38	7.63	10
at cross section	6.50	0.62	5.04	7.21	10

Graphic 8. Mean values of FT3 at the beginning and at the intersection (control group)



There are statistically significant differences (Student’s t test for dependent samples) between the mean values of FT3 at the beginning and at the end of the study (control group without drugs).

Table 8A. The significance of the differences in the mean values of FT3 at the beginning and at the cut-off (control group without drugs)

Compared values	Students t test (p)
at the beginning - at cross section	t = 2.53 p = 0.0321*

*- statistically significant difference

Discussion

Altered thyroid function (hypothyroidism/hyperthyroidism) can be considered as a frequent and common medical issue. However, due to metabolic changes, almost all systems and functional processes in the human body are affected in cases of impaired function of the thyroid gland. In the literature there is a limited amount of scientific data about established experimental animal models of thyroid dysfunction. Establishing such experimental models could enable further medical investigations and understanding of the effects of thyroid hormone disturbances at cellular and sub cellular level.

The experimental animal model that we decided to establish included Wistar rats which were treated for 1 month with pharmacological doses of pure substance Propylthiouracil 1 mg / 100g

BM in drinking water. Before the start of the administration of Propylthiouracil each rat was under condition of good hydration and nutrition. In the literature, similar models have been established, like the model of Ferreira et al. which was performed in mice (4). We decided to use the administration of Propylthiouracil in drinking water ad libitum in order to have as little animal disturbance and handling as possible compared to the models of intra peritoneal drug administration (5-7). Hegazy A et al. used a similar experimental model of induced hypothyroidism in adult albino rats but they obtained the blood samples from the retro-orbital venous plexuses while we used the tail veins (8). [JF Silva](#) et al used the dosage of 1mg/ml Propylthiouracil in drinking water, while we obtained overt hypothyroid state in our subjects with the dosage of 1 mg/100g BM (9). Several authors obtained positive result of hypothyroid induction in rats after administering Propylthiouracil and confirmed that its action is dose-dependent (10-12). Thyroid hormones (TH) are of central importance for thermogenesis, energy homeostasis and metabolism. It is widely accepted that THs modulate thermogenesis and body mass directly by changing the functionality and transcription rate of UCP1 (Uncoupling Protein 1) and obligatory thermogenesis by increasing metabolic cycling, oxidative phosphorylation at mitochondria level or by direct actions on the sodium/potassium and the calcium pump in skeletal muscle. In the thyroid hypofunctional state, an increase of protein catabolism occurs with a consecutive reduction of muscle mass, but at the same time, almost all metabolic pathways are with decreased intensity.

Hormones of the thyroid gland increase the metabolic activity in all tissues and organs except the brain, retina, spleen, testicles and intestines. Basal metabolism can decrease by 60 - 100% below normal values if the values of thyroid hormones are overtly reduced. In our study the decreased internal temperature and changes in the body mass of the rats in the group with induced hypothyroid state was seen during the cross section analyzes where the levels of thyroid hormones were overtly decreased. There were statistically significant differences between the body temperature and body mass at the beginning, cross section and the end of the study. In the periphery, thyroxine is almost completely deiodinated into triiodothyronine and therefore it is considered that triiodothyronine is the true intracellular hormone. Our results presented the levels of thyroid hormones (free triiodothyronine, free thyroxine) being with statistically significant differences between the beginning, cross section and the end of the study, which was in favor of successfully experimentally induced hypothyroid state. The levels of FT4 were significantly decreased in rats given Propylthiouracil in the cross section compared to the euthyroid rats in the beginning or the end of the study and the control group. FT3 levels were also statistically significantly decreased in hypothyroid rats compared to euthyroid rats in the beginning and in the end of the study and the control group. Hypothyroidism has traditionally been associated with weight gain and overweight state. Subjects with hypothyroidism have an adrenergic hypostimulation with decreased basal metabolism and thermogenesis, and a reduced overall energy expenditure resulting in a tendency toward weight gain (13,14). Hypothyroidism can also induce an decreased gastrointestinal transit and occasionally anorexia. All these factors may have lead to the belief of a direct association of hypothyroid states with decreasing of body weight. According to the previous knowledge of the effects of hypothyroidism on the body mass index, body temperature and the levels of thyroid hormones, in our results the increasing of body weight, decrease of body temperature and lower values of thyroid hormones, since the rats are in hypothyroid condition was already expected and in favor of successfully established experimental animal model of thyroid dysfunction - hypothyroidism. Our results show significantly increased body weight in the hypothyroid rats expressed in grams at the cross section point of the study compared to euthyroid rats of the beginning and the end of the study and in the control group. The control group of ten rats which were not treated with any medication, as seen in the tables and graphics in the results section, did not show any statistically significant differences according to the internal body temperature, body mass index or the levels of thyroid hormones.

Conclusion

Our study confirms that we have successfully established an experimental animal model of impaired function of the thyroid gland – hypothyroidism. Experimental animal models of thyroid dysfunction are the possible key for further scientific investigations of the peripheral effects of thyroid hormones at cellular and sub cellular level.

References

1. Walczak K, Sieminska L. Obesity and Thyroid Axis. *Int J Environ Res Public Health*. 2021;18 (18). <https://doi.org/10.3390/ijerph18189434>
2. Chaker L, Razvi S, Bensenor IM, et al. Hypothyroidism. *Nat Rev Dis Primers*. 2022; 19: 8(1): 30. <https://doi.org/10.1038/s41572-022-00357-7>
3. Paschou SA, Bletsas E, Stampouloglou PK, et al. Thyroid disorders and cardiovascular manifestations: an update. *Endocrine*. 2022; 75(3): 672-683. <https://doi.org/10.1007/s12020-022-02982-4>
4. Ferriera E, Silva AE, Serakides R, et al. Model of induction of thyroid dysfunctions in adult female mice. *Arq. Bras. Med. Vet.* 2007; 59: 1245–1249. <http://dx.doi.org/10.1590/S0102-09352007000500022>
5. Sener G, Kabasakal L, Atasoy BM, et al.. Propylthiouracil-induced hypothyroidism protects ionizing radiation - induced multiple organ damage in rats. *Journal of endocrinology*. 2006; 189: 257–269. <https://doi.org/10.1677/joe.1.06574>
6. Serakides R, Nunes V.A, Silva C.M. et al. Influência do hipogonadismo na histomorfometria e função tireoidiana de ratas hipotireóideas. *Arq. Bras. Med. Vet. Zootec*. 2002; 54: 473-477. <https://doi.org/10.1590/S0102-09352002000500004>
7. Silva CM, Serakides R, Oliveira TS et al. Histomorfometria e histoquímica dos ovários, tubas e útero de ratas hipotireóideas em metaestro-diestro. *Arq. Bras. Med. Vet. Zootec*. 2004; 56: 628-639. <https://doi.org/10.1590/S0102-09352004000500010>
8. Hegazy AA, Morsy MM, Moawad RS et al. Effect of Experimentally Induced Hypothyroidism on Structure of Adult Albino Rats' Testes and Possible Protective Role of L-carnitine. *Zagazig University Medical Journals* 2018; vol. 24(8): 41-55. <https://doi.org/10.21608/zumj.2018.192417>
9. Silva JF, Ocarino NM, Serakides R. Placental angiogenic and hormonal factors are affected by thyroid hormones in rats. 2015; vol. 211(3): 226-234. <https://doi.org/10.1016/j.prp.2014.11.003>
10. Silva JF, Ocarino NM, Vieira ALS, et al. Effects of Hypo- and Hyperthyroidism on Proliferation, Angiogenesis, Apoptosis and Expression of COX-2 in the Corpus Luteum of Female Rats Reproduction in domestic animals 2013; 48 (4): 691-698. <https://doi.org/10.1111/rda.12149>
11. Hapon MB, Simoncini M, Via G, et al. Effect of hypothyroidism on hormone profiles in virgin, pregnant and lactating rats, and on lactation. *Reproduction*. 2003; 126: 371–382. <https://doi.org/10.1530/rep.0.1260371>
12. Hapon MB, Motta AB, Ezquer M, et al. Hypothyroidism prolongs corpus luteum function in the pregnant rat. *Reproduction*. 2007; 133: 197–205. <https://doi.org/10.1530/rep-06-0035>
13. Silva JF, Ocarino NM, Serakides R et al. Fetal growth restriction in hypothyroidism is associated with changes in proliferative activity, apoptosis and vascularisation of the placen-

- ta. *Reproduction Fertility and Development*. 2012; 24(7): 923-931. <https://doi.org/10.1071/rd11219>
14. Venediktova N, Solomadin I, Nikiforova A, et al. Functional State of Rat Heart Mitochondria in Experimental Hyperthyroidism. *Int. J. Mol. Sci.* 2021; 22. <https://doi.org/10.3390/ijms222111744>

BREAST CANCER TUMOR CHARACTERISTICS AND METASTATIC BONE SCINTIGRAPHY FINDINGS

Jankulovska A¹, Manevska N¹, Lazareva E², Iljovska M², Jovanovski-Srceva M³, Stojanoski S¹

¹ Institute of Pathophysiology and Nuclear Medicine "Acad Isac S. Tadzer", Faculty of Medicine, University of "Ss. Cyril and Methodius", Skopje

² University Clinic of Radiotherapy and Oncology

³ University Clinic for Anesthesia, Reanimation and Intensive Care, University of "Ss. Cyril and Methodius", Skopje

ABSTRACT

Objectives: Bone scintigraphy (BS) is the gold standard for screening and initial diagnosis of bone metastases (BMs) in breast cancer (BC). The aim of this study was to analyze the correlation between multiple BMs diagnosed on BS with the tumor characteristics and molecular subtypes of the tumor in BC patients.

Materials and Methods: We performed a retrospective, observational study of 66 BC patients (mean age 52.52±10.64 years) with multiple BMs confirmed on the first diagnostic BS, in the period 2013-2018. Data regarding the initial disease stage, tumor histological type, grade and molecular subtype were evaluated for correlation with BMs.

Results: Sixteen patients (24%) presented with BMs at the time of BC. The metastasis-free period in the restaging group was 7.38±4.01 years and the same was significantly associated with the disease TNM stage ($r_s = -0.385$; $P=0.011$). Ductal BC was more frequently associated with BMs than the lobular type (65% vs. 14%, respectively). ER+ were 86% of the cases, followed by PgR+ (74%) and HER2+ (35%) of the cases. A significant correlation was found between the HR+ status of BC patients and the presence of multiple BMs ($P=0.021$). BMs were mainly detected in the spine (predominantly the thoracic segment), the ribs and the pelvis ($P= 0.013$).

Conclusion: Higher initial TNM stage reduces BMs free interval. HR positive status seems to be a significant predictor of BMs in BC.

Key Words: bone metastases, bone scintigraphy, breast cancer, molecular subtype, TNM stage.

Introduction

Breast cancer (BC), the most commonly diagnosed cancer, with approximately 2,261,419 new cases (11.7% of all cancer cases) in 2020, and it is the leading cause of cancer mortality in women worldwide (1). Early diagnosis of the advanced stage is very important, as timely application of appropriate treatment may improve patient's survival (2). Currently, bone status evaluation is not required in all BC patients. According to the European Society for Medical Oncology (ESMO) Guidelines, clinical recommendations for bone status evaluation include primary tumors >5cm (T3 and T4), tumors with aggressive biology and/ or clinical signs, symptoms or laboratory values suggesting the presence of bone metastasis (BMs) (3). It is estimated that 12% of the patients with stage I-III, during disease progression will develop distant spread to bones, while 58% of the patients diagnosed with stage IV are already present with BMs (4). Proper management of BMs is required for the reduction of skeletal-related events (SLEs) such as pathological fractures or spinal cord compression, leading to a better quality of life (5). Conventional bone scintigraphy (BS) is the first method of choice for clinical screening and initial diagnosis of metastatic bone disease. It is also used for restaging the patients with the assumption to have osseous disease progression, for change in the treatment plan, as well as for monitoring bone-targeting treatment response (6). The advantages of the method are cost-effectiveness, imaging of the whole skeleton, and its high sensitivity for detection of osteoblastic activity, despite the low specificity (7). Single photon emission computed tomography with computed tomography (SPECT/CT), as hybrid technology through three-dimensional functional and morphological assessment of the lesions, improves sensitivity and specificity and decreases the percentage of suspicion for BMs on the planar whole-body scan (WBS) (8, 9).

Several factors have been investigated for association with BMs occurrence, like tumor histology and molecular subtypes based on hormonal receptors (HR) (including estrogen receptor (ER) and progesterone receptor (PgR)), human epidermal growth factor type 2 (HER 2) expression status and Ki 67 proliferative index (10-12). To date, this data is still not confirmed for clinical use.

Therefore, in the present retrospective study, we aimed to analyze the correlation between multiple BMs diagnosed on BS with the tumor characteristics and molecular subtypes of the tumor in patients with BC.

Materials and Methods

A retrospective, observational cross-sectional study was performed at the Institute of Pathophysiology and Nuclear Medicine in collaboration with the University Clinic of Radiotherapy and Oncology. We evaluated 66 BC female patients, mean age 52.52 ± 10.64 years, that were interpreted as having multiple BMs on the first diagnostic BS, in the period 2013-2018. The study was approved by the Ethics Committee of the Medical Faculty in Skopje (number: 03-2140/3). All patients were over 18 years of age and had signed informed consent. -

The inclusion criteria were:

- patients with primary BC confirmed by biopsy or histopathology,
- the first diagnostic BS that showed multiple bone lesions, interpreted as BMs that were further confirmed by other diagnostic modalities,
- signed informed consent.

The exclusion criteria were:

- patients who had other malignant diseases besides BC,
- BS excluded due to other bone pathology (infection, trauma, benign osseous lesions, metabolic bone disease or arthropathy),
- controlled BS or BS where none or only one BM was detected,
- patients younger than 18 years old.

Bone scintigraphy method

WBS was obtained three hours after iv injection of 99m Technetium - methylene diphosphonate (99mTc-MDP) in anterior (AP) and posterior (PA) projections.

BS was performed with OPTIMA NM / CT 640 GE Healthcare dual detector/ 4 slice CT and Mediso DHV Nucline Spirit dual-head gamma cameras. Additional SPECT/ CT (OPTIMA NM/ CT 640 GE Healthcare dual detector/ 4 slice CT) was done, in the region of interest, where a suspicion of BM existed.

WBS and SPECT/ CT findings were analyzed by two nuclear medicine physicians for the presence and number of BMs and their exact localization at the axial/ appendicular skeleton. WBS along with SPECT/ CT were interpreted as positive for multiple BMs if they showed more than one bone lesion, consistent for BMs.

Data Collection

We've collected data for the initial disease stage at the time of BC diagnosis, tumor histological type and grade, molecular subtype and Ki-67 expression.

Tumor histological types were divided into three categories – ductal type, lobular type, and other types, with three degrees of differentiation - grade I, grade II and grade III.

Molecular subtypes were classified into four categories: HR+/HER 2-, HR+/HER 2+, HR-/HER 2+, and triple-negative (HR-/HER 2-). All characteristics were compared and correlated with BM status. Immunohistochemical detection of HER 2, HR and Ki 67 was performed with:

- HER 2 protein expression (Ventana anti-HER 2/ neu rabbit monoclonal antibody, clone 4B5 - Ventana BenchMark ULTRA automated stainer (Ventana Medical Systems));
- ER expression (Ventana anti-ER Rabbit Monoclonal Primary Antibody, clone SP1),
- PgR expression (Ventana anti-PgR Rabbit Monoclonal Primary Antibody, clone 1E2),
- Ki-67 expression (Ventana anti-Ki67, Primary Mon67 Antibody, clone 30-9).

We analyzed the site of BM appearance, as well as calculated the BMs-free interval as the time interval (years) between the first diagnosis of BC and the time of first BMs presentation on BS.

Statistical Analysis

Statistical analysis was performed by using SPSS 23.0. For data analysis descriptive statistics, Spearman rank R coefficient, Student t-test and analysis of variance ANOVA and MANOVA were used. Category variables are presented by absolute numbers and percentages, quantitative variables are presented by descriptive parameters (mean, SD). For the level of significance, the value of $P < 0.05$ is taken.

Results

Tumor type, grade, molecular subtype, KI-67-expression, and TNM

Regarding the histological type of the tumor, we found that invasive ductal BC was more frequently associated with BMs than the lobular type (65% vs. 14%, respectively). The most frequent was tumor grade II (44%), while grade III and grade I were present in 39% and 3% of the patients, respectively.

Table 1. Tumor characteristics regarding TNM stage and histology.

Tumor characteristics					
TNM stage		Histology		Tumor grade	
I	4 (6%)	IDC	43 (65%)	I	2 (3%)
II	23 (35%)	ILC	9 (14%)	II	29 (44%)
III	13 (20%)	Other	5 (7%)	III	26 (39%)
IV	17 (26%)	Unknown	9 (14%)	Unknown	9 (14%)
Unknown	8 (12%)				

Abbreviations: TNM, Tumor, Node, Metastasis; IDC, Invasive ductal carcinoma; ILC, Invasive lobular carcinoma.

Tumor characteristics regarding molecular subtypes are shown in Table 2. ER+ were 86% of the cases, followed by PgR+ (74%) and HER2+ (35%) of the cases. The dominant molecular subtype was HR+/HER 2- diagnosed in 43 patients (65%), while HR+/HER 2+ was found in 19 patients (29%) and only 4 patients (6%) had HR-/HER 2+. No patient had triple negative BC (TNBC). We found a significant correlation between the HR+ status of BC patients and the presence of multiple BMs ($P=0.021$). Ki-67 expression was noted in 25 patients. All of them had Ki-67 expression above 15% (mean expression $32.08 \pm 16.62\%$), only in two patients the expression was over 70%.

Table 2. Tumor characteristics regarding molecular subtype.

Tumor characteristics					
Hormone receptor		HER 2		Molecular subtype	
ER+	57 (86%)	HER 2 +	23 (35%)	HR+/HER2-	43 (65%)
ER-	9 (14%)	HER 2 -	43 (65%)	HR+/HER2+	19 (29%)
PgR+	49 (74%)			HR-/HER2+	4 (6%)
PgR-	17 (26%)			TNBC	/

Abbreviations: ER, Estrogen receptor; PgR, Progesterone receptor; HER 2, Human epidermal growth factor type 2; TNBC, Triple negative breast cancer.

Tumor characteristics regarding Tumor, Node, Metastasis (TNM) classification and tumor histology are presented in Table 1. The majority of patients had T2 (52%), N0 (27%), and M0 (62%) at presentation and were diagnosed with TNM stage 2 (35%).

Bone metastasis and metastasis – free interval

Both axial and appendicular skeletons were affected in 71% of the patients, while in the remaining 29%, only the axial skeleton was affected. BMs were mainly detected in the spine (predominantly the thoracic segment), the ribs, and the pelvis ($P = 0.013$). BMs were noted at least in the scapula, humerus, and clavicle (Table 3).

Table 3. Sites of multiple skeletal metastases in patients with breast cancer.

Skull
Spine
Cervical
Thoracic
Lumbar
Sacral
Sternum
Rib
Clavicle
Scapula
Humerus
Pelvis
Femur
Total no. of lesion sites
Super scan

* Calculated as: (no. of patients with osseous metastasis at the site)/ (total no. of lesion sites) × 100.

** Calculated as: (no. of patients with osseous metastasis at the site)/ (total no. of patients) × 100.

The period for developing BMs after initial BC diagnosis or metastasis-free period was 7.38 ± 4.01 years and was significantly associated with the disease TNM stage ($r_s = -0.385$; $P = 0.011$). Sixteen patients (24%) were presented with BMs at the time of BC diagnosis, while the others developed BMs later during disease progression.

Discussion

It is estimated that the survival rate is significantly shorter in patients with advanced BC, compared to the patients with localized disease (25% vs. 99%). BMs have been found to be the commonest metastatic site in the advanced stage of the disease. In this regard, many studies have aimed to find a correlation between the presence of BMs and other possible risk factors influencing their occurrence (13, 14).

Age was published to be a significant independent risk factor for BMs, second after BC subtypes; with older women being more likely to develop BMs (15, 16, 17). The cut-off value for age was 49.5 in the research of Yazdani et al., who found 1.85 times greater risk for BMs in postmenopausal women (18). The present study group had a mean age of 52.52 ± 10.643 years, with 39 patients (59%) being above the suggested cut-off value. In contrast, Purushotham et al. observed an inverse correlation between age at the time of diagnosis and BMs, meaning the older the patient, the lower the risk of distant metastasis (19).

Ductal carcinoma is the most frequent histologic type of the diagnosed BC, representing 80%, followed by the lobular type with 10%, while all other types are represented by 1% (20). Bannoura et al., confirmed that ductal BC was the commonest histology type metastasizing to bone (93.5%) (21). On the contrary, other studies found a significant association for BMs with the tubular mixed type ($\chi^2 = 5.03$, $P = 0.025$), as well as with the lobular type (OR, 1.27 [95% CI, 1.2–1.35]) (22). Furthermore, the invasive form of lobular BC may present with unique small sclerotic bone lesions on BS that can easily be interpreted as negative on BS (23, 24).

Bannoura et al., noted a strong relationship between ductal BC and osteolytic lesions, while the lobular type was mainly associated with osteoblastic and mixed bone lesions (21). The majority of patients in our study had ductal histology (65%) which may suggest that osteoblastic or mixed lesions diagnosed on BS were mainly ductal. However, we could not perform an analysis on bone metastatic radiographic appearance because not all patients underwent SPECT/ CT.

High-grade tumors are expected to metastasize early following diagnosis (19). The most frequent tumor grade in our study was grade II (44%), followed by grade III and grade I with 39% and 3% of the patients, respectively. However, a recent meta-analysis found no statistically significant difference between histology type and grade with BMs (25).

Molecular subtypes have the strongest influence on the development of BM ($\chi^2 = 28$). Luminal types, which are the commonest, are associated with higher risk of bone metastasis than HER2 overexpressing and TNBC ($P < 0.001$) (15, 26, 27). Indeed, Paulo and coauthors published a

prevalence of luminal bone implants of 60.34%; 70% of luminal implants were located in flat bones (28).

In contrast with this data, no significant relationship was found between ER, PgR and HER-2 expression with BMs. The only significant molecular marker associated with BMs that they found was Ki-67 proliferation index ($P=0.034$) (29).

In accordance to the previous data, we reported that 86% of the patients had ER+ expression, and the luminal A subtype was the dominant subtype (65%). In addition, a significant correlation was found between HR+ status and the presence of multiple BMs ($P=0.021$). We also found a high Ki-67% expression in the majority of evaluated patients (mean expression 32.08 ± 16.62 %).

In regard to the TNM staging, higher stage, large tumor size, and presence of lymph node metastasis were found to have statistically significant risk for developing BMs (18, 19, 25). The probability of BMs in patients with T2, T3 and T4 stages were 1.99 times, 4.74 times, and 14.57 times higher than T1 stage (25). A diameter greater than 3cm was significantly associated with BMs in the study by Başdelioğlu et al. (16). The number of affected lymph nodes is also important; thus, the increased number of metastatic axillary nodes increases the risk of BMs by 1.065-fold as published by Yazdani (18). Majority of our patients were diagnosed with TNM stage 2 (35%) with tumor size between 2 and 5cm and grade II.

Bones with higher rates of turnover and higher vascularization such as ribs, spine and pelvis, are commonly affected by cancer cells compared to hand and foot bones (16, 17). Kakhki et al. published no metastatic lesions in the tibia and fibula (30). In our study, majority of cases had a combination of both axial and appendicular skeleton involvement, with predominance in the spine (thoracic vertebrae), ribs and pelvis.

The BMs free interval was associated with the TNM stage ($r_s=-0.385$; $P=0.011$) in our study. The results suggested the higher the initial disease stage, the shorter the time for developing BMs. Tumor size, histology, grade and molecular subtype did not seem to influence the time for BMs appearance in our study. Kim and co-authors found a close relationship between BM-free interval and molecular subtypes, where luminal A had the longest (>5 years) time without metastasis. However, they investigated the presence of any distant metastasis, where BMs were the most frequent (26). The metastasis-free interval was significantly associated with the number of metastatic bone lesions in the study of Bannoura, who found that patients with multiple BMs had a higher mean of metastasis-free interval than those with one bone lesion ($P=0.001$) (21).

Study Limitation

The present study has a few limitations. The study was retrospective. The majority of patients didn't have SPECT/ CT, so we couldn't analyze the radiological appearance of BMs. Further, the study group was small. Future research with a prospective design and large number of patients would be beneficial.

Conclusion

Our study emphasizes the importance of the role of prognostic factors in BMs development. According to the present study, the thoracic spine, the ribs and the pelvis are the preferred sites of BMs from BC. We found that a higher initial TNM stage reduces BMs free interval. Furthermore, HR positive status was a significant predictor of BMs in BC. This knowledge, hopefully, will lead to better stratification of patients for BS screening.

References:

1. Sung H, Ferlay J, Siegel RL, et al. Global Cancer Statistics 2020: GLOBOCAN Estimates of Incidence and Mortality Worldwide for 36 Cancers in 185 Countries. *CA Cancer J Clin.* 2021 May;71(3):209-249 doi: 10.3322/caac.21660.
2. Pagani O, Senkus E, Wood W, et al. ESO-MBC Task Force. International guidelines for management of metastatic breast cancer: can metastatic breast cancer be cured? *J Natl Cancer Inst.* 2010 Apr 7;102(7):456-63 doi: 10.1093/jnci/djq029.
3. Cardoso F, Kyriakides S, Ohno S, et al. ESMO Guidelines Committee. Electronic address: clinicalguidelines@esmo.org. Early breast cancer: ESMO Clinical Practice Guidelines for diagnosis, treatment and follow-up†. *Ann Oncol.* 2019 Aug 1;30(8):1194-1220 doi: 10.1093/annonc/mdz173.
4. G, Taylor A, Amelio J. Systematic review and meta-analysis on the proportion of patients with breast cancer who develop bone metastases. *Crit Rev Oncol Hematol.* 2017 Jul;115:67-80 doi: 10.1016/j.critrevonc.2017.04.008.
5. Jeon HL, Oh IS, Baek YH, et al. Zoledronic acid and skeletal-related events in patients with bone metastatic cancer or multiple myeloma. *J Bone Miner Metab.* 2020 Mar;38(2):254-263 doi: 10.1007/s00774-019-01052-6.
6. Donohoe KJ, Cohen EJ, Giammarile F, et al. Appropriate Use Criteria for Bone Scintigraphy in Prostate and Breast Cancer: Summary and Excerpts. *J Nucl Med.* 2017 Apr;58(4):14N-17N.
7. Van den Wyngaert T, Strobel K, Kampen WU, Kuwert T, et al. EANM Bone & Joint Committee and the Oncology Committee. The EANM practice guidelines for bone scintigraphy. *Eur J Nucl Med Mol Imaging.* 2016 Aug;43(9):1723-38 doi: 10.1007/s00259-016-3415-4.
8. Azad GK, Taylor B, Rubello D, et al. Molecular and Functional Imaging of Bone Metastases in Breast and Prostate Cancers: An Overview. *Clin Nucl Med.* 2016 Jan;41(1):e44-50 doi: 10.1097/RLU.0000000000000993.
9. Cook GJR, Goh V. Molecular Imaging of Bone Metastases and Their Response to Therapy. *J Nucl Med.* 2020 Jun;61(6):799-806 doi: 10.2967/jnumed.119.234260.
10. Li Y, Su P, Wang Y, et al. Impact of histotypes on preferential organ-specific metastasis in triple-negative breast cancer. *Cancer Med.* 2020 Feb;9(3):872-881 doi: 10.1002/cam4.2759.
11. Nishimura R, Osako T, Nishiyama Y, et al. Prognostic significance of Ki-67 index value at the primary breast tumor in recurrent breast cancer. *Mol Clin Oncol.* 2014 Nov;2(6):1062-1068 doi: 10.3892/mco.2014.400.

-
12. Tagliabue G, Fabiano S, Contiero P, et al. Airtum Working Group. Molecular Subtypes, Metastatic Pattern and Patient Age in Breast Cancer: An Analysis of Italian Network of Cancer Registries (AIRTUM) Data. *J Clin Med*. 2021 Dec 14;10(24):5873 doi: 10.3390/jcm10245873.
 13. Alteri R, Bertaut T, Brooks D, et al. Cancer facts & figures 2015. American Cancer Society, Atlanta. 2015:58–72.
 14. Fornetti J, Welm AL, Stewart SA. Understanding the Bone in Cancer Metastasis. *J Bone Miner Res*. 2018;33(12):2099–113. Epub 2018/11/27. doi: 10.1002/jbmr.3618.
 15. Diessner J, Wischnewsky M, Stüber T, et al. Evaluation of clinical parameters influencing the development of bone metastasis in breast cancer. *BMC Cancer*. 2016 May 12; 16:307 doi: 10.1186/s12885-016-2345-7.
 16. Başdelioğlu K. Bone metastasis: evaluation of 1100 patients with breast cancer. *Int J Clin Exp Pathol*. 2021 Mar 1;14(3):338-347.
 17. Kakhki VR, Anvari K, Sadeghi R, et al. Pattern and distribution of bone metastases in common malignant tumors. *Nucl Med Rev Cent East Eur*. 2013;16(2):66-9 doi: 10.5603/NMR.2013.0037.
 18. Yazdani A, Dorri S, Atashi A, et al. Bone Metastasis Prognostic Factors in Breast Cancer. *Breast Cancer (Auckl)*. 2019 Feb 22; 13:1178223419830978 doi: 10.1177/1178223419830978.
 19. Purushotham A, Shamil E, Cariati M, et al. Age at diagnosis and distant metastasis in breast cancer—a surprising inverse relationship. *Eur J Cancer*. 2014 Jul;50(10):1697-1705 doi: 10.1016/j.ejca.2014.04.002.
 20. Arpino G, Bardou VV, Clark GM, et al. Infiltrating lobular carcinoma of the breast: tumor characteristics and clinical outcome. *Breast Cancer Res*. 2004;6(3): R149-56. <https://dx.doi.org/10.1186%2Fbcr767>.
 21. Bannoura S, Nahouli H, Noubani A, et al. Characteristics of Breast Cancer Metastasizing to Bone in a Mediterranean Population. *Cureus*. 2020 Nov 24;12(11): e11679 doi: 10.7759/cureus.11679.
 22. James JJ, Evans AJ, Pinder SE, et al. Bone metastases from breast carcinoma: histopathological - radiological correlations and prognostic features. *Br J Cancer*. 2003 Aug 18;89(4):660-5. doi: 10.1038/sj.bjc.6601198.
 23. Al-Ogaili Z, Troedson R. Novel CT and scintigraphic findings of bone metastasis from invasive lobular breast cancer. *J Med Imaging Radiat Oncol*. 2016 Feb;60(1):47-53 doi: 10.1111/1754-9485.12415.
 24. Xiao W, Zheng S, Yang A, et al. Breast cancer subtypes and the risk of distant metastasis at initial diagnosis: a population-based study. *Cancer Manag Res*. 2018 Nov 5; 10:5329-5338 doi: 10.2147/CMAR.S176763.
 25. Liu H, Zhang X, Zhang S, et al. Factors associated with bone metastasis in breast cancer: a systematic review and meta-analysis. *Ann Palliat Med*. 2021 Apr;10(4):4435-4452 doi: 10.21037/apm-21-438.
 26. Anwar SL, Avanti WS, Nugroho AC, et al. (2020). Risk factors of distant metastasis after surgery among different breast cancer subtypes: a hospital-based study in Indonesia. *Observational Study*, 18, 117–33.
 27. Guo Y, Arciero CA, Jiang R, et al. Different Breast Cancer Subtypes Show Different Metastatic Patterns: A Study from A Large Public Database. *Asian Pac J Cancer Prev*. 2020 Dec 1;21(12):3587-3593. doi: 10.31557/APJCP.2020.21.12.3587.

28. Paulo Roberto de AF C1 * , Carlos Augusto RM , José Roberto FC.Evaluation of bone methastasis of breast cancer to long or short bones, according to molecular subtypes: retrospective study.. *Mastology*, 2019;29(1):32-36.
29. Afkari H, Makrufardi F, Hidayat B, et al. Correlation between ER, PR, HER-2, and Ki-67 with the risk of bone metastases detected by bone scintigraphy in breast cancer patients: A cross sectional study. *Ann Med Surg (Lond)*. 2021 Jun 29; 67:102532 doi: 10.1016/j.amsu.2021.102532.
30. Kim HJ, Ahn SG, Lee HM, et al. Metastasis-Free Interval Is Closely Related to Tumor Characteristics and Has Prognostic Value in Breast Cancer Patients with Distant Relapse. *J Breast Cancer*. 2015 Dec;18(4):371-7. doi: 10.4048/jbc.2015.18.4.371.

DOPPLER ULTRASOUND SCORING SYSTEM FOR IDENTIFICATION OF ENDOMETRIAL CANCER IN POSTMENOPAUSAL PATIENTS

Aleksioska Papestiev I¹, Antovska V¹, Sivevski A², Karadzova D², Spasovski S², Ilieva N¹

¹ University Clinic of Obstetrics and Gynecology, Skopje - Department of Gynecology

² University Clinic of Obstetrics and Gynecology, Skopje - Department of Anesthesia

ABSTRACT

Introduction: Endometrial cancer (EC) is the most common malignancy of the female genital tract in the developed world. Nowadays, preoperative evaluations using advanced imaging techniques have become more common, but little has been done on the best imaging technique for routine use and preoperative evaluations of endometrial carcinoma. The aim of this study was to evaluate the predictive value of Doppler ultrasound scoring system in detection of endometrial malignancy in postmenopausal patients with vaginal bleeding.

Material and Methods: This cross-sectional study, was conducted at the University Clinic of Obstetrics and Gynecology, Skopje and included 164 postmenopausal patients admitted to the Gynecology Department of the clinic. They were divided into two main groups based on their clinical presentation and further subdivided according to histopathological results. All patients underwent a standard transvaginal ultrasound examination followed by power Doppler endometrial vascularity assessment, as well as histopathological analyses of endometrial sampling for each of them was performed. Univariate and multivariate logistic regression were utilized to determine the predictive values of Doppler parameters and the scoring system.

Results: Significant associations were found between endometrial malignancy and various factors, including number of blood vessels, presence of densely packed bundles, the values of pulsatility index, resistance index, time averaged maximum velocity and peak systolic velocity. Among these, pulsatility index had the greatest influence (Wald=11.32/ $p < 0.01$ ($p = 0.001$)) and time averaged maximum velocity had the weakest influence (Wald=0.10/ $p > 0.05$ ($p = 0.73$)). Clinical scoring system exhibited a sensitivity of 79.60%, the specificity is 97.30%, and overall model accuracy is 91.50%.

Conclusion: The results of our study have proved that all Doppler parameters are significant predictive factors in determining endometrial cancer in postmenopausal patients with vaginal bleeding. Their combination could obtain a non-invasive scoring system that could reduce invasive procedure in diagnosis of the endometrial malignancy in patients with ultrasound characteristic of thickened endometrium more than 5mm. For this scoring system, there is a need of modern ultrasound device and clinician with greater experience.

Key Words: Doppler examination, endometrial cancer, postmenopausal women, scoring system, vaginal bleeding.

Introduction

Endometrial cancer (EC) takes the leading place in genital tract malignancies in women in the developed world (1,2). According to GLOBOCAN, in 2020, it has been diagnosed at 417,367 women, and 90,370 women have died because of this malignancy (3). In Republic of North Macedonia, endometrial cancer takes the second place following the breast cancer. In 2020, there were 360 diagnosed cases, and 80 patients died corresponding to an age-standardized incidence rate of 22.3 per 100,000 women (3).

Endometrial cancer is predominantly a disease of postmenopausal women, but it could be diagnosed during the reproductive and perimenopausal women as well. Most of the patients with endometrial cancer are found in postmenopausal patients, but occasionally it can be diagnosed in premenopausal women. The literature data have shown that most of the endometrial malignancy (75–80%) occur in postmenopausal period of the women (4).

Abnormal uterine bleeding is the presenting first symptom in 75 - 90% of women diagnosed with endometrial cancer (5). According to that, women with abnormal vaginal bleeding should undergo diagnostic procedure to exclude endometrial cancer. However, only in 10% of the patients with postmenopausal uterine bleeding, this malignancy will be diagnosed, and in the rest of the patients with any abnormal uterine bleeding symptom or ultrasound sign of thickened endometrium, benign lesions of the endometrium would be diagnosed (6).

The patients with endometrial cancer have good prognosis, but they should be diagnosed at the early stage (7). Therefore, patients with vaginal bleeding or thickened endometrium should be evaluated to rule out malignancy of the endometrium.

Transvaginal sonography (TVS) is the first line of investigation, and a finding of endometrial thickness ≥ 4 –5mm may indicate malignancy (8). The most gynecologists recommend the use of one of the invasive procedures in postmenopausal women with ET larger than 4–5mm at ultrasound examination. The simplest invasive diagnostic procedure is endometrial sampling, but this technique has high failure rates (8). Hysteroscopy today is a diagnostic method with the best accuracy, but it is alternative because of its cost (9). On the other hand, about 80–90% of patients with postmenopausal uterine bleeding have benign endometrial pathology and undergo an invasive diagnostic procedure to obtain an endometrial sample for histopathological evaluation, which may be accompanied by certain complications. Identification initially of patients with endometrium ≥ 4 –5mm and allowing risk of endometrial cancer, could reduce the number of invasive procedures in these patients, allowing costly fast-track regimes to be reserved for patients who are at high risk of cancer (8).

Nowadays, using advanced imaging techniques in preoperative evaluations of the patients with endometrial lesions have become more common, but the best imaging technique for routine use and preoperative evaluations of endometrial malignancy has not been introduced yet (10).

In 2008 in Chicago, the International Endometrial Tumor Analysis Group (IETA), designed a standardized consensus in order to improve the terminology and definitions for the description of ultrasound findings in the uterine cavity and gave recommendations, which can aid in the prediction and diagnosis of endometrial pathology (11). In their article, it has been published that an evaluation of endometrial morphology and vascularization using grayscale and Doppler ultrasound imaging with or without the added use of sonohysterography. Installation of saline or gel into the uterine cavity during scanning can be used to further refine the estimation of risk of pathology and, in particular, the risk of endometrial cancer. According to IETA, there are several parameters that can be considered when examining the vascularization of the endometrium in a patient with an endometrial lesion, such as the presence of vascularization and if it is present,

whether it is a single dominant blood vessel or more blood vessels, whether it is of focal origin or multifocal, and whether there are densely packed vascular bundles (11). The parameters that could indicate endometrial malignancy are pulsatility index (PI pulsatility index), resistance index (RI resistance index), TAMX (time averaged maximum mean velocity) and PVS (peak systolic velocity), so its measurement could help us in the evaluation of the patients suspected of endometrial cancer (12-17).

Objective

The aim of this study was to evaluate the predictive value of Doppler ultrasound scoring system in detection of endometrial malignancy in postmenopausal patients with vaginal bleeding.

Material and Methods

In this cross-sectional study, we included 164 postmenopausal women who were admitted to the Department of Gynecology at University Clinic of Obstetrics and Gynecology, Skopje, Republic of North Macedonia, in the period from December 1st, 2015 to July 31st, 2017. Postmenopausal women were defined as patients without menstruation for at least 12 months prior to evaluating of endometrium. The patients were admitted to the hospital because of the sonographic signs of thickened endometrium or vaginal bleeding, for further histopathological analyses of endometrial sampling as gold standard in the diagnosis of endometrial lesions. The patients were divided into two groups: Group A – postmenopausal women with uterine bleeding and an endometrial thickness of more than 4mm, and Group B – postmenopausal women with sonographic signs of an endometrial lesion (those with an endometrial thickness exceeding 4mm). Based on the histopathological results, these groups were further divided into four subgroups: A1 and B1 – patients with endometrial malignancies, and A2 and B2 – patients with benign endometrial lesions.

In the study were included postmenopausal patients with a thickened endometrium of more than 4mm and/ or vaginal bleeding. From the study were excluded all patients with postmenopausal bleeding because of hormone replacement therapy or patients with vaginal bleeding due to vaginal atrophy or other systemic diseases. Approval for ethical considerations was granted by the Medical Faculty Skopje's Ethics Committee.

Ultrasound examinations were carried out by the same gynecologist, OB/GYN consultants with high experience in gynecological ultrasound scanning. In the study, Voluson E8 ultrasound machines from General Electric Healthcare, outfitted with vaginal probes ranging from 5 to 9MHz, were utilized. Every patient received a routine transvaginal ultrasound scan, which was then followed by an evaluation of endometrial blood flow using power Doppler.

For each patient a predefined examination protocol form that included information on the uterine anteroposterior (AP) ratio, endometrial thickness, echogenicity, the endometrial myometrial border (regular/irregular) and vascularization, was filled out by the examining doctor immediately after the examination. The females were assessed in the lithotomy stance while their bladders were empty. The uterus was imaged from one cornu to the other in the sagittal orientation and from the cervix to the fundus in an oblique transverse view. After obtaining a comprehensive view of the entire uterus, the image was zoomed in to focus solely on the uterine corpus. We defined the tumor mass in the sagittal plane, and we measured the uterine AP ratio and endometrium at the point where we found the thickest endometrium. At this point an examination of the vascularization of the endometrium was done. Power Doppler was included, activated to monitor the flow of blood (blood flow mapping), set to maximum sensitivity for detecting blood vessels with slow flow, without sound in order to detect the most vascularized part of the endometrium and to perform the examination at that level by activating the FVW

- flow velocity waveform. For conducting transvaginal color Doppler ultrasound (TV CDU), the wall filters were configured at 100Hz, and the pulse repetition frequency varied between 2 and 32kHz. Following the detection of blood vessels, Doppler waveforms were sourced from vessels either inside the tumor or within the abnormal endometrial tissue, as well as from those surrounding it. Analysis of Power Doppler signals was according to IETA recommendations and included detection of vascularization, number of blood vessels, presence of densely packed bundles (11). Moreover, measurements were taken for the pulsatility index (PI), resistance index (RI), time-averaged maximum velocity (TAMX), and peak systolic velocity (PSV). The blood flow metrics within the tumor were automatically calculated in the following manner: 1. Resistance Index (RI): This measure of vascular resistance is calculated by subtracting the diastolic end frequency change from the systolic frequency change, and then dividing the result by the systolic frequency change. 2. Pulsatility Index (PI): The pulsatility index is the difference between the peak systolic flow velocity and the diastolic end divided by the mean flow rate. 3. Peak Systolic Velocity (PSV): This metric was determined in each tumor, measured in centimeters per second.

The data for different parameters was detected at the specially designed Doppler scoring system (Table 1).

Table 1. Doppler scoring system

Doppler scoring system		
Number of blood vessels	No blood vessel	0
	One blood vessel	1
	Many blood vessels	2
Presence of densely packed bundles	Yes	0
	No	2
RI of vascularization of endometrial lesion	>0.42	0
	<0.42	1
PI of vascularization of endometrial lesion	>1.2	0
	<1.2	1
TAMV (time averaged maximum velocity)	<18sm/s	0
	>18sm/s	1
PSV (peak systolic velocity)	<13cm/s	0
	>13cm/s	1

All 164 patients who met the inclusion criteria underwent dilatation and curettage or hysteroscopy for endometrial sampling. The operation was carried out in the surgical suite and was administered with brief intravenous anesthesia, all by the same physician. The material obtained from the endometrial biopsy was sent to the Institute of Pathology at the Faculty of Medicine for histopathological analysis were made by a different pathologist. Depending on the histopathological analysis, patients were subdivided in four subgroups, two with endometrial

malignancy and two subgroups without.

Statistical Evaluation

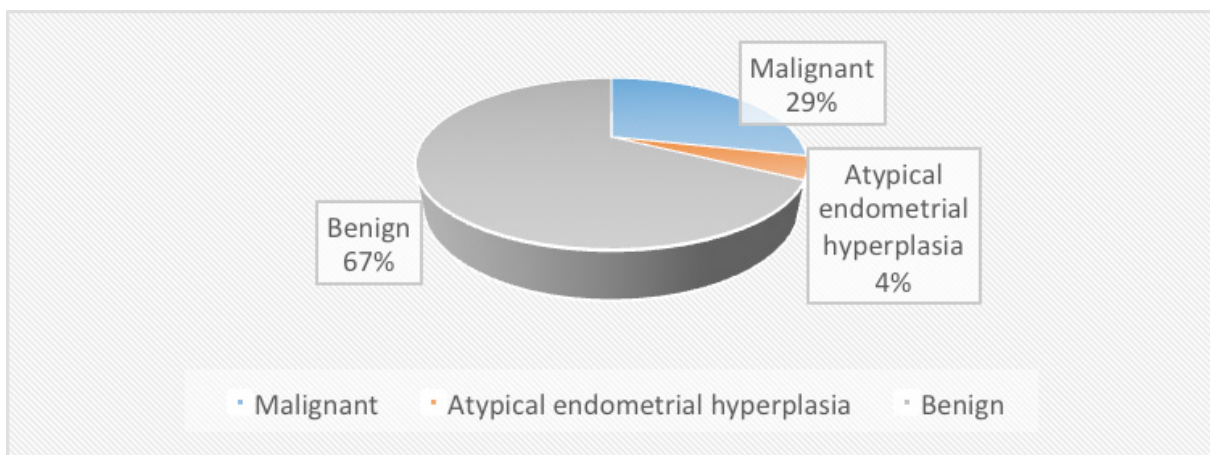
The data was analyzed using STATISTICA 7.1 and SPSS 17.0 software for Windows. We used univariate regression analysis to determine potential relationships between endometrial malignancy and Doppler parameters. A p-value below 0.05 in the likelihood ratio test was deemed to be statistically meaningful. The predictive values of the scoring system were evaluated using multivariate logistic regression.

Results

The mean age of the patients was 60.05 ± 9.09 ; $\pm 95\%$ CI: 58.80-61.30. The youngest patient was 40 years and the oldest was 85 years old.

Histopathological analysis at the examined groups (A and B) showed positive findings at 47 patients (28.66%) with endometrial cancer and atypical endometrial hyperplasia at 7 (4.27%). Another 110 patients had benign pathology as shown in Graph 1.

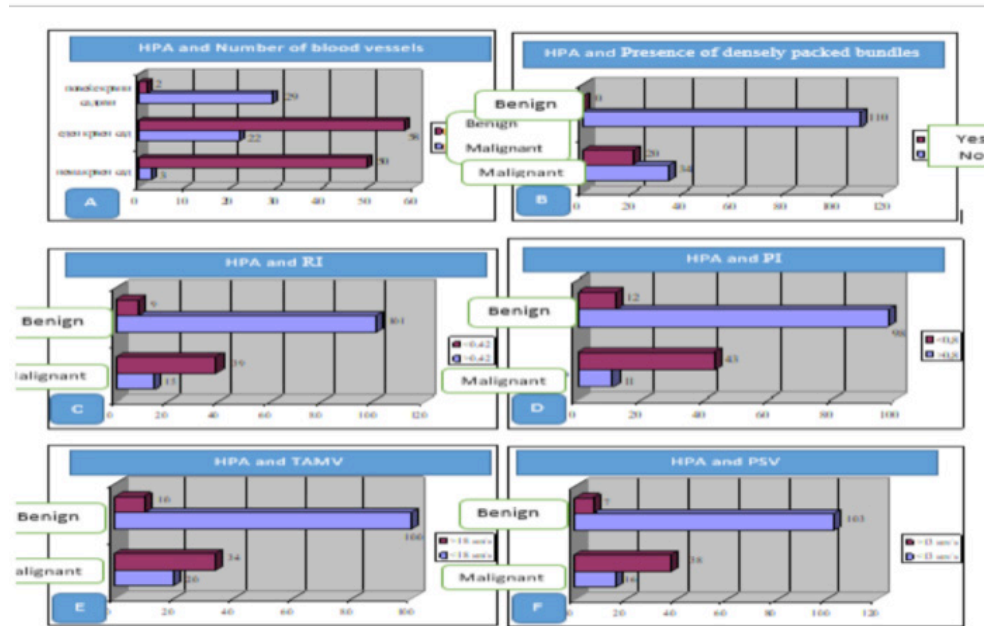
Graph 1. Histopathological findings in examined groups A+B.



On Figure 1 are shown data related to Doppler parameters (number of blood vessels, presence of densely packed bundles, the values of pulsatility index (PI), resistance index (RI), time averaged maximum velocity (TAMX) and peak systolic velocity (PSV)) in female patients and histopathological findings of endometrial sampling.

There is a significant difference in the shown distribution of data related to number of blood vessels and histopathological findings of endometrial sampling Pearson Chi-square = 70.49 and $p < 0.001$ ($p = 0.000$), presence of densely packed bundles and histopathological findings of endometrial sampling Pearson Chi-square = 46.40 and $p < 0.001$ ($p = 0.000$), the values of resistance index (RI) and histopathological findings of endometrial sampling Pearson Chi-square = 71.75 and $p < 0.001$ ($p = 0.000$), pulsatility index (PI) and histopathological findings of endometrial sampling Pearson Chi-square = 76.74 and $p < 0.001$ ($p = 0.000$), time averaged maximum velocity (TAMX) and histopathological findings of endometrial sampling Pearson Chi-square = 53.55 and $p < 0.001$ ($p = 0.000$) and peak systolic velocity (PSV) in female patients and histopathological findings of endometrial sampling = 74.53 and $p < 0.001$ ($p = 0.000$).

Figure 1. Doppler parameters and histopathological findings.



The results regarding the predictive values of the number of blood vessels crossing the endometrium-myometrium border, the presence of densely packed vascular bundles, RI, PI, TAMV, PSV, for endometrial malignancy are shown in Table 2.

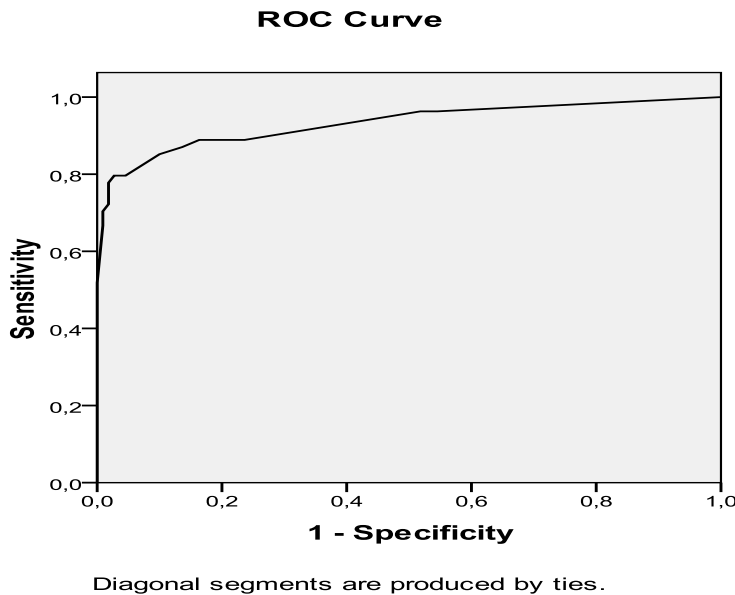
In the analysis, it was determined that there were high standard error values for the parameter presence of densely packed vascular bundles, which is why it was excluded in the repeated analysis.

Table 2. Predictive value of the Doppler parameters for endometrial malignancy.

Table 2		B	S.E.	Wald	df	Sig.	Exp(B)	95% C.I. for EXP(B)	
								Lower	Upper
Step 1 ^a	one blood vessel (1)	.29	.83	.12	1	.73	1.34	.26	6.86
	multiple blood vessels (1)	2.91	1.18	6.08	1	.01	18.41	1.82	186.40
	RI(1)	1.27	.73	3.03	1	.08	3.55	.85	14.77
	PI(1)	2.26	.67	11.32	1	.001	9.59	2.57	35.79
	TAMV(1)	-.24	.78	.10	1	.75	.78	.17	3.58
	PSV(1)	1.74	.72	5.81	1	.02	5.68	1.38	23.31
	Constant	-3.15	.68	21.34	1	.00	.04		

^aVariable(s) entered on step 1: one blood vessel, multiple blood vessels, RI, PI, TAMV, PSV. The sensitivity of the model is 79.60%, the specificity is 97.30%, and the global accuracy of the

model is 91.50%. The value of the ROC curves for this model is shown in Figure 1. The ROC zone (below the line) is 0.932.



Between endometrial malignancy and the results for the Doppler scoring system including number of blood vessels crossing the endometrial-myometrium border, RI, PI, TAMV, PSV, for Chi-square=120.95 and $p < 0.001$ ($p = 0.000$) there is a significant association.

When determining the significance of the contribution of each component, it was determined that PI (1) has the greatest influence (Wald=11.32 / $p < 0.01$ ($p = 0.001$), then more blood vessels (1) (Wald=6.08 / $p < 0.05$ ($p = 0.01$), PSV (1) (Wald=5.81 / $p < 0.05$ ($p = 0.02$), RI (1) (Wald=3.03 / $p > 0.05$ ($p = 0.73$), and TAMV (Wald=0.10 / $p > 0.05$ ($p = 0.73$)).

The probability of endometrial malignancy in patients with PI (1) < 0.8 is 9.59 times (Exp(B)=9.59) higher than in patients with PI > 0.8 , the indication is significant (95.%CI:2.57-35.79)/ $p < 0.01$; in patients with RI (1) < 0.42 is 3.55 times (Exp(B)=3.55) higher than in patients with RI > 0.42 , the indication is not significant (95.% CI:0.85-14.77)/ $p > 0.05$; in patients with multiple blood vessels (1) crossing the endometrial-myometrial border is 18.41 times (Exp(B)=18.41) higher than in patients who do not have a blood vessel crossing the endometrial-myometrial border, the indication is significant (95.%CI:1.82-186.40)/ $p < 0.05$; in patients with PSV (1) > 13 cm/s is 5.68 times (Exp(B)=5.58) higher than in patients with PSV < 13 cm/s, the indication is significant (95, %CI:1.38-23.31)/ $p < 0.05$; and in patients with TAMV (1) > 18 sm/s is 0.78 times (Exp(B)=0.78) lower than at patients with TAMV < 18 sm /s, the indication is not significant (95 ,%CI:0.17-3.58)/ $p > 0.05$.

Discussion

While merely around 10% of women experiencing abnormal uterine bleeding (AUB) will actually have cancerous tumors, precise imaging of endometrial abnormalities can aid in either ruling out or proceeding with additional invasive tests. These further tests are aimed at collecting tissue samples for histological analysis of the endometrium (18,19). The key drawback of using transvaginal sonography for distinguishing endometrial abnormalities lies in its heavy reliance

on the skill of the examiner. Even when performed by the same sonographer, the technique may display significant variability between different observers (20). The evaluation of endometrial thickness (ET) has been recommended using different cut-off points. Typically, a combined layer thickness of less than 4–4.5mm is considered a safe threshold, effectively ruling out endometrial cancer in the most cases (18,19).

Recently, with the novel technological advancement in ultrasound devices, progress of technical achievements, more and more attention has been paid to the possibility of examining the vascularization of endometrial change and measuring flow by Doppler examination and investigating its value as a predictive parameter for malignant endometrial change (13,21). According to IETA, there are several parameters that can be taken into account when examining the vascularization of the endometrium in a patient with an endometrial lesion, such as the presence of vascularization; and if it is present, whether it is a single dominant blood vessel or more blood vessels; whether it is of focal or multifocal origin and whether there are densely packed vascular bundles (11). The vascular pattern obtained using 2D ultrasound or the color content obtained using either 2D or 3D ultrasound has been shown that it can be used for the prediction of endometrial cancer in women with postmenopausal bleeding by many authors (13,21-23). In one of their publications, Opolskiene and team presented their findings on studying the endometrium's morphological features and new blood vessel formation. Their focus was on predicting endometrial cancer in postmenopausal patients who had uterine bleeding and an endometrial thickness exceeding 4.5mm. They emphasized that the density and number of blood vessels hold the most diagnostic significance for detecting endometrial malignancy in such patients (21). Dueholm also examined the value of all parameters recommended by IETA and after performing univariate analysis of each parameter concluded that all parameters were found to be significant for the prediction of EM (8). Valentin points out the densely packed bundles and irregular branching of the blood vessels of the endometrium as the most significant (24).

In this study we have shown that grayscale and vascular morphology characteristics of endometrium could help in detection of endometrial cancer. In our research, we examined the number of blood vessels crossing the endometrium-myometrium, as well as the presence of densely packed bundles. In all patients in whom the presence of densely packed bundles was recorded, the histopathological analysis showed a malignant change. Out of 81 patients in whom there was only one blood vessel, malignant change was recorded in 22 (27.50%). On the other hand, out of 31 patients who had more blood vessels crossing the border, as many as 29 (93.55%) had a malignant change, and it was determined that the patients who had more blood vessels had 18.41 times more likely to have EM than those who had a single vessel. In his study, Epstein demonstrated that the presence of multiple global vessels was associated with high-risk endometrial cancer. On the other hand, tumors that lacked vascularization were predominantly found in low-risk cases of endometrial cancer (19).

In the literature, it has been published that intra-tumor flow rate parameters including PI, RI, TAMX and PVS are parameters that can also indicate malignant change of the endometrial lesion, and in endometrial carcinoma were significantly higher than in patients with endometrial hyperplasia (10, 13-17,25). Szpurek in his paper pointed out that PI, RI, and TAMV values could help in differentiation of benign from malignant endometrial changes (14). RI, PI and PSV were investigated in patients with proven type II endometrial carcinoma in postmenopausal patients with uterine bleeding by Duguner, and he pointed out that RI and PSV were found to be significant predictive factors in his population (17). On the other hand, in the study of N. M. Anel Moboud, who examined the role of TVU and color Doppler examination in patients with postmenopausal bleeding, only PI proved to be significant, in contrast to RI (15). The same conclusion, in the same population, was also reached by Bano, in whose research PI also proved to be more significant (25).

Finally, it must be emphasized that performing a Doppler examination requires a modern ultrasound device and clinician with greater experience. It also must be pointed out that if there is intracavitary fluid or large fibromas that make it impossible to obtain a clear image of the endometrium, there is a limitation for Doppler examination. It should also be mentioned its limitation in patients with thin endometrium, in whom it can rarely be performed. However, we performed multivariate regression analysis on all Doppler parameters and obtained a Doppler scoring model with sensitivity 79.60%, specificity 97.30% and global accuracy 91.50%. The ROC zone (below the line) is 0.932.

Conclusion

The results of our study have proved that all Doppler parameters are significant predictive factors in determining of endometrial cancer in postmenopausal patients with vaginal bleeding. Their combination could obtain a noninvasive scoring system that could reduce invasive procedure in diagnosis of the endometrial malignancy in patients with ultrasound characteristic of thickened endometrium more than 5mm with endometrial. For this scoring system, there is need of modern ultrasound device and clinician with greater experience. It also must be pointed out that if there is intracavitary fluid or large fibromas that make it impossible to obtain a clear image of the endometrium, there is a limitation for Doppler examination. The results showed that the best predictive individual Doppler parameter is multiple blood vessels.

References

1. Bray F, Ferlay J, Soerjomataram I, et al. Global cancer statistics 2018: GLOBOCAN estimates of incidence and mortality worldwide for 36 cancers in 185 countries. *CA Cancer J Clin.* 2018;68(6):394-424.
2. Siegel RL, Miller KD, Jemal A. Cancer statistics, 2018. *CA Cancer J Clin.* 2018; 68:7-30.
3. Sung H, Ferlay J, Siegel RL, et al. Global cancer statistics 2020: GLOBOCAN estimates of incidence and mortality worldwide for 36 cancers in 185 countries. *CA Cancer J Clin.* 2021; 71:209–49.
4. Siegel RL, Miller KD, Jemal A. Cancer statistics. *CA Cancer J Clin.* 2016; 66:7–30.
5. Rizzo S, Femia M, Buscarino V. Endometrial cancer: An overview of novelties in treatment and related imaging keypoints for local staging. *Cancer Imaging.* 2018; 18:45.
6. M.C. Breijer, H.C. van Doorn, T.J. Clark, et al. Diagnostic strategies for endometrial cancer in women with post-menopausal bleeding: cost-effectiveness of individualized strategies *Eur. J. Obstet. Gynecol. Reprod. Biol.*, 163 (1) (2012), pp. 91-96.
7. Batool S, Manzur S, Raza S. Accuracy of Doppler ultrasound in diagnosis of endometrial carcinoma. *J Pak Med Assoc.* 2013; 63:28–31.
8. Dueholm M., Moller C, Rydbjerg S, et al. An ultrasound algorithm for identification of endometrial cancer. *Ultrasound Obstet Gynecol*2014; 43:557-568.
9. Van Dongen H, de Kroon CD, Jacobi CE, et al. Diagnostic hysteroscopy in abnormal uterine bleeding: a systematic review and meta-analysis. *BJOG*2007;114:664–675.
10. Ahmadzade A, Gharibvand MM, Azhine S. Correlation of color Doppler ultrasound and pathological grading in endometrial carcinoma. *J Family Med Prim Care* 2020; 9:5188-92.

11. F. P. G. Leone, D. Timmerman, T. Bourne, et al. Terms, definitions and measurements to describe the sonographic features of the endometrium and intrauterine lesions: a consensus opinion from the International Endometrial Tumor Analysis (IETA) group. *Ultrasound Obstet Gynecol* 2010;35: 103 – 112.
12. M El- Morsi Aboul-Fotouh, M Hani Mosbeh, A Fathi El-Gebaly, et al. Transvaginal power Doppler sonography can discriminate between benign and malignant endometrial conditions in women with postmenopausal bleeding. *Middle East Fertility Society Journal* 2012. 17,22-29.
13. J.L. Alkazar, G Castilo. J A. Mingues et al. Endometrial blood flow mapping using transvaginal power Doppler sonography in women with postmenopausal bleeding and thickened endometrium. *Ultrasound Obstet Gynecol* 2003; 21:583-588.
14. Szperek D, Sajdak S, Moszynski R, et al. Estimation of neovascularization in hyperplasia and carcinoma of endometrium using a “power” angi-Doppler technique *Eur J Gynecol Oncol.* 2000;21(4):405-7.
15. NM AbdelMaboud, HH Elsaid. Role of transvaginal ultrasonography and colour Doppler in the evaluation of postmenopausal bleeding. *The Egyptian Journal of Radiology and Nuclear Medicine* 2015.46, 235-243.
16. De Kroon CD, Hiemstra E, Trimbos JB, et al. Power Doppler area in the diagnosis of endometrial cancer. *Int J Gynecol Cancer* Oct; 2010(7):1160-5.
17. Düzgüner S, Ozkan MB, Küçüközkan T, et al. Role of spiral artery Doppler to screen type 2 endometrial cancer cases. *J Turk Ger Gynecol Assoc.* 2014 Mar 1;15(1):1-5.
18. Stachowicz, N.; Smole 'n, A.; Ciebiera, M. et al. Risk Assessment of Endometrial Hyperplasia or Endometrial Cancer with Simplified Ultrasound-Based Scoring Systems. *Diagnostics* 2021, 11, 442.
19. Van Hanegem, N.; Prins, M.M.; Bongers, M.Y. et al. The accuracy of endometrial sampling in women with postmenopausal bleeding: A systematic review and meta-analysis. *Eur. J. Obstet. Gynecol. Reprod Biol.* 2016, 197, 147–155.
20. Haldorsen, I.S.; Salvesen, H.B. What is the best preoperative imaging for endometrial cancer? *Curr. Oncol. Rep.* 2016, 18-25.
21. Opolskiene G, Sladkevicius P, Valentin L. Ultrasound assessment of endometrial morphology and vascularity to predict endometrial malignancy in women with postmenopausal bleeding and sonographic endometrial thickness ≥ 4.5 mm. *Ultrasound Obstet Gynecol* 2007;30: 332 – 340.
22. Epstein E, Van Holosbeke C, Mascilini F, et al. Gray scale and color Doppler ultrasound characteristics of endometrial cancer in relation to stage, grade and tumor size. *Ultrasound Obstet Gynecol* 2011;38:586-593.
23. Alcazar JL, Galvan R. Three-dimensional power Doppler ultrasound scanning for the prediction of endometrial cancer in women with postmenopausal bleeding and thickened endometrium. *Am J Obstet Gynecol* 2009;200:44e1–6.
24. L. Valentin. Ultrasound deserves to play prominent role in the diagnosis and management of endometrial cancer. *Ultrasound Obstet Gynecol* May 2014;43(5);483-487.
25. Bano I, Akhtar Nishat, Mittal G, et al. A study of Endometrial Pathology by Transvaginal Color Doppler Ultrasonography and its Correlation with Histopathology in Postmenopausal Women. *Indian Medical Gazette.* 2013 Apr; 147 (4): 134-139.

FABRY DISEASE – CLINICAL REVIEW RARE, BUT NOT SO RARE!

Gjorgjievski N^{1,2}, Karanfilovski V^{1,2}, G. Nikolov I^{1,2}

¹ University Clinic of Nephrology, Skopje, Republic of North Macedonia

² Faculty of Medicine, University “Ss. Cyril and Methodius” Skopje, Republic of North Macedonia

Fabry disease (FD) often referred to as Fabry-Anderson disease is uncommon monogenetic X-linked disorder of Glycosphingolipid (fat) metabolism. It is extremely rare, estimated birth prevalence is 1:40,000-170,000, but the late-onset forms of the disease are more frequent (1). The α -galactosidase A gene (GLA) is located on the X-chromosome with more than 600 mutations that are associated with FD. Dermatologist Johannes Fabry and surgeon William Anderson initially described it in 1898 (2,3). A lack of the lysosomal enzyme α galactosidase (α -GAL) results in FD, one of a vast group of illnesses known as lipid storage disorders. The disease-causing enzyme was the first identified in the 1960s and it is typically responsible for the accumulation of glycosphingolipids, primarily globotriaosylceramide (also known as Gb3, GL-3, or ceramide trihexoside), in the vascular endothelium of the skin, kidneys, nervous system and heart. This causes inflammation and fibrosis (4). Due of this abnormal buildup, which prevents blood flow to the surrounding tissues (causing a shortage of oxygen and nutrients), it is referred to as a “storage disorder”. This explains how this disease manifests its symptoms.

A multisystemic condition called Fabry disease usually starts in childhood or adolescence and worsens over time. Regarding the phenotype characteristics of the disease, two types are currently reported: classical and non-classical or late-onset. Hemizygous males usually presented as a classical type due to very low residual function of α -GAL. Due to random X-inactivation or lyonization that results in fluctuating expression of α -GAL, heterozygous females may also be impacted and experience disease onset later. They are usually presented as a non-classical type due to more variable and attenuated phenotype characteristics. However, both forms could be present in both genders with variable clinical manifestations (5,6).

The symptoms in patients with FD vary depending on the type and time of its appearance. The main symptoms are uncontrolled chronic burning pain located on the extremities (known as acroparesthesia), sometimes accompanied by swelling and abdominal cramping. They typically appear for the first time during early childhood. It is thought that this discomfort is caused by damaged peripheral nerve fibers that transmit pain and that it might worsen with time. Also, the patients may have diarrhea, nausea, bloating, sensory abnormalities, hearing loss, tinnitus, heat, cold, and exercise intolerance (7, 8). Another very frequent symptom is anhidrosis (lack of sweating) or less commonly hyperhidrosis (excessive sweating) with dry skin. Angiokeratomas, which are tiny, painless papules that can occur anywhere on the body, but are more common on the thighs, around the navel, buttocks, lower belly and groin, are also dermatological signs of FD. Angiokeratomas are common early symptoms among adults and children with classical FD type. Patients with FD manifest with corneal verticillation, sometimes referred to as vortex keratopathy, in their eyes. When asymptomatic patients appear with keratopathy, it must be distinguished from other causes of vortex keratopathy, such as drug accumulation in the cornea. Obscuration has no impact on vision. Conjunctival and retinal vascular anomalies, as well as cataracts that resemble anterior and posterior spokes, are some other ocular findings. Rarely these symptoms do cause visual diminution (8). Renal complications may appear with mild symptoms such as: microalbuminuria or intermittent proteinuria in children and adults,

hyperfiltration and impaired of urinary GL-3 excretion. Hence, the patients with advance type of FD, especially men, have severe clinical symptoms including decline of glomerular filtration rate (GFR) that lead to irreversible progressive chronic kidney disease (CKD) and end-stage renal disease. The accumulation of Gb3 within heart muscle cells causes abnormal thickening (hypertrophy) and restrictive cardiomyopathy, conduction abnormality, vascular dysfunction, arrhythmias, myocardial infarction and sudden death (9).

Generally, in patients with FD life expectancy is diminished, although this is more apparent in males and is correlated to severe complications, such as stroke, transit ischemic attacks (TIAs), heart failure, and progressive renal insufficiency. More often it can be very difficult to understand the large number of non-specific symptoms and to be recognized by many clinicians. The rarity of Fabry's disease and unawareness lead to misdiagnosis. An enzyme test using a drop blood spot card (often performed on leukocytes) can be used to determine the diagnosis based on the patient's clinical manifestations. This test measures the level of α -GAL activity and lyso GL-3. Genetic confirmatory testing needs to detect mutations in the affected gene (GLA) and is performed only if a positive or borderline enzyme test results.

Moreover, a very important thing is the screening on the high-risk populations and in patients with unexplained CKD who may identify the undiagnosed patients. However, subsequent family screening may identify affected relatives in the early stage of the disease. Furthermore, a multidisciplinary approach is essential at every stage of FD, but nephrologists are the most numerous in the setting of the diagnosis that is confirmed by literature review (10).

Treatment of Fabry Disease: Established and Emerging Therapies

Early diagnosis and initiation of therapy guided by a multidisciplinary medical team in patients with FD is crucial for preventing irreversible and potentially life-threatening complications (11). In order to prevent or stabilize kidney function, improve heart structure and function, lessen the degree of neuropathic pain and improve gastrointestinal involvement, the treatment's objective is to diminish the accumulation of Gb3 in the lysosomes (12). The existing available therapies are based on boosting the availability of α -GAL inside lysosomes by correcting α -GAL misfolding with chaperone therapy or replacing the deficient α -GAL enzyme with recombinant enzyme replacement therapy (ERT) (11,12).

Enzyme replacement therapy with recombinant human α -GAL enzyme reduced Lyso-Gb3 accumulation and could slow or delay organ damage and improve clinical signs and symptoms of FD, such as kidney dysfunction, neuropathic pain, gastrointestinal outcomes and cardiac manifestations (13). ERT had a beneficial effect on Gb3 levels, cardiac outcomes and quality of life even in heterozygous females with FD (14) [Table 1].

Table 1. Characteristics of currently available treatment options for FD (11,12)

Drug name	Agalsidase- β	Agalsidase- α	Migalasta (Chaperone therapy)
Characteristics	First ERT agent approved in 2003, Recombinant α -GAL produced in Chinese hamster ovary cells.	Recombinant α -GAL produced in a human cell line (human fibrosarcoma cells HT-1080).	First-in-class agent, Binds reversibly to the active site of the amenable mutant of α -GAL.
Administration and dosage	Intravenous infusion every two weeks at dose of 1.0 mg/kg body weight.	Intravenous infusion every two weeks at the recommended dosage of 0.2 mg/kg body weight.	Oral.
Physiological effect	Decreases accumulation of Gb3/Lyso-Gb3 accumulation.	Decreases accumulation of Gb3/Lyso-Gb3 accumulation.	Promotes trafficking of α -GAL to lysosome, thus increasing enzyme activity.

Both ERT medications have been demonstrated to increase the quality of life and overall survival of the patients with FD. However, Arends et al. found that individuals treated with Agalsidase- β had more significant drop in plasma lyso-GL3 and left ventricle mass index, but equal preservation of renal function as those treated with Agalsidase- α , based on their analysis of 387 patients with FD. The development of anti-agalsidase antibodies was higher with Agalsidase- β , but its effect continued in the presence of antibodies (15). Agalsidase- α also leads to improvement in cardiac function (at least 1 class of NYHA heart failure system), stabilization of angina pectoris (98% of the patients), and maintenance of renal function (16). The data showed that Agalsidase- β was much more successful than Agalsidase- α and should be used as the first-line therapy in classic FD males with no residual enzyme activity (19). However, switching from Agalsidase- α to Agalsidase- β without losing efficacy is possible (17,19). Development of anti-agalsidase antibodies (Ab) was present in 40% of FD men and in 8% of FD female exposed to Agalsidase, and although lyso-GL3 levels were higher in the Ab-positive patients, their clinical significance remained unclear (20).

For FD patients with susceptible mutations, migalastat, a first-in-class oral chaperone therapy, has shown encouraging outcomes as an alternative to intravenous ERT. A few on-going studies report similar or better effects of Migalastat compared to ERT on renal, cardiac and cerebrovascular events (11). The studies showed that plasma or urinary levels of Gb3 do not necessarily correlate with the severity of disease manifestations, neither in hemizygote or heterozygote FD patients, and could not be used as a parameter for initiation or cessation of ERT (20,21). Based on several laboratory markers as indicators of an early stage of organs damage, the European Fabry Working Group in 2015 published Recommendations for initiation and cessation of ERT in patients with FD (1) [Table 2]. The treatment should not be started only in patients with advanced cardiac disease, with or without end-stage renal disease without an option for transplantation or in case of end-stage FD or other comorbidities with a life expectancy of < 1 year (1).

Table 2. Consensus criteria for initiation of ERT with classes of recommendation according to European Fabry Working Group (1).

	Class I Indicated	Class IIA Should be considered	Class IIB May be considered
Classical FD, males	Microalbuminuria, Proteinuria, Renal insufficiency (GFR 60-90 ml/ min/1.73m ²), Cardiac hypertrophy, Arrhythmias.	Transition ischemic attack (TIA)/stroke, Neuropathic pain, Gastrointestinal symptoms < 16 years of age,	≥ 16 years age, Renal insufficiency (GFR 45-60 ml/ min/1.73m ²), White mass lesions, Hearing loss, corrected for age, Neuropathic pain even if completely controlled with medications, Gastrointestinal symptoms > 16 years of age.
Non-classical FD, males	Microalbuminuria, Proteinuria, Cardiac hypertrophy without/or with minimal fibrosis, Arrhythmias.	Renal insufficiency (GFR 60-90 ml/ min/1.73m ²), Transition ischemic attack (TIA)/stroke, Neuropathic pain, Gastrointestinal symptoms < 16 years of age.	Renal insufficiency (GFR 45-60 ml/ min/1.73m ²), White mass lesions, Hearing loss, corrected for age, Neuropathic pain even if completely controlled with medications, Gastrointestinal symptoms > 16 years of age.
Classical FD, females	Cardiac hypertrophy without/or with minimal fibrosis, Arrhythmias.	Renal insufficiency (GFR 60-90 ml/ min/1.73m ²), Transition ischemic attack (TIA)/stroke, Neuropathic pain, Gastrointestinal symptoms < 16 years of age.	Microalbuminuria, Proteinuria, Renal insufficiency (GFR 45-60 ml/ min/1.73m ²), White mass lesions, Hearing loss, corrected for age, Neuropathic pain even if completely controlled with medications, Gastrointestinal symptoms > 16 years of age.

Non-classical FD, females	Cardiac hypertrophy without/or with minimal fibrosis, Arrhythmias.	Transition ischemic attack (TIA)/stroke, Neuropathic pain, Gastrointestinal, symptoms < 16 years of age.	Microalbuminuria, Proteinuria, Renal insufficiency (GFR 45-90 ml/min/1.73m ²), White mass lesions, Hearing loss, corrected for age, Neuropathic pain even if completely controlled with medications, Gastrointestinal symptoms > 16 years of age.
----------------------------------	--	--	---

Table 3. *Emerging Therapies for treatment of Fabry disease (1).*

Drug class	Mechanism of action and additional characteristics	
Next Generation ERT	Pegunigalsidase-α	Low levels of treatment-induced IgG anti-drug antibodies
	Moss α -GAL	Prolonged reduction of GL3
Substrate Reduction	Lucerastat	Reduces the production of glucosylceramide (GL1), which subsequently decreases GL3 production and accumulation in cells. Combined with ERT increases its efficiency.
	Venglustat	
	Genz-682452	
Gene Therapies	Hematopoietic stem/progenitor cells are harvested and integrated with GLA cDNA into host DNA using lentivirus, and then transplanted back into bone marrow for α galactosidase A expression. Adenovirus or Lipid nanoparticle encapsulated mRNA can be also used.	

Misdiagnoses and diagnostic delays in patients with Fabry disease may result with late initiation of treatment and finally worse prognosis. The primary predictors of survival in FD are renal involvement and left ventricular hypertrophy, and cardiac disease is the leading cause of death. The early initiation of treatment is imperative to avoid multi-organ involvement and disease progression.

Abbreviations:

- FD: Fabry Disease
- GLA: α-galactosidase A gene
- α-GAL: alpha-galactosidase enzyme
- Gb3 or GL-3: globotriaosylceramide
- GFR: glomerular filtration rate
- TIA: transit ischemic attacks
- CKD: chronic kidney disease
- ERT: enzyme replacement therapy

References:

1. Biegstraaten, Marieke, et al. "Recommendations for initiation and cessation of enzyme replacement therapy in patients with Fabry disease: the European Fabry Working Group consensus document." *Orphanet journal of rare diseases* 10.1 (2015): 1-10.
2. Fabry, Joh. "losa haemorrhagica Hebrae." *Archiv für Dermatologie und Syphilis* 43 (1898): 187.
3. Anderson, William. "A case of "angeio-keratoma."." *British Journal of Dermatology* 10.4 (1898): 113-117.
4. Brady, Roscoe O., et al. "Enzymatic defect in Fabry's disease: ceramidetrihexosidase deficiency." *New England Journal of Medicine* 276.21 (1967): 1163-1167.
5. MacDermot, K. D., A. Holmes, and A.H.I Miners. "Anderson-Fabry disease: clinical manifestations and impact of disease in a cohort of 98 hemizygous males." *Journal of medical genetics* 38.11 (2001): 750-760.
6. MacDermot, K. D., A. Holmes, and A. H. Miners. "Anderson-Fabry disease: clinical manifestations and impact of disease in a cohort of 60 obligate carrier females." *Journal of medical genetics* 38.11 (2001): 769-775.
7. Paskalev, E., et al. "Fabry disease." *Meditinski Pregled/Medical Review* 47.4 (2011): 15-21.
8. Gambini, Gloria, et al. "Ophthalmic Manifestations in Fabry Disease: Updated Review." *Journal of Personalized Medicine* 13.6 (2023): 904.
9. Pieroni, Maurizio, et al. "Cardiac involvement in Fabry disease: JACC review topic of the week." *Journal of the American College of Cardiology* 77.7 (2021): 922-936.
10. Beck, Michael. "Demographics of FOS—the Fabry outcome survey." *Fabry disease: perspectives from 5 years of FOS* (2006).
11. Umer, Muhammad, and Dinesh K. Kalra. "Treatment of Fabry Disease: Established and Emerging Therapies." *Pharmaceuticals* 16.2 (2023): 320.
12. Yoo, Han-Wook. "Fabry disease: current treatment and future perspective." *Journal of Genetic Medicine* 20.1 (2023): 6-14.
13. Lee CL, Lin SP, Niu DM, Lin HY. Fabry Disease and the Effectiveness of Enzyme Replacement Therapy (ERT) in Left Ventricular Hypertrophy (LVH) Improvement: A Review and Meta-Analysis. *Int J Med Sci.* 2022 Jan 1;19(1):126-131.
14. Dominique P. Germain, Michael Arad, Alessandro Burlina, et al. The effect of enzyme replacement therapy on clinical outcomes in female patients with Fabry disease – A systematic literature review by a European panel of experts. *Molecular Genetics and Metabolism.* 2019(3): 224-235.
16. Arends, Maarten, et al. "Agalsidase alfa versus agalsidase beta for the treatment of Fabry disease: an international cohort study." *Journal of Medical Genetics* 55.5 (2018): 351-358.
17. Kampmann, Christoph, Amandine Perrin, and Michael Beck. "Effectiveness of agalsidase alfa enzyme replacement in Fabry disease: cardiac outcomes after 10 years' treatment." *Orphanet journal of rare diseases* 10 (2015): 1-7.
18. Tsuboi, Kazuya, and Hiroshi Yamamoto. "Clinical course of patients with Fabry disease who were switched from agalsidase- β to agalsidase- α ." *Genetics in Medicine* 16.10 (2014): 766-772.
19. Nowak, A.; Dormond, O.; Monzambani, V.; et al. Agalsidase- should be proposed as first line therapy in classic male Fabry patients with undetectable -galactosidase A activity. *Mol. Genet. Metab.* 2022, 137, 173–178.
20. Mauhin, W.; Lidove, O.; Amelin, D.; et al. Deep characterization of the anti-drug antibodies developed in Fabry disease patients, a prospective analysis from the French multicenter cohort FFABRY. *Orphanet J. Rare Dis.* 2018, 13, 1–12.
21. Aerts, Johannes M., et al. "Elevated globotriaosylsphingosine is a hallmark of Fabry disease." *Proceedings of the National Academy of Sciences* 105.8 (2008): 2812-2817.

DDIMERS - A POWERFUL TOOL IN THE DIAGNOSIS OF AORTIC DISSECTION

Jovanoski M^{1,2}, Nikolovski R¹, Bojovski I^{1,2}, Petkovski D^{1,2}, Boshev M^{1,2}, Georgiev A^{1,2}

¹ University Clinic for Cardiology, 1000 Skopje, Republic of North Macedonia

² Faculty of Medicine, Ss. Cyril and Methodius University University, Skopje, Republic of North Macedonia

ABSTRACT

Introduction: Acute aortic syndrome is one of the most life threatening cardiovascular conditions besides acute coronary syndrome and pulmonary embolism. Fifty percent of all the patients with aortic dissection do not survive for surgery or other therapeutic procedure to be performed and they experience a lethal end. D dimers although are a marker with a low specificity and sensitivity they can help us and guide us to make the right diagnosis.

Aim: Using d dimers to raise the suspicion for acute aortic dissection and using the triple chest pain CT angiography protocol to confirm the right diagnosis.

Case report: This series of case reports are about a few patients that presented in the emergency department with either a chest or back pain which was radiating to different body regions (including the lumbal region and the abdominal area). As these symptoms can sometime overlap and manifest as different acute cardiovascular syndromes, which can lead to increased morbidity and mortality, a CT angiography was performed after the regular noninvasive, low cost echocardiography was done to potentially find a possible diagnosis and show us the right diagnostic path. D dimers were also examined in all of the patients and increased level was found in all of the above mentioned. Aortic dissection (Stanford A or B) was the final diagnosis in all of them, every single patient requiring a different therapeutic approach.

Conclusion: D dimers in combination with a good clinical examination can be a perfect tool to raise the suspicion for acute aortic syndrome and after performing a triple chest pain protocol with CT angiography we can confirm and treat the diagnosis which requested a hospital admission.

Key words: aortic dissection; d dimers; diagnosis; treatment; triple chest pain protocol.

Introduction

D dimers is a fibrin degradation product as a result of a fibrin breakdown during fibrinolysis which happens in blood clots by enzymatic activation of plasminogen to plasmin (1). The most common cardiovascular symptoms as leading reasons for death in the field of cardiology such as acute coronary syndrome, acute aortic syndrome and pulmonary embolism which share a similar mechanism of forming a blood clots in different vascular segments can all lead to an increase in the level of d dimers. However we should be familiar with the fact that in contrast to high sensitivity troponin I and T as a marker for myocardial injury, d dimers have a much lower sensitivity index and therefore we cannot use it to confirm a specific diagnosis. High sensitivity troponin is a very specific and sensitive marker when it comes to myocardial injury, but not every increase in this parameter, especially not the one without significant time related changes in its level (during the first, second and third hour after the first sample was taken) means that acute coronary syndrome is the diagnosis responsible for this event. Many other conditions can lead to myocardial injury (including cardiovascular or non-cardiovascular origin) (2).

The symptoms with whom the patient is presenting and the laboratory findings are not enough to close the scenario. Non invasive and invasive (bedside or non-bed side) diagnostic procedures are of great value for further evaluation. As we have known for many years, CT angiography of the pulmonary arteries is the gold standard for diagnosing pulmonary embolism, a recently studied protocol which gained much attention in the last few years and is described in the latest guidelines for chronic coronary syndrome , was the triple chest pain protocol by CT angiography of the chest for confirming/excluding three main cardiovascular pathologies such as acute coronary syndrome, acute aortic syndrome and pulmonary embolism (3) in patients with atypical chest pain and low to intermediate risk. That is why clinical suspicion in combination with all the available laboratory biomarkers, ecg interpretation and echocardiography and CT can make a fast diagnosis available if we use them wisely.

As we know acute coronary syndrome is the main reason for death worldwide (especially in the field of cardiovascular diseases), pulmonary embolism comes as third in morbidity and mortality from all the cardiovascular pathologies and acute aortic syndrome is a pathology can be life threatening with almost 50% not surviving before the lifesaving procedure (TEVAR or a surgical one) can be performed.

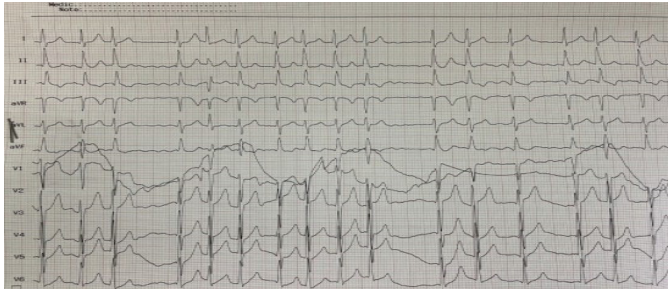
That is why we should be well aware about these conditions and be able to quickly recognize them in order for the patient to get the right treatment in the right time.

Case report number 1

This case report is about a 47 years old patient who presented in our emergency department with an acute onset of back pain starting an hour ago, which was radiating trough the lumbal region and the lower chest. He described the pain as severe and ripping, he couldn't seat on the chair because of it and was even harder to lay down for us to perform an ecg. From previous diseases he reported about having a hypertension (not regulated), already on two types of antihypertensive medications, including an ARB (tbl. valsartan 160mg o.d) plus calcium antagonist (tbl. Lercanidipine 20mg o.d). He denied any other previous health conditions. He didn't have any history of cardiovascular diseases in the family. He was a regular smoker, consuming a pack of cigarettes per day.

Physical examination showed a high normal blood pressure (140/90mmHg on both hands). He looked pale, sweaty and defocused from the high intensity of pain. ECG was performed right away which showed an atrial fibrillation with a HR around 130/min, without any deviations in the ST segment. S wave in lead I, q wave in lead III and an inverted T wave in lead III (S1Q3T3) can be seen on this ecg (Figure 1), which could easily guide the physician to think about a pulmonary embolism as a possible diagnosis (taking the fact that the heart rate was also high).

Figure 1. ESC showing atrial fibrillation as a leading rhythm at a heart rate around 130bpm

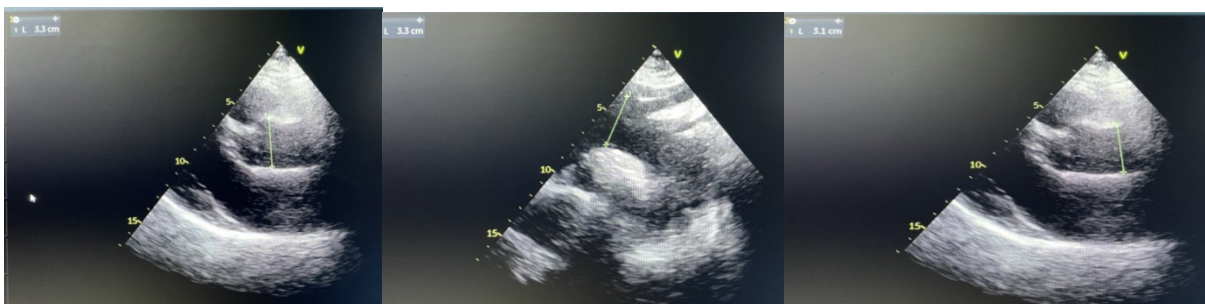


A triple rule in/out protocol for chest pain was a must in this patient, so we decided to take a quick blood sample from our patient for high sensitive troponin I and d dimers. Half an hour later, results came in with a normal troponin values, but an extremely high values of d dimers >10.000.

Echocardiography was a reasonable next step, so we immediately performed it.

Normal function of the left and right ventricle, also the other cavities, with a good ejection fraction, normal dimensions of the aorta in the visible regions of the echocardiographic window (Figure 2), including the aorta in its proximal region, the ascending aorta from the parasternal window, the aortic arch and the abdominal aorta.

Figure 2. Echocardiographic findings



Right ventricular function was completely normal with a mild tricuspid regurgitation present. Since no obvious diagnosis was obtained by the first results, we had to move forward. The patient was feeling worse and the pain was increasing.

We decided to lower the heart rate by giving beta blocker (tbl Metoprolol 100mg) plus intravenous bolus injection of Digoxin, plus tried to reduce the pain by giving an intramuscular injection of diazepam and tramadol. Then we quickly sent the patient for a CT angiography for a tri-

ple chest pain protocol to rule in/out any of the possible diagnosis (Acute coronary syndrome/ aortic dissection/pulmonary embolism).

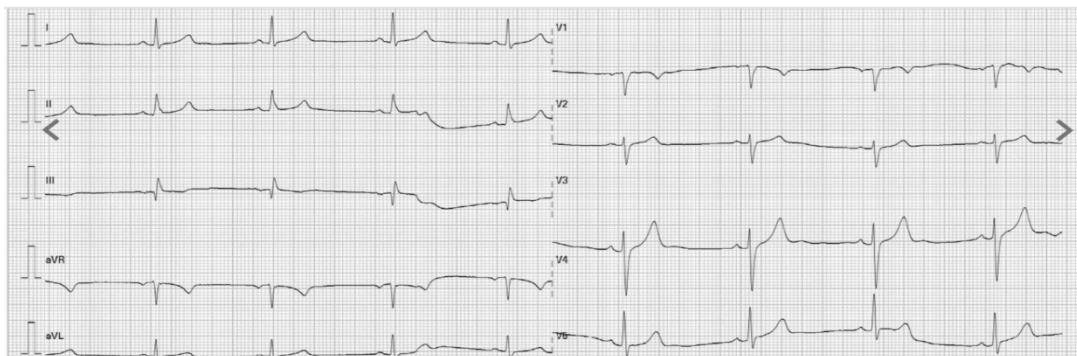
The CT angiography showed a Stanford B dissection of the aorta starting below the subclavian artery forming two separate lumens. The false lumen was affecting the left renal artery causing a stenosis with ischaemia of the left kidney, with a tendency to form a clot inside. The dissection flap was all the way to the left common iliac artery. Other branches were not involved in the false lumen.

The diagnosis was made. Although it wasn't a Stanford A dissection, we concluded that a complicated Stanford B dissection involving the renal artery resulting with an ischaemia of the left kidney was an urgency and the patient was immediately sent to a cardiac surgery and in the process we bypassed the intensive care unit so we could save this patient some time.

Unfortunately the patient was brought back in our hospital after being examined by a cardiac surgeon who decided not to operate the patient. He recommended a further hospitalization in the department of cardiology and a TEVAR procedure. So the patient was finally admitted in the ICU.

Few hours after the patient presentation, again an ecg was performed (Figure 3). The patient was now in sinus rhythm, with a good heart rate (around 50 bpm).

Figure 3. ECG after an optimal heart rate management with a leading sinus rhythm



His blood pressure was normal and the pain has decreased.

During the first day of hospitalization we optimized the blood pressure, rhythm and heart rate therapy, plus we applied an extra analgetics because of episodes of severe back pain. A heart team was necessary including an interventional cardiologist and a cardiac surgeon. The first admission laboratory results came in and other than a slightly increased creatinine (around 120), everything else was in reference values.

Despite the optimal medical treatment the patient was struggling with a frequent episodes of pain mostly in the lumbal region and a frequent applications of opioid was needed for the pain menagment. Two days later, after a continuous follow up of an eventual laboratory markers changes that would suggest an organ ishaemia related to the flap who was indangering the side branches of the aorta, mostly the renal arteries, increased biomarkers for the renal function

evaluation were spotted, with creatinine levels going double then the ones on admission. TEVAR was definitely the only option left for this patient, so after we heard the opinion of the cardiac surgeons and after we have tried the optimal medical option as a possible solution, we indicated a TEVAR procedure. But first he was transferred to the department of cardiac surgery for a carotid-subclavian bypass procedure so we can ensure that the landing zone for the TEVAR procedure is optimal. Both of the procedures were done, without having the patient experiencing any complications. After the procedures were over, the patient was feeling much better, he only had a mild pain and discomfort and most importantly his creatinine levels returned to normal referent values. Control evaluation of the surgical wound was done in the last days of his stay and finally he was released from hospital in a stable health condition with the recommendation for regular follow up, strict blood pressure and heart rate control.

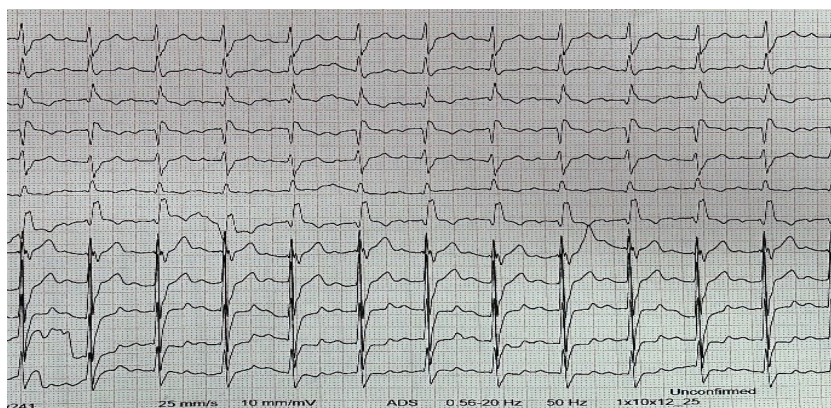
A regular follow up from a cardiologist and cardiac surgeon was advised and a control CT angiography of the aorta was the next step which revealed a perfectly inserted endovascular device without any complications. The patient was in a very good shape after a few months of the procedure.

Case report number 2

Our next patient is a 65 years old patient, admitted because of a typical chest discomfort which was radiating in the back and in the lumbal region. It started few hours ago and he described it with a moderate severity. He denied having any similar symptoms before. Other than that, he mentioned that he had a long period of uncontrolled hypertension and he refused to take the therapy which was given by his physician. Although he was constantly having a grade III hypertension, he didn't complain about having any symptoms connected to the high blood pressure. As he came in the emergency department, we measured a very high levels of BP at around 220/130 mmHg (without significant difference in both of his hands). He denied previous medical conditions and he didn't report any family diseases. He was a non smoker.

An ecg was the first step to our differential diagnosis. A sinus rhythm was the leading rhythm and morphology of right bundle branch block was spotted on the electrocardiogram. There was a right axis deviation (including a S1Q3T3 pattern) with a slightly increased heart rate at around 102 bpm (Figure 4).

Figure 4. ESC with sinus rhythm at a heart rate of 102bpm and a right bundle branch morphology



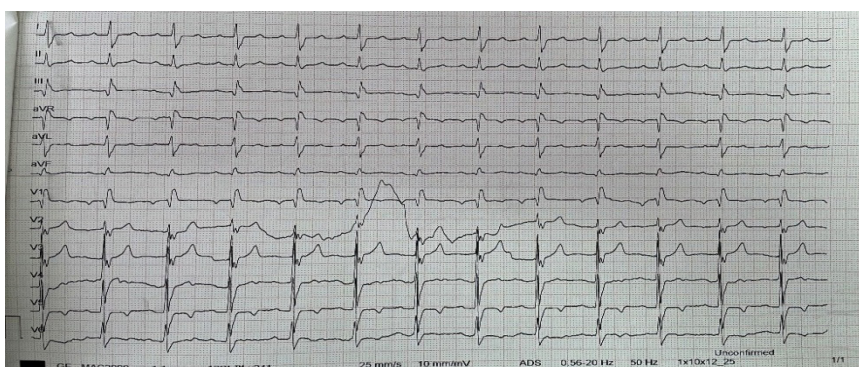
Since there was no previous ecg to compare it with the new one and we didn't know if it was a new bundle branch block or an old one, we suspected for either acute coronary syndrome or pulmonary embolism. However, no previous risk factors for venous thrombembolism were found from a previous medical history of the patient. The uncontrolled hypertension could also have been the reason for the symptoms mentioned above. So the first step was for us to analyze the high sensitivity troponin levels in the blood and to exclude acute coronary syndrome as a possible cause. Results came in half an hour later, and hsTnI was slightly elevated – 70ng/L (normal values for men are less than 34 ng/L). These values could easily have been due to the hypertensive urgency, so we were still not sure if we had the right diagnosis.

Echocardiogram was the next logical step to fill in the puzzle. We had our focus on the main findings of chest pain. Aorta diameters were normal, no regurgitation was present. Right ventricle was perfectly normal, with a normal right ventricle function. There were no wall motion abnormalities other than the basal segment of the inferior wall. The ejection fraction was calculated at around 55%. We admitted the patient in the ICU for further treatment and evaluation.

A coronary angiography was a reasonable next step. In the meanwhile, we took another blood sample 3 hours after the previous one and the result was 150ng/L. The angiography showed a narrowed LAD in all of its segments (the proximal part was with an intermediate plaque, the medial segment was with a plaque – a stenosis between 30-50%, and the distal LAD had a stenosis of around 95%). The interventional cardiologist decided to stent the distal LAD.

Our patient was monitored for 24 hours in the ICU, he was clinically stable for that period and then he was transferred in a regular room. During the next few days he described a mild discomfort in the chest and in the back and we thought it was nothing acute. Few ecgs were made during chest pain without changes comparing it to the old ones (Figure 5).

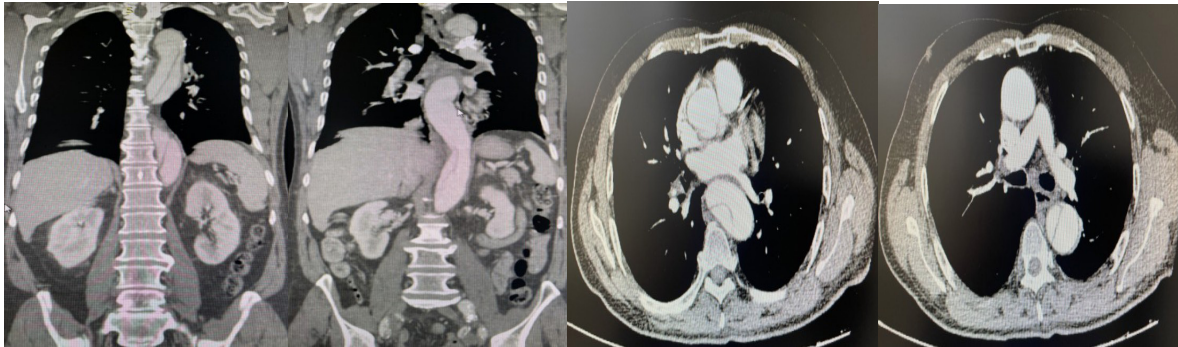
Figure 5. ESC made during the second day of hospitalization with sinus rhythm at a heart rate of 78 bpm and right bundle branch morphology



The symptoms were persisting on the third day of hospitalization so we had to think of another possible etiology. A control echocardiogram didn't show any changes (our thoughts were on an acute pericarditis). Giving the fact that the first ecg involved pulmonary embolism as a potential underlying pathology, we decided to take another blood sample for d dimers and the results came in extremely increased (around 9000ng/ml).

So we had to perform the gold standard for chest pain and find the real reason behind these symptoms. Pulmonary arteries were clean, not showing any filling defects. However, an aortic dissection (Stanford B) starting below left subclavian artery continuing through the descending aorta and the abdominal aorta, all the way to the both iliac arteries (Figure 6). A diagnosis was finally made.

Figure 6. *CT angiography findings*



The pain was again described as mild and the laboratory findings were normal (including creatinine and LDH levels). There were no organs involved with an ischaemia which were supplied from the arteries coming out of the abdominal aorta, the pain was almost fully regulated with the perfect blood pressure control (at around 120/70mmHg) and a heart rate between 70-80 bpm, reducing the wall stress of the aorta. So, we decided to go with an optimal medical treatment, not referring this patient for surgery or TEVAR procedure.

He was stable until the 3th day of hospitalization, when a new symptom occurred. The patient was not feeling his left leg and he had trouble moving it, so when he tried to stand up from his bed, he fell down on the floor without losing consciousness. He had a complete loss of sensibility of his left leg and the motor function was also affected. Cardiac surgeon was consulted immediately and after seeing the CT angiography and performing a physical exam we transferred the patient for an immediate cardiac surgery at their department. It was a successful one. A bypass procedure connecting the two femoral arteries (cross over) was performed. After surgery the patient had a fully recovered motor function of the lower left extremity and a special focus was on the potential blood loss due to the fact the patient was covered with a triple therapy containing two antiplatelet medications plus an anticoagulant.

Hemoglobin was stable during the following days and the patient was discharged few days later. He came up for a regular check up one month later and he was feeling good and symptoms free. A control CT angiography of the aorta was performed few months later and the findings were very similar to the first one (the Stanford B dissection had undergone just an optimal medical treatment). The patient was physically active in the following period, he was riding his bike on a daily basis without experiencing symptoms like chest pain, fatigue or leg pain.

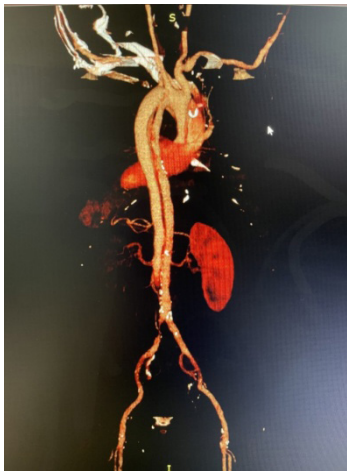
Case report number 3

Our third patient was the most dramatic one. Things were happening really fast. He was admitted in our emergency center with a hypertensive crisis and a blood pressure at 250/120mmHg.

He was screaming in pain which started early in the morning and wasn't resolving with any analgetics. It irradiated into the back and lumbal region, describing it literally as a knife tearing through the chest and back. He was only treated for high blood pressure in the past, not reporting any other medical conditions and he wasn't on any supplements or medications which could affect his condition. He was a non smoker. On the physical exam everything was normal, even blood pressure was almost the same in the both hands. Electrocardiogram ruled out transmural myocardial infarction, so while we were waiting for the echocardiographer for a focus echo of the heart, we admitted the patient in the ICU and took a blood sample for high sensitivity troponin and d dimers and we sent the patient for an urgent CT angiography of the lungs with the main focus on the aorta – we used the triple chest pain protocol CT to exclude the three most dangerous clinical scenarios, pulmonary embolism and aortic dissection besides acute coronary syndrome.

After 15 minutes the patient had a cardiac arrest and cardiac pulmonary resuscitation was performed and a focus echo was made which revealed a huge pericardial effusion. Laboratory results came in with a normal high sensitivity troponin and increased level of d dimers at around 5000 ng/ml. The results were quickly followed by the CT result showing a Stanford A dissection starting from the aortic root all the way to the left common iliac artery, affecting the mesenteric, celiac and renal arteries (Figure 7).

Figure 7. *CT angiography findings*



Cardiac surgeon was present during the CPR, but unfortunately it was too late to operate. Death was the final outcome in this 52 year old patient.

Discussion

Acute chest pain is a very recognizable symptom in the field of cardiology. Mostly it associates us with acute coronary syndrome, but other forms of acute cardiovascular pathology can present mainly with a chest discomfort, including acute aortic syndrome, pulmonary embolism, all forms of arrhythmia with a fast heart rate etc. The first tool to realize what is hiding behind the patient symptoms is to perform an ecg which can sometimes confirm the right diagnosis and give us the right answer. However we should always suspect about a pathology hidden behind the ecg and let the clinical picture of the patient lead the way.

The triage we make in our emergency department allows us to also have a few fast laboratory markers which we can use if we have a differential diagnosis dilemma. As such, an easily performed blood draw in combination with a quickly measured high sensitivity troponin, d dimers and N terminal pro BNP can be the second tool used for the true diagnosis.

Firstly we are going to focus on d dimers. Although a parameter which has a pretty low specificity at around 56%, the level of sensitivity at around 97% and a negative predictive value at around 96%, can be used in combination with other diagnostic procedures to confirm or exclude the reason for chest pain especially in patients with low or intermediate probability for aortic dissection or pulmonary embolism as described by Kathrin Hahne et al.(1).

On the other hand, high sensitivity troponin has a much better specificity regarding myocardial injury. However its specificity is somewhere lower when it comes to diagnosing acute myocardial infarction since many other conditions can lead to an increase in hsTn levels such as (tachyarrhythmias, heart failure, kidney disease, anemia etc.) (2).

A final diagnosis is a combination of a well performed physical examination plus a good interpretation of the ecg, with laboratory parameters and diagnostic procedures completing the process. That is why our next step was to make an echocardiography in these patients to exclude direct or indirect signs for pulmonary embolism, ACS and AAS. As a final diagnostic approach a triple rule out protocol for chest pain is needed as a confirmation for our suspicion. Although a very expensive tool, with a high rate of radiation as mentioned in the article by Hwa Yeon Lee it can be necessary in some cases when the suspicion is high in order to save the patient's life (3). The ecg on some of these patients was normal, others had an atrial fibrillation with a fast heart rate and others had a change in the morphology of the qrs complex and a right bundle branch morphology.

Newly recognized RBBB in combination with fast heart rate (either a sinus rhythm or some kind of supraventricular arrhythmia) followed by high levels of d dimers can make us sometimes focus more on pulmonary embolism as primary cause than AAS. In an article by Duncan Thomson 20-25% of the patients had a normal ecg, and the other electrocardiographic abnormalities were some of the mentioned in our patients (4). But we have to remember that chest pain was the dominant symptom in our patients rather than dyspnea and fatigue. Also, no other risk factors from previous medical history were noted to make a strong association between our patients and pulmonary embolism as their final diagnosis. None of the mentioned risk factors for venous thromboembolism in the article by Frederick A. Anderson Jr and Frederick A Spencer were part of our patient's medical history. So the probability was low for VTE (5).

As we mentioned above d dimers were the main weapon we used to confirm or exclude acute aortic syndrome as possible reason for the clinical manifestation of the patients. In a study by Armaghan Y Soomro et al. D dimers were examined in various diseases. In some of the studies mentioned in this article, the increased level of d dimers corresponded with an increase of MACE in patients with acute coronary syndrome (6). The rate of in stent restenosis, prolonged length of hospital stay and adverse effects were higher in patients with higher values. Levels of d dimers also corresponded with the degree of dissection of the aorta in the same article, followed by worse prognosis of the patient.

A case-control study performed by Patirck Ohlmann confirmed that 99% of the patients with AAS confirmed during the hospitalization, at presentation had increased level of d dimers, reminding us about the high sensitivity of this essay, although the specificity of 34% was really modest. Again this study confirmed the degree of dissection extension in correlation with the level of d dimers (7). D-dimer was the only independent predictor of mortality in a study which consisted of 27 patients with confirmed aortic dissection type A as conclude by T. Weber et al. (8).

Finally a pooled meta analysis which consisted of 11 studies and 349 patients which had an aortic dissection confirmed the importance of d dimers in diagnosing AAS, once again confirming their high sensitivity in these patients and even more importantly excluding AAS as possible diagnosis in patient with negative d dimers and low probability for aortic dissection (9). In seven patients where d dimers were examined in the emergency department and had a final diagnosis of aortic dissection, all of them tested positive by latex agglutination (10). The patients from our series of cases also had increased d dimers measured on admission in our emergency department.

Three scenarios were presented in our case series with a three different therapeutic modalities and ways to solve this condition in a best possible way. The european guidelineses for acute aortic syndrome place the surgery as the one and only solution , as fast as possible performed in acute aortic dissection (Stanford A type). Kuroyanagi S et al. performed 320 such surgeries of a Stanford A dissection and they compared the short and long term complications in different sites of entry tear in these patients concluding minimally invasive procedures, such as stent-grafting, is the best method to treat these patients (11). Unfortunately our patient condition was deteriorating so fast we couldn't even get him to the operation table.

On the other hand Stanford B patients can be treated differently depending on the clinical scenario. Medical therapy regarding optimal puls and blood pressure control is an imperative, but if should go with TEVAR procedure or surgery and in which phase decides the complications of the dissection. Alfson and Ham in their article and confirmed by the latest guidelines for AAS refer the complicated Stanford B dissections to an urgent TEVAR, while the ones without complications and signs of organ malperfusion receive TEVAR in the subacute phase (12). Our patient was with an acute renal ischaemia which required an urgent procedure.

Surgery has a 2B class of recommendation when it comes to Stanford B aortic dissection and it is less often performed in the new era of TEVAR procedure. Medical treatment is also an option in a non complicated Stanford B dissection. Cooper M et al confirmed in their study (13) that medical treatment is better than open repair in these patients because of the high morbidity up to 31% when deciding to go for an open repair, although the morbidity and mortality in the medical treated group is also with a high percentage.

Conclusion

The most urgent causes of chest pain in the emergency department that we must think of are acute coronary syndrome, aortic dissection and pulmonary embolism with an extremely high mortality rate. The literature says that 50% of patients with aortic dissection die in the first 48

hours of presentation. That is why we have to bring fast and solid decisions while evaluating a patient for a chest pain.

Although the CT angiography for a triple chest pain protocol is a gold standard to differentiate these conditions, d dimers (as less sensitive and specific laboratory finding) together with the highly sensitive troponin can be fast and powerful noninvasive tool to suspect these highly morbid cardiovascular diseases and treat them right in the right time.

References

1. Hahne K, Lebiez P, Breuckmann F. Impact of d-Dimers on the Differential Diagnosis of Acute Chest Pain: Current Aspects Besides the Widely Known. *Clin Med Insights Cardiol.* 2014 Oct 19;8(Suppl 2):1-4. doi: 10.4137/CMC.S15948. PMID: 25392700; PMCID: PMC4216819.
2. Marini MG, Cardillo MT, Caroli A, et al. Increasing specificity of high- sensitivity troponin: new approaches and perspectives in the diagnosis of acute coronary syndromes. *J Cardiol.* 2013 Oct;62(4):205-9. doi: 10.1016/j.jjcc.2013.04.005. Epub 2013 Jun 17. PMID: 23787156.
3. Lee HY, Yoo SM, White CS. Coronary CT angiography in emergency department patients with acute chest pain: triple rule-out protocol versus dedicated coronary CT angiography. *Int J Cardiovasc Imaging.* 2009 Mar;25(3):319-26. doi: 10.1007/s10554-008-9375-4. Epub 2008 Oct 14. PMID: 18853277.
4. Thomson D, Kourounis G, Trenear R, et al. ECG in suspected pulmonary embolism. *Postgrad Med J.* 2019 Jan;95(1119):12-17. doi: 10.1136/postgradmedj-2018-136178. Epub 2019 Jan 21. PMID: 30665906.
5. Anderson FA Jr, Spencer FA. Risk factors for venous thromboembolism. *Circulation.* 2003 Jun 17;107(23 Suppl 1):I9-16. doi: 10.1161/01.CIR.0000078469.07362.E6. PMID: 12814980.
6. Soomro AY, Guerchicoff A, Nichols DJ, et al. The current role and future prospects of D-dimer biomarker. *Eur Heart J Cardiovasc Pharmacother.* 2016 Jul;2(3):175-84. doi: 10.1093/ehjcvp/pvv039. Epub 2015 Sep 27. PMID: 27533759.
7. Ohlmann P, Faure A, Morel O, et al. Diagnostic and prognostic value of circulating D-Dimers in patients with acute aortic dissection. *Crit Care Med.* 2006 May;34(5):1358-64. doi: 10.1097/01.CCM.0000216686.72457.EC. PMID: 16557157.
8. Weber T, Rammer M, Auer J, et al. Plasma concentrations of D-dimer predict mortality in acute type A aortic dissection. *Heart.* 2006 Jun;92(6):836-7. doi: 10.1136/hrt.2005.072959. PMID: 16698837; PMCID: PMC1860671.
9. Marill KA. Serum D-dimer is a sensitive test for the detection of acute aortic dissection: a pooled meta-analysis. *J Emerg Med.* 2008 May;34(4):367-76. doi: 10.1016/j.jemermed.2007.06.030. Epub 2008 Jan 18. PMID: 18207693.
10. Perez A, Abbet P, Drescher MJ. D-dimers in the emergency department evaluation of aortic dissection. *Acad Emerg Med.* 2004 Apr;11(4):397-400. doi: 10.1197/j.aem.2003.10.030. PMID: 15064216.
11. Kuroyanagi S, Higashiue S, Komooka M, et al. [Treatment Strategy for Stanford Type A Acute Aortic Dissection]. *Kyobu Geka.* 2020 Aug;73(8):563-571. Japanese. PMID: 32879281.

12. Alfson DB, Ham SW. Type B Aortic Dissections: Current Guidelines for Treatment. *Cardiol Clin.* 2017 Aug;35(3):387-410. doi: 10.1016/j.ccl.2017.03.007. Epub 2017 May 26. PMID: 28683909.
13. Cooper M, Hicks C, Ratchford EV, et al. Diagnosis and treatment of uncomplicated type B aortic dissection. *Vasc Med.* 2016 Dec;21(6):547-552. doi: 10.1177/1358863X16643601. Epub 2016 Apr 28. PMID: 27126951.

ACUTE PULMONARY EDEMA ASSOCIATED WITH INTRAVASCULAR ABSORPTION (OHIA) SYNDROME DURING OPERATIVE HYSTEROSCOPY

Gunaydin DB, Erel S Koksall N, Buyukgebiz Yeşil BM, Emmez G

Department of Anesthesiology & Reanimation, Gazi University School of Medicine, Ankara, Besevler 06500, Turkey

ABSTRACT

During operative hysteroscopies, hemodilution by absorption of distention fluids is one of the most feared complications. Resulting hyponatremia due to hemodilution with respiratory distress associated with pulmonary edema, and subsequent cardiovascular collapse may occur. In this case report, we aimed to present management of acute pulmonary edema developed in a 45-years old ASA II woman scheduled to undergo operative hysteroscopy under general anesthesia.

Key Words: *anesthesia, hysteroscopy, intravascular absorption (OHIA) syndrome, pulmonary edema.*

Introduction

Operative hysteroscopy, which is a commonly used surgical approach for performing submucosal myomectomy, might be rarely complicated with potentially life-threatening intravascular absorption (OHIA) syndrome (1, 2). The OHIA is caused by the absorption of hypo-osmolar distension/ irrigation fluids during hysteroscopy, which can lead to rapid hyponatremia and subsequently to cerebral and/ or pulmonary edema (1). The OHIA syndrome is referred to as gynecological transurethral resection of the prostate (TURP) syndrome due to the similarities in its mechanism, pathogenesis, clinical manifestation, and treatment (1, 2). Herein, we report management of severe pulmonary edema recognized during emergence from anesthesia due to use of perioperative excessive irrigation fluid in patient underwent hysteroscopic resection of a submucosal large leiomyoma.

Case Presentation

Informed consent was obtained from the patient for this case report. A 45-years-old ASA II woman with 57kg weight and 158cm height was scheduled to undergo operative hysteroscopy for the submucosal leiomyoma under general anesthesia. In the preoperative evaluation, it was found that the patient had previous uneventful cesarean section under spinal anesthesia. In her medical history she had COVID infection twice. Patient was a smoker (5-6 cigarettes/ day) and she has been receiving fosinopril/ hydrochlorothiazide (10mg/ 12.5mg) once a day as an antihypertensive for the last 5 years and has been using budesonide/ formoterol (160mcg/ 4.5mcg) occasionally when needed. In the laboratory examination, preoperative complete blood count, liver and kidney function tests, serum electrolytes and coagulation profile (prothrombin time, and activated partial thromboplastin time) were within normal clinical range. The patient's ECG was sinus rhythm, and the heart rate (HR) was 72bpm. There was no remarkable abnormal finding in the preoperative chest X-ray (Figure 1).

On admission to the operating room, standard monitorization was performed which revealed blood pressure of 130/80 mmHg, HR of 78 bpm, and SpO₂ of 98%. After establishing an intravenous (IV) route to administer saline, general anesthesia was induced with IV 1mg/kg of lidocaine, 2.5mg/kg of propofol, and 0.1mcg/kg/min remifentanyl infusion and then laryngeal mask airway (LMA) size number 3 was placed uneventfully. During the operation, the patient received approximately 2% sevoflurane in 50% air-oxygen mixture during remifentanyl infusion to maintain anesthesia. Before the end of the procedure, which lasted approximately 2.5 hours, 1 gram (g) of IV paracetamol was given for postoperative analgesia. After removing the LMA, the patient could not be ventilated adequately. Acutely developed severe bronchospasm was suspected and treated with 100% oxygen breathing via face mask. Because of evident desaturation in the SpO₂ tracing, the case was rapidly intubated and treated with IV infusion of 0.2g of theophylline/ 100mL and 4mg of IV dexamethasone. Meanwhile, pink-reddish foamy sputum from the patient's mouth-nose/ endotracheal tube was observed, and acute pulmonary edema associated with OHIA syndrome was became apparent since almost 12 liters of mannitol 5% (Resectisol, Kocak Farma, Turkey) had been used to excise the relatively large leiomyoma with an approximately 5cm diameter during the procedure. Thus, 20mg of IV furosemide was immediately administered and a urinary catheter was inserted. After 20 minutes follow-up, when the patient started to ventilate with a sufficient tidal volume and she was extubated, she opened her eyes and woke up. Afterwards she was admitted to the recovery unit, where she was kept for an hour and then transferred to the gynecology ward for further follow up and monitoring for 1 day postoperatively. According to the records sodium level showed a decline trend perioperatively from 141mEq/L to 137mEq/L and subsequently 135mEq/L and she received almost 1.5 liter 0.9%NaCl infusion perioperatively. No significant difference was observed between the chest X-rays (Figure 1 and 2). The laboratory findings on discharge demonstrated: sodium of 138mEq/L, potassium of 3.7mEq/L, chloride of 100mEq/L, and hemoglobin of 12g/dL.

Figure 1. Preoperative Chest X-Ray

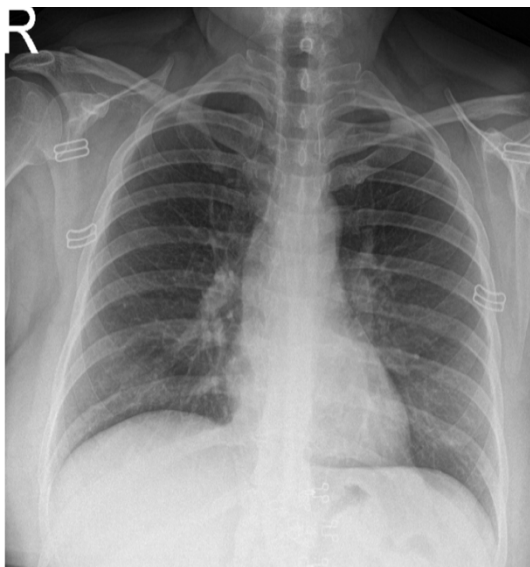
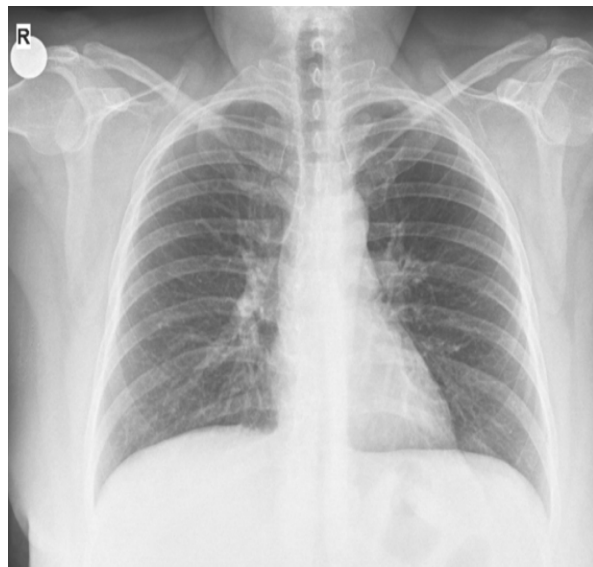


Figure 2. Postoperative Chest X-Ray



Discussion

In this case report, we presented the management of acute pulmonary edema complication of OHIA syndrome in a 45-years-old ASA II woman who underwent operative hysteroscopy under general anesthesia using LMA.

Hysteroscopy, despite being a minimally invasive procedure, can result in uterine perforation, hemorrhage, infection, insufficient resections or fluid load associated OHIA syndrome (3). Hereby, as soon as suspecting pulmonary edema associated OHIA syndrome resulting from the absorption of a large amount of hypo-osmolar distension/ irrigation fluid that have been used unintentionally for resection of a large myoma via hysteroscopy, treatment was started immediately since mortality risk of clinically significant OHIA syndrome has been reported to be as high as 25% (4).

The primary cause of hyponatremia during hysteroscopy is the absorption of fluid into the vascular space, known as intravasation, where the pressure of the distension media plays a critical role. In a study involving 250 operative hysteroscopy procedures, maintaining intrauterine pressure below 80mmHg was without significant fluid absorption (5). In our present case, the pressure was kept at 80mmHg, and the lowest sodium level was 135meq/L.

During a hysteroscopy performed under general anesthesia, early symptoms of excessive fluid intake may be masked. Symptoms such as bradycardia, hypotension, oxygen desaturation, elevated peak airway pressures, and decreased end-tidal carbon dioxide (6). Currently, none of these symptoms were present perioperatively except oxygen desaturation encountered immediately after removing LMA. The delayed awakening, shortness of breath, and pink foamy sputum led us to intubate our patient and administer bronchodilator, corticosteroid and diuretic.

Regarding the choice of regional anesthesia, since the patient is awake and conscious it may seem to be safer and more advantageous to recognize early warning signs to diagnose the syndrome. However, a notable increase in fluid absorption during hysteroscopy could occur under epidural anesthesia because of the epidural anesthesia associated vasodilation of the pelvic vessels and sympathetic block (7). In our institution we mostly prefer general anesthesia using LMA, like we did for the present case. But this time the procedure was much longer than expected because of the size of the leiomyoma.

Hyponatremia has been observed in hysteroscopy procedures when using certain nonconductive fluids for irrigation and distension, such as 1.5% glycine, 3% sorbitol, 5% mannitol and 5% dextrose (6,8). Our routine irrigation fluid was mannitol 5% which has the potential to induce hyponatremia and hypervolemia as a result of its hypo-osmolar properties. Although asymptomatic hyponatremia does not require immediate intervention, severe hyponatremia necessitates prompt treatment to minimize potential complications (9). The sodium level decreased from 141meq/L to 135meq/L in our case and became symptomatic.

The management of hyponatremia involves various measures such as fluid restriction and administration of 3% saline, with correction rates typically limited to a maximum increase of 0.5mEq/L/h of sodium. This cautious approach aims to prevent the development of central pontine myelinolysis and aims to maintain the sodium concentration above 120mEq/L through serial monitoring. Diuretics, particularly frusemide, can correct fluid overload and promote sodium balance (10). In our case, we managed our patient with oxygen supplementation and IV frusemide, aminophylline and dexamethasone in the semi-fowler position. Our patient has predisposing factors such as smoking, past COVID infection twice, and receiving bronchodilator therapy occasionally for allergic asthma. We preferred to correct fluid overload by using diuretic, thus we maintained sodium balance as recommended.

Conclusion

In the present case report, management of acute pulmonary edema as a complication of OHIA syndrome during operative hysteroscopy has been revisited. Since hysteroscopy procedures may sometimes iatrogenic result in this catastrophic syndrome, extreme caution is required

to limit and actively monitor fluid intake regardless of the surgeon's persistency in continuing the procedure – to excise the pathologic tissue. Prompt recognition and treatment are crucial to counteract fluid overload and hyponatremia caused by the iatrogenic use of hypo-osmolar distension fluids.

References

1. Elegante MF, Hamera JA, Xiao J, et al. Operative Hysteroscopy Intravascular Absorption Syndrome Causing Hyponatremia With Associated Cerebral And Pulmonary Edema. *Clin Pract Cases Emerg Med* 2019; 3: 252-255. doi:10.5811/cpcem.2019.4.41878.
2. Hsieh MH, Chen TL, Lin YH, et al. Acute Pulmonary Edema From Unrecognized High Irrigation Pressure in Hysteroscopy: A Report of Two Cases. *J Clin Anesth* 2008; 20: 614-617. doi:10.1016/j.jclinane.2008.05.026.
3. Aas-Eng MK, Langebrette A, Hudelist G. Complications in operative hysteroscopy – is prevention possible? *Acta Obstet Gynecol Scand.* 2017; 96: 1399–1403.
4. Hahn RG. Fluid absorption in endoscopic surgery. *Br J Anaesth.* 2006; 96: 8-20. doi: 10.1093/bja/aei279.
5. Shirk GJ, Gimpelson RJ. Control of intrauterine fluid pressure during operative hysteroscopy. *J Am Assoc Gynecol Laparosc.* 1994;1: 229-233 doi: 10.1016/s1074-3804(05)81015-1.
6. Sethi N, Chaturvedi R, Kumar K. Operative hysteroscopy intravascular absorption: A bolt from the blue. *Indian J Anaesth.* 2012; 56 :179–182.
7. Goldenberg M, Cohen SB, Etchin A, et al. A Randomized Prospective Comparative Study of General Versus Epidural Anesthesia for Transcervical Hysteroscopic Endometrial Resection. *Am J Obstet Gynecol* 2001;184: 273–276. doi: 10.1067/mob.2001.108997.
8. Woo YC, Kang H, Cha SM, et al. Severe Intraoperative Hyponatremia Associated With The Absorption of Irrigation Fluid During Hysteroscopic Myomectomy: A Case Report. *J Clin Anesth* 2011;23: 649-652. doi: 10.1016/j.jclinane.2011.03.003.
9. Atieh AS, Abu Shamma OK, Abdelhafez MO, et al. Acute Severe Hyponatremia following Hysteroscopic Procedure in a Young Patient: A Case Report and Review of the Literature. *Case Rep Nephrol* 2021;20; 2021:7195660. doi: 10.1155/2021/7195660.
10. Chauhan R, Ganesan V, Luthra A. Operative hysteroscopy intravascular absorption syndrome: the gynecological transurethral resection syndrome. *J Obstet Anaesth Crit Care.* 2018; 8: 112-114. doi: 10.4103/joacc.JOACC_38_19.

SUPRAGLOTTIC AIRWAY DEVICE(IGEL) IN A ELEVEN MONTH OLD PATIENT WITH MULTIPLE NECK MASS AND ANTERIOR MEDIASTINAL MASS

Hernandez AG, Simpao AS

¹ *St. Luke's Medical Center, Quezon City, Philippines*

ABSTRACT

Anesthetic management of pediatric patients with mediastinal mass, poses a great challenge to anesthesiologists. Complications related to airway obstruction with the use of general anesthesia are frequent concerns. This case report describes the anesthetic management of an eleven-months old girl scheduled for lateral neck biopsy. This case is unique because supraglottic airway device and general anesthesia is not routinely used in this kind of patients because of fear of airway obstruction. This report adds to the limited number of cases where a supraglottic airway device and general anesthesia were applied without serious complications.

Key Words: anterior mediastinal mass, iGel, pediatric patient, supraglottic device

Introduction

Anesthetic management of pediatric patients with mediastinal mass, poses a great challenge to anesthesiologists. The masses may be large so it can cause trachea-bronchial compression which can compromise the ventilation. Another concern is great vessel compression, which may affect blood flow into and out of the heart causing superior vena cava syndrome. The objective of this report is to cite considerations regarding anesthetic management of a pediatric patient with mediastinal mass, putting emphasis on preoperative risk predictors, anesthetic technique, and the possible complications associated with the use of general anesthesia (GA).

Review of Related Literature

Pediatric mediastinal masses are the most common chest masses in children, with the anterior mediastinum being the most common site. Langerhans cell histiocytosis (LCH) is a group of idiopathic disorders characterized by the presence of cells with characteristics similar to bone marrow-derived Langerhans cells juxtaposed against a backdrop of hematopoietic cells, including T-cells, macrophages, and eosinophils (1). LCH is believed to occur in 1:200,000 children, but any age group can be affected, from infancy through adulthood (1).

Several reports have suggested preoperative predictors as a guide to predict anesthetic problems that may occur peri-operatively. Symptoms of airway and cardiovascular compression such as cough, stridor, dyspnea, orthopnea, postural dyspnea, cyanosis, neck vein engorgement, edema neck and upper extremities are considered as clear warning to avoid surgery (2).

Studies by Griscom and Wohl put emphasis on tracheal diameter as predictors of respiratory complications and suggested that patients with less than 50% of the predicted area, have higher risk of respiratory complications and recommended that these patients should not receive GA. In their study, tracheal cross-sectional area was measured in 130 normal children and described a formula to calculate the tracheal area as $\text{tracheal area} = \text{age in years} / 9, \text{ plus } 0.35\text{cm}^2$ for boys and girls up to the age of 14 years (3).

Studies by Turoff et al. and Piro AJ et al. utilized mediastinal thoracic ratio (MTR) as predictors of peri-operative respiratory risk complications. MTR is calculated by comparing the size of the mediastinal mass with the thoracic diameter. A patient with MTR of more than 50% has higher risk of perioperative respiratory complications (4). Another predictor by King et al. utilized "Mediastinal mass ratio" (MMR) as a maximum width of the mediastinal mass relative to the maximum width of the mediastinum, measured by the CT scan. They observed that children with small masses have no risk of anesthetic complications, whereas patients with MMR of more than 56% are associated with respiratory complications (5).

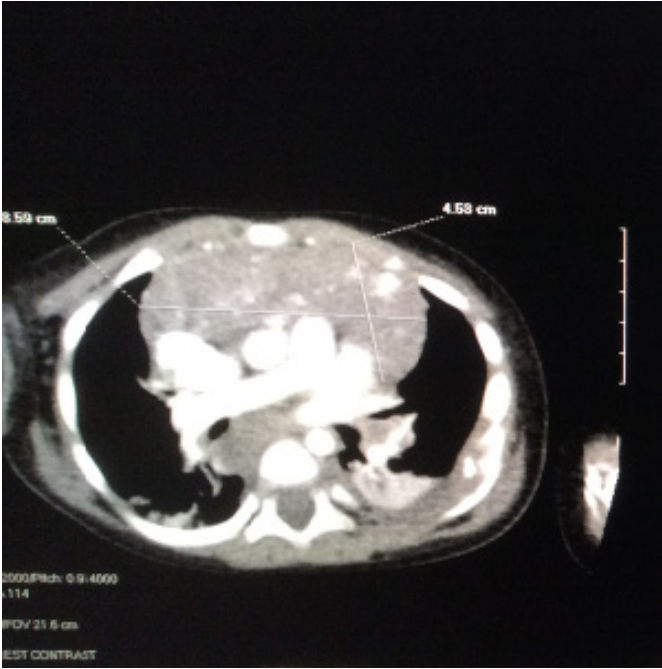
Pulmonary function study provides more objective data in identifying the high-risk patients. Shamberger et al. developed "Shamberger risk assessment box" to select the appropriate anesthetic technique. The parameters are a combination of peak expiratory flow rate (PEFR) (%predicted) and tracheal area (% predicted). With all these data, the case report would correlate and use this scope of knowledge in managing patients with mediastinal mass.

Case Presentation

This is a case of an eleven-months old girl diagnosed with anterior mediastinal mass who underwent lateral neck biopsy under general anesthesia. The patient was brought to our institution due to enlarging bilateral cervical neck mass. The patient weighs 9.7kg. Pertinent physical examination findings revealed airway MO 1 1/2 FB, TMD 1 1/2, MAL 3, enlarged lateral neck mass measuring 3x2cm on the right and 1.5x 4cm on the left, symmetrical chest expansion and clear breath sounds.

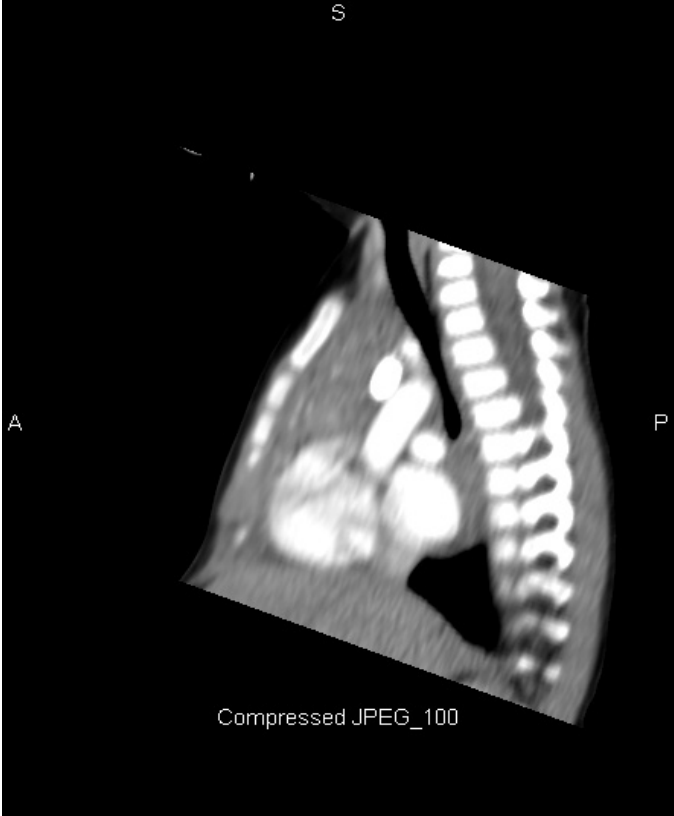Patient was scheduled for excision biopsy of lateral neck mass. Standard monitors were placed, and initial vital signs were stable. On induction, patient was positioned in a semi supine, moderate back rest position with intravenous access in the lower limb. The patient was given 1mg of Midazolam, 200 micrograms of Atropine, 10mg of Ketamine and 0.5micrograms/kg/hr of Dexmedetomidine. Sevoflurane 1% was started prior to insertion of the supraglottic airway device (iGel) size 1.5. Spontaneous respiration was maintained. Intraoperatively, a 2x2cm of whitish yellowish mass was excised and was sent for histopathology. The procedure lasted for 1 hour and 38 minutes. The patient was placed in the lateral position prior to removal of the supraglottic airway device. Patient was fully awake with stable vital signs.

Figure 1. CT Scan of the chest showing an enhancing mass with diffuse coarse calcifications in the anterior mediastinum/ pre-vascular space measuring about 4.5x8.6x5.7cm.



No compression of the vascular structures was noted. SVC, brachiocephalic veins and aorta are intact.

Figure 2. CT scan showing a narrowed trachea measuring 0.46cm² at the level of T3 -T4. Note the large mass compressing the trachea.



Discussion

Induction of general anesthesia in children with anterior mediastinal mass may cause serious complications of severe airway compression, obstruction to venous return or cardiovascular collapse. Many guidelines have been published on the management anterior mediastinal masses in children.

Sedation is a continuum process from minimal sedation (anxiolysis) to moderate sedation (previously conscious sedation) to deep sedation and general anesthesia. Pediatric patients may readily pass from a light level of sedation to deep sedation or general anesthesia. With this continuum process of sedation, there is a greater chance that respiratory function will be affected. Thus, in this age group, general anesthesia with a secured airway is greatly advocated. The patient was evaluated for signs and symptoms of possible airway and cardiovascular compromise. Using the formula of the tracheal area as proposed by Griscom and Wohl et al., the patient's computed tracheal area is 0.45cm^2 for her age. The measured CT scan diameter at the level of compression was 0.46cm^2 at T3-T4 (Figure 2). Based on this computation, tracheal area would still be normal even with compression as noted in CT scan. The formula is based on age in years, hence it is not reliable in patients younger than 1 year.

As proposed in the study of King et al., mediastinal mass ratio (MMR) could be a predictor of respiratory complications. As measured by the pediatric radiologist, MMR of our patient is 100% (1:1). However, we cannot consider mediastinal mass ratio as a true predictor of respiratory compromise, since MMR is no more than an approximate indicator of tumor size relative to the size of the patient. Based also on the experience of King et al., 3 patients with MMR of more than 56%, underwent anesthesia without difficulty. This case can be considered as one of those cases wherein MMR is quite significant, but predicted respiratory complications did not happen.

Another study by Turoff et al. and Piro AJ et al., utilized mediastinal thoracic ratio as predictors of perioperative respiratory risk complications. The computed MTR was 0.60 or 60%. It was stated in their study that a patient with MTR of more than 50% has higher risk of perioperative respiratory complications. However, MTR did not correlate with the risk of perioperative respiratory complication in our patient. The "Shamberger risk assessment box" which combines peak expiratory flow rate (PEFR) (%predicted) and tracheal area (% predicted) can be a helpful predictor. However, our case did not have pulmonary function study.

Presenting features in a patient with mediastinal mass depend upon the pressure effects on the surrounding airway and cardiac structures. The unique feature in our case was that the vascular and cardiac structures remained unaffected, uncompressed despite the presence of the huge mediastinal mass. With uncompressed great vessels and a secured airway, forward flow of blood to pulmonary circulation, as well as to the cardiac chambers, is unaffected leading to good oxygenation and perfusion.

Anesthetic Technique

The anesthesiologist's preferential requirements in doing such a case, are a secured airway, an immobile patient, and spontaneous respiration under general anesthesia. Spontaneous respiration generates negative intra-thoracic pressure which is very important in maintaining patency of the lower airways and the great vessels. The use of neuromuscular blockade (NMB) was avoided. NMB can cause loss of negative intra-thoracic pressure as a result of weakening of the chest wall muscles and is associated with life threatening respiratory obstruction.

Induction of anesthesia in semi supine, moderate back rest position is to avoid gravity induced tracheal compression of large anterior mediastinal masses. This basic maneuver creates a big difference in the stability of ventilation, allowing unobstructed gas exchange creating good oxygen saturation values.

Dexmedetomidine was used as it has good sedative, analgesic, amnesic and antisialagogue properties that maintain spontaneous respiration. Ketamine would provide additional antinociceptive effect. The combination of these 2 drugs is beneficial as Dexmedetomidine can prevent tachycardia, hypertension, salivation and emergence from Ketamine. While Ketamine may prevent bradycardia and hypotension caused by Dexmedetomidine. Propofol was not used as evidence, suggesting that with increasing depth of propofol anesthesia, configurational changes happen to the entire upper airway that leads to further airway narrowing in spontaneously breathing children.

In cases of superior vena cava syndrome (SVC), IV access can be obtained in the lower extremities. In SVC syndrome there is impedance in blood flow in the head, neck and upper extremities. Some clinicians prefer to insert IV access in the lower extremities, so to avoid problems with superior vena cava obstruction.

Anesthesia was maintained using Sevoflurane 1-2% and a supraglottic airway device (iGel) was used to secure the airway. iGel was preferred over LMA because iGel offers a non-collapsible airway cuff. Multiple neck mass may influence the fitting of LMA cuff, and hence has a greater chance of being folded. Unlike the inflatable LMA cuff, iGel is more rigid, it cannot be compressed and cannot be folded. Hence in this case, it offers proper fit in the laryngeal and peri-laryngeal structures, avoiding compression of neck masses.

In extubating process, smooth emergence from anesthesia is an advantage. Additional maneuver of placing the patient on a left lateral position prior to removal of supraglottic device offers the advantage of a patent and unobstructed trachea [6]. Lateral positioning could relieve airway obstruction by taking some weight of the tumor away from the tracheobronchial tree.

Recommendations and Conclusion

Pediatric patients with mediastinal mass require an individualized and highly tailored anesthetic plan. It is important to consider multiple factors as there is no single clinical sign or radiographic finding that could specifically predict the risk of respiratory compromise. There are still a lot of questions and concerns that remain unanswered. This limited group of patients, with life threatening co-morbidities cannot be subjected to randomized controlled trial. However, future direction to anesthetic case management and guidelines can be validated in prospective observational studies. Although this is just one case, we cannot generalize the result to all anterior mediastinal mass cases, but this could add up to the limited number of evidence that anesthetic procedures in this population could be achieved using a supraglottic airway device.

References

1. Shea, Christopher, MD. Langerhans Cell Histiocytosis. <https://emedicine.medscape.com/article/1100579-clinical>. November 2, 2022.
2. Shamberger RC. Preanesthetic evaluation of children with anterior mediastinal masses. *Semin Pediatr Surg* 1999; 8: 61-68.
3. Griscom NT, Wohl MB. Dimensions of the growing trachea related to the age and gender. *Am J Radiol* 1986; 146: 233-237.
4. Turoff RD, Gomez GA, Berjian R et al. Postoperative respiratory complications in patients with Hodgkin's disease: Relationship to the size of the mediastinal tumor. *J Cancer Clin Oncol* 1985; 21: 1043-1046.
5. King DR, Patrick LE, Ginn-pease ME et al. Pulmonary function is compromised in children with mediastinal lymphoma. *J Pediatr Surg* 1997; 32: 294-300.
6. Radvansky B, Hunt ML, Augoustides JG, et al. Perioperative Approaches to the Anterior Mediastinal Mass-Principles and Pearls From a Ten-Year Experience at an Experienced Referral Center. *J Cardiothorac Vasc Anesth* 2021; 35(8):2503-2512.

A CASE OF TWIN PREGNANCY WITH CONJOINED TWINS

Bushinoska Ivanova G¹, Ivanov J², Bushinoska J²

¹ *University Clinical Center Mother Theresa, Gynecology and Obstetrics Clinic, Skopje*

² *Acibadem Sistina Hospital, Skopje*

ABSTRACT

Background: A twin pregnancy in very rare cases, may be developed as a conjoined twin pregnancy. Conjoined twins are identical twins, who are completely inseparable and whose bodies are joined in the womb. They share the same chorion, placenta and amnion, but with mutually fused bodies. In most of these pregnancies when detected, termination of pregnancy is indicated.

Case Report: The aim of the paper is to present a case of pregnancy with conjoined twins, joined with the lower part of the chest and the upper part of the abdomen (omphalopagus), diagnosed during the early ultrasound screening at 13th gestational week of pregnancy. A 37- years old pregnant woman, with a third pregnancy (the first terminated with intentional abortion, the second with a Cesarean delivery) was examined in an outpatient clinic, for ultrasound screening of fetal anomalies in the first trimester. The diagnosis was confirmed also conciliary, that it was about conjoined twins (omphalopagus) - joined with the lower part of the chest and abdomen. After explaining the risks and possible outcomes of such a pregnancy to the parents and the poor quality of life of these newborns after delivery, they requested and accepted the termination of the pregnancy. The pregnancy was terminated at 13th gestational week of pregnancy, after the patient was admitted to the hospital for termination of the pregnancy.

Conclusion: Conjoined pregnancies have no future because of the poor life quality of these fetuses after delivery and usually are terminated when they are discovered. Ultrasound examinations during pregnancy are of great importance for the detection of fetal anomalies and these conditions, for the timely termination of these pregnancies, when they are detected.

Key Words: conjoined twins, gestational week, omphalopagus, pregnancy, termination of pregnancy.

Introduction

A twin pregnancy, in very rare cases may be developed as a conjoined twin pregnancy. It can appear with a frequency of 1:49.000 to 1:200.000, in different parts of the world (1). It occurs more often in some parts of Asia and Africa than in other regions of the world. Conjoined twins are identical twins, who are completely inseparable and whose bodies are joined in the womb from the beginning of pregnancy (2). They share the same chorion, placenta and amnion, but with mutually fused bodies, unlike other identical twins who usually have completely separate organs (3,4). Conjoined twins can be conjoined at the chest (thoracopagus), conjoined at the lower chest and upper abdomen (omphalopagus), conjoined at the lower back (pygopagus), conjoined skulls (craniopagus), conjoined at the pelvis with 4 arms and two legs (ischio-omphalopagus), with two separate heads and multiple limbs (dicephalus) (5, 6).

This phenomenon is the most common in female children 75%. Half of these pregnancies end with death during pregnancy or are stillborn, and another 30% die after delivery within the first 24 hours (7). They can survive from 5-25%, with, of course, a poor quality of life. Most of those who survive again are female, 75% (2.6.7).

Case report

A case of pregnancy with conjoined twins, joined in the lower part of the chest and the upper part of the abdomen (omphalopagus) is presented, at 13th g.w. of the pregnancy, during the early ultrasound screening of the same. Until then, the pregnancy was managed as a normal twin pregnancy, without additional symptoms and complications from the beginning of the pregnancy.

The patient is 37 years old, with a third pregnancy (the first ended with an intentional abortion in 2019, the second with a Cesarean delivery in 2020) and she was examined in an outpatient clinic for ultrasound screening of anomalies in the first trimester. After a short history taken by the pregnant woman, it was detected by ultrasound that it was a twin pregnancy with fetuses with parallel growth that corresponded to 13th g.w., with positive heart action in both fetuses. Nasal bone present in both, NT within reference limits for both, upper and lower limbs separate normally shaped, as well as spinal column in both twins. Since ultrasound could not detect a membrane that would separate two amnions, it was confirmed that they are monochoriaties, monoamniates. What was striking is that both fetuses were facing each other with their faces and bodies during the entire examination.

When the ultrasound was used to analyze the surface of the chest and abdomen in the fetuses, it was seen that the both were joined in the lower chest and upper abdomen and that they were conjoined twins. The diagnosis was confirmed conciliary, that it is about conjoined twins (omphalopagus) - joined with the lower part of the chest and abdomen. From the patient's history, there was nothing special about family and personal chronic diseases in her. The patient only had hypothyroidism, for which she regularly took Eutirox 50mg therapy daily. The entire diagnostic procedure and the established diagnosis were shown and explained to the patient, who, in the conversation together with her husband, requested termination of the pregnancy, without any further investigations. The patient asked to be hospitalized for termination of pregnancy and the same was done immediately with a record of admission to the hospital, for induced termination of pregnancy.

Results

Upon admission, laboratory tests were ordered - blood group, hemogram, hemostasis, infectious markers and examination by an anesthesiologist.

It was determined by ultrasound 4D (Figure 1) and 2D (Figure 2), that it was a twin pregnancy of Siamese-conjoined twins, joined in the lower part of the chest and abdomen (omphalopagus), monoamniates, monochoriaties. The twins had separate hearts, and the junction between them was at the anterior abdominal wall, which was shared, with one umbilical cord.

Figure 1. 4D Ultrasound of conjoined twins

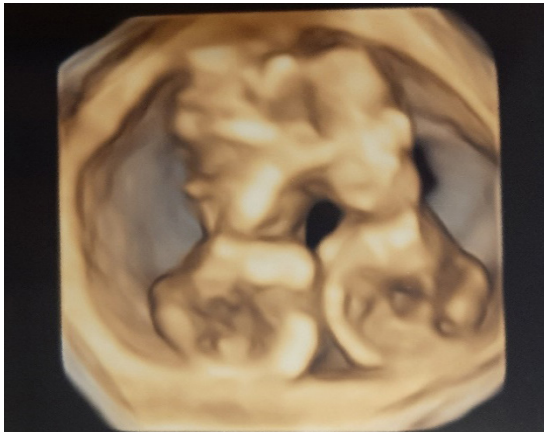
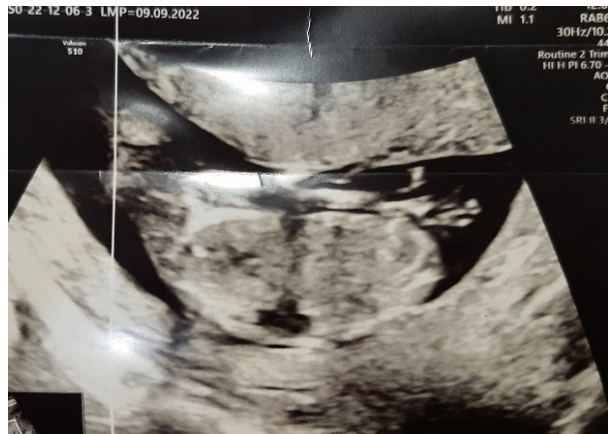

Figure 2. 2D Ultrasound of conjoined twins



The hemogram on admission was with normal values, without signs of anemia, leukocytosis and with normal platelets. The proteinogram, degradation products and electrolytes were within reference values. The patient's blood type was O Rh + (positive).

Infectious and serological tests for HIV, Hepatitis B and Hepatitis C were negative, as well as negative swabs from the nose and throat, which are taken according to protocol before admission to the hospital.

The patient was induced to terminate the pregnancy with Misoprostol, she got epidural anesthesia and after 8 hours of applying the therapy according to the scheme, the cervix was dilated, and the fetuses were expelled vaginally, with the spontaneous separation of the two fetuses in during the ejection, with separation and defect of the anterior abdominal wall in both fetuses. Both fetuses were female. After the spontaneous ejection of the two fetuses that weighed 38 and 41 grams, revision of the uterine cavity was performed with a curettage and placental tissues were removed from the uterine cavity. Then an antibiotic and uterotonic were applied parenterally. After two hours of monitoring after the intervention, the patient continued to be treated normally in the department and was discharged from the hospital the next day, with antibiotic and uterotonic therapy for the next 5 days. The patient requested that no further investigations to be carried out on the aborted fetuses and that they would not be photographed after the termination of the pregnancy.

Discussion

The first described case of conjoined twins in the literature came from Siam, now Thailand born in 1811, conjoined brothers, traveled the world for many years performing in circuses and the disease was named after them the "Siamese Twins". Today they could easily be separated (6,7,8). This situation is not related to hereditary factors, nor to the age of the mother (8). All these twins are monoamniotes, monochoriated, where an error occurs in their separation, in the earliest stage of pregnancy in the first two weeks, and they remain joined with some parts of the bodies (9,10).

About 500 cases of conjoined twins worldwide have been described in the literature. Our case is a rare case of conjoined twins with omphalopagus - conjoined lower thorax and abdomen, detected at early pregnancy in 13th gestational week using ultrasound. The conjoined twins were both female, with a common umbilical cord. Since they were detected at an early stage of pregnancy, termination of pregnancy by abortion was indicated.

Sometimes, if there is a diagnostic dilemma when using ultrasound whether it is conjoined twins, MRI or CT diagnostics can also be used [8]. That's why the availability of health care for all pregnant women is very important, as well as quality screenings in pregnancy to detect such cases and all other anomalies in fetuses, so that early termination of pregnancy can be performed if necessary.

Conclusion

A twin pregnancy in very rare cases can be a conjoined twin pregnancy, which occurs as an error in the separation of the identical twins, when they are not completely separated and remain joined with certain parts of the bodies. Such pregnancies have no future and when they are discovered it is best to terminate them. Ultrasound in pregnancy has the greatest importance in detection of fetal anomalies, conditions of the fetus that are incompatible with life, and conditions in the pregnancy that may require its termination.

Abbreviations: GOC - Skopje: Gynecology and Obstetrics Clinic - Skopje; G.W. - gestational week.

References

1. Spitz L. Conjoined twins. *Prenat Diagn.* 2005;25(9):814-9.
2. Jaczyńska R, Niemiec KT, Przybyłkowska M, et al. Conjoined twins diagnostic problems, difficult decisions in choosing the most optimal management in one of the rarest pathologies of pregnancy. *Ginekol Pol.* 2005;76(8):602-11.
3. Le, Tao; Bhushan, Vikas; Vasan, Neil (2010). *First Aid for the USMLE Step 1: 2010 20th Anniversary Edition*. USA: The McGraw-Hill Companies, Inc. p. 121. ISBN 978-0-07-163340-6.
4. Donald I. *Practical obstetric problems*. 7th ed. India: Wolters Kluwer; 2014:353-6.
5. Rathod S, Samal S. Conjoined twins: report of two cases and review of literature. *Int J Res Med Sci.* 2014;2:1203.
6. Swati T, Santosh K, Shashank T, et al. A rare case report of conjoined twins: Thoraco-omphalopagus with anterior abdominal wall defect. *Int J Reprod Contracept Obstet Gynecol.* 2021 Apr;10(4):1724-1726. DOI: <https://dx.doi.org/10.18203/2320-1770.ijrcog20211168>.
7. Stone JL, Goodrich JT. The craniopagus malformation: classification and implications for surgical separation. *Brain J Neurol.* 2006;129(5):1084-95.
8. Sharma M. Conjoined twins-thoraco-omphalopagus (type A). *BJR Case Rep.* 2015;2(1):20150016.
9. Weber MA, Sebire NJ. Genetics and developmental pathology of twinning. *Semin Fetal Neonatal Med.* 2010;15(6):313-8.
10. Cunningham L, Bloom D, Hoffman C. *Obstetrics*. 25th ed. USA: MC Graw Hill Education; 2018:863- 9.

MARIJUANA-INDUCED ACUTE CORONARY SYNDROME IN A YOUNG PATIENT

Boshev M^{1,3}, Pejkov H^{1,3}, Jovanoski M^{1,3}, Bojovski I^{1,3}, Andov M^{2,3}, Georgiev A^{1,3}

¹ University Clinic of Cardiology, 1000 Skopje, Republic of North Macedonia

² University Clinic of Thoracic and Vascular Surgery, 1000 Skopje, Republic of North Macedonia

³ Faculty of Medicine, University "Ss. Cyril and Methodius" - Skopje, Republic of North Macedonia

ABSTRACT

Introduction: Acute coronary syndrome (ACS) is generally a natural consequence of the progression of coronary atherosclerosis. But in minority of cases, it might be developed due to non-atherosclerotic reasons including recreational marijuana use. Possible pathophysiological mechanisms include inflammation, procoagulant state and vasoconstriction (vasospasm) of the coronary arteries. Marijuana adverse effects on cardiovascular system are various and well documented.

Case report: We present a 29-years old male who was referred to our Clinic due to chest pain and morphologic ECG changes. The patient has been previously hospitalized in local hospital due to hematochezia. Because of the chest pain, ECG was performed, and blood sample was taken there to determine the troponin level (hs-Tn I). ST-segment elevation and high level of hs-Tn I were indication for urgent transfer of the patient to our clinic. After admission, the patient underwent coronary angiography and PCI. Thoroughly taken history revealed that the patient was occasionally smoking marijuana in recreational purposes. He was a cigarette smoker, but he had no additional known risk factors for CAD.

Conclusion: Recreational marijuana use may be a trigger factor for an acute coronary syndrome. We should always think and suspect marijuana and other recreational drugs as a potential risk factor for adverse cardiovascular events in young patients.

Key Words: ACS, marijuana, PCI, risk factor.

Introduction

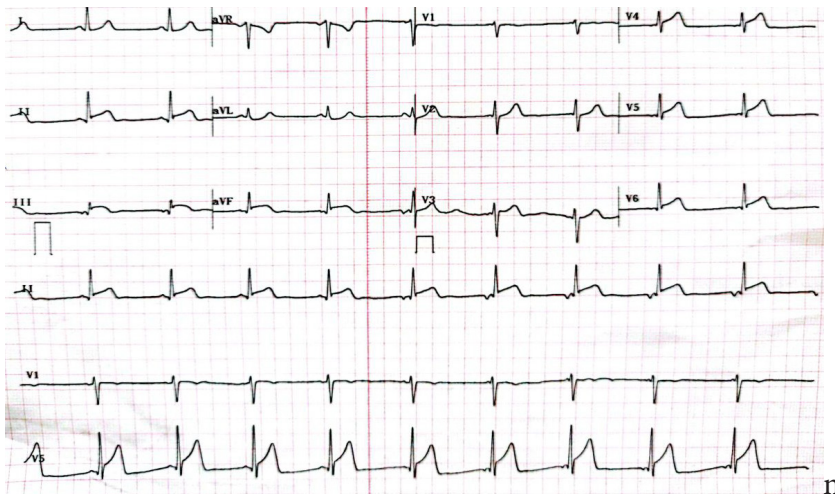
Acute coronary syndrome (ACS) is an acute cardiovascular condition that is generally a natural consequence of the progression of coronary atherosclerosis (atherosclerotic cardiovascular disease, ASCVD). But in small proportion of patients ACS may develop due to non-atherosclerotic factors like coronary vasospasm, embolism, spontaneous coronary artery dissection (SCAD), etc. Recreational marijuana use has been recognized as one of the most important trigger factors for various adverse cardiovascular effects especially in younger population, even in absence of traditional cardiovascular risk-factors, and it is well documented in currently available literature (1-4).

Case Report

We present a clinical case of 29-years-old male who was primarily hospitalized in local hospital due to hematochezia and blood loss caused by activated hemorrhoid nodules. The clinical

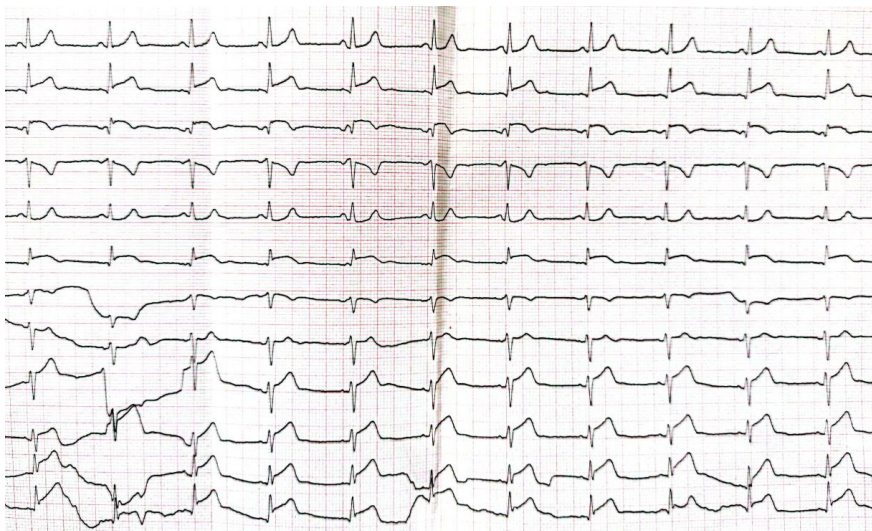examination has revealed that he has had a periodical bleeding from stool in previous 2 weeks. During this hospitalization, the patient had received a transfusion with 2 units of RBC. But later he has started to experience sharp chest pain. ECG revealed morphological ST-changes consistent with an acute myocardial infarction of the inferolateral wall (Figure 1) whereas high sensitive troponin I levels (hs-Tn I) were elevated. He was referred to the University Clinic of Cardiology and he has been transferred there afterwards.

Figure 1. ECG from local hospital showing ST-segment elevation in inferolateral leads.



The patient's history showed that he has had no previous cardiac conditions, negative familiar history for CAD, but he was an active cigarette smoker (1 pack/day) and occasional marijuana consumer (his last time of marijuana use was one day prior to local hospital admission). After admission to our clinic, the patient was urgently examined by gastroenterologist and active rectal bleeding was excluded. ECG changes were identical with previous ones (Figure 2). CBC revealed normocytic anemia (RBC $3,6 \times 10^{12}/L$, Hgb 101g/l, Hct 29,6%), while biochemistry showed hs-Tn I 7607 ng/L, and normal lipid profile (total cholesterol 4,0 mmol/l, LDL-c 2,4mmol/l, HDL-c 0,95mmol/l, TG 1,24mmol/l).

Figure 2. ECG upon admission at the University Clinic of Cardiology – Skopje showing ST-segment elevation in inferior and anterolateral leads.



He received standard pre-procedural pharmacological treatment with UFH 5000 IU iv, ASA 300mg, Clopidogrel 600mg, Rosuvastatin 40mg and Pantoprazole iv and went to the Cath-Lab immediately afterwards. Coronary angiography detected a thrombotic culprit lesion of the proximal LAD causing 95% vessel stenosis, as well as embolic occlusion of the distal LAD segment (Figure 3). We proceeded with direct stenting of the proximal LAD segment with 3.5/19mm DES on 20atm. with optimal angiographic result and TIMI 3 flow (Figure 4). We finished the procedure with no complications, and the patient was returned to the ICU for further monitoring.

Figure 3. Left: caudal projection of the LCA showing a significant culprit lesion at the LADprox segment (white arrow) and occluded LADdist segment (black arrow); Right: cranial projection of the LCA showing culprit lesion at the LADprox segment. LCA=left coronary artery.

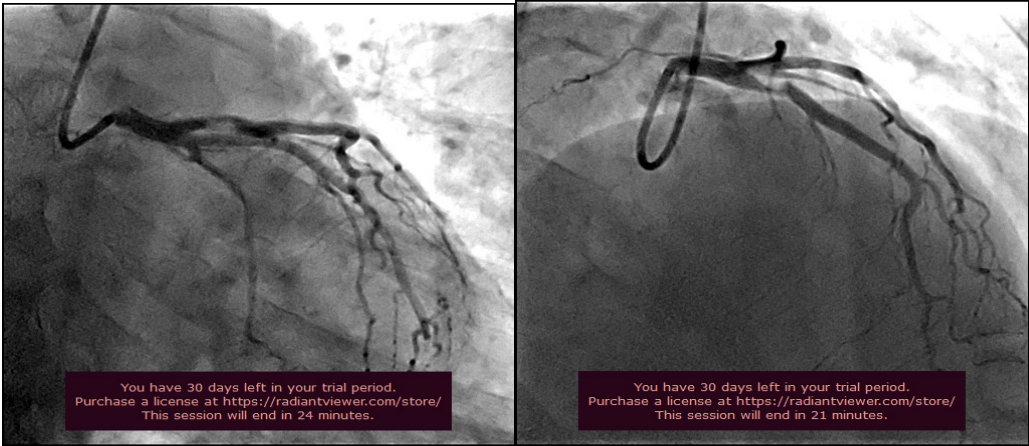
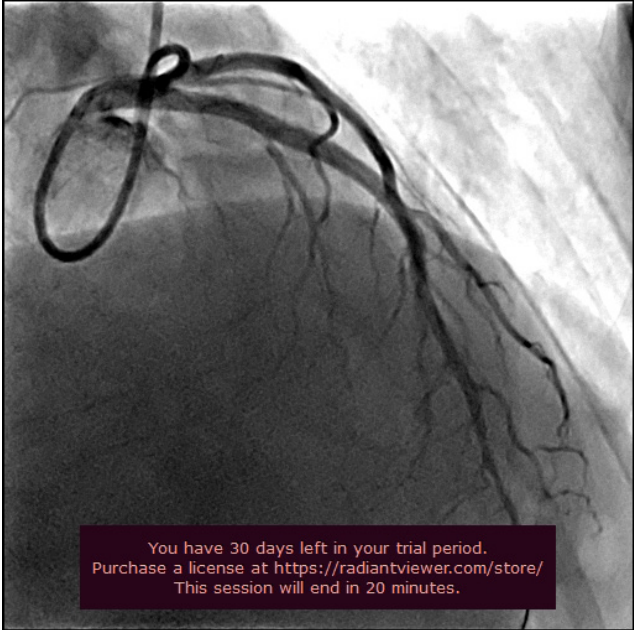


Figure 4. Final result after stenting of the LADprox segment with DES 3,5/19mm x 20atm.



Two days later rectoscopy was performed at the University Clinic of Gastroenterology and Hepatology and the second degree internal hemorrhoidal nodules were diagnosed with no active bleeding. Echocardiography showed normal dimensions of the left ventricle, preserved LV

systolic function (LVEF 60%), and hypo-akinesia of the whole LV apex. The patient was stable all the time and he was discharged 5 days upon admission. No bleeding episode was detected during this hospital stay and a colonoscopy was scheduled after 2 weeks. Dual antiplatelet therapy with ASA and Clopidogrel, Rosuvastatin and Pantoprazole were prescribed for further treatment.

Discussion

Marijuana or cannabis originates from the plant strains *Cannabis sativa* or *Cannabis indica* although many more hybrid strains have been produced (5). It contains many active substances, out of which tetrahydrocannabinol (THC) has been recognized as the most important. The biological effects of THC and cannabinoids are usually mediated via so-called endogenous cannabinoid receptors (CBR) distributed in various tissues and organs in the body. There are 2 types of CBR: CBR 1 (found in central, peripheral and autonomous nervous system, smooth muscle and myocardium) and CBR 2 found in hematopoietic tissue and cardiomyocytes (2-5). These effects occur dominantly due to sympathetic nervous system stimulation and include accelerated heart rate (tachycardia), hypertension, extreme sweating and increased myocardial oxygen demand (5). Currently available literature suggests an association between recreational marijuana use and adverse cardiovascular effects like rhythm disturbances (supraventricular and ventricular arrhythmias), syncope, ACS (STEMI and NSTEMI), myocarditis, sudden cardiac death etc. (6). Some authors report that marijuana use has been associated with almost a 5-fold increased risk of myocardial infarction in 1 hour after use (7). But sometimes cannabis is smoked together with tobacco and may be very difficult to differentiate the true trigger/association with cardiovascular (myocardial infarction) or cerebrovascular (ischemic stroke) events (7, 8). On the other hand, Johnson-Sasso et al. in their retrospective study (over 1,2 million patients) of acute myocardial infarction outcomes in marijuana users found that previous marijuana use was associated with decreased in-hospital mortality after myocardial infarction, similarly like Desai et al. in their study (9,10).

There are several proposed mechanisms of cannabis in the pathogenesis of an ACS. One of them includes cannabis-induced coronary vasospasm which is probably due to severely impaired endothelial dysfunction. Cannabis exerts pro-coagulant effects which can be seen by in-vitro studies with increased expression of glycoprotein IIb/IIIa receptors on the platelet surface which leads to enhanced platelet aggregation. Cannabis may also have hemodynamic effects on the coronary arteries which could lead to plaque erosion/rupture and eventually thrombosis. Furthermore, it may increase the carboxyhemoglobin level in blood and reduce its oxygen carrying capacity which can potentially lead to angina worsening. All these mechanisms may definitely contribute to the development of an ACS (11). And not to forget, this is possible even in cases of no other significant traditional cardiovascular risk-factors.

We presented a clinical case of young male patient with a history of tobacco and recreational marijuana smoking who experienced chest pain as an initial manifestation of an ACS. Development of ACS may not be exclusively due to marijuana use, but it definitely played a significant role as a trigger in this cardiovascular event. In addition, there are also several literature reports where marijuana alone or in combination with tobacco led to acute coronary event (1, 3, 12-14).

Conclusion

Increased recreational marijuana use, unambiguously led to increased number of adverse effects among which cardiovascular have been the most important. Since young people are the most frequent recreational drug users, we should always think about cannabis as a potential trigger in

case of an acute coronary syndrome in young patients even with no additional cardiovascular risk factors. Further clinical studies are needed to confirm a significant association between cannabis use and risk of adverse cardiovascular events.

References:

1. Aissaoui H, Bouloiz S, El-Azrak M, Bouchlarhem A, et al. Cannabis-induced myocardial infarction in a 27-year-old man: Case report. *Annals of Medicine and Surgery* (2022). <https://doi.org/10.1016/j.amsu.2022.104054>.
2. Jean-Louis F. et al. Analysis of STEMI and NSTEMI in a Community Cohort of Marijuana Users. *Cardiol Res.* 2022;13(5):297-302. doi: <https://doi.org/10.14740/cr1340>.
3. Biyik I. et al. Cannabis joint triggered recurrent anterior myocardial infarction in an adolescent taking dual antiplatelet therapy. *Postep Kardiol Inter* 2012; 8, 2 (28): 156–159. DOI: 10.5114/pwki.2012.29658.
4. Mankgele M. et al. Cannabis-associated MINOCA with underlying myocardial bridge. *Am J Case Rep*, 2023; 24: e938175. DOI: 10.12659/AJCR.938175.
5. Singh A. et al. Cardiovascular Complications of Marijuana and Related Substances: A Review. *Cardiol Ther* (2018) 7:45–59. <https://doi.org/10.1007/s40119-017-0102-x>.
6. Pasha K.A. et al. Cardiovascular Effects of Medical Marijuana: A Systematic Review. *The American Journal of Medicine* (2021) 134:182–193. <https://doi.org/10.1016/j.amjmed.2020.09.015>.
7. Dabiri E. A., Kassab S. G. Effect of Cannabis on Cardiovascular System; The Good, The Bad, and The Many Unknowns. *Med Cannabis Cannabinoids* 2021;4:75–85. DOI: 10.1159/000519775.
8. Casier I. et al. Is recent cannabis use associated with acute coronary syndromes? An illustrative case series. *Acta Cardiol* 2014;69(2): 131-136. doi: 10.2143/AC.69.2.3017293.
9. Johnson-Sasso CP, Tompkins C, Kao DP, et al. (2018). Marijuana use and short-term outcomes in patients hospitalized for acute myocardial infarction. *PLoS ONE* 13(7): e0199705.
10. Desai R, Patel U, Sharma S, et al. Recreational Marijuana Use and Acute Myocardial Infarction: Insights from Nationwide Inpatient Sample in the United States. *Cureus.* 2017; 9(11):e1816. <https://doi.org/10.7759/cureus.1816> PMID: 29312837.
11. Goyal H, Awad H.H., Ghali J.K. Role of cannabis in cardiovascular disorders. *J Thorac Dis* 2017;9(7):2079-2092. doi: 10.21037/jtd.2017.06.104.
12. Verma A, Nanda V, Kabi A, et al. Marijuana-induced acute myocardial infarction in a young adult male. *BMJ Case Reports CP* 2021;14:e243335.
13. Nagappan D, Demeester S. Cannabis-Associated Myocardial Infarction in a Young Woman Without Other Cardiac Risk Factors. *J Urgent Care Med.* September 2020.
14. Lawin D, Lawrenz T, Tego A, et al. Cannabis-induced recurrent myocardial infarction in a 21-year-old man: a case report. *European Heart Journal - Case Reports* (2020) 4, 1–5, doi:10.1093/ehjcr/ytaa063.

PREOPERATIVE MANAGEMENT OF THROMBOCYTOPENIA AND PSEUDOTHROMBOCYTOPENIA

Kraleva S¹, Petkov N², Trojikj T¹, Crnusheva S³, Markoska V¹

¹ Department of Anesthesiology and Intensive Care, City General Hospital "8th September", Skopje

² Department of Orthopedic Surgery and Traumatology, City General Hospital "8th September", Skopje

³ Public Health Institution "Health Center - Veles", Veles

ABSTRACT

A normal platelet count is from 150 to 450×10⁹/L. Thrombocytopenia is a platelet count under 150×10⁹/L. Mild thrombocytopenia is a platelet count from 100 to 150×10⁹/L, moderate from 50 to 99×10⁹/L, and severe under 50×10⁹/L. Patients with thrombocytopenia sometimes need a surgical treatment, and a platelet count under normal values is a relative contraindication for a surgery because of bleeding. Prior to surgery thrombocytopenia should be corrected with platelet transfusion and Guidelines often recommend a platelet count value above 50×10⁹/L prior to major surgery and 100×10⁹/L prior to surgery of the brain and eyes.

The aim of our presentation was to show the two rare cases of thrombocytopenia, idiopathic and pseudothrombocytopenia in two patients prior to surgery, and how we managed it. Platelet transfusion is the only available therapy capable of achieving a rapid increase in platelet count, although platelet transfusion has several risks. In pseudothrombocytopenia, the low platelet count is a consequence of platelets aggregation that appears in vitro, associated to the use of EDTA in the blood-collection tube, so using heparin blood-collection tube helps us to found out a real platelet count.

We concluded that, in elective surgeries or postoperative thrombocytopenic patients, hematology consultation may be helpful in diagnosing the etiology of thrombocytopenia, selecting appropriate therapy, and determining the utility of platelet transfusion or its alternatives.

Key Words: *idiopathic thrombocytopenia, platelet count, platelet transfusion pseudothrombocytopenia, surgery.*

Introduction

Platelets are part of blood cells whose main function is to participate in blood coagulation, in the formation of a blood clot. Normal platelet count is from 150×10⁹/L to 450×10⁹/L, depending on laboratory variations, and relatively stable over the lifetime of an individual (1).

Thrombocytopenia is when platelet counts are under 150×10⁹/L. When a platelet count is above 50×10⁹/L, patients are usually asymptomatic, but with platelet counts between 20 and 50×10⁹/L patients may have petechiae, purpura or ecchymosis. If a patient has a platelet count under 10×10⁹/L, it is very likely to result in serious bleeding. Mild thrombocytopenia is when platelet

counts are from 100 to $150 \times 10^9/L$, moderate from 50 to $99 \times 10^9/L$, and severe when platelet counts are under $50 \times 10^9/L$. Reasons for thrombocytopenia can be multiple: decreased bone marrow production of platelets, increased peripheral destruction, consumption of platelets, splenic sequestration, dilution or platelet clumping (2). The incidence of thrombocytopenia or thrombocytosis is 1 case in 14 patients.

Thrombocytopenia has been divided, for surgical purposes into mild ($100-149 \times 10^9/L$), moderate ($50-99 \times 10^9/L$), and severe ($<50 \times 10^9/L$). Correlation between platelet count and bleeding risk is not linear and depends on platelet function, other patient's specific factors, as well as on the etiology of thrombocytopenia. It is known that patients with idiopathic thrombocytopenia bleed less than other patients do at similarly low platelet counts, probably because of the increased size and function of their platelets. Preoperatively thrombocytopenia should be corrected with platelet transfusion and Guidelines often recommend a platelet count value above $50 \times 10^9/L$ prior to major surgery and $100 \times 10^9/L$ prior to surgery of the brain and eyes (3).

A normal platelet count is 15–40 times higher than it is necessary to achieve hemostasis (9). Indeed, platelets have a role, not only in hemostasis, but also in inflammatory and immune system and wound healing (10). Platelet transfusion is usually available therapy to achieve a rapid increase in platelet count, but as we know, platelet transfusion has a lot of risks.

In pseudothrombocytopenia, the low platelet count is a consequence of platelets aggregation that appears in vitro, associated to the use of EDTA in the blood-collection tube, so using heparin blood-collection tube helps us to found out a real platelet count. Pseudothrombocytopenia (PTCP), can lead the clinicians in wrong way, unnecessary testing and wrong treatment. Other causes of a falsely low platelet count can be platelet damage during blood collection, mega-thrombocytes, but the most common is pseudothrombocytopenia as a result of ethylenediaminetetraacetic acid (EDTA)-dependent antibodies (4). The first report for this type of pseudothrombocytopenia was in 1969, with incidence of 0.03-0.27% of the general population. But, it is known that some other anticoagulants, like citrate, heparin, or sodium fluoride have also caused pseudothrombocytopenia (4). The EDTA causes changes of platelet surface glycoprotein IIb/IIIa and natural IgM or IgG autoantibodies bind to GPIIb/IIIa, resulting in platelet agglutination in vitro (10). In pseudothrombocytopenia platelet count can be very low, $\leq 10 \times 10^9/L$, but without hemorrhagic signs because of, in vivo, normal platelet count and function.

Pseudothrombocytopenia as a clinical sign in surgical patients is a diagnostic challenge for anesthesiologists, to make correct assessment, diagnostic procedures to confirm the diagnosis, and to prepare the patient for surgery. No correlation between clinical symptoms and laboratory tests in a case with a low platelet count, should be direction to think about pseudothrombocytopenia.

Case reports

Our first case was a 24-years old male patient, admitted in the hospital for orthopedic surgery, Dg: Osteochondritis condyle lateralis femoris lateralis dextri. At the age of 16, he developed idiopathic thrombocytopenia, threated with corticosteroids for four years. But, for the last four years he was without therapy, with a low platelet count and no clinical signs of bleeding. His

laboratory tests were normal, except platelet count, $22 \times 10^9/L$ (severe thrombocytopenia). The hemostasis was in the normal ranges. The patient was a smoker.

Therapy from the hematologist was decortin, vitamin C tablets, pyridoxine (B6) and magnesium, and platelets concentration transfusion in case of bleeding. A day before surgery, 8 units of platelets concentration were given, and platelet count increased to $47 \times 10^9/L$. On the day of surgery, plus 7 units of platelets concentration were given, and prior to surgery platelet count was $97 \times 10^9/L$. Because of thrombocytopenia, surgery was done under general anesthesia with propofol, remifentanyl and rocuronium. Tranexamic acid 1gr and methylprednisolone 80mg was given at the beginning of the surgery. Vital signs were stable during the surgery, and no bleeding was observed. After 30 minutes in the recovery room, patient was sent to the general ward. Fraxiparine 5700IU/0,6ml was given postoperatively up to 3 weeks after the operation. Postoperative control of platelet count was $78 \times 10^9/L$. Two days later, patient was discharged home in a good condition.

Our second case was a 62-years old male patient, admitted in our hospital for orthopedic surgery on the left arm, with Dg: SLAP laesio ommae et ruptura rotator cuff ommae lat.sin. From his medical history, he suffered from asthma bronchiolae, hyperlipidemia, hypertension arterialis, and for the last 10 years he was diagnosed with pseudothrombocytopenia. Leucocytes count, erythrocytes count and hemoglobin were within normal values. His last control at Hematology Clinic confirmed the diagnosis, low platelet count in the EDTA blood-collection tube ($53 \times 10^9/L$), normal platelet count in the heparin blood-collection tube ($161 \times 10^9/L$), with platelet aggregation in the blood smear.

Preoperatively, platelet count in the EDTA blood-collection tube was $29 \times 10^9/L$, but in the heparin blood-collection tube platelet count was in the normal ranges, $181 \times 10^9/L$. Other laboratory tests were normal. Surgery was done under general anesthesia, with propofol, fentanyl and rocuronium, maintained with remifentanyl and sevoflurane. After intubation, our patient was sat in the beach-chair position. Cerebral oximetry was used on the right cerebral hemisphere. Vital signs were stable all the time, blood pressure within ranges of moderate hypotension and good cerebral oxygenation, no bleeding observed during surgery. The operation lasted 150 minutes. After extubating, patient was discharged to the ward in a stable condition. Postoperatively, platelet count in the EDTA blood-collection tube was $20 \times 10^9/L$, with normal platelet count in the heparin blood-collection tube. The day after surgery, our patient was discharged in a good condition.

Discussion

The thrombocytopenia as a hematologic finding can be the first manifestation of a lot of diseases. Looking for the reason of thrombocytopenia is essential for the management of these patients. The clinical manifestation of thrombocytopenia in the patients is variable and depends on the reason, but as we know the platelets play a main role in hemostasis. A lot of mechanisms for thrombocytopenia are involved: increased destruction of platelets, decreased production, reduced function of platelets associated with using of antiplatelet drugs. So, platelet function disorders can be inherited, and they are very rare, and acquired forms thanks to the wide use of antiplatelet drugs for thromboprophylaxis (5).

Surgical patients with thrombocytopenia require a good preoperative evaluation and preparation for surgery. Because of risk of bleeding during surgery, these patients often need platelet transfusion to reach platelet count that allows procedure to be performed, and to prevent bleeding (6).

In our cases we had completely different types of thrombocytopenia, idiopathic and pseudothrombocytopenia. Detailed preoperative anamnesis gave us opportunity for good preoperative management of patients. Our first patient platelet count was in a range of severe thrombocytopenia ($<50 \times 10^9/L$), with high risk of bleeding without proper management preoperatively. The only choice of the therapy we had at that moment for the prevention of bleeding during surgery was to give platelet transfusion. We had to give platelet transfusion to obtain optimal platelet count for surgery, more than $50 \times 10^9/L$ because Guidelines recommend a platelet count above $50 \times 10^9/L$ prior to major surgery. Platelet transfusion is the only therapy to achieve a rapid increase in platelet count, but platelet transfusion has a lot of risks: volume overload, febrile non-hemolytic transfusion reactions, transfusion-associated acute lung injury, allergic reactions, immunomodulation, post-transfusion purpura, infectious risk, and alloimmunization with subsequent ineffectiveness of platelet transfusion. Because platelets cannot be frozen, they have a high risk of bacterial sepsis, more than other blood products (8). As we know, platelets have main role in hemostasis, but they have a role in inflammatory and immune system and wound healing too, so platelet transfusion in our first case was mandatory. Our second case, the patient with pseudothrombocytopenia was a rare phenomenon. Our patient had a low platelet count in preoperative blood tests but did not show any bleeding signs and had normal hemostasis. The exact identification of this phenomenon is crucial, since there is a high chance that EDTA-induced pseudothrombocytopenia to be confused with some disorders, such as heparin-induced thrombocytopenia, disseminated intravascular coagulation, or sometimes can lead to inappropriate clinical and therapeutic decisions such as administration of platelet transfusion, unnecessary splenectomies, cancelled or delayed invasive procedures, avoidance of anesthesia, as well as no administration of antiplatelet or anticoagulant drugs in patients who would need them, further undue investigations and, last but not least, patient anxiety (8-11). Hematological, as well as other types of laboratory investigation, is nowadays an essential part of the clinical and therapeutic decision-making (12). Our patient was already diagnosed with thrombocytopenia, but we had to be careful during intraoperative period, focusing all our attention on the patient. In our patient, we checked out the real platelet count preoperatively by using heparin blood-collection tube.

Observing pseudothrombocytopenia in some people does not mean that they are at risk of developing other disorders. Risk population for pseudothrombocytopenia includes male, over 50 years of age, some diseases, or thromboprophylaxis with LMWH (13).

Conclusion

The bleeding risk in thrombocytopenic patients undergoing surgical procedures is difficult to predict. At any given platelet count, congenital or acquired platelet dysfunction may render available platelets less effective. So, each patient is unique with unique risk of bleeding, at acceptable platelet count for some procedures. Following the Recommendations for procedure-specific 'safe' platelet counts often gives us opportunity for good management and safe procedure for our patients. We should know that the benefit of prophylactic platelet transfusion is still unclear

and the need for platelet transfusion should be a decision based on each patient individually. In elective surgeries or postoperative thrombocytopenic patients, hematology consultation may be helpful in diagnosing the etiology of thrombocytopenia, selecting appropriate therapy, and determining the benefit of platelet transfusion or its alternatives.

We've presented two cases with thrombocytopenia, and good preoperative management of our patients of all aspects resulted in stable intra and postoperative condition.

References

1. Buckley MF, James JW, Brown DE. et al. A novel approach to the assessment of variations in the human platelet count. *Thromb Haemost.* 2000; 83: 480-484.
2. Arnold DM, Cuker A. Diagnostic approach to the adult with unexplained thrombocytopenia. *UpToDate.* Updated May 18, 2021. Accessed December 6, 2021.
3. Estcourt LJ, Birchall J, Allard S, et al. and the British Committee for Standards in Haemathology. Guidelines for the use of platelet transfusions. *British Journal of Haemathology* 2017; 176:365-394.
4. Gowland E, Kay HEM, Spillman JC, et al. Agglutination of platelets by a serum factor in the presence of EDTA. *J. Clin. Pathol.* 1969; 22: 460–464.
5. Kumar A, Mhaskar R, Grossman BJ. et al. Platelet transfusion: a systematic review of the clinical evidence. *Transfusion.* 2015; 55 (quiz 1115): 27. doi: 10.1111/trf.12943. Epub 2014 Nov 12. PMID: 25387589.
6. Estcourt LJ, Malouf R, Doree C, et al. Prophylactic platelet transfusions prior to surgery for people with a low platelet count. *Cochrane Database of Systematic Reviews* 2018, Issue 9. Art. No.: CD012779.
7. Corash L. Bacterial contamination of platelet components: potential solutions to prevent transfusion-related sepsis. *Expert Rev Hematol.* 2011; 4: 509-525.
8. Chae H, Kim M, Lim J, et al. Novel method to dissociate platelet clumps in EDTA-dependent pseudothrombocytopenia based on the pathophysiological mechanism. *Clin. Chem. Lab. Med.* 2012; 50: 1387–1391.
9. Kovacs F, Varga M, Pataki Z, et al. Pseudothrombocytopenia with multiple anticoagulant sample collection tubes. *Interv. Med. Appl. Sci.* 2016; 8:181–183.
10. Veenhoven WA, van der Schans GS, Huiges W, et al. Pseudothrombocytopenia due to agglutinins. *Am J Clin Pathol* 1979; 72: 1005–1008.
11. Lippi G, Plebani M. “EDTA-dependent pseudothrombocytopenia: further insights and recommendations for prevention of a clinically threatening artifact. *Clinical Chemistry and Laboratory Medicine*, 2012; 50(8): 1281–1285.
12. Kharel H, Pokhrel NB, Pant SR, et al. Surgical Delay due to Ethylenediaminetetraacetic Acid-Induced Pseudothrombocytopenia. *Cureus* (July 19, 2020); 12(7): e9273. doi:10.7759/cureus.9273.
13. Lardinois B, Favresse J, Chatelain B, et al. Pseudothrombocytopenia-A Review on Causes, Occurrence and Clinical Implications. *J Clin Med.* 2021 Feb 4; 10(4): 594. doi: 10.3390/jcm10040594. PMID: 33557431; PMCID: PMC7915523.

DELAYED TREATMENT OF DECOMPRESSION SICKNESS TYPE II RESPONSIVE TO HYPERBARIC OXYGEN

Etemi J¹, Nacevska Gjorgjeska A¹, Pejkova S¹, Peev I¹, Lleshi A², Cvetkova Mladenovska M²

¹ University Clinic of Plastic and Reconstructive Surgery – “Mother Theresa”, Republic of North Macedonia

² University Clinic of Traumatology, Orthopedic Surgery, Anesthesiology and Intensive Care and Emergency Center – “Mother Theresa”, Republic of North Macedonia

ABSTRACT

A 38-years-old recreational female diver presented at our hospital with fatigue, dizziness, cutis marmorata, swollen and painful ankles, back pain and pulmonary symptoms. The patient was diving in the Maldives, with series of daily dives mostly around 22m, each dive decompression made on 6m with duration of 3 minutes. After more than 30 hours from her last dive, she took an international flight Maldives – North Macedonia that lasted for about 12 hours. Her first checkup was more than 80 hours of the onset of symptoms. Neurological examination, electrocardiogram, chest X-ray and lung ultrasound were normal. Laboratory data only showed evidence of thrombocytopenia and elevated D-dimer. Decompression sickness type II was diagnosed according to history and physical examination. Recompression treatment with hyperbaric oxygen (HBO₂) was immediately started (2.8 ATA on 100% oxygen over a period of 90 minutes) and additional session at the same day with a duration of 70 minutes to 2.4 ATA. Additional courses with HBO₂ were required daily in the next 7 days to 2.4 ATA. The most of the patient's symptoms were resolved after the third therapy with HBO₂, and the cough after the 7th therapy. The patient was released from hospital after resolution of the symptoms. **Conclusion:** Cutis marmorata is often associated with more serious manifestations of decompression sickness. Treatment with HBO₂ is the cornerstone therapy for DCS. Indeed, treatment with hyperbaric oxygen can be successful even in cases with delayed start.

Key Words: *cutis marmorata, decompression sickness, diving, hyperbaric oxygen.*

Introduction

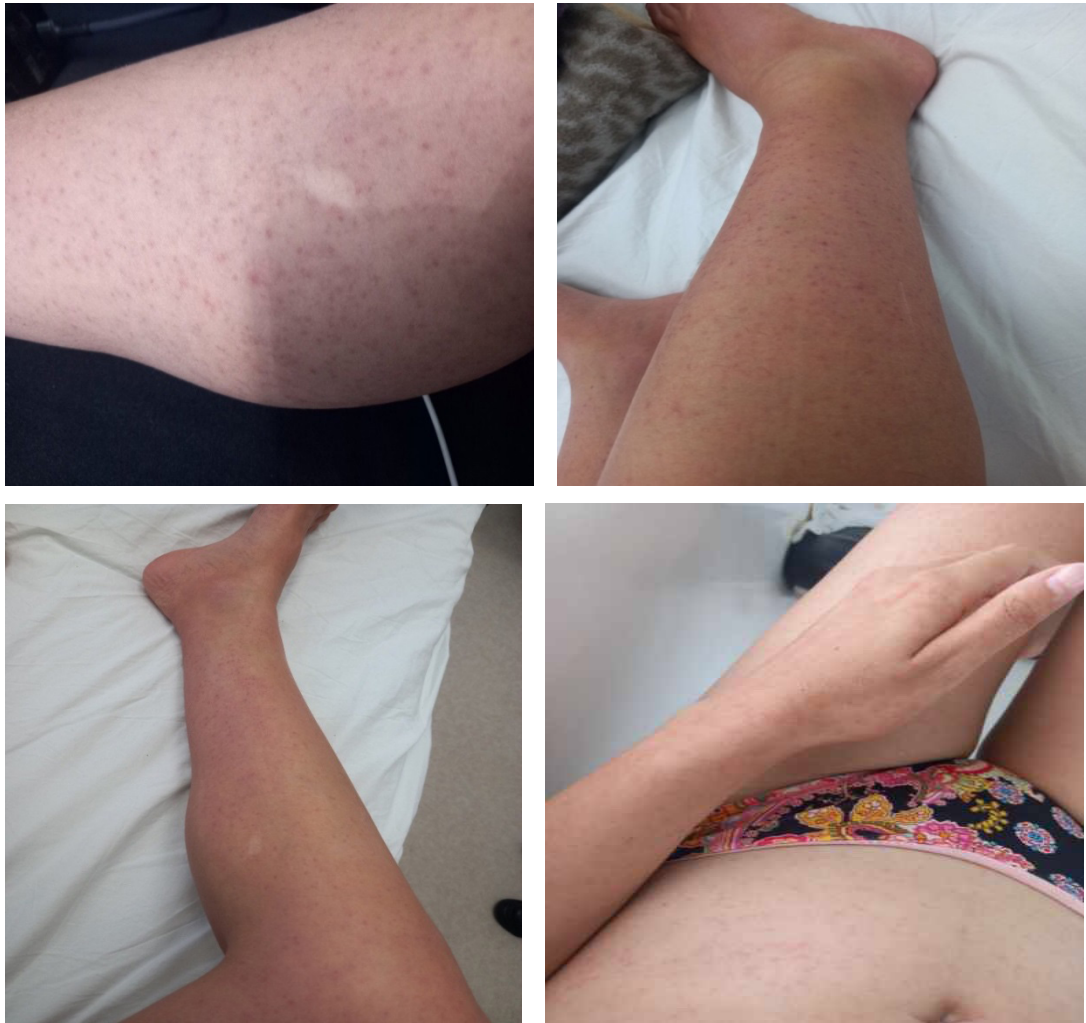
A major risk in scuba diving is the exposure to changes in pressure when diver ascends to the surface too quickly. Diving has become an increasingly popular sport and previously very rare complications, such as Decompression sickness, are becoming more common (1). The development of bubbles in tissues and/ or blood when the total pressure of the dissolved gas exceeds the ambient pressure, results in decompression sickness (also known as “bends”). Mild altitude exposure, like that from a flight in a commercial aircraft, can cause DCS after a dive (2). Decompression illness was first described in mid-1840 during the construction of the Brooklyn Bridge, when construction workers were put in pressurized boxes (caissons) used underwater. The condition was referred to as “the bends” because when workers returned from the compressed atmosphere of the caisson to air pressure, they walked with bent appearance from the joint pain. Later, DCI was divided into two categories: arterial gas embolism (AGE)

and decompression sickness (DCS) (1). The factors have been discovered that affect the risk of decompression sickness like altitude or time since the previous dive. Dehydration, tiredness, poor physical condition, having a higher body mass index, being older, and having a right to left shunt such a patent foramen ovale are additional risk factors for decompression illness (3). Symptoms of decompression sickness, which can range in severity from mild to severe, can include pain, skin changes, neurologic symptoms and cardiopulmonary symptoms (1,3). DCS is typically divided into two types: type 1, which refers to skin changes and less severe symptoms including joint discomfort, and type 2, which refers to symptoms that are more severe and affect the neurologic, cardiac and pulmonary systems (3). The majority of symptoms surface within 24 hours, unless there is an additional decompression (for example, altitude exposure), with severe symptoms typically appearing one to three hours after decompression (2). An incidence of 1.5 to 10 per 10,000 dives is seen among commercial divers. The duration of the dive and depth will determine this (4). Males are 2.5 times as likely as females to get DCS (4). Diagnosis of DCS is clinical, based on careful evaluation, clinical examination and historical data (1,2). The cornerstone of this condition's therapy is hyperbaric oxygen (HBO₂) (2). The aim of this case report is to present the first case of DCS type II described in our country that was presented in the hospital nearly 4 days after the onset of symptoms and underwent successful recompression treatment of DCS with hyperbaric oxygen in a multiple chamber.

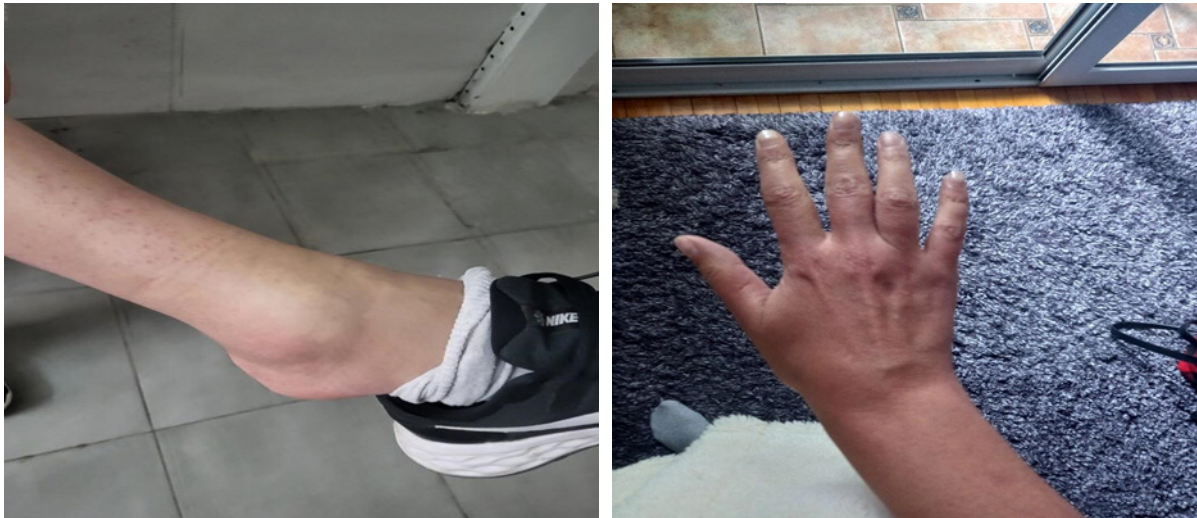Case Presentation

We describe a case of 38-year-old female recreational diver with no prior medical history, no family history either. She is a smoker, weighing 57kg, BMI 19.3kg/m² with no previous history of diving accidents. She had a sum of 35 dives during the 10-years period. While on vacation in the Maldives, she went diving every day for 8 days. This consisted of a daily dive schedule of two repetitive dives with duration of 40-45 minutes each with a 45minutes pause between them. The dives typically occurred at a depth of 22 meters (each dive with 3 minutes safety stop on 6 meters). She used a dive computer, and appropriate decompression schedules were followed while diving with tank, using enriched air nitrox (EAN). The last day of diving she made two repetitive dives with duration of 40-45 minutes each with a 45-minute pause between them. Approximately 20 minutes after surfacing, she noticed a mottled rash covering her face and body, which she thought were due to sunburn. She used some topic solution with no effect. The rash was followed by fatigue, discomfort and malaise, that prevented her from diving again the next two days before taking a long international flight to come back home, but she continued with her daily activities like boat floating. After more than 30 hours from her last dive, she took a flight from Maldives to North Macedonia that lasted for about 12 hours, and which include one transfer. When she landed (the third day of onset of symptoms), she noticed swelling of the ankles, especially the right one, which she thought was due to long flight. The next day (4th day of onset of symptoms) when she woke up, she had swollen and painful elbows and hands, chest pain and cough. More than 80 hours after the start of her symptoms, she went for her first checkup at the University Clinic of Plastic and Reconstructive Surgery, where she complained of fatigue, dizziness, malaise, swollen and painful ankles and elbows, back pain, dyspnea, an intense irritating cough and chest pain. During the initial medical examination, she was conscious, oriented, afebrile, normotensive, with purpuric-violaceous macular rash on her face, trunk and limbs (Figure 1 - a, b, c, d - cutis marmorata).

Figure 1.- a, b, c, d. *Cutis marmorata* in 38-years-old woman after diving.

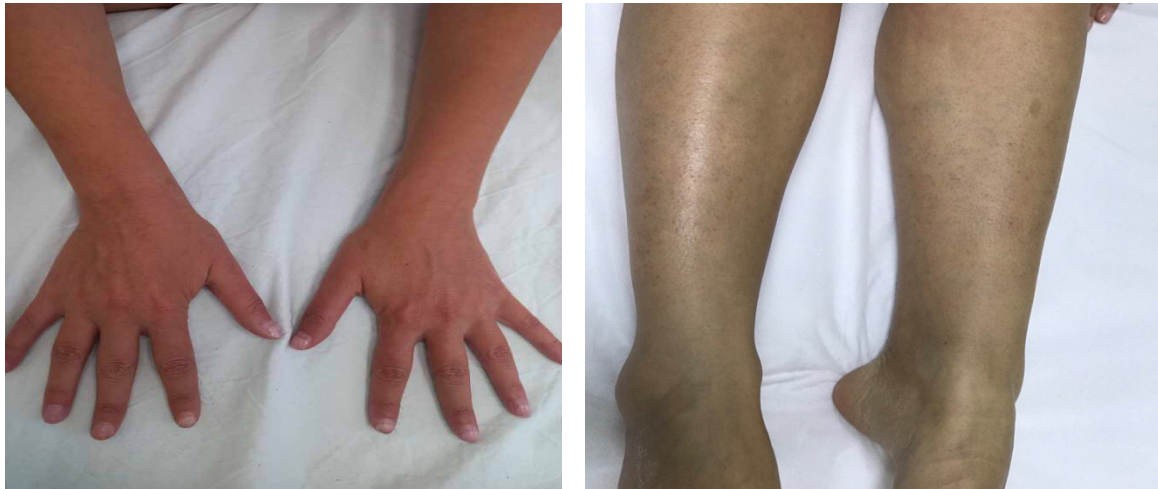

On auscultation of the lung breath sounds were vesicular. Abdomen was soft and non-tender. The neurological examination showed normal cranial nerve function. Motor and sensory functions were normal. Romberg sign was negative. Her elbows and ankles were swollen, painful, with restriction in movement (Figure 2 - a, b).

Figure 2 - a, b. Swollen ankle and elbow due to decompression sickness.

Vital signs were within normal limits: blood pressure 120/80mmHg, heart rate 56/minutes, saturation O_2 -97%. Electrocardiogram showed sinus rhythm, with normal p wave, QRS complex and T wave. An arterial gas blood demonstrated pH 7.41, pCO_2 41.3mmHg, pO_2 96.4mmHg, carboxyhemoglobin 2.1%, methemoglobin 1.1%, lactate 0.9mmol/L, bicarbonate 25.7mmol/L, base deficit 1.7mmol/l; On admission laboratory data showed evidence of thrombocytopenia $89 \times 10^9/L$ (referent values 150-450) and elevated D-dimer 884.16ng/ml (referent values <500). The rest of the findings were within normal range: RBC $4.58 \times 10^{12}/L$, HGB 145g/l, WBC $5.3 \times 10^9/l$, Ne 57.5%, CRP 0mg/l, myoglobin 18.2ng/ml, Na 135mmol/l, K 4.17mmol/l. No abnormalities were found on chest X-ray and lung ultrasound. Based on the clinical presentation, dive history and medical examination a diagnosis of type II Decompression sickness was taken into consideration. Recompression treatment in multiple chamber was immediately started of pressuring to 2.8 ATA initially according to the US Navy treatment table on 100% oxygen over a period of 90 minutes and second session with hyperbaric oxygen at the same day with a duration of 70 minutes to 2.4 ATA. Additional courses were required daily in the next 7 days with 2.4 ATA over a period of 70 minutes. Crystalloids, non-steroid anti-inflammatory drugs and treatment with low molecular weight heparin (Enoxaparin sodium) were carried out in the first three days. The patient underwent a total of 9 hyperbaric chamber treatments over 8 days. The patient's symptoms like chest pain, back pain, dyspnea, rash and swelling of the ankles and elbows resolved after the third therapy with hyperbaric oxygen (Figure 3 - a, b).

Figure 3 - a, b. After treatment with hyperbaric oxygen (after third therapy).



The cough resolved after the 7th therapy. The patient was released from hospital after resolution of the symptoms. Control laboratory findings made on the sixth day of treatment showed normal platelet count and D-dimer 212ng/ml. An outpatient echocardiography about evaluation for PFO was suggested, but the patient refused to conduct the diagnostic procedure. We advised no diving in the next two months to the patient. A month later, she reported being healthy and experiencing no new symptoms during a phone call.

Differential diagnosis:

- Myocardial infarction (normal ECG), no history of angina, no risk factors;
- Pneumothorax, Bronchopneumonia-afebrile, no abnormalities on x-ray of the lungs;
- Thrombotic thrombocytopenic purpura (no fever, no hemolytic anemia, no kidney failure or neurologic deficit);
- Immersion pulmonary edema;
- Pulmonary thromboembolism.

Discussion

Increases in ambient pressure during a dive's descent phase lead to greater amounts of nitrogen dissolving in body tissues up until the point at which the tissues are saturated. When ascending from a dive, inert nitrogen gas bubbles enter the circulation and tissues, which results in decompression sickness (DCS) (5). This is explained by Boyle's law, which states that at a constant temperature, the absolute volume of a fixed mass of gas is inversely proportional to absolute pressure. Furthermore according to Henry's law the amount of gas that will dissolve in a liquid is proportional to the partial pressure of the gas over the liquid at a constant temperature (3,6,7). If a person dives and then flies, DCS is more likely to happen (3,7). Decreased pressure during flying and possibility of dehydration are DCS risk factors (8). Based on the organs damaged and the presenting symptoms, DCS was divided into the two categories - DCS type I and DCS type II.

The clinical manifestations of Type I DCS may include one or more of the following symptoms: arthralgia, myalgia, dermal manifestations and fatigue, while Type II DCS is associated with neurological symptoms or cough, chest pain, dyspnea and other cardiopulmonary symptoms known as “chokes” (5,9-12). Delayed symptoms are caused by intravascular and extravascular bubbles mechanically obstructing the vasculature, which results in stroke-like signs and symptoms and activates clotting and inflammatory cascades, as well as platelet activation and deposition or consumption (3,10–12). Mitchell S et al. say that changes in the coagulation system after decompression include a modest decrease in circulating platelets due to activation and higher consumption, as well as an increase in circulating fibrin monomer (12). Diagnosis of DCI is made almost entirely on history and clinical examination (1,2,11,12). Indeed, in the case of divers, diagnostic tests frequently do not influence treatment choices and should not postpone definitive treatment (12). Inman AL et al. suggest that the absence of symptoms following recompression with HBO₂ therapy supports the diagnosis of DCS (13). Our patient herein was 38-years-old woman, recreational diver, smoker, that was diagnosed DCS Type 2 according to the clinical manifestations and history data. She developed DCS while being on a diving vacation in the Maldives. Her first symptoms were cutaneous manifestation known as cutis marmorata and fatigue. She attributed the symptoms to sunburn and tiredness. Kerut C et al. say that cutis marmorata is often associated with a more serious background like neurological symptoms or atrial level shunt, mostly PFO (14). Our patient did not have neurological manifestations, neurologic physical examination showed no abnormalities, Romberg test was negative. Echocardiography was suggested, but the patient refused to conduct it. Her situation worsened after exposure because of the changes in ambient pressure in dives and flight transfers. According to DAN recommendations for flying after diving it was advised that a single no-decompression dive be followed by a minimum 12-hours surface break, a surface interval of at least 18 hours while diving repeatedly over several days and significantly more than 18 hours after diving with mandatory decompression, or while using heliox and trimix (15). The pre-flight surface period in our case was correct according to DAN, but she had already developed symptoms which worsened due to the flight. Lee S W et al reported that shortness of breath, dyspnea, and cough are typical symptoms of exceptionally high loads of gas microemboli in the pulmonary arteries (so-called “chokes”). Substernal chest pain, which is sometimes described as burning, is another common symptom (16). This is a rare, but serious manifestation of DCS. Our patient had intense chest pain and dry irritating cough, but she had a good saturation with oxygen on admission and remained hemodynamically stable, without any signs of hypoxemia or hypotension. Thrombocytopenia and elevated D-dimer were noted. Treatment with hyperbaric oxygen according to US Navy treatment Table 6 is recommended for both decompression sickness and arterial gas embolism. It reduces bubbles’ size while boosting the gradients in inert gas partial pressure between tissue and alveolar gas, which leads to redistribution and resolution of bubbles trapped in the microcirculation (2, 11, 12). The likelihood of a good recovery is considerably increased by early recompression treatment considered Tawar et al. (9). On the other hand, Hadanny A et al., Inman AL et al. reported in their research that the findings show that hyperbaric treatment, even though delayed, still has significant clinical value and can result in full recovery in 76% of divers, similar to earlier treatment. Indeed, in comparison to the early treatment group, there was no discernible difference (13, 17). Although our patient was delayed with her first medical examination due to late recognition of DCS and delayed with her first treatment, she responded positively to the therapy with hyperbaric oxygen, NSAIL, crystalloids and enoxaparin sodium. She had complete resolution of symptoms with recompression therapy 12 days after the symptom onset.

Conclusion

DCS needs to be suspected anytime a scuba diver experiences any signs of DCS even when followed by appropriate decompression schedules, especially if they have air travel planned. Cutis marmorata is often associated with more serious manifestations of decompression sickness. Treatment with hyperbaric oxygen is the cornerstone therapy for DCS. Indeed, treatment with hyperbaric oxygen can be successful even in cases with delayed start of treatment.

References

1. Zhang XC, Golden A, Bullard DS. Neurologic Deep Dive: A Simulation Case of Diagnosing and Treating Decompression Sickness for Emergency Medicine Residents. *MedEdPORTAL J Teach Learn Resour.* 2016 Sep 28; 12:10473.
2. Moon RE, Mitchell SJ. Hyperbaric oxygen for decompression sickness. *Undersea Hyperb Med J Undersea Hyperb Med Soc Inc.* 2021;48(2):195–203.
3. de la Cruz RA, Clemente Fuentes RW, Wonnum SJ, et al. Aerospace Decompression Illness. In: *StatPearls [Internet]. Treasure Island (FL): StatPearls Publishing; 2023 [cited 2023 May 30]. Available from: <http://www.ncbi.nlm.nih.gov/books/NBK448160/>.*
4. Cooper JS, Hanson KC. Decompression Sickness. In: *StatPearls [Internet]. Treasure Island (FL): StatPearls Publishing; 2023 [cited 2023 May 30]. Available from: <http://www.ncbi.nlm.nih.gov/books/NBK537264/>.*
5. Saadi A, Ferenczi EA, Reda H. Spinal Decompression Sickness in an Experienced Scuba Diver: A Case Report and Review of Literature. *The Neurohospitalist.* 2019 Oct;9(4):235–8.
6. Shosholcheva M. Physics for anesthesiologist. 2014. 59–67 p.
7. Yao CK, Huang KL, Peng CK. Near-Fatal Air Travel after Diving: A Case of Impending Tension Pneumothorax on an International Flight. . Vol. 33(6).
8. St Leger Dowse M, Howell S, Smerdon GR. Flying after diving: a questionnaire-based evaluation of pre-flight diving behaviour in a recreational diving cohort. *Diving Hyperb Med.* 2021 Dec 20;51(4):361–7.
9. Tawar A, Gokulakrishnan P. Decompression Illness. *J Mar Med Soc.* 2019 Dec;21(2):112.
10. Okeya K, Suzuki S, Koyama Y, Inoue Y. Urticaria-like decompression illness in a caisson worker treated successfully in a monoplace chamber. *Acute Med Surg.* 2022;9(1) :e808.
11. Vann RD, Butler FK, Mitchell SJ, et al. Decompression illness. *The Lancet.* 2011 Jan 8;377(9760):153–64.
12. Mitchell SJ, Bennett MH, Moon RE. Decompression Sickness and Arterial Gas Embolism. *N Engl J Med.* 2022 Mar 31;386(13):1254–64.
13. Inman AL, Sorrell LP, Lagina AT. Decompression sickness responsive to delayed treatment with hyperbaric oxygen: a case report of two divers. *Undersea Hyperb Med.* 2020 Jan 1;47(4):551–4.
14. Kerut, C. K., Serio, J. R., & Kerut, E. K. (2019). Cutis marmorata in decompression sickness is associated with a patent foramen ovale. *Echocardiography.* doi:10.1111/echo.14360 10.1111/echo.14360 .
15. Divers Alert Network (DAN). Decompression sickness. 2019. Available at: [https://dan.org/health-medicine/health-resource/health-safety-guidelines/guidelines-for flying-after-diving/](https://dan.org/health-medicine/health-resource/health-safety-guidelines/guidelines-for-flying-after-diving/) .

16. Lee, S. W., Shim, S. S., Choi, J., et al. (2013). Pulmonary Involvement in Decompression Sickness of a Self Contained Underwater Breath Apparatus Diver. *The Korean Journal of Sports Medicine*, 31(1), 30. doi:10.5763/kjasm.2013.31.1.30 10.5763/kjasm.2013.31.1.30 .
17. Hadanny A, Fishlev G, Bechor Y, et al. (2015) Delayed Recompression for Decompression Sickness: Retrospective Analysis. *PLoS ONE* 10(4): e0124919. doi:10.1371/journal.pone.0124919 .

ANESTHESIA IN PATIENT WITH SJÖRGEN'S SYNDROME

Trojickj T^{1,2}, Krалеva S¹, Spasovski Z¹, Bozinovska Beaka G^{1,2}, Markovska Z¹, Pavlova Bogoevska N¹

¹ City general Hospital "8 Septemvri", Skopje, Republic of North Macedonia

² University "Goce Delchev", Shtip Republic of North Macedonia

ABSTRACT

Sjögren's syndrome is a chronic, systemic disorder of autoimmune nature, characterized by exocrine glands disorder mostly resulting with eyes and mouth dryness, but can be associated with multiple organ dysfunction. Fibrotic changes in lungs and heart problems are main concerns for general anesthesia, and patients with this syndrome should be carefully evaluated before operation for ensuring maximal patient's safety and stability.

Key Words: *eyes and mouth dryness, pulmonary fibrosis, Sjögren's syndrome.*

Introduction

Patient S.D., female, 62 years old (163cm, 75kg) came to our hospital, complaining about abdominal discomfort, nausea and weight loss. She had gastroscopy and biopsy confirmed Ventricular Carcinoma and scheduled for surgery.

During preoperative evaluation and examination, we were given anamnestic information about Systemic Lupus Erythematosus (SLE) diagnosed six years before, treated with Prednisolone (Decortin), Tocilizumab (Actemra), Methotrexat, Vit B12 and Iron supplement. She used to take these medications regularly. After a couple of years, she noticed swallowing difficulties, dry mouth and eyes and further examinations were made. Sjögren's syndrome was confirmed after receiving positive results for anti-Ro/SSA and anti-La/SSB.

A few months after, she had an eye operation and lacrimal gland was removed. There was a vision lost in that eye. Because of eye dryness she regularly uses artificial lacrimal moisturizing eye drops four times a day. Mouth dryness results with rhagades and extreme food swallowing difficulties. During further investigations she was diagnosed with giant cell arteritis (gigantocellular changes in arterial vessels) and changes in lungs with conformation of pulmonary fibrosis. The cardiologist was consulted for heart problems (tachyarrhythmia, fatigue, hypertension) and she was prescribed therapy with beta blockers and ACE inhibitors. Very often patients with Sjogren's Sy have arrhythmia, and these patients also are prone to develop heart failure and sudden heart arrest.

Management of Anesthesia

In perioperative period laboratory tests, electrocardiogram and chest x-ray were performed. In the operating theater we were monitoring non-invasive blood pressure, ECG and pulse oximetry. Initial blood pressure was 140/95, pulse 100/min, she was breathing regularly and had peripheral saturation of 96.

She was placed in the right lateral decubital position, and we performed insertion of an epidural catheter with medial approach on Th 9-10 intervertebral disk space.

Pure oxygen (5 l/min) was supplied via facial oxygen mask for preoxygenation. Induction in anesthesia was accomplished with Propofol 2mg/kg, Fentanyl 100µg. The patient was intubated after intravenous Rocuronium was given. During anesthesia we applied Propofol 200mcg/kg/min immediately after intubation, but we decreased the dose to 50mcg/kg/min. We didn't use volatile anesthetics or Nitroxide. We used epidurally continuous infusion of 20ml Bupivacaine 0,125% with 50mcg Fentanyl with rate 5-10ml/hour. We also used continuous intravenous Remifentanyl in dose 2g diluted in 40ml 0,9% NaCl at rate of 10ml/h. Atropine was avoided. Saline solution was installed on eyes and mouth every 15-20 minutes. It was necessary to use heat and moisture exchanger to obtain and maintain moisture in the respiratory tract. Vital signs were stable during the operation.

Operation

Gastrectomia total, Esophago-jejuno T-L stapler anastomosis, Jejun-jejunal anastomosis sec. Braun Lavage. Drainage.

Because of the giant cell arteritis, the operation was performed very carefully. After the operation we extubated the patient immediately and the pain score in VAS scale was 3-4.

The patient was transferred to the ward for the following day and dismissed from the hospital after 7 days.

Discussion

Sjögren's syndrome is a chronic, systemic disorder of autoimmune nature associated with recessive genetic background that mostly affects women (female: male ratio is 9:1). Patients with Sjögren's syndrome usually have infiltration of lymphocyte in salivary and lacrimal glands. They are also characterized by B-cell hyperactivity, which is manifested with presence of serum immunoglobulins and antibodies that are acting against Ro/SSA, La/SSB.

In 1 to 3% of general population, Sjögren's syndrome is primary disease associated with oral and/ or eye dryness, neuro-cutaneous disorder manifested as congenital ichthyosis, spasticity of muscles, intellectual disability, seizures and ophthalmological changes.

Ten to twenty percents of patients with Rheumatoid Arthritis, Systemic Lupus Erythematosus and Scleroderma can develop secondary Sjögren's syndrome. Detailed examination and evaluation of medical history should be taken before operation. It is very important to have a proper physical examination. Very often an echography of abdominal organs is necessary. Chest radiography and detailed biochemical investigation should be done prior anesthesia.

Sjogren's syndrome has slowly progression and most of the patients have only lacrimal and saliva glands symptoms. Some patients (about 30%) can develop general signs, including neurological dysfunction, such as autonomic nervous system dysfunction, seizures, movement disorder, ataxia, insensitivity to pain, hyporeflexia, paraparesis and quadriparesis. Patients can be

immunologically compromised. They are associated with abnormality in pharyngeal function, pulmonary interstitial-like changes, distal renal tubular acidosis, gastrointestinal changes such as atrophic gastritis and celiac-like disease, and other skin and vascular changes. These patients are connected to higher incidence of lymphoma that can increase mortality.

Conclusion

Sjögren's syndrome in the adult population is characterized by changes in exocrine glands. Lung fibrosis is main concern for the anesthesiologist. When patients with Sjögren's syndrome go under operative treatment, it is suggested that they should be evaluated whether ventilation and oxygenation are sufficient, prior to induction in anesthesia. Fibrotic changes in lungs and dryness of eyes and mouth, as well as changes in blood vessels are primary challenges that should be considered as soon as we are making plan for operative treatment of the patient. Preventing keratoconjunctivitis should be managed with protection of the eyes and regular corneal humidification. It is recommended to avoid dryness in the respiratory tract by using fresh gases that are humidified. Anesthetic agents must be applied slowly and complete monitoring must be used because of a high incidence of autonomic nervous system instability. Patients are supposed to take their therapy regularly, including the morning of the surgery. We must try to avoid parasympatholytic and anticholinergic drugs in order to prevent decrease in secretions of the lacrimal and saliva glands.

It is very difficult to manage children population, as well as a newborn babies from mothers with primary Sjögren's Sy, because of the potential risks of existence of congenital heart block, large joints dislocation, palatal defect and difficult laryngoscopy.

References

1. Marcellene H Franzen, Michelle M LeRiger Kaitlyn P Pellegrino et al. Sjögren-Larsson syndrome: Anesthetic considerations and practical recommendations Paediatr Anaesth 2020 Dec;30(12):1390-1395.
2. Hong JM, Kim E, Kim HK, et al. Combined spinal-epidural anesthesia for radical hysterectomy in a patient with Sjögren syndrome with progressive interstitial lung disease. Springerplus. 2016 Oct 6;5(1):1737.
3. Bissonnette B, Luginbuehl I, Marciniak B, et al. eds. Syndromes: Rapid Recognition and Perioperative Implications. McGraw Hill; 2006. Accessed July 13, 2023.

THE THREE REVOLUTIONS IN AIRWAY MANAGEMENT

Biljana Shirgoska

ENT University Clinic, Medical Faculty, "Ss. Cyril and Methodius" University, Skopje, Republic of North Macedonia

Airway management is the base of anesthetic practice, and the anesthetic devices innovations in the past 39 years have had big impact on many aspects of the airway management.

Securing the airway in a safe way is the most important in anesthetic practice. This applies to a routine of difficult intubations, anticipated or unanticipated (1).

Numerous new airway devices are available on the market. The aim of their use in everyday clinical practice is to facilitate airway management in a safe way.

The introduction of the laryngeal mask airway (LMA) in clinical practice played an important role in airway management. LMA found its use in everyday clinical practice, but also as a rescue device in the 'cannot intubate, cannot ventilate' scenario.

Archie Brain's description of the classic laryngeal mask airway (cLMA) in 1983 was the first revolution in safe airway management (2).

The first generation of laryngeal masks, the classic one (cLMA), was being used for hundred years in almost one third of cases with a success rate of 99.8%. The second and the third generation of laryngeal masks allowed more frequent use of laryngeal mask airway as a safe airway establishment device in surgical procedures, like bariatric surgery. The third generation of laryngeal masks is designed for quality ventilation at intensive care patients.

Dr. Brimacombe emphasizes that the LMA is not just an airway device, but it is a new approach to anesthetic management that has improved patients' comfort and safety (3).

Regarding too difficult airway, the intubating LMA (iLMA) is a supraglottic device that finds its place in the difficult airway algorithm. It is used for the first intubation as a blind technique, and it is still using as a blind technique for trauma patients, in emergency medicine, but as the device it can be used in combination with fiber optic bronchoscope. The third generation of laryngeal mask airway can be used for tracheal intubation in many clinical scenarios nowadays.

There is no contraindication for laryngeal mask airway use, except supraglottic pathology in the upper airway.

The second revolution in airway management and the most exciting one was videolaryngoscopy as innovation (4).

Video laryngoscopy has big potential to facilitate intubation, compared to standard direct laryngoscopy as the most safety device. A further exciting development, speaking about airway

devices, was the introduction into clinical practice of a number of indirect video laryngoscopes that allow a non-line-of-sight view of the larynx. All of them have an intense light source and a fiberoptic camera built into the laryngoscope blade. The fiberoptic system relays the image of the larynx from beyond the curvature of the blade and on to an external monitor.

Video laryngoscopes can be classified into two categories, channeled or non-channeled. Video-laryngoscopy is a diagnostic and therapeutic tool in head and neck surgery, too. Video-laryngoscopy is an excellent tool for education and medico legal recording (5).

Studies about the success of tracheal intubation by video laryngoscopy, present that it has 98% - 99% effectiveness. Still, we need more studies for intubation difficulty, necessary time to intubation, or the success rates of training doctors and medical students (6).

A retrospective analysis by the Multicenter Perioperative Outcomes Group⁴⁴ reported 92% success using a video laryngoscope as a rescue device after failed intubation.

Video laryngoscope can be used for anticipated and unanticipated difficult airway management. A Cochrane Review comparing video laryngoscopy to direct laryngoscopy, reported fewer failed intubations in anticipated difficult airway patients in video laryngoscope's group (7, 8).

Awake video laryngoscopy intubation has advantage over fiber optic tracheal intubation in patients with anticipated airway (9). The advantages of awake video laryngoscopy intubation over awake fiberoptic intubation are: awake video laryngoscopy intubation is faster technique of establishing of the airway; The 'screen' offers a larger field of view, improving the recognition of airway anatomy and direct observation of actions in the airway of all doctors involved in the procedure; The upper airway can be examined after the intubation that can be helpful in cases where the risk of bleeding is high, like the presence of a tumor in the upper airway.

There are some limitations for awake video laryngoscopy intubation. This technique cannot be used when mouth opening is limited, awake nasal fiberoptic intubation is still essential. However, awake video laryngoscopy would be entirely appropriate in patients who were difficult to mask ventilation (10), as well as the obese patients with difficult airway (11).

The third revolution in airway management is ultrasonography of the upper airway.

Upper airway ultrasound can be used for evaluation and management of the upper airway, in patients with existing pathology at upper airway, even with distorted anatomy by pathology or trauma. Ultrasound enables clinicians to identify anatomy of the upper airway, such as: thyroid cartilage, epiglottis, cricoid cartilage, cricothyroid membrane, tracheal cartilages and esophagus. Numerous studies have described various roles of ultrasound imaging in airway management in the last 10 years. It helps in rapid assessment of the airway anatomy in the operating theater, intensive care unit and emergency department (12).

We can use ultrasound for laryngeal mask placement, too. We are able to visualize the depth of the tracheal tube and the assessment of airway size. Ultrasound-guided invasive procedures such as percutaneous needle cricothyroidotomy and tracheostomy could also be performed using this technique.

Ultrasonography can be utilized to predict airway difficulty during induction of anesthesia and post extubating problems, as well. Ultrasound can be used for evaluation if the stomach is empty or possesses gastric content that poses an aspiration risk. It is a useful device to perform nerve blocks for awake intubation and confirm tracheal or oesophageal intubation. The technique can facilitate localization of tracheal rings for tracheostomy and localization of laryngeal trauma (13, 14). Furthermore, it can be used for prediction of left double-lumen bronchial tube size and for detection of the upper airway pathologies.

Advantages of ultrasound of the upper airway are the following: it is noninvasive and simple procedure that gives us valuable information of the airway. It has some limitations. The interpretation of ultrasound images requires a basic understanding of the physical principles involved in ultrasound image generation. Transducer selection, orientation and anatomy of the airway relevant to ultrasound imaging require a proper training for the clinical doctors who want to evaluate the upper airway anatomy by this technique (15).

Despite these revolutions, there is no perfect airway management device or technique designed yet. Everyone involved in airway management should be familiar with several devices and techniques, because if a difficult airway problem appears, it has to be managed in a safe manner. We are living in the era of modern technologies and newly designed devices and new techniques for their clinical use that are very helpful in everyday clinical practice.

References:

1. McNarry AF, Patel A. The evolution of airway management – new concepts and conflicts with traditional practice. *British Journal of Anaesthesia*, 119 (S1): i154–i166 (2017) doi: 10.1093/bja/aex385.
2. Brain AIJ. The Laryngeal Mask—a new concept in airway management. *Br J Anaesth* 1983; 55: 801–6 2.
3. Brimacombe JR. *Laryngeal Mask Anesthesia Principles and Practice*, 2nd Edn. Saunders, Philadelphia: Elsevier, 2005.
4. Cooper RM. Use of a new videolaryngoscope (GlideScope) in the management of a difficult airway. *Can J Anaesth* 2003; 50: 611–3.
5. Goranovic T. Videolaryngoscopy, the Current Role in Airway management. *Special Considerations in Human Airway Management*. Nabil A Shallik. 2020. DOI: 10.5772/intechopen.93490.
6. Ahmad I, Bailey CR. Time to abandon awake fiberoptic intubation? *Anaesthesia* 2016; 71: 12– 16.
7. Marshall SD, Pandit JJ. Radical evolution: the 2015 Difficult Airway Society guidelines for managing unanticipated difficult or failed tracheal intubation. *Anaesthesia* 2016; 71: 131– 7.
8. Lewis SR, Butler AR, Parker J, et al. Videolaryngoscopy versus direct laryngoscopy for adult patients requiring tracheal intubation. *Cochrane Database of Systematic Reviews* 2016; 11: CD011136.
9. Wilson W.M.A., Smith F. The emerging role of awake videolaryngoscopy in airway management. *Anaesthesia* 2018; 73: 1151-61.
10. Nørskov AK, Wetterslev J, Rosenstock CV, et al. Prediction of difficult mask ventilation using a systematic assessment of risk factors vs. existing practice—a cluster randomised clinical trial in 94,006 patients. *Anaesthesia* 2017; 72: 296–308.

-
11. Ander F, Magnuson A, Berggren L, et al. Time-to-intubation in obese patients. A randomized study comparing direct laryngoscopy and videolaryngoscopy in experienced anaesthetists. *Minerva Anesthesiol* 2017; 83: 906–13.
 12. Osman A, Sum KM. Role of upper airway ultrasound in airway management. *Journal of Intensive Care* (2016) 4:52 DOI 10.1186/s40560-016-0174-z.
 13. Kristensen MS, Teoh WH, Graumann O et al. Ultrasonography for clinical decision-making and intervention in airway management: from the mouth to the lungs and pleurae. *Insights Imaging* (2014) 5:253–279 DOI 10.1007/s13244-014-0309-5.
 14. Osman A, Sum KM, Ahmad AH, et al. Novel role of focused airway ultrasound in early airway assessment of suspected laryngeal trauma. *The Ultrasound Journal* volume 12, Article number: 37 (2020).
 15. Kundra P, Kumar MS, Ramesh A. Ultrasound of the upper airway. *Indian J Anaesth.* 2011 Sept-Oct, 55(5): 456-462.

GUIDELINES FOR AUTHORS

Macedonian Journal of Anaesthesia (MJA) is a scientific journal of the Macedonian Society of Anaesthesia (MSA) and Macedonian Society of Critical Care Medicine (MSCCM). The aim of this specialized medical journal is to speed and promote scientific achievements, novelties, clinical experience's, reviews, controversial topics in anesthesia, reanimation and intensive care, as well as other correlated medical branches.

The Journal is published four times a year (April, June, October and December), but additional supplements might be published when needed. MJA publishes original articles in basic and applied research, review articles, case studies, therapeutic and technological innovation, discussions, critics, surveys, impressions from meetings, information for international conferences and reviews of new books or variate.

Manuscripts that are published should have not been published previously. Manuscripts that have been previously published only in form of abstracts are eligible for publishing in the journal but should be followed by additional letter send to the Editor, where the abstract details are noted (abstract number, which book of proceeding or doi, date and place).

The authors are responsible for respecting the ethical guidelines for medical researches, as well as for all that is explained, attitudes, analyses and shown results.

The redaction sends the manuscripts to anonymous reviewing process from international or domestic reviewers and the Editors determine the definitive categorization of the manuscript. Once reviewed manuscript together with the reviewers' remarks is send back to the corresponding author, after what the author is omitted to deliver the final form of the manuscript to the Editorial board within one week.

Editorial board has the right to publish the manuscripts according to the reviewer's priority. The order in which the manuscripts are published does not reflect the scientific value of the article. The Editorial board keeps the rights to make changes to the manuscript to fulfil the criteria.

MANUSCRIPT PREPARATION

Manuscript should be sent together with the accompanying letter from the corresponding authors where declaration that the text has not been published previously is signed. Additional conflict of interests and confirmation by all the authors should be declared in this letter (example: Annex no. 1).

The guidelines for authors adhere to the uniform Requirements for Manuscripts submitted to Biomedical Journals: www.nlm.nih.gov.

Language and style of the manuscripts should be clear, simple to according the language, anesthesiological and medical taxonomy.

The manuscript has to be written in **English Manuscripts** should be written in **Microsoft Word** (*.doc format) with **Times New Roman** font and **size 12**. Margins on left, up and bottom should be 3 cm and right margin should be 2,5 cm.

The inline space should be 2. Do not use Bold or Italic letters for the whole text (only for parts that have to be emphasized). Manuscript should not exceed 10 pages (without the references).

Abbreviations and correct medical terms should be used according to the International Committee of Editors of Medical Journals (<http://www.icmje.org>). Use only standard abbreviations; use of nonstandard abbreviations can be confusing to readers. Avoid abbreviations in the title of the manuscript. The spelled-out abbreviation followed by the abbreviation in parenthesis should be used on first mention unless the abbreviation is a standard unit of measurement.

MANUSCRIPT SECTIONS

Manuscript should be organized in:

- Title page
- Text organized in IMRaD
- Acknowledgments
- Authors Contribution
- References

Review articles, case reports, therapeutic and technological innovation, discussions, critics, impressions from meetings, information for international conferences and reviews of new books or variate may be written in different sequences and manners.

TITLE PAGE

The title of the manuscript written in CAPITAL LETTERS.

Authors Surname and Name initial (Jovanov J, maximum 6 authors), without academic or other titles.

Name and address of the institution where the authors come from whit the subscribed digits

Abstract in English. Abstract should include up to 250 words and should contain goals of the paper, important elements from the methodology, concisely displayed results and conclusion. Each abstract at the end must have **Key words:** in alphabetical order.

TEXT

- Introduction
- Matherial and Method,
- Results
- Discussion
- Conclusion

Review articles, case reports, therapeutic and technological innovation, discussions, critics, impressions from meetings, information for international conferences and reviews of new books or variate may be written in different sequences and manners.

Introduction section should include a literature overview in relevance to the elaborated problem. In this sections 3-5 key references are cited and this section should not be longer than 2 pages.

Material and method sections includes detailed description of the performances in the research as well as the statistical analyses used. This section should include: time during what the research was conducted, type of the study, place of where the research was undertaken, randomization or stratification used (clear description of the examined groups), exclusion and inclusion criteria, method, analysis types, apparatus and instruments used and referent values of the examined features (in SI-International System units).

Results are displayed in simple manner with text, images, tables and charts that are submitted in the text where author wants to stand, titled and numbered appropriately. Additionally, on separate document all carts images and tables are send together with the manuscript.

Title and the number of the charts and tables are placed above them while the explanations, abbreviations and comments are placed below. Images title and number is placed below and the image should include proper explanation.

Discussion section emphasize the key finding of the actual research and compares these result to other relevant literature data.

Conclusion section should not include more than 150 words and shoul be drown from the relevant elaborated results.

Acknowledgment and Author contributions sections are displayed after the conclusion and before the reference section.

REFERENCES

This sections include only the cited references. **The references** are listed in order of appearance in the paper and the citation is standard numbers enclosed in small brackets in the same line with the text ().

For each reference if more than three authors appear provide the names of the first three authors and followed by **et al.**

1. Examples:

Journal references:

Nirmala BC, Kumari G. Foot drop after spinal anaesthesia: a rare complication. *Indian J Anaesth.* 2011; 55: 78 – 79.

Lynch EP, Lazor MA, Gellius JE, et al. The Impact of Posoperative Pain on the Development of Postoperative Delirium. *Anesth Analg* 1998; 86:781-785.

2. Journal supplements:

AzmanJ, Frkovic V, Bilic L, et al. Korelacija I regresija. *Acta Med Croat* 2006;60 (suppl I):81-89. | 70 |

3. Books

Brown, D.L. Spinal, epidural, and caudal anesthesia. In R.D. Miller Miller's Anesthesia, 6th edition. Philadelphia: Elsevier Churchill Livingstone; 2005.p 98-198

4. Doctoral or master thesis

Jelisavac Cosic S. Urokinazni I tkivni aktivator plazminogena i njihov inhibitor u raku dojke (Master thesis). Zagreb: Farmaceutsko-biohemijski fakultet 2004, p.50

5. Electronic reference

Dag Stat. Mackinnon A. Available from: <http://www.mhri.cdu.au/biostats>. Accessed May 5th 2006.

Webster NR. The anaesthetist as peri-operative physician. *Anaesthesia*. <http://dx.doi.org/10.1046/j.1365-2044.2000.01722.x>

References used from abstracts are marked as (abstr)., and from letters with (letter)

MANUSCRIPT SUBMISSION

Prepared manuscript should be submitted electronically to:

macedoniananesthesiology@gmail.com.

All manuscripts that don't fulfill the above criteria will not be accepted for reviewing

Accompany letter ANNEX no. 1


I _____ . Here by declare that the article _____ (NAME OF THE ARTICLE) has not been previously published (fully or partialy) previously.

Weauthors _____

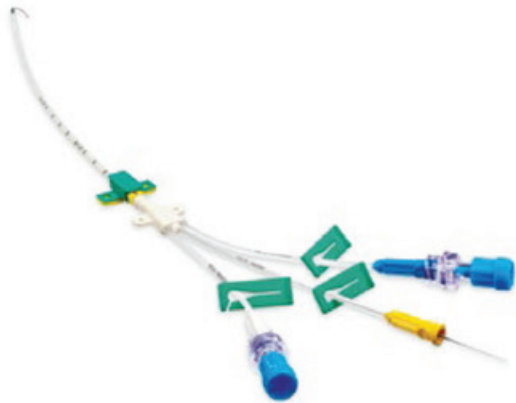_____ (FULL NAME AND SURNAMES OF THE AUTORS AND SIGNATURES) are responsible for the etic, profesional and scientific content of the study.

I _____ (THE FIRST AUTHOR FULL NAME) declare Conflict of interest or declare non Conflict of interest.

_____ (FIRST AND SURNAME OF THE CORESPONDING AUTHOR, (ADDRESS),, (TELEPHONE NUMBER), E-MAIL



Превенција на инфекции Certofix® protect



DR. PANOVSKI

Скупи 3 бр.55, 1000 Скопје, Р.Македонија
тел: +389 2 3093.600 • факс: +389 2 3093.610
e-mail: panovski@drpanovski.com.mk



Atlan, The new Family member in Anesthesia
Protective therapies: patient protection & patient safety

Protective Therapies

Connected Technologies

Care-Centred Workplaces

Comprehensive Services

It is all about Improving Acute Care!

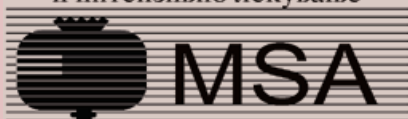
LUNG DECK

CONNECT DECK

CYBER DECK

INFECTION DECK

Здружение на лекарите по
анестезија, реанимација
и интензивно лекување



Macedonian Society of Anesthesiologists
and Intensive Care Medicine



Здружение на лекари за
критично болни пациенти