

OUTCOME EVALUATION OF ARTHROSCOPIC RESECTION OF DORSAL WRIST GANGLIA

Katerina Kasapinova¹, Viktor Kamiloski¹, Emilija Atanasovska², Katerina Spasovska³

¹ Medical Faculty, University "St.Cyril and Methodius", University Surgery Clinic "St.Naum Ohridski", Department of Traumatology, Skopje, RN Macedonia

² Medical Faculty, University "St.Cyril and Methodius", Institute for pharmacology and toxicology, Skopje, RN Macedonia

³ Medical Faculty, University "St.Cyril and Methodius", University Clinic for Infectious Diseases, Skopje, RN Macedonia

Corresponding author: Katerina Kasapinova, Email: kasapinovakaterina@yahoo.com, +38923235014, University Surgery Clinic "St.Naum Ohridski", 11 Oktomvri 53, 1000 Skopje, Republic of North Macedonia

ABSTRACT

Goals: Arthroscopic ganglionectomy has become an increasingly popular surgical option for dorsal wrist ganglia. The aim of this study was to describe our technique for the arthroscopic treatment of dorsal wrist ganglia and to evaluate the clinical results as well as the recurrence rate in our patients.

Methods: In a prospective study, 48 patients who underwent arthroscopic treatment of dorsal ganglion of the wrist were included. Patients were evaluated preoperatively and 3 and 24 months post arthroscopy. A presence of recurrence at 24 months was recorded. The subjective outcome was evaluated with The Patient-Rated Wrist Evaluation (PRWE) and the Visual analog scale (VAS). Objective outcomes included grip strength and range of movement measurements.

Results: The mean age was 36 years; the majority were women (36/48). Mean grip strength and the average flexion and extension in the wrist showed improvement after 3 months. The total PRWE score improved from 26.7 preoperatively to 10.2 at three months and 2.4 two years after surgery. After 24 months follow-up, there were only two patients with recurrence (4.2%).

Conclusion: The arthroscopic resection of the dorsal wrist ganglia is a procedure with a low recurrence rate and lowest scarring and stiffness; it should be considered as a golden standard for operative treatment of the dorsal wrist ganglia.

Keywords: Dorsal ganglion, Wrist arthroscopy, Arthroscopic ganglionectomy

INTRODUCTION

Ganglia are the most common benign soft tissue masses around the wrist, usually on the dorsal aspect (60-70%). Around 13-20% are on the volar side, and they rarely arise around tendon sheets (10%) or are intraosseous [1-3].

They can be asymptomatic, but they can also cause pain and functional impairment, and most often aesthetic discomfort, especially because they are typically found in young women [1, 2].

Dorsal wrist ganglia are commonly mis-called "synovial cysts" or simple joint herniation, but that concept is difficult to support since no synovial lining exists in these structures and the cystic fluid is different biochemically than the intra-articular synovial fluid [4]. In 44% of patients with dorsal wrist ganglion, a connection with the underlying joint was demonstrated with movement of the intra-articular contrast from the radiocarpal

joint into the ganglion through a one-way valve mechanism [5]

The presence of the dorsal capsulo-scapholunate septum (DCSS) has been proven by recent cadaveric studies [6, 7]. An MRI study by Garret, conducted on 42 patients, showed that the origin of the dorsal wrist ganglion is always in the DCSS [8], from there, the ganglion extends with a pedicle, proximally beneath the dorsal radiocarpal ligament (radiocarpal presentation), or distally beneath the dorsal intercarpal ligament (midcarpal presentation). It is important to identify the exact presentation of the ganglion in order to plan the arthroscopic procedure [9].

Treatment of the dorsal ganglia has been controversial. Non-surgical treatment is unreliable with high recurrence rates [1-3]. Surgical resection is the most "effective" treatment but the classical open surgical excision leads to unsightly scars and poorer outcomes (joint stiffness and high recurrence rates) [2, 3, 10]. Recently developed techniques for arthroscopic resection have shown very promising results with lower recurrence rates [10, 11, 12, 13, 14]. Arthroscopic resection of dorsal wrist ganglia of the wrist was first described by Osterman and Raphael in 1995 [15].

The aim of this study was to describe the technique for arthroscopic treatment of the dorsal wrist ganglia that we used and to evaluate the clinical results, as well as the recurrence rate in our patients.

PATIENTS AND METHODS

Patient selection

We conducted a prospective, single-center study of patients who underwent arthroscopic treatment of their dorsal ganglion of the wrist (2012-2016). The inclusion criteria were: symptomatic dorsal wrist ganglia (including occult ones) in adults aged over 16 years needing operative treatment of the ganglion. The exclusion criteria were: bilateral wrist ganglia and contraindications for wrist arthroscopy (local infection, problems positioning for vertical traction). In all patients, standard wrist x-rays were done (to exclude any osseous pathology) and an MRI of the wrist (to help determine the exact position of the ganglion regarding the midcarpal and radiocarpal joint). All patients gave their written informed

consent and the study obtained approval from the ethical committee of the clinic.

Operative treatment

All the operations were performed by the first two authors of the study. Arthroscopic procedure was performed according the standardized protocol. The patient was positioned supine (general anesthesia), hand was abducted, a pneumatic tourniquet applied. Wrist distraction was achieved using a mechanism for vertical wrist traction with finger traps. A 2.7mm, 30-degree-angle arthroscope was used. At the beginning the ganglion was clearly marked, because later during the procedure it is not that well recognizable. Skin incisions for portals were vertical, 2mm long. Initially, the arthroscope was introduced through the dorsal MCU portal (Figure 1) and the midcarpal joint was explored, the dorsal stamp of the ganglion and the overlying synovitis were identified. Then an additional trans-cystic portal (corresponding to the MCR portal) was created; first with the needle, than with a mosquito hemostat (Figure 2a,b). A small joint shaver was placed through this portal to help clear the dorsal synovitis and excise the capsule providing wide communication with the ganglion itself. We needed to identify and protect the scapholunate ligament throughout the whole procedure. The time needed for shaving is quite long; we should be patient, as it can take 15-30 minutes. Luchetti recommended that a diameter area of 1.5 cm dorsal capsule should be resected [13], although most studies concluded 1 cm² is sufficient [9, 14, 15]. We aimed to make a 1cm hole in the dorsal capsule. An essential part of the surgical treatment is to excise the attachment or stamp of the ganglion. At the end of the procedure, the underlying extensor tendons should be identified and cleared of any remaining capsular and ganglion tissue (Figure 3). For ganglions with predominant radiocarpal presentation, the same procedure was performed but through the 3-4 and 6R portals. The portals were sutured in some of the patients, in others they were covered with Steristrips, and a bulky dressing was applied.

Postoperative interventions

Immediately postoperatively, the patients were instructed (and also received a printed instructions) for at home digits, elbow, and shoulder exercises. No immobilization was applied. Sutures were removed 7-10 days after surgery.

Figure 1. *Dorsal ganglion marked and arthroscope introduced through the MCU portal*

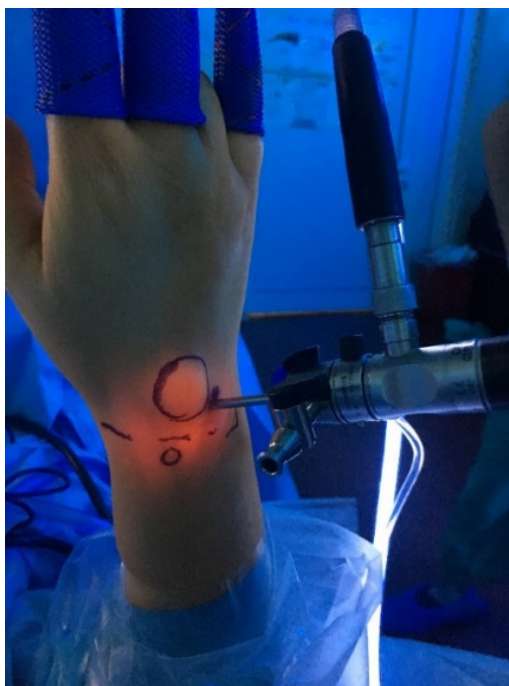
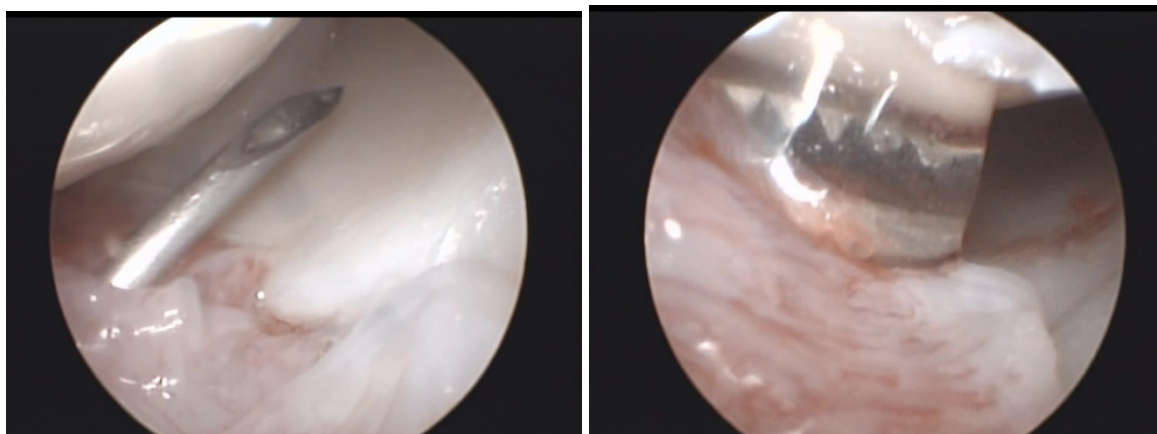


Figure 2. *Needle introduced trans-ganglion to identify the working portal. Dorsal synovitis overlying the ganglion stump is seen(a). Trans-cystic portal created with a hemostat (b)*



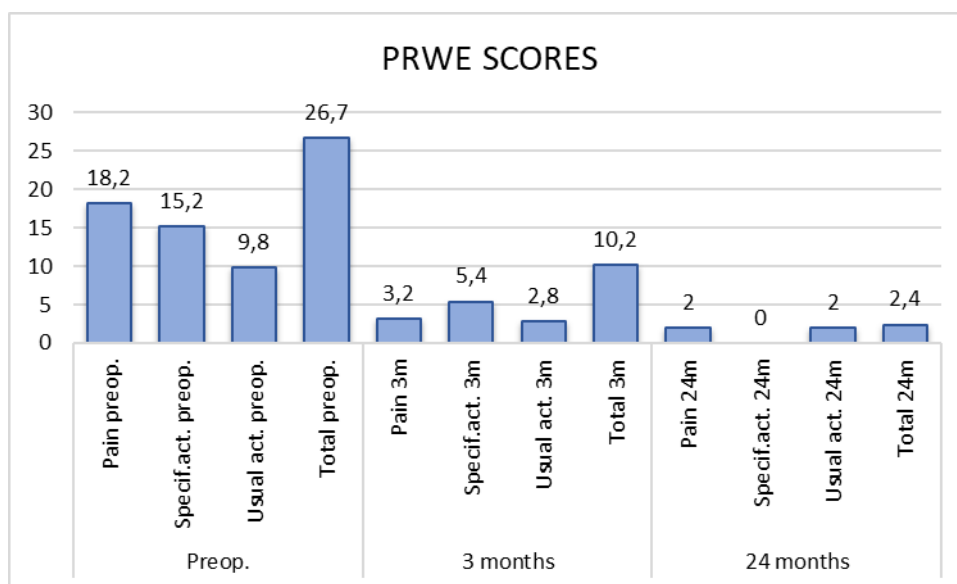
a

b

Figure 3. End result, extensor tendons identified and cleared of the ganglion tissue

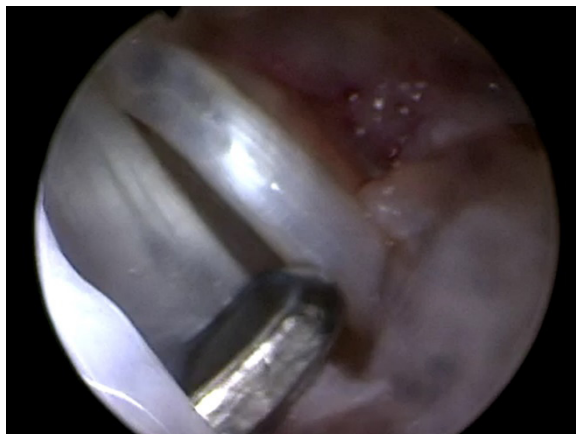

Figure 4. Mean PRWE score for the examined group, preoperatively, 3 and 24 months after arthroscopy. Specif. act. = specific activities, Usual act. = usual activities



We analyzed 48 patients who met the inclusion criteria and completed the 24 months follow-up.

Assessment

Patients were evaluated preoperatively and at 3 and 24 months post arthroscopy. Any presence of recurrence at 24 months was recorded.

Subjective outcome was evaluated using the patient-reported outcome measure, The Patient-Rated Wrist Evaluation (PRWE) [16]. The questionnaire was administered and explained to the patients by their surgeon preoperatively and

during their third month follow-up visit. The 24th month questionnaire was received by mail, and only patients with complaints were examined by the surgeon to confirm if there was recurrence. The pain was evaluated with the Visual analog scale (VAS) from 0-10 as well [17].

Objective outcomes included grip strength and range of movement measurements preoperatively and 3 months after arthroscopy.

The grip strength measurements were done with a hydraulic hand dynamometer. 3 attempts were obtained on both sides, and the highest values were recorded. The results were expressed as

a percentage of the strength of the uninjured hand, correcting by a factor of 1.07 for the non-dominant hand strength [18]. Active dorsal extension and palmar flexion were measured with a goniometer, according the standardized volar/dorsal LaStayo technique [19]. The range of movement was presented as percentage of the movement of the unaffected wrist.

Statistical analysis

Data were analyzed using SPSS Statistics for Windows, Version 18.0 (SPSS Inc., Chicago, IL, USA). Descriptive statistics were computed, means and percentages, minimal and maximal values. The Wilcoxon matched pairs test was used to determine statistical difference of the results of the examined patients pre- and postoperatively. A p value of less than 0.05 was considered statistically significant.

RESULTS

In this study, 48 patients with arthroscopically treated dorsal wrist ganglion were included; 6 of them had occult ganglions confirmed with MRI.

The mean age of the patients in this study was 36 (range 16 to 59) years; the majority were women (36/48). Table 1 presents patients' characteristics, as well as the clinical symptoms of the ganglia (most dominant complaint was the aesthetic discomfort, then the pain, followed by functional impairment).

The presentation of the ganglion determined by the MRI, as well as the position of the ganglion during examination were predominantly midcarpal in 38 (79%) and predominantly radiocarpal in 10 (21%) patients. Arthroscopic resection was completed through the midcarpal joint in 30 (63%), through the radiocarpal joint in 8 (16%) and through the both of the joints in 10 (21%) patients.

Mean operative time (tourniquet time) was 42 minutes (range 22-78 minutes).

Mean preoperative grip strength was 71% of the strength of the unaffected side, while 3 months after arthroscopic resection it improved up to 98% of the contralateral value ($p=0.016$).

Range of movement showed improvement of the average flexion (from 86% to 99%) and

extension (from 82% to 96%), but it was statistically not significant ($p=0.389$).

The total PRWE score improved from 26.7 preoperatively to 10.2 at three months and 2.4 two years after surgery. The scores for the pain subscale, as well as specific and usual activities also showed improvements; they are presented in the Figure 4. The PRWE results showed significant differences preoperatively and in the third month postoperatively (total PRWE score, $p=0.002$), as well as preoperatively and 24 months postoperatively (total PRWE score, $p=0.001$).

36 patients complained of preoperative pain, evaluated as VAS score ranging 2-6, only 4 patients reported pain after 3 months, scored as 2 and 3 on the visual analogue scale.

After 24 months follow-up, there were two patient with visible recurrence (4.2%) but without pain, so no revision surgery was performed. No other postoperative complications were noted. In two patients, there was persistent postoperative swelling during 2 and 4 weeks, mimicking the ganglion cyst. In both it resolved spontaneously.

DISCUSSION

Arthroscopic ganglionectomy has become an increasingly popular surgical option for dorsal wrist ganglia, given the recurrence rates, cosmetic and functional result, as well as superior evaluation and treatment of associated intraarticular pathology.

There are a few studies that have reported on the association of the ganglion cysts with scapholunate (SL) pathology. In their prospective study on 55 arthroscopically resected ganglia, Edwards and Johansen found scapholunate lesion in all their patients (100%) (Gr.I-2; Gr.II- 22; Gr.III-20; Gr.IV-1) [20]. Mantovani et al. assessed 74 symptomatic dorsal cysts [21]. They reported scapholunate instability in 100% (not identifiable on pre-operative imaging), DCSS rupture in 96% and scapholunate rupture in 9.5%. They suggested that the symptomatic dorsal wrist ganglion is not a disease by itself, but rather a clinical sign for the pre-dynamic scapholunate instability (DCSS / SL lesion).

The rationale for the arthroscopic treatment of the dorsal ganglion cysts is that the symptom-

Table 1 Characteristics of the evaluated patients

		No (%)
Gender	Female	36 (75%)
	Male	12 (25%)
Age (years)	Mean	36.2
	Max	59
	Min	16
Patient complaints	Pain	36 (75%)
	Functional impairment	20 (42%)
	Aesthetic discomfort	42 (88%)
Involved side	Left	26 (54%)
	Right	22 (46%)
Dominant side	Left	2 (4%)
	Right	46 (96%)
Previous surgery	No	40 (83%)
	Recurrence after open	8 (17%)

Table 2. Recurrence rates reported for arthroscopic and open dorsal ganglion procedures

	Author	%	No.	Follow-up
Arthroscopic procedures	Osterman (1995)[15]	0	18	
	Luchetti (2000) [13]	5,9	34	16 months
	Chen (2010) [22]	6,6	15	15,3 months
	Rizzo (2004) [14]	4,9	41	47,8 months
	Edwards (2009)[20]	0	55	2 years
	Mathoulin (2004) [23]	4,2	96	34 months
	Kang (2008) [24]	7,1	28	1 year
	Gallego (2010)[10]	12,3	114	2y
	Angelides (1976)[25]	0,87	346	9 m - 25 y
	Clay (1988) [26]	3,9	51	28 months
Open procedures	Hwang (1999)[27]	5,3	19	
	Limpaphayom (2004)[28]	18	11	6 months
	Kang (2008)[24]	8,7	23	12 months
	Dias (2007) [29]	39	103	70 months

% - Recurrence rate; No. – Number of patients in the study

atic dorsal ganglions are associated with SL instability and DCSS rupture; the symptoms could be related to the associated SL pathology; and the need to address the SL/DCSS pathology, not just the cyst. Classical open procedures provide inadequate diagnosis and treatment of the associated wrist intra-articular pathology.

The reported recurrence rates in the literature are still, however, debatable. Close to 0% in some series, and up to 30% in others. Clearly the follow up period influences results significantly [2]. The recurrence rates slightly favor arthroscopic resection over open procedures. Results of some of the studies evaluating arthroscopic and open techniques are presented in Table 2.

In our series, we only had two recurrences after two years (4.2%), similar to the results in other studies. Patients experienced objective and subjective improvement three months postoperatively, expressed as improved grip strength and range of movement, better PRWE scores, as well as less pain evaluated by VAS.

It is of importance to note the fact that most of the patients were complaining of aesthetic discomfort because of the presence of the dorsal ganglion, and with this operative arthroscopic technique, they received functional improvement with only minimal (almost invisible) scarring, no postoperative immobilization and an early return to their everyday and work activities.

Those who do not favor classic ganglionectomy claimed that open surgery is simply “trading an unsightly lump with an unsightly and permanent scar” [14]. The open procedure implies excision of the ganglion with the stalk and part of the dorsal capsule, preserving the scapholunate ligament. Reported complications range 0-56%, including stiffness, infection, cosmetically unacceptable scars, neuroma formation [2].

The advantage of the arthroscopic treatment of the dorsal ganglia, compared to open procedures, is that it is less invasive (better cosmetic result) and more precise; arthroscopic excision from inside out eliminates the considerable amount of dissection and potential scarring (less stiffness). It enables intra-articular “check-up” of the associated radiocarpal and midcarpal pathology, as well as its appropriate treatment. And finally, it has low rate of recurrence. The disadvantage, however, would be the cost.

CONCLUSION

Dorsal ganglia are a frequent, benign pathology of the wrist. They cause functional or cosmetic discomfort. Arthroscopic resection of the dorsal wrist ganglia is a safe procedure with the lowest recurrence rates and lowest scarring and stiffness. It should be considered a golden standard for operative treatment of the dorsal wrist ganglia.

REFERENCES

1. Meena S, Gupta A. Dorsal wrist ganglion: current review of literature. *Journal of clinical orthopaedics and trauma* 2014; 5: 59-64.
2. Suen M, Fung B, Lung CP. Treatment of ganglion cysts. *ISRN Orthopedics*. 2013; 2013 (ID 940615): 7p. doi:10.1155/2013/940615.
3. Gude W, Morelli V. Ganglion cysts of the wrist: pathophysiology, clinical picture, and management. *Curr Rev Musculoskelet Med* 2008; 1: 205-211.
4. Loder RT, Robinson JH, Jackson WT, et al. A surface ultrastructure study of ganglia and digital mucous cysts. *J Hand Surg* 1988; 13(5):758-62.
5. Andren L, Eiken O. Arthrographic studies of wrist ganglions. *J Bone Joint Surg Am* 1971; 53(2):299-302.
6. Overstraeten LV, Camus EJ, Wahegaonkar A, et al. Anatomical Description of the Dorsal Capsulo-Scapholunate Septum (DCSS). Arthroscopic staging of scapholunate instability after DCSS sectioning. *J Wrist Surg* 2013; 2(2):149-54.
7. Tommasini Carrara de Sambuy M, Burgess TM, Cambon-Binder A, et al. The Anatomy of the Dorsal Capsulo-Scapholunate Septum: A Cadaveric Study. *J Wrist Surg* 2017; 6(3): 244-7.
8. Garret J, Bordet B. Dorsal ganglion cyst: MRI study. *IRCAD 2015* (available at: www.web-surg.com/MEDIA/?noheader=1&doi=lt03engaret002)
9. Mathoulin C. *Wrist Arthroscopy Techniques*. Stuttgart, New York, Deli, Rio de Janeiro: Thieme; 2015.
10. Gallego S, Mathoulin C. Arthroscopic resection of dorsal wrist ganglia: 114 cases with minimum follow-up of 2 years. *Arthroscopy* 2010; 26(12): 1675-82.
11. Chung SR, Tay SC. Audit of Clinical and functional outcomes of arthroscopic resection of wrist ganglions. *Hand Surgery* 2015; 20(3): 415-20.
12. Edwards SG, Johansen JA. Prospective outcomes and associations of wrist ganglion cysts resected

- arthroscopically. *J Hand Surg* 2009; 34(3): 395-400.
13. Luchetti R, Badia A, Alfarano M, et al. Arthroscopic resection of dorsal wrist ganglia and treatment of recurrences. *J Hand Surg Br* 2000; 25(1): 38-44.
 14. Rizzo M, Berger R, Steinmann S, Bishop A. Arthroscopic resection in the management of dorsal wrist ganglions: results with a minimum two-year follow-up period. *J Hand Surg Am* 2004; 29(1): 59-62.
 15. Osterman AL, Raphael J. Arthroscopic treatment of dorsal ganglion of the wrist. *Hand Clin* 1995; 11:7-12.
 16. MacDermid JC, Turgeon T, Richards RS, et al. Patient rating of wrist pain and disability: a reliable and valid measurement tool. *J Orthop Trauma* 1998; 12:577-86.
 17. Scott J, Huskisson EC. Graphic representation of pain. *Pain* 1976; 2(2):175-84.
 18. Karnezis IA, Fragkiadakis EG. Association between objective clinical variables and patient-rated disability of the wrist. *J Bone Joint Surg Br* 2002; 84: 967-70.
 19. LaStayo PC, Wheeler DL. Reliability of passive wrist flexion and extension goniometric measurements: a multicenter study. *Physical Therapy* 1994; 74: 162-74.
 20. Edwards SG, Johansen JA. Prospective outcomes and associations of wrist ganglion cysts resected arthroscopically. *J Hand Surg Am* 2009; 34(3): 395-400.
 21. Mantovani Ruggiero G. The predynamic scapholunate instability: A new entity and the role of dorsal ganglion etiology. IRCAD 2014. (available at: www.websurg.com/MEDIA/?noheader=1&doi=lt03enmantovani002).
 22. Chen AC, Lee WC, Hsu KY, et al. Arthroscopic ganglionectomy through an intrafocal cystic portal for wrist ganglia. *Arthroscopy* 2010; 26(5): 617-22.
 23. Mathoulin C, Hoyos A, Pelaez J. Arthroscopic resection of wrist ganglia. *Hand Surg* 2004; 9(2): 159-64.
 24. Kang L, Akelman E, Weiss AP. Arthroscopic versus open dorsal ganglion excision: a prospective, randomized comparison of rates of recurrence and of residual pain. *J Hand Surg Am* 2008; 33(4): 471-5.
 25. Angelides AC, Wallace PF. The dorsal ganglion of the wrist: Its pathogenesis gross and microscopic anatomy, and surgical treatment. *J Hand Surg Am* 1976; 1(3): 228-35.
 26. Clay NR, Clement DA. The treatment of dorsal wrist ganglia by radical excision. *J Hand Surg Br* 1988;13(2):187-91.
 27. Hwang JJ, Goldfarb CA, Gelberman RH, et al. The effect of dorsal carpal ganglion excision on the scaphoid shift test. *J Hand Surg Br* 1999; 24(1):106-8.
 28. Limpaphayom N, Wilairatana V. Randomized controlled trial between surgery and aspiration combined with methylprednisolone acetate injection plus wrist immobilization in the treatment of dorsal carpal ganglion. *J Med Assoc Thai* 2004; 87(12):1513-7.
 29. Dias JJ, Dhukaram V, Kumar P. The natural history of untreated dorsal wrist ganglia and patient reported outcome 6 years after intervention. *J Hand Surg Eur Vol* 2007;32(5): 502-8..

Резиме**ПРОЦЕНА НА ИСХОДОТ НА АРТРОСКОПСКАТА РЕСЕКЦИЈА НА ДОРЗАЛНИТЕ ГАНГЛИОМИ НА РАЧНИОТ ЗГЛОБ****Катерина Касапинова¹, Виктор Камилоски¹, Емилија Атанасовска², Катерина Спасовска³**¹ Универзитетска клиника по хируршки болести „Св.Наум Охридски“, Скопје, РС Македонија² Институт за фармакологија и токсикологија, Скопје, РС Македонија³ Универзитетска клиника за инфективни болести, Скопје, РС Македонија

Цели: Артроскопската ганглионектомија станува сè попопуларна хируршка опција за третман на дорзалните ганглиоми на рачниот зглоб. Целта на оваа студија е да се опише нашата техника за артроскопски третман на дорзалните ганглиоми на рачниот зглоб и да се процени клиничкиот резултат, како и стапката на рецидивирање кај нашите пациенти.

Методи: Во оваа проспективна студија беа вклучени 48 пациенти кај кои беше спроведен артроскопски третман на дорзален ганглиом на рачјето. Пациентите беа иследувани предоперативно и 3 и 24 месеци по артроскопијата. На 24-тиот месец беше нотирано дали е присутен рецидив. Субјективниот исход беше оценуван со The Patient-Rated Wrist Evaluation (PRWE) и со Визуелната аналогна скала (VAS). Објективната проценка на исходот вклучуваше мерење на силата на стисокот и опсегот на движење.

Резултати: Просечната возраст беше 36 години, повеќето беа жени (36/48). Просечната сила на стисок и просечната флексија и екстензија на рачниот зглоб покажаа подобрување по 3 месеци. Вкупните PRWE бодови се подобрија од 26,7 предоперативно на 10,2 на третиот месец и 2,4 на две години по операцијата. По 24 месеци следење кај само два пациента беше најден рецидив (4,2 %).

Заклучок: Артроскопската ресекција на дорзалните ганглиоми на рачниот зглоб е процедура со ниска стапка на рецидивирање и најмало формирање лузни и вкочанетост; таа треба да биде сметана за златен стандард за оперативно лекување на дорзалните ганглиоми на рачниот зглоб.

Клучни зборови: дорзален ганглиом, артроскопија на рачен зглоб, артроскопска ресекција на ганглиом