

## ABNORMAL T WAVE INVERSIONS AND EXTREME QT PROLONGATION

Georgiev Antonio<sup>1</sup>, Janusevski Filip<sup>1</sup>, Nikolov Igor<sup>2</sup>, Gavrilovska Brzanov Aleksandra<sup>3</sup>, Jovanovski Srceva Marija<sup>3</sup>, Ivanovski Ognen<sup>4</sup>

<sup>1</sup>University Clinic for Cardiology, Faculty of Medicine, Ss. Cyril and Methodius University in Skopje, Republic of North Macedonia

<sup>2</sup>University Clinic for Nephrology, Faculty of Medicine, Ss. Cyril and Methodius University in Skopje, Republic of North Macedonia

<sup>3</sup>University Clinic for Traumatology, Orthopedics, Anesthesia, Reanimation, Intensive Care and Emergency, Faculty of Medicine, Ss. Cyril and Methodius University in Skopje, Republic of North Macedonia

<sup>4</sup>University Clinic for Urology, Faculty of Medicine, Ss. Cyril and Methodius University in Skopje, Republic of North Macedonia  
*e-mail: antoniogeorgiev@yahoo.com*

### Abstract

**Introduction:** Cardiovascular diseases are the cause of sudden cardiac arrest. One of the leading causes of death is the occurrence of ventricular arrhythmias. Prompt evaluation, diagnosis and management of ventricular arrhythmias are life-saving for these patients.

**Case report:** We present the case of a 70-year-old female patient with neurological sensorimotor polyneuropathy with quadriparesis and verified chronic renal failure (CRF) gr. IV admitted at the University Clinic for Nephrology for acute renal failure. After hemodialysis treatment, she developed arrhythmogenic disability such as episodes of ventricular fibrillation (VF) and ventricular tachycardia (VT). The onset of VT/VF required pharmacologic and shock therapy treatment. Electrocardiogram (ECG) at presentation upon admission to the cardiology clinic was with abnormal T wave and QT inversions. We did not find any electrolytic disturbances or echocardiographic abnormalities in search for ischemia segment wall changes. Coronary angiography showed no significant lesions of the coronary arteries. Our strategy for treating this long QT interval was temporary pacing with high doses of b-blockers. According to the good response to the therapy, the patient got permanent pacing therapy (AAI→DDD mode) and till this day she is still safe from occurrence of ventricular arrhythmias.

**Conclusion:** Prolongation of ventricular repolarization in patients with long QT interval must be registered as a predictor of occurrence of ventricular arrhythmias.

**Keywords:** abnormal T wave inversions, long QT, ventricular arrhythmias, pacing

### Introduction

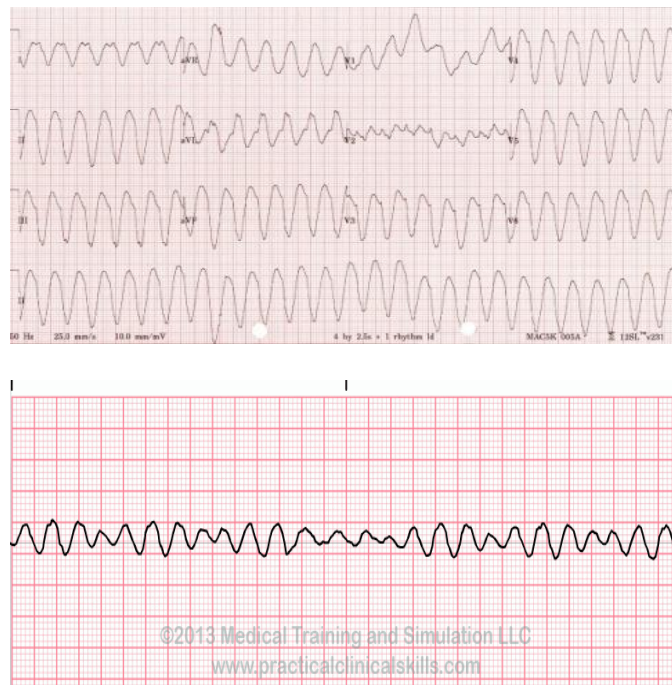Sudden cardiac death accounts for near half of the mortality from cardiovascular diseases and a fifth of the total mortality. It mostly occurs in patients unrecognized to be at risk. The majority of sudden cardiac deaths are caused by acute ventricular arrhythmia<sup>[1,2,3]</sup>.

Long QT syndrome (LQTS) is a rare disorder of the cardiac electrical activity. It can cause problems with rhythm or the rate of the heartbeat causing ventricular arrhythmias and possible sudden cardiac death. LQTS often goes undiagnosed and because of this it is not

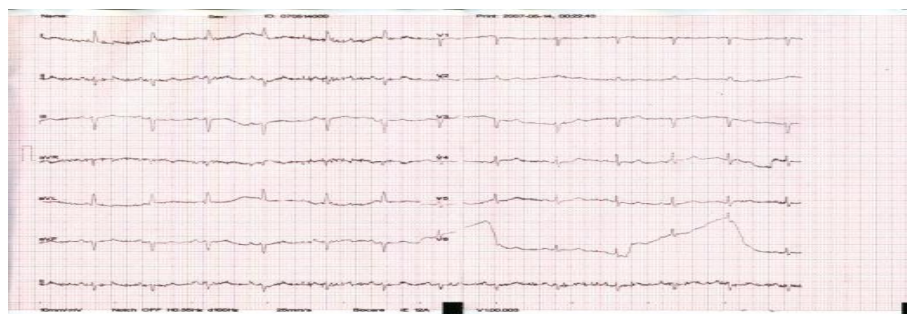known exactly how many people are with this syndrome. Some papers and studies estimate that 1 in 7,000 individuals have LQTS. Ventricular arrhythmia due to prolongation of ventricular repolarization is observed in patients with rare genetically determined congenital long QT syndrome (LQTS). In addition, this QT prolongation in general population can be due to genetic variations or acquired LQTS. The physiopathological hallmark of ventricular repolarization prolongation is early after depolarization's (EAD) which can induce reentry and provoke torsade de pointes and fatal ventricular arrhythmias<sup>[4-7,9,10]</sup>. The patient we are referring to was with an acquired form of LQTS. Our patient was successfully treated with pacing modified ventricular repolarization.

### Case report

We describe a case of a 70-year-old female patient, D. M., with sensorimotor neurological disorder (polyneuropathy sensomotoria cum quadriparesis) and verified CRF gr. IV admitted at the University Clinic for Nephrology for acute renal failure. Three days after acute hemodialysis at the Clinic for Nephrology, the patient developed sudden cardiac death in several occasions due to ventricular fibrillation and ventricular tachycardia (Figure 1 and 2). She was successfully resuscitated with defibrillation according to acute coronary syndrome (ACLS) algorithm. After this accident, an indication was set for transferring the patient to the University Clinic for Cardiology for further cardiac treatment. The patient ECG on admission and vital parameters were without significant disturbances (Figure 3).

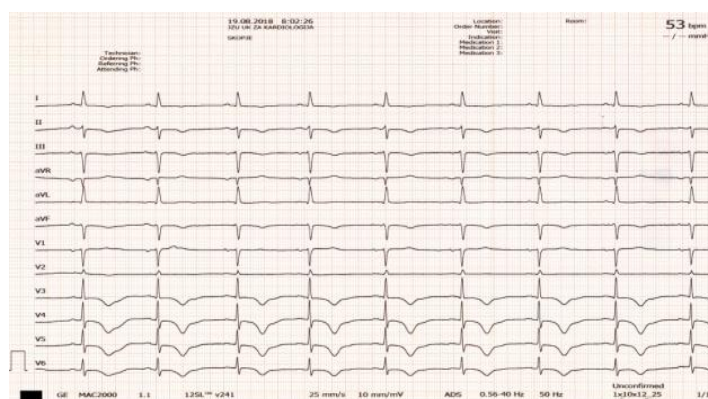
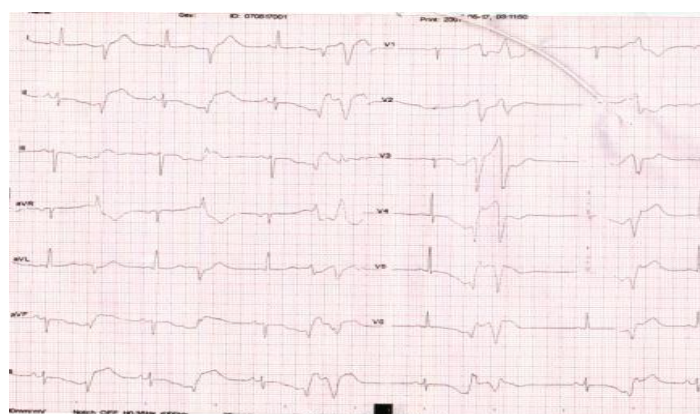


**Fig. 1 and 2. VT/VF episodes**



**Fig. 3.** ECG on admission without significant disturbances

Because of her rhythm instability, she was transferred to intensive cardiac care unit at the Clinic for Cardiology for further evaluation, diagnostics and treatment. Her clinical status was significant for the primary neurological disorder, but the cardiovascular status was normal. Heart rate on admission was around 70 beats per minute; the arterial tension was normal; on auscultation nothing remarkable. Her electrocardiogram revealed a long QT interval 800 msec occasionally with unifocal premature ventricular complexes with very short coupling intervals (Figure 4 and 5). Her laboratory was unremarkable for electrolyte or cardiac, nephrological, hepatic impairments. The echocardiography showed no structural or ischemic heart disease. Abnormal T inverse waves were examined by coronary angiography. Performed coronary angiography revealed no significant lesions of the coronary arteries.

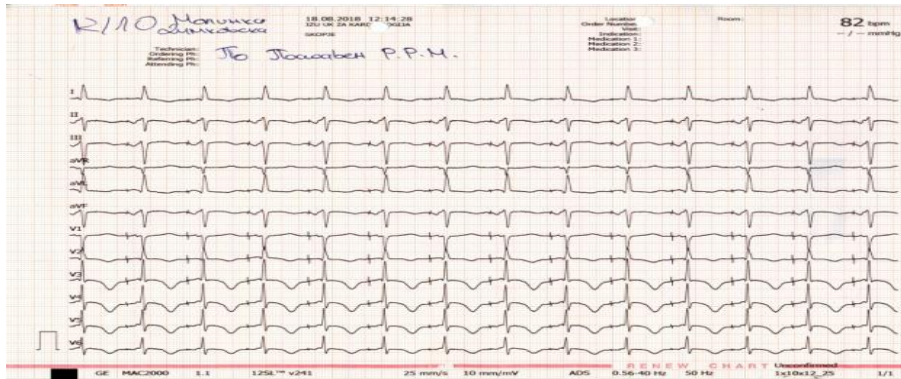


**Fig. 4 and 5.** Abnormal T wave and QT inversions

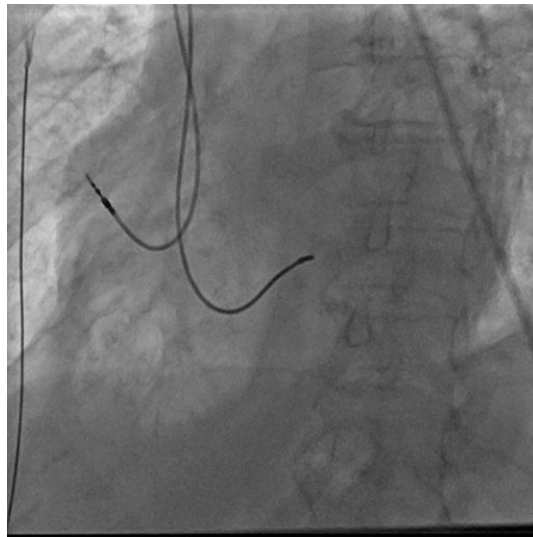
Our strategy for treatment of the extreme QT prolongation and the potential occurrence of rhythm instability was to initially implant a temporary pacemaker. After that we started with beta blockers, in her case lipid soluble, which were during her hospitalization



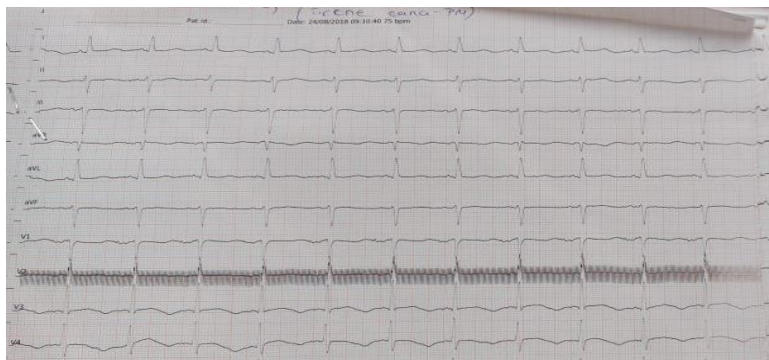
titrated to maximal tolerant dose (300 mg per day). According to the good response to the therapy without developing heart failure (HF), on the 5<sup>th</sup> day after hospitalization a permanent pacemaker was implanted with pacing lead positioned in the right atrium and right ventricle, ECG after implantation (Figures 6, 7 and 8). Because of the good therapeutic response, the pacemaker was programmed to AAI→DDD mode. To this day, the patient is safe from deleterious life-threatening ventricular arrhythmias.



**Fig. 6.** ECG after temporary pacemaker implantation



**Fig. 7.** Electrodes after permanent pacemaker implantation



**Fig. 8.** ECG after implantation of permanent pacemaker

## Discussion

The QT interval that is electrical measurement for assessment of the duration of ventricular depolarization and repolarization is measured in millisecond on the electrocardiogram and is corrected for the heart rate usually using the Bazett's formula<sup>[1,2,11]</sup>. According to the European guidelines, intervals longer than 450 msec in men and 470 msec in women are referred to as prolonged QT interval. The electrical heart activity is a result of Na, K, Ca ion in- and efflux regulation across the cell membrane. Malfunction of ion channels may lead to an intracellular excess of positively charged ions, i.e., either by an inadequate outflow of potassium ions or by an excessive inflow of sodium ions. The intracellular excess of positively charged ions prolongs ventricular repolarization, which results in QT prolongation on the electrocardiogram.

In spite of the congenital genetically determined LQTS where errors in the K and Na channels are discovered, in the acquired QT prolongation there are myriad of factors that predispose this disease, including age, female gender, left ventricular hypertrophy, heart failure, myocardial ischemia, hypertension, diabetes mellites, increased levels of thyroid hormone, high body mass index, bradycardia, hypokalemia, hypomagnesemia, hypocalcemia and the most common is the usage of specific drugs (antiarrhythmics class I, III, antimalware's, certain antibiotics, some opiates and antipsychotics, etc.) The pathophysiology mechanism of ventricular arrhythmia development is drug-drug, drug-gene interaction on the cardiac membrane channels<sup>[7-10,12,13,15]</sup>.

The beta blockers, pacemaker and the implantable cardioverter defibrillators (ICD) have been shown to be highly effective in preventing sudden cardiac death in high-risk populations. A number of studies have shown nearly significant reduction in mortality rate in patients with LQTS treated with pacemaker or ICD. High-risk patients are those with aborted cardiac arrest or recurrent cardiac events (e.g., syncope or torsade de pointes) despite conventional therapy with beta blockers. Physical activity has shown improvement of the heart rate and later on the ventricular repolarization. Beta blockers, on the other hand, have combined effects on the adrenergic tone<sup>[12,14-16]</sup>. The patient in our case has had a good response to beta blocker therapy with maximal tolerant dose without developing HF.

With our approach combining beta blocker and implantation of DDD pacemaker in our patient we have protected her from the onset of ventricular arrhythmias to this day. Pacing the atrium in patients with preserved AV node conduction or pacing the atrium and ventricle in AV disease at higher rates mostly around 80 beats per minute modifies ventricular repolarization in a way that eliminates arrhythmogenic bradycardia, decreases heart rate irregularities (short-long-short sequences that affect AV coupling) and decreases repolarization diversity. As a result of pacing, we are diminishing the risk of perpetuating ventricular arrhythmias<sup>[12,14,17]</sup>.

## Conclusion

Sudden cardiac death has an overall high mortality impact and mostly the ventricular arrhythmias are the main culprit. Proper distinguishment of the population at risk with adequate investigation tools such as patients' history, physical examination, ECG findings lead to better understanding of the ventricular abnormalities. Although not a novel method in treatment of long QT syndrome, pace modified ventricular repolarization with beta blockers and other antiadrenergic therapies gives us a good tool for mortality rate reduction.

*Conflict of interest statement.* None declared.

## References

1. Myerburg RJ, Kessler KM, Castellanos A. Sudden cardiac death: epidemiology, transient risk, and intervention assessment. *Ann Intern Med* 1993; 119: 1187-97.
2. Myerburg RJ, Interian AJr, Mitrani RM, Kessler KM, Castellanos A. Frequency of sudden cardiac death and profiles of risk. *Am J Cardiol* 1997; 80: 10F-19F.
3. Gorgels AP, Gijssbers C, de Vreede-Swagemakers J, Lousberg A, Wellens HJ. Out-of-hospital cardiac arrest – the relevance of heart failure. The Maastricht Circulatory Arrest Registry. *Eur Heart J* 2003; 24: 1204-9.
4. Vink AS, Neumann B, Lieve KVV, Sinner MF, Hofman N, El Kadi S, et al. Determination and interpretation of the QTinterval. *Circulation* 2018; 138: 2345-58. doi: 10.1161/CIRCULATIONAHA.118.033943 pmid: <http://www.ncbi.nlm.nih.gov/pubmed/30571576>.
5. Adler A, Novelli V, Amin AS, Abiusi E, Care M, Nannenberg EA, et al. An international, multicentered, evidence-based reappraisal of genes reported to cause congenital long QT syndrome. *Circulation* 2020; 141: 418-28. doi: 10.1161/CIRCULATIONAHA.119.043132 pmid:<http://www.ncbi.nlm.nih.gov/pubmed/31983240>.
6. Straus SM, Kors JA, De Bruin ML, van der Hooft CS, Hofman A, Heeringa J, et al. Prolonged QTc interval and risk of sudden cardiac death in a population of older adults. *J Am Coll Cardiol* 2006; 47: 362-7.
7. Lasser KE, Allen PD, Woolhandler SJ, Himmelstein DU, Wolfe SM, Bor DH. Timing of new black box warnings and withdrawals for prescription medications. *JAMA* 2002; 287: 2215-20.
8. Roden DM. Drug-induced prolongation of the QT interval. *N Engl J Med* 2004; 350: 1013-22.
9. Al-Khatib SM, LaPointe NM, Kramer JM, Califf RM. What clinicians should know about the QT interval. *JAMA* 2003; 289: 2120-7.
10. Yap YG, Camm AJ. Drug induced QT prolongation and torsades de pointes. *Heart* 2003; 89: 1363-72.
11. Bazett HC. The time relations of the blood-pressure changes after excision of the adrenal glands, with some observations on blood volume changes. *J Physiol* 1920; 53: 320-39.
12. Ackerman MJ, Zipes DP, Kovacs RJ, Maron BJ. Eligibility and Disqualification Recommendations for Competitive Athletes With Cardiovascular Abnormalities: Task Force 10: The Cardiac Channelopathies: A Scientific Statement From the American Heart Association and American College of Cardiology. *Circulation* 2015; 132(22): e326-9.
13. Zipes DP, Camm AJ, Borggrefe M, Buxton AE, Chaitman B, Fromer M, et al. ACC/AHA/ESC 2006 Guidelines for Management of Patients With Ventricular Arrhythmias and the Prevention of Sudden Cardiac Death: a report of the American College of Cardiology/American Heart Association Task Force and the European Society of Cardiology Committee for Practice Guidelines (writing committee to develop Guidelines for Management of Patients With Ventricular Arrhythmias and the Prevention of Sudden Cardiac Death): developed in collaboration with the European Heart Rhythm Association. *Circulation* 2006; 114(10): e385-484.
14. Koponen M, Marjamaa A, Hiippala A, Happonen JM, Havulinna AS, Salomaa V, et al. Follow-up of 316 molecularly defined pediatric long-QT syndrome patients: clinical course, treatments, and side effects. *Circ Arrhythm Electrophysiol* 2015; 8(4): 815-23.
15. Ferri FF. Long QT syndrome. In: Ferri's Clinical Advisor 2020. Elsevier 2020.

16. Wilde AAM, Ackerman MJ. Beta-Blockers in the treatment of congenital long QT syndrome: is one beta-blocker superior to another? *J Am Coll Cardiol* 2014; 64: 1359-61. doi:10.1016/j.jacc.2014.06.1192 pmid:<http://www.ncbi.nlm.nih.gov/pubmed/25257638>.
17. Früh A, Siem G, Holmström H, Haugaa KH. The Jervell and Lange-Nielsen syndrome; atrial pacing combined with  $\beta$ -blocker therapy, a favorable approach in young high-risk patients with long QT syndrome? *Heart Rhythm* 2016; 13: 2186-92. doi:10.1016/j.hrthm.2016.07.020 pmid:<http://www.ncbi.nlm.nih.gov/pubmed/27451284>.