

CASE REPORT

**CLINICAL AND GENETIC CHARACTERISTIC OF AUTOSOMAL DOMINANT STARGARDT-LIKE DISEASE**

Cheleva Markovska Vesna

Eye Clinic, Ss Cyril and Methodius University of Skopje, Skopje, Republic of Macedonia

**ABSTRACT**

**Objective:** Presentation of 7-year-old boy with a Stargardt-like disease using noninvasive imaging techniques and genetic investigation.

**Description:** A seven-year-old boy was examined at the Department of Retina at the University Eye Clinic in Skopje, by the ophthalmologist after a pediatric systematic examination. From the heteroanamnesis it was established that the child was watching TV close to the monitor. His teacher noticed that he could not see letters and numbers from the back of the classroom. The visual acuity was 0,1 on both eyes without correction and was 0,16 with glasses. The biomicroscopy, ophthalmoscopy, OCT, FFA and ERG was done. Genetic testing was performed as well.

**Conclusion:** OCT, FFA, ERG help for the clinical stadium diagnostics and monitoring of Stargardt Macular dystrophy or Stargardt-like macular dystrophy. Furthermore, since no effective therapy for treating the Stargardt-like disease is available, understanding the disease progression will be essential in developing and monitoring response to therapies in the future.

**Keywords:** Stargardt Macular dystrophy, Fundus flavimaculatus, Stargardt like disease, gene ABCA4, gene ELOVL4

**INTRODUCTION**

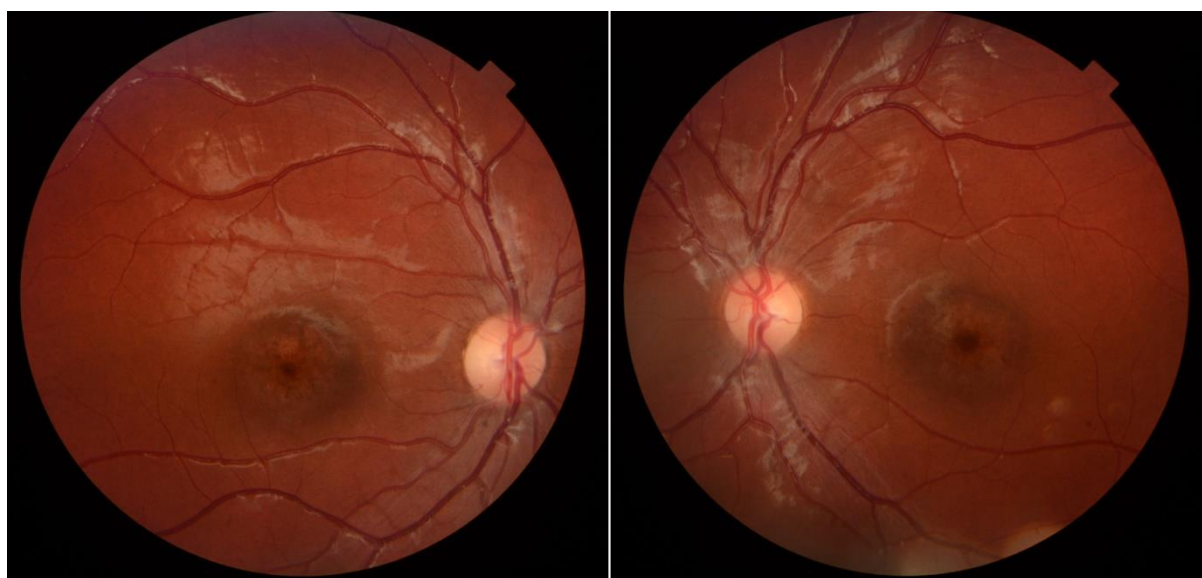The Stargardt macular dystrophy is autosomal recessive inherited macular degeneration, although dominantly inherited cases have been described as well. The Stargardt disease/fundus flavimaculatus is one form of macular dystrophy in childhood, affecting 1 in 10.000 individuals [1]. Stargardt-like disease is autosomal dominant inherited disease and is phenotypically similar to autosomal recessive Stargardt disease. An autosomal dominant form of rare Stargardt dystrophy also known as Stargardt-like dystrophy is caused by mutation in a gene encoding ELOVL4, an enzyme that catalyzes the elongation of very long-chain fatty acids in photoreceptors and other tissues. Characteristic features include significant loss of visual acuity, i.e. central vision. There are bilateral atrophic changes in the central retina-macula associated with degeneration of photoreceptors and underlying retinal pigment epithelial cells. In some cases, presence of yellow flecks extending from the atrophic macula can be seen. Diagnosing is usually during the first or second decade of life with impaired visual acuity. Both sexes are affected equally.

## CASE REPORT

From the heteroanamnesis the parents claim that their child watches television sitting close to the monitor. He could not see letters and numbers, from far away. They were aware that something is not normal with the child's vision very early, since he was 5 years old. They have made consultation with the neurologist and MR (magnet resonance) was done. The patient did not complain for impairment night vision. The child was adopted.

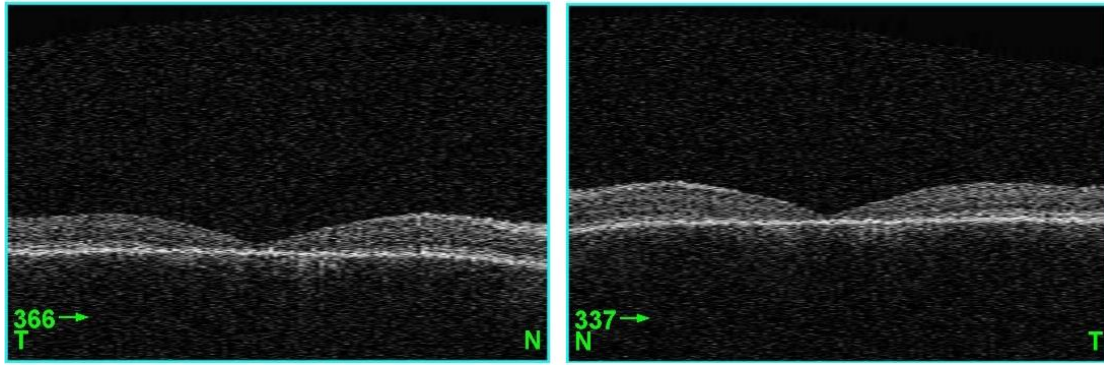
The vision of the right eye was 0,1 without correction and vision of the same eye with refraction of +0,50 D sph +0,75 D cyl/90 was 0,16 on the Snellen optotype. The vision of the left eye was 0,1 without correction and vision of the same eye with refraction of +0,50 D sph +0,75 D cyl/110 was 0,16 on the Snellen optotype. The autorefractometry was done and the results were: OD +0,75 D sph +1,0 D cyl /90 and OS +0,50 D sph + 1,0 D cyl /110. The intraocular pressure was digitally normal. Ishihara test for color vision deficiency was done. The patient had mild color vision loss for the red/green colors.

The primary examination was done, including biomicroscopy and ophthalmoscopy. Using the inspection with light, no abnormalities were seen of the lids, super cilium etc. Biomicroscopy investigation of the anterior segment showed normal findings. Optical media were clear. On the posterior segment, the fundus finding on both eyes was: vital papilla optic nerve with clear boundary, blood vessels with normal lumen, pre-grouping of the pigment epithelium resulting in an oval lesion on macula with 1,5 disk diameter in size without reflex on the right eye and with beaten bronze reflex on the left eye (Figure 1).



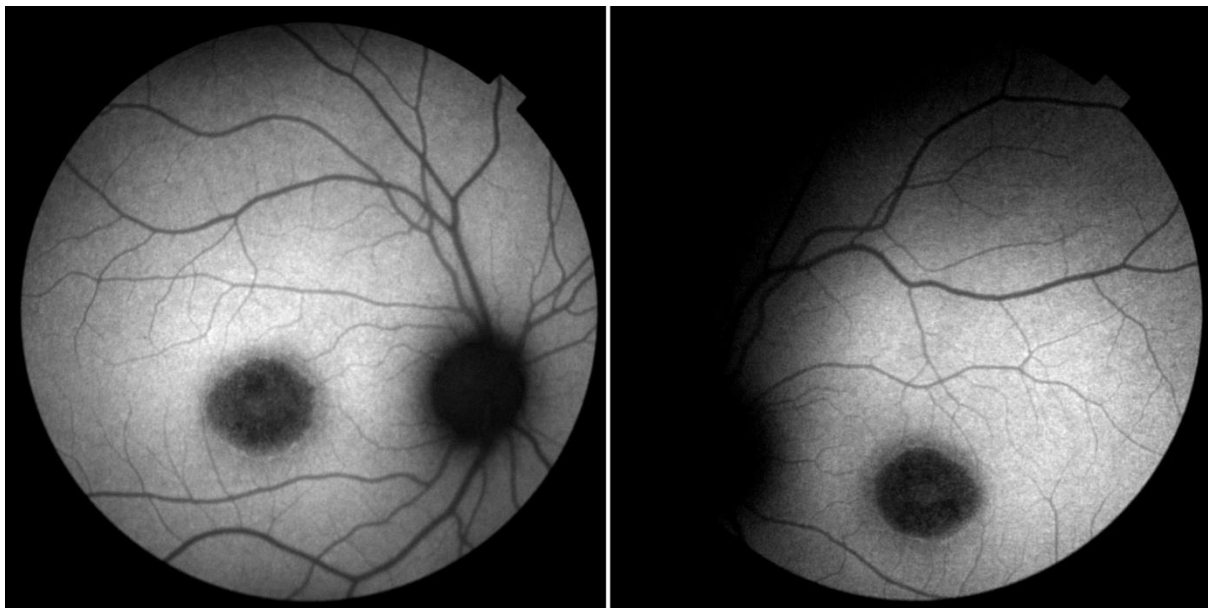**Fig. 1.** Red Cam fundus images of Stargardt-like disease (macular pregroupation of pigment-epithelial cells and atrophy of the RPE in ML).

Additional investigations were done, such as optical coherent tomography (OCT) and fluorescein fundus angiography (FFA). OCT images on both eyes revealed disruption, absence or thinning of intraretinal layers. The visual acuity loss correlated with central fovea thickness in atrophic areas in the patient (Figure 2).

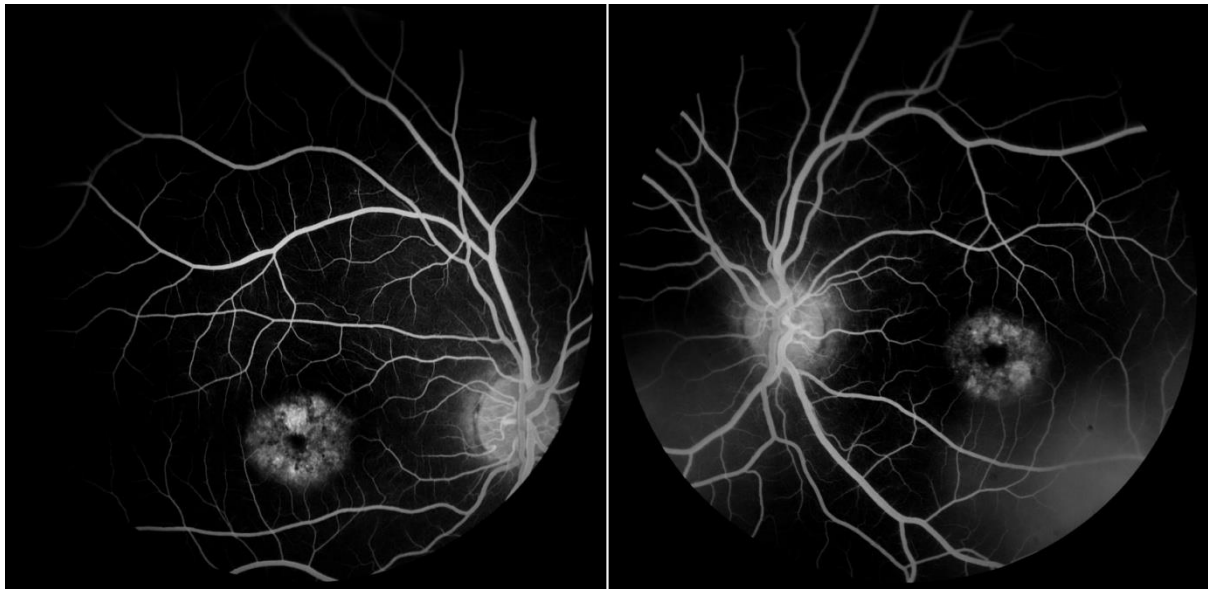


**Figure 2.** 3D OCT images: disruption of inner and outer photoreceptors' layers and central foveal thickness.

On the angiogram from the fluorescein fundus angiography, the characteristic signs for Stargardt disease were present. During FFA, lipofuscin absorbs blue excitatory light producing the characteristic dark choroid (blockage of choroidal fluorescence). Hyperfluorescence in the macula zone was present because of the atrophic changes in the retinal pigment epithelium (Figure 3, 4).




**Fig. 3.** Fundus autofluorescence images of Stargardt-like disease, dark macular zone with clear boundary.



**Fig. 4.** FFA angiogram: dark choroid and window effect in the macula (hyperfluorescence)

With the aim to complete the clinical diagnosis the patient was sent to the EAD Aleksandrovska University Hospital in Sofia, Bulgaria, for an electroretinography (ERG) exam (Reti scan multifocal ERG) and Kugel perimeter. The results of the ERG were abnormal: right eye OD- to 30,45 miV/43.7 ms.; left eye OS- to 25, 62 mi V/42.7 ms., the bioelectrical activity is reduced by 40% on the right eye and 50% on the left eye, primarily in the zone of 20 degrees (Figure 5). The results of the Kugel perimeter exam were normal peripheral vision field on both eyes.



**Fig. 5.** ERG of Stargardt-like disease reduce bioelectrical activity for 40% OD and 50% OS

Moreover, genetic testing was performed and the STGD3 gene has been mapped to chromosome 6q in this patient with genetically distinct autosomal dominant form of Stargardt-like disease. The genetic testing proves the clinical diagnosis.

After one year, on the control examination the vision acuity was unchanged. Vision acuity of the right eye was of 0,1 without glasses and of left eye was 0,1 without glasses on the Snellen optotype.

## **DISCUSSION**

The first description of the disease was by Karl Stargardt in 1909 and the gene discovery was by Allikments and colleagues in 1997.

As the name implies, autosomal dominant Stargardt-like disease is phenotypically similar to autosomal recessive SD [2, 3, 4, 5]. The STRGD3 gene was first identified in 2001 by Zhang and coworkers and shown to encode ELOVL4 (elongation of very long chain fatty acid-4), a member of the ELO family of proteins involved in the elongation of fatty acids [6].

Fundus flavimaculatus (FF) is a retinal disease first described by Franceschetti in the 1960s [7]. It is characterized by the symmetrical appearance of yellow-white flecks extending from the macula [7, 8]. Extensive clinical and genetic analyses have shown that autosomal recessive SD and FF are variations of the same disease, typically caused by different mutations in the same gene [9, 10, 11]. Fundus flavimaculatus is generally used to describe a late onset and milder form of SD [12, 13].

Two genes associated with inherited macular degeneration disease encode proteins that function in the processing of lipids in photoreceptor cells. Mutations in the gene known as ABCA4 cause autosomal recessive SD and related macular disease [14]. Mutations in the gene encoding ELOVL4, an elongate enzyme involved in the elongation of very long chain fatty acids, have been linked to autosomal dominant SD-like disease [6].

The gene ABCA4 encodes the rod and cone photoreceptor Rim protein, which is a transmembrane transporter of vitamin A intermediates. This gene produces a protein that binds the toxic by-products of vitamin A in the photoreceptors, preventing Vit A toxicity to the photoreceptors esp. the cones. Therefore, the ophthalmologists have to avoid prescribing any Vitamin A, especially high doses.

FFA shows impairment or blockage of choroidal fluorescence and dark choroid characterized by absence of normal background fluorescence, because lipofuscin absorbs blue excitatory light producing the characteristic dark choroid appearance in many Stargardt disease (SD) patients [15]. The hyperfluorescence in the macula zone is present in the patients with SD because of the atrophic changes in the retinal pigment epithelium (RPE). FFA is diagnostic key method for the SD disease. On the angiogram, the macular window defects (hyperfluorescence) are coupled with characteristic dark choroid. The diffuse darkening is due to background blocking of choroidal fluorescence, by the widespread deposits of toxic material in the RPE. Histochemical analysis of donor eyes from deceased SD patients revealed significant loss in photoreceptor cells and excessive accumulation of lipofuscin deposits in the RPE cells [8, 16].

Electroretinography (ERG) and electrooculography (EOG) are usually abnormal only in advanced cases when the changes have progressed to involve the RPE, choroid and neurosensory retina diffusely. Scotopic electroretinograms characterizes with rod photoreceptor function and photopic ERGs that measure cone response differ between Stargardt patients. Some individuals show relatively normal full-field ERGs, whereas some patients exhibit significant loss in scotopic and/or photopic ERGs [17, 18, 19]. The ERG provides clinically important information of retinal function for SD patients, hence the ERG is

primarily used for diagnostics and monitoring of the evolution of the SD in these patients. EOG is not widely used, however it is useful if there is abnormal Arden's ratio.

Gene therapy for SD associated with ABCA4 Gene-mutations in the photoreceptor-specific flippases lead to accumulation of the toxic bisretinoid A2E, resulting in atrophy of the retinal pigment epithelium (RPE) and death of the photoreceptor cells. Many blinding diseases are associated with this type of mutations including the Stargardt disease, con rod dystrophy, retinitis pigmentosa and increased susceptibility to age related macular degeneration. The future therapy approaches to ABCA4 gene therapy may include the treatment with novel AAV vectors, lentiviral vectors and non-viral compacted DNA nanoparticles. As a result of the development of these novel technologies, effective therapies for ABCA4 associated diseases may finally be within reach [20].

Since there is no effective treatment for SD patients, the disease progresses over time and the visual acuity worsens. Once the patient's visual acuity drops below 6/12, it tends to decrease rapidly and stabilize at about 6/60 to 3/60. SD-affected individuals typically experience significant loss in central vision with a marked reduction in visual acuity in their first or second decade of life [21, 22]. Progressive reduction in visual acuity generally occurs through the patient's life with values reaching 20/200 or worse in the final stages of the disease. SD patients show a delay in dark adaptation and variable loss in color vision as well [12, 23, 24, 25]. In general, peripheral visual fields and night vision are normal in SD patients. The degree and type of color vision deficiency in Stargardt disease patients correlate better with best visual acuity than with ERG results. The presence of specific color vision deficiencies may help to establish a diagnosis of SD [26].

The Stargardt disease (macular dystrophy) or Stargardt-like disease (macular dystrophy) have similar clinical appearance. For both diseases the early diagnosis is important, because the genetic counseling has to be done subsequently for children and family. It is important to redirect children to studies less dependent on reading. The usual age of diagnosis is in the first or more often second decade, between 18-20 years, when the young patient is already in college and finds himself/herself unable to proceed and finish the studies.

## **CONCLUSION**

Early diagnosis of SD like disease or SD is important for the correct redirecting of the patients to suitable studies. If the child or teenager complains of poor vision, the ophthalmologist has to think about SD and should not conclude prematurely that the reason of poor vision acuity is bilateral amblyopia or hysterical visual loss. OCT, FFA, ERG help for the clinical stadium diagnostics and monitoring of Stargardt Macular dystrophy or Stargardt-like macular dystrophy.

Furthermore, since no effective therapy for treating the Stargardt-like disease is available, understanding the disease progression will be essential in developing and monitoring response to therapies in the future. As a result of the novel genetic technologies, effective therapies for ABCA4 associated diseases may finally be within reach.

## **REFERENCES**

1. Bither PP, Berns LA. Stargardts disease: a review of the literature. J. Am Optom Assoc. 1989; 59:106-111.
2. Stone EM, Nichols BE, Kimura AE, Weingeist TA, Drack A, Sheffield VC. Clinical features of Stargardts-like dominant progressive macular dystrophy with genetic linkage to chromosome 6q. Arch Ophthalmol.1994; 112:765-72.



3. Donoso LA, Edwards AO, Frost A, Vrabec T, Stone EM, Hageman GS, et al. Autosomal dominant Stargardt-like dominant progressive macular dystrophy. *Surv Ophthalmol.*2001; 46:149-63.
4. Edwards AO, Miedziak A, Vrabec T, Verhoeven J, Acott TS, Weleber RG, et al. Autosomal dominant Stargardt-like macular dystrophy: I Clinical characterization, longitudinal follow up, and evidence for a common ancestry in families linked to chromosome 6q14. *Am J Ophthalmol.*1999; 127:426-35.
5. Lopez PF, Maumenee IH, de la Cruz, Green WR. Autosomal-dominant fundus flavimaculatus. Clinical pathologic correlation. *Ophthalmology.*1990;97:798-809.
6. Zhang K, Kniazeva M, Han M, Li W, Yu Z, Yang Z, et al. A 5-bp deletion in ELOVL4 is associated with two related forms of autosomal dominant macular dystrophy. *Nat Genet.* 2001; 27:89-93
7. Franceschetti AF, J. Fundus flavimaculatus. *Arch Ophthalmol.* 1965; 25:505-30.
8. Steinmetz RL, Garner A, Maguire JL, Bird AC. Histopathology of incipient fundus flavimaculatus. *Ophthalmology.*1991;98:953-6.
9. Noble KG, Carr RE. Stargardts disease and fundus flavimaculatus. *Arch Ophthalmol.*1979; 97:1281-5.
10. Hadden OB, Gass JD. Fundus flavimaculatus and Stargardts disease. *Am J Ophthalmol* 1976; 82:527-39.
11. Kaplan J, Gerber S, Larget-Piet D, Rozet JM, Dolffus H, Dufier JL, et al. A gene for Stargardts disease (fundus flavimaculatus) maps to the short arm of chromosome 1. *Nat Genet.* 1993; 5:308-11.
12. Welwber RG. Stargardts macular dystrophy. *Arch Ophthalmol.* 1994; 112:752-4.
13. Westerfeld C, Mukai S. Stargardts disease and the ABCR gene. *Semin Ophthalmol.* 2008; 23:59-65.
14. Allikments R, Singh N, Sun H, Shroyer NF, Hutchinson A, Chidambaram A, et al. A photoreceptor cell-specific ATP-binding transporter gene (ABCR) is mutated in recessive Stargardt macular dystrophy *Nat Genet.*1997; 15:236-46
15. Fish G, Grey R, Sehmi KS, Bird AC. The dark choroid in posterior retinal dystrophies. *Br J Ophthalmol.* 1981; 65:359-63.
16. Birnbach CD, Jarvelainen M, Possin DE, Milam AH. Histopathology and immunocytochemistry of the neurosensory retina in fundus flavimaculatus. *Ophthalmology.*1994;101:1211-9. (3)
17. Lois N, Holder GE, Bunce C, Fitzke FW, Bird AC. Phenotypic subtypes of Stargardt macular dystrophy-fundus flavimaculatus. *Arch Ophthalmol.*2001;119:359-69.
18. Lois N, Holder GE, Fitzke FW, Plant C, Bird AC. Intrafamilial variation of phenotype in Stargardts macular dystrophy -Fundus flavimaculatus. *Invest Ophthalmol Vis Sci* 1999; 40:2668-75.
19. Genead MA, Fishman GA, Stone EM, Allikmets R. The natural history of Stargardts disease with specific sequence mutation in the ABCA4 Gene. *Invest Ophthalmol Vis Sci* 2009
20. Molday S.R, Zhang K. Defective lipid transport and biosynthesis in recessive and dominant Stargardt macular degeneration. *Prog.Lipid Res.* 2010 Oct;49(4); 476-492.
21. Fishman GA, Farber M, Patel BS, Derlacki DJ. Visual acuity loss in patients with Stargardts macular dystrophy. *Ophthalmology.*1987;94:809-14.
22. Rotenstreich Y, Fishman GA, Anderson RJ. Visual acuity loss and clinical observation in a large series of patients with Stargardts disease. *Ophthalmology.*1991;98:957-62.
23. Fishman GA, Farbman JS, Alexander KR. Delayed rod dark adaptation in patients with Stargardt disease. *Ophthalmology.*1991;98:957-62.

24. Moloney JB, Mooney DJ, O Connor MA. Retinal function in Stargardts disease and fundus flavimaculatus. *Am J Ophthalmol.* 1983; 96:57-65.
25. Mantyjarvi M, Tuppurainen K. Color vision in Stargardts disease. *Int Ophthalmol.* 1992; 16:423-8.
26. Vandenbroucke T, Buyl R, De Zaeytijd J, Bauwens M, Uviils A, De baere E, Lerov BP. Color vision in Stargard disease. *Ophthalmic Res.* 2015; 54(4):181-94.