

## THE ROLE OF AFIBERCEPT IN THE TREATMENT OF A PATIENT WITH POLYPOIDAL CHOROIDAL VASCULOPATHY- Case report

Natasha Trpevska Shekerinov<sup>1,2</sup>, Jana Nivichka Kjaeva<sup>1,2</sup>, Stefan Pandilov<sup>1</sup>, Emilija Gjoshevska Dashtevska<sup>1,2</sup>, Andrijana Petrushevska<sup>1,2</sup>

<sup>1</sup>University Clinic for Eye Diseases, Skopje, Republic of North Macedonia

<sup>2</sup>Faculty of Medicine, Ss. Cyril and Methodius University in Skopje, Republic of North Macedonia

### Abstract

To present a patient with polypoidal choroidal vasculopathy, an entity often overlooked and misdiagnosed in daily clinical practice.

A 73-year-old patient with reduced visual acuity in the left eye was evaluated with a complete ophthalmological examination, fundus photography, optical coherence tomography of the posterior segment of the eye, and optical coherence tomography with angiography and a diagnosis of polypoidal choroidal vasculopathy with development of a type 1 choroidal neovascular network (aneurysmal-polypoidal network) was made.

The changes shown on OCT referred to the presence of subretinal fluid, PED in the shape of the letter M, the presence of a "double layer sign" from the developed neovascular network in the form of a renal glomerulus. After application of an anti-VEGF preparation (Aflibercept) for a period of six months (five applied doses, three consecutive, and two every two months) there was regression of the lesion and improvement of visual acuity from 0.5 to 0.9 according to the Snellen optotype.

The characteristic changes of OCT and OCT-A, as well as the course of the disease corresponded with the literature data that we consulted during the evaluation of this case, thus the diagnosis of polypoidal choroidal vasculopathy was confirmed. Timely recognition of this not so rare entity is of great importance for appropriate management and treatment of the affected patient.

**Keywords:** polypoidal choroidal vasculopathy, subretinal fluid, choroidal neovascular membrane, aflibercept.

### Introduction

Polypoidal choroidal vasculopathy (PCV), formerly also known as "posterior uveal syndrome" or "recurrent multiple retinal pigment epithelial detachment in black women", is an uncommon disease in the human population [1].

It was first described in the eighties of the last century by Yannuzzi, as a subretinal, vascular lesion accompanied by serous or hemorrhagic detachment of the retinal pigment epithelium (RPE) in the area of the macula lutea [2].

The name of the disease indicates the presence of branched choroidal blood vessels with aneurysmal dilated endings resembling polyps. Due to the similarity with some pathologies, this entity is included in the so-called pachychoroid spectrum of retinal diseases. Along with PCV, this category also includes: central serous chorioretinopathy, pachychoroid pigment epitheliopathy and pachychoroid neovasculopathy [3].

The term pachychoroid refers to choroidal thickening, as a result of dilatation of blood vessels in Haller's choroidal layer. Thus dilated, they are a good substrate for reduced blood flow, pressure on choriocapillaris blood vessels and increased vascular permeability, which is basically the main mechanism for the occurrence of these diseases. This mechanism differentiates PCV from age-related macular degeneration in pathogenesis.

Most often, PCV presents as a massive subretinal hemorrhage or orange-colored nodules in the macular region. In addition to the macular, much less often such lesions can also be found peripapillary or in extramacular region. During the pathophysiological course of the disease, there is the formation of a choroidal neovascular membrane that protrudes towards the retinal layers and is subject to frequent bleeding [4].

In most cases, PCV is a unilateral disease, although cases with bilateral affection have been described in the literature. Vulnerable category for the occurrence of PHV are middle-aged people, between 50-65 years of age [5].

According to some studies, the disease shows predominance in the female sex, and according to others, in the male [5,6].

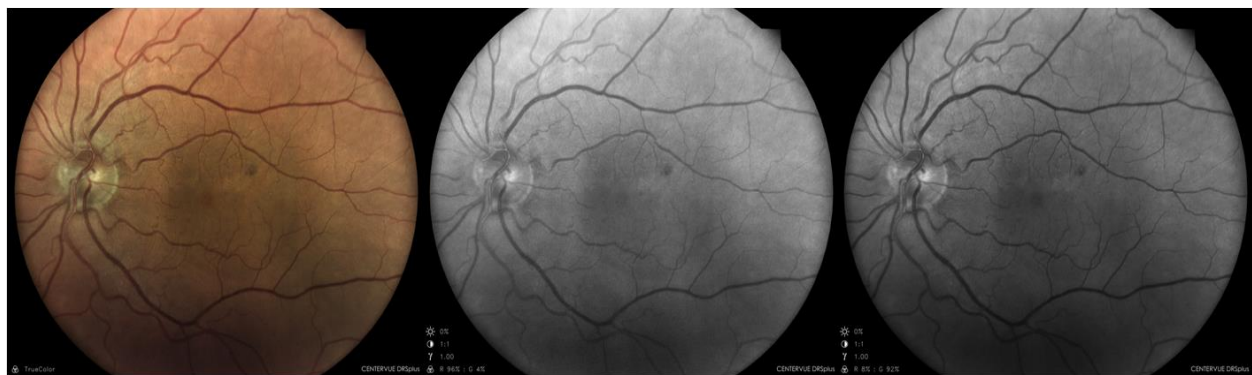
It is more common in blacks and Asians, compared to the white population. The following are mentioned as risk factors for the occurrence of PCV: cardiovascular diseases, diabetes, metabolic syndrome, smoking and elevated body mass index [7].

The most common differential diagnostic challenges in patients with PCV are age-related macular degeneration, which begins similarly in the older population, and central serous chorioretinopathy, along with other pachychoroidal diseases due to a similar pattern of disease progression [8].

These moments are the reason why PHV is often missed as a diagnosis in everyday ophthalmic practice.

### Case report

A 73-year-old patient came for an examination at the PHI UC for eye diseases in Skopje with information about a recent decrease in vision in the left eye. We received anamnestic data from the patient about a blunt injury to the right eye more than ten years ago and a burn of the same, 6 years ago, with an alkaline substance while working in the yard. Regarding other diseases or comorbidities, hypertension treated with tablet therapy was observed. Best-corrected visual acuity (BCVA) at the time of examination was 0.2 in the right eye and 0.5 in the left, according to the Snellen optotype. Intraocular pressure was determined using the contact indentation method, and was within the normal range (14.6 mmHg) in both eyes. Bulbomotors were normal in all directions, with no changes in convergence and pupillary light response tests. Next, a detailed clinical examination was undertaken, for which artificial pupillary mydriasis was performed with Sol. Tropicamide 1%.

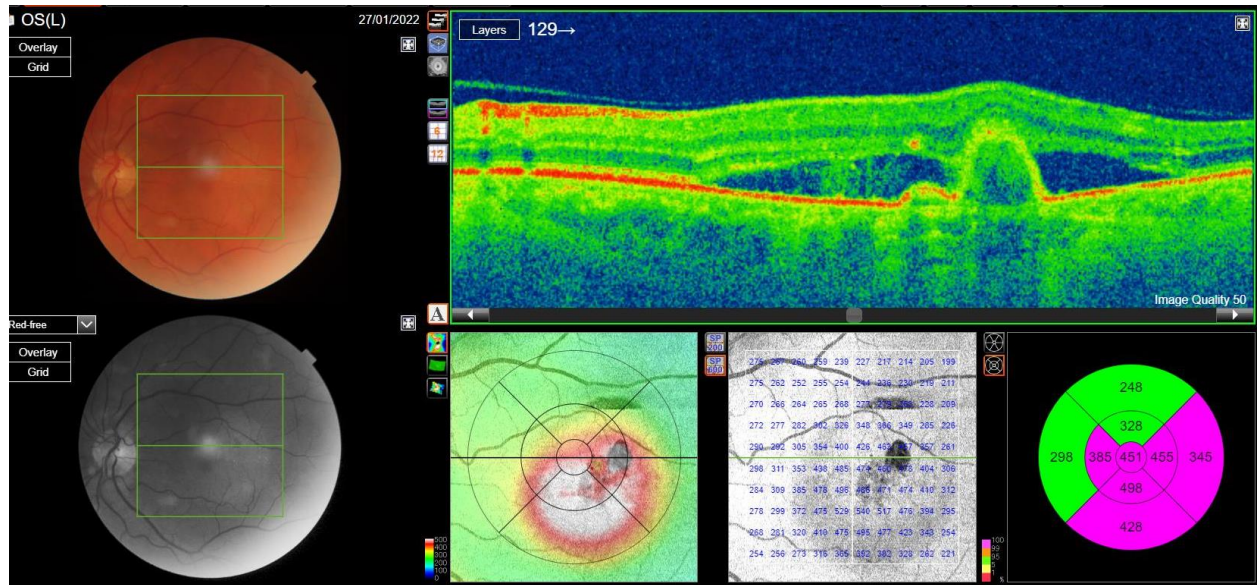


**Figure 1.** Color fundus photo, photo with green (540nm) and red filter (630nm) on the left eye, showing a small vascular lesion on the periphery of the macular region.

On the biomicroscopic examination of the anterior segment of the eye, pterygium verum is noted bilaterally in the nasal sector of the cornea, without affection of the visual axis. On the right eye, in the vicinity of the pterygium, a zone of corneal changes was observed, with a surface neovascular network, macular clouding of the cornea in that sector, a possible consequence of the previous chemical combustion of that eye. The other structures of the anterior segment of the eye were without significant changes.

Fundoscopically, bilateral papillae were of regular morphology, blood vessels were moderately attenuated, on the right eye in the macular region several individual solid drusen with a diameter less than 65µm and a lost foveolar reflex were observed.

On the left fundus in the macular region, a zone with edema and possible retinal pigment epithelium detachment was noted in that sector. In order to more subtly evaluate the change, a native fundus photograph and OCT of the macular region were made, with accompanying angiography.

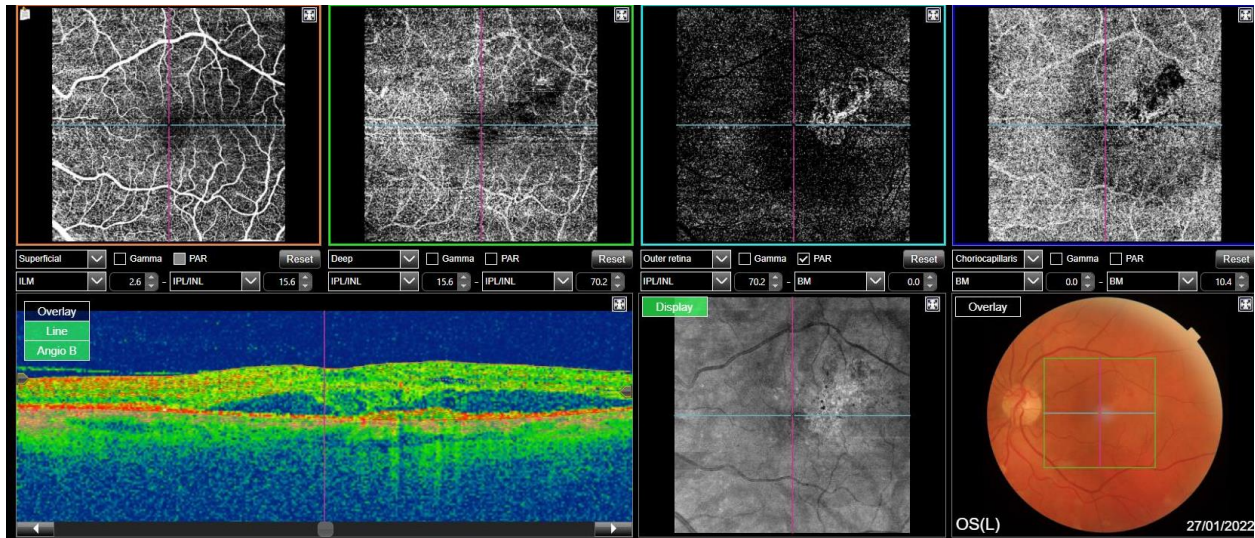


**Figure 2.** OCT image at initial examination. The polypoidal lesion, M form of PED and double layer sign are observed. In the Choroidea, dilatation of Haller's blood plexus is present.

The central macular thickness of the left eye was 451µm. The tomogram showed an oval zone of edematous swelling in the perifoveolar region. The highest elevation thickness reached 498µm in the lower perifoveolar sector. A zone of subretinal fluid extending into most of the macula was noted.

Perifoveolar surface of PED in the shape of the letter M, and double reflecting layers, i.e. "double layer sign" was observed.

On the angiogram, that area corresponds to a choroidal neovascular membrane that extends from the height of the choriocapillaris, through the outer layers of the retina, and reaches the deep inner retinal blood plexus. OCT showed dilatation of blood vessels in the Haller's layer of the choroid. In the absence of age-related macular degeneration changes in both the affected eye and the other eye, as well as in the presence of a developed type 1 neovascular network and accompanying tomographic features, a diagnosis of polypoidal choroidal vasculopathy was made. Also a treatment with an anti-VEGF preparation - Aflibercept, monthly doses and regular follow-up and monitoring of the patient was started.



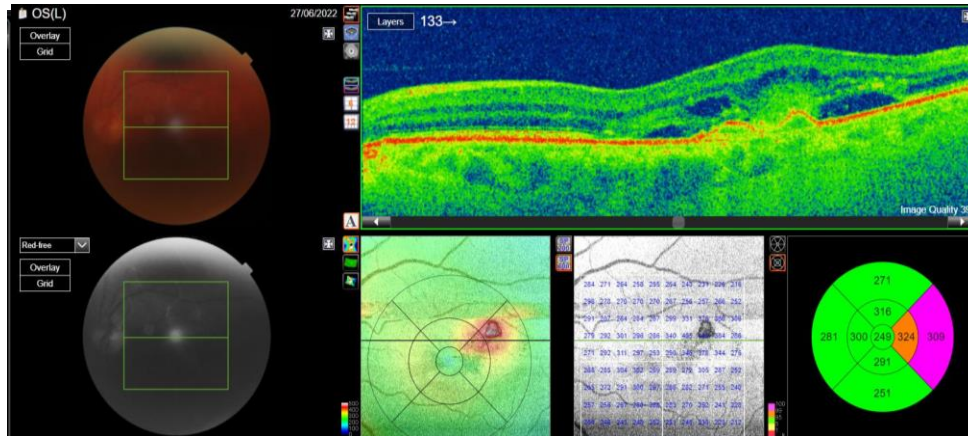
**Figure 3.** OCT-A image at initial examination. In the choriocapillary layer, a neovascular network in the form of a renal glomerulus can be observed, which protrudes towards the outer retinal layers.

After three administered doses, there was a visible decrease in subretinal fluid in all quadrants of the macula. The central macular thickness decreased to 244 $\mu$ m, and the highest point on the tomogram showed the zone adjacent to the choroidal neovascular network with a height of 295 $\mu$ m. Regarding the CNV, there was a significant reduction in its dimension, according to the angiogram, compared to the finding at the beginning. In addition to the anatomical results, a significant improvement in the visual acuity of the eye was also achieved.

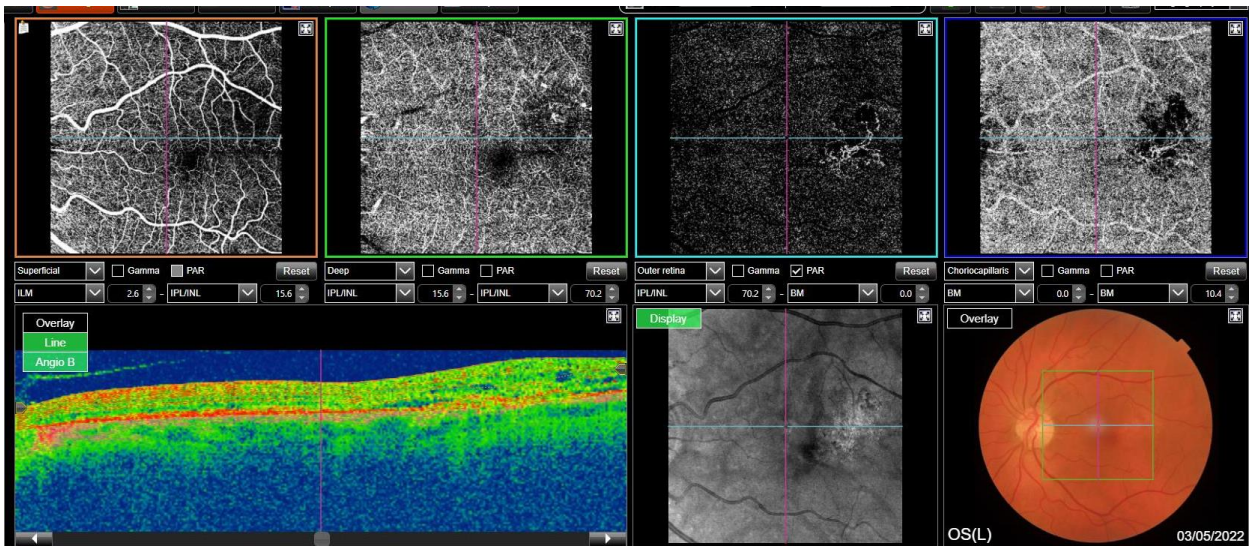
The best-corrected visual acuity of the affected eye after three consecutive monthly doses was 0.9, according to the Snellen optotype.

However, due to the still present residual subretinal fluid and PED, as well as the presence of a pathologic neovascular network, the patient was continued with two more applications of Aflibercept, every two months.

After six months (five applied doses), there was complete withdrawal of the exudative component, regression of the neovascular network and preservation of visual acuity of 0.9 according to the Snellen optotype. The patient is still being monitored at the PHI UC for eye diseases-Skopje at regular monthly ophthalmological examinations. Until the moment of publication of this paper, no relapse of the disease has been observed.



**Figure 4.** OCT finding in the patient after three (top image) and five (bottom image) months of starting the patient's therapy. Visible reduction of initial edema and macular thickness.



**Figure 5.** OCT-angiogram in the patient 4 months after the onset of the condition. Reduction of blood neovascular network, compared to the initial angiogram.

## Discussion

The diagnosis of this pathology is based on the skillful use of modern imaging techniques in ophthalmology. The main diagnostic modality is indocyanine green angiography (ICGA), which can easily show the branched vascular network in PCV, so it is rightfully the gold standard in the diagnosis of this entity [9].

With ICGA, polypoidal changes are shown as hyperreflective points that lose their intensity in the late stages of imaging, but the environment becomes hyperfluorescent, due to transudation from the pathologically changed blood vessels. In 2015, the EVEREST study performed on 61 patients presented diagnostic criteria, based on ICGA, which are currently used in clinical practice in the evaluation of patients suspected of PCV [10].

These include: a nodular appearance of the polyp, a hypofluorescent halo around the lesion, abnormal blood vessels vascularizing the polyp and its pulsatile filling, a yellow-stained subretinal lesion visible in the fundus showing hyperfluorescence on ICGA, and the presence of submacular hemorrhage. According to the characteristics of ICGA, PCV is divided into two categories: Type 1 with polypoidal choroidal neovascularization (a well-branched vascular network is observed) and type 2, that is, a typical form of PCV without the presence of a branched vascular network [11].

Unlike ICGA, FFA has a limited significance in the diagnosis of PCV, it does not make a clear distinction of the lesion in relation to the surrounding structures, it shows it larger than the actual dimension [12].

OCT is also an important morphological method in analyzing PCV. On the one hand it makes a good identification of the subretinal fluid, and the fluid under the RPE, and on the other hand it shows the site for a possible neovascular network. The double-reflective layers that appear on OCT are known as the "double layer sign" and are found in as many as 59% of patients with PCV.

Characteristic OCT manifestations, in addition to the "double layer sign", in PCV are: subretinal fluid, detachment of the retinal pigment epithelium, with serous or hemorrhagic content underneath, M-shape or QRS complex-form of detached pigment epithelium. In addition to these characteristic signs, choroidal thickening and dilatation of Haller's blood vessels can also be observed during OCT [13].

OCT angiography is another modality used in the evaluation of these patients. The developing choroidal neovascular membrane (CNV) and dilated blood vessels in the macular region can be visualized by OCT-angiography. That is, the type of neovascular membrane in PCV is type 1 (aneurysmal neovascularization). Most often, the newly formed vascular network takes a branched form, or a glomerulus-like form and is present immediately next to the polypoidal lesion [14].

According to this, since PCV is a disease based on a vascular event: dilatation of blood vessels, exudation in the subretinal space, hemorrhage and formation of a neovascular network, it is logical to conclude that the therapeutic protocol would be based on preparations that prevent neovascularization or photodynamic therapy.

In the past years, several studies have been done that aimed to show which therapeutic modality is dominant in the treatment of this disease. The EVEREST study performed on 61 patients in Asia compared Ranibizumab and photodynamic therapy as single modalities and simultaneously applied together. The results indicated a predominance in lesion regression as demonstrated by ICGA in groups treated with photodynamic therapy alone or in combination with ranibizumab compared with ranibizumab as a single therapeutic modality [10].

The LAPTOP study in Japan indicated the improvement of visual acuity in patients treated with Ranibizumab compared to photodynamic therapy [15].

The PLANET study in 2017 analyzed the effect of Aflibercept, alone, compared with photodynamic therapy, over a period of 12 months. The conclusions indicated similar results in both analyzed groups [16].

Similar results were shown by the EPIC study, when using Aflibercept in patients for a period of 6 months. In 70% of them, subretinal hemorrhage and exudative complications subsided, as well as a significant improvement in visual acuity during treatment with Aflibercept as monotherapy [17].

According to the PLANET and EPIC studies, in the treatment of our patient, we decided on a monotherapy regimen with Aflibercept for six months.

The patient gradually experienced regression of the exudative component and retraction of the neovascular network, accompanied by improved visual acuity of four lines according to the Snellen optotype.

The prognosis of this disease is generally good. Spontaneous retraction of the changes occurs in a certain percentage of patients, especially in those without a formed neovascular network. In patients who have multiple polypoidal changes, there is an increased risk of fibrotic tissue formation.

## Conclusion

Through this paper we tried to indicate the new views on the management of patients with polypoidal choroidal vasculopathy, an entity that is often misdiagnosed as age-related macular degeneration. The recognition of this pathology is of great importance for timely and appropriate treatment of it, because with a good therapeutic regimen, the results are really optimistic in terms of the morphological integrity of the chorioretina, but also in terms of the patient's visual acuity.

Prompt diagnosis of the lesion and initiation of intravitreal treatment with Aflibercept for a period of six months (five applied doses) gave excellent results in our case.

## References

1. Kleiner RC, Brucker AJ, Johnston RL. The posterior uveal bleeding syndrome. *Retina*. 1990;10(1):9-17. PMID: 2343198.
2. Yannuzzi LA. Presented at the Macula Society Meeting. Miami, Fla: 1982. Feb 5, Idiopathic polypoidal choroidal vasculopathy.
3. Borooah S, Sim PY, Phatak S, Moraes G, Wu CY, Cheung CMG, Pal B, Bujarborua D. Pachychoroid spectrum disease. *Acta Ophthalmol*. 2021 Sep;99(6):e806-e822. doi: 10.1111/aos.14683. Epub 2020 Nov 30. PMID: 33258304.
4. Kumar A, Kumawat D, Sundar M D, Gagrani M, Gupta B, Roop P, Hasan N, Sharma A, Chawla R. Polypoidal choroidal vasculopathy: a comprehensive clinical update. *Ther Adv Ophthalmol*. 2019 Feb 27;11:2515841419831152. doi: 10.1177/2515841419831152. PMID: 30834360; PMCID: PMC6393826.
5. Yannuzzi LA, Wong DW, Sforzolini BS, Goldbaum M, Tang KC, Spaide RF, Freund KB, Slakter JS, Guyer DR, Sorenson JA, Fisher Y, Maberley D, Orlock DA. Polypoidal choroidal vasculopathy and neovascularized age-related macular degeneration. *Arch Ophthalmol*. 1999 Nov;117(11):1503-10. doi: 10.1001/archophth.117.11.1503. PMID: 10565519.
6. Byeon SH, Lee SC, Oh HS, Kim SS, Koh HJ, Kwon OW. Incidence and clinical patterns of polypoidal choroidal vasculopathy in Korean patients. *Jpn J Ophthalmol*. 2008 Jan-Feb;52(1):57-62. doi: 10.1007/s10384-007-0498-2. Epub 2008 Mar 28. PMID: 18369702.
7. Sakurada Y, Yoneyama S, Imasawa M, Iijima H. Systemic risk factors associated with polypoidal choroidal vasculopathy and neovascular age-related macular degeneration. *Retina*. 2013 Apr;33(4):841-5. doi: 10.1097/IAE.0b013e31826ffe9d. PMID: 23400077.
8. Ma D, Kumar M, Khetan V, Sen P, Bhende M, Chen S, Yu TTL, Lee S, Navajas EV, Matsubara JA, Ju MJ, Sarunic MV, Raman R, Beg MF. Clinical explainable differential diagnosis of polypoidal choroidal vasculopathy and age-related macular degeneration using deep learning. *Comput Biol Med*. 2022 Feb 14;143:105319. doi: 10.1016/j.combiomed.2022.105319. Epub ahead of print. PMID: 35220077.
9. Anantharaman G, Sheth J, Bhende M, Narayanan R, Natarajan S, Rajendran A, Manayath G, Sen P, Biswas R, Banker A, Gupta C. Polypoidal choroidal vasculopathy: Pearls in diagnosis and management. *Indian J Ophthalmol*. 2018 Jul;66(7):896-908. doi: 10.4103/ijo.IJO\_1136\_17. PMID: 29941728; PMCID: PMC6032720.
10. Tan CS, Ngo WK, Chen JP, Tan NW, Lim TH; EVEREST Study Group. EVEREST study report 2: imaging and grading protocol, and baseline characteristics of a randomised controlled trial of polypoidal choroidal vasculopathy. *Br J Ophthalmol*. 2015 May;99(5):624-8. doi: 10.1136/bjophthalmol-2014-305674. Epub 2015 Mar 10. PMID: 25758601; PMCID: PMC4413842.
11. Kawamura A, Yuzawa M, Mori R, Haruyama M, Tanaka K. Indocyanine green angiographic and optical coherence tomographic findings support classification of polypoidal choroidal vasculopathy

- into two types. *Acta Ophthalmol.* 2013 Sep;91(6):e474-81. doi: 10.1111/aos.12110. Epub 2013 Jul 15. PMID: 23848133.
12. Gomi F, Sawa M, Mitarai K, Tsujikawa M, Tano Y. Angiographic lesion of polypoidal choroidal vasculopathy on indocyanine green and fluorescein angiography. *Graefes Arch Clin Exp Ophthalmol.* 2007 Oct;245(10):1421-7. doi: 10.1007/s00417-007-0564-y. Epub 2007 Mar 9. PMID: 17347808.
  13. De Salvo G, Vaz-Pereira S, Keane PA, Tufail A, Liew G. Sensitivity and specificity of spectral-domain optical coherence tomography in detecting idiopathic polypoidal choroidal vasculopathy. *Am J Ophthalmol.* 2014 Dec;158(6):1228-1238.e1. doi: 10.1016/j.ajo.2014.08.025. Epub 2014 Aug 22. PMID: 25152500.
  14. Wang M, Zhou Y, Gao SS, Liu W, Huang Y, Huang D, Jia Y. Evaluating Polypoidal Choroidal Vasculopathy With Optical Coherence Tomography Angiography. *Invest Ophthalmol Vis Sci.* 2016 Jul 1;57(9):OCT526-32. doi: 10.1167/iovs.15-18955. PMID: 27472276; PMCID: PMC4970807.
  15. Oishi A, Miyamoto N, Mandai M, Honda S, Matsuoka T, Oh H, Kita M, Nagai T, Bessho N, Uenishi M, Kurimoto Y, Negi A. LAPTOS study: a 24-month trial of verteporfin versus ranibizumab for polypoidal choroidal vasculopathy. *Ophthalmology.* 2014 May;121(5):1151-2. doi: 10.1016/j.ophtha.2013.12.037. Epub 2014 Jan 29. PMID: 24484991.
  16. Lee WK, Iida T, Ogura Y, Chen SJ, Wong TY, Mitchell P, Cheung GCM, Zhang Z, Leal S, Ishibashi T; PLANET Investigators. Efficacy and Safety of Intravitreal Aflibercept for Polypoidal Choroidal Vasculopathy in the PLANET Study: A Randomized Clinical Trial. *JAMA Ophthalmol.* 2018 Jul 1;136(7):786-793. doi: 10.1001/jamaophthalmol.2018.1804. Erratum in: *JAMA Ophthalmol.* 2018 Jul 1;136(7):840. PMID: 29801063; PMCID: PMC6136040.
  17. Kokame GT, Lai JC, Wee R, Yanagihara R, Shantha JG, Ayabe J, Hirai K. Prospective clinical trial of Intravitreal aflibercept treatment for Polypoidal choroidal vasculopathy with hemorrhage or exudation (EPIC study): 6 month results. *BMC Ophthalmol.* 2016 Jul 27;16:127. doi: 10.1186/s12886-016-0305-2. PMID: 27465105; PMCID: PMC4964097.