



Case report

Laparoscopic fenestration and omentopexy as treatment for large splenic pseudocyst: Case report

Elena Zafirovikj^{a,*}, Blagica Krsteska^b^a Department of Abdominal Surgery, University Hospital St. Naum Ohridski-Skopje, Macedonia^b Institute of Pathology, Faculty of Medicine, Ss. Cyril and Methodius University, Skopje, Macedonia

ARTICLE INFO

Keywords:

Splenic cysts
Laparoscopic
Pseu
Fenestration
Case report

ABSTRACT

Introduction and importance: Pseudocysts of the spleen are rare entities with cystic lesions of the spleen being uncommon in general. It is estimated that splenic cysts occur in about 0, 07% of the population¹. In general, splenic cystic lesions are discovered incidentally or by mass effect. In the literature, only a limited number of splenic cysts are reported. We report a case of splenic pseudocyst with mass effect where we used laparoscopic fenestration of the pseudocyst with omentopexy as a treatment of choice.

Case presentation: The patient is a 62-year-old male with no previous history of trauma. He visited his GP for abdominal pain with flaring towards the left shoulder accompanied by early satiety, occasional obstipation, and breathing difficulties. He was referred to our hospital after enhanced computed tomography showed a 15 × 13 cm splenic cyst with displaced stomach and pancreatic tail medially and left kidney downward. Management options were discussed with the patient and he opted for a laparoscopic approach.

In this case, we performed laparoscopic fenestration of the pseudocyst with omentopexy.

Clinical discussion: Until recently splenectomy was the surgical treatment of choice for all large or symptomatic cystic lesions of the spleen² however with growing knowledge about the protective role of the spleen an approach with spleen protection is advocated.

Conclusion: There are many advantages to the laparoscopic approach of splenic cystic lesions and it may be the treatment of choice for this uncommon surgical problem.

1. Introduction

Pseudocysts of the spleen are rare entities with cystic lesions of the spleen being uncommon in general. It is estimated that splenic cysts occur in about 0, 07% of the population [1].

Due to the lack of specific clinical symptoms in the early stage, the vast majority of patients were found accidentally [1]. Clinical imaging techniques such as ultrasound, CT, and MRI can all be used for the diagnosis of this condition [1]. As for treatment cyst aspiration with or without a sclerosing agent, cyst fenestration and drainage, marsupialization, partial splenectomy, and total splenectomy have all been used [2–4].

However, the treatment of choice is still up for discussion due to the limited evidence.

This work has been reported in line with the SCARE criteria [5].

2. Case report

A 62-year-old male patient was referred to our hospital by his family physician with left-sided abdominal pain with flaring towards the left shoulder, accompanied by early satiety, occasional obstipation, and breathing difficulties. The pain gradually increased over time and the patient described it as ‘unbearable’ the last few weeks with a constant need for painkillers.

His past medical history is significant for groin hernia repair in 2017; no history of previous abdominal trauma was reported. Family history is unremarkable.

Physical examination revealed a fit and otherwise healthy gentleman with only significant finding on the abdomen, a palpable formation 5–6 cm below the left costal margin. His laboratory findings were as follows: WBC $10.5 \times 10^9/L$, RBC $4.34 \times 10^{12}/L$, HGB 122 g/L, AST 6.70 U/L, ALT 6.00 U/L glucose 10.80 mmol/L, creatinine 99 0.70 umol/L, urea 7.30 mmol/L, amylase 50.80 U/L.

* Corresponding author at: Department of Abdominal Surgery, University Hospital St. Naum Ohridski-Skopje, 11 Oktomvri N 53, 1000 Skopje, Macedonia.

E-mail address: zafirovikje@gmail.com (E. Zafirovikj).

<https://doi.org/10.1016/j.ijscr.2021.106475>

Received 15 September 2021; Received in revised form 1 October 2021; Accepted 3 October 2021

Available online 7 October 2021

2210-2612/© 2021 The Authors. Published by Elsevier Ltd on behalf of IJS Publishing Group Ltd. This is an open access article under the CC BY-NC-ND license

(<http://creativecommons.org/licenses/by-nc-nd/4.0/>).

He underwent a CT scan of the abdomen that showed a 15×13 cm splenic cyst with displaced stomach and pancreatic tail medially and left kidney downward, as well as two kidney cysts, 2×1 cm and 2×1.5 cm, on the left and the right kidney respectively (Figs. 1 and 2).

Serologic testing for *Echinococcus* spp. was negative.

Management options were discussed with the patient and he opted for a laparoscopic approach and cyst fenestration.

The operation was performed by a consultant surgeon with advanced knowledge in laparoscopic surgery.

The patient was placed in a conventional full right lateral position with appropriate support and padding. Three port approach was used, with the first 10 mm trocar placed paraumbilical 10 cm below the right costal margin with an open Hassan approach, and two 5 mm trocars were placed in the left anterior axillary line and right subcostal mid-clavicular line.

The operative finding was significant for a large splenic cyst with dense adhesions to the peritoneum, the diaphragm, and the stomach which was pushed towards the right, the left colic flexure was elevated and adherent to the superior surface of the cyst.

Exposure of the cyst was achieved with the division of the adhesions and mobilization of the left colic flexure using electrocautery and Ligasure (Fig. 3).

The cyst was then aspirated and fluid was sent for culture and cytological analysis. Around 2, 5 l of fluid was evacuated in total.

Fenestration of the cyst was performed by excision of the wall of the cyst within one centimeter of the splenic rim. The cyst wall proved to be quite thick and difficult for resection, so we used a variety of instruments including Ligasure, electrocautery, and Harmonic scalpel which proved to be most useful in this case (Fig. 4).

After the fenestration of the cyst was complete, a drain was placed in the cyst bed and omentopexy was performed. The great omentum was placed over the cyst bed drain and fixed by three sutures to the remaining wall of the cyst over the splenic rim.

Postoperatively on day one, the patient was put on a light diet, the drain was removed on day three and the patient was discharged on day four.

Histologic analysis revealed a wall of pseudocyst structure composed of hypocellular fibrocollagen tissue with hyaline zones. Chronic mononuclear inflammatory infiltrates, frequent plasma cells, lymphocytes, macrophages, and multifocal clusters of siderophages are found multifocally in the wall cyst. Hemolyzed blood is also found on some of the samples towards the lumen side. No epithelial or mesothelial lining of the cyst wall was identified (Fig. 5).

Six months after the surgery he was asymptomatic with CT of the

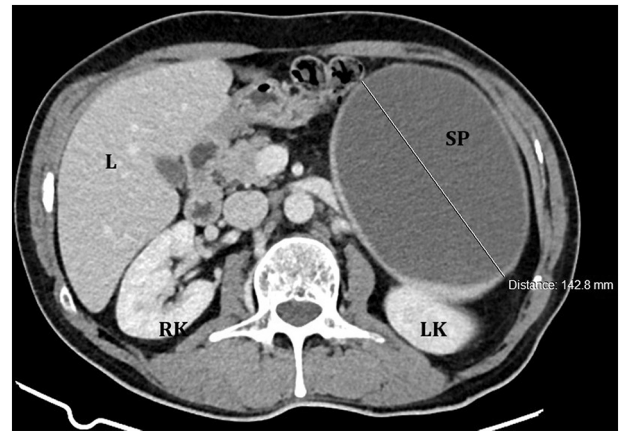


Fig. 2. CT scan abdomen showing displaced left kidney (LK) downward by low density, a non-enhancing cystic mass of the spleen (SP).

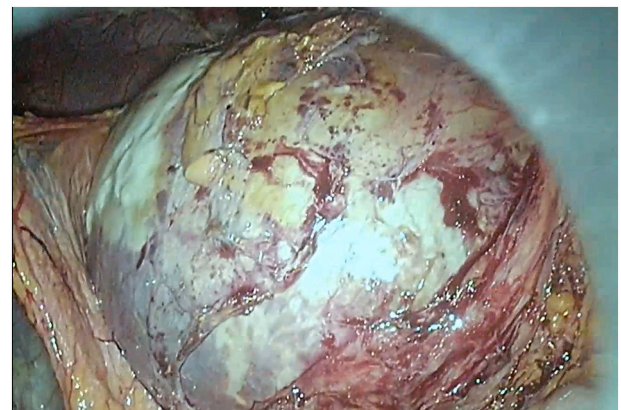


Fig. 3. The cyst exposed with mobilization of the adhesions to the peritoneum and left flexure of the colon.

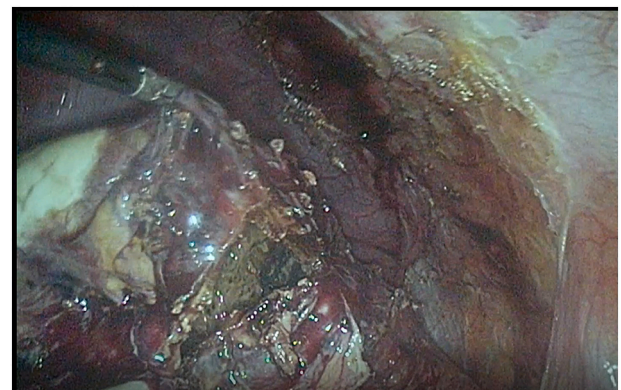


Fig. 4. The cyst after fenestration.

abdomen showing the omentum in cyst bed.

3. Discussion

Since the first report of cystic disease of the spleen by Andral in 1829 [6], less than 800 splenic cysts have been reported in the literature [4,6,7].

A workable clinical classification proposed by Martin is generally accepted where he classifies the cysts based on the presence or absence

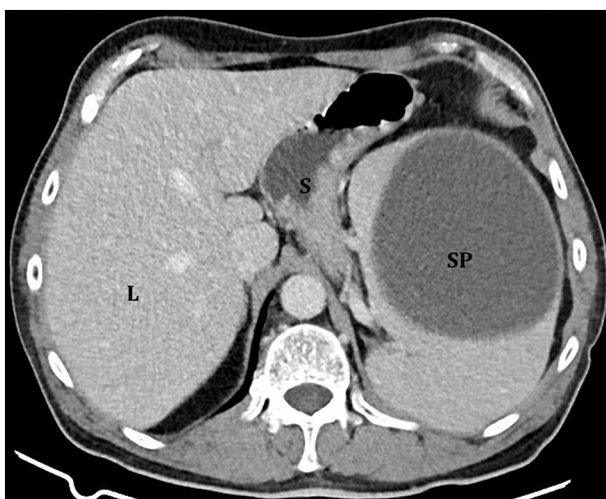


Fig. 1. CT scan of the abdomen show compression of the stomach (S) by a low density, a non-enhancing cystic mass of the spleen (SP).

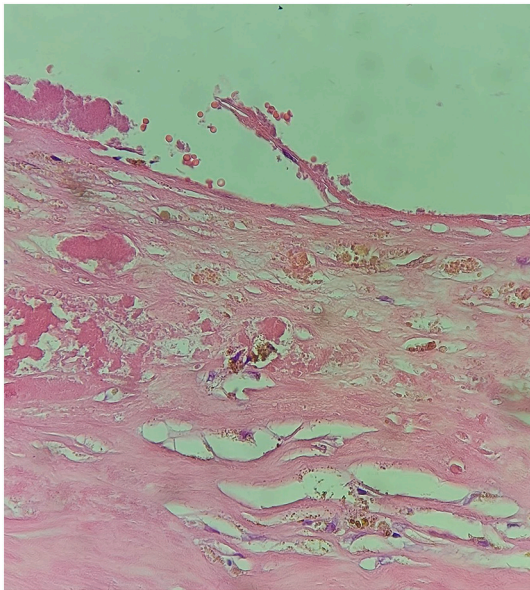


Fig. 5. The microscopic structure of splenic pseudocyst.

of true cellular lining of the cyst wall [8].

1. Primary or true cysts –with cellular lining, which can further be classified as:

- Parasitic-almost exclusively due to *Echinococcus* spp. in regions where hydatid disease prevails.
- Nonparasitic.
- Congenital –less than 10% of total.
- Neoplastic-include dermoid and epidermoid cysts, lymphangiomas, and cavernous angiomas.

2. Secondary or false cysts without true cellular lining or pseudocysts constitute over 75% of all non-parasitic cysts of the spleen.

Pseudocysts of the spleen mostly develop secondary to trauma although, sometimes they can be degeneration cysts arising from secondary changes (for example from arterial degeneration and occlusion resulting in infarction and necrosis of the parenchyma) or infectious associated with CMV infection or mononucleosis for example [9–12]. In addition, Fowler in his paper from 1913 states that 10 of the 66 cases of splenic cysts described were positive for malaria and two for syphilis [9].

The majority of the splenic cysts are diagnosed incidentally during ultrasonography or computed tomography and are asymptomatic [13]. In larger cysts dull abdominal pain in the left hypochondrium and the left shoulder is the most common symptom [11]. Early satiety, nausea, vomiting, and breathing difficulties are often present as well [11]. Although very rare, major complications such as hemorrhage, infection, and cyst rupture can be life-threatening [7].

Treatment decisions are often based on the size of the cyst and related symptoms [5], as well as the age of the patients and their general condition.

In small <5 cm asymptomatic cysts, regular follow-ups are recommended, while in symptomatic and cysts larger than >5 cm surgery is considered the best option [14].

Conservative treatment using percutaneous aspiration of the cyst contents with or without instillation of sclerosing agents has been generally accepted recently [3]; however most of the studies are for true cysts of the spleen in younger patients.

Rifai et al. report in a study of 138 patients only 12 patients had splenic cyst sclerotherapy. In 33% of them only a single therapy session was necessary, while 67% had to undergo 1–11 further ultrasound-guided fine-needle cyst therapies after the initial sclerotherapy [15].

Partial splenectomy is another option used more frequently lately

with the introduction of new techniques for parenchyma dissection with partial ischemia by splenic hilum vascular dissection/ligation [16]. Nevertheless, severe and life threatening complications are also reported such as ischemia/infarction of the splenic remnant as the most common reason for intraoperative conversion to total splenectomy, as well as, small bowel perforation requiring resection, pneumothorax from diaphragm lesion and massive bleeding exceeding 1000 ml [16].

For this reason until recently splenectomy was the surgical treatment of choice for all large or symptomatic cystic lesions of the spleen [3], as cyst aspiration often leads to recurrence and partial splenectomy is associated with an increased rate of complications. However, with growing knowledge about the protective role of the spleen as an organ of reticuloendothelial and hematopoietic importance, more specifically of OPSI, the current approach has been of splenic conservation [17].

As splenic cysts are seen infrequently it is unlikely that a randomized controlled study comparing surgical techniques could be performed [18].

However, based on the many case reports published to date, laparoscopic splenic cyst fenestration appears to be a safe and effective treatment for uncomplicated nonparasitic splenic cysts [18].

4. Conclusion

The goal of splenic cyst treatment is to relieve symptoms, prevent complications and cyst recurrence.

Laparoscopic cyst fenestration with omentopexy proved to be a safe and effective method for the definitive treatment of splenic cysts.

Provenance and peer review

Not commissioned, externally peer-reviewed.

Funding

There are no external funding resources for the study.

Ethical approval

Ethical approval is not required.

Consent

Written informed consent was obtained from the patient for publication of this case report and accompanying images. A copy of the written consent is available for review by the Editor-in-Chief of this journal on request.

Registration of research studies

Not applicable.

Guarantor

Elena Zafirovikj

CRediT authorship contribution statement

Elena Zafirovikj performed the operation, research, collected and analyzed the data, drafting, revision and approval of final manuscript. Blagica Krsteska performed the histologic analysis and images and revision and approval of final manuscript.

Declaration of competing interest

The authors report no declarations of interest.

References

- [1] Y. Feng, X. Qi, Y. Jin, Y. Yu, H. Geng, J. Li, Giant splenic pseudocyst: a case report and literature review, *Austin J. Clin. Case Rep.* 6 (2) (2019) 1145.
- [2] S.W. Mun, T.J. Lim, E.H. Hwang, Y.J. Lee, U.B. Jeon, J.H. Park, A case of post-traumatic pseudocyst in the spleen was successfully treated with alcohol sclerotherapy, in: *Pediatric Gastroenterology, Hepatology, and Nutrition* 18(4), 2015, pp. 276–279, <https://doi.org/10.5223/pghn.2015.18.4.276>.
- [3] S. Chawla, P. Kumar, R.L. Gogna, Post-traumatic pseudocyst of the spleen, *Med. J. Armed Forces India* 61 (3) (2005) 279–280, [https://doi.org/10.1016/S0377-1237\(05\)80175-3](https://doi.org/10.1016/S0377-1237(05)80175-3).
- [4] J. Spanyer, I. Jaafar, M. Mackowski, F. Kehdy, Laparoscopic treatment of nonparasitic splenic cysts, *Am. Surg.* 81 (2) (2015) E75–E77, <https://doi.org/10.1177/000313481508100213>.
- [5] R.A. Agha, T. Franchi, C. Sohrabi, G. Mathew, for the SCARE Group, The SCARE 2020 guideline: updating consensus Surgical Case REport (SCARE) guidelines, *Int. J. Surg.* 84 (2020) 226–230.
- [6] A. Verma, A. Yadav, S. Sharma, D. Saini, P. Om, H. Khoja, K. Banerjee, H. NL, A rare splenic pseudocyst, *J. Surg. Case Rep.* 2013 (9) (2013), rjt086, <https://doi.org/10.1093/jscr/rjt086>.
- [7] Giant pseudocyst of the spleen: A case report and review of the literature, Krasimira Kalinova, Department of Pediatric Surgery, University Hospital, Stara Zagora, Bulgaria 2 July 2005 *Journal of Indian Association of Pediatric Surgeons* 10(3) DOI:10.4103/0971-9261.16971.
- [8] J.W. Martin, Congenital splenic cysts, *Am. J. Surg.* 96 (2) (1958) 302–308, [https://doi.org/10.1016/0002-9610\(58\)90916-4](https://doi.org/10.1016/0002-9610(58)90916-4).
- [9] M. Senol, H. Ozdemir, I.T. Sahiner, Z.U. Ozdemir, Non-traumatic pseudocyst of the spleen: a case report, *Kafkas J. Med. Sci.* 4 (2) (2014) 79–83, <https://doi.org/10.5505/kjms.2014.24008>.
- [10] L.A. Schlittler, V.W. Dallagasperina, Cistos esplênicos não-parasitários, *Rev. Colégio Bras. Cirurgiões* 37 (6) (2010) 442–446, <https://doi.org/10.1590/s0100-69912010000600011>.
- [11] C. Kishanchand, R. Naalla, S. Kumar, M. Mathew, Non-traumatic pseudocyst of spleen presenting as chronic abdominal pain and vomiting, *BMJ Case Rep.* 2014 (2014) 9–10, <https://doi.org/10.1136/bcr-2014-207133>.
- [12] A. Anjum, J.T. Neuman, R. Sidlow, A large congenital splenic pseudocyst in an adolescent treated surgically after failed percutaneous drainage, *J. Pediatr. Surg. Case Rep.* 35 (May) (2018) 14–16, <https://doi.org/10.1016/j.epsc.2018.05.009>.
- [13] E.A. Karfis, E. Roustanis, E.C. Tsimoyiannis, Surgical management of nonparasitic splenic cysts, *JLS* 13 (2) (2009 Apr-Jun) 207–212. PMID: 19660217; PMCID: PMC3015942.16.
- [14] Hansen and Moller2 Cabano, F., Venegoni, A., & De Medici, A. (1990). Splenic cysts. *Chirurgia Italiana*, 42(5–6), 198–207.
- [15] K. Rifai, D. Berger, A. Potthoff, M.P. Manns, M.J. Gebel, Fine needle sclerotherapy as a new effective therapeutic approach for nonparasitic splenic cysts: a case series, *Dig. Liver Dis.* 45 (7) (2013) 595–599, <https://doi.org/10.1016/j.dld.2012.12.008>.
- [16] R. Costi, C. Castro Ruiz, A. Romboli, P. Wind, V. Violi, A. Zarzavadjian Le Bian, Partial splenectomy: who, when and how. A systematic review of the 2130 published cases, *J. Pediatr. Surg.* 54 (8) (2019 Aug) 1527–1538, <https://doi.org/10.1016/j.jpedsurg.2018.11.010>. Epub 2018 Dec 5. PMID: 30665627.
- [17] Case Reports in Gastrointestinal Medicine, 25 Dec 2017, 2017:9896856 DOI: 10.1155/2017/9896856 PMID: 29435376 PMCID: PMC5757091.
- [18] Comitolo JB. Laparoscopic treatment of splenic cysts. *JLS*. 2001 Oct-Dec;5(4): 313-6. PMID: 11719977; PMCID: PMC3015395.