

# Penile cancer after a tick bite: A possible association

SAGE Open Medical Case Reports  
Volume 9: 1–3  
© The Author(s) 2021  
Article reuse guidelines:  
sagepub.com/journals-permissions  
DOI: 10.1177/2050313X211036779  
journals.sagepub.com/home/sco



Ognen Ivanovski<sup>1</sup> , Skender Saidi<sup>1</sup>, Bashkim Shabani<sup>1</sup>, Slobodan Gurmshesovski<sup>1</sup>, Risto Pejkov<sup>1</sup>, Selim Komina<sup>2</sup> and Aleksandra Gavrilovska-Brazanov<sup>3</sup>

## Abstract

Penile cancer is a rare cancer in Western countries, but is more common in parts of the developing world. Usually, it is associated with older uncircumcised men who have a long-term phymotic preputium. Here, we report a case of penile cancer in a circumcised patient, occurring 3 months after a tick bite on the head of the penis. To the best of our knowledge, this is the first report that suggests a possible association between Lyme disease and occurrence of “de novo” penile cancer. Further studies are needed to confirm this hypothesis.

## Keywords

Penile cancer, tick bite, inflammation, Lyme disease, penectomy

Date received: 22 December 2020; accepted: 12 July 2021

## Introduction

Penile cancer is a rare but aggressive disease. It usually presents as a painless ulcer or lump on the head of the penis. Squamous cell carcinoma represents the most common histological subtype of penile cancer with pathogenesis intimately linked to chronic Human Papilloma Virus (HPV) infection.<sup>1</sup> Here we report a patient who has been bitten by a tick on the head of the penis that subsequently developed into a penile cancer 3 months after the bite. A possible association between Lyme’s disease and de novo penile cancer is discussed.

## Case report

A 48-year-old circumcised patient, working as a sheep shearer, presented with ulcerous and inflammatory lesion of the penis with crusts spreading from the tip of the glans until the subcoroneal penile shaft. He reported that the disease has begun 3 months earlier when he found a tick under the glans that he took out by himself using a burning cigarette without any medical assistance. However, the lesion started to spread locally leading to inflammation and pain. He subsequently developed an expanding penile rash with crusts but did not report any systematic symptoms such as fever, malaise, and/or regional lymphadenopathy. The family medicine doctor ordered an enzyme immunoassay (EIA) to measure IgM and

IgG antibodies specific for Lyme disease and prescribed 14 days of doxycycline based on increased IgM values but negative IgG, suggesting a very recent infection. Thereafter, he referred the patient to an infectious disease specialist for evaluation.

When presented at our Clinic, 3 months after the bite, the head of the penis along with the distal part of the urethra was completely destroyed. No enlarged inguinal nodes were observed. A lesion biopsy was immediately scheduled that revealed well-differentiated squamous cell carcinoma accompanied with an extensive inflammatory component. A partial penile amputation was performed with negative margins revealed from intraoperative frozen section (Figure 1(a) and (b)). However, during the operation, a large inflammatory component was observed manifesting as pus-like

<sup>1</sup>University Clinic of Urology, Medical Faculty, University “SS Cyril and Methodius,” Skopje, Macedonia

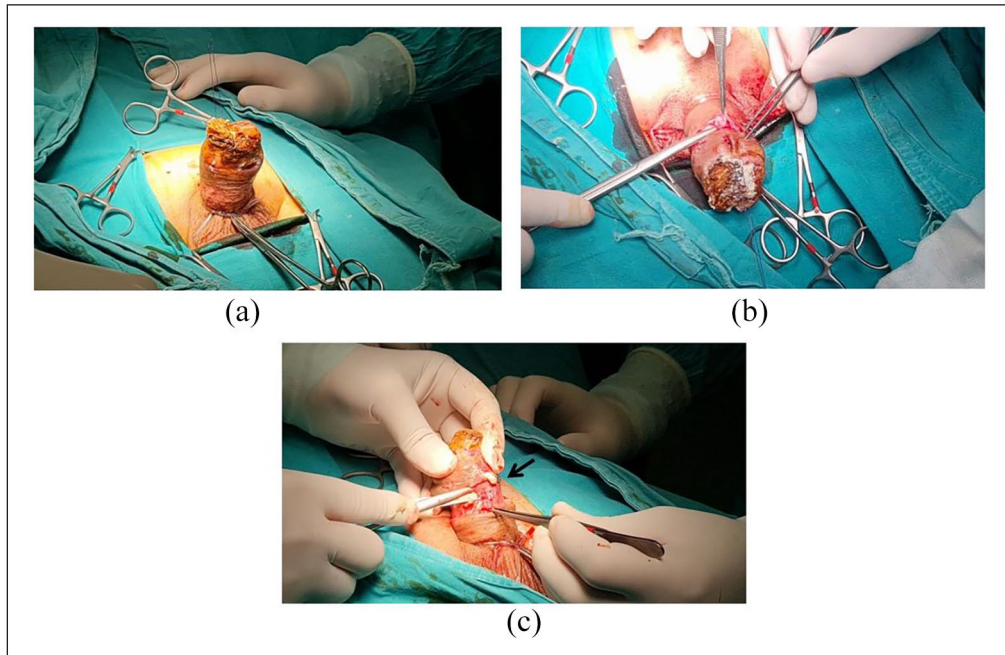
<sup>2</sup>Institute of Pathology, University “SS Cyril and Methodius,” Skopje, Macedonia

<sup>3</sup>University Clinic for Traumatology, Orthopaedic Diseases, Anaesthesia, Reanimation, Intensive Care and Emergency Centre, Medical Faculty, University “SS Cyril and Methodius,” Skopje, Macedonia

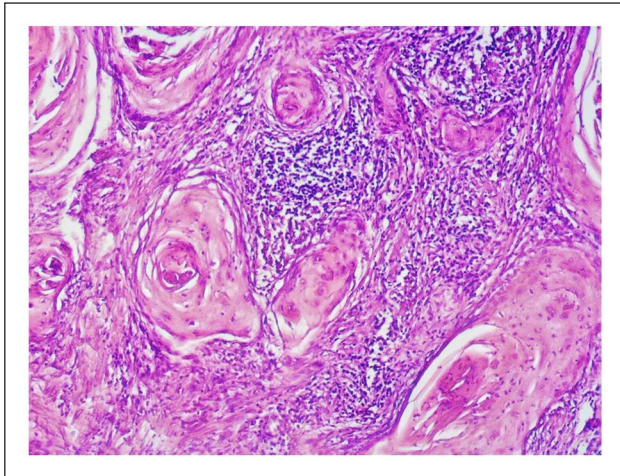
### Corresponding Author:

Ognen Ivanovski, University Clinic of Urology, Medical Faculty, University “Ss Cyril and Methodius,” Vodnjanska 17, 1000 Skopje, Macedonia.  
Email: ognen.ivanovski@medf.ukim.edu.mk





**Figure 1.** Representative intraoperative images of the penile cancer. (a) Preoperative appearance. (b) Dissecting neurovascular bundle. (c) Dissecting ventral side of the penis and the urethra. Arrow points the white pus-like material leaking from the corporal bodies.



**Figure 2.** Haematoxylin and eosin staining confirming squamous cell carcinoma that invades the spongios and corporal bodies and a large infiltration of inflammatory cells consistent of neutrophils and eosinophils.

material leaking from the corporal bodies (Figure 1(c)). Haematoxylin and eosin staining confirmed squamous cell carcinoma that invades the spongios and corporal bodies (pT3, L0, V0, G1, R0) and a large infiltration of inflammatory cells consistent of neutrophils and eosinophils (Figure 2). However, the Warthin–Starry stain of the pathological sample that shows various microorganisms tested negative. The patient was treated with broad spectrum of antibiotics postoperatively. He was dismissed from the hospital the third

postoperative day and was put on surveillance every 6 months since. Recent CT scan showed neither lymph node involvement nor local or distant metastasis. In terms of functional outcome 1 year after the operation, he has a normal voiding and even a sexual function.

## Discussion

Here we report an occurrence of penile cancer in a circumcised patient occurring 3 months after a tick bite on the head of the penis. Before the incident, he had a normal penis without lesions. To the best of our knowledge, this is a third report of a tick bite on the head of the penis<sup>2,3</sup> and first report that suggests an association of tick bite (Lyme diseases) and penile cancer.

Lyme disease, also known as Lyme borreliosis, is an infectious disease caused by the *Borrelia* bacterium, which is spread by ticks. Tick-borne illnesses range from a mild fever that may be treated at home to a severe disease necessitating hospitalization. Occupationally acquired, tick bites are often seen in people working with animals that are prone to ticks. The patient has been sheep shearing for 4 months of the year for the past 20 years working all over the region. It is not the first time that he was bitten by a tick. However, following the tick bite on the head of the penis, symptoms begin to manifest as pruritus and burning at the site of the lesion, without systematic signs such as fever, malaise, and/or regional lymphadenopathy.

Tick bites of the penis have rarely been reported. The first report dated from 1939 when first two cases were published.

Shields et al.<sup>4</sup> have recently published two cases of possible tick bites in children manifesting as significant scrotal cellulitis in one and swelling and induration of the distal penis and glans, pruritus of the left groin and penis in the second. The authors suggest a high index of suspicion because a tick bite may present as penile edema. Nishi et al.<sup>5</sup> reported a case of a tick bite on the shaft of the penis that was surgically excised. Okahashi et al.<sup>6</sup> emphasizes the need for deep excision of tick bite lesions on the penis.

Penile cancer is a rare cancer in Western countries, but is more common in parts of the developing world. In these areas, penile cancer can account for up to 10% to 20% of all malignancies in men.<sup>7</sup> Among etiological factors, it seems that HPV infection plays a prominent role. In a recent review, 40% of all penile cancers were HPV related and type 16 HPV was the most common subtype often associated with aggressive variants of penile tumors with a poorer outcome in these patients.<sup>8</sup> In this patient, a local inflammatory reaction occurred after a tick bite and chronic inflammation is associated with increased risk of penile cancer.<sup>9</sup> Among proposed mechanisms, it seems that overexpression of NF- $\kappa$ B in cervical and penile cancers is a key modulator in driving chronic inflammation to cancer. Increased NF- $\kappa$ B activity is associated with many cancers, especially cancers associated with viral infections.<sup>10</sup>

The increased risk in penile cancer prone areas may be due to differences in hygiene practices and increased numbers of uncircumcised males who are more likely to get and stay infected with HPV. In a systematic review, Larke et al.<sup>11</sup> reported a strong protective effect of childhood/adolescent circumcision on invasive penile cancer. The current patient had been circumcised as a child. Nevertheless, he develops squamous cell carcinoma of the glans suggesting a possible link between the tick bite with the occurrence of de novo penile cancer.

A recent study suggested a link between zoophilia and penile cancer in a cohort of nearly 500 men.<sup>12</sup> In this study, 44.9% of men with penile cancer reported sex with animals versus 31.6% of controls. Both univariate and multivariate analysis suggested zoophilia may be a risk factor for penile cancer. However, our patient had denied any link with this behavior.

## Conclusion

This is first report that suggests a possible association between Lyme disease and occurrence of “de novo” penile cancer. Further studies are needed to confirm this hypothesis.

## Declaration of conflicting interests

The author(s) declared no potential conflicts of interest with respect to the research, authorship, and/or publication of this article.

## Ethics approval

Our institution does not require ethical approval for reporting individual cases or case series.

## Funding

The author(s) received no financial support for the research, authorship, and/or publication of this article.

## Informed consent

Written informed consent was obtained from the patient(s) for their anonymized information to be published in this article.

## ORCID iD

Ognen Ivanovski  <https://orcid.org/0000-0002-3359-5771>

## References

1. Peyraud F, Allenet C, Gross-Goupil M, et al. Current management and future perspectives of penile cancer: an updated review. *Cancer Treat Rev* 2020; 90: 102087.
2. Suh KS, Park JB, Han SH, et al. Tick bite on glans penis: the role of dermoscopy. *Ann Dermatol* 2013; 25(4): 528–530.
3. Brunet WM. Wood ticks found on the penis: case reports. *Br J Vener Dis* 1939; 15(1): 55–56.
4. Shields LBE, Peppas DS and Rosenberg E. Urological evidence of tick bites in children. *Pediatr Emerg Care. Epub ahead of print* 20 December 2019. DOI: 10.1097/PEC.0000000000001933.
5. Nishi M, Matsumoto K, Sawamura M, et al. [Tick-bite in penile skin: a case report]. *Hinyokika Kyo* 2010; 56(3): 185–187.
6. Okahashi K, Oiso N, Yano Y, et al. Tick attachment cement to a feeding cavity in the deep dermis of the penis. *Acta Derm Venereol* 2015; 95: 741–742.
7. Chalya PL, Rambau PF, Masalu N, et al. Ten-year surgical experiences with penile cancer at a tertiary care hospital in northwestern Tanzania: a retrospective study of 236 patients. *World J Surg Oncol* 2015; 13: 71.
8. Backes DM, Kurman RJ, Pimenta JM, et al. Systematic review of human papillomavirus prevalence in invasive penile cancer. *Cancer Causes Control* 2009; 20(4): 449–457.
9. Archier E, Devaux S, Castela E, et al. Carcinogenic risks of psoralen UV-A therapy and narrowband UV-B therapy in chronic plaque psoriasis: a systematic literature review. *J Eur Acad Dermatol Venereol* 2012; 26(Suppl. 3): 22–31.
10. Senba M, Buziba N, Mori N, et al. Human papillomavirus infection induces NF- $\kappa$ B activation in cervical cancer: a comparison with penile cancer. *Oncol Lett* 2011; 2: 65–68.
11. Larke NL, Thomas SL, dos Santos Silva I, et al. Male circumcision and penile cancer: a systematic review and meta-analysis. *Cancer Causes Control* 2011; 22(8): 1097–1110.
12. Zequi Sde C, Guimarães GC, da Fonseca FP, et al. Sex with animals (SWA): behavioral characteristics and possible association with penile cancer. *J Sex Med* 2012; 9(7): 1860–1867.