

CIRCONSCRIPT SUBCUTANEOUS ARTERIOVENOUS MALFORMATION OF THE HEAD

Vladimir Mirchevski¹, Elizabeta Zogovska², Aleksandar Chaparoski¹, Venko Filipce¹, Milenko Kostov¹, Mirko Mishel Mirchevski⁴

¹ University Clinic for Neurosurgery, Clinical Center “Mother Teresa” Skopje, Macedonia

² University Clinic for Plastic, Aesthetic and Reconstructive Surgery, Clinical Center “Mother Teresa” Skopje, Macedonia

³ Clinic for Anesthesiology, Reanimation and Intensive Care, Clinical Center “Mother Teresa” Skopje, Macedonia

⁴ Medical faculty, University of “Cyril and Methodius” Skopje, Macedonia

Corresponding Author: Vladimir Mirchevski, University Clinic for Neurosurgery, Clinical Center “Mother Teresa” Skopje, Macedonia

SUMMARY

The aim of this study is to show the various possibilities to treat this rare malformation, accentuating the results of the early surgical treatment before complications.

Material: The authors present 8 cases of patients with subcutaneous arteriovenous malformations, 5 females and 3 males (age of 7, 13, 19, 23, 27, 52 and 58 years) treated in the period of 1999 until 2015 at the Clinic for Neurosurgery and the Clinic for Plastic, Aesthetic and Reconstructive Surgery in Skopje, Republic of Macedonia. This malformation has been observed by the parents in the childhood, around the age of 3 years in all cases. Local red circumscribed nodule, soft, with manually discharging tendency and varicose dilated veins have been observed in all cases, deaf on both sides in one case, while in the older case, a cavernous sinus thrombosis caused unilateral exophthalmia, hyaline indurated ophthalmic vein, vertigo, arrhythmia, heart failure and bradypsychia have been observed. The size of the malformation has been from 2.5 to 7 cm. The diagnostics was done using CT, CT-angiography and digital angiography including external carotid angiography. Endocranial arterials peduncle was present in all cases.

Results: Six cases underwent surgery, while two cases were treated with several treatments of endovascular embolization. The follow up has been ranged from 2 to 15 years. All surgically treated patients improved without recurrence, the exophthalmia, bradypsychia and the heart problems regressed, while in patients treated with endovascular non-complete occlusion the AVM decreased, but still remained.

In conclusion: The Surgical treatment remains a first option if it is possible, and as earlier as possible, while embolization is a useful tool in cases where a complete excision is not possible.

Kew words: Subcutaneous AVM, surgery

INTRODUCTION

Subcutaneous arteriovenous malformations are known as angioma arteriovenosum cirsoides or aneurisma arteriovenosum cirsoides¹ in the literature¹. They often appear in the subcutaneous tissue of the head and the face, rarely elsewhere on the human body. Although there are some indications in the literature for the traumatic cause whether, at birth or soon after

birth, an error in the development of the blood vessels in the normal embryonic arteriovenous seals of the primitive bloodstream is rather adopted.

Therefore at that place appears a constant entry of arterial blood in the veins, which makes them dilated, soar and tortuous due to the increased pressure. The increased blood pressure in the veins causes reactive flourishing of the tissue in the walls of the venous junctions and therefore, they become increased and thicker.

CLINICAL MATERIAL

In the period of 15 year from 1999 to 2015 at the Clinic for Neurosurgery and the Clinic for Plastic, Cosmetic and Reconstructive Surgery in Skopje,

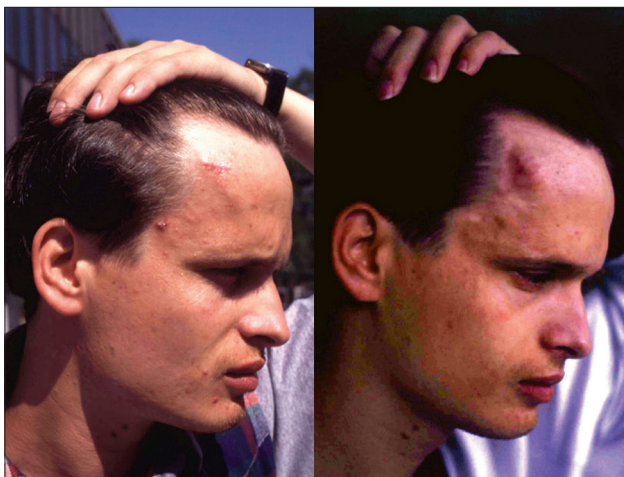

Figure 1. Subcutaneous arterio-venous malformation in right frontal region; before and eight days after the surgical excision.

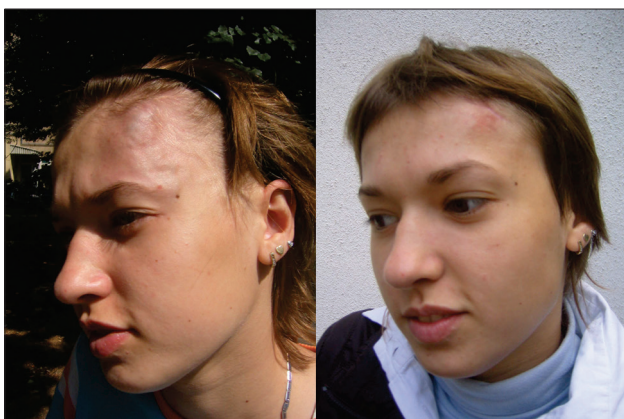

Figure 2. Subcutaneous arterio-venous malformation in right frontal region; before and one month after the surgical treatment

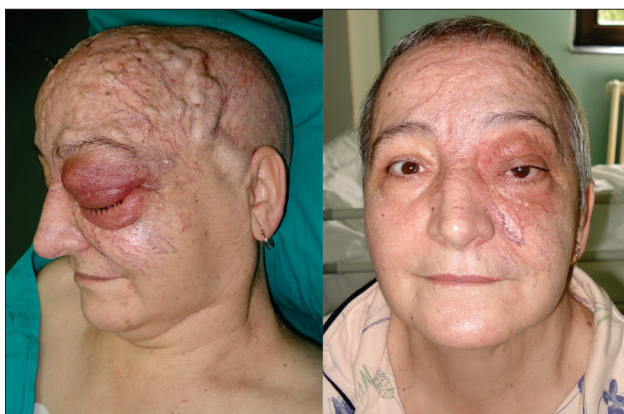

Figure 3. Subcutaneous arterio-venous malformation in the left temporoparietal region complicated with exophthalmia due to sinus thrombosis in the oldest patient; before and two months after the surgery.

Republic of Macedonia we observed and treated eight patients with subcutaneous arterio-venous malformations, five females and 3 males with different ages (...7, 13, 19, 23, 27, 52 and 58 years...) average 28.5 years, median 25 years.

The malformation is noticed in the parents in the childhood (about the 3rd year after birth), but due to insufficient knowledge of the pathology and the insufficient diagnostics the medical treatment has been delayed.

The clinical picture in all patients manifested local red circumscribed island on the skin of the frontal, parietal or temporal area of the skin of the skull, soft on palpation with the tendency to diminish the volume under pressure, dilated varicose vein of the scalp and systolic noise on auscultation over the swelling. The two youngest patients have a pulsatile swelling of one temporal region, one with loss of audition because of extension to the pyramidal bone. The oldest patient has exophthalmia due to cavernous sinus thrombosis and consecutive purulent conjunctivitis, ptosis, hyaline changed dilated varicose veins, arrhythmias, cardiac problems arising from chronic cardiomyopathy and bradycardia. The size of the arterio-venous malformation appears from 2.5 to 7 cm in diameter, all with endocranial feeders.

DIAGNOSIS

The diagnosis is set up with clinical examination, computed tomography, magnetic resonance imaging of the brain, CT-angiography and digital pan angiography, showing external carotid arteries of both sides.

TREATMENT

The arterio-venous malformation has been excised in 6 patients, while two patients have been partially treated in the Acibadem hospital with partial endovascular embolization. The oldest patient with exophthalmia has been firstly treated with adequate antibiotic therapy after antibiogram and after the remission of the infection the malformation has been excised.

RESULTS

The revascularization of the malformation in surgically treated patients is not observed. An excellent aesthetic results and complete disappearance of the varicose veins is observed in five cases. Varicose veins regressed in the oldest patient treated surgically, the exophthalmia was withdrawn, the mesh completely open, and remained only a small soft tissue in

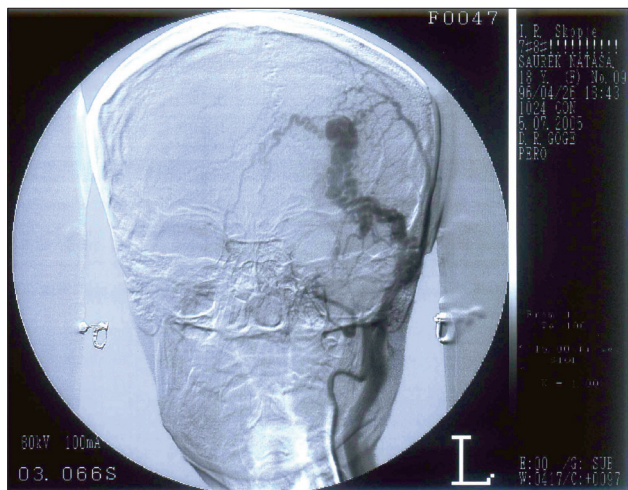


Figure 4. Digital angiography of the patient with arteriovenous malformation in the left frontal region.

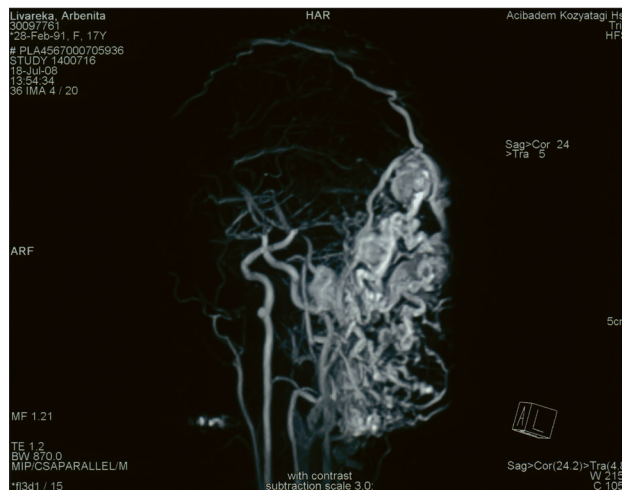


Figure 5. Digital angiography of the patient with arteriovenous malformation in the left temporal region.

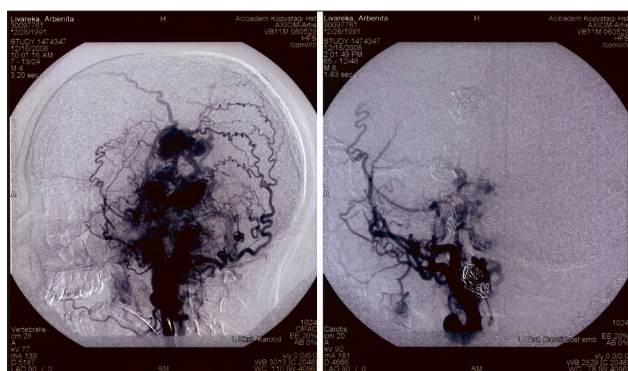


Figure 6. Digital angiography in the patient with subcutaneous arteriovenous malformations in the left temporal region before and after a partial endovascular treatment.

the upper level of the term eyelid which corresponds to the changed hyaline varicose ophthalmic vein. Furthermore, the patient changed her behavior, from depressive and slow she became dynamic, quick in reactions (according to the statement of the children "...completely different personality..."), the cardiac problems disappeared. There is amelioration in the two cases treated with partial embolization, but the malformation still persists on auscultation and angiography.

DISCUSSION

The malformation is not easy to identify because it is not a frequent one^{2,6,7,8,9,10,11,12,15,16,19,20}; sometimes it could remain unknown to the specialists in plastic, aesthetic and reconstructive surgery. In the literature there are few published papers on treatment of the subcutaneous arteriovenous malformations of the sculp. According to the published papers, the surgical excision remains radical manner for treatment

of these malformations. It is usually feasible when the nidus of the malformation is small and easily accessible for excision. In older age when the varicose developed veins of the scalp may cover the malformation, or when other associated complications may appear changing the surrounding skin, the modern medicine employs the methods of endovascular embolization. However, the endovascular treatment is rarely complete and may lead to incomplete occlusion of the malformation because of the many anastomoses of the blood vessels of the skin^{3,18,23}. Apart from that, the endovascular treatment may lead the hair disorder in a certain part of the head causing an unpleasant aesthetic effect. Therefore, a combined surgical treatment with surgical excision of the nidus or ligation of certain arteries or branches of the artery that feed the malformation may be employed.

CONCLUSION

The early recognition and treatment of circumscribed subcutaneous arteriovenous malformations of the scalp is of great importance because of the excellent results. A complete angiographic study of the head is mandatory before the treatment. The surgical treatment represents the first option in the medical treatment of these malformations, if possible, and should be realized as earlier as possible. The endovascular treatment may be applied as an additional method in the medical treatment, independent or combined with the operational treatment.

BIBLIOGRAPHY

1. Fisher-Jeffes N.D., Domingo Z., Madden M., Villiers J.C., Arteriovenous malformation of the scalp. *Neurosurgery* 1995;36:656-60.

2. Goya T., Kitano I., Kinoshita K., Mihara K., Congenital arteriovenous malformation of the scalp. Report of two cases. *No Shinkei Geka (Jpn)* 1981;9:1089-1097.
3. Ikeda Y., Nakazawa S., Higuchi H., Honda K., Embolisation of an arteriovenous malformation of the scalp using stainless steel coils. *Neurol. Med. Chir. (Tokyo)* 1983;23:273-277
4. Irving A.D., Thakur A., Walker W.F., Cirroid aneurysm of the scalp, *J.R.Coll.Surg.Edinb.* 1982;27:115
5. Khodadad G., Arteriovenous malformation of the scalp. *Ann.Surg.* 1973;177:79-85
6. Komatsu Y., Narushima K., Kobayashi E., Nose T., Maki Y., Congenital arteriovenous malformation of the scalp: case report. *Neurol.Med. Chir. (Tokyo)* 1989;29:230-234
7. Konishi Y., Tamagawa T., Hara M., Takeuchi K., Toyoda H., Cirroid aneurysm of the scalp. Case report. *Neurol.Med.Chir. (Tokyo)*(Jpn) 1982;22:673-676
8. Kuroki K., Taguchi H., Sumida M., Eguchi K., Saitoh Y., A case of haemorrhagic non traumatic arteriovenous fistula of the scalp *No Shinkei Geka (Jpn)* 1999;27:851-853
9. Matsushige T., Kiya K., Satoh H., Mizoue T., Kagawa K., Araki H., Arteriovenous Malformation of the Scalp: Case report and Review of the Literature, *Surgical Neurology* 2004;62:253-259
10. Mohanty S., Rao C.J., A large cirroid aneurysm of the scalp associated with epilepsy. *Jornal of Neurology, Neurosurgery and Psychiatry* 1976;39:835-836.
11. Nishimura T., Kubota S., A case of congenital AVM in temporoparietal muscle. *No Shinkei Geka (Jpn)* 1996;24:277-280
12. Nishimura T., Nishida A., Handa A., Gotoh M., Tsuno K., Ishimitsu H., Congenital arteriovenous malformation of the scalp with drainage to the transverse sinus: a case report. *No Shinkei Geka (Jpn)* 1999;27:895-901
13. Ohno K., Tone O., Inaba Y., Terasaki T., Coexistent congenital arteriovenous malformation and aneurysm of the scalp. *No Shinkei Geka (Jpn)* 1981;9:1187-1191
14. Schultz R.C., Hermosillo C.X., Congenital arteriovenous malformation of the face and scalp. *Plastic and Reconstructive Surgery* 1980;65:496-501.
15. Shimoda M., Matumae M., Shibuya N., Yamamoto I., Sato O., Three cases of scalp arteriovenous malformation. *No Shinkei Geka (Jpn)* 1987;15:173-178
16. Steinfl G., *Vojno Sanitetski Pregled;* 19:10. 707-709, 1962
17. Stucker F.J. Extracranial arteriovenous fistulas. *Laryngoscope* 1974;84:970-975
18. Takahashi N., Kikuchi H., Karasawa J., Embolisation and detached balloon occlusion by femoral route in craniofacial lesions. *No Shinkei Geka (Jpn)* 1983;11:591-602
19. Takahashi N., Furuhashi N., Koushu K., Congenital arteriovenous malformation of the extracranial region. Report of the case with review of literature., *No Shinkei Geka (Jpn)* 1977;5:889-893.
20. Tani S., Kawamoto A., Kawamura Y., Matsumura H., Tanaka M., Ikeda K., Vascular tumor of the scalp. A cause of haemangioendothelioma and two cases of cirroid aneurysm. *Neuro.Med. Chir.* 1983;23:755-760
21. Vasconnez L.O., Congenital defect of the skull and scalp due to an arteriovenous malformation. *Plastic and Reconstructive Surgery* 1973;51:692-695.
22. Waga S., Ohtsubo K., Handa H., Extracranial congenital arteriovenous malformations. *Surgical Neurology* 1974;2:241-245.
23. Yamaki T., Yoshino E., Uchibori M., Odake G., Hirakawa K., Artificial embolisation with cyanoacrylate for the treatment of the extracranial arteriovenous malformation. *No Shinkei Geka (Jpn)* 1982;10:991-995.

Резиме

ЦИРКОНСКРИПТНИ ПОТКОЖНИ АРТЕРИОВЕНСКИ МАЛФОРМАЦИИ НА ГЛАВАТА

Владимир Мирчевски¹, Елизабета Жоговска², Александар Чапароски¹,
Венко Филипче^{1,5}, Миленко Костов¹, Мирко Мишел Мирчевски⁴

¹ Универзитетската клиника за неврохирургија, Клинички центар „Мајка Тереза“, Скопје, Македонија

² Универзитетска клиника за пластична, естетска и реконструктивна хирургија,
Клинички центар „Мајка Тереза“, Скопје, Македонија

³ Специјална болница за ортопедска хирургија и трауматологија „Св Еразмо“ - Охрид, Македонија

⁴ Клиниката за анестезија, реанимација и интензивна нега, Клинички центар „Мајка Тереза“, Скопје,
Македонија

⁵ Медицински факултет, Универзитет „Св. Кирил и Методиј“, Скопје, Македонија

Апстракт

Целта на овој труд е да се прикажат различните можности за третман на овие ретки малформации, ставајќи акцент на раниот третман, додека не настанат големи компликации.

Материјал: Авторите прикажуваат 8 случаи на поткожни артериовенски малформации, 5 женски и 3 машки (возраст 7, 13, 18, 19, 23, 27, 52 и 58 години) лекувани во периодот од 1999 до 2015 година на Клиниката за неврохирургија и на Клиниката за пластична, естетска и реконструктивна хирургија во Скопје, Република Македонија. Малформацијата кај пациентите била забележана од родителите во детска возраст (од три години). Болеста се манифестирала со локален црвен цирконскриптен оток на кожата на поглавината, мек на палпација, со тенденција на празнење на притисок до варикозно дилатирани вени на поглавината кај сите четири случаи, глувост на двете уши кај една пациентка, додека кај возрасната личност и со егзофталмус поради додатна тромбоза на sinus cavernosus, хијалино променети дилатирани варикозни вени, аритмии, срцеви проблеми што произлегуваат од хроничното преоптоварување на срцето и брадикардија. Дијаметарот на малформацијата од 2,5 до 7 cm е неправилен. Дијагнозата е поставена со КТ-скен, КТ-ангиографија и дигитална панангиографија, вклучувајќи и a. carotis externa. Сите случаи имале ендокранијални артериски педункули, кои ја хранеле малформацијата.

Резултат: Третманот кај 6 случаи е изведен оперативно, со ексцизија на малформацијата, додека кај двајца пациенти таа е делумно емболизирана. Постоперативното следење на пациентите изнесува од 3 до 15 години, кај оперативно лекуваните пациенти нема рецидив, додека кај пациентката лекувана со емболизација сè уште постои васкуларна малформација.

Заклучок: Хируршкиот третман претставува прва опција во лекувањето на овие малформации, доколку е можен и што е можно порано, додека емболизацијата може да се примени како дополнителна метода во лекувањето.

Кew words: поткожен AVM, операција