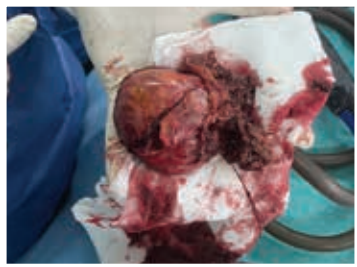


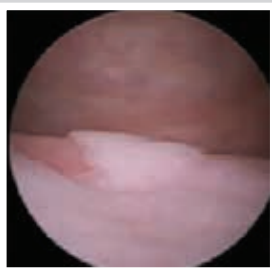
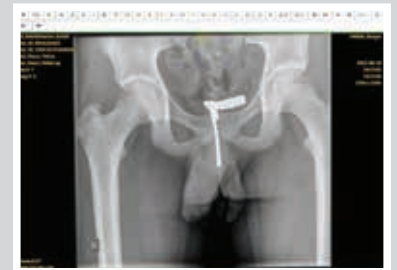
# УРОНЕТ



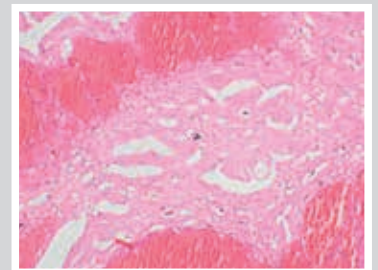
**Тумори на надбъбрека**

**Рядък клиничен случай**



**Заболявания на пикочния мехур**

**Тумори на бъбрека – онкоцитом**





В хармония със себе си...

УроГард съдържа екстракт от червена боровинка и пробиотични бактерии.

**Препоръчителна дневна доза:**

*При възрастни и деца над 12 години:*

Да се приема по 1 капсула два пъти дневно (сутрин и вечер) в 10 последователни дни. След това е препоръчително да се приема по 1 капсула дневно. Препоръчва се приемането на вода в количество от 1,5-2 литра дневно.

*При деца от 2 до 12 години:*

Да се приема по 1 капсула дневно (сутрин).

Състав в дневната доза:

2 (две) капсули УроГард съдържат:

- Концентриран екстракт от червена боровинка – 500 mg
- L. acidophilus – 16 mg
- L. rhamnosus – 16 mg
- L. gasseri – 10 mg



10 дни	2x1
10 дни	1x1



# УРОНЕТ

Официално научно издание на  
Българско урологично гружество  
със съдействието на  
Българска Асоциация по Урология,  
Нефрология и Трансплантология  
(БАУНТ, УРОНЕТ)

**Главен редактор:**

Петър Панчев

**Зам. Главни Редактори:**

Марин Георгиев, Красимир Янев

**Научен Секретар:**

Владислав Младенов

**Редакционна Колегия:**

Пламен Димитров, Васил Василев,  
Александър Тимев, Деян Анакиевски,  
Димитър Шишков, Николай Колев,  
Чавдар Славов, Тодор Ганев,  
Боян Атанасов, Николай Миринчев,  
Явор Семерджиев, Емил Атанасов,  
Иван Вълканов, Младен Дойков,  
Стоян Пеев, Валентин Йотовски,  
Александър Кръстанов, Иван Лилянов,  
Йенс-Уве Щолценбург, Йенс Расвайлер,  
Евангелос Лиацикос, Джорджо Боцини,  
Йован Ивчев

**Editor-in-chief:**

Petar Panchev

**Deputy Editor-in chief:**

Marin Georgiev, Krassimir Yanev

**Scientific Secretary:**

Vladislav Mladenov

**Editorial Board:**

Plamen Dimitrov, Vassil Vassilev,  
Aleksandar Timev, Deyan Anakievski,  
Dimitar Shishkov, Nikolay Kolev,  
Chavdar Slavov, Todor Ganev,  
Boyan Atanasov, Nikolay Mirinchev,  
Yavor Semerdzhiev, Emil Atanasov,  
Ivan Vulkanov, Mladen Doykov,  
Stoyan Peev, Valentin Yotovski,  
Aleksandar Krastanov, Ivan Lilyanov,  
Jens-Uwe Stolzenburg, Jens J. Rassweiler,  
Evangelos Liatsikos, Giorgio Bozzini,  
Jovan Ivchev

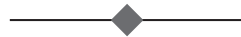# Съдържание:

**ADRENOCORTICAL CARCINOMA: SYMPTOMATOLOGY, DIFFERENTIAL DIAGNOSIS, OPERATIVE AND POSTOPERATIVE TREATMENT - OUR EXPERIENCES IN THE LAST 5 YEARS ..... 3**

**ИНТЕРЕСЕН РЯДЪК КЛИНИЧЕН СЛУЧАЙ НА ПОСТАВЕНИ 91 МЕТАЛНИ МАГНИТНИ ТОПЧЕТА В УРЕТРАТА И ПИКОЧНИЯ МЕХУР  
AN INTERESTING RARE CLINICAL CASE OF 91 METAL MAGNETIC BALLS PLACED IN THE URETHRA AND BLADDER ..... 10**

**THE ASSOCIATION OF SQUAMOUS KERATINIZING METAPLASIA (LEUKOPLAKIA) OF THE BLADDER WITH SYMPTOMS OF THE LOWER URINARY TRACT IN WOMEN ..... 15**

**ТЕЛАНГИЕКТАТИЧЕН ОНКОЦИТОМ - РЯДЪК СЛУЧАЙ НА ОНКОЦИТОМ С НЕТИПИЧНИ МОРФОЛОГИЧНИ ХАРАКТЕРИСТИКИ И ИМУНОПРОФИЛ  
TELANGIECTATIC ONCOCYTOMA - A RARE CASE OF ONCOCYTOMA WITH ATYPICAL MORPHOLOGICAL CHARACTERISTICS AND IMMUNE PROFILE ..... 22**



Списание УРОНЕТ публикува оригинални статии и клинични случаи в сферата на урологията, хирургичните науки, нефрологията, имунологията, бъбречната трансплантация и образната диагностика.

Всички доклади изпратени за публикуване трябва да са в PDF и WORD (\*.doc or \*.docx) формат и трябва да включват: заглавие и авторски колектив (български и английски език), абстракт (български и английски език), ключови думи (български и английски език). Шрифт Times New Roman 12, междуредие 1.5. Всяка таблица, графика или снимка се представя, както в статията, така и на допълнителен файл и номерирана спрямо последователността ѝ на поява в текста напр. (фигура XX, снимка XX и т.н.).

Допускат се и доклади само на английски език.

Книгописа трябва да е минимум от 10 и не повече от 20 цитирани научни трудове, които се номерират спрямо реда им на поява в текста на статията като се следва следната последователност при цитиранията — фамилия последвана от инициали на първо име на водещия автор, имената на останалите автори, година на публикуване, заглавие, съкратено име на журнала, издание, номер на страница.

Пример:

Йотовски В, Василев В, Милушев М, Лазаров Ц, Миринчев Н, Тимев А, Иванов Г, Младенов В, Димитров П, Янев К, Герогиев М. МР- Трансперинеална Фюзън биопсия с “Koelis” — високотехнологична прецизност. Уронет, 2/2020: стр 8

Yotovski V, Vassilev V, Milushev M, Dimitrov P, Krastanov A, Mladenov V, Timev A, Lazarov C, Ivanov G, Yanev K, Georgiev M. MRI Fusion Biopsy with „Koelis“. High-Tech Precision. 41st CONGRESS OF THE SOCIÉTÉ INTERNATIONALE D’UROLOGIE — SIU 2021 ABSTRACT BOOK, VOLUME 2, Supplement 2, page 144.

Адресите на всеки автор с пощенски код, ел. поща, телефон (по желание), трябва да са написани в края на научния труд след книгописа (български и английски език).

Докладите може да изпращате на ел. поща — [dr.vl.mladenov@gmail.com](mailto:dr.vl.mladenov@gmail.com), както и на <http://uroweb.bg/>

# ADRENOCORTICAL CARCINOMA: SYMPTOMATOLOGY, DIFFERENTIAL DIAGNOSIS, OPERATIVE AND POSTOPERATIVE TREATMENT - OUR EXPERIENCES IN THE LAST 5 YEARS

J. Ivchev<sup>1,2</sup>

<sup>1</sup> DEPARTMENT OF UROLOGY, GENERAL CITY HOSPITAL "8TH SEPTEMBER",  
SKOPJE, REPUBLIC OF NORTH MACEDONIA

<sup>2</sup> FACULTY OF MEDICAL SCIENCES, UNIVERSITY GOCE DELCEV - STIP,  
REPUBLIC OF NORTH MACEDONIA

## ABSTRACT

*Adrenal gland tumors represent from 3 to 10% of the total number of tumors in humans. Most of them are benign non-functional adenocortical adenomas. In contrast, adenocortical carcinomas (ACCs) are extremely rare malignant tumors, with a representation of one to two cases per one million inhabitants per year. They occur more often in women than in men in a ratio of 1.5-2.5:1.*

*At the Urology Department in the City General Hospital „8th of September“ in Skopje, R. North Macedonia, in the last 5 years, 12 patients with adrenal gland tumors were diagnosed and operated on. The study includes an analysis of preoperative laboratory findings of adrenal gland hormones, biochemical parameters, serum tumor markers, postoperative pathohistological findings and their correlation in relation to the clinical picture and other diagnostic procedures (ultrasound, CT and MR).*

*Out of a total of 12 patients operated on for an adrenal gland tumor, the post-operative pathohistological findings showed that in 8 i.e. 66.7% of the patients it was a hormonally inactive benign adenoma, while in 2 i.e. 16.7% of the patients adrenocortical carcinoma was confirmed histologically and immunohistochemically. - ACC and in 1 patient or 8.3% a neoplastic hemangioma was determined. In 8 patients, the tumor of the adrenal gland was diagnosed as an incidentaloma, while in 3 or 25% of the patients, investigations were performed due to unspecified pain in the groin as the main symptom. The average age of the patients is 58 years. Of them, 8 or 66.7% were women and 4 or 33.3% were men.*

*- Adrenocortical cancer is a very rare, but highly aggressive malignant disease, confirmed in our practice so far, with a representation of 16.7% of the operated patients with diagnosed adenoma of the adrenal gland.*

*- Adrenocortical carcinoma in this study is diagnosed as an asymptomatic incidentaloma or only with the presence of undefined dull pain in the lumbar region, which makes its early detection extremely difficult.*

*- The preoperative laboratory analyzes of the adrenal gland hormones and their metabolites: Vanilmandelic acid - VMA, metanephrine, cortisol, ASTN, DHEA-SO<sub>4</sub> - dehydroepiandrosterone sulfate and the rapid dexamethasone test, in our study group preoperatively were within the limits of the reference values, i.e. did not show correlation with postoperative pathohistological findings. Therefore, according to our previous practice, they cannot be taken as the main criterion for setting an indication for operative treatment.*

*- In our study, magnetic resonance imaging and computed tomography, as well as the size of the tumor over 4 cm in diameter, proved to be relevant criteria for setting an indication for surgical treatment.*

*- Laparoscopic supraadrenalectomy enables a much faster recovery of the patient compared to the open surgical approach.*

**KEY WORDS:**

*Adrenal gland, Adrenocortical carcinoma, Adrenal gland adenoma, ASTN, Cortisol, Vanillinmandelic acid, Metanephrine*

**INTRODUCTION:**

Adrenal gland tumors represent from 3 to 10% of the total number of tumors in humans. Most of them are benign non-functional adenocortical adenomas. In contrast, adenocortical carcinomas (ACCs) are extremely rare malignant tumors, with a representation of one to two cases per one million inhabitants per year (1). The latest epidemiological data published in the United States show an incidence of about 0.72 per million patients, with a 0.2% mortality (2). The median age of diagnosed ACS published in Germany and France is 46 years, while in the United States it is 55 years. Characteristic of ASS is their bimodal distribution, where they are represented by 1.3% of all malignant tumors in childhood and from 0.02 to 0.2% of all malignant tumors in adult patients over 55 years of age. They occur more often in women than in men in a ratio of 1.5-2.5:1 (2). The most common reason for their occurrence in 50 to 80% is considered to be a mutation of the tumor protein RT 53 of the germ cells (3). In children, it usually occurs in conjunction with Li Fraumeni.s syndrome (a rare autosomal dominant hereditary cancer characterized by early onset of bone and soft tissue sarcoma, brain tumors, adrenocortical carcinoma and acute leukemia) (4).

**MATERIAL AND METHODS:**

At the Urology Department in the City General Hospital „8th of September“ in Skopje, R. North Macedonia, in the last 5 years, 12 patients with adrenal gland tumors were diagnosed and operated on. The study includes an analysis of preoperative laboratory findings of adrenal gland hormones, biochemical parameters, serum tumor markers, postoperative pathohistological findings and their correlation in relation to the clinical picture and other diagnostic procedures (ultrasound, CT and MR). The obtained data are statistically processed and shown through mean value, percentage representation and graphic display of the correlation between the parameters.

**OBJECTIVES:**

- Determining the correlation of preoperative

values of adrenal hormones (Vanilmandelic acid - VMA, metanephrine, cortisol, ASTN, DHEA-SO<sub>4</sub> - dehydroepiandrosteron sulfate, rapid dexamethasone test) serum tumor markers (testosterone, estrogen, progesteron dyhydroepiandrosteron), biochemical parameters and findings from imagine diagnostic procedures (ultrasound, MR and CT) with the clinical picture and the postoperative pathohistological finding.

- Determination of criteria for indicating operative treatment of tumors of the adrenal gland, based on the post-operative pathohistological findings obtained so far.

**RESULTS:**

Out of a total of 12 patients operated on for an adrenal gland tumor, the post-operative pathohistological findings showed that in 8 i.e. 66.7% of the patients it was a hormonally inactive benign adenoma, while in 2 i.e. 16.7% of the patients adrenocortical carcinoma was confirmed histologically and immunohistochemically - ACC and in 1 patient or 8.3% a neoplastic hemangioma was determined. In 8 patients, the tumor of the adrenal gland was diagnosed as an incidentaloma, while in 3 or 25% of the patients, investigations were performed due to unspecified pain in the groin as the main symptom. The operation in 10 patients or 83.3% was performed laparoscopically and in 2 patients or 16.7% supraadrenalectomy was performed with open surgery together with gastric cancer and colon cancer surgery. The average age of the patients is 58 years (the youngest is 20 and the oldest is 80). Of them, 8 or 66.7% were women and 4 or 33.3% were men.

**DISCUSSION**

**Etiology:** current knowledge about the etiology of adrenal neoplasms (adrenocortical carcinoma and pheochromocytoma) indicates a genetic mutation of the germ cells at the level of the so-called tumor protein TP 53, as a basic etiological factor. Today, several genetic syndromes are linked as a risk of developing adrenocortical cancer, including: Beckwith-Wiedemann syndrome - BWS (alterations of DNA methylation of the 11p15

locus), Multiple endocrine neoplasia type 1 - MEN1 (caused by mutations in the MEN1 gene on chromosome 11q13), Lynch syndrome (caused by mutations in genes involved in DNA mismatch repair genes MSH2, MSH6, PMS2, MLH1), familial adenomatous polyposis (FAP), neurofibromatosis type 1, Werner syndrome, patients with Carney complex and uncontrolled use of contraceptives in young women (5,-13).

**Symptomatology of adrenocortical neoplasms:** published studies to date describe three clinical presentations. In the first, ACS is manifested in 40 to 60% of patients with symptoms and signs of hormonal excess. One-third of patients with ACS develop symptoms as a result of tumor growth and are manifested by pain in the groin, abdominal bloating or a feeling of fullness, and in 20 to 30% of patients, cancer is diagnosed incidentally during investigations of other diseases (6).

In the studied group, out of a total of 12 operated patients, in 8 (66.7%) patients the tumor of the adrenal gland was diagnosed as an incidentaloma during a routine ultrasound examination due to another pathology. In 3 (25%) patients, one aged 25 years, one aged 20 years, and a patient aged 59 years, an adrenal gland tumor was diagnosed on investigation of a symptom of unspecified intermittent lower back pain with radiation to the back in back, which lasted several months back, while in one patient (8.3%) aged 64 years, a tumor of the left adrenal gland was found as an incidental finding intraoperatively during surgery for recurrent gastric cancer (table 1).

Adrenal gland tumor symptoms	Number of patients	Percentage representation
Asymptomatic - accidental finding (incidentaloma)	8	66,7%
Unspecified pain in the loin radiating to the back	3	25%
An incidental intraoperative finding	1	8,33%

Table 1. Symptomatology of adrenal gland tumors in the studied group

### BIOCHEMICAL FINDINGS:

Adrenocortical hormones (mineralocorticoids, glucocorticoids and androgens) according to previous studies, are elevated in 45 to 70% (6,7,14). The increased excretion of hormones (in 50 to

80% of cases of adrenocortical cancer) causes symptoms such as: plethora, diabetes mellitus, muscle weakness/atrophy and osteoporosis.

Often, very high levels of cortisol in ACC saturate the renal HSD11B2 system, resulting in glucocorticoid-mediated activation of mineralocorticoid receptors. Therefore, hypokalemia and hypertension occur very often in patients with ACS (16,17,18). In most cases of elevated cortisol secretion, patients can detect decreased ASTN values of less than 10 pg/mL and elevated cortisol levels at the 08:00 AM blood draw.

The diagnosis of hypercortisolism is usually established by a 1-mg dexamethasone suppression test, midnight salivary cortisol, or elevated 24-hour urine-free cortisol.

### TUMOR MARKERS

According to current clinical practice, analysis of total testosterone, estrogen, progesterone and Dehydroepiandrosterone sulfate (DHEA-SO<sub>4</sub>) is mandatory. Increased values of these hormones can also be used as tumor markers because they point to the existence of malignancy, that is, adrenocortical cancer (19,20). Today it has been confirmed that elevated values of metabolites of 11-deoxycortisol and DHEA in urine can be reliably used to differentiate ACC tumors from benign adenomas. The metabolite tetrahydro-11-deoxycortisol in urine is considered the most significant such tumor marker (21).

In contrast to the previously published data regarding the change in biochemical tumor markers and the hormonal status of the adrenal gland, in our study group, with the exception of two patients in whom the postoperative pathohistological finding showed that it was an adrenocortical carcinoma, in the rest of the patients with a diagnosed tumor of adrenal gland, preoperatively all laboratory parameters, including the values of hormones and hormonal metabolites, did not show deviation from the reference values.

Both patients with adrenocortical carcinoma were characterized by mildly elevated blood cortisol levels ranging from 16.8 to 26 ug/dl (normal values 5.00 - 25 ug/dl), low protein levels (total protein below 50 g/l, globulins below 20.8 g/l, albumins below 29.4 g/l) and an elevated level of C-reactive protein (from 40 to 63.7 mg/L), while the other parameters: vanillinmandelic acid in 24 hourly diuresis with normal mean values from

16.5 to 21.6 umol/dU (reference values from 7.0 to 68.0 umol/dU), metanephrine from 1.1 to 2.3 umol/dU (reference values up to 5.5 umol/dU), ASTN with a mean value of 30.3 pg/ml (reference values from 5.00 - 46.0 pg/ml) and DHEA-SO4 - dehydroepiandrosterone sulfate with a mean value of 65.5 µg/dL (reference values from 45 to 320 µg/dL), did not indicate a possible neoplastic process in terms of adrenocortical carcinoma or pheochromocytoma (table no. 2,3).

Biochemical parameters in patients with adrenocortical carcinoma	Normal values	Reduced values	Increased values
leukocytes	7,5 x 10 <sup>9</sup> /l		
erythrocytes		3,30 x 10 <sup>12</sup> /l	
hemoglobin		10,4 g/dl	
hematocrit		29,1%	
Na	138 mmol/l		
Cl	103 mmol/l		
K	3,7 mmol/l		
Creatinin	52,1 umol/l		
Total protein		50,2 g/L	
globulin		20,8 g/L	
albumin		29,4 g/L	
CRP			63,7 mg/L
glucose	4,4 mmol/l		

Table No. 2. Biochemical parameters in blood in patients with adrenocortical cancer in the studied group

Values of adrenal hormones and their metabolites in patients with adrenocortical carcinoma	Normal values	Reduced values	Increased values
Vanilmandelic acid-VMA (24 h diuresis)	21,6 umol/dU		
Metanephrin (24 h diuresis)	1,1 umol/dU		
ACTH	30,3 pg/ml		
DHEA-SO4	65,5 µg/dL		
Cortisol			16,8 - 26,0 ug/dL
Dexamethasone test	0.8 mg/dL (normal <1,8mg/dL)		

Table 3. Values of adrenal hormones, their metabolites and dexamethasone test in patients with adrenocortical carcinoma

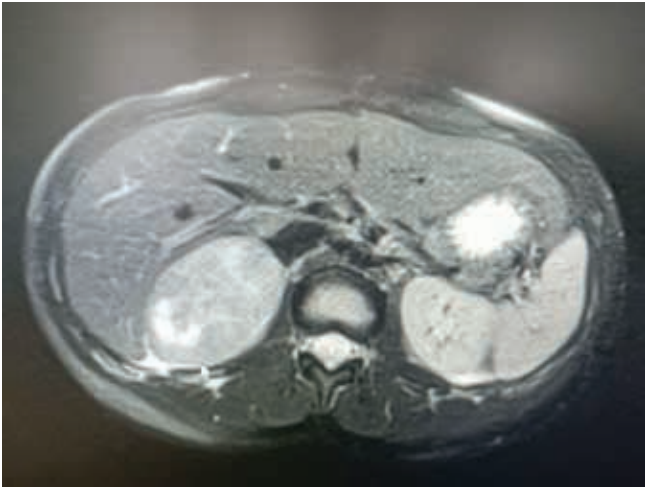
### CRITERIA FOR SETTING AN INDICATION FOR SURGICAL TREATMENT OF ADRENAL GLAND TUMORS

Very often, except for the finding of a large tumor, hormonal and biochemical parameters in patients with ACS are normal with the absence of any symptoms and are diagnosed incidentally during other routine examinations. Usually ASS are diagnosed as large tumors over 6 cm in diameter.

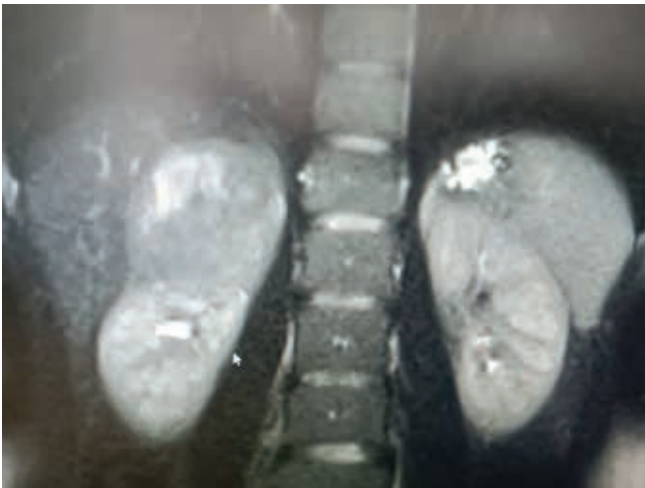
Until the use of modern „imagine“ diagnostic procedures (CT and MR with contrast medium) the size of adrenal tumors was considered the main criterion for setting an indication for surgery. At the same time, the finding of the presence of bleeding in the tumor, necrotic zones and calcifications, suggest a possible malignant destruction.

The risk of adrenal malignancy increases with tumor size, with the index of suspicion increasing for tumors larger than 4 cm (sensitivity, 97%; specificity, 52%) and larger than 6 cm (sensitivity, 91%; specificity, 80%) (22). Tumors 1 to 4 cm in diameter without definite benign features and a homogeneous mass of low density ( $\leq 10$  Hounsfield units [HU]) with smooth margins should be regularly monitored and supplemented with other diagnostic protocols and procedures in order to timely detect the beginning of the malignant process.

The size of the adrenal tumors in the study group can be divided into two groups: tumors with a diameter of 2 to 4.5 cm and tumors with a diameter of 4.5 to 7 cm. Out of a total of 12 operated patients, in 8 patients in whom the postoperative pathohistological finding showed that it was an inactive benign adenoma, the size of the tumoral change was from 2 to 4.5 cm, while in 3 patients with confirmed adrenal carcinoma and one patient with glandular cavernous hemangioma of the adrenal gland, the size was between 5.5 and 7.3 cm in diameter (Picture 1,2).



Picture 1. MR of the ACC of the right adrenal gland in a 25-year-old female patient operated laparoscopically in the General City Hospital „8th of September“ - Skopje (the size of the tumor is 73 x 55 mm)



Picture 2. MRI of the ACC in a 59-year-old man with a diameter of 53x45 mm, operated in the General City Hospital „8th of September“ - Skopje

#### **POSTOPERATIVE PATHOHISTOLOGICAL FINDINGS IN THE STUDIED GROUP**

Out of a total of 12 operated patients with adrenal gland tumor, in 7 patients the pathohistological analysis showed classic features of adenoma (larger cells with different cytoplasm, increased variation in the size of the nucleus, abundant foamy cytoplasm and different cell borders resembling zona fascicula, in one patient, the tumor is described as cortical hyperplasia, (adrenocortical nodular disease), in one patient, the tumor is described as a large neoplastically altered cavernous hemangioma, and in three patients, adrenocortical cancer is diagnosed (of which two patients have the second stage and one patient the third stage of malignancy) (table 4).

Pathohistological findings in the studied group	Number of patients	Percentage representation
Histological finding of benign adenoma	7	58,3%
Hyperplasio corticalis glandulae suprarenalis	1	8,33%
Haemangioma cavernosum glandulae suprarenalis	1	8,33%
Adrenocortical Carcinoma- Stage II, pT2,pNX,pMx,L1,V1	2	16,7%
Adrenocortical Carcinoma - Stage III, pT3a, pN1,pMx	1	8,33%

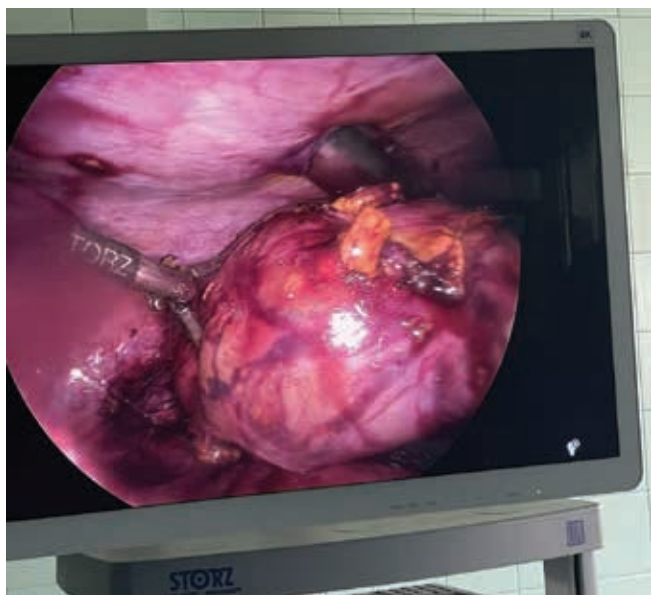
Table No. 4. Pathohistological findings in the studied group

#### **TREATMENT OF ADRENAL TUMORS**

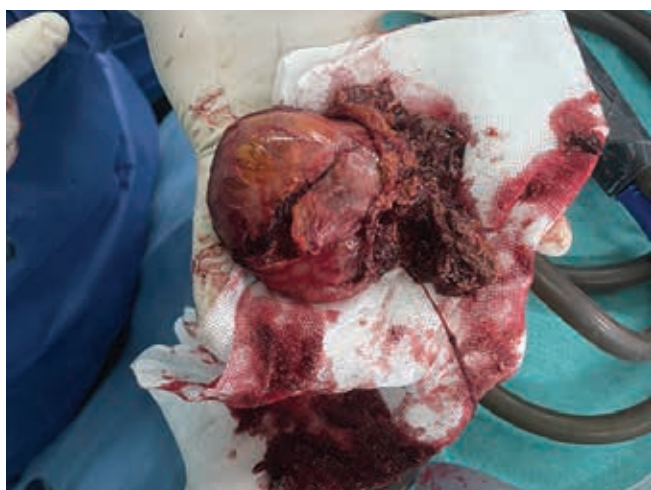Indication for surgical treatment according to the Guideline of the World Urological Association includes the following criteria:

- Tumors  $\geq 4.0$  cm,
- Regardless of size, any incidentaloma with clinical, radiological or hormonal abnormalities indicative of malignancy or hyperfunction should be surgically removed,
- any incidentaloma that during follow-up shows signs of malignancy or hyperfunction, as well as any tumor that shows an increase in diameter from 0.5 to 1 cm, should be surgically removed,
- If the skill of the surgeon and the characteristics of the lesion allow, laparoscopic supraadrenalectomy is the method of choice, compared to the open surgical method.

In our study group, only one patient was operated because of symptoms and signs of hypercorticism and one as an incidental intraoperative finding during gastric cancer surgery, while in the rest, the indication for adrenalectomy was set based on the size of the tumor mass which was more than 4 cm in diameter. out of a total of 12 patients, 10 (83.3%) were operated laparoscopically and two (16.6%) with an open surgical approach (Picture 3,4).



Picture No. 3. Laparoscopic right supraadrenalectomy. Adrenocortical carcinoma (dimensions 72 x 58mm) in a 25-year-old female patient operated on in the „8th of September“ General Hospital - Skopje, Republic of Macedonia



Picture no. 4. Left supra-adrenalectomy due to an incidental finding of adrenocortical cancer, in a 72-year-old woman operated during a partial gastrectomy due to cancer, in the GOB „8mi Septemvri“ Skopje, RS Macedonia

Although in all 12 patients the hormonal and biochemical findings did not show indications of

the existence of pheochromocytoma, due to the possible danger of bleeding or hypertensive crisis, a fine needle biopsy was not performed.

#### **POSTOPERATIVE PROGNOSIS OF ADRENOCORTICAL CARCINOMA**

Even with apparently complete resections, local recurrence rates typically ranged from at least 19% to 34% in those patients without residual disease after surgery (23,24,25). In our study group, the two-year follow-up of patients with all „image“ diagnostic procedures, CT, MR and PET Scan and all hormonal, biochemical and tumor marker analyses, showed 100% survival.

#### **CONCLUSION:**

- Adrenocortical cancer is a very rare, but highly aggressive malignant disease, confirmed in our practice so far, with a representation of 16.7% of operated patients diagnosed with adenoma of the adrenal gland. Adrenocortical carcinoma in this study is diagnosed as an asymptomatic incidentaloma or only with the presence of an undefined dull pain in the lumbar region, which makes its early detection extremely difficult.

- Preoperative laboratory analyzes of adrenal hormones and their metabolites: vanillinmandelic acid - VMA, metanephrine, cortisol, ASTN, DHEA-SO<sub>4</sub> - dehydroepiandrosterone sulfate and the rapid dexamethasone test, in our study group preoperatively were within the limits of the reference values, i.e. did not show correlation with postoperative pathohistological findings. Therefore, they cannot be taken as the main criterion for setting an indication for operative treatment.

- Magnetic resonance and computed tomography, as well as the size of the tumor over 4 cm in diameter, in our study proved to be relevant criteria for setting an indication for surgical treatment.

- Laparoscopic supraadrenalectomy enables a much faster recovery of the patient compared to the open surgical approach.

#### **REFERENCES:**

1. Else T, Kim AC, Sabolch A, Raymond VM, Kandathil A, Caoili EM, Miller BS, Giordano TJ, Hammer GD. Adrenocortical Carcinoma. *Endocr Rev.* 2014 Apr; 35(2): 282–326.
2. Kebebew E, Reiff E, Duh QY, Clark OH, McMillan A. Extent of disease at presentation and outcome for adrenocortical carcinoma: have we made progress? *World J Surg.* 2006;30:872–878.
3. Figueiredo BC, Sandrini R, Zambetti GP, et al. Penetrance of adrenocortical tumours associated with the germline TP53 R337H mutation. *J Med Genet.* 2006;43:91–96.
4. Pianovski MA, Maluf EM, de Carvalho DS, et al. Mortality rate of adrenocortical tumors in children under 15 years of age in Curitiba, Brazil. *Pediatr Blood Cancer.* 2006;47:56–60.

5. Pinto EM, Billerbeck AE, Villares MC, Domenice S, Mendonça BB, Latronico AC. Founder effect for the highly prevalent R337H mutation of tumor suppressor p53 in Brazilian patients with adrenocortical tumors. *Arq Bras Endocrinol Metabol.* 2004;48:647–650.
6. Fassnacht M, Allolio B. Clinical management of adrenocortical carcinoma. *Best Pract Res Clin Endocrinol Metab.* 2009;23:273–289.
7. Luton JP, Cerdas S, Billaud L, et al. Clinical features of adrenocortical carcinoma, prognostic factors, and the effect of mitotane therapy. *N Engl J Med.* 1990;322:1195–1201.
8. Bilimoria KY, Shen WT, Elaraj D, et al. Adrenocortical carcinoma in the United States: treatment utilization and prognostic factors. *Cancer.* 2008;113:3130–3136.
9. Wajchenberg BL, Albergaria Pereira MA, et al. Adrenocortical carcinoma: clinical and laboratory observations. *Cancer.* 2000;88:711–736.
10. Wooten MD, King DK. Adrenal cortical carcinoma. Epidemiology and treatment with mitotane and a review of the literature. *Cancer.* 1993;72:3145–3155.
11. Wasserman JD, Zambetti GP, Malkin D. Towards an understanding of the role of p53 in adrenocortical carcinogenesis. *Mol Cell Endocrinol.* 2012;351:101–110.
12. Schteingart DE, Doherty GM, Gauger PG, et al. Management of patients with adrenal cancer: recommendations of an international consensus conference. *Endocr Relat Cancer.* 2005;12:667–680.
13. Crucitti F, Bellantone R, Ferrante A, Boscherini M, Crucitti P. The Italian Registry for Adrenal Cortical Carcinoma: analysis of a multiinstitutional series of 129 patients. The ACC Italian Registry Study Group. *Surgery.* 1996;119:161–170.
14. Abiven G, Coste J, Groussin L, et al. Clinical and biological features in the prognosis of adrenocortical cancer: poor outcome of cortisol-secreting tumors in a series of 202 consecutive patients. *J Clin Endocrinol Metab.* 2006;91:2650–2655
15. Michalkiewicz E, Sandrini R, Figueiredo B, et al. Clinical and outcome characteristics of children with adrenocortical tumors: a report from the International Pediatric Adrenocortical Tumor Registry. *J Clin Oncol.* 2004;22:838–845.
16. Seccia TM, Fassina A, Nussdorfer GG, Pessina AC, Rossi GP. Aldosterone-producing adrenocortical carcinoma: an unusual cause of Conn's syndrome with an ominous clinical course. *Endocr Relat Cancer.* 2005;12:149–159.
17. Egoshi K, Masai M, Nagao K, Ito H. 11-Deoxycorticosterone-producing adrenocortical carcinoma. *Urol Int.* 1998;61:251–253.
18. Müssig K, Wehrmann M, Horger M, Maser-Gluth C, Häring HU, Overkamp D. Adrenocortical carcinoma producing 11-deoxycorticosterone: a rare cause of mineralocorticoid hypertension. *J Endocrinol Invest.* 2005;28:61–65.
19. Grondal S, Eriksson B, Hagenas L, Werner S, Curstedt T. Steroid profile in urine: a useful tool in the diagnosis and follow up of adrenocortical carcinoma. *Acta Endocrinol (Copenh).* 1990;122:656–663.
20. Arlt W, Biehl M, Taylor AE, et al. Urine steroid metabolomics as a biomarker tool for detecting malignancy in adrenal tumors. *J Clin Endocrinol Metab.* 2011;96:3775–3784.
21. Song G, Joe BN, Yeh BM, Meng MV, Westphalen AC, Coakley FV. Risk of catecholamine crisis in patients undergoing resection of unsuspected pheochromocytoma. *Int Braz J Urol.* 2011;37:35–40; discussion 40–41
22. Sturgeon C, Shen WT, Clark OH, Duh QY, Kebebew E. Risk assessment in 457 adrenal cortical carcinomas: how much does tumor size predict the likelihood of malignancy? *J Am Coll Surg.* 2006;202:423–430
23. Gonzalez RJ, Tamm EP, Ng C, et al. Response to mitotane predicts outcome in patients with recurrent adrenal cortical carcinoma. *Surgery.* 2007;142:867–875; discussion 867–875
24. Miller BS, Gauger PG, Hammer GD, Giordano TJ, Doherty GM. Proposal for modification of the ENSAT staging system for adrenocortical carcinoma using tumor grade. *Langenbecks Arch Surg.* 2010;395:955–961.
25. Miller BS, Gauger PG, Hammer GD, Doherty GM. Resection of adrenocortical carcinoma is less complete and local recurrence occurs sooner and more often after laparoscopic adrenalectomy than after open adrenalectomy. *Surgery.* 2012;152:1150–1157

**ADDRESS FOR CORRESPONDENCE:**

Dr. J. Ivchev  
City General Hospital „8th of September“,  
66, Pariska Str., Skopje 1000, Republic of North Macedonia  
Tel: +389 2 3087400  
Fax: +389 2 3072125  
E-mail: urologija@bolnica.org.mk

# ИНТЕРЕСЕН РЯДЪК КЛИНИЧЕН СЛУЧАЙ НА ПОСТАВЕНИ 91 МЕТАЛНИ МАГНИТНИ ТОПЧЕТА В УРЕТРАТА И ПИКОЧНИЯ МЕХУР

Н. Миринчев<sup>1,2</sup>, З. Чолакова<sup>1,2</sup>

1 МЕДИЦИНСКИ ФАКУЛТЕТ, УНИВЕРСИТЕТ „ПРОФ. Д-Р АСЕН ЗЛАТАРОВ“

2 КЛИНИКА ПО УРОЛОГИЯ, УНИВЕРСИТЕТСКА МНОГОПРОФИЛНА БОЛНИЦА ЗА АКТИВНО  
ЛЕЧЕНИЕ - БУРГАС АД

## AN INTERESTING RARE CLINICAL CASE OF 91 METAL MAGNETIC BALLS PLACED IN THE URETHRA AND BLADDER

N. Mirinchev<sup>1,2</sup>, Z. Cholakova<sup>1,2</sup>

1 FACULTY OF MEDICINE, UNIVERSITY „PROF. DR. ASEN ZLATAROV“

2 UROLOGY CLINIC, UNIVERSITY MULTIDISCIPLINARY HOSPITAL FOR ACTIVE TREATMENT -  
BURGAS AD

### РЕЗЮМЕ

#### ВЪВЕДЕНИЕ

Диагнозата на чужди тела в уретрата и пикочния мехур е предизвикателство, като се има предвид колебанието на пациентите да докладват за поставянето им. Забавената диагностика увеличава честотата на усложненията. Магнитните чужди тела са особено опасни поради възможността от притискане на уретрата или стената на пикочния мехур, което води до тежка исхемия. Отстраняването на тези обекти е трудно поради тяхната магнитна адхезия.

#### ЦЕЛ

Целта на тази публикация е да представим рядък и интересен клиничен случай на поставени 91 метални магнитни топчета в уретрата и пикочния мехур от младо 15 годишно момче и да потърсим подобни описани случаи в медицинските база данни.

#### МАТЕРИАЛИ И МЕТОДИ

Беше направена справка в PUB MED с ключави думи: чуждо тяло; магнитни топчета; пикочен мехур; уретра. В базата данни се откриха докладвани 2 случая на поставени магнитни топчета в уретрата и пикочния мехур: 28 г., мъж с 159 топчета и 10 г., момче с 83 топчета.

#### РЕЗУЛТАТИ

Представяме рядък и интересен клиничен случай на момче на 15 години поставило в уретрата и пикочния си мехур 91 метални магнитни топчета. Здраво 15 годишно момче постъпва по спешност в клиниката. По данни на детето и майката, пациента си е вкарал в уретрата около 30 метални магнитни топчета. Отричат за заболявания

и приемане на медикаменти. Отричат за алергия.

Извърши се екстракция на 15 броя метални магнитни топчета от уретрата с щипка за чуждо тяло. Извърши се цистоскопия и се установи когломерат от множество топчета в пикочния мехур и поради силните магнитни сили на неодимовите магнитни топчета се установи невъзможност по миниинвазивен път да се екстрахират магнитните метални топчета през уретрата. Взе се решение да се извърши цистотомия. Извърши се екстракция на множество магнитни топчета от пикочен мехур. Металните магнитни топчета бяха общо 91 броя.

### **ОБСЪЖДАНЕ**

Този клиничен случай на поставени в уретрата и пикочният мехур метални магнитни топчета дава ценна представа за рядък, но потенциално сериозен медицински сценарий и изисква допускането му в диференциално-диагностичният план. Успешното идентифициране и отстраняване на магнитните топчета в този случай е от решаващо значение за предотвратяване на допълнителни усложнения, като инфекция или увреждане на уретрата и пикочния мехур.

При деца с повтарящи се дизурични оплаквания трябва да се има предвид възможността за чуждо тяло в уретрата или пикочния мехур.

За пациенти без сериозни усложнения цистоскопията е златен стандарт за диагностика и лечение.

Този случай доказва необходимостта от повишена обществена осведоменост и по-строги регулаторни мерки по отношение на магнитните играчки.

### **КЛЮЧОВИ ДУМИ:**

чуждо тяло, магнитни топчета, пикочен мехур, уретра

### **ABSTRACT**

#### **INTRODUCTION:**

The diagnosis of foreign bodies in the urethra and bladder is challenging given the reluctance of patients to report their insertion. Delayed diagnosis increases the incidence of complications. Magnetic foreign bodies are particularly dangerous because of the possibility of compressing the urethra or bladder wall, leading to severe ischemia. Removal of these objects is difficult due to their magnetic adhesion.

#### **PURPOSE**

The purpose of this publication is to present a rare and interesting clinical case of 91 metallic magnetic balls placed in the urethra and bladder of a young 15-year-old boy and to search for similar reported cases in medical databases.

#### **MATERIALS AND METHODS**

PUB MED was searched using keywords: foreign body; magnetic balls; bladder; urethra. The database found 2 reported cases of magnetic beads placed in the urethra and bladder: a 28-year-old man with 159 balls and a 10-year-old boy with 83 balls.

#### **RESULTS**

We present a rare and interesting clinical case of a 15-year-old boy who had 91 metallic magnetic balls inserted into his urethra and bladder. A healthy 15-year-old boy is urgently admitted to the clinic. According to the child and the mother, the patient inserted about 30 metal magnetic balls into his urethra. They deny illness and medication. They deny an allergy.

Fifteen metal magnetic balls were extracted from the urethra with a foreign body clip. A cystoscopy was performed and a conglomerate of multiple balls was found in the bladder and due to the strong magnetic forces of the neodymium magnetic balls, it was found impossible to

*minimally invasively extract the magnetic metal balls through the urethra. A decision was made to perform a cystotomy. Extraction of multiple magnetic balls from bladder was performed. The metal magnetic balls were a total of 91 pieces.*

### **DISCUSSION**

*This clinical case of metal magnetic balls placed in the urethra and bladder provides valuable insight into a rare but potentially serious medical scenario and warrants its inclusion in the differential diagnosis plan. Successful identification and removal of the magnetic balls in this case is critical to prevent further complications, such as infection or damage to the urethra and bladder.*

*In children with recurrent dysuric complaints, the possibility of a foreign body in the urethra or bladder should be considered.*

*For patients without serious complications, cystoscopy is the gold standard for diagnosis and treatment.*

*This case demonstrates the need for increased public awareness and stricter regulatory measures regarding magnetic toys.*

### **KEYWORDS:**

*foreign body, magnetic balls, bladder, urethra*

## **ВЪВЕДЕНИЕ**

Диагнозата на чужди тела в уретрата и пикочния мехур е предизвикателство, като се има предвид колебанието на пациентите да докладват за поставянето им. Забавената диагностика увеличава честотата на усложненията. Полиемболокоиламания/ Polyembolokoilamania/, или вмъкване на предмет в телесен отвор за сексуално задоволяване, е най-честата причина за уретрални чужди тела. При този акт се вкарват чужди тела в отвори като уретра, ректум и вагина. Често се проявява при пациенти със синдром на Smith-Magenis, когато е мотивирано от желание за сексуално удовлетворение, то може да се счита за парафилия. Парафилията е преживяването на повтаряща се или интензивна сексуална възбуда към нетипични обекти, ситуации, фантазии, поведение или индивиди. Също така е дефинирано като сексуален интерес към нещо различно от конвенционален сексуален контакт със съгласен човешки партньор.

Други мотиви за вмъкване на чужди тела в уретрата включват любопитство или като помощник при уриниране.

Клиничната картина на чуждо тяло в уретрата е подобно на инфекция или стриктура. Усложненията включват хроничен цистит, хидронефроза, вторично образуване на камъни и бъбречна недостатъчност. При деца и тийнейджъри е от съществено

значение да се допусне наличието им и да се проведе образно изследване за изключване на чуждо тяло в уретрата. Магнитните чужди тела са особено опасни поради възможността от притискане на уретрата или стената на пикочния мехур, което води до тежка исхемия. Отстраняването на тези обекти е трудно поради тяхната магнитна адхезия [1], [2], [3], [4]. Неогимовите магнитни играчки бяха временно премахнати от Световният пазар, но продажбите на гребно бяха възобновени през 2016 г. и те продължават да представляват риск в нашето общество.

### **ЦЕЛ**

Целта на тази публикация е да представим рядък и интересен клиничен случай на поставени 91 метални магнитни топчета в уретрата и пикочния мехур на младо 15 годишно момче и да потърсим подобни описани случаи.

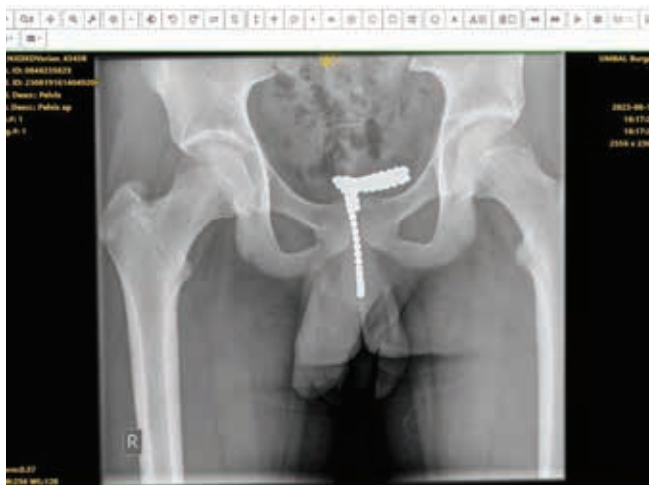### **МАТЕРИАЛИ И МЕТОДИ**

Беше направена справка в PUB MED с ключави думи: чуждо тяло; магнитни топчета; пикочен мехур; уретра. В базата данни се откриха докладвани 2 случая на поставени метални магнитни топчета в уретрата и пикочния мехур: 28 г., мъж с 159 топчета и 10 г., момче с 83 топчета.

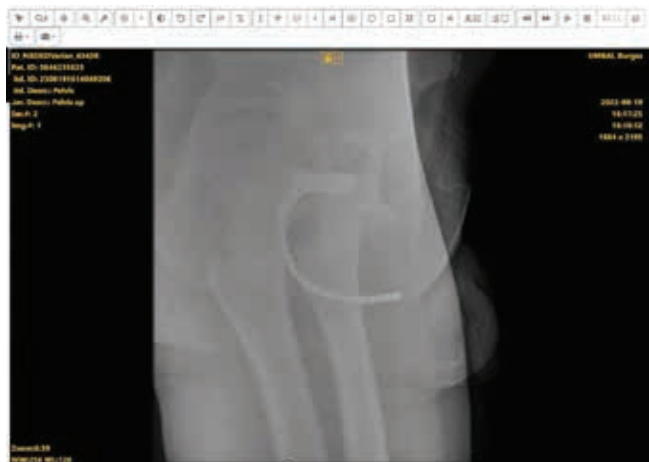### **РЕЗУЛТАТИ**

Представяме рядък и интересен клиничен случай на 15 годишно момче поставило

В уретрата и пикочния си мехур 91 метални магнитни топчета. Пациента постъпва по спешност в клиниката. По данни на детето и майката, пациента си е вкарал в уретрата около 30 метални магнитни топчета. Отричат за заболявания и приемане на медикаменти. Отричат за алергия. Пациента имаше дизурични оплаквания, които се „засилили значително през последните 3 часа“. Анализът на урината показва наличие на левкоцити и микроскопска хематурия. Пълната кръвна картина и биохимия бяха в нормални граници. Проведената ехография на пикочо-отделителна система - без уростаза и калкулоза в двата бъбрека, чуждо тяло в пикочния мехур. Назначи се обзорна рентгенография на пикочо-отделителна система-фас и профил: данни за множество свързани тела с метална плътност в малък таз.

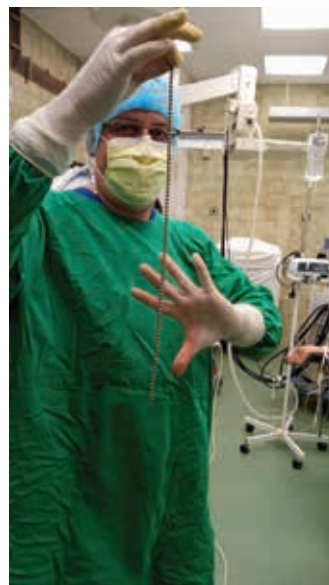


Фиг. 1 Обзорна рентгенография на пикочен мехур — фас - чуждо тяло в пикочния мехур и уретрата



Фиг. 2 Обзорна рентгенография на пикочен мехур — профил - чуждо тяло в пикочния мехур и уретрата

След обсъждане на клиничният случай се взе решение за оперативно лечение по спешност като първо се проведе уретроскопия. Установиха се множество метални магнитни топчета в уретрата. Извърши се екстракция на 15 броя метални топчета от уретрата с щипка за чуждо тяло. Извърши се цистоскопия и се установи конгломерат от множество топчета в пикочния мехур и невъзможност по миниинвазивен път да се екстрахират през уретрата поради силните магнитни сили на неодимовите магнитни топчета. Взе се решение да се извърши цистотомия. Извърши се екстракция на множество магнитни топчета от пикочен мехур. Общо се извадиха 91 метални магнитни топчета.



Фиг. 3 - Чуждо тяло от пикочния мехур и уретрата - 91 броя метални магнитни топчета

### ОБСЪЖДАНЕ

Този случай на поставени в уретрата и пикочния мехур метални магнитни топчета дава ценна представа за този рядък, но потенциално сериозен медицински сценарий и изисква допускането му при диференциална диагноза при заболявания на пикочните пътища [5], [6], [7], [8]. Успешното идентифициране и отстраняване на металните магнитни топчета в този случай е от решаващо значение за предотвратяване на допълнителни усложнения, като инфекция или увреждане на уретрата и пикочния мехур [9].

При деца с повтарящи се дизурични оплаквания трябва да се има предвид възможността за чуждо тяло в уретрата или в

пикочния мехур.

При пациенти без сериозни усложнения цистоскопията е златен стандарт за диагностика и лечение. Докато по-голямата част от чуждите тела се отстраняват ендоскопски, сложните обекти или тези, чийто отстраняване е свързано със значително

нараняване на уретрата, може да се извърши отворена оперативна интервенция [10].

Този случай доказва необходимостта от повишена обществена осведоменост и по-строги регулаторни мерки по отношение на магнитните играчки.

#### БИБЛИОГРАФИЯ:

1. Liu ZH, Zhu XF, Zhou N. Retrieval of 159 magnetic balls from urinary bladder: A case report and literature review. *Urol Case Rep.* 2019;26:100975. Published 2019 Jul 23. doi:10.1016/j.eucr.2019.100975
2. Chao L, Lei Z, Xiang L, Qi Z. Self-inflicted intravesical insertion of 83 magnetic balls in a 10-year-old boy: a case report and literature review. *Turk J Pediatr.* 2023;65(1):176-179. doi:10.24953/turkjped.2022.429
3. Hegde AV, Choubey S, Kanagali RS, et al. Listening to his inner voice? An unusual urethral foreign body: a review of literature and few learning points. *Asian J Urol.* 2018;5(2):131-2.
4. Naidu K, Chung A, Mulcahy M. An unusual urethral foreign body. *Int J Surg Case Rep.* 2013;4(11):1052-4.
5. Robey TE, Kaimakliotis HZ, Hittelma AB, et al. An unusual destination for magnetic foreign bodies. *Pediatr Emerg Care.* 2014;30(9):643-5.
6. Sharma D, Pandey S, Garg G, et al. Foreign body urethra misdiagnosed as stricture leading to inadequate management and prolonged treatment duration: a lesson to learn. *BMJ Case Rep.* 2018.
7. Rafique M. Intravesical foreign bodies: review and current management strategies. *Urol J.* 2008;5:223–231.
8. Li Y, Gao Y, Chen X, et al. Rare foreign body in bladder: a case report. *Medicine (Baltim).* 2018;97:e519.
9. Levine MA, Evans H. Open removal as a first-line treatment of magnetic intravesical foreign bodies. *Can Urol Assoc J.* 2013;7:E25–E28.
10. Ko YH, Kang SG, Kang SH, et al. Removal of long, complex foreign bodies from bladder using single laparoscopic port under pneumovesicum. *J Laparoendosc Adv Surg Tech.* 2010; 20:639–642.

#### АДРЕС ЗА КОРЕСПОНДЕНЦИЯ:

гр. Бургас, Бул. Ст. Стамболов 73,  
E-mail: drmirinchev@abv.bg,  
z\_cholakova@yahoo.com

#### ADDRESS FOR CORRESPONDENCE:

Burgas, Bul. St. Stambolov 73,  
E-mail: drmirinchev@abv.bg,  
z\_cholakova@yahoo.com

# THE ASSOCIATION OF SQUAMOUS KERATINIZING METAPLASIA (LEUKOPLAKIA) OF THE BLADDER WITH SYMPTOMS OF THE LOWER URINARY TRACT IN WOMEN

D. Markovski

DEPARTMENT OF UROLOGY, GENERAL CITY HOSPITAL "8<sup>TH</sup> SEPTEMBER",  
SKOPJE, REPUBLIC OF NORTH MACEDONIA

## ABSTRACT

### INTRODUCTION

Squamous keratinizing metaplasia (SCM) of the bladder, also known as leukoplakia of the bladder, is a condition in which the normal transitional epithelium is transformed into a squamous epithelium overlying a layer of keratin (1). In most patients, typical non-specific urinary symptoms are expressed, such as frequency, urgency, suprapubic pain, discomfort, microhematuria and, less often, macrohematuria (7).

### OBJECTIVES OF THE STUDY

- To prove the relationship between bladder leukoplakia and urinary symptoms in affected women.
- To determine the effect of endoscopic resection of leukoplakia in relation to conservative treatment

### MATERIALS AND METHODS

The study analysed 50 patients with long-term lower urinary tract symptoms (more than six months) between 2021 and July 2024. All underwent cystoscopy. The study included patients with a pathohistological diagnosis of squamous keratinizing metaplasia of the bladder. The severity of symptoms was determined according to the international classification for urinary symptoms (International prostate symptom score - IPSS). Bi-polar transurethral resection of squamous keratinizing metaplasia of the bladder was performed in all patients. One month after the intervention, the patients were called for a follow-up examination, during which the severity of urinary symptoms was re-evaluated according to the IPSS. Then a comparative analysis was performed, on the basis of which the significant difference of IPSS before and after the intervention was assessed.

### RESULTS

Of the total number of female patients, lower urinary tract symptoms, pain and hematuria were the most common symptoms. After the intervention there was a significant improvement in the initial IPSS score. The percentage of patients with severe and moderate lower urinary tract symptoms decreased from 57.1% to 25.7%. No hematuria was reported, and most of the patients reported an improvement in their quality of life. A total of 64.4% of patients reported an improvement in symptoms, in 23.5% there was no improvement, and 12.1% reported worsening of symptoms.

### CONCLUSION

Bipolar transurethral resection significantly relieves symptoms in women with squamous keratinizing metaplasia, improves quality of life according to the IPSS questionnaire by an acceptable 64.4%, and is superior to conservative treatment.

### KEY WORDS:

squamous keratinizing metaplasia, leukoplakia, bladder, non-specific urinary symptoms

## INTRODUCTION

### DEFINITION

Rare bladder diseases include leukoplakia (white plaques on the bladder), malakoplakia (brown plaques on the bladder), bladder amyloidosis, bladder sarcoidosis, and megacystic bladder syndrome.

Squamous keratinizing metaplasia (SKM) of the bladder, also known as leukoplakia of the bladder, is defined as the transformation of the normal multilayered transitional epithelium of the bladder into a multilayered squamous epithelium, which may be covered with a layer of keratin in squamous keratinizing metaplasia, or to be without a keratinized layer in squamous metaplasia.

The first description of leukoplakia was given by Rokitanski in 1861. Older statistics show that leukoplakia was more common in men (1). In more recent research, women predominate among the sick. The greatest frequency of leukoplakia is between 30 and 60 years of age. Leukoplakia is twice as common in the bladder than in the pyelon and ureter (1). It is less common in the urethra. It can also be called in a family form. Sometimes it occurs as a systemic disease of the urothelium, affecting both the upper and lower urinary tract.

Leukoplakia pathohistologically is a metaplastic lesion, which occurs as a reaction of the normal multilayered transitional epithelium to chronic irritation such as frequent and long-term urinary infections, calculus of the bladder or a foreign body.

In the literature, chronic infection is often associated with leukoplakia (1,3). It is often found in chronic cystitis, calculus of the bladder, schistosomiasis and long-term wearing of a urinary catheter. However, in some patients neither functional nor anatomical obstruction can be proven, and urine cultures are sterile.

Leukoplakia can appear in different places in the bladder and urinary tract, but the most common localization is in the trigonum of the bladder. Microscopically, there is a picture of multilayered squamous epithelium with keratinization. Apart from squamous metaplasia, histopathological criteria for leukoplakia include acanthosis, cellular atypia and dysplasia.

The preoperative gold standard for diagnosis is cystoscopy. Cystoscopy shows a "snowstorm" phenomenon (floating scrums) and characteristic shiny, whitish "velvet" plates. In rare cases,

almost the entire wall of the bladder is covered with irregular whitish membranes. Tumor-like inflammatory changes can also be seen. Therefore, a definitive diagnosis requires a biopsy that shows the nature of the change.

### ETIOLOGY

The bladder has endodermal and mesodermal origins. The presence of ectodermal cells in the bladder mucosa is explained by the process of squamous metaplasia. Metaplasia represents the transformation of one type of tissue into another type of tissue, which is morphologically and functionally different. Mostofi believes that the transitional epithelium has a great capacity for metaplasia and neoplasia under the influence of various stimuli (chronic irritation, infection, hormone imbalance or vitamin deficiency) (1).

Many authors believe that chronic infection is often associated with leukoplakia. It is often found in chronic cystitis, calculus of the bladder, schistosomiasis and long-term wearing of a urinary catheter (1). However, in some patients neither functional nor anatomical obstruction can be proven, and urine cultures are sterile.

Embryological theory considers that leukoplakia develops from ectodermal cells, which during embryogenesis accidentally or by genetic mechanism came to the urinary tract. It is possible that during the caudal dislocation of the Wolff duct, dislocation of some ectodermal cells may occur.

### PATHOLOGY

Leukoplakia can appear in different places in the bladder and urinary tract, but the most common localization is in the trigonum of the bladder. Microscopically, there is a picture of multilayered squamous epithelium with keratinization. Apart from squamous metaplasia, histopathological criteria for leukoplakia include acanthosis, cellular atypia and dysplasia.

Keratinization is a basic pathological criterion that distinguishes leukoplakia from multi-layered squamous epithelium of the vaginal type. "Vaginal-like" epithelium is often found on the trigone in women. Multilayered squamous epithelium without keratinization is found on the trigone and on the back of the urethra in 50-70% of women in the reproductive period of life. Under the influence of sex hormones, this epithelium changes during the menstrual cycle and over the years.

In addition to squamous metaplasia with

keratinization, inflammatory changes can also be found in the vaginal wall beneath these lesions. Electron microscopy showed a distinct type of basal cells with small, dense granulations. These cells resemble the Merkel cells found in the skin and have hormonal and sensory functions. This type of cells is found not only in the zone of leukoplakia but also in the zones of “Vaginal-like” epithelium of the trigonum of the bladder in women. The presence of these cells supports the theory of dislocation of ectodermal cells during embryogenesis (1).

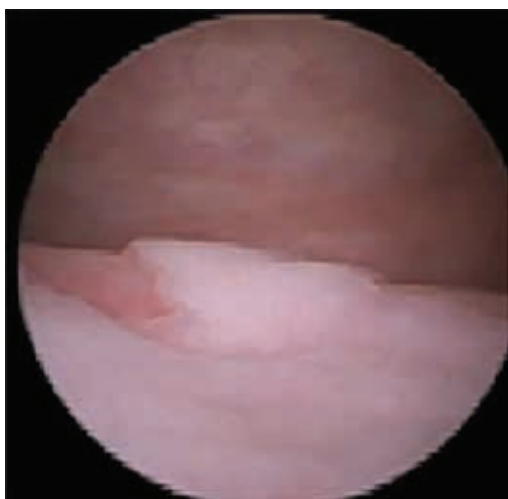### **SYMPTOMS AND SIGNS**

The symptoms of leukoplakia are long-lasting and refractory to conservative therapy. Lower urinary tract symptoms (LUTS), pollakisuria, dysuria, urgent urination, as well as signs of urinary infection are common and most common. The infection is present in 50% of patients. Some patients have difficult and painful urination as well as hematuria. Whitish scrums can be seen in the urine. In certain cases, calculi have also been found in the bladder (1,2).

### **DIAGNOSE**

Cytological examination of the urine shows numerous mature squamous cells and keratin material, in addition to transitional epithelial cells.

The gold standard for diagnosis is cystoscopy. Cystoscopy shows a “snowstorm” phenomenon (floating scrums) and characteristic shiny, whitish “velvet” plates. In rare cases, almost the entire wall of the bladder is covered with irregular whitish membranes. Tumor-like inflammatory changes can also be seen. Therefore, a definitive diagnosis requires a biopsy that shows the nature of the change. (1)



Picture 1. Bladder leukoplakia

### **LEUKOPLAKIA AND CARCINOMA**

According to some authors, the simultaneous occurrence of leukoplakia and squamous cell carcinoma of the bladder ranges up to 37% (1). This occurrence is more common in the bladder than in other parts of the urinary tract. According to other authors, the simultaneous occurrence during the initial diagnosis is lower and ranges from 10-20% (1,3). The occurrence of cancer in the later period of multi-year follow-up of the patient is even rarer.

The occurrence of squamous cell carcinoma in an afunctional bladder, 19 years after urine derivation, is described. This leads to the conclusion that further irritation with urine is not necessary for the progression of leukoplakia to cancer (1).

Moloney in 1981 published a study with 300 cases of leukoplakia, of which 26 patients later developed squamous cell carcinoma of the bladder. Also, the same author describes the occurrence of squamous cell carcinoma in three patients sixteen years after initial urine derivation. Therefore, in the case of urine derivation, prophylactic removal of the bladder is also recommended (1,3).

### **TREATMENT**

The etiology of squamous keratinizing metaplasia is still unclear, and there is currently no effective medical therapy. Antibiotics, alpha blockers and anticholinergics are effective in lower urinary tract symptoms associated with benign prostatic hyperplasia and not in leukoplakia.

More recently, intravesical instillation of hyaluronic acid has also been used, but with limited success.

Combined therapy is recommended as the best treatment, i.e. resection and electrocoagulation of the lesion with subsequent instillation of hyaluronic acid.

Limited plaques are treated with endoscopic resection and electrocoagulation to healthy tissue. Leukoplakia is often accompanied by inflammatory changes and in most cases is located on the trigone of the bladder.

Some authors describe that pathologically altered glycocalyx cells are responsible for chronic inflammation of the bladder wall. That's why studies were done where the drug sodium pentosan polysulfate (Elmiron) of 300 mg per day was used for 6 months (1). Between the cells of the transitional epithelium there is a narrow space

that prevents the penetration of urine between the cells. In the squamous epithelium, the intercellular connection spaces are larger and the connections between the cells are weaker, so urine penetrates between them more easily. Sodium pentosan polysulfate has a non-specific anti-inflammatory effect and “coats” the epithelium, thus preventing the penetration of urine into the intercellular space. However, the effect has not been scientifically proven. Because there is no more effective treatment than endoscopic resection, leukoplakia requires long-term follow-up, including cystoscopies and occasional biopsies.

### OBJECTIVES OF THE RESEARCH

The purpose of this research is:

- To prove the relationship between bladder leukoplakia and urinary symptoms in affected women.
- To determine the effect of endoscopic resection of leukoplakia in relation to conservative treatment.

### MATERIALS AND METHODS

#### ELABORATION AND PLAN

The study analyzed 50 patients with long-term lower urinary tract symptoms (more than six months) between January 2021 and July 2024. The patients were aged 18 to 70 years. The mean age of the patients was 44 years. Cystoscopy was performed in all of them.

The study included patients with a pathohistological diagnosis of squamous keratinizing metaplasia of the bladder. The severity of symptoms was determined according to the international classification for urinary symptoms (International prostate symptom score - IPSS).

Bi-polar transurethral resection of squamous keratinizing metaplasia of the bladder was performed in all patients. All patients were operated in our institution GOB September 8 - Skopje.

One month after the intervention, the patients were called for a follow-up examination, during which the severity of urinary symptoms was re-evaluated according to the IPSS. Then a comparative analysis was performed, on the basis of which the significant difference of IPSS before and after the intervention was assessed.

The following tests were performed on all patients:

1. **IPSS score (international prostate symptom score) questionnaire** - patients filled it in the

urology clinic

**International Prostate Symptom Score (I-PSS)**

Patient Name: \_\_\_\_\_ Date of birth: \_\_\_\_\_ Date completed: \_\_\_\_\_

In the past month:	Not at All	Less than 1 in 5 Times	Less than Half the Time	About Half the Time	More than Half the Time	Almost Always	Your score
1. Incomplete Emptying How often have you had the sensation of not emptying your bladder?	0	1	2	3	4	5	
2. Frequency How often have you had to urinate less than every two hours?	0	1	2	3	4	5	
3. Interference How often have you found you stopped and started again several times when you urinated?	0	1	2	3	4	5	
4. Urgency How often have you found it difficult to postpone urination?	0	1	2	3	4	5	
5. Weak Stream How often have you had a weak urinary stream?	0	1	2	3	4	5	
6. Straining How often have you had to strain to start urination?	0	1	2	3	4	5	
	None	1 Time	2 Times	3 Times	4 Times	5 Times	
7. Nocturia How many times did you typically get up at night to urinate?	0	1	2	3	4	5	
<b>Total I-PSS Score</b>							

Scores: 1-7: Mild      8-19: Moderate      20-35: Severe

Quality of Life Due to Urinary Symptoms	Definitely	Frequently	Mostly Satisfied	Satisfied	Mostly Dissatisfied	Very Dissatisfied	Terrible
If you were to spend the rest of your life with your urinary condition, just the way it is now, how would you feel about that?	0	1	2	3	4	5	6

Picture 2. IPSS score - questionnaire

2. **Anthropometric measurements** - body height (cm); body weight (kg);
3. **Physical examination by systems** - including measurement of blood pressure (BP) and pulse
4. **Laboratory analyzes** - were carried out in the central laboratory in the GOB “8th Septemvri” and included: complete blood count (CBC), basic biochemical analyses, urine, hemostasis, as well as viral markers for hepatitis and HIV, blood group and Rh factor
5. **Urine culture** done in a microbiological laboratory
6. **Ultrasonography of the urinary tract** - performed in the urology clinic
7. **Cytological analysis of urine** - performed at the pathology department
8. **BTA (bladder tumor antigen) immunohistochemical test** - performed in a certified laboratory
9. **Cystoscopy** - performed in the cystoscopy clinic at the urology department
10. **Transurethral resection** - all patients were operated on in GOB September 8, Skopje, with an average duration of the intervention of 15 minutes, the hospital stay was 3 days, and the patients wore a urinary catheter for 2 days. There is no reported case of postoperative hematuria

The patient follow-up protocol has been modified according to the latest recommendations of the EAU (European Association of Urology) for preoperative preparation of patients.

### INCLUSION CRITERIA

- female
- Age above 18 to 70 years
- Patients with chronic urinary infections, with lower urinary tract symptoms, as well as hematuria, in whom leukoplakia has been proven cystoscopically and pathohistologically

### EXCLUSION CRITERIA

- male gender
- Age below 18 and above 70 years
- Cystoscopy negative finding
- A finding of papillomatous changes of the bladder associated with bladder cancer
- Acute bacterial cystitis
- Neurogenic bladder

### RESULTS

Table 1. Demographic characteristics and anthropometric measurements

characteristics	Average value
Age (years)	44 (18-700)
Pol	Female (100%)
Height (cm)	163
Weight (kg)	65

Table 2. Medical history surrounding the underlying disease

Operative treatment and finding	initial score n(%)	control result n(%)
Positive cystoscopy finding	50 (100%)	0 (0%)
Positive urine culture	23 (46%)	3 (6%)
Positive BTA test	2 (4%)	1 (2%)
Cytological analysis of urine	*Cl. group I 35 (70%) Cl. group II 13 (26%) Cl. group III 2 (4%)	* Cl. group I 43 (86%) Cl. group II 7 (14%) Cl. group III 0 (0%)

\*classification group

Table 3. Urine analysis

Laboratory analyzes of urine	initial score n(%)	initial score n(%)
Glucose	7 (14%)	5 (10%)
Erythrocytes	37 (74%)	12 (24%)
Leukocytes	41 (82%)	8 (16%)
Nitrites	17 (34%)	5 (10%)
Ph urine value	5.5	5.8

Table 4. Pathohistological results

Pathohistological analysis	result n(%)
Squamous keratinizing metaplasia	18 (36%)
Squamous metaplasia	27 (54%)
Chronic cystitis	5 (10%)

Table 5. \* IPSS score international questionnaire first part

IPSS score parameters	Preoperative (average value) n50	Postoperative (average value) n50
How often in the past month have you had a feeling of incomplete emptying of the bladder after urinating? (0-5)	3	
How often in the last month did you have to urinate again in less than 2 hours? (0-5)	3	1
How often in the last month did you stop and start urinating several times? (0-5)	3	2
How often in the last month did you have difficulty holding (delaying) urination? (0-5)	4	2
How often in the last month did you have a weak stream of urine? (0-5)	2	1
How often in the last month did you have to strain to urinate? (0-5)	3	1
How often in the last month have you woken up to urinate? (points according to the number of urinations) (0-5)	2	1
* Total IPSS score	20	9

\*a score of 0-7 indicates mild symptoms, 8-19 indicates moderate-severe symptoms, 20-35 indicates severe symptoms

\* never 0, less than once 1, less than half the time 2, about half the time 3, more than half the time 4, almost always 5

Table 6. \*Quality of life as a result of urinary symptoms

If you had to spend the rest of your life with the urinary symptoms you have now, how would you feel?	Preoperative (average value) n50	Preoperative (average value) n50
Delighted 0	0	8
Satisfied 1	0	22
Generally satisfied 2	3	11
Equally satisfied and dissatisfied 3	12	4
Mainly dissatisfied 4	23	5
Unlucky 5	7	0
Terrible 6	5	0

\*second part of the IPSS score questionnaire

## CONCLUSION

All patients in our study were female. The patients ranged in age from 18 to 70 years old, with a mean of 44 years. All patients reported lower urinary tract symptoms lasting from three months to one year previously. All were treated with antibiotic therapy for lower urinary tract symptoms at least once in the past 3 months. 46% of the patients had a positive urine culture at the first examination, and only 6% at the control examination. The BTA (bladder tumor antigen) test was positive in 4% of the first and 2% of the follow-up examinations. The cytological analysis of the urine varied between the first, second and third classification groups, and there was an improvement in the first group by 16%, in the third group for 12% and the third group for 100%. All patients had negative markers

of hepatitis B, hepatitis C and HIV. Urinalysis showed a finding of erythrocytes 73% at the first examination and 24% at the control examination. Leukocytes were found in 82% of the patients at the first and 12% at the control examination, and the Ph value of the urine varied from 5.5 to 5.8. In all patients, cystoscopically, leukoplakic changes in the trigonum of the bladder were confirmed. Pathohistologically, the patients were divided into three groups depending on the findings, namely 36% squamous keratinizing metaplasia of the bladder, 54% squamous metaplasia of the bladder and 10% with chronic cystitis.

According to the IPSS score (international prostate symptom score) questionnaire, we divided the patients into two groups, that is, 32 patients (64%) belonged to the group with medium-severe

symptoms, while 18 patients (36%) belonged to the group with severe symptoms. There was a significant improvement in baseline IPSS score over control. The percentage of lower urinary tract symptoms decreased from 57.1% to 25.7%.

According to the evaluation of the quality of life of the postoperative control, 64.4% of patients reported improvement, 23.5% reported no improvement, and 12.1% reported deterioration.

Squamous keratinizing metaplasia of the bladder (SCM) is considered a rare disease of unclear etiology for which there is currently no effective medical therapy. Female patients with SCM present severe lower urinary tract symptoms refractory to conservative therapy. Antibiotics, alpha blockers, and anticholinergics are effective in lower urinary tract symptoms associated with benign prostatic hyperplasia but not in squamous

keratinizing metaplasia of the bladder. Therefore, in these cases, for now, the only treatment that offers improvement and disappearance of symptoms is recommended, which is the transurethral resection of the bladder lesion.

The results of our study showed a 64.4% improvement in quality of life, compared to studies by Constantini et al, Hussain et al. and Benelli's study (10,2,5) postoperatively observed improvement of lower urinary tract symptoms in 68%, 72% and 75% of patients.

The results of this study show us that squamous keratinizing metaplasia of the bladder in women is closely related to symptoms of the lower urinary tract, and transurethral resection of squamous keratinizing metaplasia stands out as a superior diagnostic and therapeutic method compared to conservative treatment.

#### REFERENCES:

1. Markovik V, Urologija Tom 2. Novinarsko-izdavacka institucion Sluzben list SRJ. Belgrade 1997. Surgery mokracnih organs. Rare sick basically , pp. 885-892
2. Hussain SA, Alhalabi F, Zimmern PE. Long-term efficacy of fulguration of trigonitis for recurrent urinary tract infections in women. *Urol Sci.* 2015; 26:197 - 201.
3. Al S, Schlechte H, Sachs M, Kristiansen G, Burkhardt M, Schnorr D. Clinical value of vesical leukoplakia and evaluation of the neoplastic risk by mutation analyzes of the tumor suppressor gene TP53. *Int J Urol.* 2006; 13: 1092-1097.
4. Lee KS, Yoo TK, Liao L, et al. Association of lower urinary tract symptoms and OAB severity with quality of life and mental health in China, Taiwan and South Korea: results from a cross-sectional, population-based study. *BMC Urol.* 2017; 17:108.
5. Benelli A, Varca V, Vaccaro C, et al. Keratinizing squamous metaplasia of the bladder: our experience and current approaches. *Urologia.* 2018; 3:391560318810197.
6. Ablove T, Bell LN, Liang H, Chappell RJ, Toklu HZ, Yale SH. The effect of solifenacin on postvoid dribbling in women: results of a randomized, double-blind placebo-controlled trial. *Int Urogynecol J.* 2018; 29:1051-1060.
7. McKenney JK. Precursor lesions of the urinary bladder. *Histopathology.* 2019; 74: 68-76.
8. Khan MS, Thornhill JA, Gaffney E, Loftus B, Butler MR. Keratinising squamous metaplasia of the bladder: natural history and rationalization of management based on a review of 54 years of experience. *Eur Urol.* 2002; 42: 469- 474.
9. Steven PP, Pinkstaff DM, Kevin JW, Kenneth JB. Leukoplakia of the bladder. *Infect Urol.* 2003; 16: 95-102.
10. Costantini E, Zucchi A, Del Zingaro M, Mearini L. Treatment of urethral syndrome: a prospective randomized study with Nd:YAG laser. *Urol Int.* 2006; 76: 134-138.
11. Grzech-Leśniak K, Sculean A, Gašpiric B. Laser reduction of specific microorganisms in the periodontal pocket using Er:YAG and Nd:YAG lasers: a randomized controlled clinical study. *Lasers Med Sci.* 2018; 33:1461-1470.
12. Rofeim O, Hom D, Freid RM, Moldwin RM. Use of the neodymium: YAG laser for interstitial cystitis: a prospective study. *J Urol.* 2001; 166: 134-136.
13. Connery DB. Leukoplakia of the urinary bladder and its association with carcinoma. *J Urol* 1953; 69:121-7. 10.1016/S0022-5347(17)68038-8

#### ADDRESS FOR CORRESPONDENCE:

Dr. D. Markovski  
 City General Hospital "8th of September",  
 66, Pariska Str., Skopje 1000,  
 Republic of North Macedonia  
 Tel: +389 2 3087400  
 Fax: +389 2 3072125  
**E-mail:** urologija@bolnica.org.mk

# ТЕЛЕАНГИЕКТАТИЧЕН ОНКОЦИТОМ - РЯДЪК СЛУЧАЙ НА ОНКОЦИТОМ С НЕТИПИЧНИ МОРФОЛОГИЧНИ ХАРАКТЕРИСТИКИ И ИМУНОПРОФИЛ

Сл. Котова<sup>1</sup>, Ц. Йоцов<sup>2,3</sup>, Р. Котов<sup>2</sup>

<sup>1</sup> КЛИНИКА ПО УРОЛОГИЯ, УМБАЛ „АЛЕКСАНДРОВСКА“ - СОФИЯ  
КАТЕДРА ПО УРОЛОГИЯ, МУ-СОФИЯ

<sup>2</sup> УМБАЛ „МЕДИКА“ – РУСЕ

<sup>3</sup> РУСЕНСКИ УНИВЕРСИТЕТ „АНГЕЛ КЪНЧЕВ“, КАТЕДРА ПО ЗДРАВНИ ГРИЖИ

## TELANGIECTATIC ONCOSYTOMA - A RARE CASE OF ONCOSYTOMA WITH ATYPICAL MORPHOLOGICAL CHARACTERISTICS AND IMMUNE PROFILE

S. Kotova<sup>1</sup>, Ts. Yotsov<sup>2,3</sup>, R. Kotov<sup>2</sup>

<sup>1</sup> UNIVERSITY HOSPITAL ALEXANDROVSKA, DEPARTMENT OF UROLOGY, SOFIA, BULGARIA  
MEDICAL UNIVERSITY OF SOFIA, DEPARTMENT OF UROLOGY, SOFIA, BULGARIA

<sup>2</sup> UNIVERSITY HOSPITAL MEDICA – RUSE, BULGARIA

<sup>3</sup> “ANGEL KANCHEV” UNIVERSITY OF RUSE, DEPARTMENT OF HEALTH CARE, RUSE, BULGARIA

### АБСТРАКТ

**Въведение:** Онкоцитомът на бъбрека е сравнително рядка патология. Представява доброкачествен епителен тумор с честота 3-7% от всички първични бъбречни неоплазми. [1] Засяга предимно възрастното население, като най-голяма е честотата на пациентите в седмото десетилетие. Често протича безсимптомно и се явява случайна находка от образно изследване, извършено по друг повод. При контрастна компютърна томография се представя като солидна бъбречна лезия с нееднородна структура и наличие на централна хиподенсна зона. Макроскопски класическият онкоцитом е кръгловат, кафеникав, инкапсулиран и добре отграничен от околните тъкани, с наличие на т.нар. „централен белег“. Хистологично е представен от гнездовидни или тубуларни структури от еозинофилни клетки с гранулирана цитоплазма. Телеангиектатичният вариант на бъбречния онкоцитом показва значителни различия по отношения на радиологичните и хистологичните белези, което затруднява поставянето на диагнозата. Предвид доброкачествения си характер, онкоцитомите подлежат на проследяване, но поради сходните характеристики в образната диагностика с тези на бъбречноклетъчния карцином хирургичното лечение често е за предпочитане.

**Цел:** Да се представят и анализират клиничните, радиологичните, морфологичните и хистологичните особености на телеангиектатичния онкоцитом и да се дадат

препоръки за лечебно-диагностичния план.

**Материали и методи:** Представяме случая на 59-годишен пациент, претърпял лапароскопска нефректомия в Урологично отделение на УМБАЛ „Медика“-Русе по повод солидна бъбречна лезия, с хистологичен резултат телеангиектатичен и тубуларен вариант на бъбречен онкоцитом. Предоперативната диагностика се базира на компютър томографско изследване с интравенозен контраст. За хистологична верификация е проведено оцветяване с хематоксилин-еозин и имунохистохимия. Метод на лечение е радикална лапароскопска нефректомия.

**Резултати:** Проведен е ретроспективен анализ на клиничните, радиологичните, патологоанатомичните и хирургичните резултати при пациент, подложен на десностранна лапароскопска нефректомия по повод солидна бъбречна лезия. При проведената предоперативна компютърна томография се диагностицира добре ограничена хетерогенна солидна бъбречна лезия с диференциална диагноза бъбречноклетъчен карцином или онкоцитом. Хистологичният анализ потвърди бъбречен тумор с нетипична морфологична характеристика и имунопрофил — телеангиектатичен и тубуларен вариант на онкоцитом.

**Заклучение:** Телеангиектатичният онкоцитом се проявява с нетипични радиологични характеристики, които затрудняват предоперативната диагностика и налагат допълнителни имунохистохимични патологоанатомични методи за постоперативна оценка.

**Ключови думи:** онкоцитом, телеангиектатичен, имунохистохимия бъбречен тумор

## ABSTRACT

**Introduction:** *Oncocytoma of the kidney is an infrequent pathological condition. This benign epithelial tumor accounts for 3-7% of all primary renal neoplasms. [1] It is predominantly observed among the elderly, and its highest incidence occurs within the seventh decade of life. It is often asymptomatic and may be discovered incidentally during imaging studies. Contrast computed tomography reveals a solid renal lesion with a heterogeneous structure and a central hypodense zone. Pathologically, the classic oncocytoma is round, brownish, encapsulated, and well delimited from the surrounding tissues, with the characteristic presence of a “central scar” or “central stellate scar.” Histologically, it is characterized by nest-like or tubular structures of eosinophilic cells with granular cytoplasm. The telangiectatic variant of renal oncocytoma presents significant differences in radiological and histological characteristics, making diagnosis challenging. Due to their benign nature, oncocytomas warrant regular follow-up. However, given their imaging characteristics, which are akin to those of renal cell carcinoma, surgical intervention is often the preferred course of action.*

**Objectives:** *To present and analyze the clinical, radiological, morphological, and histological features of telangiectatic oncocytoma and to provide recommendations for treatment and diagnostic planning.*

**Materials and Methods:** *We present the case of a 59-year-old patient who underwent laparoscopic nephrectomy at the Urology Department of the University Hospital “Medica” in Ruse for a solid renal lesion. The histological result revealed a telangiectatic and tubular variant of renal oncocytoma. Preoperative diagnosis relies on a CT scan with contrast, followed by histological verification using H&E staining and immunohistochemistry. Treatment involves laparoscopic radical nephrectomy.*

**Results:** *A retrospective analysis was conducted on clinical, radiological, pathoanatomical, and surgical results in a patient who underwent laparoscopic nephrectomy on the right side for a solid renal lesion. The preoperative computed tomography has diagnosed a well-defined, heterogeneous solid renal lesion with a possible diagnosis of renal cell carcinoma or oncocytoma. Histological analysis confirmed the presence of a renal tumor with atypical morphological charac-*

*teristics and an immune profile consistent with telangiectatic and tubular variants of oncocytoma.*

**Conclusion:** *Telangiectatic oncocytoma presents atypical radiological characteristics that complicate preoperative diagnosis, necessitating additional immunohistochemical methods for postoperative assessment.*

**Keywords:** *oncocytoma, telangiectatic, immunohistochemistry, renal tumor*

## ВЪВЕДЕНИЕ

Бъбречният онкоцитом е доброкачествен тумор, произлизащ от интеркаларните клетки на събирателните каналчета. Представява сравнително рядка патология, като честотата му в световен мащаб е 3-7% от всички първични бъбречни неоплазми. [1] Засяга предимно възрастното население, най-често в седмото десетилетие. Бъбречният онкоцитом рядко има клинична изява и се явява случайна находка от образно изследване, проведено по повод друга абдоминална патология. В случаите на симптоматично протичане той имитира клиничната картина на злокачествените бъбречни тумори, с най-чести симптоми болка и дискомфорт в лумбалната област и хематурия. Предоперативната диагноза се основава на методите на образната диагностика — ехография, компютърна томография (КТ) с контрастно усилване, ядреномагнитен резонанс. През последните години в урологичната и радиологичната практика навлезе новата технология  $^{99m}\text{Tc}$ -sestamibi SPECT/CT, показваща обещаващи резултати в диференциалната диагноза между low-grade БКК и доброкачествения онкоцитом, която нерядко е затруднена при конвенционалните образно-диагностични методи. [2,3] Радиологичната находка е на добре ограничена хетерогенна солидна туморна формация в бъбречния паренхим, като патогномоничен е т. нар. „централен белег“ — хиподенсен/хипоинтензен спиковиден участък във вътрешността на лезията. Макроскопски класическият онкоцитом представлява добре отграничена от околния бъбречен паренхим окръглена лезия. Той е кафеникав или махагонов на цвят, на срез във вътрешността му се наблюдава белезникав фиброзен участък, а в 20–37% е описана кистична дегенерация. В малък процент се срещат и хеморагични участъци. Микроскопски класическият онкоцитом има характерна цитоархитектоника и е представен от гнездовидни или туболарни

структури, съставени от клетки с плътна еозинофилна цитоплазма с цитоплазмени включвания. Въпреки това, в малък процент случаи онкоцитомът може да се представи с атипична макроскопска и микроскопска характеристика, което създава диагностични трудности. [4,5] Рядък вариант на бъбречния онкоцитом е телеангиектатичният, който се характеризира с преобладаващи кистични участъци, изпълнени с кръв (т. нар. „кръвни езера“) сред туморната маса. [6]

В настоящата статия е представено клиничното протичане, радиологичните и патологоанатомичните особености при пациент, подложен на лапароскопска нефректомия по повод солидна бъбречна лезия с рядката хистологична диагноза телеангиектатичен и тубуларен вариант на онкоцитом.

## МАТЕРИАЛИ И МЕТОДИ

Касае се за мъж на 59 години, с оплакване от дискомфорт в дясна лумбална област със значителна давност, поради което е консултиран с уролог и ехографски е диагностицирана окръглена хетероехогенна паренхимна лезия в горен полюс на десен бъбрек. Проведена е КТ с интравенозен контраст на корем и малък таз, като е установена добре ограничена хетерогенна формация в горна трета на бъбрека.

При пациента се извърши лапароскопска радикална нефректомия чрез трансперитонеален достъп. Контролът над бъбречния хилус бе осъществен с помощта на съдов стаплер тип „Endo GIA“. Отстраненият бъбрек бе екстирпирен през инцизия в голем коремен квадрант и изпратен за патологоанатомичен анализ.

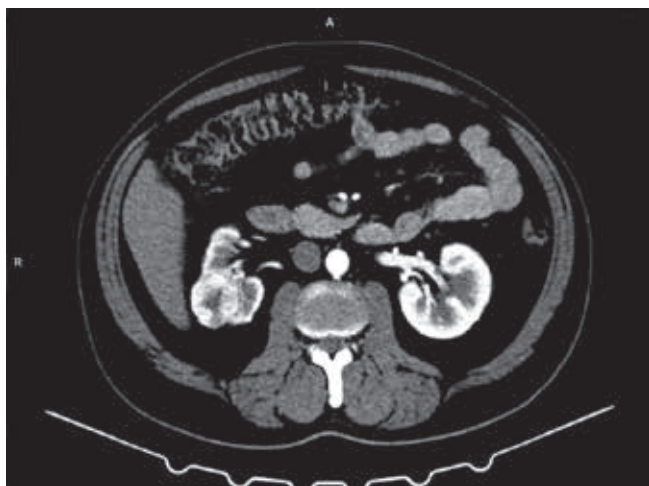
При хистологичната оценка на туморната формация за доказване на онкоцитом са използвани следните критерии: епителна неоплазма, съставена от големи онкоцитни клетки — епителни клетки с еозинофилна цитоплазма, богата на фини грануляции, и малки, кръгли, правилни ядра с фино гранулиран, равномерно диспергиран хроматин, и

централна нуклеола. [6] За поставяне на патологоанатомичната диагноза телеангиектатичен онкоцитом са използвани два критерия: 1. наличие на т. нар. „кръвни езера“ — различни по големина кистични пространства, тапицирани с епителни клетки с типични онкоцитни характеристики и изпълнени с кръв или серо-кръвениста субстанция; 2. имунохистохимична обработка на препарата за цитокератин 7 (CK7), CD117; vimentin, AMACR, GATA3, HMB-45, Melan A за оценка на тумора и епителните клетки, тапициращи телеангиектатичните пространства. [6,7]

## РЕЗУЛТАТИ

### **Резултати, свързани с радиологичната характеристика на тумора**

След провеждане на КТ на корем и малък таз с приложение на интравенозен контраст е диагностицирана добре демаркирана меко-тъканна лезия в горна трета на бъбрека с размери 43x37x36 мм, характеризираща се с хетерогенно контрастно усилване (wash-out ефект) и централна хиподенсна зона, без наличие на калцификати. Формацията компримира и деформира чашките на горна трета на бъбрека, като не е изключена инвазия в пиелокаликсната система и синусната мастна тъкан. Не са открити данни за патологични промени в други органи и системи. На база резултата от образното изследване в диференциален план се обсъди онкоцитом или бъбречноклетъчен карцином (БКК). (Фиг. 1)

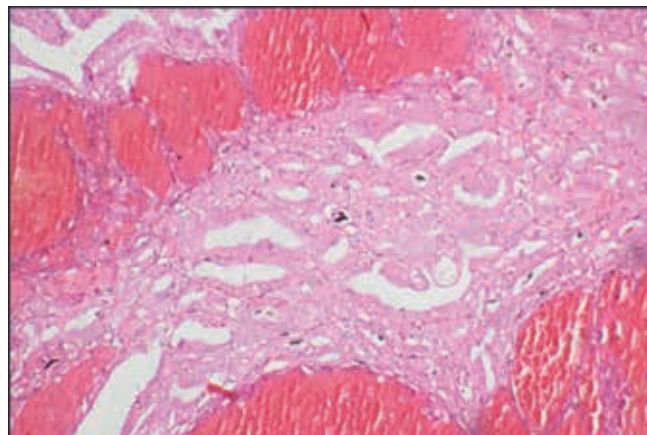


Фиг. 1 КТ с интравенозен контраст, показваща хетерогенна формация в десен бъбрек.

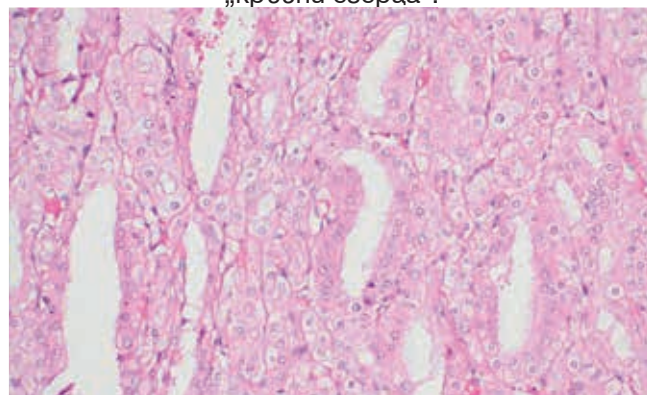
### **Резултати, свързани с патологоанатомичните характеристики на формацията** *Макроскопско описание:* кафеникава ту-

морна формация, сравнително добре отграничена от околния бъбречен паренхим, с размери 4.5/3см, изпъстрена от кръвоизливи. Формацията компримира, без да ангажира пиелокаликсната система.

*Морфологично описание:* бъбрек с тумор с тубуло-папиларен строеж, обширни кръвоизливи, отлагане на тъмнокафяв зърнист Perl's-негативен пигмент сред хеморагичните участъци и сред туморния паренхим без хеморагии. Туморните клетки са с овални везикуларни ядра, лек до умерен ядрен полиморфизъм, с малки нуклеоли, с обилна светла еозинофилна цитоплазма и ниска митотична активност. Проведено е имунохистохимично изследване (ИХХ) на препарата за CK7 — фокална цитоплазмена експресия в туморните клетки, AMACR — липсва експресия в туморните клетки, vimentin - липсва експресия в туморните клетки, GATA3 - липсва експресия в туморните клетки, HMB-45 и Melan A — липсва експресия, CD117 — дифузно имунооцветяване. (Фиг. 2,3)



Фиг. 2 Хистологичен препарат: телеангиектатичен вариант на онкоцитом; „кръвни езера“.



Фиг. 3 Хистологичен препарат: бъбречен онкоцитом с гнездовидни и тубуларни структури от еозиновидни клетки с малки кръгли ядра с централна нуклеола.

След обстоен патологоанатомичен анализ на препаратата се постави диагнозата бъбречен тумор с нетипични морфологични характеристики и имунопрофил — онкоцитом на бъбрека, предимно телеангиектатичен и тубуларен вариант.

### ОБСЪЖДАНЕ

Телеангиектатичните неоплазми са рядка патология. Описани са най-често под формата на телеангиектатичен вариант на чернодробен агеном и телеангиектатичен остеосарком. [8,9]

Хистологично се характеризират с наличие на кистични пространства, изпълнени с кръв или серо-кръвениста субстанция и тапицирани с неопластични клетки. В настоящата статия е представен клиничен случай на 59-годишен пациент, подложен на десностранна лапароскопска нефректомия по повод солидна бъбречна лезия, патологоанатомично класифицирана като рядък вариант на онкоцитом на бъбрека — телеангиектатичен и тубуларен онкоцитом.

Бъбречният онкоцитом е с честота едва 3-7% от първичните бъбречни неоплазми. По литературни данни по-често е засегнато възрастното население, предимно в седмото десетилетие, с по-голяма честота сред мъжкия пол. Подобно е и разпределението на телеангиектатичния онкоцитом. Обикновено заболяването протича без да даде клинична изява. То се явява случайна находка при абдоминално образно изследване. При поставяне на диагнозата средният размер на тумора при телеангиектатичния вариант е по-малък спрямо този, докладван за класическия онкоцитом (3.5 см спрямо 4.3 см). [10] Размерът на формацията при нашия пациент е бил 4.5/3 см. За разлика от класическия онкоцитом, който е кафеникав на цвят със солидна срезна повърхност, в централната част на която при 32% от случаите се

описва „централен белег“ — пиковидна фиброзна дегенерация, който е патогномоничен за бъбречен онкоцитом, при макроскопски оглед на препаратата от извършената от нас нефректомия се видя кафеникава мековата формация, чиято срезна повърхност бе изпълнена от множество кръвоизливи и кистоподобни структури, изпълнени със серо-кръвениста субстанция. Не се видя наличие на централна фиброзна дегенерация. От методите на образна диагностика — абдоминална ехография и контрастна компютърна томография, се описа хетерогенна мековата туморна формация в горен полус на бъбрека, суспектна за малигнена (в диференциално-диагностичен план се обсъди онкоцитом или бъбречноклетъчен карцином). При хистологичната оценка на препаратата се установи наличие на типични белези за телеангиектатичен вариант на бъбречен онкоцитом — кръвни езера — кистоподобни структури, изпълнени с кръв или серо-кръвениста субстанция и тапицирани с онкоцитомни клетки. Диагнозата се потвърди хистохимично. [11]

### ЗАКЛЮЧЕНИЕ

С настоящата статия е представен рядък случай на телеангиектатичен и тубуларен вариант на бъбречен онкоцитом, представящ се с характерни радиологични и патологоанатомични белези, отличаващи го от класическия онкоцитом и бъбречноклетъчния карцином. Макар да е рядка нозологична единица, познаването на тези особености подпомага правилната диагноза и избора на подходящо лечение.

### БЛАГОДАРНОСТИ КЪМ:

*Клиника по образна диагностика към УМБАЛ „Мегика“-Русе;*

*Клиника по патология към УМБАЛ „Мегика“-Русе*

### БИБЛИОГРАФИЯ:

1. Trevisani F, Floris M, Minnei R, Cinque A. Renal Oncocytoma: The Diagnostic Challenge to Unmask the Double of Renal Cancer. Int J Mol Sci. 2022 Feb 26;23(5):2603. doi: 10.3390/ijms23052603. PMID: 35269747; PMCID: PMC8910282.
2. Wilson MP, Katlariwala P, Murad MH, Abele

- J, McInnes MDF, Low G. Diagnostic accuracy of 99mTc-sestamibi SPECT/CT for detecting renal oncocytomas and other benign renal lesions: a systematic review and meta-analysis. Abdom Radiol (NY). 2020 Aug;45(8):2532-2541. doi: 10.1007/s00261-020-02469-8. PMID: 32193593.
3. Ishigami K, Jones AR, Dahmouh L, Leite LV,

- Pakalniskis MG, Barloon TJ. Imaging spectrum of renal oncocytomas: a pictorial review with pathologic correlation. *Insights Imaging*. 2015 Feb;6(1):53-64. doi: 10.1007/s13244-014-0373-x. Epub 2014 Dec 14. PMID: 25504153; PMCID: PMC4330236.
4. Val-Bernal JF, Garijo MF, Gymez-Romбн JJ. Renal oncocytoma with prominent xanthomatous reaction. A rare histopathological variant of oncocytoma. *Rom J Morphol Embryol*. 2021 Jul-Sep;62(3):663-670. doi: 10.47162/RJME.62.3.02. PMID: 35263393; PMCID: PMC9019639.
  5. Wobker SE, Williamson SR. Modern Pathologic Diagnosis of Renal Oncocytoma. *J Kidney Cancer VHL*. 2017 Oct 9;4(4):1-12. doi: 10.15586/jkcvhl.2017.96. PMID: 29090117; PMCID: PMC5634396.
  6. Xiao GQ, Ko HB, Unger P. Telangiectatic oncocytoma: a previously undescribed variant of renal oncocytoma. *Am J Clin Pathol*. 2013 Jul;140(1):103-8. doi: 10.1309/AJCP9HDXYB2WYYJX. PMID: 23765540.
  7. Williamson SR, Gadde R, Trpkov K, Hirsch MS, Srigley JR, Reuter VE, Cheng L, Kunju LP, Barod R, Rogers CG, Delahunt B, Hes O, Eble JN, Zhou M, McKenney JK, Martignoni G, Fleming S, Grignon DJ, Moch H, Gupta NS. Diagnostic criteria for oncocytic renal neoplasms: a survey of urologic pathologists. *Hum Pathol*. 2017 May;63:149-156. doi: 10.1016/j.humpath.2017.03.004. Epub 2017 Mar 14. PMID: 28315424.
  8. Mounajjed T, Wu TT. Telangiectatic variant of hepatic adenoma: clinicopathologic features and correlation between liver needle biopsy and resection. *Am J Surg Pathol*. 2011 Sep;35(9):1356-63. doi: 10.1097/PAS.0b013e31822280f3. PMID: 21836491
  9. Limaiem F, Kuhn J, Tiwari V, et al. Telangiectatic Osteosarcoma. [Updated 2023 Aug 3]. In: *StatPearls* [Internet]. Treasure Island (FL): StatPearls Publishing; 2024 Jan-. Available from: <https://www.ncbi.nlm.nih.gov/books/NBK537309/>
  10. Trpkov K, Yilmaz A, Uzer D, Dishongh K M, Quick C M, Bismar T A & Gokden N (2010) *Histopathology* **57, 893—906**
  11. Val-Bernal JF, Garijo MF, Gymez-Romбн JJ. Renal oncocytoma with prominent xanthomatous reaction. A rare histopathological variant of oncocytoma. *Rom J Morphol Embryol*. 2021 Jul-Sep;62(3):663-670. doi: 10.47162/RJME.62.3.02. PMID: 35263393; PMCID: PMC9019639.

**АДРЕС ЗА КОРЕСПОНДЕНЦИЯ:**

Д-р Славина Котова  
УМБАЛ „Александровска“,  
Клиника по Урология,  
Медицински Университет София,  
Категра по урология  
Бул. Георги Софийски № 1,  
гр. София, ПК 1431, България  
Тел.: +359 899 855 196  
E-mail: slavina\_rk@abv.bg

**ADDRESS OF CORRESPONDENCE:**

Dr. Slavina Kotova  
University Hospital Alexandrovska,  
Clinic of Urology,  
Medical University Sofia,  
Department of Urology;  
1, Georgi Sofiyski, Blvd,  
Sofia 1431, Bulgaria  
Phone: +359 899 855 196  
e-mail: slavina\_rk@abv.bg



# НЕКА НЕ СЛЕДИМ ЧАСОВНИКА



- Лечение на еректилна дисфункция при възрастни мъже
- Лечение на признаци и симптоми на доброкачествена хиперплазия на простатата при възрастни мъже

Материалът е предназначен за медицински специалисти.  
По лекарско предписание. Преди предписание се запознайте с  
КХП Тадилекс 5мг 20210013/BG/МА/MP-53592/24.02.2021 и  
КХП Тадилекс 20мг 20210009/BG/МА/MP-53663/26.02.2021.

**Nobel Pharma**, 1415 София, ул. Околовръстен път № 36, Комплекс "Перла парк", ет.4,  
тел.:(+359 2) 962 90 35; факс: (+359 2) 962 90 36, e-mail: info@nobelpharma.bg



NOBEL

ИАЛ - 29530/10.07.2023

# Когато искате Вашите пациенти да продължат напред!

Само за медицински специалисти

Xtandi (enzalutamide) 40 mg меки капсули

Xtandi (enzalutamide) 40 mg филмирани таблетки

Терапевтични показания. Xtandi е показан за: лечение на възрастни мъже с метастазирал, хормоночувствителен рак на простатата (mHSPC) в комбинация с андроген депривационна терапия; лечение на възрастни мъже с високорисков, неметастазирал, резистентен на кастрация рак на простатата (castration-resistant prostate cancer, CRPC); лечение на възрастни мъже с метастазирал, резистентен на кастрация рак на простатата (castration-resistant prostate cancer, CRPC), които са без симптоми или с леки симптоми след неуспешна андроген-депривационна терапия и за които все още не е клинично показана химиотерапия; лечение на възрастни мъже с метастазирал CRPC, чието заболяване е прогресирало по време на или след лечение с доцетаксел.

Притежател на разрешението за употреба:

Astellas Pharma Europe B.V., Sylviusweg 62, 2333 BE Leiden, Нидерландия  
Номера на разрешението за употреба EU/1/13/846/001, EU/1/13/846/002

Дата на последно одобрение на КХП: 04.2021

По лекарско предписание. Преди да предпишете това лекарство, моля, запознайте се с пълната Кратка характеристика на продукта, която съдържа цялата информация за лекарствения продукт.

За пълна информация:

Астелас Фарма ЕООД, 1784 София, Бул. „Цариградско шосе“ № 90, Офис сграда Капитал форт, етаж 11, тел.: 02 8625372

Подробна информация за този лекарствен продукт е предоставена в пълната кратка

характеристика на продукта на уебсайта на Европейската агенция по лекарствата

<http://www.ema.europa.eu> и е достъпна при сканиране на QR кода или на:

[https://www.ema.europa.eu/en/documents/product-information/xtandi-epar-product-information\\_bg.pdf](https://www.ema.europa.eu/en/documents/product-information/xtandi-epar-product-information_bg.pdf)

За допълнителна информация относно лекарствените продукти на Астелас, моля изпратете запитване на адрес:

[medinfo.hbr@astellas.com](mailto:medinfo.hbr@astellas.com)

Нежеланите лекарствени реакции трябва да се докладват. Съобщавайте за нежелани лекарствени реакции на Astellas

чрез email до: [pharmacovigilance\\_bg@astellas.com](mailto:pharmacovigilance_bg@astellas.com), по факс на +359 (0)2 862 53 77, или се свържете с офиса на Astellas

локално. От медицинските специалисти се изисква да съобщават всяка подозирана нежелана реакция чрез

национална система за съобщаване.

Изпълнителна агенция по лекарствата ул. „Дамян Груев“ № 8, 1303 София, Тел.: +35 928903417, уебсайт: [www.bda.bg](http://www.bda.bg).

