

CLINICAL CASE REPORTS

The Ukrainian Journal of Clinical Surgery. 2026 January/February; 93(1):122-124
DOI: 10.26779/2786-832X.2026.1.122

Non-ampullary mucinous adenocarcinoma of the small intestine unmasked by persistent anemia: A Case Report

O. Kostovski¹, D. Jankoski¹, D. Kutanoski², P. Zdravkovski³, I. Kostovska⁴

¹ University Clinic of Digestive Surgery, Clinical Center “Mother Theresa”, Skopje, North Macedonia,

² Department of Surgery, General Hospital Ohrid, Ohrid, North Macedonia,

³ Institute of Pathology, Faculty of Medicine, Ss. Cyril and Methodius University in Skopje, Skopje, North Macedonia,

⁴ Department of Medical and Experimental Biochemistry, Faculty of Medicine, Ss. Cyril and Methodius University in Skopje, North Macedonia

Introduction

Although the small intestine constitutes approximately 75% of the gastrointestinal tract length and nearly 90% of its mucosal surface, fewer than 3% of gastrointestinal malignancies originate in this segment [1]. Small bowel tumors are classified into four major histologic types: adenocarcinoma (30–40%), carcinoid tumors (35–42%), lymphoma (15–20%), and sarcoma (10–15%). Adenocarcinomas are most frequently located in the duodenum (57%), followed by the jejunum (29%) and the ileum (10%) [2]. Mucinous adenocarcinoma of the small intestine is poorly characterized due to its rarity, with an estimated annual incidence of 0.3–2.0 cases per 100,000 persons. Epidemiological studies suggest a higher prevalence among Black populations and a gradual increase in incidence over time [3]. Most small bowel tumors remain clinically silent until advanced stages. Patients typically present with vague abdominal pain, weight loss, gastrointestinal bleeding, anemia, vomiting, diarrhea, or bowel obstruction [4]. We present a 74-year-old woman

with mucinous adenocarcinoma of the ileum, initially asymptomatic and later presenting with intestinal bleeding and anemia, causing a four-month diagnostic delay. Written informed consent was obtained for publication. This nonspecific presentation, combined with tumor location, often results in delayed diagnosis and poorer outcomes.

Case Presentation

A 74-year-old woman presented with intestinal bleeding and symptomatic secondary anemia, accompanied by intermittent dull right infraumbilical pain. Anemia symptoms, including pallor, dizziness, generalized weakness, and fatigue, had begun 2–3 months prior. Physical examination revealed a soft, non-tender abdomen; no masses were palpable. Digital rectal examination was unremarkable. Laboratory evaluation showed hemoglobin of 71 g/L and an erythrocyte count of $3.40 \times 10^{12}/L$. Abdominal ultrasound and contrast-enhanced CT of the abdomen and pelvis revealed no mass, lymphadenopathy, or metastasis (Figure 1). The patient received intravenous

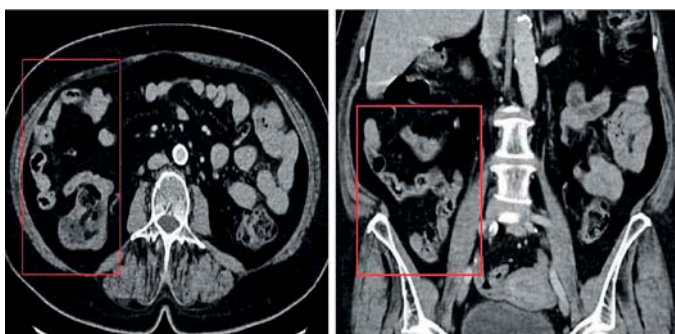

Figure 1. Axial and coronal CT images of the ileocecal region show no visible pathological mass.

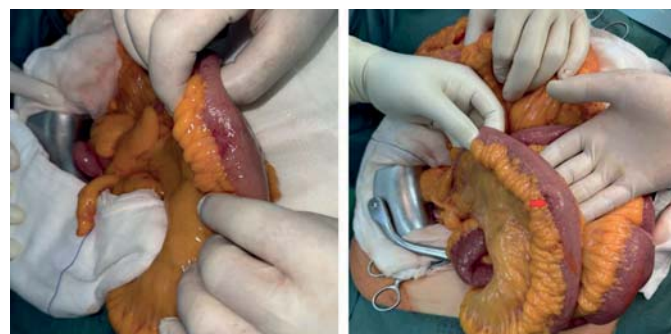


Figure 2. Intraoperative macroscopic finding of the ileal mass located 25–30 cm proximal to the ileocecal valve.

fluids and two units of packed red blood cells, raising the hemoglobin to 80 g/L. Elective midline laparotomy identified a 3-cm neoplastic lesion 25–30 cm proximal to the ileocecal valve, extending into the mesenteric tissue, with no distant metastases (Figure 2). Segmental small bowel resection with 10 cm proximal and distal margins, including mesenteric fat, was performed. Gastrointestinal continuity was restored via a termino-terminal ileo-ileal anastomosis (Figure 3). Gross pathology showed a 2.7-cm ulcerated gray-whitish mucinous tumor involving ~70% of the luminal circumference, located 10 cm from the proximal margin. Microscopic analysis shows a mucinous adenocarcinoma with mucin production up to 60% of the tumor population. The tumor shows an infil-

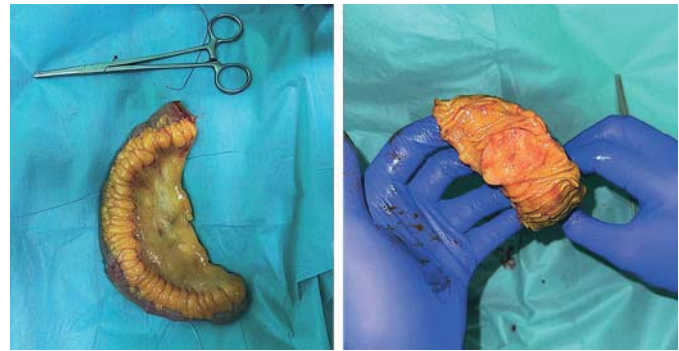

Figure 3.
Resected segment of ileum with associated mesentery showing intraluminal mucinous adenocarcinoma.

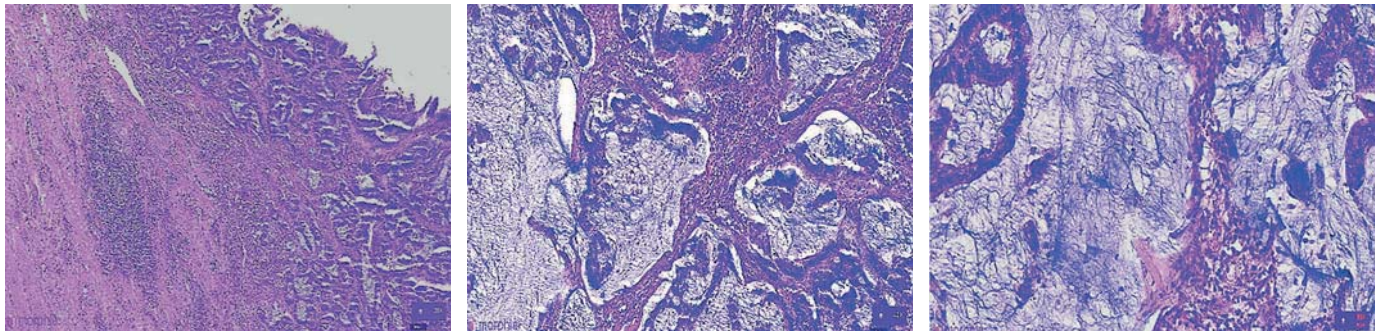


Figure 4.
Mucinous adenocarcinoma with infiltrative growth, high tumor budding, and full-thickness wall invasion. Hematoxylin-Eosin (HE) staining at $\times 20$, $\times 40$, and 8×0 .

trative growth front and a high degree of tumor budding. A moderate lymphocytic inflammatory reaction accompanies the neoplastic process. The neoplasm infiltrates the entire thickness of the small-intestinal wall and perforates into the subserous adipose tissue. Histopathology confirmed non-ampullary mucinous adenocarcinoma (pT3, pN0, pM0, G2, L0, V0, R0, Stage IIA) (Figure 4). All lymph nodes were negative. Postoperative recovery was uneventful, and the patient was discharged on day 6 and received adjuvant chemotherapy. At two-month follow-up, she remains disease-free.

Primary small bowel adenocarcinoma is rare, representing <3% of gastrointestinal cancers. Despite the small bowel comprising the majority of gastrointestinal length and mucosa, tumors in this location are uncommon. Mucinous adenocarcinoma is particularly rare and poorly described, with the ileum being the least frequent site [5]. Clinical presentation is nonspecific, including vague abdominal discomfort, occult or overt bleeding, anemia, changes in bowel habits, or weight loss. In this case, chronic anemia dominated, with only mild abdominal symptoms, resulting in a four-month diagnostic delay consistent with reports showing delays of up to six months [6]. Imaging such as ultrasound and CT often fails to detect small or early-stage ileal lesions, especially ulcerative tumors. Deep enteroscopy or ileocolonoscopy is cru-

cial when initial investigations are inconclusive. Surgical resection remains the mainstay for localized disease, aiming for negative margins and adequate lymphadenectomy [7]. The prognostic significance of mucinous histology in small bowel adenocarcinoma is unclear, unlike colorectal cancer. Adjuvant chemotherapy is extrapolated from colorectal cancer protocols, in this case, it was administered successfully, with the patient disease-free at two months.

Conclusion

Mucinous adenocarcinoma of the ileum is exceptionally rare, often presenting with nonspecific symptoms or anemia. Conventional imaging may fail to detect small or ulcerated lesions. Deep enteroscopy is essential in evaluating obscure gastrointestinal bleeding. Early diagnosis and timely surgical resection are crucial for improving outcomes.

Conflicts of Interest. The authors declare no conflict of interest.

Acknowledgments. No

References

1. Fujimori S, Hamakubo R, Hoshimoto A, Nishimoto T, Omori J, Akimoto N, et al. Risk factors for small intestinal adenocarcinomas that are common in the proximal small intestine. *World J Gastroenterol.* 2022 Oct 21;28(39):5658-65. doi: 10.3748/wjg.v28.i39.5658. PMID: 36338888; PMCID: PMC9627424.

2. Manley J, Ibrahim Y, Ansell J, Alastal H, Rasheed A. Small bowel adenocarcinoma: Case reports and review of the literature. *Arab J Gastroenterol*. 2021 Sep;22(3):240-5. doi: 10.1016/j.ajg.2021.07.003. Epub 2021 Sep 13. PMID: 34531134.
3. Bouali M, Sylvestre K, Benghait H, El Bakouri A, El Hattabi K, Bensardi FZ, et al. Small bowel adenocarcinoma a rare cause of upper gastrointestinal obstruction (a case report and literature review). *Int J Surg Case Rep*. 2022 Feb;91:106763. doi: 10.1016/j.ijscr.2022.106763. Epub 2022 Jan 11. PMID: 35030405; PMCID: PMC8760343.
4. Vlachou E, Koffas A, Toumpanakis C, Keuchel M. Updates in the diagnosis and management of small-bowel tumors. *Best Pract Res Clin Gastroenterol*. 2023 Jun-Aug;64-65:101860. doi: 10.1016/j.bpg.2023.101860. Epub 2023 Aug 12. PMID: 37652650.
5. Khosla D, Dey T, Madan R, Gupta R, Goyal S, Kumar N, et al. Small bowel adenocarcinoma: An overview. *World J Gastrointest Oncol*. 2022 Feb 15;14(2):413-22. doi: 10.4251/wjgo.v14.i2.413. PMID: 35317322; PMCID: PMC8918997.
6. Kim BS, Li BT, Engel A, Samra JS, Clarke S, Norton ID, et al. Diagnosis of gastrointestinal bleeding: A practical guide for clinicians. *World J Gastrointest Pathophysiol*. 2014 Nov 15;5(4):467-78. doi: 10.4291/wjgp.v5.i4.467. PMID: 25400991; PMCID: PMC4231512.
7. Ko MY, Yen CE, Yen HH. Obscure gastrointestinal bleeding with negative abdominal computed tomography study: The importance of enteroscopy for early diagnosis of small bowel malignancy. *JGH Open*. 2019 Feb 22;4(1):94-6. doi: 10.1002/jgh3.12159. PMID: 32055704; PMCID: PMC7008162.

Received 20.12.25