

See discussions, stats, and author profiles for this publication at: <https://www.researchgate.net/publication/361401845>

SURGICAL TREATMENT OF CONGENITAL CENTRAL DEFICIENCY OF THE HAND (CLEFT HAND) IN AN ADULT PATIENT – CASE REPORT

Article in Academic Medical Journal · January 2022

DOI: 10.53582/AMJ2221148F

CITATIONS

0

READS

147

1 author:



Marta Foteva

Ss. Cyril and Methodius University in Skopje

14 PUBLICATIONS 14 CITATIONS

SEE PROFILE

SURGICAL TREATMENT OF CONGENITAL CENTRAL DEFICIENCY OF THE HAND (CLEFT HAND) IN AN ADULT PATIENT - CASE REPORT

Foteva Marta

University Clinic for Orthopedic Surgery, Faculty of Medicine, Ss. Cyril and Methodius
University in Skopje, Republic of North Macedonia

e-mail:marta.foteva@medf.ukim.edu.mk

Abstract

Cleft hand is a congenital hand anomaly, which is characterized by the absence of one or more central digits (II, III and/or IV) of the hand and/or foot. The clinical appearance is very irregular, and treatment of cleft hand involves cosmetic and functional considerations. Due to the great clinical variability, the choice of the appropriate surgical procedure is difficult as there is no single surgical procedure to treat all cleft hands.

We present a case of bilateral cleft hand in an adult male patient (24 years of age). The patient presented with cleft hand of both hands; the right hand more severely affected with missing middle metacarpal and finger, typical V cleft with wide interdigital space, normal first web space and incomplete syndactyly of IV-V finger. Since his main concern was the cosmetic appearance of the right hand and there was good function in the thumb and index finger, the logical choice was to close the central cleft and preserve the function he already had. Postoperatively, the patient gained useful grip with all fingers, a satisfactory range of motion and preserved useful pattern of pinch. The cosmetic appearance improved substantially, much to the patient's satisfaction.

To the best of our knowledge, this is the first reported case of cleft hand in our country. For an adult patient to whom the aspect of cosmetic appearance is very important, surgery is indicated for cosmetic improvement, but care must be taken not to sacrifice the functionality of the hand.

Keywords: hand, fingers, hand deformities, congenital, limb surgical procedures, operative, reconstructive surgical procedures.

Introduction

Central deficiency of the hand (also known as cleft hand, SHFM - split hand/foot malformation, *manus fissa*, lobster hand, ectrodactyly) is a congenital hand anomaly caused by a defect in the central part of the apical ectodermal ridge during embryological development, which is characterized by the absence of one or more central digits (II, III and/or IV) of the hand and/or foot^[1]. According to the updated IFFSH classification of congenital upper limb anomalies, the so-called OMT (Obert, Manske, Tonkin) classification^[2], this anomaly is classified in category I B: malformations due to abnormal axis formation/differentiation of the hand plate, and further subcategorized (iii c) as a complex anomaly suggesting that multiple axes can be involved in its development^[2]. The clinical appearance of this congenital deformity is very irregular and can vary from a simple soft-tissue cleft between the long and ring fingers without loss of digits to suppression of all osseous elements of the hand except for the little finger ray^[3]. Historically, there have been many attempts to clinically classify different phenotypic

presentations of this anomaly: typical and atypical cleft hand^[4], status of the thumb web^[5], presence of associated anomalies^[6], and radiological morphology^[3], among others.

Classically, this anomaly appears as a "V-shaped" cleft in the hand with a variable degree of deformity, the phalanges of the affected digits are absent, and the metacarpals are present. The deficiency is typically bilateral^[1,7]. The defect does not include deficiencies of the wrist but associated carpal coalition and proximal radioulnar synostosis have been reported^[6,7].

The incidence of cleft hand is difficult to determine due to its phenotypic variability, but it is generally accepted that this anomaly appears as 1 in 90,000 births and 1 in 120,000 within the population^[8]. Bilateral cleft hands are observed in 56% of patients, while unilateral deformity is present in 44% of cases^[9].

There is no conservative treatment for this anomaly. Treatment of cleft hand involves cosmetic and functional considerations. Mild cases that are causing little functional impairment are left untreated. Surgical treatment is directed towards restoration of the first web space for function, cleft closure, syndactyly release and further procedures for any additional deformities. Repetitive surgery for any recurring deformities might be needed. Due to the great clinical variability of this congenital malformation, the choice of the appropriate surgical procedure is difficult as there is no single surgical procedure to treat all cleft hands. Functional and surgical classifications have been proposed to simplify the indication for and choice of surgery. Sandzén classification^[10] is based on three types, which differ completely in inheritance pattern, characteristic features, bilaterality, and functional management, but have one common denominator-central metacarpal deficiency or absence. Manske and Halikis⁵ proposed a classification and treatment according to the characteristics of the thumb web, which are more important to the function of the hand than are the central deficiency features, so surgery should be addressing the thumb web first and then closing the cleft. The recent DAST concept^[11] uses the morphological determinants of function for the cleft hand and includes: number of missing digits (D), associated anomalies (A), the site of the cleft (S) and functional state of the thumb (T). Further, numerical values have been assigned under each head in an increasing order of complexity. Depending on the status and complexity of the cleft, available surgical procedures are then classified into three types applicable for each cleft.

The optimal time for surgery of the cleft hand is at the age of 12-18 months^[6,11,12], with additional surgeries completed before school age.

Case report

We present a case of bilateral cleft hand in an adult male patient (24 years old at time of surgery). The patient comes from an impoverished and undeveloped rural background, and he was told there is no treatment for his deformity and was never examined by a doctor. He finally was able to seek medical treatment when he became independent. Out of 7 siblings in his family, only one of his sisters beside him is affected with this condition, but her cleft hand is unilateral, mild, and almost identical to his left hand. Both he and his sister have no associated cleft foot or syndromic conditions and are otherwise healthy. The patient presented with cleft hand of both hands (Figure 1); the right hand more severely affected with missing middle metacarpal and finger, typical V cleft with wide interdigital space, normal first web space and incomplete syndactyly of IV-V finger (Figure 2). The left hand is missing the middle finger, but all the metacarpals are present, there is no syndactyly and the first web space is normal (Figures 1,4). The X-ray of the right hand showed a visible remnant of the third metacarpal as part of the fourth metacarpal (Figure 3), impinging on the second metacarpal.

The patient has been using the right hand his whole life, mainly for grip and pinch with his thumb and index finger. He was unable to use the ulnar side of the hand. Mainly, he was very unhappy with the physical appearance of his right hand and his main concern was not being able to get married because of his visible deformity.

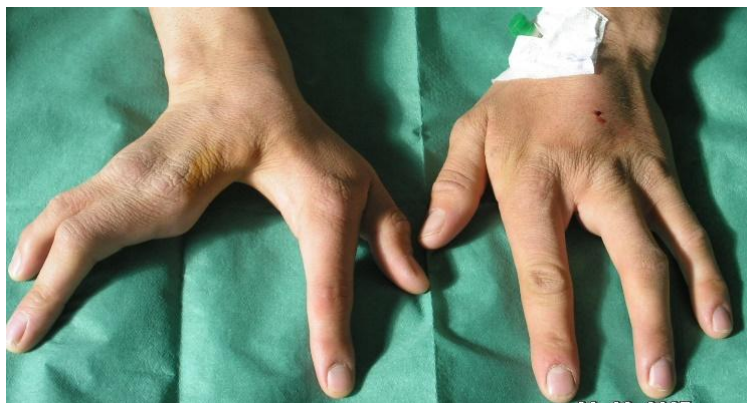

Fig. 1. Bilateral cleft hand

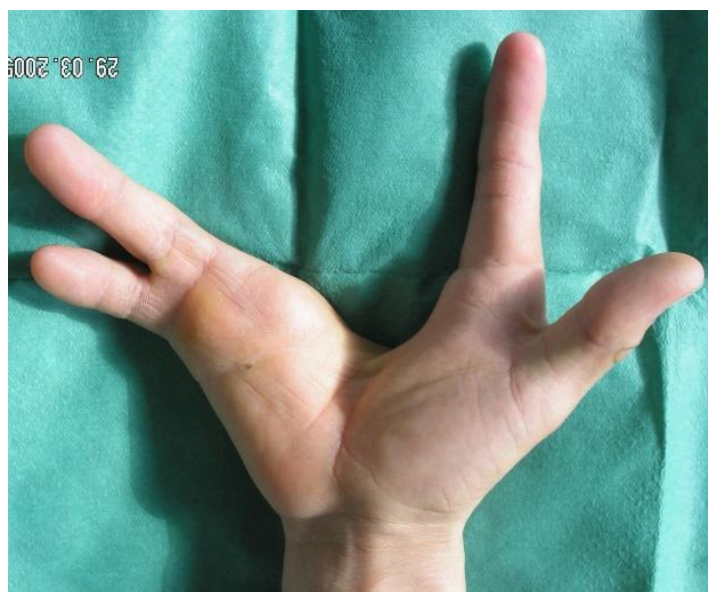

Fig. 2. Right hand with central wide cleft, absent middle finger, normal first web and incomplete syndactyly of IV-V finger

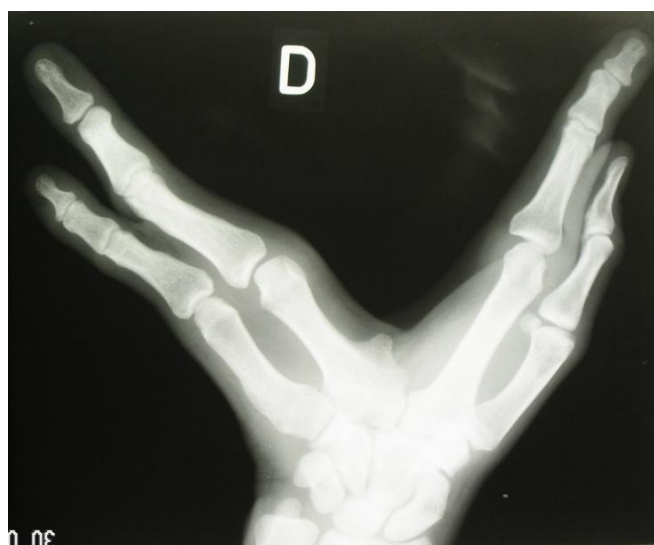

Fig. 3. X- ray of right hand

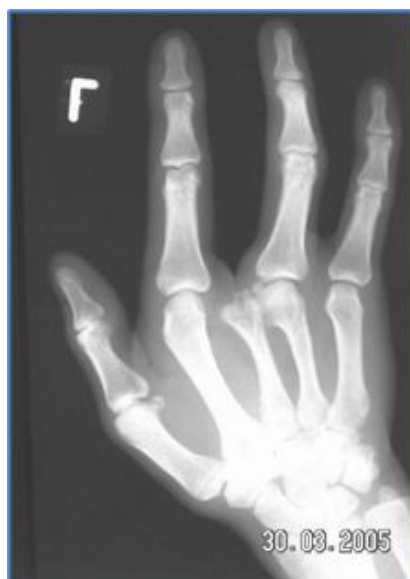

Fig. 4. X- ray of left hand

In preparation for surgical treatment, we had to find the most suitable surgical procedure for this type of cleft hand, considering the age of the patient and the desired cosmetic appearance of the hand. According to the Sandzén classification, this cleft hand can be classified as type II. Type II reconstructive procedures should provide as effective a pinch and grasp as possible between the radial and ulnar columns by deepening the central cleft, excising "digital nubbins" and any impinging skeleton, and performing rotational osteotomies of either metacarpal base or both and, occasionally, transfer to provide active digital flexion^[10]. We classified this patient as Manske and Halikis type I - normal first web, and they propose no surgical intervention for this type of cleft hand⁵. Using the DAST concept, we classified this patient as D1 (one missing digit), A0 (no associated anomalies), S1 (site of the cleft- central) and T0 (functional status of the thumb - normal)^[11]. When there is wide central cleft with normal thumb and index finger, the author's recommended procedure is the Barsky technique of creating a commissure^[11].

We could not find any references in the literature regarding surgical treatment in an adult patient with cleft hand as these cases are operated on at an early age. Since the patient's main concern was the cosmetic appearance of the hand and there was good function in the thumb and index finger, we felt that the logical choice was to perform single surgical procedure which will close the central cleft and preserve the function he already had.

Surgery: Following the description of the Barsky technique^[13] for closure of cleft, we made a diamond shaped skin flap on the medial side within the cleft, with its base distal and leveled it with the web space of the existing fingers. This flap was to form the new web after closure of the cleft. We removed the remnant of the third metacarpal which prevented the metacarpals to be drawn together. Metacarpals were then approximated by two heavy sutures passed through holes drilled in the bones just proximal to their heads. We sutured the deep tissues. Then we sutured the flap in place so that it bridges the gap near the bases of the adjoining fingers. The remaining dorsal and palmar skin edges were sutured in a zig-zag fashion. We also performed separation of the syndactyly between IV and V finger. The patient's hand was placed in a cast postoperatively for one month, and then in a splint for overnight use.

Results of surgery: The functional outcome and patient's satisfaction were followed up postoperatively for one year and at 15 years. The patient gained useful grip with all fingers, a satisfactory range of motion and preserved useful pattern of pinch (Figures 5,6,7). A shorter index finger and ulnar deviation of the index and ring finger were observed

postoperatively, but the functional result was still satisfactory. The cosmetic appearance of the hand improved substantially, much to the patient's satisfaction (Figure 5). At 15-year follow-up, the final result was very satisfactory - with preserved range of motion, preserved postoperative appearance of the hand and no complaints from the patient (Figure 8). He got married 5 years after surgery and he is a father of one son who is healthy with no congenital anomalies.

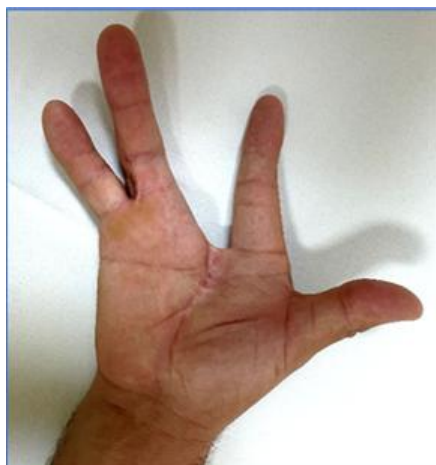

Fig. 5. Right hand at 15 year follow-up

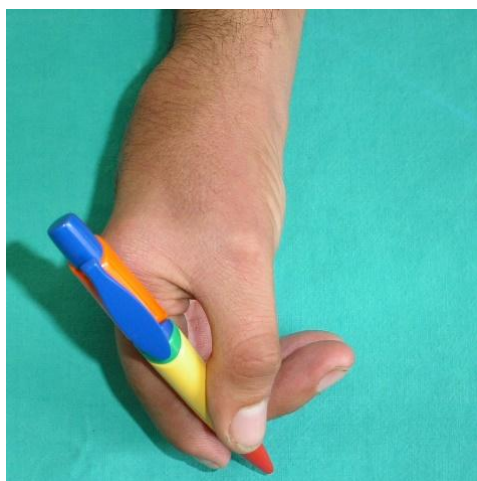


Fig. 6. Right hand - Postoperative functional result

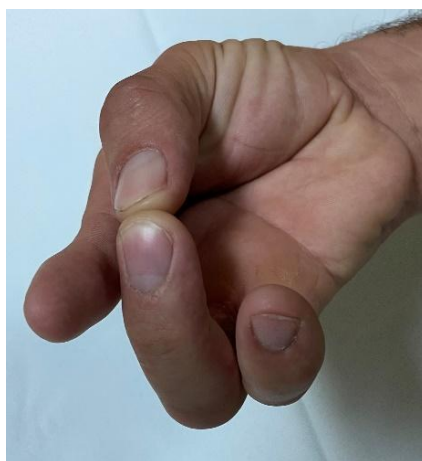

Fig. 7. Right hand - Postoperative functional result

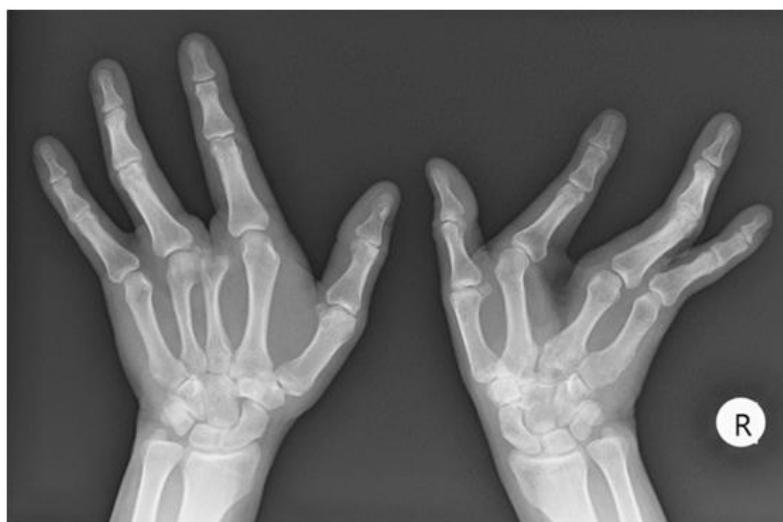

Fig. 8. At 15-year follow-up, X- ray - both hands

Conclusion

To the best of our knowledge, this is the first reported case of cleft hand in our country. A cleft hand has been described by Flatt as "a functional triumph and a social disaster"^[14] referring to the high degree of functionality of most hands with this deformity despite its atypical and malformed appearance. Even so, surgical intervention, in most cases, can improve the appearance of the hand without significantly affecting the functional outcome. Most patients are operated at an early age for best functional results, but occasionally there is an adult patient to whom the aspect of "social disaster" or cosmetic appearance is very important. For these patients, surgery is indicated for cosmetic improvement, but care must be taken not to sacrifice the functionality of the hand. Our patient was treated surgically and excellent results were obtained, with functional and cosmetic appearance improvement. Of all the proposed surgical classifications, we find the DAST classification most applicable, easy to understand, and helpful for the surgeon in deciding which type of surgical procedure to use in individual patients with cleft hand.

Conflict of interest statement. None declared.

References

1. Kozin SH. Upper-extremity congenital anomalies. *The Journal of bone and joint surgery. J Bone Joint Surg Am* 2003; 85(8): 1564-76. PubMed PMID:12925640.
2. Oberg KC. Classification of congenital upper limb anomalies: towards improved communication, diagnosis, and discovery. *J Hand Surg Eur Vol* 2019; 44(1): 4-14. doi: 10.1177/1753193418801280. PMID: 30269619.
3. Falliner A. The cleft hand. Proposal of a classification based on 279 cleft hands. *Handchir Mikrochir Plast Chir* 2004; 36(1): 47-54. doi: 10.1055/s-2004-817834. PubMed PMID: 15083390).
4. Miura T, Suzuki M. Clinical differences between typical and atypical cleft hand. *J Hand Surg Br* 1984; 9(3): 311-5. doi: 10.1016/0266-7681(84)90050-0. PMID: 6096467.
5. Manske PR, Halikis MN. Surgical classification of central deficiency according to the thumb web. *J Hand Surg Am* 1995; 20: 687-97. [PubMed PMID:8679337]

6. Glicenstein J, Guero S, Haddad R. Fentes médianes de la main. Classification et indications thérapeutiques a propos de 29 cas [Median clefts of the hand. Classification and therapeutic indications apropos of 29 cases]. *Ann Chir Main Memb Super* 1995; 14(6): 253. doi: 10.1016/s0753-9053(05)80404-1. PMID: 8679337.
7. Aleem AW, Wall LB, Manske MC, Calhoun V, Goldfarb CA. The transverse bone in cleft hand: a case cohort analysis of outcome after surgical reconstruction. *J Hand Surg Am* 2014; 39(2): 226-36. doi: 10.1016/j.jhsa.2013.11.002. Epub 2013 Dec 18. PMID: 24359797.
8. Tertarry SA, McKuisk VA. Absence deformities as isolated malformations. In Bergsma D, Mudge JR, Paul NW, Greene Sc, (Eds). *The Genetics of Hand Malformations*. New York; Alan R Liss, Inc, 1978F: 36.
9. Baba AN, Bhat YJ, Ahmed SM, Nazir A. Unilateral cleft hand with cleft foot. *Int J Health Sci (Qassim)* 2009; 3(2): 243-6. PMID: 21475543; PMCID: PMC3068821.
10. Sandzén SC Jr. Classification and functional management of congenital central defect of the hand. *Hand Clin* 1985; 1(3): 483-98. PMID: 3831049.
11. Sharma A, Sharma N. A comprehensive functional classification of cleft hand: The DAST concept. *Indian J Plast Surg* 2017; 50(3): 244-250. doi: 10.4103/ijps.IJPS_8_17. PMID: 29618858; PMCID: PMC5868102.
12. Katarincic JA. Cleft hand. *Journal of the American Society for Surgery of the Hand*. 2003; 3 (2): 108-116. doi: [https://doi.org/10.1016/S1531-0914\(03\)00022-6](https://doi.org/10.1016/S1531-0914(03)00022-6).
13. Barsky AJ. Cleft Hand: Classification, Incidence, and Treatment. Review of the literature and report of nineteen cases. *J Bone Joint Surg Am* 1964; 46: 1707-20. PMID: 14239859.
14. Flatt AE. The care of congenital hand anomalies (Cleft hand and central defects). *CV Mosby: St. Louis* 1977; 265-85.