

See discussions, stats, and author profiles for this publication at: <https://www.researchgate.net/publication/382149968>

# MRI EVALUATION OF BIOLOGICALLY ENHANCED ANTERIOR CRUCIATE LIGAMENT RECONSTRUCTION

Article in Academic Medical Journal · April 2024

DOI: 10.53582/AMJ2442041a

---

CITATIONS

0

---

READS

33

4 authors, including:



**Marta Foteva**

Ss. Cyril and Methodius University in Skopje

14 PUBLICATIONS 14 CITATIONS

SEE PROFILE



**Danica Doncovska**

PHI University Clinic for Traumatology, Orthopedic Diseases, Anesthesia, Reanima...

12 PUBLICATIONS 6 CITATIONS

SEE PROFILE

## MRI EVALUATION OF BIOLOGICALLY ENHANCED ANTERIOR CRUCIATE LIGAMENT RECONSTRUCTION

**Andonovski Alan, Foteva Marta, Andonovska Biljana, Popovska Danica**

University Clinic for Orthopedic Surgery, Traumatology, Anesthesiology and Intensive Care, Faculty of Medicine, Ss. Cyril and Methodius University in Skopje, Republic of North Macedonia  
*e-mail: martafoteva@hotmail.com*

### Abstract

**Introduction:** Platelet-rich plasma (PRP) and anterior cruciate ligament (ACL) residual remnant preservation are used today as biologic therapies aimed at stimulating graft healing process after ACL reconstruction, but their synergism has not been established yet. The aim of our study was to investigate the combined influence of PRP and ACL remnant preservation on graft healing after ACL reconstruction and evaluate the results with MRI.

**Material and methods:** The study included 52 patients (45 men and 7 women, mean age 28) divided into 2 groups: group I (control group) - 28 patients in whom after the removal of ACL residual bundle, a standard single bundle ACL reconstruction was made, and group II (examined group) - 24 patients in whom remnant preserving ACL reconstruction with addition of PRP was performed. The results were assessed 6 months after surgery by MRI evaluation of the graft healing process.

**Results:** Patients in the examined group had more frequently a light hyperintense signal of the intra-articular part of the graft (75% vs. 35.7%,  $p=0.0046$ ) and absence of synovial fluid at tunnel-graft interface (45.8% vs. 21.4%,  $p=0.06$ ), average 0.98 cm<sup>2</sup> less surface of bone edema around the graft ( $p=0.009$ ) than those from the control group.

**Conclusion:** Combined use of PRP and ACL remnant preservation has a positive influence on graft healing after ACL reconstruction leading to faster ligamentization and osteoligamentous integration of the graft.

**Keywords:** anterior cruciate ligament reconstruction, platelet-rich plasma, anterior cruciate ligament residual remnant preservation, graft healing process

### Introduction

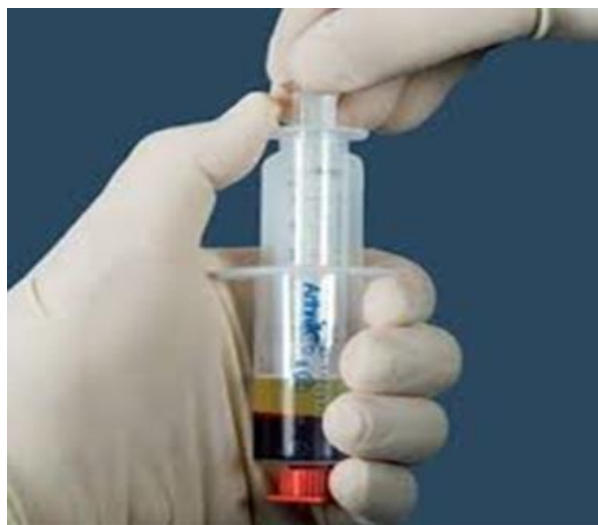In the previous decades, there has been an advancement in the surgical techniques for anterior cruciate ligament (ACL) reconstruction, but no significant improvement has been noticed in the postoperative results of these patients<sup>[1,2]</sup>. In the last decade, emerging new methods such as biologic therapy aim at stimulating the graft healing process leading to faster postoperative rehabilitation and better clinical results in patients with ACL reconstructive surgery. Biologic therapy in orthopedic surgery includes the use of pluripotent stem cells, biocompatible scaffolds, gene therapy, growth factors from platelet-rich plasma (PRP), mechanical stimulus and ACL residual remnants preservation<sup>[3-12]</sup>. The use of PRP in ACL reconstruction surgery is focused on two biologic processes: osteoligamentous integration of the graft into the tibial and femoral tunnels and maturation of the articular portion of the

graft<sup>[3-10]</sup>. ACL remnant preservation during ACL reconstruction is also very important because of its biomechanical, vascular, proprioceptive, and protective function<sup>[4,11-13]</sup>. With ACL remnant preservation there is a partial protection of the ACL vascular net, which is very important for the graft revascularization that can initiate faster graft healing according to the experimental and clinical studies<sup>[11-15]</sup>. Evaluation of the graft maturation could be indirectly monitored during MRI examinations since it has been proved that poor biomechanical properties and an incomplete graft maturation are related to a hyperintense graft signal on MRI.

The aim of our study was to investigate the combined influence of PRP and ACL remnant preservation on graft healing after ACL reconstruction and evaluate the results with MRI imaging.

### Material and methods

The study included 52 patients (45 men and 7 women) with a mean age of 28 years (range 16 to 50). The study included only patients with ACL rupture and arthroscopically confirmed presence of ACL residual remnant with a diameter greater than 1/3 of that of normal ACL and a continuity of the ligament fibers down to the tibia and above to the wall of the intercondylar notch or to the posterior cruciate ligament (PCL). Patients with present infection of the knee, significant degenerative changes in the cartilage of the knee, previous surgeries of the knee and associated lesions of the other ligaments in the knee, as well as those with comorbidities and pregnant women were excluded from this study. They were divided into 2 groups: *group I* (control group) - 28 patients in whom after the removal of the ACL residual bundle, a standard single bundle ACL reconstruction was made, and *group II* (examined group) - 24 patients in whom remnant preserving ACL reconstruction with addition of PRP was done. All patients were operated on at the University Clinic for Orthopedic Surgery - Skopje by the same orthopedic surgeon, and the same postoperative rehabilitation protocol was implemented in all of them by the same physiotherapist. MRI evaluation was performed 6 months after the ACL reconstruction by the same radiologist. This study was part of a doctoral thesis approved by the Ethics Committee of the Faculty of Medicine, Ss. Cyril and Methodius University in Skopje. The study was prospective and randomized.

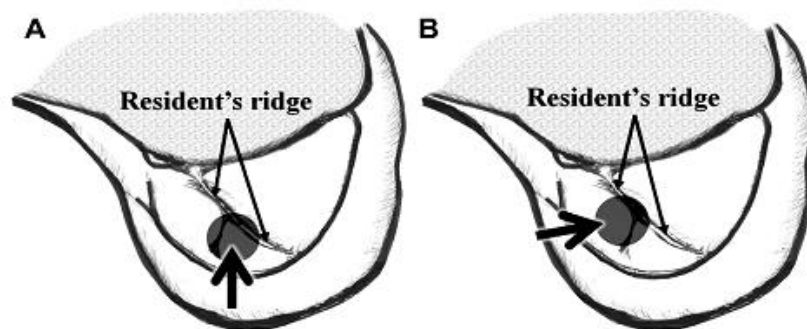


**Fig. 1.** Arthrex double syringe system with three different blood layers after blood centrifugation

Platelet-rich plasma (PRP) preparation was produced using Arthrex double syringe system (Figure 1). For this purpose, 15 ml of the patient's blood was drawn and centrifuged at 1500 rpm for 5 minutes. After the centrifugation, three layers were formed: the bottom layer containing red blood cells, the middle layer rich with platelets and white blood cells (buffy coat), and the top platelet-poor plasma layer. Then, with the other smaller syringe, about 3 ml plasma with platelets and white blood cells were drawn from the bigger syringe. Produced PRP using this system has 2 to 3 times more platelets than pure blood.

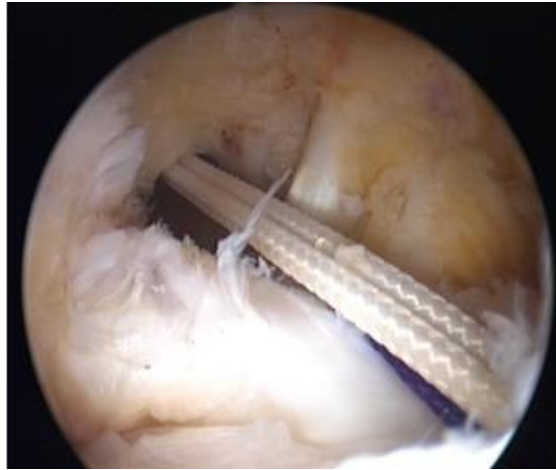
### **Surgical technique and PRP application**

ACL reconstruction was performed in spinal anesthesia under tourniquet placed in the upper thigh. Each intervention started with an arthroscopic revision of the knee joint, treatment of associated meniscal and cartilage injuries as well as measurement of the ACL residual remnant diameter. Tendons of hamstring muscles were used as a graft in all patients. Graft fixation was done by Endobutton (Smith & Nephew Ltd) on the femoral side and resorbing screw in the tibia tunnel. The placement of the femoral tunnel was done with or without a special femoral guide, by using the transportal technique of drilling. Taking into account that in cases of ACL partial rupture, the remaining residual bundles are not completely intact and there is some reduction in their biomechanical function and strength as well as that the graft is shifting down after its application, the femoral tunnels were placed slightly above to cover the lateral intercondylar ridge and with one part (about  $\frac{1}{4}$  the size of the channel) to pass on the other side of bifurcation ridge (Figure 2).

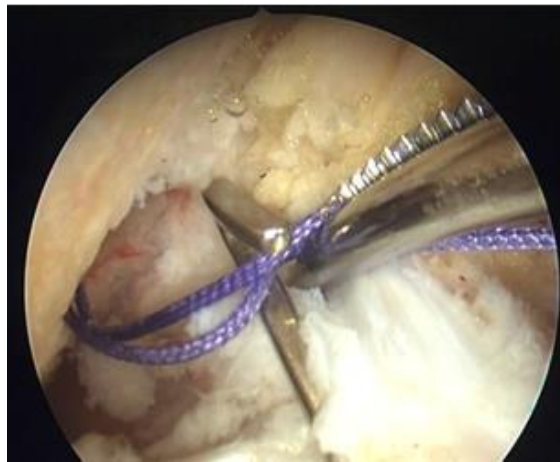

**Fig. 2.** Location of placement of posterolateral (A) and anteromedial (B) femoral tunnel in remnant preserving ACL reconstruction

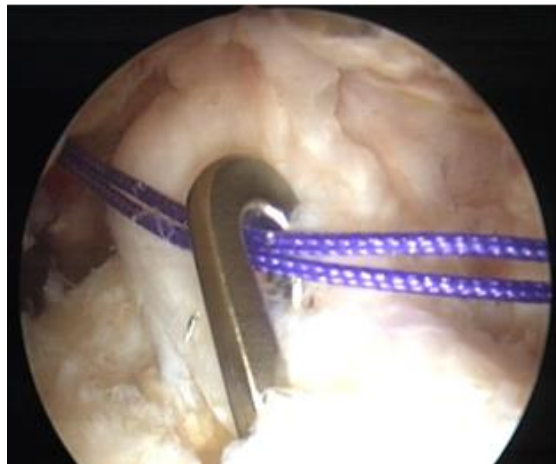
In complete rupture of ACL with existence of 2a, 2b, and 2c types of residual remnants, according to Kazusa classification<sup>[16]</sup> the femoral tunnel was placed in a position as in the reconstruction of anteromedial bundle of ACL. This position was also used in patients with standard single bundle ACL reconstruction. Drilling of femoral tunnels was done at 110 to 120 degrees of knee flexion. When making tibial tunnels, a special tibial guide was used. Non-absorbable suture was first inserted through both bony tunnels to pull the graft through the tunnels (Figure 3, 4, 5).



**Fig. 3.** Suture placement in the bony tunnels in remnant preserving ACL reconstruction with preservation of the posterolateral (Type Ia) residual bundle



**Fig. 4.** Suture placement in the bony tunnels in remnant preserving ACL reconstruction with preservation of the anteromedial (Type Ib) residual bundle



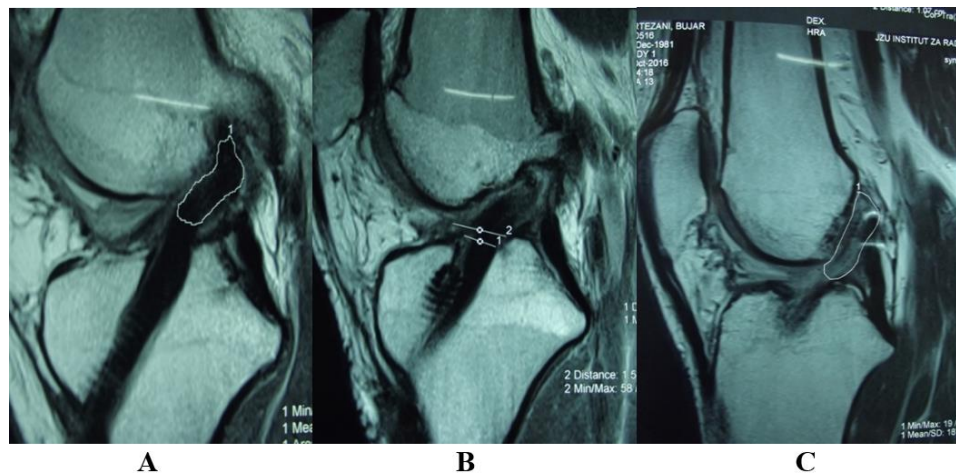
**Fig. 5.** Suture placement in the bony tunnels in remnant preserving ACL reconstruction with preservation of the residual bundle after complete proximal rupture and healing on the posterior cruciate ligament (Type IIa)

PRP was applied intraarticularly 7 to 10 days after surgery only in the examined group of patients.

Postoperative rehabilitation protocol: Patients wore knee brace in the first 3-4 weeks after surgery. Knee flexion more than 90 degrees and full weight bearing on the operated leg were allowed 4 weeks after ACL reconstruction.

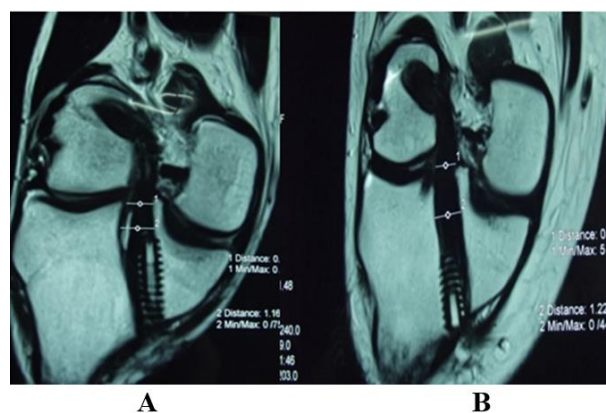
### Magnetic resonance imaging

Six months after ACL reconstruction, MRI was performed in all patients to assess graft healing. Graft healing was monitored on the intra-articular part to evaluate graft maturation and on the bone tunnel-graft interface to evaluate graft to bone tunnel healing. MRI (Siemens Avanto 1.5 T) evaluation was done in T2 sequence in the sagittal plane. Depending on the surface of the graft that had the same signal on MRI with posterior cruciate ligament (PCL), grafts were separated as grafts with a light hyperintense signal (more than 2/3 of the surface), grafts with a moderate hyperintense signal (between 1/3 and 2/3 of the surface) and grafts with a marked hyperintense signal (less than 1/3 of the surface) (Figure 6).



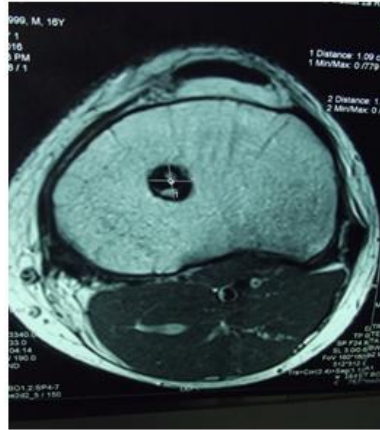
**Fig. 6.** Sagittal MRI view of the knee in T2 sequence showing grafts with light hyperintense (A), moderate hyperintense (B) and marked hyperintense signal (C)

Graft to bone tunnel healing was evaluated in T2 sequence in the sagittal and coronal plane of MRI. The presence of synovial fluid at tunnel – graft interface showed that graft-to-bone tunnel healing or integration was not finished (Figure 7).



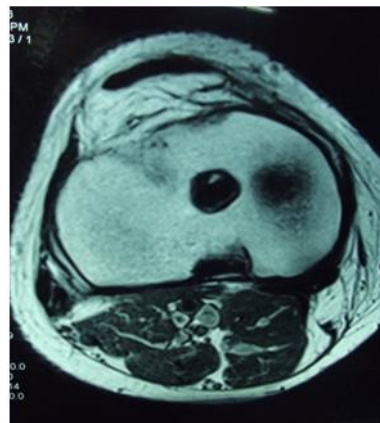
**Fig. 7.** Coronal MRI view of the knee in T2 sequence showing presence (A) and absence (B) of synovial fluid at tunnel-graft interface

To better evaluate graft-to-bone tunnel healing we determined the surface of bone edema around the graft and the percentage of sclerotic bone ring around the graft in tibia. The surface of bone edema around the graft was determined on axial MRI view using the formula  $(r_2^2 * \pi) - (r_1^2 * \pi)$ , where  $r_2$  was the radius of the circle of the bone edema around the graft and  $r_1$  was the radius of the circle around the graft (Figure 8).



**Fig. 8.** Axial MRI view of the knee in T2 sequence showing the surface of bone edema around the graft with  $r_2$  and  $r_1$  radius of the circles

The percentage of sclerotic bone ring around the graft was determined on axial MRI view perpendicular on the tibia tunnel axis where the percentage of sclerotic bone ring with thickness of more than 1 mm was determined (Figure 9).



**Fig. 9.** Axial MRI view of the knee perpendicular to the tibia tunnel axis in T2 sequence showing the sclerotic bone ring around the graft

### **Statistical Analysis**

For the statistical analysis, SPSS 12.0 software was used. Group comparison was performed with t test (Student's) determining a statistically significant difference between examined and control group and  $p < 0.05$  was considered statistically significant.

### **Results**

There were no significant demographic differences between patients from the two groups (Table 1).

**Table 1.** Demographic data of patients

Demographics	Control group (n=28)	Examined group (n=24)	p-value
<i>Sex n (%)</i>			
Male	23(82.14)	22(91.67)	<b>p=0.43</b>
Female	5(17.86)	2(8.33)	
Age (years)	26.96±6.6	28.67±8.5	<b>p=0.40</b>
Body mass index	26.01±3.6	25.09±3.7	<b>p=0.37</b>

### MRI evaluation

Regarding the *graft maturation*, MRI showed that 6 months after ACL reconstruction 53.85% of patients from both groups had a light hyperintense signal, 32.69% had a moderate hyperintense signal and 13.46% a marked hyperintense signal of the graft compared to the signal of PCL. This means that only in half of the patients 6 months after surgery the graft maturation was finished. The statistical analysis showed (Table 2) that patients in the examined group had significantly more frequently a light hyperintense signal of the graft than those from the control group (p=0.0046).

**Table 2.** MRI graft signal intensity distribution

MRI graft signal n (%)	Control group (n=28)	Examined group (n=24)	p-value
light hyperintense	10(35.71)	18(75)	p=0.0046
moderate hyperintense	12(42.86)	5(20.83)	p=0.091
marked hyperintense	6(21.43)	1(4.17)	p=0.1

Regarding the *graft-to-bone tunnel healing or integration*, MRI showed that 6 months after ACL reconstruction 67.31% of patients from both groups had presence of synovial fluid at tunnel-graft interface, which means that graft-to-bone tunnel healing or integration was not finished. The statistical analysis (Table 3) showed in the examined group of patients significantly more frequent absence of synovial fluid at tunnel-graft interface than in the control group (p=0.06).

**Table 3.** Incidence of synovial fluid appearance at tunnel-graft interface

MR detection of synovial fluid at tunnel-graft interface n (%)	Control group (n=28)	Examined group (n=24)	p-value
Yes	22(78.57)	13(54.17)	p=0.06
No	6(21.43)	11(45.83)	

For the *surface of bone edema around the graft* in tibia, the statistical analysis (Table 4) showed that the examined group had on average 0.98 cm<sup>2</sup> less surface of bone edema around the graft than the control group. This difference was statistically significant (p=0.009).

**Table 4.** Average surface of bone edema around the graft in tibia

Surface of bone edema around the graft in tibia (cm <sup>2</sup> )	Control group (n=28)	Examined group (n=24)	p-value
mean±SD	1.94±1.4	0.96±1.1	p=0.009

For the percentage of sclerotic bone ring around the graft determined on axial MRI view perpendicular on the tibia tunnel axis, the results (Table 5) showed that patients in the

examined group had a higher percentage of sclerotic bone ring around the graft than the control group, although this difference was not statistically significant ( $p=0.076$ ).

**Table 5.** Average percentage of formed cortical bone ring around the graft in tibia with thickness more than 1 mm

Sclerotic bone ring around the graft in tibia (%)	Control group (n=28)	Examined group (n=24)	p-value
mean±SD	67.68±19.2	76.67±15.9	p=0.076

## Discussion

Postoperative clinical results in patients with ACL reconstruction have not changed spectacularly in the last years. According to the literature, 83% of patients continue with sport activities after surgery, but only 63% come back to preinjury level of sport activity<sup>17</sup>. The period elapsed from ACL surgery to sport activities has remained unchanged in the last 30 years, ranging from 6 to 13 months<sup>2</sup>.

Biological augmentation of graft healing after ACL reconstruction using PRP administration has been investigated in the last 20 years. *In vitro* studies and animal trials confirmed the potential effect of PRP in stimulating tissue healing via increasing the expression of procollagen gene and collagen protein synthesis and reducing apoptosis and stimulating fibroblast metabolic activity<sup>9,18-22</sup>. In the animal model, it was observed that PRP was able to determine superior biomechanical properties such as higher tensile load and linear stiffness of the graft after ACL reconstruction<sup>7,23,24</sup>. Unfortunately, these positive results from the experimental studies were not confirmed in the available clinical studies which presented results that were more controversial in terms of biological efficacy of PRP on the reconstructed ACL. According to majority of studies,<sup>11,25-28</sup> PRP has no stimulating influence on graft integration in bony tunnels. Only studies by Vogrin *et al.*<sup>29</sup> and Ruprecht *et al.*<sup>30,31</sup> showed a significantly higher neovascularization at the graft-tunnel interface 4–6 weeks after PRP administration as well as reduced bone edema and increased cortical bone formation around the tibial tunnel wall at 6 months after ACL reconstruction and PRP administration. Regarding the graft maturation, several studies showed that PRP augmentation led to faster and better graft maturation at 4 to 12 months after ACL surgery<sup>25,32,33</sup>. Besides MRI evaluation, Sánchez *et al.* performed second-look arthroscopic and histological evaluations of the graft biopsies confirming the superior tissue quality in patients with ACL reconstruction and PRP administration<sup>34</sup>. Studies by Figueroa *et al.* and Nin *et al.* also presented better and faster graft maturation at MRI in the PRP augmented group, but with no statistical significance probably attributed to the low sample size included in these trials<sup>10,26</sup>. The study by Vogrin *et al.*<sup>29</sup> was the only one which did not show a positive effect of PRP on graft maturation after ACL reconstruction. Although ACL remnant preservation during ACL reconstruction should be very important because of its biomechanical, vascular, proprioceptive and protective function, its actual effectiveness according to the studies is still controversial<sup>14,35</sup>. Biological augmentation of graft healing using ACL remnant preservation and its synovial sheet should be expected because we partially preserve blood vessels that are very important for graft revascularization and incorporation. However, this has been confirmed only in the experimental studies by Wu<sup>36</sup>, Li<sup>37</sup> and Mifune<sup>13</sup>, and it is still not clearly supported by clinical findings. Gohil *et al.* showed that signal intensity at MRI was higher in ACL remnant preserving group, supporting the idea that the revascularization process occurred earlier in the remnant preserving group<sup>15</sup>. Several studies showed that second-look arthroscopy demonstrated better synovial coverage of the graft in ACL remnant preserving group<sup>38-41</sup>. Unfortunately,

this method of evaluation sometimes could be too subjective and the best method of evaluation is graft biopsy and histological examination of the healing process, which is too complicated mainly due to ethical reasons. Although there are no prospective studies investigating the role of ACL remnant in preventing synovial fluid leakage into the tibial tunnel due to the adhesions between graft and remnant, this influence should be taken as very important for biological augmentation of graft healing because of the reduced osteoclasts activity, impaired graft-to-bone tunnel healing and tunnel widening after ACL reconstruction. Several studies showed that remnant preservation in ACL reconstruction decreased the percentage of tibial tunnel enlargement<sup>[5,42,43]</sup>.

In our study, we combined PRP and ACL remnant preservation as a two-biologic therapy in order to investigate if they can obtain a synergistic effect, accelerate graft healing process and obtain better clinical results in patients with ACL reconstruction.

In the examined group we included all patients with ACL residual remnants after partial and complete ACL rupture and healing of its proximal part on the non-anatomic site but with diameter of the remnant greater than 1/3 of that of normal ACL measured with an arthroscopic probe. Analysis showed that 83% of patients had residual remnant after complete ACL rupture and 17% after partial ACL rupture.

We did the intra-articular PRP application in the knee joint 7 to 10 days after ACL surgery. It is our opinion that immediate application of PRP inside the knee joint during ACL surgery as in the previous studies is not rational because this surgery produces pronounced joint bleeding; surgeons put drains to take blood out and thus PRP is washed out from the knee joint.

In our study, graft healing after ACL reconstruction was evaluated using MRI 6 months after surgery. We chose this time interval because most surgeons consider 6 months as a cut-off value for allowing sport resumption after ACL reconstruction. From the biological point of view, the intra-articular graft undergoes a maturation and remodeling process in 3 phases: initial avascular necrosis and inflammation, revascularization and cellular proliferation, and final remodeling phase<sup>[46]</sup>. From the histological point of view, hyperintense graft signal is correlated to the presence of new hypervascular and hypercellular reparative tissue which means that the graft is weak and not matured<sup>[47]</sup>. Taking into consideration that in half of the patients in our study we found a moderate and marked hyperintense graft signal, the conclusion is that 6 months after ACL surgery the intra-articular graft was still not matured and was still weak. A statistically significantly higher percentage ( $p=0.0046$ ) of patients in the examined group showed a light hyperintense graft signal, which confirmed that PRP and ACL residual remnant preservation had a positive influence on intra-articular graft maturation. This is in accordance with the previous published studies. According to some studies<sup>[48,49]</sup>, graft integration in the bony tunnels should be finished in the first 3 months after ACL surgery. However, our results determining synovial fluid at tunnel-graft interface in 67.31% of patients from both groups showed that this process has not still been completely finished even after 6 months from surgery. Patients in the examined group had less ( $p=0.06$ ) presence of synovial fluid at tunnel-graft interface, less ( $p=0.009$ ) surface of bone edema around the graft and higher percentage ( $p=0.076$ ) of sclerotic bone ring formation around the tibial tunnel wall than those in the control group like in the studies by Ruprecht *et al.*<sup>[30,31]</sup> and Vogrin *et al.*<sup>[29]</sup>. Our opinion is that stimulated neovascularization at the graft-tunnel interface by PRP and reduced inflammatory cytokines catabolic activity at the graft-tunnel interface due to reduced synovial fluid leakage because of ACL residual remnant preservation are the main reasons for these results.

Our study has some weaknesses. First of all, the study included patients with different types of ACL residual remnants, which has to be taken into consideration because

some of them could give better biological stimulation than others. Secondly, we made only one MRI investigation at only one single time point 6 months after ACL surgery. More MRI investigations at different time points could give us more information about the dynamics of graft maturation and graft osseointegration. Thirdly, we did not make contrast enhanced MRI determining signal noise quotient to get quantitative results. Finally, we did not make quantification of platelet concentration and quantification and typing of growth factors to determine the optimal concentration of platelets and growth factors for biological augmentation after ACL reconstruction. We still believe that the best method for evaluation of graft healing after ACL reconstruction is graft biopsy and histological examination, which would be too complicated in the future mainly due to ethical reasons.

### **Conclusion**

Our study showed that a combined use of PRP and ACL remnant preservation had a positive influence on graft healing processes after ACL reconstruction leading to faster maturation and osteoligamentous integration of the graft. This opens the possibility to combine these two therapies in order to obtain a synergistic effect, accelerate graft healing process and obtain better clinical results in patients with ACL reconstruction. More prospective high-quality studies in the future are necessary in order to investigate whether this combined treatment can give better results than treatment with PRP or ACL residual remnant preservation alone.

*Conflict of interest statement.* None declared.

### **References**

1. Cameron M, Buchgraber A, Passler H, Vogt M, Thonar E, Fu F, *et al.* The natural history of the anterior cruciate ligament-deficient knee. Changes in synovial fluid cytokine and keratan sulfate concentrations. *Am J Sports Med* 1997; 25(6): 751-754. doi: 10.1177/036354659702500605.
2. Ardern CL, Webster KE, Taylor NF, Feller JA. Return to sport following anterior cruciate ligament reconstruction surgery: a systematic review and meta-analysis of the state of play. *Br J Sports Med* 2011; 45(7): 596-606. doi: 10.1136/bjism.2010.076364.
3. da Silveira Franciozi CE, Ingham SJ, Gracitelli GC, Luzo MV, Fu FH, Abdalla RJ. Updates in biological therapies for knee injuries: anterior cruciate ligament. *Curr Rev Musculoskelet Med* 2014; 7(3): 228-238. doi: 10.1007/s12178-014-9228-9.
4. Junkin DM Jr, Johnson DL. ACL tibial remnant, to save or not? *Orthopedics* 2008; 31(2): 154-159. doi: 10.3928/01477447-20080201-13.
5. Tie K, Chen L, Hu D, Wang H. The difference in clinical outcome of single-bundle anterior cruciate ligament reconstructions with and without remnant preservation: A meta-analysis. *Knee* 2016; 23(4): 566-574. doi: 10.1016/j.knee.2015.07.010.
6. Graziani F, Ivanovski S, Cei S, Ducci F, Tonetti M, Gabriele M. The in vitro effect of different PRP concentrations on osteoblasts and fibroblasts. *Clin Oral Implants Res* 2006; 17(2): 212-219. doi: 10.1111/j.1600-0501.2005.01203.x.
7. Murray MM, Spindler KP, Devin C, Snyder BS, Muller J, Takahashi M, *et al.* Use of a collagen-platelet rich plasma scaffold to stimulate healing of a central defect in the canine ACL. *J Orthop Res* 2006; 24(4): 820-830. doi: 10.1002/jor.20073.
8. Le ADK, Enweze L, DeBaun MR, Dragoo JL. Current Clinical Recommendations for Use of Platelet-Rich Plasma. *Curr Rev Musculoskelet Med* 2018; 11(4): 624-634. doi: 10.1007/s12178-018-9527-7.

9. Fallouh L, Nakagawa K, Sasho T, Arai M, Kitahara S, Wada Y, Moriya H, Takahashi K. Effects of autologous platelet-rich plasma on cell viability and collagen synthesis in injured human anterior cruciate ligament. *J Bone Joint Surg Am* 2010; 92(18): 2909-2916. doi: 10.2106/JBJS.I.01158.
10. Nin JR, Gasque GM, Azcárate AV, Beola JD, Gonzalez MH. Has platelet-rich plasma any role in anterior cruciate ligament allograft healing? *Arthroscopy* 2009; 25(11): 1206-1213. doi: 10.1016/j.arthro.2009.06.002.
11. Silva A, Sampaio R. Anatomic ACL reconstruction: does the platelet-rich plasma accelerate tendon healing? *Knee Surg Sports Traumatol Arthrosc* 2009; 17(6): 676-682. doi: 10.1007/s00167-009-0762-8.
12. Andriolo L, Di Matteo B, Kon E, Filardo G, Venieri G, Marcacci M. PRP Augmentation for ACL Reconstruction. *Biomed Res Int* 2015; 2015: 371746. doi: 10.1155/2015/371746.
13. Mifune Y, Ota S, Takayama K, Hoshino Y, Matsumoto T, Kuroda R, et al. Therapeutic advantage in selective ligament augmentation for partial tears of the anterior cruciate ligament: results in an animal model. *Am J Sports Med* 2013; 41(2): 365-373. doi: 10.1177/0363546512471614.
14. Muneta T, Koga H. Anterior cruciate ligament remnant and its values for preservation. *Asia Pac J Sports Med Arthrosc Rehabil Technol* 2016; 7: 1-9. doi: 10.1016/j.asmart.2016.09.002.
15. Gohil S, Annear PO, Breidahl W. Anterior cruciate ligament reconstruction using autologous double hamstrings: a comparison of standard versus minimal debridement techniques using MRI to assess revascularisation. A randomised prospective study with a one-year follow-up. *J Bone Joint Surg Br* 2007; 89(9): 1165-1171. doi: 10.1302/0301-620X.89B9.19339.
16. Kazusa H, Nakamae A, Ochi M. Augmentation technique for anterior cruciate ligament injury. *Clin Sports Med* 2013; 32(1): 127-140. doi: 10.1016/j.csm.2012.08.012.
17. Lai CCH, Ardern CL, Feller JA, Webster KE. Eighty-three per cent of elite athletes return to preinjury sport after anterior cruciate ligament reconstruction: a systematic review with meta-analysis of return to sport rates, graft rupture rates and performance outcomes. *Br J Sports Med* 2018; 52(2): 128-138. doi: 10.1136/bjsports-2016-096836.
18. Yoshida R, Cheng M, Murray MM. Increasing platelet concentration in platelet-rich plasma inhibits anterior cruciate ligament cell function in three-dimensional culture. *J Orthop Res* 2014; 32(2): 291-295. doi: 10.1002/jor.22493.
19. Yoshida R, Murray MM. Peripheral blood mononuclear cells enhance the anabolic effects of platelet-rich plasma on anterior cruciate ligament fibroblasts. *J Orthop Res* 2013; 31(1): 29-34. doi: 10.1002/jor.22183.
20. Cheng M, Johnson VM, Murray MM. Effects of age and platelet-rich plasma on ACL cell viability and collagen gene expression. *J Orthop Res* 2012; 30(1): 79-85. doi: 10.1002/jor.21496.
21. Mastrangelo AN, Magarian EM, Palmer MP, Vavken P, Murray MM. The effect of skeletal maturity on the regenerative function of intrinsic ACL cells. *J Orthop Res* 2010; 28(5): 644-651. doi: 10.1002/jor.21018.
22. Scherping SC Jr, Schmidt CC, Georgescu HI, Kwok CK, Evans CH, Woo SL. Effect of growth factors on the proliferation of ligament fibroblasts from skeletally mature rabbits. *Connect Tissue Res* 1997; 36(1): 1-8. doi: 10.3109/03008209709160209.

23. Joshi SM, Mastrangelo AN, Magarian EM, Fleming BC, Murray MM. Collagen-platelet composite enhances biomechanical and histologic healing of the porcine anterior cruciate ligament. *Am J Sports Med* 2009; 37(12): 2401-2410. doi: 10.1177/0363546509339915.
24. Weiler A, Förster C, Hunt P, Falk R, Jung T, Unterhauser FN, et al. The influence of locally applied platelet-derived growth factor-BB on free tendon graft remodeling after anterior cruciate ligament reconstruction. *Am J Sports Med* 2004; 32(4): 881-891. doi: 10.1177/0363546503261711.
25. Orrego M, Larrain C, Rosales J, Valenzuela L, Matas J, Durruty J, et al. Effects of platelet concentrate and a bone plug on the healing of hamstring tendons in a bone tunnel. *Arthroscopy* 2008; 24(12): 1373-1380. doi: 10.1016/j.arthro.2008.07.016.
26. Figueroa D, Melean P, Calvo R, Vaisman A, Zilleruelo N, Figueroa F, et al. Magnetic resonance imaging evaluation of the integration and maturation of semitendinosus-gracilis graft in anterior cruciate ligament reconstruction using autologous platelet concentrate. *Arthroscopy* 2010; 26(10): 1318-1325. doi: 10.1016/j.arthro.2010.02.010.
27. Mirzatooleei F, Alamdari MT, Khalkhali HR. The impact of platelet-rich plasma on the prevention of tunnel widening in anterior cruciate ligament reconstruction using quadrupled autologous hamstring tendon: a randomised clinical trial. *Bone Joint J* 2013; 95-B(1): 65-69. doi: 10.1302/0301-620X.95B1.30487.
28. Vadalà A, Iorio R, De Carli A, Ferretti M, Paravani D, Caperna L, et al. Platelet-rich plasma: does it help reduce tunnel widening after ACL reconstruction? *Knee Surg Sports Traumatol Arthrosc* 2013; 21(4): 824-829. doi: 10.1007/s00167-012-1980-z.
29. Vogrin M, Ruprecht M, Dinevski D, Hašpl M, Kuhta M, Jevsek M, et al. Effects of a platelet gel on early graft revascularization after anterior cruciate ligament reconstruction: a prospective, randomized, double-blind, clinical trial. *Eur Surg Res* 2010; 45(2): 77-85. doi: 10.1159/000318597.
30. Ruprecht M, Vogrin M, Hussein M. MRI evaluation of tibial tunnel wall cortical bone formation after platelet-rich plasma applied during anterior cruciate ligament reconstruction. *Radiol Oncol* 2013; 47(2): 119-124. doi: 10.2478/raon-2013-0009.
31. Ruprecht M, Jevtič V, Serša I, Vogrin M, Jevšek M. Evaluation of the tibial tunnel after intraoperatively administered platelet-rich plasma gel during anterior cruciate ligament reconstruction using diffusion weighted and dynamic contrast-enhanced MRI. *J Magn Reson Imaging*. 2013; 37(4): 928-935. doi: 10.1002/jmri.23886.
32. Radice F, Yánez R, Gutiérrez V, Rosales J, Pinedo M, Coda S. Comparison of magnetic resonance imaging findings in anterior cruciate ligament grafts with and without autologous platelet-derived growth factors. *Arthroscopy* 2010; 26(1): 50-57. doi: 10.1016/j.arthro.2009.06.030.
33. Seijas R, Ares O, Catala J, Alvarez-Diaz P, Cusco X, Cugat R. Magnetic resonance imaging evaluation of patellar tendon graft remodelling after anterior cruciate ligament reconstruction with or without platelet-rich plasma. *J Orthop Surg (Hong Kong)* 2013; 21(1): 10-14. doi: 10.1177/230949901302100105.
34. Sánchez M, Anitua E, Azofra J, Prado R, Muruzabal F, Andia I. Ligamentization of tendon grafts treated with an endogenous preparation rich in growth factors: gross morphology and histology. *Arthroscopy* 2010; 26(4): 470-480. doi: 10.1016/j.arthro.2009.08.019.
35. Papalia R, Franceschi F, Vasta S, Di Martino A, Maffulli N, Denaro V. Sparing the anterior cruciate ligament remnant: is it worth the hassle? *Br Med Bull* 2012; 104: 91-111. doi: 10.1093/bmb/ldr053.

36. Wu B, Zhao Z, Li S, Sun L. Preservation of remnant attachment improves graft healing in a rabbit model of anterior cruciate ligament reconstruction. *Arthroscopy* 2013; 29(8): 1362-71. doi: 10.1016/j.arthro.2013.05.010.
37. Li Z, Liu Y, Shi B, Wu X, Zhu J, Wang Z, Li Z. [An experimental study on anterior cruciate ligament reconstruction with remnants and remaining bundle preservation]. *Zhongguo Xiu Fu Chong Jian Wai Ke Za Zhi* 2009; 23(3): 282-286. PMID: 19366134.
38. Ohsawa T, Kimura M, Kobayashi Y, Hagiwara K, Yorifuji H, Takagishi K. Arthroscopic evaluation of preserved ligament remnant after selective anteromedial or posterolateral bundle anterior cruciate ligament reconstruction. *Arthroscopy* 2012; 28(6): 807-817. doi: 10.1016/j.arthro.2011.11.033.
39. Ahn JH, Wang JH, Lee YS, Kim JG, Kang JH, Koh KH. Anterior cruciate ligament reconstruction using remnant preservation and a femoral tensioning technique: clinical and magnetic resonance imaging results. *Arthroscopy* 2011; 27(8): 1079-1089. doi: 10.1016/j.arthro.2011.03.002.
40. Guo L, Yang L, Duan XJ, Xu Q, Chen JR, Chen GX, et al. Second-look arthroscopy study after anterior cruciate ligament reconstruction: effect of residual anterior cruciate ligament tissue upon accelerating revascularization of allogeneic bone-patellar tendon-bone grafting. *Zhonghua Yi Xue Za Zhi* 2009; 89(29): 2030-2033. PMID: 20017323.
41. Noh JH, Kyung HS, Roh YH, Kang TS. Remnant-preserving and re-tensioning technique to cover the graft in anterior cruciate ligament reconstruction. *Knee Surg Sports Traumatol Arthrosc* 2017; 25(4): 1205-1210. doi: 10.1007/s00167-015-3854-7.
42. Demirağ B, Ermutlu C, Aydemir F, Durak K. A comparison of clinical outcome of augmentation and standard reconstruction techniques for partial anterior cruciate ligament tears. *Eklem Hastalik Cerrahisi* 2012; 23(3): 140-144. PMID: 23145756.
43. Zhang Q, Zhang S, Cao X, Liu L, Liu Y, Li R. The effect of remnant preservation on tibial tunnel enlargement in ACL reconstruction with hamstring autograft: a prospective randomized controlled trial. *Knee Surg Sports Traumatol Arthrosc* 2014; 22(1): 166-173. doi: 10.1007/s00167-012-2341-7.
44. Ahn JH, Lee SH, Choi SH, Lim TK. Magnetic resonance imaging evaluation of anterior cruciate ligament reconstruction using quadrupled hamstring tendon autografts: comparison of remnant bundle preservation and standard technique. *Am J Sports Med* 2010; 38(9): 1768-1777. doi: 10.1177/0363546510368132.
45. Wilson TC, Kantaras A, Atay A, Johnson DL. Tunnel enlargement after anterior cruciate ligament surgery. *Am J Sports Med* 2004; 32(2): 543-549. doi: 10.1177/0363546504263151.
46. Janssen RP, Scheffler SU. Intra-articular remodelling of hamstring tendon grafts after anterior cruciate ligament reconstruction. *Knee Surg Sports Traumatol Arthrosc* 2014; 22(9): 2102-2108. doi: 10.1007/s00167-013-2634-5.
47. Gnannt R, Chhabra A, Theodoropoulos JS, Hodler J, Andreisek G. MR imaging of the postoperative knee. *J Magn Reson Imaging* 2011; 34(5): 1007-1021. doi: 10.1002/jmri.22672.
48. Ekdahl M, Wang JH, Ronga M, Fu FH. Graft healing in anterior cruciate ligament reconstruction. *Knee Surg Sports Traumatol Arthrosc* 2008; 16(10): 935-947. doi: 10.1007/s00167-008-0584-0.
49. Deehan DJ, Cawston TE. The biology of integration of the anterior cruciate ligament. *J Bone Joint Surg Br* 2005; 87(7): 889-895. doi: 10.1302/0301-620X.87B7.16038.