

CLINICAL AND EXPERIMENTAL OBSTETRICS & GYNECOLOGY

an International Journal

Founding Editor

A. Onnis

Montréal (CND)

Editors-in-Chief

M. Marchetti

Montréal (CND)

J.H. Check

Camden, NJ (USA)

Assistant Editor

A. Sinopoli

Toronto (CND)

Editorial Board

Audet-Lapointe P., *Montréal (Canada)*

Axt-Flidner R., *Lübeck (Germany)*

Basta A., *Krakow (Poland)*

Bender H.J., *Dusseldorf (Germany)*

Bhattacharya N., *Calcutta (India)*

Bonilla Musoles F., *Valencia (Spain)*

Cabero-Roura L., *Barcelona (Spain)*

Charkviani T., *Tbilisi (Georgia)*

Dexeus S., *Barcelona (Spain)*

Di Paola G., *Buenos Aires (Argentina)*

Eskes T.K.A.B.,
Nijmegen (The Netherlands)

Farghaly S.A., *New York (USA)*

Friedrich M., *Homburg (Germany)*

Gomel V., *Vancouver (Canada)*

Gorins A., *Paris (France)*

Grella P.V., *Padua (Italy)*

Holub Z., *Kladno (Czech Republic)*

Kaplan B., *Petach Tikva (Israel)*

Markowska J., *Poznan (Poland)*

Marth C., *Innsbruck (Austria)*

Meden-Vrtovec H., *Ljubljana (Slovenia)*

Murta E.F.C., *Uberaba (Brazil)*

Papadopoulos N., *Alexandroupolis (Greece)*

Rakar S., *Ljubljana (Slovenia)*

Rigó J., *Budapest (Hungary)*

Sciarra J.J., *Chicago (USA)*

Stelmachow J., *Warsaw (Poland)*

Varras M.N., *Athens (Greece)*

Winter R., *Graz (Austria)*

7847050 CANADA, Inc.

Administrative Office (M. Beaucage):

4900 Côte St-Luc, Apt #212 – Montréal, Québec, H3W 2H3 (Canada)

Tel. +1-514-4893242 – Fax +1-514-4854513 – e-mail: canlux@mgroup-online.com

Website: www.irog.net

Editorial Office (M. Critelli):

Via Martiri della Libertà, 9, 35137 Padua (Italy)

Tel. +39-049-656521 – Fax +39-049-8752018 – e-mail: irog.canada@gmail.com

CLINICAL AND EXPERIMENTAL OBSTETRICS & GYNECOLOGY – CEOG (ISSN 0390-6663) publishes original work, preferably brief reports, in the fields of Gynecology, Obstetrics, Fetal Medicine, Gynecological Endocrinology and related subjects, (Fertility and Sterility, Menopause, Uro-gynecology, Ultrasound in Obstetrics and Gynecology, Sexually Transmitted Diseases, and Reproductive Biological Section). The Journal is covered by ISI Journal Master List, Index Copernicus International, Science Citation Index Expanded, Current Contents - Clinical Medicine, Web of Science, Index Medicus/MEDLINE, EMBASE Excerpta Medica, PubMed, MedSci, Pubget, Genamics JournalSeek, Sciencscape, Unbound Medicine, and PubFacts.com. **CEOG** is issued bimonthly in one volume per year by 7847050 CANADA Inc., Montréal (Canada).

Printed in Italy by "Centro Servizi Editoriali S.r.l." - Grisignano di Zocco - 36040 Vicenza (Italy).

ORIGINAL ARTICLES

Reproductive Biology Section

- Mid-luteal phase injection of subcutaneous leuprolide acetate improves live delivered pregnancy and implantation rates in younger women undergoing in vitro fertilization-embryo transfer (IVF-ET)** 173
 J.H. Check, C. Wilson, J.K. Choe - *Camden, NJ, USA*
 The injection of leuprolide acetate three days after embryo transfer resulted in a non-significant trend for higher pregnancy rates.
- Correlation of ImmunoBead® and ImmunoSphere™ Immunoglobulin G (IGG) tests on detecting antisperm antibody (ASA) on sperm** 175
 A. Bollendorf, J.H. Check - *Mt. Laurel, NJ, USA*
 Detecting antibody on sperm using immunospheres seems to be an accurate test which compares well with the direct immunobead assay.
- The use of granulocyte colony stimulating factor to enhance oocyte release in women with the luteinized unruptured follicle syndrome** 178
 J.H. Check, J. Vaniver, D. Senft, G. DiAntonio, D. Summers - *Mt. Laurel, NJ, USA*
 A single injection of granulocyte colony stimulating factor may enable oocyte release in women with luteinized unruptured follicle syndrome.
- In vitro fertilization (IVF) outcome in women in overt menopause attempting to induce follicular maturation by follicle stimulating hormone (FSH) receptor down-regulation** 181
 J.H. Check, C. Wilson, G. DiAntonio, A. DiAntonio - *Mt. Laurel, NJ, USA*
 Induction of ovulation by restoring down-regulated follicle stimulating hormone (FSH) receptors can result in a 10% live delivered pregnancy rate per retrieval.
- The effect of clomiphene citrate vs. letrozole on post-coital tests** 184
 J.H. Check, J.R. Liss, J. Vaniver - *Mt. Laurel, NJ, USA*
 Despite its shorter half-life, letrozole was at least as likely to adversely effect cervical mucus compared to clomiphene citrate.
- Failed fertilization with conventional oocyte insemination can be overcome with the ability of ICSI according to binding or failing to bind to the zona pellucida** 186
 J.H. Check, A. Bollendorf, C. Wilson - *Mt. Laurel, NJ, USA*
 The presence of sperm binding to the zona pellucida despite failed fertilization negatively correlates with fertilization with subsequent intracytoplasmic sperm injection.
- The progesterone receptor antagonist mifepristone does not lower serum progesterone induced blocking factor (PIBF) in the presence of progesterone** 189
 J.H. Check, G. DiAntonio, A. DiAntonio, M. Duroseau - *Mt. Laurel, NJ, USA*
 The selective progesterone receptor modulator mifepristone does not seem to cause abortions by decreasing serum progesterone induced blocking factor (PIBF).

General Section

- The relationship between the daily step counts and low back pain during pregnancy** 192
 S. Morino, Y. Kajiwara, M. Ishihara, S. Nishiguchi, N. Fukutani, Y. Tashiro, M. Yamada, M. Yamashita, T. Aoyama - *Kyoto, JAPAN*
 Acute increase of daily step counts in early pregnancy is a risk for pregnancy-related low back pain.
- Safety, efficacy, and tolerability of differential treatment to prevent and treat vaginal dryness and vulvovaginitis in diabetic women** 198
 D. Carati, A. Zizza, M. Guido, A. De Donno, R. Stefanizzi, R. Serra, I. Romano, C. Ouedraogo, M. Megha, A. Tinelli - *Lecce, ITALY*
 The efficacy and safety of three gynecological treatments in diabetic women was assessed.
- Is urinary incontinence during and after pregnancy related to family history? A web-based survey among postpartum women (motherfit project)** 203
 P. Albers-Heitner, L. Bekkers, H. Moosdorff, B. Berghmans, P. Verdonk - *Maastricht, THE NETHERLANDS*
 A family history of urinary incontinence is associated with urinary incontinence during pregnancy.
- Complete longitudinal vaginal septum resection. Description of a bloodless new technique** 209
 I. Chatzipapas, D. Zacharakis, L. Michala, T. Grigoriadis, P. Antsaklis, A. Protopapas - *Athens, GREECE*
 Bipolar cutting forceps as a novel approach for longitudinal vaginal septum resulted in an effective and safe technique.
- Comparing maternal and perinatal outcomes in pregnancies complicated by preeclampsia superimposed chronic hypertension and preeclampsia alone** 212
 W.S. Hu, Y. Feng, M.Y. Dong, J. He - *Hangzhou, CHINA*
 Preeclampsia with chronic hypertension and preeclampsia alone are compared in relation to maternal and perinatal outcomes.
- Unilateral sacrospinous ligament fixation (USLF) with a mesh stabilizing anchor set: clinical outcome and impact on quality of life** 216
 M.U. Karacaoglu, E.S. Ozyurek, S. Mutlu, E. Odacilar - *Istanbul, TURKEY*
 Better quality of life and clinical outcome are obtained with sacrospinous ligament fixation with mesh stabilizing anchor set than with traditional methods.
- Correlation of the system of cytokines in moderate and severe preeclampsia** 220
 A. Markova Daneva, M. Hadži-Lega, M. Stefanovic - *Skopje, REPUBLIC OF MACEDONIA*
 The assessment of cytokine profile in the monitoring of pregnancy complicated by preeclampsia is recommended.
- Effects of piroxicam administration on pregnancy outcome in intrauterine insemination (IUI) cycles: a randomized clinical trial** 225
 A. Zarei, M. Mahboubi, M.E. Parsanezhad, S. Alborzi, M. Younesi, G. Madadi - *Shiraz, IRAN*
 A favorable effect of piroxicam on increasing pregnancy rate after intrauterine insemination (IUI) was found.
- Efficiency of GnRH analogues in treating large functional ovarian cysts** 230
 S. Zervoudis, G. Iatrakis, E. Tomara, A. Bothou, P. Peitsidis, G. Mastorakos - *Athens, GREECE*
 The treatment of functional large cysts through a single dose of GnRH analogue is proposed.
- In vitro fertilization outcomes in obese women under and above 35 years of age** 233
 F. Vural, B. Vural, Y. Çakiroglu - *Kocaeli, TURKEY*
 Age is the factor that influences the outcome of in vitro fertilization.
- Feasibility of prophylactic laparoscopic appendectomy in obese patients** 238
 H. Wang, C. Lu, J. Zhao, L. Gao, X. Li, J. Hou, A. Zhou - *Shijiazhang, CHINA*
 For obese patients, prophylactic appendectomy during gynecological surgery is favourable to avoid further operation.
- The early pregnancy volume measurements in predicting pregnancy outcome** 241
 G. Batmaz, A. Aksoy, S. Aydin, P. Ozcan, C. Dane, B. Dane - *Istanbul, TURKEY*
 The variables in determining pregnancy outcomes were evaluated.

Early fetal heart ultrasonography as additional indicator for chromosomopathies	245
A. Dmitrovic, K. Jeremic, U.M. Babic, M. Perovic, T. Mihailovic, D. Opric, N. Zečević, M. Gojnić-Dugalić - <i>Belgrade, SERBIA</i>	
The use of ultrasonography in the first trimester of pregnancy, as an additional indicator for chromosomopathies, is evaluated.	
Analysis of rectal injuries resulting from laparoscopic peritoneal vaginoplasty (Luohu operation)	250
A. Le, Z. Wang, L. Shan, T. Xiao, G. Luo, Y. Shen - <i>Shenzhen, CHINA</i>	
The management of rectal injuries caused by laparoscopic vaginoplasty is discussed.	
-1195 A/G promoter variants of the cyclooxygenase-2 gene increases the risk of pain occurrence in endometriotic women	254
H. Wang, L. Sun, M. Jiang, L. Liu, G. Wang - <i>Dalian, CHINA</i>	
The association of -1995 A/G polymorphism in cyclooxygenase-2 gene and pain caused by endometriosis were evaluated.	
Evaluation of female athlete triad and gynaecological complaints in young Turkish female athletes	258
P. Solmaz Hasdemir, O. Oral, E. Calik, M. Ulusoy, R. Varol, H. Tayfun Ozcakir - <i>Manisa, TURKEY</i>	
The female athlete triad and its relationship with gynecologic complaints were examined and age of menarche was found to be delayed in athletes with low BMI.	
CASE REPORTS	
Cesarean delivery via a transverse uterine fundal incision for the successful management of a low-lying placenta and aplastic anemia	262
S. Matsuzaki, K. Yoshino, K. Mimura, T. Kanagawa, T. Kimura - <i>Osaka, JAPAN</i>	
A case of the successful management of a low-lying placenta and aplastic anemia is reported.	
Ganglioneuroblastoma during pregnancy – A rare case report	265
M.A. Moga, A. Daniilidis, N.F. Bigiu, C. Andrei, K. Dinas, D.G. Festila - <i>Brasov, ROMANIA</i>	
A multidisciplinary approach was considered in a rare case of ganglioneuroblastoma in pregnancy.	
Umbilical intra-abdominal vein varix: a case report and review of the literature	268
G. Virdis, A. Gulotta, C. Cherchi, G. Spanedda, M.G. Olzai, G. Ambrosini, S. Dessole, G. Capobianco - <i>Sassari, ITALY</i>	
Isolated umbilical intra-abdominal vein varix should be managed by ultrasound and cardiotocographic close monitoring.	
Rectovaginal fistula caused by retained colpotomy cup after surgery	271
Y.S. Kwon, S. Ki You, K. Shil Im, A. Suk Kim - <i>Ulsan, KOREA</i>	
The case of a forgotten colpotomy cup in vagina after laparoscopic surgery, causing a rectovaginal fistula, is described.	
Peripartum cardiomyopathy: a case of patient with triplet pregnancy	274
B. Kastratović Kotlica, A. Četković, S. Plešinac, Đ. Macut, M. Ašanin - <i>Belgrade, SERBIA</i>	
Management and outcome of a case of peripartum cardiomyopathy are reported.	
Chronic renal failure, diabetes mellitus type-II, and gestation: an overwhelming combination	276
E.N. Kontomanolis, S. Panagoutsos, P. Pasadakis, Z. Koukouli, A. Liberis- <i>Alexandroupolis, GREECE</i>	
Treatment of a patient with chronic renal failure and diabetes mellitus type-II during gestation is highlighted.	
Prenatal diagnosis of Binder's syndrome: report of two cases	279
S. Mutlló Cantarell, L. Serra Azuara, S. Pina Pérez, J. Lleberia Juanos, F. Mellado Navarro, M. Corona Martínez - <i>Barcelona, SPAIN</i>	
Two rare cases of Binder's syndrome are discussed.	

- Idiopathic massive fetomaternal haemorrhage in the third trimester of pregnancy causing neonatal death** 284
X. Peng, C. Liu, B. Peng - *Chengdu, CHINA*
The management of two cases of idiopathic fetomaternal haemorrhage is discussed.
- A rare occurrence of three consecutive autosomal trisomic pregnancies in a couple without offspring** 287
F. Burada, S. Sosoi, D. Iliescu, M. Ioana, D. Cernea, S. Tudorache - *Craiova, ROMANIA*
The management of a cases with three consecutive autosomal trisomies is discussed.
- Successful conservative treatment of a cervical ectopic pregnancy at 13 weeks** 291
S. Kadija, A. Stefanovic, K. Jeremic, M. Radojevic, R. Cerovic-Popovic, M. Srbinovic, I. Likic-Ladjevic - *Belgrade, SERBIA*
The treatment of a case of cervical ectopic pregnancy is presented.
- Abdominal lithopedion formation with 30 years of evolution: report of a case** 294
Yali Yang, Hong Zhou, Jin Guo, Wei Su, Hong Shen - *Kunming, CHINA*
A case of lithopedion in a 60-year-old woman is reported.
- A rare complication of colporrhaphy anterior procedure: vesicovaginal fistula due to foreign body** 297
O. Birge, D. Arslan, E. Kinali, C. Karaca - *Nyala, SUDAN*
A case of vesicovaginal fistula as a result of in-site foreign body after vaginal surgery is reported.
- Successful management of recurrent pregnancy-related thrombotic thrombocytopenia purpura: case report and review** 300
H. Chen, L. Luo, J. Cai, Y. Wu, B. Liu, Z. Wang - *Guangzhou, CHINA*
Prompt and proper management of recurrent pregnancy-associated thrombotic thrombocytopenia purpura allows a favorable outcome for the patient and newborn.
- Uterine rupture in pregnancy: two case reports and review of literature** 304
A. Pontis, C. Prasciolu, P. Litta, S. Angioni - *Cagliari, ITALY*
Uterine rupture should be considered in the differential diagnosis of all pregnant women who present acute abdomen and have specific risk factors.

Mid-luteal phase injection of subcutaneous leuprolide acetate improves live delivered pregnancy and implantation rates in younger women undergoing in vitro fertilization-embryo transfer (IVF-ET)

J.H. Check^{1,2}, C. Wilson², J.K. Choe^{1,2}

¹ Cooper Medical School of Rowan University, Department of Obstetrics and Gynecology, Division of Reproductive Endocrinology & Infertility, Camden, NJ; ² Cooper Institute For Reproductive Hormonal Disorders, P.C., Mt. Laurel, NJ (USA)

Summary

Purpose: To determine if a single injection of one-mg leuprolide acetate three days after embryo transfer (ET) in younger women causes an increase in pregnancy rates, and if so, is it associated with a higher initial serum hCG level? **Materials and Methods:** A prospective study was initiated where women aged ≤ 35 years were offered the option of taking the leuprolide or not. **Results:** Though a significant difference was not found, there was a trend for higher live delivered pregnancy rates in those taking the leuprolide supplement (47.8%) vs. those not taking it (38.6%). There was no difference in the first serum beta hCG level. **Conclusions:** The trends is interesting enough to continue with a higher powered study.

Key words: GnRH agonist; Leuprolide acetate; Embryo implantation rate; Beta hCG levels.

Introduction

A previous study by Tesarik *et al.* found that the single injection during the mid-luteal phase of a gonadotropin releasing hormone agonist (GnRHa) in women undergoing in vitro fertilization-embryo transfer (IVF-ET) and intracytoplasmic sperm injection (ICSI) in both GnRHa and GnRH antagonist cycles improved embryo implantation rates [1].

Tesarik *et al.* suggested that the beneficial effect may have been related to stimulating the embryo to make more hCG since high levels of serum hCG were found in early pregnancies in the women who conceived and took the GnRHa vs. those who did not take the GnRHa [1].

The objective of the present study was aimed to determine if some beneficial effect would be found with a single mid-luteal phase injection of a different GnRHa – leuprolide acetate one-mg. Furthermore the aim was to corroborate or refute the mechanism of action related to increased hCG secretion from the fetal-placental unit.

Materials and Methods

Consecutive women who requested IVF-ET age ≤ 35 years or under were given the option of taking 1mg leuprolide acetate three days after ET or not. They were advised of the data from the Tesarik *et al.* study and from a pilot study in the present authors' IVF-ET center.

Only controlled ovarian hyperstimulation (COH) regimens using GnRH antagonists were included. Chi-square analysis was used for comparison of clinical and live delivered pregnancy rates. The average first serum beta-hCG levels in those conceiving were determined.

There were no exclusions for failure to conceive in previous IVF-ET cycles or diminished oocyte reserve. Fertilization requiring ICSI or conventional oocyte insemination were not distinguished. A clinical pregnancy was defined as ultrasound evidence of pregnancy at eight weeks.

Results

There were 134 women who chose to take one mg leuprolide acetate and 197 who chose not to take the GnRHa. The results are seen in Table 1. Chi-square analysis failed to reveal any significant differences in either clinical preg-

Revised manuscript accepted for publication July 15, 2015

Table 1. — *Effect of GnRH agonist (leuprolide acetate) single injection on pregnancy rates following IVF-ET.*

Leuprolide acetate one mg given	No. transfers	No. clinical pregnancies (%)	No. live delivered pregnancy rates
Yes	134	69 (51.5%)	64 (47.8%)
No	197	97 (44.2%)	76 (38.6%)

nancy rates ($p = 0.77$) or live delivered pregnancy rates ($p = 0.12$). The implantation rates for those receiving GnRHa injection was 37.9% (97/256) vs. 33.1% (128/387) for those not receiving one-mg leuprolide acetate ($p = 0.24$) with the mean number of embryos transferred at 1.9 vs. 2.0. The average first serum beta-hCG level from pregnant women taking leuprolide was 285 mIU/ml and 273 mIU/ml for those pregnant not taking it ($p = \text{NS}$).

Discussion

There have been a few studies suggesting improved benefit from the use of GnRHa's in the mid-luteal phase, e.g., Tesarik *et al.* using triptorelin and Picard *et al.* using buserelin [1, 2]. This is the first study with the GnRHa leuprolide acetate. Although there were no significant differences noted, there was a trend for improved pregnancy outcome by using one mg of leuprolide acetate three days

after ET. The possibility is that the younger group has less likelihood of the need to improve embryo implantation compared to women of more advanced reproductive age. Presently the authors are evaluating women under similar circumstances between age 36-39 years, where pregnancy rates are significantly lower without the use of the mid-luteal phase injection of leuprolide acetate.

It would appear that, if indeed, a GnRHa study with more power shows a significant difference, the mechanism does not seem to be related to increasing the beta-hCG output from the fetal-placental unit.

References

- [1] Tesarik J., Hazout A., Mendoza-Tesarik R., Mendoza N., Mendoza C.: "Beneficial effect of luteal phase GnRH agonist administration on embryo implantation after ICSI in both GnRH agonist and antagonist treated ovarian stimulation cycles". *Hum. Reprod.*, 2006, 21, 2572.
- [2] Pirard C., Donnez J., Loumaye E.: "GnRH agonist as novel luteal support results of a randomized, parallel group, feasibility study using intranasal administration of buserelin". *Hum. Reprod.*, 2005, 20, 1798.

Address reprint requests to:
 J.H. CHECK, M.D., Ph.D.
 7447 Old York Road
 Melrose Park, PA 19027 (USA)
 e-mail: laurie@ccivf.com

Correlation of ImmunoBead[®] and ImmunoSphere[™] Immunoglobulin G (IGG) tests on detecting antisperm antibody (ASA) on sperm

A. Bollendorf¹, J.H. Check^{1,2}

¹ Cooper Institute for Reproductive Hormonal Disorders, P.C., Mt. Laurel, NJ; ² Cooper Medical School Of Rowan University,
Department of Obstetrics and Gynecology, Division of Reproductive Endocrinology & Infertility, Camden, NJ (USA)

Summary

Purpose: To determine the correlation with detection of antibody on sperm by a new ImmunoSphere[™] Immunoglobulin test vs. ImmunoBeads[®]. **Materials and Methods:** A sampling of sperm tested for antisperm antibody (ASA) tested by direct ImmunoBead[®] assay with levels varying from zero to 100% were compared to the percentage of sperm positive for ASA by a new test using immunospheres. **Results:** The correlation was not perfect but, in general, there was good correlation. **Conclusion:** Now that the manufacturer is curtailing the manufacture of immunobeads, it is comforting to see a good correlation with immunospheres.

Key words: Antisperm antibodies; Direct immunobead test; Immunospheres; Post-coital test.

Introduction

Recently a statement from the American Society for Reproductive Medicine Society stated that the post-coital test is an archaic procedure but cautiously advised that it has value when used in the hands of certain clinicians experienced with this test. The majority of infertility centers perform intrauterine insemination (IUI) each month in non-IVF cycles allegedly to improve pregnancy rates. However, at least one study found no advantage in improving pregnancy rates with IUI with normal sperm vs. sexual relations where a normal post-coital test was demonstrated [1].

Most infertility centers do not seem to determine if the sperm are laden with antisperm antibodies when they are performing the initial semen analysis. Cervical factor, where there is a primary mucus problem, only accounts for 3% of the causes of infertility. However, one study demonstrated that when >50% of sperm were coated with antisperm antibodies, only 31% had sperm progressing in the cervical mucus at least eight hours after intercourse in properly timed post-coital tests in the presence of normal follicular maturation [2]. Thus, if one did not measure antisperm antibodies with the initial semen analysis, perhaps subnormal post-coital tests could prompt repeating the semen analysis to measure antisperm antibodies.

Some would argue what would it matter if one is bypassing the mucus and performing an IUI anyhow? However, Francavilla *et al.* found no live pregnancies following 119 IUI cycles when 100% of the sperm were found to be

coated by antisperm antibodies [3]. Francavilla *et al.*'s study suggested that in addition to immobilizing antibodies (which when combined with complement in the cervical mucus impedes sperm progression) [4-7], that there may be antisperm antibodies that may impair fertility in other ways including disrupting sperm oocyte recognition and fusion [8, 9], or inhibiting sperm from binding to the zona pellucida [10-12]. Other areas inhibiting fertilization and normal pregnancies have been found including inhibiting capacitation or the acrosome reaction and even inhibiting a fertilized oocyte from cleaving [13].

Thus it seems very important in the modern era to still measure sperm for antisperm antibodies. One of the most commonly used tests has been the direct immunobead test [14]. However, the manufacturer is starting to phase out the production of ImmunoBeads[®].

Materials and Methods

In order to replace the ImmunoBeads[®] method, the authors chose to evaluate ImmunoSpheres[™] since they are a similar method. The ImmunoSpheres[™] have already been tested and reported to have good correlation with the ImmunoBeads[®] using indirect testing [15]. In this study the authors are evaluating the direct method of testing for anti-sperm antibodies on the sperm.

There are a few differences between the two manufacturers. The ImmunoBeads[®] tend to clump and are non-uniform in size. A phase contrast microscope needs to be used since the beads are translucent. The ImmunoSpheres[™] are monodispersed and uniform in size of 3.0 µm latex beads. They are also colored blue for use with either a bright field or phase contrast.

Revised manuscript accepted for publication July 15, 2015

The Direct ImmunoSpheres[®] test for IgG is performed by mixing live motile sperm with latex beads coated with antibodies that bind to human IgG antibodies. The beads are first washed with a medium containing 1-2% bovine serum albumin and can be stored up to three days at 4°C. The semen is washed three times and the sperm is diluted to give a final concentration of 10x10⁶/ml. Five microliters of sperm suspension is mixed with five microliters of anti-IgG beads. After one to two minutes, 100 motile sperm are counted (in duplicate) and the percentage having beads attached is determined.

Procedural notes: the ImmunoBeads[™] tended to have quick binding, however the bead clumping made it difficult to differentiate if the sperm were attached to the beads or trapped in the clumps of beads. The ImmunoSpheres[®] tended to be very sensitive with bead attachment, sometimes taking longer than the one-to-two-minute incubation to form binding, as seen with the positive control. Also, controls failed often due to the weaker reactions with sperm. However, the ImmunoBeads[™] consistently had normal control values.

The objective of the present study is to see if there is a reasonable correlation with a new direct antisperm antibody test from a different manufacturer but using instead of ImmunoBead[™], ImmunoSphere[®].

Results

There were 29 known ASA samples that were split and the presence of ASA was measured by ImmunoBeads[™] and ImmunoSpheres[®] tests. There were 11 ImmunoBeads[™] specimens read as zero and all 11 were similarly read as zero with ImmunoSpheres[®].

There were 14 specimens read as zero by ImmunoSpheres[®] with four slightly discordant ImmunoBeads[™] tests read as 3, 2, and 7%, respectively. There were 11 ImmunoBeads[™] specimens read as 100% ASA with complete agreement with ImmunoSpheres[®] in three; 98-99% in three, and the others showing 95%, 95%, 92%, 83%, and 64%.

One ImmunoSphere[®] test was read as 100% and the corresponding ImmunoBeads[™] was 97%. There were some larger discrepancies however. One sample was 87% by ImmunoBeads[™] read as 31% ImmunoSpheres[®]. Other samples showed 7 vs. 0, 48 vs. 42, and 97 vs. 87.

Discussion

There appears to be a good correlation between measuring ASA by ImmunoBeads[™] vs. the ImmunoSpheres[®]. This confirms an older study performed over 15 years ago using different methodology than the new assay [15]. Some andrologists consider a positive test with ImmunoBeads[™] ASA levels >50%, and some consider >80% as clinically important.

It is important to detect antisperm antibodies from the beginning to prevent the couple from wasting the expense, time away from work or children, and mounting frustration from performing IUI without first treating the sperm with the protein digestive enzyme chymotrypsin galactose [13,

15]. Of course in vitro fertilization with intracytoplasmic sperm injection (ICSI) is more effective (but a lot more expensive).

Detection of antisperm antibodies prior to conventional insemination of normal appearing sperm can present the catastrophe of failed or poor fertilization which could have been circumvented by performing ICSI [16-19]. The present infertility center is now prepared to switch to the measurement of antisperm antibodies on sperm by ImmunoSpheres[®].

References

- [1] Check J.H., Liss J., Bollendorf A.: "Intrauterine insemination (IUI) does not improve pregnancy rates in infertile couples where semen parameters are normal and postcoital tests are adequate". *Clin. Exp. Obstet. Gynecol.*, 2013, 40, 33.
- [2] Check J.H., Bollendorf A.: "The effect of antisperm antibodies on post-coital results and the effect of intrauterine insemination on pregnancy outcome". *Arch. Androl.*, 1992, 28, 25.
- [3] Francavilla F., Romano R., Santucci R., Marrone V., Corrao G.: "Failure of intrauterine insemination in male immunological infertility in cases in which all spermatozoa are antibody-coated". *Fertil. Steril.*, 1992, 58, 587.
- [4] Steen Y., Forssman L., Lonnerstedt E., Jonasson K., Wassen A.C., Lycke E.: "Anti-sperm IgA antibodies against the equatorial segment of the human spermatozoon are associated with impaired sperm penetration and subfertility". *Int. J. Fertil.*, 1994, 39, 52.
- [5] Eggert-Kruse W., Hofstab A., Haurly E., Tilgen W., Gerhard I., Runnebaum B.: "Relationship between local anti-sperm antibodies and sperm-mucus interaction in vitro and in vivo". *Hum. Reprod.*, 1991, 6, 267.
- [6] Menge A.C., Beitner O.: "Interrelationships among semen characteristics, antisperm antibodies and cervical mucus penetration assays in infertile human couples". *Fertil. Steril.*, 1989, 51, 486.
- [7] Clarke G.N.: "Immunoglobulin class and regional specificity of antispermatozoal autoantibodies blocking cervical mucus penetration by human spermatozoa". *Am. J. Reprod. Immunol. Microbiol.*, 1988, 16, 135.
- [8] Fann C.H., Lee C.Y.G.: "Monoclonal antibodies affecting sperm-zona binding and/or zona-induced acrosome reaction". *J. Reprod. Immunol.*, 1992, 21, 175.
- [9] Wolfe J.P., DeAlmeida M., Ducot B., Rodrigues D., Jouannet P.: "High levels of sperm-associated antibodies impair human sperm oolemma interaction after subzonal insemination". *Fertil. Steril.*, 1995, 63, 584.
- [10] Mahony M.C., Blackmore P.F., Bronson R.A., Alexander N.J.: "Inhibition of human sperm-zona pellucida tight binding in the presence of antisperm antibody positive polyclonal patient sera". *J. Reprod. Immunol.*, 1991, 19, 287.
- [11] Zouari R., De Almeida M.: "Effect of sperm associated antibodies on human sperm ability to bind to zona pellucida and to penetrate zona-free hamster oocytes". *J. Reprod. Immunol.*, 1993, 24, 175.
- [12] Liu D.Y., Clarke G.N., Baker H.W.G.: "Inhibition of human sperm-zona pellucida and sperm-oolemma binding by antisperm antibodies". *Fertil. Steril.*, 1991, 55, 440.
- [13] Check J.H.: "Antisperm antibodies and human reproduction". *Clin. Exp. Obstet. Gynecol.*, 2010, 37, 169.
- [14] Clark G.N., Elliott P.J., Smaila C.: "Detection of sperm antibodies in semen using the immunobead test: a survey of 813 consecutive patients". *Am. J. Reprod. Immunol.*, 1985, 7, 118.
- [15] Centola G.M., Andolina E., Deutsch A.: "Comparison of the immunobead binding test (IBT) and immunospheres (IS) assay for detecting serum antisperm antibodies". *Am. J. Reprod. Immunol.*, 1997, 37, 300.

- [16] Lahteenmaki A., Reima I., Hovatta O.: "Treatment of severe male immunological infertility by intracytoplasmic sperm injection". *Hum. Reprod.*, 1995, 10, 2824.
- [17] Nagy Z.P., Verheyen G., Liu J., Joris H., Janssenswillen C., Wisanto A., et al.: "Results of 55 intracytoplasmic sperm injection cycles in the treatment of male-immunological infertility". *Hum. Reprod.*, 1995, 10, 1775.
- [18] Clarke G.N., Bourne M., Baker H.W.G.: "Intracytoplasmic sperm injection for treating infertility associated with sperm autoimmunity". *Fertil. Steril.*, 1997, 68, 112.
- [19] Check M.L., Check J.H., Katsoff D., Summers-Chase D.: "ICSI as an effective therapy for male factor with antisperm antibodies". *Arch. Androl.*, 2000, 45, 125.

Address reprint requests to:
J.H. CHECK, M.D., Ph.D.
7447 Old York Road
Melrose Park, PA 19027 (USA)
e-mail: laurie@ccivf.com

The use of granulocyte colony stimulating factor to enhance oocyte release in women with the luteinized unruptured follicle syndrome

J.H. Check^{1,2}, J. Vaniver², D. Senft², G. DiAntonio², D. Summers²

¹ Cooper Medical School of Rowan University, Department of Obstetrics and Gynecology, Division of Reproductive Endocrinology & Infertility, Camden, NJ; ² Cooper Institute for Reproductive Hormonal Disorders, P.C., Mt. Laurel, NJ (USA)

Summary

Purpose: To determine if an injection of granulocyte colony stimulating factor (G-CSF) prevulatory can enable oocyte release from the follicle in women who have failed to release in natural cycles despite an endogenous luteinizing hormone (LH) surge, and also despite treatment with human chorionic gonadotropin (hCG) or a gonadotropin releasing hormone agonist (GnRHa). **Materials and Methods:** A single injection of 100 mg G-CSF was given in the late follicular phase followed by hCG 10,000 units at peak follicular maturation in women with at least three consecutive cycles of luteinization without oocyte release. **Results:** Six women had ten cycles with G-CSF and hCG. Definite release occurred in four, inconclusive in four, and definitely the luteinized unruptured follicle in two. Biochemical pregnancies occurred in two of the cycles where oocyte release occurred and a live delivered pregnancy in another cycle of release. **Conclusions:** Without controls one cannot state with certainty that G-CSF enabled oocyte release when hCG and leuprolide failed. Nevertheless, the data do support a trial with G-CSF before proceeding to IVF-ET.

Key words: Luteinized unruptured follicle syndrome; Granulocyte colony stimulating factor; Human chorionic gonadotropin; Gonadotropin releasing hormone agonists; Natural cycles.

Introduction

Though there is not universal agreement that pelvic sonography can determine with a reasonable certainty oocyte release, it appears that some women have a tendency to not release the oocyte from the follicle despite luteinization [1, 2].

There are data suggesting that though human chorionic gonadotropin (hCG) injection may help to release oocytes in some women who have the trend for non-release (termed the luteinized unruptured follicle syndrome or LUF) a 10,000 IU injection of hCG does not always correct the defect [3]. In some circumstances raising endogenous LH and/or FSH levels by the use of a gonadotropin releasing hormone agonist, e.g., leuprolide acetate, can enable oocyte release even when hCG has failed [4, 5].

Granulocyte-colony stimulating factor (G-CSF) is an inflammatory cytokine present mainly in granulosa cells [6]. There is evidence that mRNA for G-CSF was ten times higher in the late follicular phase than in other phases [7].

Indeed Espy proposed a hypothesis that ovulation is an inflammatory process [8]. Besides G-CSF, other inflammatory cytokines, e.g., interleukin (IL)-1, IL-6, tumor necrosis factor alpha, granulocyte macrophage colony stimulating factor (GM-CSF), and macrophage colony-stimulating factor (M-CSF) have shown increased levels in the pre-ovulatory follicle [9-14].

Because some studies have found that compared to other inflammatory cytokines, e.g., IL-1B and IL-6, only G-CSF showed a significant increase in the serum during the ovulation phase [15], it was decided to see if oocyte release could be achieved in women with LUF syndrome who previously failed to release with hCG and GnRH agonists.

Materials and Methods

Women failing to demonstrate collapse of the follicle (shrinkage by > five mm) before the serum P exceeded two ng/ml first in a completely natural cycle, then a natural cycle where 10,000 units of hCG was given at the time of peak follicular maturation, and a third failure despite three s.c injections of one-mg leuprolide acetate given 12 hours apart also at the time of peak follicular maturation were enlisted.

G-CSF 100 mg s.c. was given as soon as the serum E2 approached 200 pg/ml (usually two days before hCG 10,000 unit injection). Failure of the follicle to shrink at all before the serum P exceeded two ng/ml was considered LUF. Shrinkage by only three to four mm was considered borderline release. Pregnancy rates were compared in those who appeared to release oocytes vs. those with inconclusive release vs. those with definite LUF. A pregnancy that did not proceed to ultrasound evidence of pregnancy but showed at least one rising level of serum beta hCG, was counted as pregnancy achievement.

Only women with patent fallopian tubes and male partners with normal semen parameters were selected.

Revised manuscript accepted for publication July 15, 2015

Results

Six women were enlisted with long-term infertility who fulfilled the aforementioned criteria for selection. G-CSF (filgrastim) was given in ten natural cycles. Oocyte release occurred in four of ten cycles (40%). Conclusive LUF was found in only two cycles (20%). Inconclusive release occurred in four cycles. One woman failed to release in both cycles. One woman failed to release in the first cycle but released in second cycle. Thus LUF only occurred in one of six (16.69%) women.

Three of six women released an oocyte (one woman in both cycles and one woman in one of two cycles) and two of them had biochemical pregnancies and one 43-year-old woman (G-0) delivered a live baby. None of the two women with inconclusive release conceived.

Discussion

Infertile women despite regular menses and attaining adequate mid-luteal phase serum progesterone levels may still have subtle ovulatory defects [16]. These defects include releasing the oocyte before the follicle is mature [17], premature luteinization [18], a short follicular phase [19], or merely the insufficient production of progesterone by the corpus luteum [20,21].

As mentioned, the luteinized unruptured follicle syndrome may be another subtle ovulatory defect, which when corrected, leads to pregnancies [1-5]. Though not uncommon as an isolated phenomenon (as in frequently the etiologic factor for the development of ovarian cysts), the occurrence of non-release of the oocytes in the majority of natural cycles (and thus considered the LUF syndrome) is relatively uncommon [1]. Even less common are women with LUF syndrome who fail to release oocytes even with hCG or GnRH agonists [3, 5]. Thus, it would be extremely difficult to perform a randomized prospective placebo controlled study from one institution to evaluate the efficacy of G-CSF in correcting the LUF syndrome in oocyte release failures even with hCG or GnRH agonist treatment. Similarly, there is probably insufficient interest to establish a multicenter study to acquire more statistical power.

This small series does not clearly prove that G-CSF was needed to enable oocyte release as compared to a fortuitous chance. Nevertheless, it is worth trying a new therapy, e.g., G-CSF, when everything else has failed rather than the very expensive option of mechanically removing the eggs from the follicle, i.e., in vitro fertilization.

A search of the literature was not able to find the use of G-CSF for LUF in natural cycles. However, the authors did find one study of a comparison of 16 women treated with clomiphene citrate and hCG [15]. Whereas only 56.5% showed oocyte release in the clomiphene hCG cycles, the addition of G-CSF (in this case filgrastim) resulted in a re-

lease rate of 88.9% [15]. Their definition of release included follicle collapse even five days after hCG without regards to the serum P level, so they may have assumed some women released when by the present authors' definition they would not have released [15].

References

- [1] Check J.H., Chase J.S., Adelson H.G., Dietterich C.: "New approaches to the diagnosis and therapy of the luteinized unruptured follicle syndrome". *Int. J. Fertil.*, 1986, 30, 29.
- [2] Check J.H., Adelson H.G., Dietterich C., Stern J.: "Pelvic sonography can predict ovum release in gonadotropin-treated patients as determined by pregnancy rate". *Hum. Reprod.*, 1990, 5, 234.
- [3] Check J.H., Dietterich C., Nowroozi K., Wu C.H.: "Comparison of various therapies for the luteinized unruptured follicle (LUF) syndrome". *Int. J. Fertil.*, 1992, 37, 33.
- [4] Check J.H., Vetter B.H., Weiss W.: "Comparison of hCG versus GnRH analog for releasing oocytes following ultra-low-dose gonadotropin stimulation". *Gynecol. Endocrinol.*, 1993, 7, 115.
- [5] Check J.H., Nazari A., Barnea E.R., Weiss W., Vetter B.H.: "The efficacy of short-term gonadotrophin-releasing hormone agonists versus human chorionic gonadotrophin to enable oocyte release in gonadotrophin stimulated cycles". *Hum. Reprod.*, 1993, 8, 568.
- [6] Salmassi A., Schmatzler A.G., Huang L., Hedderich J., Jonat W., Mettler I.: "Detection of granulocyte colony-stimulating factor and its receptor in human follicular luteinized granulosa cells". *Fertil. Steril.*, 2004, 81, 786.
- [7] Yanagi K., Makinoda S., Fujii R., Miyazaki S., Fujita S., Tomizawa H., et al.: "Cyclic changes of granulocyte colony-stimulating factor (G-CSF) mRNA in the human follicle during the normal menstrual cycle and immunolocalization of G-CSF protein". *Hum. Reprod.*, 2002, 17, 3046.
- [8] Espey L.L.: "Ovulation as an inflammatory reaction--a hypothesis". *Biol. Reprod.*, 1980, 22, 73.
- [9] Wang L.J., Norman R.J.: "Concentrations of immunoreactive interleukin-1 and interleukin-2 in human preovulatory follicular fluid". *Hum. Reprod.*, 1992, 7, 147.
- [10] Buyalos R.P., Watson J.M., Martinez-Maza O.: "Detection of interleukin-6 in human follicular fluid". *Fertil. Steril.*, 1992, 57, 1230.
- [11] Wang L.J., Briinnstrom M., Robertson S.A., Norman R.J.: "Tumor necrosis factor alpha in the human ovary: presence in follicular fluid and effects on cell proliferation and prostaglandin production". *Fertil. Steril.*, 1992, 58, 934.
- [12] Jasper M.J., Briinnstrom M., Olofsson J.I., Petrucco O.M., Mason H., Robertson S.A., Norman R.J.: "Granulocyte-macrophage colony-stimulating factor: presence in human follicular fluid, protein secretion and mRNA expression by ovarian cells". *Mol. Hum. Reprod.*, 1996, 2, 555.
- [13] Witt B.R., Pollard J.W.: "Colony stimulating factor-1 in human follicular fluid". *Fertil. Steril.*, 1997, 68, 259.
- [14] Nishimura K., Tamaka N., Kawano T., Matsuura K., Okamura H.: "Changes in macrophage colony-stimulating factor concentration in serum and follicular fluid in in-vitro fertilization and embryo transfer cycles". *Fertil. Steril.*, 1998, 69, 53.
- [15] Makinoda S., Mikuni M., Sogame M., Kobamatsu Y., Furuta I., Yamada H., et al.: "Erythropoietin, granulocyte-colony stimulating factor, interleukin-1 beta and interleukin-6 during the normal menstrual cycle". *Int. J. Gynecol. Obstet.*, 1996, 55, 265.
- [16] Check J.H.: "Ovulation defects despite regular menses: Part III". *Clin. Exp. Obstet. Gynecol.*, 2007, 34, 133.
- [17] Check J.H., Nowroozi K., Wu C.H., Adelson H.G., Lauer C.: "Ovulation-inducing drugs versus progesterone therapy for infertility in patients with luteal phase defects". *Int. J. Fertil.*, 1988, 33, 252.

- [18] Check J.H., Chase J.S., Nowroozi K., Dietterich C.J.: "Premature luteinization - Treatment and incidence in natural cycles". *Hum. Reprod.*, 1991, 6, 190.
- [19] Check J.H., Liss J.R., Shucoski K., Check M.L.: "Effect of short follicular phase with follicular maturity on conception outcome". *Clin. Exp. Obstet. Gynecol.*, 2003, 30, 195.
- [20] Check J.H.: "Progesterone therapy versus follicle maturing drugs - possible opposite effects on embryo implantation". *Clin. Exp. Obstet. Gynecol.*, 2002, 29, 5.
- [21] Check J.H., Cohen R.: "The role of progesterone and the progesterone receptor in human reproduction and cancer". *Expert Rev. Endocrinol. Metab.*, 2013, 8, 469.

Address reprint requests to:
J.H. CHECK, M.D., Ph.D.
7447 Old York Road
Melrose Park, PA 19027
e-mail: laurie@ccivf.com

In vitro fertilization (IVF) outcome in women in overt menopause attempting to induce follicular maturation by follicle stimulating hormone (FSH) receptor down-regulation

J.H. Check^{1,2}, C. Wilson², G. DiAntonio², A. DiAntonio²

¹ Cooper Medical School of Rowan University, Department of Obstetrics and Gynecology,
Division of Reproductive Endocrinology & Infertility, Camden, NJ

² Cooper Institute for Reproductive Hormonal Disorders, P.C., Mt. Laurel, NJ (USA)

Summary

Purpose: To determine the frequency of ovulation induction, obtaining oocytes leading to embryos, and pregnancy rates per embryo transfer in women with premature menopause. **Materials and Methods:** Prospective observational study of women hoping to have in vitro fertilization-embryo transfer (IVF-ET) with their own oocytes despite being in menopause. Ethinyl estradiol was used to lower follicle stimulation hormone (FSH) and restore sensitivity of follicles to mild FSH stimulation. **Results:** Three of five women had a live baby. Only one woman failed to induce ovulation and thus failed to have an embryo to transfer. One woman conceived two times and delivered a live healthy baby twice. The live delivered pregnancy rate per transfer was 20% (4/20) with generally one or occasionally two embryos transferred. The pregnancy rate per retrieval was 9.3% (4/43). **Conclusions:** These data can help other women in this circumstance to decide on IVF with their own eggs or switch to donor eggs.

Key words: Premature menopause; Embryo transfer; Restoration of FSH receptors; Ethinyl estradiol.

Introduction

Over the last 30 years, it has become clear that by lowering elevated serum follicle stimulation hormone (FSH), ovulation induction can be achieved much more frequently than expected in women who appear to be in overt menopause [1-5].

The most frequently used method to induce ovulation in this population is by lowering the high serum FSH with ethinyl estradiol (which has the advantage over estradiol (E2) of not contributing to the serum E2 levels, thus allowing better follicular monitoring) [6]. However, ovulation induction has also occurred by lowering the serum FSH with gonadotropin releasing hormone agonists, e.g., leuprolide acetate, or antagonists (cetorelix) [3, 7, 8].

Anecdotal reports of reversal of apparent menopause with subsequent pregnancy achieved by in vitro fertilization-embryo transfer (IVF-ET) have also been reported [9-11]. IVF is expensive. The objective of this study was to determine the efficacy of IVF-ET in women with premature ovarian failure. Knowing that previous precedents for success by anecdotal reports may help a woman to decide to try IVF when needed if there is a severe tubal or male factor, (although the women appear to be in menopause) if ovulation is induced. Others, before spending the money, would like to have some idea of the success rate to decide whether to spend the money or consider other options, e.g., donor oocyte or adoption.

Materials and Methods

A prospective observational study was performed on couples with either tubal factor or male factor where the female partner was in apparent menopause and desired IVF-ET with the female partner's own oocytes. Additional inclusion criteria were: age \leq 42, serum E2 $<$ 20 pg/ml, serum FSH $>$ 20 mIU/ml, amenorrhea $>$ one year. The treatment rendered was ethinyl estradiol 20 mcg per day was given. The woman was monitored by serial serum levels of E2, LH, FSH, and occasionally progesterone (P) plus ultrasound to evaluate follicular size and endometrial thickness. When serum FSH approached normal, mild stimulation with FSH may have been given. Human chorionic gonadotropin 10,000 units was given when there appeared to be at least one mature follicle. Details of methodology have been previously published [12, 13].

Results

There were five couples enrolled. Patient 1 failed to increase her E2 at all (remained $<$ 20 pg/ml) in two attempts and dropped out of study. Patient 2 developed a mature follicle in 24 of 28 attempted cycles. She formed one embryo in 13 of 24 cycles (54.1%). Her first four cycles resulted in single embryos, but she failed to conceive after four fresh embryo transfers.

Her Crohn's disease exacerbated and she was treated with cyclophosphamide, precluding any more transfers to herself. She decided to stockpile cryopreserved embryos until

Revised manuscript accepted for publication July 14, 2015

she acquired a gestational carrier. She proceeded with 24 more attempted IVF with cryopreservation cycles. Oocyte retrieval occurred in 20 cycles. A single two pronuclear embryo was created and cryopreserved nine times. Six of the nine cryopreserved embryos were thawed and two embryos were transferred to a gestational carrier twice and she conceived on her third attempt and delivered a live healthy baby. The gestational carrier by choice had only one embryo transferred in cycle 1 and cycle 2, but allowed two in the third cycle, which was successful. Thus one of ten embryos formed resulted in a live baby. This patient was part of the observational study, but her case report has already been published [14]. She has three embryos left and is planning to transfer them again to a gestational carrier.

Patient 3 made a mature follicle in five of nine cycles leading to oocyte retrieval. She had a total of four embryos. She failed to conceive with one embryo transfer x 2 but she was successful with a two-embryo transfer following her fifth oocyte retrieval (and third embryo transfer).

Patient 4 had ten oocyte retrievals leading to nine embryo transfers. There were a total of 12 embryos created. She conceived and delivered a healthy baby following single embryo transfer on her third attempt. She returned for baby 2 and formed one or two embryos in six of seven oocyte retrieval cycles. She conceived and delivered a healthy baby a second time from oocyte retrieval number 10 with two embryos transferred.

Patient 5 had 6 initiated cycles and four of them led to oocyte retrieval. She had two embryo transfers of one embryo each. However, she failed to conceive.

Overall the live delivered pregnancy rate per transfer was 20% (4/20). Overall, the live delivered pregnancy rate per retrieval was 9.3% (4/43). The live delivered pregnancy rate per initiated cycle was 6.1% (4/65).

Discussion

IVF-ET is generally a very expensive procedure, especially related to the cost of gonadotropins and the cost of the IVF-ET procedure itself. IVF-ET also has certain risks, especially ovarian hyperstimulation syndrome (OHSS).

More expensive than IVF-ET is the cost of being a donor oocyte recipient, with extra costs of donor fees frequently leading to prices twice as high as a regular IVF-ET cycle.

The cost of medication in described techniques to induce ovulation in women in apparent menopause is only a fraction of normal price for medication with normal IVF-ET because hardly any (or none at all) gonadotropins are used. Because there is generally only one or two oocytes, the price of IVF-ET could be considerably lowered by a given IVF center when faced with this type of problem. There obviously is no risk of OHSS.

There does not appear to be any age time-line for successful pregnancy from donor oocytes [15]. With this information as to success rates and a cost analysis, a given

couple can decide to try IVF with their own oocytes or try donor oocytes. It should be noted that though highly successful, some women fail to conceive even with donor oocytes. One woman (not part of this series because she did not have IVF-ET) had failed to conceive despite four cycles of transferring embryos derived from donor oocytes. She spent USD 120,000.00 without success. She was made to ovulate three times out of four initiated cycles with ethinyl estradiol despite two years of amenorrhea with serum E2 < 20 pg/ml and a serum FSH initially 125 mIU/ml but one time getting to 185 mIU/ml. She was successful with just intercourse alone in her fourth ovulation induction cycle with luteal phase P support. IVF was not suggested because she had patent fallopian tubes and her husband's semen parameters were normal [16].

This study also confirms that the technique to induce ovulation in women in apparent premature menopause by lowering FSH and theoretically restoring down-regulated FSH receptors making the follicle more sensitive to FSH stimulation, seems to be an effective technique in that there is no question that the frequency of ovulation in these women far exceeds what would have been expected just fortuitously.

References

- [1] Check J.H., Chase J.: "Ovulation induction in hypergonadotropic amenorrhea with estrogen and human menopausal gonadotropin therapy". *Fertil. Steril.*, 1984, 42, 919.
- [2] Check J.H., Chase J.S., Wu C.H., Adelson H.G.: "Case report: ovulation induction and pregnancy with an estrogen-gonadotropin stimulation technique in a menopausal woman with marked hypoplastic ovaries". *Am. J. Obstet. Gynecol.*, 1989, 160, 405.
- [3] Check J.H., Nowroozi K., Chase J.S., Nazari A., Shapse D., Vaze M.: "Ovulation induction and pregnancies in 100 consecutive women with hypergonadotropic amenorrhea". *Fertil. Steril.*, 1990, 53, 811.
- [4] Shanis B.S., Check J.H.: "Spontaneous ovulation and successful pregnancy despite bilateral streaked ovaries". *Infertility*, 1992, 15, 70.
- [5] Check M.L., Check J.H., Kaplan H.: "Pregnancy despite imminent ovarian failure and extremely high endogenous gonadotropins and therapeutic strategies: Case report and review". *Clin. Exp. Obstet. Gynecol.*, 2004, 31, 299.
- [6] Check J.H.: "The multiple uses of ethinyl estradiol for treating infertility". *Clin. Exp. Obstet. Gynecol.*, 2010, 37, 249.
- [7] Check J.H., Wu C.H., Check M.: "The effect of leuprolide acetate in aiding induction of ovulation in hypergonadotropic hypogonadism: A case report". *Fertil. Steril.*, 1988, 49, 542.
- [8] Check J.H., Katsoff B.: "Ovulation induction and pregnancy in a woman with premature menopause following gonadotropin suppression with the gonadotropin releasing hormone antagonist, cetrorelix - a case report". *Clin. Exp. Obstet. Gynecol.*, 2008, 35, 10.
- [9] Check J.H., Nowroozi K., Nazari A., Baker A., Goldsmith A.: "In vitro fertilization-embryo transfer in three women with ovarian failure". *J. In Vitro Fert. Embryo Transf.*, 1990, 7, 45.
- [10] Check J.H., Summers D., Nazari A., Choe J.: "Successful pregnancy following in vitro fertilization-embryo transfer despite imminent ovarian failure". *Clin. Exp. Obstet. Gynecol.*, 2000, 27, 97.
- [11] Check M.L., Check J.H., Choe J.K., Berger G.S.: "Successful pregnancy in a 42-year-old woman with imminent ovarian failure following ovulation induction with ethinyl estradiol without gonadotropins and in vitro fertilization". *Clin. Exp. Obstet. Gynecol.*, 2002, 29, 11.

- [12] Check J.H.: "Pharmacological options in resistant ovary syndrome and premature ovarian failure". *Clin. Exp. Obstet. Gynecol.*, 2006, 33, 71.
- [13] Check J.H.: "The concept and treatment methodology for inducing ovulation in women in apparent premature menopause". *Clin. Exp. Obstet. Gynecol.*, 2009, 36, 70.
- [14] Check J.H., Srivastava M., Brasile D., Amui J., Choe J.K., Dix E.: "Successful pregnancy with frozen embryo transfer into a gestational carrier from eggs obtained from a woman in premature menopause – case report". *Clin. Exp. Obstet. Gynecol.*, 2009, 36, 54.
- [15] Check J.H., Jamison T., Check D., Choe J.K., Brasile D., Cohen R.: "Live delivery and implantation rates of donor oocyte recipients in their late forties are similar to younger recipients". *J. Reprod. Med.*, 2011, 56, 149.
- [16] Check J.H., Katsoff B.: "Successful pregnancy with spontaneous ovulation in a woman with apparent premature ovarian failure who failed to conceive despite four transfers of embryos derived from donated oocytes". *Clin. Exp. Obstet. Gynecol.*, 2006, 33, 13.

Address reprint requests to:
J.H. CHECK, M.D., Ph.D.
7447 Old York Road
Melrose Park, PA 19027 (USA)
e-mail: laurie@ccivf.com

The effect of clomiphene citrate vs. letrozole on post-coital tests

J.H. Check^{1,2}, J.R. Liss², J. Vaniver²

¹ Cooper Medical School of Rowan University, Department of Obstetrics and Gynecology, Division of Reproductive Endocrinology & Infertility, Camden, NJ

² Cooper Institute for Reproductive Hormonal Disorders, P.C., Mt. Laurel, NJ (USA)

Summary

Purpose: To determine if letrozole is less likely to create a hostile cervical mucus than clomiphene citrate. *Materials and Methods:* Post-coital testing compared at time of peak follicular maturation in women attaining mature follicles in first or second cycle of these two drugs. The study was randomized. Intercourse occurred at least 8-16 hours before. *Results:* Poor post-coital tests were found in twice the frequency in letrozole cycles than clomiphene citrate cycles. *Conclusions:* Despite its shorter half-life, letrozole seems to be as least as likely, if not more, to adversely affect cervical mucus.

Key words: Post-coital test; Cervical mucus; Clomiphene citrate; Letrozole.

Introduction

Aromatase inhibitors, e.g., letrozole, because of a shorter half-life, have been considered to have less anti-estrogenic side effects resulting in less adverse effect on endometrial thickness, less vasomotor symptoms, and less premenstrual syndrome [1, 2]. Because of its anti-estrogen effect, clomiphene citrate frequently creates a hostile cervical mucus associated with poor post-coital tests [3]. A priori, if letrozole has less anti-estrogen effect than clomiphene, it seems logical that it should have less adverse on cervical mucus.

The objective of the study was to determine if a “good” post-coital test (defined as finding any sperm with progressive linear motion 8-12 hours after intercourse) is more likely to be found in letrozole vs. clomiphene stimulated cycles.

Materials and Methods

A randomized prospective pilot study was performed. Anovulatory women were randomly assigned to clomiphene citrate vs. letrozole. Starting dosages were 50 mg days 5-9 for clomiphene. Starting dosages were 2.5 mg days 5-9 for letrozole. If a serum estradiol of 200 pg/ml was not achieved, the dosage of clomiphene or letrozole would be doubled for cycle 2.

The post-coital test that was recorded was the one performed with the appropriate peak serum E2 and prior to the LH surge. Intercourse was 8-16 hours before the post-coital test. Only couples with male partners with normal semen parameters (including absence of antisperm antibodies) were selected for the study. If a mature follicle was not achieved in cycles 1 or 2, the patient was

eliminated and a reserve was added to the study and given the same drug regimen.

All couples selected for the study did not want to have an intrauterine insemination performed if there was a poor post-coital test. Patients were given the option to try a second cycle with the same regimen and normal follicular maturation was achieved or they could switch to gonadotropin injections. If they switched, that cycle was not included in the data. Thus the number of second cycles could be unequal related to switching to gonadotropin therapy or pregnancy.

Results

The frequency of poor post-coital tests (no sperm with linear progressive motion in the mucus) is seen in Table 1 for cycles 1 and 2. Overall combining cycles 1 and 2 poor post-coital tests were found in three of 19 (15.7%) clomiphene cycles vs. five of 17 (29.4%) with letrozole.

Discussion

Though the frequency of poor post-coital tests was twice as high in the letrozole group vs. the clomiphene

Table 1. — *Relative effect of clomiphene citrate vs. letrozole on post-coital tests.*

	Clomiphene citrate	Letrozole
Cycle 1 – no. poor PCT	(n=12) 2 (16%)	(n=12) 4 (33%)
Cycle 2 – no. poor PCT	(n=7) 1 (14%)	(n=5) 1 (20%)

Revised manuscript accepted for publication July 15, 2015

group, the study was not sufficiently powered to show a significant difference ($p > 0.05$, Chi-square analysis). However, because of the failure to demonstrate even a trend to support the initial hypothesis that the known less anti-estrogenic effects of letrozole could result in a lower frequency of poor post-coital tests, the study was discontinued. Possibly the shorter half-life of letrozole, and therefore less anti-estrogenic effects on endometrial thickness and vasomotor symptoms, was negated at the mucus level by a higher average peak serum E2 442.4 pg/ml for clomiphene vs. 372.3 pg/ml for letrozole.

References

- [1] Mitwally M.F.M., Casper R.F.: "Aromatase inhibition improves ovarian response to follicle-stimulating hormone in poor responders". *Fertil. Steril.*, 2002, 774, 776.
- [2] Mitwally M.F.M., Casper R.F.: "Potential of aromatase inhibitors for ovulation and superovulation induction in infertile women". *Drugs*, 2006, 66, 2149.
- [3] Check J.H., Adelson H.G., Davies E.: "Effect of clomiphene citrate therapy on postcoital tests in successive treatment cycles including response to supplemental estrogen therapy". *Arch. Androl.*, 1994, 32, 69.

Address reprint requests to:
J.H. CHECK, M.D., Ph.D.
7447 Old York Road
Melrose Park, PA 19027 (USA)
e-mail: laurie@ccivf.com

Failed fertilization with conventional oocyte insemination can be overcome with the ability of ICSI according to binding or failing to bind to the zona pellucida

J.H. Check^{1,2}, A. Bollendorf², C. Wilson²

¹ Cooper Medical School of Rowan University, Department of Obstetrics and Gynecology,
Division of Reproductive Endocrinology & Infertility, Camden, NJ

² Cooper Institute for Reproductive Hormonal Disorders, P.C., Mt. Laurel, NJ (USA)

Summary

Purpose: To determine the frequency of failed fertilization with conventional oocyte insemination and to determine the ability of intracytoplasmic sperm injection (ICSI) to overcome the failed fertilization according to binding or failing to bind to the zona pellucida. **Materials and Methods:** Retrospective review of 12,448 in vitro fertilization (IVF) cycle to identify cycles where failed fertilization occurred following conventional oocyte insemination with seemingly normal sperm. A number of three oocytes retrieved was required. **Results:** There were only 12 cases of failed fertilization (0.1%). Six were related to failure of any or few sperm attaching to the zona pellucida. These six had high fertilization rates with ICSI. Six had normal attachment and five attempted another cycle, this time with ICSI. Only 60% had good fertilization. **Conclusions:** When there is failed fertilization with normal sperm oocyte binding following conventional oocyte insemination, ICSI may still be effective in 60% of the cases, but it would be probably recommended to combine ICSI with artificial oocyte activation by calcium ionophore.

Key words: Failed fertilization; Zona pellucida; Sperm binding; Intracytoplasmic sperm injection; Calcium ionophore.

Introduction

The zona pellucida is composed of glycoproteins secreted by the oocyte. Zona protein (ZP) 3 is the most abundant. ZP3 and ZP4 are the primary ligands for sperm binding which lasts for approximately one minute. ZP2 binding occurs after the acrosome reaction and this process helps to inhibit the penetration by other sperm, i.e., prevents polyspermy [1-4].

The initial binding of the sperm to the zona pellucida requires recognition on the part of the sperm of the carbohydrate component of species specific glycoprotein ligand [4, 5]. Binding of sperm head receptors and zona pellucida ligands produce an enzyme complex which induces the acrosome reaction. The acrosome reaction releases enzymes that allow the sperm to fuse to the oocyte membrane. The fusion of sperm and oocyte membranes trigger the cortical reaction which involves the release of substances from cortical granules which are localized just below the oocyte cell membrane. The cortical reaction leads to the enzyme-induced zona reaction which causes the zona to harden. The cortical reaction also inactivates ligand for sperm receptors. This process thus inhibits penetration by more than one sperm (polyspermy).

Oocyte activation is characterized by a two-step pattern of rises in intracellular calcium (Ca^{++}) concentrations. A first Ca^{++} rise, referred to as the trigger, originates from the oocyte after sperm-oocyte membrane interaction. This initial Ca^{++} rise that is released from internal Ca^{++} stores of the oocyte membrane is dependent on a receptor-mediated interaction between the sperm and the oocyte plasma membrane [6]. With intracytoplasmic sperm injection (ICSI) this sperm oocyte plasma membrane interaction is eliminated. However, the mechanical injection procedure itself (which can occur by merely the injection without a sperm) also causes a massive influx of calcium into the oocyte and is referred to as a pseudotrigger [6].

The second step of oocyte activation that is referred to as the oscillator (related to the characteristic of a series of shorter calcium transients of high amplitude that begins 30 minutes after the trigger (step one) and continues for three to four hours) [6]. The oscillator function is dependent on the release of a sperm associated activating factor [6].

ICSI has enabled fertilization of oocytes from extremely low concentrations of viable sperm, sperm coated with a high concentration of antisperm antibodies, and immature

Revised manuscript accepted for publication July 14, 2015

testicular sperm even when taken many hours after the death of a man not on life support [7-9]. In 3% or less of cases in women who make an adequate number of follicles, there will be complete failure to fertilize the oocytes despite ICSI [10-12].

The objective of this study was to evaluate fertilization rates following ICSI in cases of failed fertilization with conventional oocyte insemination with "normal sperm" according to whether the sperm did or did not bind to the zona pellucida.

Materials and Methods

This retrospective review evaluated all in vitro fertilization (IVF) cycles where there was failed fertilization following conventional insemination with normal appearing sperm. A minimum of three oocytes retrieved was required. ICSI was offered in a succeeding IVF cycle. Fertilization rates with ICSI were then compared according to reason for failed fertilization-failure of sperm binding or failure to activate the oocyte.

Results

Twelve cases of failed fertilization were identified over a 13-year period in 12,448 IVF cycles. Six of 12 were related to very few or no sperm attached to the zona pellucida. Two cases with zona binding defects that failed to fertilize any of 16 inseminated oocytes shared a pool of oocytes with two other couples. The two male partners of these other couples fertilized 11/15 (73.3%) of the oocytes with conventional stimulation suggesting sperm receptor defect for ZP3 or ZP4 rather than mutated ZP3 or ZP4 proteins in the oocyte. ICSI negated the sperm binding defects in all six couples, showing > 50% fertilization with a total percentage of 73% (60/82). However, ICSI was not as effective with failed fertilization with normal sperm binding in two out of five couples (one did not try IVF again), showing failed fertilization (0/7) or poor fertilization (12.5%, 1/8). The other three had very good fertilization rates of 88.8% (16/18).

Discussion

Fertilization failure despite ICSI can be related to the partial or complete inability of the sperm to activate oocytes [13]. Another reason for fertilization failure despite ICSI is the inability of the oocytes to decondense the sperm [14]. Sometimes the problem is obviously related to the sperm lacking the sperm oocyte activating factor, e.g., with globozoospermia, where the fertilization rate varies from 0-37% [10, 15, 16].

Fertilization has occurred with globozoospermia following ICSI when the eggs were activated artificially by calcium ionophore [16, 17]. Cases have been described where calcium ionophore allowed activation and fertilization of an oocyte and a successful pregnancy in a couple with fer-

tilization failure despite normozoospermic motile sperm [18, 19].

The present data showed that failed fertilization following conventional oocyte insemination with sperm with normal semen parameters is uncommon occurring in about one in 1,000 cases. Failure of sperm binding accounts for 50% of the cases and is corrected by ICSI.

ICSI injection by attaining a rapid calcium influx, overcomes phase I but not phase II oocyte activation defects. Thus when failed fertilization occurs despite normal zona binding by the sperm, a second attempt with ICSI should be accompanied by artificial activation by calcium ionophore since phase II defects may occur in about 40% of cases as suggested by these data. In fact one of the two women had marked diminished oocyte reserve. She tried Ca⁺⁺ ionophore with ICSI in cycle 3 and fertilized the one oocyte retrieved and conceived. Unfortunately she miscarried at eight weeks despite showing fetal viability. However, she fertilized both oocytes retrieved in cycle 4 and had a normal single baby [19].

References

- [1] Shabanowitz R.B., O'Rand M.G.: "Characterization of the human zona pellucida from fertilized and unfertilized eggs". *J. Reprod. Fertil.*, 1988, 82, 151.
- [2] Lefièvre L., Conner S.J., Salpekar A., Olufowobi O., Ashton P., Pavlovic B., et al.: "Four zona pellucida glycoproteins are expressed in the human". *Hum. Reprod.*, 2004, 19, 1580.
- [3] Jovine L., Qi H., Williams Z., Litscher E.S., Wassarman P.M.: "Features that affect secretion and assembly of zona pellucida glycoproteins during mammalian oogenesis". *Soc. Reprod. Fertil. Suppl.*, 2007, 63, 187.
- [4] Wassarman P.M.: "Zona pellucida glycoproteins". *J. Biol. Chem.*, 2008, 283, 2485.
- [5] Wassarman P.M.: "Mouse gamete adhesion molecules". *Biol. Reprod.*, 1992, 46, 86.
- [6] Tesarik J., Mendoza C., Greco E.: "The activity (calcium oscillator?) responsible for human oocyte activation after injection with round spermatids is associated with spermatid nuclei". *Fertil. Steril.*, 2000, 74, 1245.
- [7] Van Steirteghem A.C., Nagy Z., Joris H., Liu H., Liu J., Staessen C., et al.: "High fertilization and implantation rates after intracytoplasmic sperm injection". *Hum. Reprod.*, 1993, 8, 1061.
- [8] Check M.L., Check J.H., Summers-Chase D., Choe J.K., Check D.J., Nazari A.: "Live birth after posthumous testicular sperm aspiration and intracytoplasmic sperm injection with cryopreserved sperm: Case report". *Clin. Exp. Obstet. Gynecol.*, 2002, 29, 95.
- [9] Check M.L., Check J.H., Katsoff D., Summers-Chase D.: "ICSI as an effective therapy for male factor with antisperm antibodies (ASA)". *Arch. Androl.*, 2000, 45, 125.
- [10] Liu J., Nagy Z., Joris H., Tournay H., Devroey P., Van Steirteghem A.: "Successful fertilization and establishment of pregnancies after intracytoplasmic sperm injection in patients with globozoospermia". *Hum. Reprod.*, 1995, 10, 626.
- [11] Flaherty S.P., Payne D., Matthews C.D.: "Fertilization failures and abnormal fertilization after intracytoplasmic sperm injection". *Hum. Reprod.*, 1998, 13, 155.
- [12] Horwath D., Check J.H., Katsoff B., Amui J., Brasile D.: "Subsequent therapeutic options and outcome in couples who fail to fertilize despite in vitro fertilization (IVF) and intracytoplasmic sperm injection (ICSI)". *Clin. Exp. Obstet. Gynecol.*, 2007, 34, 109.

- [13] Sakkas D., Urner F., Bianchi P.G., Bizzaro D., Wagner I., Jaquenoud N., *et al.*: "Sperm chromatin anomalies can influence decondensation after intracytoplasmic sperm injection". *Hum. Reprod.*, 1996, 11, 837.
- [14] Schmiady H., Tandler-Schneider A., Kentenich H.: "Premature chromosome condensation of the sperm nucleus after intracytoplasmic sperm injection". *Hum. Reprod.*, 1996, 11, 2239.
- [15] Battaglia D.E., Koehler J.K., Klein N.A., Tucker M.J.: "Failure of oocyte activation after intracytoplasmic sperm injection using round-headed sperm". *Fertil. Steril.*, 1997, 68, 118.
- [16] Rybouchkin A.V., Van der Straeten F., Quatacker J., De Sutter P., Dhont M.: "Fertilization and pregnancy after assisted oocyte activation and intracytoplasmic sperm injection in a case of round-headed sperm associated with deficient oocyte activation capacity". *Fertil. Steril.*, 1997, 68, 1144.
- [17] Tesarik J., Sousa M.: "More than 90% fertilization rates after intracytoplasmic sperm injection and artificial induction of oocyte activation with calcium ionophore". *Fertil. Steril.*, 1995, 63, 343.
- [18] Eldar-Geva T., Brooks B., Margalioth E.J., Zylber-Haran E., Gal M., Silber S.J.: "Successful pregnancy and delivery after calcium ionophore oocyte activation in a normozoospermic patient with previous repeated failed fertilization after intracytoplasmic sperm injection". *Fertil. Steril.*, 2003, 79, 1656.
- [19] Check J.H., Summers-Chase D., Cohen R., Brasile D.: "Artificial oocyte activation with calcium ionophore allowed fertilization and pregnancy in a couple with long-term unexplained infertility where the female partner had diminished egg reserve and failure to fertilize oocytes despite intracytoplasmic sperm injection". *Clin. Exp. Obstet. Gynecol.*, 2010, 37, 263.

Address reprint requests to:
J.H. CHECK, M.D., Ph.D.
7447 Old York Road
Melrose Park, PA 19027 (USA)
e-mail: laurie@ccivf.com

The progesterone receptor antagonist mifepristone does not lower serum progesterone induced blocking factor (PIBF) in the presence of progesterone

J.H. Check^{1,2}, G. DiAntonio¹, A. DiAntonio¹, M. Duroseau¹

¹ Cooper Institute for Reproductive and Hormonal Disorders, P.C., Mt. Laurel, NJ

² Cooper Medical School of Rowan University, Camden, NJ (USA)

Summary

Purpose: To determine if mifepristone can lower serum levels of a progesterone (P) induced immunomodulatory protein believed to be needed for the fetus to escape immune surveillance. **Materials and Methods:** A female volunteer had her serum P induced blocking factor (PIBF) increased by ingestion of oral micronized P. While remaining on P mifepristone, 200 mg/day was given for six days when another serum PIBF level was obtained. **Results:** The serum PIBF was 273 ng/ml after five days of oral micronized P. It increased further to 737 ng/ml despite taking six days of 200 mg mifepristone. **Conclusions:** The mechanism for inducing abortion by mifepristone does not seem to be related to decreasing serum levels of PIBF. This does not eliminate the possibility that the mechanism involves reducing the intracytoplasmic PIBF levels.

Key words: Selective progesterone receptor antagonists; Mifepristone; Serum immunomodulatory protein; Progesterone induced blocking factor; Therapeutic abortion.

Introduction

It is common knowledge that a certain minimal level of progesterone (P) must be maintained from ovulation until delivery to allow a full-term baby to be born. P acting in conjunction with the P receptor causes the production of various molecules needed for appropriate development of a secretory endometrium to allow proper implantation [1].

The maintenance of P secretion throughout pregnancy is needed, at least in part, for inhibiting myometrial contraction and for immune suppression of the fetal semi-allograft [1]. One of the mechanisms by which the interaction of P and P receptors may inhibit immune suppression is by the secretion of the immunomodulatory protein, the progesterone induced blocking factor (PIBF) [1-4]. One of the main functions of PIBF is to inhibit degranulation of perforin granules in natural killer (NK) cells thus inhibiting their cytotoxicity [5].

The PIBF is a protein which when detected in serum measures 34 kDa and is a splice variant of the parent compound which resides in the nucleus at a centrosomal position and measures 90 kDa [6]. The full length protein consists of 757 amino acid residues and the 48 kDa N terminal part is biologically active [7]. PIBF seems to be unique in that it shows no significant amino acid sequence homology with any known protein [7].

RNA expression analysis has demonstrated that centrosomal PIBF is overexpressed in rapidly proliferating cells irrespective of whether they have been found to be positive or not for P receptors [1,6]. Serum levels of PIBF are mainly produced by the interaction of P with P receptors on gamma delta T cells [8]. Whereas addition of P to the media of certain leukemia cell lines caused an upregulation of the 34 kDa intracytoplasmic splice variant of PIBF, in contrast, adding the P receptor antagonist mifepristone caused downregulation of PIBF expression [9].

Interestingly mifepristone was found to reduce NK cell activity in pregnant women [10]. The assumption was made, but not proven, that the mechanism of action probably was related to the P receptor antagonist interfering with the reaction of P with P receptors on gamma/delta T cells, and thus reduction of secretion by these cells of the circulating 34 kDa protein, and thus failure to stabilize perforin granules in circulating NK cells. Recently, with purification of the PIBF protein, a sensitive ELISA assay to PIBF has been developed [11-13]. The objective of the present study was to determine if mifepristone can suppress circulating levels of serum PIBF.

Materials and Methods

A 23-year-old young lady volunteer on continuous oral contraceptives had a baseline serum PIBF level obtained. On day 5 of taking oral micronized P 200 mg daily, a serum PIBF level

Revised manuscript accepted for publication July 15, 2015

was obtained. The 200-mg oral micronized P was maintained, and she was also given 200 mg mifepristone orally concomitantly. On the 6th day of combined oral P and mifepristone, another serum PIBF was obtained. The PIBF was measured by a non-commercial research ELISA assay using a monoclonal anti-PIBF antibody [12,13].

Results

The baseline serum PIBF was 62 ng/ml. The PIBF levels increased to 273 ng/ml after five days of oral P therapy. The level was over 737 ng/ml six days later, despite taking a dosage of mifepristone that will usually terminate a live fetus.

Discussion

Mifepristone is a known abortifacient. As mentioned, in view of the inhibiting effect of mifepristone on NK cell activity, and since NK cell activity is suppressed by PIBF (which is induced by P), logically, it seemed likely that the mechanism of causing abortion was by immune rejection probably by inhibiting PIBF production by circulating gamma/delta T cells [10]. However, mifepristone has been hypothesized to have other actions abrogating immune suppression other than via a PIBF mechanism [14,15]. Thus, based on the present data, failing to demonstrate any suppression of PIBF by mifepristone in a patient taking exogenous P, one hypothetical conclusion is that the mechanism of action does not involve PIBF. However, the study by Ivanova-Todorova *et al.* did not evaluate serum PIBF levels and thus reduced NK cell activity may not have been through suppression of circulating PIBF secreted by gamma/delta T cells [10].

The study of the effect of mifepristone on reducing the intracytoplasmic 34-36 kDa splice variant of PIBF secretion by certain leukemia cell lines allow an alternative hypothesis [9]. Mifepristone may cause immune rejection of the fetus by suppressing intracytoplasmic PIBF of the rapidly growing cells of the placenta or the fetus itself thus abrogating immune tolerance to the fetal semi-allograft leading to abortion.

Mifepristone has been demonstrated to have a palliative effect on a variety of human and murine cancers, not only not known to be P receptor positive, but where there has been demonstration of normal serum PIBF levels [16-24]. Though there are many mechanisms of how P and P receptors may allow cancer cells to grow even without effects on tumor immunology, suppressing intracellular conversion of the parent 90 kDa parent PIBF compound to the 34-36 kDa intracytoplasmic splice variant is one of the possibilities. Thus, mifepristone suppressing intracytoplasmic PIBF could be one, if not the major mechanism, as to how mifepristone ingestion leads to pregnancy termination.

Acknowledgements

Actavis (Parsippany, NJ) provided financial support for the purchase of reagents for the PIBF assay.

References

- [1] Check J.H., Cohen R.: "The role of progesterone and the progesterone receptor in human reproduction and cancer". *Expert Rev. Endocrinol. Metab.*, 2013, 8, 469.
- [2] Szekeres-Bartho J., Autran B., Debre P., Andreu G., Denver L., Chaouat G.: "Immunoregulatory effects of a suppressor factor from healthy pregnant women's lymphocytes after progesterone induction". *Cell Immunol.*, 1989, 122, 281.
- [3] Check J.H., Szekeres-Bartho J., O'Shaughnessy A.: "Progesterone induced blocking factor seen in pregnancy lymphocytes soon after implantation". *Am. J. Reprod. Immunol.*, 1986, 35, 277.
- [4] Check J.H., Arwitz M., Gross J., Szekeres-Bartho J., Wu C.H.: "Evidence that the expression of progesterone-induced blocking factor by maternal T-lymphocytes is positively correlated with conception". *Am. J. Reprod. Immunol.*, 1997, 38, 6.
- [5] Faust Z., Laskarin G., Rukavina D., Szekeres-Bartho J.: Progesterone induced blocking factor inhibits degranulation of NK cells. *Am. J. Reprod. Immunol.*, 1999, 42, 71.
- [6] Lachmann M., Gelbmann D., Kalman E., Polgar B., Buschle M., von Gabain A., *et al.*: "PIBF (progesterone induced blocking factor) is overexpressed in highly proliferating cells and associated with the centrosome". *Int. J. Cancer*, 2004, 112, 51.
- [7] Polgar B., Kispal G.Y., Lachmann M., Paar C., Nagy E., Csere P., *et al.*: "Molecular cloning and immunological characterization of a novel cDNA coding for PIBF". *J. Immunol.*, 2003, 171, 5956.
- [8] Szekeres-Bartho J., Barakonyi A., Polgar B., Par G., Faust Z., Palkovics T., Szereday L.: "The role of γ/δ T cells in progesterone-mediated immunomodulation during pregnancy: a review". *Am. J. Reprod. Immunol.*, 1999, 42, 44.
- [9] Srivastava M.D., Thomas A., Srivastava B.I., Check J.H.: "Expression and modulation of progesterone induced blocking factor (PIBF) and innate immune factors in human leukemia cell lines by progesterone and mifepristone". *Leuk. Lymphoma*, 2007, 48, 1610.
- [10] Hansen K.A., Opsahl M.S., Nieman L.K., Baker J.R. Jr., Klein T.A.: "Natural killer cell activity from the pregnant subjects is modulated by RU 486". *Am. J. Obstet. Gynecol.*, 1992, 166, 87.
- [11] Ivanova-Todorova E., Kyurkchiev D.S., Nalbanski A., Timeva T., Shterev A., Kyurkchiev S.D.: "Production and characterization of a novel monoclonal antibody against progesterone-induced blocking factor (PIBF)". *J. Reprod. Immunol.*, 2008, 78, 94.
- [12] Cohen R., Check J.H., DiAntonio A., Srivastava M.D.: "Progesterone induced blocking factor (PIBF), an immunosuppressive protein that inhibits natural killer (NK) cell cytolytic activity, detected 3 days after embryo transfer (ET)". *Fertil. Steril.*, 2012, 98, S28.
- [13] Check J.H., Cohen R., Jaffe A., Tran J., Sarumi M.: "An allogeneic stimulus is not a prerequisite for the expression of the immunomodulatory protein the progesterone induced blocking factor (PIBF)". *Am. J. Reprod. Immunol.*, 2013, 69, 21.
- [14] Chien C.H., Lai J.N., Liao C.F., Wang O.Y., Lu L.M., Huang M.I., *et al.*: "Mifepristone acts as progesterone antagonist of non-genomic responses but inhibits phytohemagglutinin-induced proliferation in human T cells". *Hum. Reprod.*, 2009, 24, 1968.
- [15] Van Voorhis B.J., Anderson D.J., Hill J.A.: "The effects of RU 486 on immune function and steroid-induced immunosuppression in vitro". *J. Clin. Endocrinol. Metab.*, 1989, 69, 1195.
- [16] Check J.H., Dix E., Sansoucie L.: "Support for the hypothesis that successful immunotherapy of various cancers can be achieved by inhibiting a progesterone associated immunomodulatory protein". *Med. Hypoth.*, 2009, 72, 87.
- [17] Check J.H., Dix E., Sansoucie L., Check D.: "Mifepristone may halt progression of extensively metastatic human adenocarcinoma of the colon - case report". *Anticancer Res.*, 2009, 29, 1611.

- [18] Check J.H., Dix E., Cohen R., Check D., Wilson C.: "Efficacy of the progesterone receptor antagonist mifepristone for palliative therapy of patients with a variety of advanced cancer types". *Anticancer Res.*, 2010, 30, 623.
- [19] Check J.H.: "The importance of the immunomodulatory protein, the progesterone induced blocking factor, in allowing cancer cells to escape immune surveillance and therapeutic considerations". *Anticancer Res.*, 2014, 34, 5860.
- [20] Check J.H., Sansoucie L., Chern J., Amadi N., Katz Y.: "Mifepristone treatment improves length and quality of survival of mice with spontaneous leukemia". *Anticancer Res.*, 2009, 29, 2977.
- [21] Check J.H., Sansoucie L., Chern J., Dix E.: "Mifepristone treatment improves length and quality of survival of mice with spontaneous lung cancer". *Anticancer Res.*, 2010, 30, 119.
- [22] Check J.H., Dix E., Wilson C., Check D.: "Progesterone receptor antagonist therapy has therapeutic potential even in cancer restricted to males as evidenced from murine testicular and prostate cancer studies". *Anticancer Res.*, 2010, 30, 4921.
- [23] Check J.H., Wilson C., Cohen R., Sarumi M.: "Evidence that mifepristone, a progesterone receptor antagonist can cross the blood brain barrier and provide palliative benefits for glioblastoma multiforme grade IV". *Anticancer Res.*, 2014, 34, 2385.
- [24] Check J.H., Check D., Cohen R., Sarumi M.: "Mifepristone causing complete remission of rapidly advancing leukemia with measurement of progesterone-induced blocking factor". *Anticancer Res.*, 2014, 34, 2413.

Address reprint requests to:
J.H. CHECK, M.D., Ph.D.
7447 Old York Road
Melrose Park, PA 19027 (USA)
e-mail: laurie@ccivf.com

The relationship between the daily step counts and low back pain during pregnancy

S. Morino¹, Y. Kajiwara¹, M. Ishihara², S. Nishiguchi^{1,3}, N. Fukutani¹, Y. Tashiro¹, M. Yamada⁴,
M. Yamashita², T. Aoyama¹

¹Department of Physical Therapy, Human Health Sciences, Kyoto University Graduate School of Medicine, Kyoto

²Kishokai Medical Corporation, Nagoya; ³Japan Society for the Promotion of Science, Tokyo

⁴Graduate School of Comprehensive Human Sciences, University of Tsukuba, Tokyo (Japan)

Summary

Purpose: To investigate the relationship between the change of daily step counts and low back pain (LBP) during pregnancy. **Materials and Methods:** Pregnant women at less than eight weeks of gestation (WG) were recruited. Daily step counts were measured with a pedometer. To assess LBP, the Oswestry disability index (ODI) score was recorded. Thirty-six individuals were divided into the LBP and non-LBP groups. The effect of step counts on LBP between the two groups was analyzed. **Results:** At 16–19 WG, step counts were not considerably changed in the non-LBP group but were significantly increased in the LBP group. At 24–27 and 32–35 WG, step counts were increased in the non-LBP group but were significantly decreased in the LBP group. **Conclusions:** Acute increase of daily step counts in early pregnancy is a risk for LBP, and gradual increases of step counts after mid-pregnancy is recommended for women.

Key words: Low back pain; Physical activity; Pregnancy

Introduction

Low back pain (LBP) is considered a minor complication, but is one of the most common discomforts, during pregnancy, and about 70–85% of all pregnant women experience LBP [1–5]. Some postpartum follow-up studies have shown that about 30–45% of women with pregnancy-related LBP complained about the symptom during three months after delivery [6, 7], and LBP persisted for three years in 17% of these women [8]. Pregnancy-related LBP often adversely influences the activities of daily living such as carrying, cleaning, sitting, and walking, hinders the ability of pregnant women to report for work, and causes sleep disturbance [9, 10]. Consequently, these symptoms lower the quality of life of many pregnant women [11]. Therefore, it is important to reduce pregnancy-related LBP to allow for a comfortable pregnancy.

Some randomized controlled trials have been conducted to prevent or reduce pregnancy-related LBP. Interventions that were found effective for LBP include acupuncture treatment, osteopathic manipulation, spinal manipulation and neuro-emotional technique [12–14]. Recently, some systematic physical exercises, for example, stability ball exercise, aerobic and strengthening exercises, and yoga, have succeeded in decreasing the prevalence of pregnancy-related LBP [15–17]. In addition, physical exercise during

pregnancy confers maternal benefits, including improved cardiac function, decreased risk for gestational hypertension and diabetes, improved mental state, and less complicated labor [18, 19]. Previous reports suggest that regular physical exercise is recommended not only for preventing pregnancy-related LBP, but also for maintaining desirable weight and improving the risk profiles of pregnant women [18].

Although some systematic physical exercises have been recommended for pregnancy-related LBP [20], they have some limitations. First, the trials were conducted at different times during pregnancy, and the effective timing for administering exercise is unknown. Second, although regular physical exercise during pregnancy is recommended, heavy or physically demanding work increases the risk of pregnancy-related LBP [21]. There is little knowledge about the ideal timing and intensity of physical activity for pregnant women. Furthermore, many women find it difficult to exercise during pregnancy. Some studies have shown that pregnant women commonly complain about hindrances to leisure-time physical exercise such as financial constraints, feeling of tiredness, being too busy, and experiencing physical limitations [22–25]. Therefore, investigating the activities of daily living, not a specific exercise, is necessary. Many physical activity guidelines containing step-based

recommendations were published for various population such as children, adolescents, adults, older adults, and special populations [26–28]. Similarly, for pregnancy, walking is the activity that is indispensable to everyday life. Nevertheless, few studies have focused on daily life activities in association with LBP and studies focusing on the benefits of daily walking are lacking [29]. Hence recommendations about daily activities such as walking during pregnancy, including the required amount of walking, are needed.

On the basis of the above considerations, data about the change of pregnancy-related LBP and the timing and amount of daily physical activity for the prevention or treatment of LBP is needed. The purpose of this study was to investigate the change of pregnancy-related LBP in pregnant women depending on the gestational period and to clarify the relationship between LBP and daily step counts during pregnancy.

Materials and Methods

Participants

Pregnant women were recruited at the obstetrics and gynecology clinics in Aichi Prefecture, Japan, between October 2011 and October 2012. One hundred and fifty-six women who met the inclusion criteria for the survey and agreed to participate in the study were observed from eight to 36 weeks of gestation (WG). Before inclusion, the authors provided verbal and written information about the study. The inclusion criteria were <8 WG and a singleton pregnancy. Women with serious orthopedic disorders or neurological diseases were excluded. Those with a high-risk pregnancy were also excluded. Participants were asked to fill out a questionnaire with personal information (height, weight before the pregnancy, parous history, medical history of LBP, and occupation). The authors provided them with an original leaflet for recording their step counts and Oswestry disability index (ODI) (version 2.1a) scores. The present study was carried out in accordance with the guidelines of the Declaration of Helsinki, and the study protocol was reviewed and approved by the Ethics Committee of the Kyoto University Graduate School of Medicine and written informed consent for the survey was obtained in accordance with the guidelines.

Measurement of daily step counts

Daily step counts were measured using a pedometer. Participants were instructed to wear the pedometer after the prenatal checkup for one week bimonthly (8–11, 16–19, 24–27, and 32–35 WG), except during bathing, sleeping, or performing water-based activities, and to record their step counts on the leaflet. The authors calculated the average number of steps per day during the week.

Assessment of LBP

To assess the LBP daily, ODI (version 2.1a) was used [30]. The ODI is a condition-specific tool used in the management of spinal disorders. It attempts to quantify the level of pain interference on physical activities by providing an estimate of disability expressed as a percentage score [31]. It has been used in previous studies on pregnancy-related LBP [32]. This index is a questionnaire with ten sections covering the assessment of pain intensity, personal care, lifting, walking, sitting, standing, sleeping, sex life, social life, and travelling. Each item is scored from 0 to 5, and the scores

Table 1. — Comparison of groups with and without low back pain.

	LBP (n = 21)	Non-LBP (n = 15)	p-value
(Unpaired <i>t</i> -test for the interval scale)	Mean ± SD	Mean ± SD	
Age, years	31.5 ± 4.7	32.9 ± 4.8	0.37
Height, m	1.58 ± 0.05	1.59 ± 0.05	0.34
Weight, kg	53.7 ± 15.0	54.1 ± 7.8	0.92
BMI before pregnancy, kg/m ²	21.7 ± 6.1	21.3 ± 2.5	0.80
Step counts			
8–11 WG	3614 ± 1891	3428 ± 1748	0.77
16–19 WG	4840 ± 2810	3676 ± 1728	0.16
24–27 WG	4340 ± 2043	4814 ± 2791	0.56
32–35 WG	3320 ± 1398	4410 ± 2764	0.13
(χ^2 test for the ordinal scale)	n (%)	n (%)	
Pre-pregnancy LBP	5 (23.8%)	3 (20.0%)	0.79
Parous history	11 (52.4%)	5 (33.3%)	0.26
Occupational status	8 (38.1%)	5 (33.3%)	0.91

are calculated as a percentage. A higher percentage score indicates a greater disability. The participants were instructed to record their answers to the ODI questions on the leaflet once a month (8, 12, 16, 20, 24, 28, 32, and 36 WG). In this study, the ODI score was calculated without the item “sex life,” as in previous studies, because of the low response rate in Japan (about 60%) and the reduction in the frequency of sexual activity during pregnancy [33, 34]. The authors determined the presence or absence of LBP in each pregnant woman on the basis of the score at the last period (36 WG) because the intensity of pregnancy-related LBP usually increases throughout pregnancy [35] and reaches a peak in both prevalence and severity during the third trimester [4, 36].

Statistical analyses

The participants were divided into two groups (LBP group and non-LBP group) according to the ODI score at 36 WG ($\geq 10\%$ or $< 10\%$, respectively), as in a previous study [32]. To compare the interval scale between the two groups, an unpaired *t*-test was used, and to compare the ordinal scale, the χ^2 test was used. For the change of ODI score through the pregnancy, a two-way analysis of variance (ANOVA) with repeated measures was conducted to determine any significant difference in the measurements by time between the two groups. To analyze the effect of daily step counts on LBP, a two-way ANOVA with repeated measures was used for the step counts of every time point (8–11, 16–19, 24–27, and 32–35 WG) in both groups. When a significant difference was found in the two-way ANOVA, the authors performed a multiple comparison using a paired *t*-test with Bonferroni correction, for verification. Data were entered and analyzed using the Statistical Package for the Social Sciences. For all analyses, $p < 0.05$ was considered statistically significant.

Results

Characteristics

Among the participants ($n = 156$), 83 had complete records on the leaflet, whereas 47 were lacking some records of step counts or ODI scores, or gave birth before 36

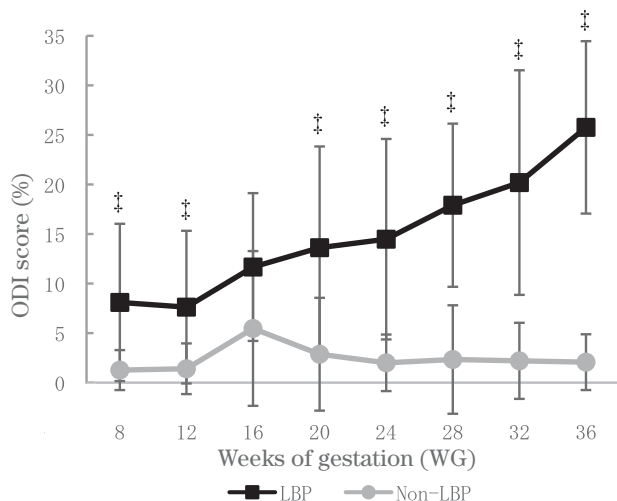


Figure 1. — Changes of the ODI score in the non-LBP and LBP groups. F-value (group \times time): [main effect] 11.64, [interaction] 11.81 ($p < 0.001$). ‡Significant differences were found between the two groups ($p < 0.0063$ [0.05/8]).

WG. The authors analyzed 36 subjects (mean age: 32.1 ± 4.7 years, body mass index (BMI): 21.7 ± 4.64 kg/m²). Among them, eight (22.2%) women have had LBP before pregnancy, six (4.4%) were multiparas, and 11 (30.6%) worked full- or part-time. The authors assigned 21 women into the LBP group and 15 women into the non-LBP group. The demographic characteristics of the LBP group and the non-LBP group are summarized in Table 1. There were no significant differences between the two groups (LBP vs. non-LBP) in age (31.5 ± 4.7 years vs. 32.9 ± 4.8 years), height (1.58 ± 0.05 m vs. 1.59 ± 0.05 m), BMI before pregnancy (21.7 ± 6.1 kg/m² vs. 21.3 ± 2.5 kg/m²), pre-pregnancy LBP ($n = 5$: 23.8% vs. $n = 3$: 20.0%), parous history ($n = 11$: 52.4% vs. $n = 5$: 33.3%), and occupation status ($n = 8$: 38.1% vs. $n = 5$: 33.3%).

Change of ODI score in the LBP and non-LBP groups

Figure 1 shows the changes of ODI score over time between the two groups. The change of ODI score was small in the non-LBP group, but progressively increased during pregnancy statistically significantly in the LBP group ($p < 0.0063$ [0.05/8]). When the score was compared between the two groups at each gestational period, the average ODI score of the LBP group was higher than that of the non-LBP group at eight, 12, 16, 20, 24, 28, 32, and 36 WG, with statistical significance ($p < 0.0063$ [0.05/8]).

Change of daily step counts in the LBP and non-LBP groups

Figure 2 shows the changes of step counts over time between the two groups. Significant differences were observed between the two groups with significant group \times

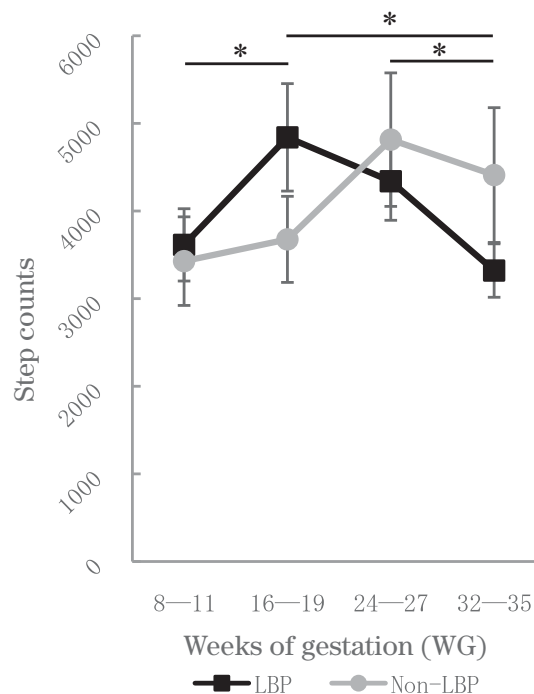


Figure 2. — Changes of physical activity in the non-LBP and LBP groups. F-value (group \times time): [main effect] 3.94, [interaction] 4.33 ($p = 0.015$). *Each provided meaningful alteration ($p < 0.013$ [0.05/4]).

time interactions (F-value: [main effect] 3.94, [interaction] 4.33; $p = 0.015$). From the first to the second trimester (from 8–11 to 16–19 WG), step counts were not considerably changed in the non-LBP group (from 3428 ± 1748 to 3676 ± 1728 steps), but were significantly increased in the LBP group (from $3,614 \pm 1,819$ to $4,840 \pm 2,810$ steps) ($p < 0.013$ [0.05/4]). Conversely, in the second trimester (from 16–19 to 24–27 WG), step counts were increased in the non-LBP group (from $3,676 \pm 1,728$ to $4,814 \pm 2,791$ steps) but were decreased in the LBP group (from 4840 ± 2810 to $4,340 \pm 2,043$ steps). From the second to the third trimester (from 24–27 to 32–35 WG), step counts gradually decreased in both groups (from $4,340 \pm 2,043$ to $3,320 \pm 1,398$ steps in the LBP group and from $4,818 \pm 2,791$ to $4,410 \pm 2,764$ steps in the non-LBP group). In the LBP group, the decrease in step counts was statistically significant ($p < 0.013$ [0.05/4]).

Discussion

The average ODI score of all participants increased during pregnancy. In comparing the score between the two groups, LBP had little impact on the daily life of women in the non-LBP group throughout their pregnancy, while it increasingly negatively affected the daily life of pregnant women in the LBP group (Figure 1). In comparing the

change of step counts between the two groups, the LBP group was increasingly more active than the non-LBP group from 8–11 to 16–19 WG. Thereafter, women in the LBP group reduced their step counts from 16–19 to 24–27 WG, whereas those in the non-LBP group increased their daily step counts (Figure 2).

The average ODI score of pregnancy in the current study was equivalent to those of previous reports [7, 37, 38]. Comparing the score between the two groups, the results suggest that in pregnant women with LBP in pregnancy, the impact of LBP on daily life increases gradually, and it might become increasingly difficult to minimize the symptoms. Therefore, preventing the occurrence of pregnancy-related LBP is desirable. Additionally, the difference in the score between the two groups became larger after 16 WG, and therefore the authors recommend treating LBP in pregnant women during this time. The ODI score indicated that LBP primarily disturbed the women's ability to maintain a sitting or standing position (data not shown). These results indicate that the simple daily movements of pregnant women are limited by pregnancy-related LBP. Therefore, recommendations for pregnant women about basic daily physical movements such as ways of standing that reduce the load on the back are needed.

From the findings of the current study, excessive increase in physical activity during early pregnancy might be a risk factor for LBP, and the authors recommend that pregnant women should be more active after mid-pregnancy. Physical symptoms during the first period of pregnancy, such as nausea and vomiting, usually begin and peak in the first trimester [39, 40] and these symptoms cause a reduction in physical activity among pregnant women [41]. In addition, pregnant women are advised to avoid strenuous activity to reduce the risk of miscarriage in the first trimester. Accordingly, the step counts of the study participants might be low in the first period. Nevertheless, according to ACOG Committee on Obstetric Practice, pregnant women are also advised to perform moderate exercises during pregnancy for the health benefits of both the fetus and the mother [42]. In the subjects of the LBP group, we can assume that the rapid increase of daily step counts from the first to the second trimester was due to the recommendation to exercise; however, as a result of increased steps, a rapid decrease of step counts occurred at the next period in this group. Pregnant women who have no risks related to exercise are advised to maintain regular physical activity (ACOG Committee on Obstetric Practice, 2002), and it was shown that women who performed regular exercise in the third trimester experienced less pregnancy-related pelvic girdle pain and that pre-pregnancy regular exercise was a factor for continued physical exercise in the third trimester [43]. However, as shown by the results of this study, excessive activity such as a high number of steps in early pregnancy may cause a reduction of activity level in the third trimester. Although, regular physical activity during pregnancy has

beneficial outcomes for women and their babies, incorrect timing of being active might be harmful because it may lead to increased LBP. In addition, the present authors used step counts, not special exercises, to investigate the influence of daily physical activity. The results of this study show that daily physical activity such as a moderate amount of steps daily can also have an influence on LBP. Therefore, the authors recommend that pregnant women should increase their daily physical activity after mid-pregnancy in order to minimize risk for LBP.

As the increase of daily step counts in early pregnancy was found to contribute to LBP, the influence of hormones should be considered. Serum relaxin concentrations reach a peak in the first trimester [44]. Relaxin increases the laxity of muscles and ligaments, and previous studies have reported a significant relation between serum relaxin concentrations and pelvic pain [35]. Excess physical activity such as a high number of steps from the first to the second trimester can place an extra load on the lumbar spine or pelvic girdle of pregnant women, causing LBP. In this study, LBP contributed to a reduction in the step counts of women in the LBP group. In addition, the reduction of daily physical activity might worsen LBP considering that moderate exercise is recommended for LBP. Therefore, the influence of hormones should be considered when advising pregnant women about physical activity.

This study has several limitations. First, there is a sampling bias because the number of target subjects decreased because of the long period of data collection, and results of the analysis might have deflection. Second, there were differences in the activity level of pregnant women between this study and other previous study. The change of physical activity with advancing pregnancy in this study is comparable to that reported in the study by Renault *et al.* [45]. However, from the data of step counts, the participants of this study were less active than those of the previous study throughout pregnancy. These differences in results suggest that physical activity in pregnancy depends not only on personal factors but also on the differences in lifestyle among pregnant women. Therefore, it can be difficult to make a recommendation about the ideal step count during pregnancy. In the future, a similar study should be performed with a large number of pregnant women with various lifestyles. The goal is recommendations to all pregnant women for daily physical activity during each trimester of the pregnancy in order to minimize risk for pregnancy-related LBP.

Conclusion

According to the ODI score in this study, LBP had little impact on the daily life of women throughout their pregnancy in the non-LBP group, whereas it increasingly disturbed the quality of life of women in the LBP group. This suggests that the impact of LBP on daily life during pregnancy increases gradually, and therefore measures to min-

imize the risk for LBP should be applied. Comparing the change of step counts between the two groups, the LBP group was more active than the non-LBP group in the first trimester. Thereafter, the LBP group reduced their daily step counts in the second trimester, whereas the non-LBP group increased their step counts. This finding shows that an increase in steps taken in the first trimester is a risk factor for LBP; therefore, pregnant women should be advised to be more active after the first trimester.

Acknowledgments

The authors are grateful to Nobuhiko Suganuma, Reiko Suzumura, and the staff of Kisho-kai for the recruitment of participants. They are also grateful to Yuiko Yonemori and the members of Human Health Sciences, Graduate School of Medicine, Kyoto University for their helpful advice.

References

- [1] Fast A., Weiss L., Ducommun E.J., Medina E., Butler J.G.: "Low-back pain in pregnancy. Abdominal muscles, sit-up performance, and back pain". *Spine (Phila Pa 1976)*, 1990, 15, 28.
- [2] Ostgaard H.C., Andersson G.B., Karlsson K.: "Prevalence of back pain in pregnancy". *Spine (Phila Pa 1976)*, 1991, 16, 549.
- [3] Ando F., Ohashi K.: "Using the posterior pelvic pain provocation test in pregnant Japanese women". *Nurs. Health Sci.*, 2009, 11: 3.
- [4] Mogren I.M., Pohjanen A.I.: "Low back pain and pelvic pain during pregnancy: prevalence and risk factors". *Spine (Phila Pa 1976)*, 2005, 30, 983.
- [5] Skaggs C.D., Prather H., Gross., George J.W., Thompson P.A., Nelson D.M.: "Back and pelvic pain in an underserved United States pregnant population: a preliminary descriptive survey". *J. Manipulative Physiol. Ther.*, 2007, 30, 130.
- [6] Ostgaard H.C., Roos-Hansson E., Zetherstrom G.: "Regression of back and posterior pelvic pain after pregnancy". *Spine (Phila Pa 1976)*, 1996, 21, 2777.
- [7] Gutke A., Lundberg M., Ostgaard H.C., Oberg B.: "Impact of postpartum lumbopelvic pain on disability, pain intensity, health-related quality of life, activity level, kinesiophobia, and depressive symptoms". *Eur Spine J.*, 2011, 20, 440.
- [8] Noren L., Ostgaard S., Johansson G., Ostgaard H.C.: "Lumbar back and posterior pelvic pain during pregnancy: a 3-year follow-up". *Eur Spine J.*, 2002, 11, 267.
- [9] Noren L., Ostgaard S., Nielsen T.F., Ostgaard H.C.: "Reduction of sick leave for lumbar back and posterior pelvic pain in pregnancy". *Spine (Phila Pa 1976)*, 1997, 22, 2157.
- [10] Sydsjo A., Sydsjo G., Wijma B.: "Increase in sick leave rates caused by back pain among pregnant Swedish women after amelioration of social benefits". A paradox. *Spine (Phila Pa 1976)*, 1998, 23, 1986.
- [11] Hueston W.J., Kasik-Miller S.: "Changes in functional health status during normal pregnancy". *J. Fam. Pract.*, 1998, 47, 209.
- [12] Licciardone J.C., Buchanan S., Hensel K.L., King H.H., Fulda K.G., Stoll S.T.: "Osteopathic manipulative treatment of back pain and related symptoms during pregnancy: a randomized controlled trial". *Am. J. Obstet. Gynecol.*, 2010, 202, 43.e41.
- [13] Peterson C.D., Haas M., Gregory W.T.: "A pilot randomized controlled trial comparing the efficacy of exercise, spinal manipulation, and neuro emotional technique for the treatment of pregnancy-related low back pain". *Chiropr. Man. Therap.*, 2012, 20, 18.
- [14] Ekdahl L., Petersson K.: "Acupuncture treatment of pregnant women with low back and pelvic pain--an intervention study". *Scand. J. Caring Sci.*, 2010, 24, 175-182.
- [15] Yan C.F., Hung Y.C., Gau M.L., Lin K.C.: "Effects of a stability ball exercise programme on low back pain and daily life interference during pregnancy". *Midwifery*, 2014, 30, 412.
- [16] Stafne S.N., Salvesen K.A., Romundstad P.R., Stuge B., Morkved S.: "Does regular exercise during pregnancy influence lumbopelvic pain? A randomized controlled trial". *Acta Obstet. Gynecol. Scand.*, 2012, 91, 552.
- [17] Martins R.F., Pinto e Silva J.L.: "Treatment of pregnancy-related lumbar and pelvic girdle pain by the yoga method: a randomized controlled study". *J. Altern. Complement. Med.*, 2014, 20, 24.
- [18] Ferraro Z.M., Gaudet L., Adamo K.B.: "The potential impact of physical activity during pregnancy on maternal and neonatal outcomes". *Obstet. Gynecol. Surv.*, 2012, 67, 99.
- [19] Demissie Z., Siega-Riz A.M., Evenson K.R., Herring A.H., Dole N., Gaynes B.N.: "Physical activity and depressive symptoms among pregnant women: the PIN3 study". *Arch. Womens Ment. Health*, 2011, 14, 145.
- [20] Pennick V., Liddle S.D.: "Interventions for preventing and treating pelvic and back pain in pregnancy". *Cochrane Database Syst. Rev.*, 2013, 8, CD001139.
- [21] Mogren I.M.: "Previous physical activity decreases the risk of low back pain and pelvic pain during pregnancy". *Scand. J. Public Health*, 2005, 33, 300.
- [22] Ning Y., Williams M.A., Dempsey J.C., Sorensen T.K., Frederick I.O., Luthy D.A.: "Correlates of recreational physical activity in early pregnancy". *J. Matern. Fetal. Neonatal. Med.*, 2003, 13, 385.
- [23] Duncombe D., Wertheim E.H., Skouteris H., Paxton S.J., Kelly L.: "Factors related to exercise over the course of pregnancy including women's beliefs about the safety of exercise during pregnancy". *Midwifery*, 2009, 25, 430.
- [24] Clapp J.F. 3rd.: "The effects of maternal exercise on early pregnancy outcome". *Am. J. Obstet. Gynecol.*, 1989, 161, 1453.
- [25] Cramp A.G., Bray S.R.: "A prospective examination of exercise and barrier self-efficacy to engage in leisure-time physical activity during pregnancy". *Ann. Behav. Med.*, 2009, 37, 325.
- [26] Tudor-Locke C., Craig C.L., Brown W.J., Clemes S.A., De Cocker K., Giles-Corti B., et al.: "How many steps/day are enough? For adults". *Int. J. Behav. Nutr. Phys. Act.*, 2011, 8, 79.
- [27] Tudor-Locke C., Craig C.L., Beets M.W., Belton S., Cardon G.M., Duncan S., et al.: "How many steps/day are enough? for children and adolescents". *Int. J. Behav. Nutr. Phys. Act.*, 2011, 8, 78.
- [28] Tudor-Locke C., Craig C.L., Aoyagi Y., Bell R.C., Croteau K.A., De Bourdeaudhuij I., et al.: "How many steps/day are enough? For older adults and special populations". *Int. J. Behav. Nutr. Phys. Act.*, 2011, 8, 80.
- [29] Heneweer H., Staes F., Aufdemkampe G., van Rijn M., Vanhees L.: "Physical activity and low back pain: a systematic review of recent literature". *Eur. Spine J.*, 2011, 20, 826.
- [30] Fairbank J.C., Pynsent P.B.: "The Oswestry Disability Index". *Spine (Phila Pa 1976)*, 2000, 25, 2940.
- [31] Davidson M.: "Rasch analysis of three versions of the Oswestry Disability Questionnaire". *Man. Ther.*, 2008, 13, 222.
- [32] Gutke A., Ostgaard H.C., Oberg B.: "Pelvic girdle pain and lumbar pain in pregnancy: a cohort study of the consequences in terms of health and functioning". *Spine (Phila Pa 1976)*, 2006, 31, E149.
- [33] Fujiwara A., Kobayashi N., Saiki K., Kitagawa T., Tamai K., Saotome K.: "Association of the Japanese Orthopaedic Association score with the Oswestry Disability Index, Roland-Morris Disability Questionnaire, and short-form 36". *Spine (Phila Pa 1976)*, 2003, 28, 1601.
- [34] Pauleta J.R., Pereira N.M., Graca L.M.: "Sexuality during pregnancy". *J. Sex Med.*, 2010, 7, 136.
- [35] Kristiansson P., Svardsudd K., von Schoultz B.: "Serum relaxin, symphyseal pain, and back pain during pregnancy". *Am. J. Obstet. Gynecol.*, 1996, 175, 1342.
- [36] Ostgaard H.C., Zetherstrom G., Roos-Hansson E.: "Back pain in relation to pregnancy: a 6-year follow-up". *Spine (Phila Pa 1976)*, 1997, 22, 2945.

- [37] Pierce H., Homer C.S., Dahlen H.G., King J.: "Pregnancy-related lumbopelvic pain: listening to Australian women". *Nurs Res Pract.*, 2012, 2012, 387428.
- [38] Haakstad L.A., Voldner N., Henriksen T., Bo K.: "Physical activity level and weight gain in a cohort of pregnant Norwegian women". *Acta Obstet. Gynecol. Scand.*, 2007, 86, 559.
- [39] Gadsby R., Barnie-Adshead A.M., Jagger C.: "A prospective study of nausea and vomiting during pregnancy". *Br. J. Gen. Pract.*, 1993, 43, 245.
- [40] Sherman P.W., Flaxman S.M.: "Nausea and vomiting of pregnancy in an evolutionary perspective". *Am. J. Obstet. Gynecol.*, 2002, 186, S190.
- [41] Smith C., Crowther C., Beilby J., Dandeaux J.: "The impact of nausea and vomiting on women: a burden of early pregnancy". *Aust. N. Z. J. Obstet. Gynaecol.*, 2000, 40, 397.
- [42] ACOG committee opinion.: "Exercise during pregnancy and the postpartum period. Number 267, January 2002. American College of Obstetricians and Gynecologists". *Int. J. Gynaecol. Obstet.*, 2002, 77, 79.
- [43] Haakstad L.A., Voldner N., Henriksen T., Bo K.: "Why do pregnant women stop exercising in the third trimester?". *Acta Obstet. Gynecol. Scand.*, 2009, 88, 1267.
- [44] O'Byrne E.M., Carriere B.T., Sorensen L., Segaloff A., Schwabe C., Steinetz B.G.: "Plasma immunoreactive relaxin levels in pregnant and nonpregnant women". *J. Clin. Endocrinol. Metab.*, 1978, 47, 1106.
- [45] Renault K., Norgaard K., Andreassen K.R., Secher N.J., Nilas L.: "Physical activity during pregnancy in obese and normal-weight women as assessed by pedometer". *Acta. Obstet. Gynecol. Scand.*, 2010, 89, 956.

Address reprint requests to:

S. MORINO, R.P.T

Department of Human Health Sciences

Graduate School of Medicine

Kyoto University

53 Kawahara-cho, Shogoin, Sakyo-ku

Kyoto 606-8507 (Japan)

e-mail: saori.51.m@gmail.com

Safety, efficacy, and tolerability of differential treatment to prevent and treat vaginal dryness and vulvovaginitis in diabetic women

D. Carati¹, A. Zizza², M. Guido³, A. De Donno³, R. Stefanizzi¹, R. Serra⁴, I. Romano⁴,
C. Ouedraogo⁵, M. Megha⁶, A. Tinelli⁷

¹ Research & Development Department, Ekuberg Pharma srl, Martano; ² Institute of Clinical Physiology, National Research Council, Lecce; ³ Laboratory of Hygiene, Department of Biological and Environmental Sciences and Technologies, Faculty of Sciences, University of Salento, Lecce; ⁴ Department of Diabetology, Poliambulatory "Cittadella della Salute", Lecce (Italy)
⁵ Department of Obstetrics and Gynecology, Teaching Hospital of Ouagadougou, Ouagadougou (Burkina Faso)
⁶ Laboratory of Clinical Pathology, Poliambulatory "Cittadella della Salute" Lecce; ⁷ Department of Obstetrics and Gynecology, Division of Experimental Endoscopic Surgery, Imaging, Technology and Minimally Invasive Therapy, Vito Fazzi Hospital, Lecce (Italy)

Summary

Background: Problems affecting the vaginal tract in diabetic women are very often neglected. The efficacy and safety of three gynecological treatments in diabetic women have been assessed. **Materials and Methods:** A single-blind randomized progressive trial on 48 diabetic women affected by vaginal dryness, dyspareunia, and recurrent Candida infections was carried out. The ICIQ Vaginal Symptoms (ICIQ-VS) questionnaire was administered. **Results:** The analysis of the parameters of ICIQ-VS questionnaire among the three groups showed significant difference only for "dragging pain" ($p = 0.019$) and "soreness" ($p = 0.028$). In all groups and for all parameters of the questionnaire, improvement of symptoms was observed. In particular, in Group 1 for all symptoms a highly significant difference was observed, to support the already known benefits of the products and of the proposed combination. Significant improvement was also observed in Group 2. **Conclusions:** The proposed treatment with DermoXEN® Ultracalming Special for diabetics and DermoXEN® Vitexyl vaginal gel exert effective moisturizing and soothing action. Indeed, the aforementioned products have been proven effective for the main gynecological problems of diabetic women.

Key words: Diabetes; vulvovaginal discharge; vaginal dryness; DermoXEN®; Candida Albicans.

Introduction

Diabetes mellitus (DM) is one of the most popular non-communicable diseases all over the world, affecting approximately 346 million people. In many developing countries and in newly industrial countries, the epidemic is growing fast [1, 2]. Data from the Centers for Disease Control and Prevention (CDC) and from the National Center for Health Statistics in the United States indicate that the number of people affected by DM has increased considerably from 1980 and 2010, passing from around 5.6 to 20.9 million people [3, 4]. Today, the main problems for diabetic people are no longer problems related to survival, but those related to chronic complications of diabetes, both microangiopathic (retinopathy, nephropathy, neuropathy) and macroangiopathic (ischaemic heart disease, arteriopathy of the lower limbs, arteriopathy of the supra-aortic trunks) [5]. Patients affected by DM are more susceptible to bacterial and fungal infections [6]. Numerous studies have proven a close correlation between hyperglycaemia and candidiasis [7, 8]. Diabetic women are more predisposed to a high risk

of recurrent vaginitis caused by *Candida* spp, leading to inflammations that result in pain during sexual intercourse (dyspareunia) and cystitis, especially caused by *Escherichia coli*. These problems are often associated with vaginal dryness, redness, burning and itching during sexual intercourse. Problems of female sexual dysfunction (FSD) affect from 30% up to 78% women [9]. It is estimated that the prevalence in diabetic women ranges between 20% and 80% [9, 10]. Indeed, diabetic women are more predisposed to develop a decline in sexual desire, dyspareunia, reduction in sexual arousal, and poor lubrication [11, 12]. Furthermore, a recent study underlines that vaginal dryness is more common in diabetic women compared to non-diabetic women [13]. DM is also recognised as a predisposing factor to vulvovaginal candidiasis, as well as pregnancy, use of broad spectrum antibiotics, high-dose estrogen oral contraceptives and continuous administration of drugs [14, 15]. Symptomatic vulvovaginal infections caused by *Candida* spp. have higher prevalence in patients with diabetes compared to the general population [16]. Hyperglycaemia is the main cause

Revised manuscript accepted for publication April 27, 2015

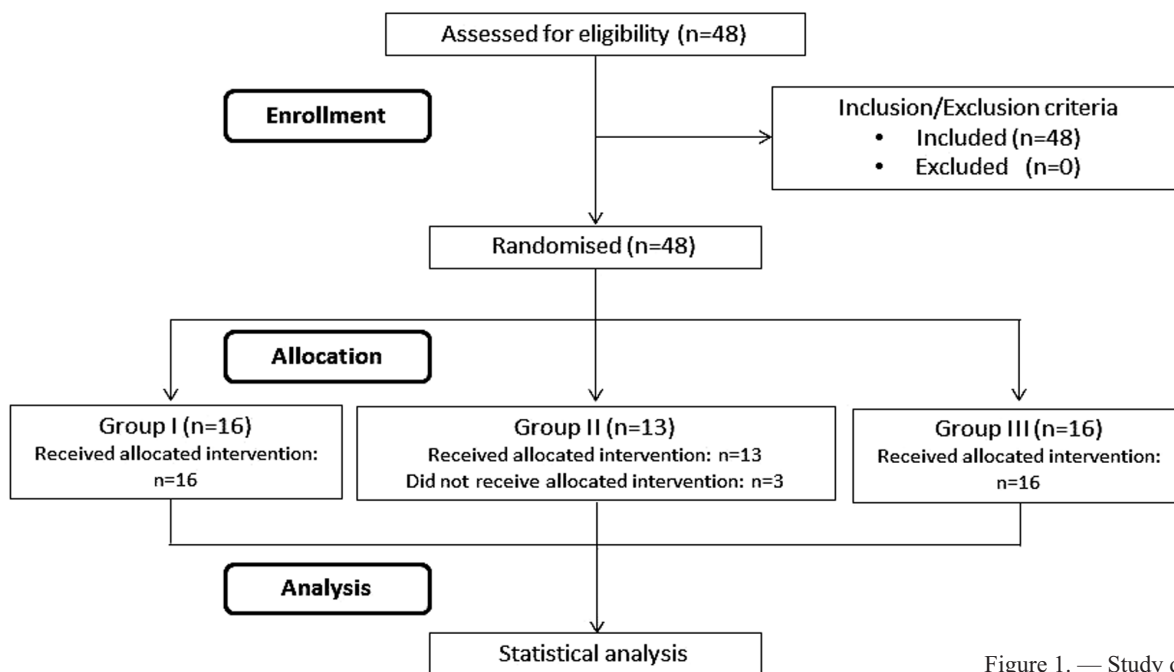


Figure 1. — Study design.

of increased susceptibility to vulvovaginal candidiasis in diabetic patients. High blood glucose level in the genital tissues enhances yeast adhesion and growth. *Candida albicans* binds to epithelial cells more easily in diabetic women, independently if they are premenopausal, post-menopausal or pregnant women [17]. Moreover, hyperglycaemia can influence the humoral response, causing a reduction in neutrophils, chemotaxis, and phagocytosis [18].

The aim of study is to evaluate the efficacy of different gynecological treatments for vaginal dryness, itching, burning, dyspareunia, and recurrent *Candida* infections in diabetic women. In particular, in this randomized study was compared efficacy, safety and tolerability of DermoXEN® Ultracalming Special for Diabetics and DermoXEN® Vitexyl gel used in combination with DermoXEN® Vitexyl gel and another gel based on mineral oil.

Materials and Methods

Forty-eight diabetic women afferent to the Operative Unit (O.U.) of Diabetology of the Local Health Unit (LHU) of Lecce affected by vaginal dryness, dyspareunia, and recurrent *Candida* infections, were selected for this single-blind, randomized, progressive study in the period between August 2013 and March 2014.

Ethical approval was granted by the Ethics Committee of LHU of Lecce (Protocol n. 1394, August 8, 2013) and written informed consent was obtained for each enrolled women. Three women, belonging to Group 2 dropped out. Women were divided as follows (Figure 1): Group 1: 16 women used daily (for 14 days) DermoXEN® Ultracalming SD for intimate cleansing in the morning and they applied DermoXEN® Vitexyl gel before going to bed; Group 2: 13 women used daily (for 14 days) DermoXEN® Vi-

texyl gel before going to bed; Group 3: 16 women used daily (for 14 days) a common commercially available gel containing mineral oil (Replens gel) before going to bed. Eligible patients were randomized to one of the three treatment at the enrolling time using a 1:1:1 allocation ratio.

Women over 18 years and under 65 years of age affected by diabetes type I and/or II with problems of vaginal dryness and dyspareunia, women did not take the contraceptive pill for at least six months, women did not take corticosteroids and/or antihistamines for at least six months were included in the study.

Women under 18 years of age, over 65 years of age, pregnant, took the contraceptive pill, took corticosteroids and/or antihistamines, with serious chronic-degenerative pathologies, with serious infectious diseases, and that used different cleaning vaginal products were excluded from the study.

Information on general characteristics (age, body mass index, parity, DM type, and glycemia) were collected. The ICIQ Vaginal Symptoms (ICIQ-VS) questionnaire in order to collect information on dryness, burning, itching, dyspareunia, vaginal symptoms, sexual matter and quality of life before (T0) and after (T1) the use of selected medical devices was administered [16]. Furthermore, data on pH value and frequency and species of *Candida* before and after treatment were collected. The yeast isolation were detected in the analysis laboratory of LHU by the commercial kit.

Medical devices

DermoXEN® Ultracalming Special for Diabetics contains high molecular weight hyaluronic acid which moisturizes and protects internal and external mucous membrane, lactic acid which exerts a rebalancing effect of vaginal pH, *Fucus vesiculosus* extract which provides moisturization and protection of the mucous membrane and dihydro-avenanthramide, a biotechnological byproduct exerting a soothing and calming action against irritations. DermoXEN® Vitexyl vaginal gel is a medical device essentially composed of water and glycerin, with high molecular weight hyaluronic acid and panthenol. It exerts an intense moisturizing action inside the

Table 1. — General characteristics of study participants variable.

	Group 1 (n = 16)	Group 2 (n = 13)	Group 3 (n = 16)	p
Age (years ± SD)	49.5 ± 10.5	49.8 ± 14.3	55.8 ± 9.7	0.243*
BMI (kg/m ² ± SD)	28.9 ± 5.4	26.9 ± 3.1	26.2 ± 4.4	0.230*
Parity (n ± SD)	2.2 ± 1.3	2.3 ± 1.1	2.4 ± 1.5	0.925*
Diabetes mellitus				
Type 1 (n, %)	5 (31.2)	7 (53.8)	8 (50.0)	
Type 2 (n, %)	11 (68.8)	6 (46.2)	8 (50.0)	0.408**
Glycemia (mg/dl ± SD)	135.3 ± 30.5	142.3 ± 36.8	119.4 ± 25.2	0.127*

SD: standard deviation; * Statistical analysis was performed by two-way ANOVA.
** Statistical analysis was performed by χ^2 .

vaginal tract. Replens vaginal gel contains mineral oil, mucoadhesive substances, glycerin and sodium hydroxide especially designed to moisturize and lubricate the vaginal tract and take care of irritation and itching related to vaginal dryness.

Statistical analysis

For the statistical analysis, one goal of the proposed study was to test the null hypothesis that the proportion positive is identical in the two populations. The criterion for significance (α) was set at 0.05. The test was two-tailed, which means that an effect in either direction was interpreted. The sample size was calculated by a 95% prerequisite confidence interval (CI) and an estimated error rate exceeding $\pm 20\%$. With 80% power, 16 women in each group were needed.

The statistical analysis of all collected data was performed using the SPSS software package (version 18.0). Continuous variables were expressed as mean and standard deviation (SD), while categorical variables in absolute values. Homogeneity of general characteristic data at baseline was verified by analysis of variance (ANOVA) for continuous variables and by a Chi-square test for categorical variables. Intragroup changes were evaluated with the paired Student *t*-test. A *p*-value of <0.05 was considered to be significant.

Results

The average age of enrolled women was 49.5 ± 10.5 years in Group 1, 49.8 ± 14.3 years in Group 2, and 55.8 ± 9.7 years in Group 3 ($p = 0.243$). The analysis of the other general characteristics (BMI, parity, glycaemia, and diabetes type) did not show any differences among the study groups (Table 1).

The pH value and vaginal symptoms (dryness, burning, itching, and dyspareunia) showed significant differences among the three groups only for “dryness” ($p = 0.024$) and “dyspareunia” ($p = 0.011$) at T0 and for pH ($p = 0.017$) and “dyspareunia” ($p = 0.013$) at T1 (Table 2).

Intragroup comparison at T0 and T1 showed significant reduction for pH and vaginal symptoms, except for “burning” and “itching” in Group 3. In Group 1, a highly significant difference was observed for all symptoms (Table 2). The analysis of the parameters described in ICIQ-VS questionnaire, showed significant difference only for “dragging

Table 2. — Vaginal symptoms in the three groups of diabetic women, after enrollment (T0) and after 14 days (T1).

	Group 1			Group 2			Group 3			G1vsG2vsG3	
	T0	T1	<i>p</i> *	T0	T1	<i>p</i> *	T0	T1	<i>p</i> *	<i>p</i> (T0)**	<i>p</i> (T1)**
pH	5.9 ± 0.8	5.2 ± 0.8	<0.0001	5.9 ± 1.0	5.6 ± 0.9	0.0019	6.3 ± 0.9	6.1 ± 0.8	0.0188	0.334	0.017
Dryness	6.1 ± 3.1	3.3 ± 2.3	<0.0001	3.5 ± 3.2	1.7 ± 1.9	0.0012	3.2 ± 3.0	2.1 ± 2.3	0.0005	0.024	0.127
Burning	1.3 ± 1.7	0.6 ± 1.1	0.0066	1.1 ± 1.0	0.5 ± 0.2	0.0136	0.9 ± 1.1	0.8 ± 1.0	0.3332	0.728	0.609
Itching	2.4 ± 1.6	0.7 ± 0.9	<0.0001	2.1 ± 1.3	0.9 ± 0.9	0.0025	1.3 ± 1.4	1.0 ± 1.3	0.0555	0.103	0.697
Dyspareunia	2.4 ± 1.7	1.3 ± 1.2	0.0004	0.7 ± 0.9	0.2 ± 0.6	0.0124	1.3 ± 1.4	0.7 ± 0.9	0.0011	0.011	0.013
<i>ICIQ Questionnaire Vaginal symptom</i>											
Dragging pain	0.6 ± 0.9	0.1 ± 0.2	0.0235	0.2 ± 0.6	0.0 ± 0.0	0.1902	0.8 ± 0.9	0.5 ± 0.8	0.0962	0.173	0.019
Soreness	0.2 ± 0.8	0.0 ± 0.0	0.2162	0.2 ± 0.4	0.0 ± 0.0	0.0821	0.6 ± 1.0	0.3 ± 0.6	0.0197	0.290	0.028
Reduced sensation	0.4 ± 0.8	0.2 ± 0.5	0.1881	0.1 ± 0.6	0.1 ± 0.6	-	0.1 ± 0.3	0.1 ± 0.3	-	0.452	0.936
Loose vagina	0.2 ± 0.4	0.1 ± 0.2	0.0825	0.3 ± 0.5	0.1 ± 0.3	0.0821	0.3 ± 0.8	0.0 ± 0.0	0.1359	0.949	0.570
Lump felt inside	0.1 ± 0.3	0.1 ± 0.2	0.3332	0.1 ± 0.3	0.1 ± 0.3	-	0.0 ± 0.0	0.0 ± 0.0	-	0.378	0.570
Lump seen outside	0.0 ± 0.0	0.0 ± 0.0	-	0.0 ± 0.0	0.0 ± 0.0	-	0.0 ± 0.0	0.0 ± 0.0	-	-	-
Dry vagina	2.5 ± 1.9	0.4 ± 0.6	0.0002	1.3 ± 1.3	0.5 ± 0.7	0.0060	1.5 ± 1.3	0.0 ± 0.0	0.0002	0.079	0.674
Faecal evacuation	0.0 ± 0.0	0.0 ± 0.0	-	0.0 ± 0.0	0.0 ± 0.0	-	0.0 ± 0.0	0.0 ± 0.0	-	-	-
<i>Sexual matter</i>											
Worries about vagina interfere with sex-life	1.1 ± 1.1	0.3 ± 0.6	0.0014	0.5 ± 0.7	0.3 ± 0.5	0.1902	0.6 ± 0.7	0.5 ± 0.7	0.1639	0.154	0.622
Relationship affected	0.9 ± 1.0	0.2 ± 0.4	0.0066	0.7 ± 0.7	0.2 ± 0.4	0.0075	0.7 ± 0.9	0.5 ± 0.8	0.0410	0.851	0.288
Sex life spoilt	3.6 ± 3.6	1.3 ± 1.6	0.0009	3.1 ± 3.2	2.3 ± 2.2	0.0145	2.7 ± 2.2	2.1 ± 1.8	0.0011	0.723	0.305
<i>Quality of life</i>											
Quality of life affected	5.1 ± 3.2	2.5 ± 2.1	<0.0001	2.9 ± 2.6	1.9 ± 1.6	0.0207	3.5 ± 2.5	2.7 ± 2.2	0.0103	0.099	0.575

Data are expressed mean score ± SD.

* Statistical analysis was performed by paired Student's *t*-test (two-tailed). ** Statistical analysis was performed by two-way ANOVA.

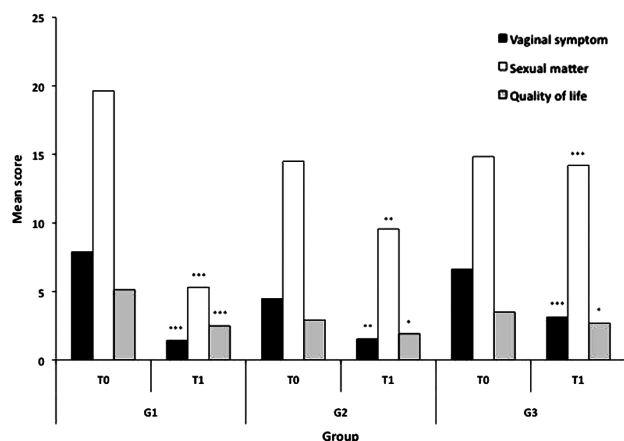


Figure 2. — Mean scores for 3 domains of the ICIQ-VS questionnaire (vaginal symptoms, sexual matters and quality of life), in the three groups of diabetic women, after enrollment (T0) and after 14 days (T1). Asterisks identify statistical intra-group comparisons with paired t test (* $p < 0.05$; ** $p < 0.01$; *** $p < 0.0001$).

pain” ($p = 0.019$) and “soreness” ($p = 0.028$) among the three groups. Improvement in symptoms was observed in all groups and for all parameters of the questionnaire. No enrolled patients had “lump seen outside” and “faecal evacuation” at T0 and T1. In Group 1, sexual matters and quality of life showed a significant improvement for all parameters, while the “worries about vagina interfere with sex-life” was not improved significantly in Group 2 and 3 (Table 2). The score analysis at T0 and T1 was carried out using the validated ICIQ-VS questionnaire [19]. Analysis of score data underlined highly significant improvement ($p < 0.0001$) in Group 1 for all domains. A similar trend was observed in Group 3, with exception of the quality of life, because the perceived improvement was lower compared to Group 1 ($p < 0.05$). Significant improvement was observed in Group 2 for the domains related to vaginal symptoms ($p < 0.01$), sexual matters ($p < 0.01$), and quality of life ($p < 0.05$) (Figure 2). All *Candida* species isolated by vaginal mucous membrane at T0 were found negative after the treatment period (T1) in all groups (Table 3).

Discussion

Problems of the vaginal tract in diabetic women are very often neglected, although they entail a reduced quality of life. Indeed, vaginal dryness, caused by angiopathic and neuropathic complications typical of diabetes, often causes dyspareunia. Moreover, high glucose level in normal secretion, as well as in body fluids (for example in blood), increases the risk of bacterial and fungal infections, especially caused by *Candida* spp. A recent study confirmed that diabetes is associated with *Candida Albicans* and non-*C. Albicans* fungal infections in Brazilian women with incidence

Table 3. — Frequency of *Candida* species isolated from the vaginal mucosa in the three groups of diabetic women, after enrollment (T0) and after 14 days (T1).

Isolated species	G1*		G2		G3	
	T0 n. (%)	T1 n. (%)	T0 n. (%)	T1 n. (%)	T0 n. (%)	T1 n. (%)
<i>C. albicans</i>	2 (12.5)	0	0	0	1 (6.25)	0
<i>C. krusei</i>	2 (12.5)	0	0	0	0	0
<i>C. glabrata</i>	2 (12.5)	0	0	0	0	0
<i>C. sphaerica</i>	0	0	1 (7.7)	0	0	0

* Statistical analysis was performed by χ^2 : T0 vs. T1 $p < 0.0001$.

of isolation of 55.6% and 44.4%, respectively. The high incidence of reported cases underlines that a particular attention and further investigation regarding to *Candida* infections in DM patients are needed [20]. In the study no adverse effects were observed in the three treatments. The medical device DermoXEN® Ultracalming Special for Diabetics was produced to give a daily non-pharmacological treatment to diabetic women in order to tackle effectively the problems of the vaginal tract. This device was tested in association with a vaginal gel. Results obtained as balance of pH level around acidic values (more suitable for the vaginal environment), as treatment of *Candida* spp. and Female Sexual Function Index score (by administering specific questionnaires) demonstrated the efficacy of the device in management of vaginal complications in diabetic women. Indeed, the results of pH analysis, before and after the combined application of DermoXEN® Ultracalming Special for Diabetics and DermoXEN® Vitexyl vaginal gel showed a highly significant improvement ($p < 0.0001$) that was not observed in the remaining two groups. Acid pH values (4.0-5.5) determine a chemico-physical situation conducive to the growth of Doderlein flora inhibiting the growth of pathogenic ones. In particular, *Candida* species are not able to develop hyphae (pathogenic profile) in acidic pH conditions [21]. The analysis of score data showed a highly significant improvement ($p < 0.0001$) in Group 1 for all domains. A similar trend was observed in Group 3, with the exception of the domain related to quality of life, that the perceived improvement was lower than Group 1 ($p < 0.05$). The treatment of Groups 1 and 2 was more effective than that of the Group 3 and no adverse event was observed. *Candida* infections at T0 were observed mainly in Group 1 (6 in 7 women); the combined treatment with DermoXEN® Ultracalming SD and DermoXEN® Vitexyl gel proved to be effective to restore an adequate vaginal pH level, inhibiting the growth of *Candida Albicans*. At the beginning and at the end of the treatment, the intragroup comparison showed significant reduction of pH values and vaginal symptoms, except for “burning” and “itching” in Group 3. In Group 1 a highly significant difference was observed for all symptoms (Table 2), highlighting greater effectiveness of the proposed product combination. Comparing the effects of the proposed

treatments in Groups 1 and 2, the moisturizing and soothing action of DermoXEN® Ultracalming Special for diabetics emerges. Significant improvement was observed in Group 2 for vaginal symptoms ($p < 0.01$), sexual matters ($p < 0.01$) and quality of life ($p < 0.05$), demonstrating the real efficacy of the DermoXEN® Vitexyl vaginal gel. Indeed, it has been especially designed in order to improve lubrication of the vaginal tract and improve sexual intercourse in case of dyspareunia. Therefore, this trial shows that DermoXEN® Ultracalming Special for diabetics and DermoXEN® Vitexyl gel have a safety and efficacy profile suitable for the treatment of the main problems of the vaginal tract in diabetic women. The association with DermoXEN® Vitexyl vaginal gel is recommended in order to improve the symptoms in diabetic women.

Acknowledgments

Special thanks to Federica Traldi and Elvia Sicuro for their intense and fruitful collaboration.

References

- [1] World Health Organization (WHO): "Diabetes". Available at: <http://www.euro.who.int/en/health-topics/noncommunicable-diseases/diabetes>
- [2] Pascale R., Vitale M., Esposito S.: "Update on diabetic foot infections". *Infezioni in Medicina*, 2012, 20, 157.
- [3] Centers for Disease Control and Prevention (CDC): "National Diabetes Surveillance System". Available at: <http://www.cdc.gov/diabetes/statistics/index.htm>.
- [4] National Institute for Health and Clinical Excellence: "Diabetic foot-inpatient management of people with diabetic foot ulcers and infection (2011)". Available at: <http://guidance.nice.org.uk/CG119.6/4/2011>.
- [5] Apelqvist J., Bakker K., van Houtum W.H., Schaper N.C., International Working Group on the Diabetic Foot (IWGDF) Editorial Board: "Practical guidelines on the management and prevention of the diabetic foot: based upon the International Consensus on the Diabetic Foot (2007). Prepared by the International Working Group on the Diabetic Foot". *Diabetes Metab. Res. Rev.*, 2008, 24, 181.
- [6] Sobel J.D.: "Vulvovaginal candidosis". *Lancet*, 2007, 369, 1961.
- [7] Antony G., Saralaya V., Gopalkrishna Bhat K., Shalini Shenoy M., Shivananda P.G.: "Effect phenotypic switching on expression of virulence factors by *Candida albicans* causing candidiasis in diabetic patients". *Rev. Iberoam. Micol.*, 2009, 26, 202.
- [8] Brumar A., Rosu A.F., Calina D., Bitu A., Rosu L., Zlatian O., Iliet A., et al.: "Study concerning vulvovaginal candidiasis in women with diabetes". *Eur. J. Hosp. Pharm.*, 2012, 19, 213.
- [9] Elnashar A.M., El-Dien Ibrahim M., El-Desoky M.M., Ali O.M., El-Sayd Mohamed Hassan M.: "Female sexual dysfunction in Lower Egypt". *BJOG*, 2007, 114, 201.
- [10] Erol B., Tefekli A., Ozbey I., Salman F., Dincag N., Kadioglu A., Tellaloglu S.: "Sexual dysfunction in type II diabetic females: a comparative study". *J. Sex. Marital. Ther.*, 2002, 28, 55.
- [11] Meston M.C., Frohlich P.F.: "Update on female sexual function". *Curr. Opin. Urol.*, 2001, 11, 603.
- [12] Enzlin P., Mathieu C., Van den Bruel A., Bosteels J., Vanderschueren D., Demyttenaere K.: "Sexual dysfunction in women with type I diabetes: a controlled study". *Diabetes Care*, 2002, 25, 672.
- [13] Abu Ali R.M., Al Hajeri R.M., Khader Y.S., Shegem N.S., Ajlouni K.M.: "Sexual Dysfunction in Jordanian diabetic women". *Diabetes Care*, 2008, 31, 1580.
- [14] Sobel J.D.: "Candidal vulvovaginitis". *Clin. Obstet. Gynecol.*, 1993, 36, 153.
- [15] Scudamore J.A., Tooley P.J., Allcom R.J.: "The treatment of acute and chronic vaginal candidosis". *Br. J. Clin. Pract.*, 1992, 46, 260.
- [16] Rowe B.R., Logan M.N., Farrell I., Barnett A.H.: "Is candidiasis the true cause of vulvovaginal irritation in women with DM?" *J. Clin. Pathol.*, 1990, 43, 644.
- [17] Segal E., Soroka A., Schechter A.: "Correlative relationship between adherence of *Candida albicans* to human vaginal epithelial cells in vitro and candidal vaginitis. Sabouraudia". *J. Med. Vet. Mycol.*, 1984, 22, 191.
- [18] Bagdade J.D., Root R.K., Bulgar R.J.: "Impaired leukocyte function in patients with poorly controlled diabetes". *Diabetes*, 1974, 23, 9.
- [19] Price N., Jackson S., Avery K., Brookes S., Abrams P.: "Development and psychometric evaluation of the ICIQ Vaginal Symptoms Questionnaire: the ICIQ-VS". *BJOG*, 2006, 113, 700.
- [20] Gunther L.S.A., Rodrigues M.H.P., Gimenes F., Pimenta de Abreu A.L., Consolaro M.A.L., Svidzinski T.I.E.: "Prevalence of *Candida albicans* and non-*albicans* isolates from vaginal secretions: comparative evaluation of colonization, vaginal candidiasis and recurrent vaginal candidiasis in diabetic and non-diabetic women". *Sao Paulo Med. J.*, 2014, 132, 116.
- [21] Konno N., Ishii M., Nagai A., Watanabe T., Ogasawara A., Mikami T., Matsumoto T.: "Mechanism of *Candida albicans* Transformation in Response to Changes of pH". *Biol. Pharm. Bull.*, 2006, 29, 923.

Address reprint requests to:
 D. CARATI, Ph.D.
 Research & Development
 Ekuberg Pharma s.r.l.
 Via Pozzelle, 36
 73025 Martano, Lecce (Italy)
 e-mail: davide.carati@ekubergpharma.com

Is urinary incontinence during and after pregnancy related to family history? A web-based survey among postpartum women (motherfit project)

P. Albers-Heitner^{1,2}, L. Bekkers³, H. Moosdorff^{4,5}, B. Berghmans⁵, P. Verdonk⁶

¹ Department of Obstetrics and Gynecology, Maastricht University Medical Center, Maastricht

² School for Public Health and Primary Care: CAPHRI, Maastricht; ³ Amsterdam Medical Center (AMC), Amsterdam

⁴ Fysio Papendrecht, Papendrecht; ⁵ Pelvic Care Center Maastricht, Maastricht University Medical Center, Maastricht

⁶ Department Medical Humanities, VU University Medical Center, EMGO Institute for Health and Care Research, Amsterdam (the Netherlands)

Summary

Purpose of investigation: The authors studied whether family history of urinary incontinence (UI) is associated with pre- and postpartum UI. **Materials and Methods:** In 2010, Dutch postpartum women at three months were approached to fill in a Web-based questionnaire on UI and risk factors (body mass index, BMI), parity, pelvic organ prolapse, and family history. Results were analyzed with Chi-square and logistic regression analyses. **Results:** 162 (61%) questionnaires were analyzed, 76 (47%) women reported UI before, during and/or after pregnancy, of which 34% also reported a UI family history. Sixteen (19%) out of 84 women without UI reported UI family history ($p = 0.05$). BMI was associated with prepartum UI ($p = 0.035$), but the association disappears when adding family history. Women with unknown UI family history had higher risk for postpartum UI. **Conclusion:** UI family history is associated with UI during pregnancy. More awareness and research is needed whether adding family history questions on UI in prepartum consultations improves timely prevention.

Key words: Urinary incontinence; Family history; Hereditary; Pregnancy; Postpartum period; Body mass index; Prevention.

Introduction

During pregnancy, 32% to 64% of women experience urinary incontinence (UI) and at one year postpartum, 15% to 30% still experience UI [1]. UI is defined as the complaint of any involuntary leakage of urine [2] and affects one in three women during their life [3]. UI brings along high costs in terms of impact on health related quality of life and costs for surgery and its complications [4, 5]. Effective treatment is available for the most prevalent types of UI such as lifestyle advice, bladder training, and pelvic floor muscle training (PFMT) [6]. However, help-seeking patients are mostly only prescribed absorbent pads [7].

Understanding the cause of this common health problem is critical to improve treatment and prevention. Pregnancy and vaginal delivery are potential inciting factors to alter the pelvic floor function and contribute to UI [8], as well as increased body mass index (BMI), physically heavy work, and maternal age [9]. Some studies have shown that specific genotypes and chromosome expression can predispose for pelvic floor dysfunctions and are correlated with UI [8, 10]. A hardly studied predisposing risk factor for UI is family history. In a recent Catalan study, besides age and BMI, family history was significantly correlated with UI during pregnancy [11]. Ertunc *et al.* found a prevalence of stress urinary

incontinence (SUI) of 71.4% among mothers and 24.6% among sisters of women who had surgery for SUI, compared with 40.3% among mothers and 11.6% among sisters of continent women [12]. Furthermore, UI started significantly younger in 'incontinent families' [12]. These findings suggest a genetic influence on pelvic floor disorders including UI [10, 13]. Currently, few studies are published to identify the role of genes and the onset of UI. For example, Söderberg *et al.* concluded that women with SUI have a decreased gene signal and weaker immune-reactivity for fibrillin, important for elasticity [10]. A loss of elasticity in tissue can lead to pelvic floor disorders like UI and pelvic organ prolapse (POP).

Obviously hereditary factors do play a role in the development and occurrence of pelvic floor disorders. Family history taking is not uncommon in primary healthcare. For instance, family doctors routinely ask for family history in cardiovascular diseases. This is a relatively simple and low cost risk assessment that reflects predisposing factors such as hereditary factors, but also shared cultural and environmental factors that might be related to intervening factors such as BMI [14]. According to a review study about the use and outcomes of family history questionnaires, accurate family history information can be used to identify pop-

Revised manuscript accepted for publication May 25, 2015

Table 1. — Characteristics of study population.

Variable	Total n (%) n=162	UI during pregnancy n (%)		UI post partum n (%)	
		Yes n=65 (40)	No n=97 (60)	Yes n=52 (32)	No n=110 (68)
Age in years					
18-24	7 (4.3)	3 (4.6)	4 (4.1)	3 (5.8)	4 (3.6)
25-34	126 (77.8)	45 (69.2)	81 (83.5)	38 (73.1)	88 (80.0)
35-44	29 (17.9)	17 (26.2)	12 (12.4)	11 (21.2)	18 (16.4)
≥45	0 (0)	-	-	-	-
Education					
No or lower education	17 (10.5)	10 (15.3)	7 (7.3)	8 (15.3)	9 (8.9)
Intermediate vocational education	65 (40.1)	28 (43.1)	37 (38.1)	21 (40.3)	44 (40.0)
Higher vocational education	80 (49.4)	27 (41.5)	53 (54.6)	23 (44.2)	57 (51.8)
Smoking - missing values: 1					
No	148 (91.9)	60 (93.8)	88 (90.7)	47 (92.2)	101 (91.8)
Yes	13 (8.1)	4 (6.3)	9 (9.3)	4 (7.8)	9 (8.2)
Alcohol consumption					
No	94 (58.0)	36 (55.4)	58 (59.8)	27 (51.9)	67 (60.9)
Yes	68 (42.0)	29 (44.6)	39 (40.2)	25 (48.1)	43 (39.1)
Other diseases*					
Asthma or COPD	1 (0.6)	0 (0)	1 (1.0)	0 (0)	1 (0.9)
Hay fever, a lot of sneezing	25 (15.4)	9 (13.8)	16 (16.5)	8 (15.4)	17 (15.5)
Inguinal hernia or abdominal hernia	3 (1.9)	1 (1.5)	2 (2.1)	2 (3.8)	1 (0.9)
Varices	15 (9.3)	13 (20.0)	2 (2.1)	7 (10.3)	8 (7.3)
Thyroid defect	3 (1.9)	2 (3.1)	1 (1.0)	1 (1.9)	2 (1.8)
Persistent back disease	7 (4.3)	3 (4.6)	4 (4.1)	1 (1.9)	6 (5.5)
Arthrosis	1 (0.6)	1 (1.5)	0 (0)	1 (1.9)	0 (0)
Diabetes mellitus	1 (0.6)	0 (0)	1 (1.0)	0 (0)	1 (0.9)
Connective tissue disease	1 (0.6)	1 (1.5)	0 (0)	1 (1.9)	0 (0)
Other chronic diseases	11 (6.8)	3 (4.6)	8 (8.2)	3 (5.8)	8 (7.3)
No other diseases	94 (58.0)	32 (49.2)	62 (63.9)	28 (53.8)	66 (60.0)

*None of the women reported arthritis or other chronic rheumatism. UI = urinary incontinence, COPD: chronic obstructive pulmonary disease.

ulations at risk [15]. To the present authors' knowledge, studies about the association between family history and UI in pregnant and postpartum women are scarce.

The present authors hypothesize that a family history of UI is associated with UI during pregnancy and shortly after delivery. The risk factors maternal age, BMI, and physically heavy work are taken into account, as well as parity, cesarean birth and POP.

The aim of this study was to gain insight in the relationship between a family history of UI and UI during pregnancy and shortly after delivery.

Materials and Methods

Motherfit (www.motherfit.nl) [16], a quality improvement strategy in the Netherlands, is a multidisciplinary screening and supervised PFMT program for pregnant and postpartum women to prevent postpartum pelvic floor disorders. Timely information/education on lifestyle, healthy bladder and bowel behaviour, and intensive group PFMT supervised by registered pelvic physical therapists are provided. Special attention is paid to training principles, eg, adequate dose-response, type of training, training frequency, intensity, overload, follow-up, and adherence to the protocol [17]. In 2010, prior to the start of the motherfit program, a Web-based questionnaire was filled in by postpartum women to

test the feasibility of the program. The women were approached by their midwife, gynecologist, family doctor or physical therapist and gave their informed consent. All postpartum women in the present pilot regions of 18 years and older who gave birth after 37 weeks gestation were eligible. These women delivered their baby two to three months before filling out the questionnaire. Reasons for exclusion or non-participation were registered by the health care professionals. Because women's participation was anonymous, reminding was impossible. Upon consultation, the Medical Ethics Committee of the Maastricht region, the Netherlands, stated that ethical approval was not needed given the non-invasive character of the survey. However, all participating women gave their informed consent to the health professionals that approached them for the survey.

Measurement instrument

Participants answered 198 questions: personal characteristics (eg, age, maternal age, education level, occupation, length, weight), general health (eg, prevalence of other diseases than UI), smoking, alcohol consumption, obstetrical history (parity, type of delivery), urogynecological history (of which five items about family history, UI, POP), pelvic floor disorders (93 items), knowledge, and experience with pelvic floor muscle exercises. Finally, to find barriers and facilitators for implementation of the motherfit program, women were asked for their perceptions of the motherfit program (the questionnaire is available on request). In the present study only the most relevant outcomes are presented to answer the study question.

Table 2. — Comparison of women with and without UI during pregnancy and post partum on risk factors.

Risk factors		Total n=162	UI during pregnancy N (%)			UI post partum N(%)		
			Yes n=65 (40)	No n=97 (60)	<i>p</i> -value	Yes n=52 (32)	No n=110 (68)	<i>p</i> -value
Maternal age	mean (SD)	28.9 (3.5)	29.1 (3.8)	28.7 (3.2)	n.s.	28.8 (3.8)	29.0 (3.4)	n.s.
BMI (4 missing)	mean (SD)	24.3 (4.8)	25.3 (6.1)	23.6 (3.6)	n.s.	24.9 (6.3)	24.1 (4.0)	n.s.
Parity	n (%)							
	1	76 (46.9)	25 (38.5)	51 (52.6)		23 (44.2)	53 (48.2)	
	2	51 (31.5)	13 (33.8)	29 (29.9)	n.s.	15 (28.8)	36 (32.7)	n.s.
	3 or more	35 (21.6)	18 (27.7)	17 (17.5)		14 (26.9)	21 (19.1)	
Cesarean birth	n (%)							
	No	136 (84.0)	53 (81.5)	83 (85.6)	n.s.	43 (82.7)	93 (84.5)	n.s.
	Yes	26 (16.0)	12 (18.5)	14 (14.4)		9 (17.3)	17 (15.5)	
Pelvic organ prolapse	n (%)							
	No	147 (90.7)	57 (87.7)	90 (92.8)	n.s.	44 (84.6)	103 (93.6)	n.s.
	Yes	15 (9.3)	8 (12.3)	7 (7.2)		8 (15.4)	7 (6.4)	
Physically heavy work	n (%)							
	No	115 (71.0)	46 (70.8)	69 (71.7)		35 (67.3)	80 (72.7)	
	0-5 years	17 (10.5)	4 (6.2)	13 (13.4)	n.s.	5 (9.6)	12 (10.9)	n.s.
	> 6 years	30 (18.5)	15 (23.1)	15 (15.5)		12 (23.1)	18 (16.4)	
Family history	n (%)							
	No	69 (42.6)	22 (33.8)	47 (48.5)		15 (28.8)	54 (49.1)	
	Yes	40 (24.7)	23 (35.4)	17 (17.5)	0.030	17 (32.7)	23 (20.9)	0.042
	I don't know	53 (32.7)	20 (30.8)	32 (33.0)		20 (38.5)	32 (29.0)	
UI during pregnancy	n (%)							
	No	97 (59.9)				9 (17.3)	88 (80.0)	
	Yes	65 (40.1)				43 (82.7)	22 (20.0)	n.s.

BMI = body mass index. Four women did not fill in their weight. Therefore their BMI could not be calculated.

UI = urinary incontinence; n.s. = not significant, $p > 0.05$.

Outcome measures

The primary analysis was based on the question: 'Have you ever experienced urine loss during your last pregnancy (also if it was only a little bit)?' measured the prevalence of UI during pregnancy. The prevalence of UI postpartum was measured as: 'Have you ever experienced urine loss after your last delivery (also if it was only a little bit)?' Both questions were derived from the '3 Incontinence Questions' (3IQ), a simple, quick, and non-invasive symptom-based patient reported approach with acceptable accuracy for classifying UI and appropriate for use in primary care settings [17]. Answering categories were yes/no.

In secondary analysis, severity of UI is reported with the International Consultation on Incontinence Questionnaire Short Form (ICIQ-UI SF) [18]. This is a grade A, easy to use questionnaire which gives a severity sum-score of UI frequency, perceived UI quantity (weighted items), and the UI impact on quality of life (Visual Analogue Scale (VAS) score from zero (no impact) to ten (most severe impact) [18, 19]. Overall score ranges from zero (no UI) to 21 (most severe UI).

Risk factors for UI

Participants were asked for their age at their first delivery (maternal age). Furthermore, the authors asked for height and weight before their first pregnancy, in order to calculate the BMI (weight (kg)/height (m)²), parity, type of delivery (vaginal or cesarean birth), and whether they ever had experienced POP (seeing or feeling a bulge). The performance of physically heavy work was measured with: 'Did you regularly perform physically heavy work in the past? (a lot of lifting or bending or standing for a long time)' and the answers yes/no, and when yes, how many years they performed heavy work when they count all the years together. The answers were categorized in '0-5 years', '6-10 years', '11-15 years', and 'more than 15 years'. Because there was a low number of participants with a high number of years of physical work, answers were recoded in no physical work, 0-5 years, and more than 6 years.

Family history is measured as: 'Does or did your mother or your mother's mother ever experience UI?' Answering categories varied between 'yes', 'no', 'I don't know (anymore)'.

Analyses

First, the number and percentage of participants for each demographic variable were defined (Table 1). *T*-Tests and Chi-square tests were performed to compare women with and without UI and risk factors during pregnancy as well as postpartum (Table 2). In logistic regression analyses, three blocks were entered to analyse the relationship of maternal age, BMI, parity, cesarean birth, POP, physically heavy work, and finally family history with UI during pregnancy and UI after delivery. The women in the present group hardly reported other health problems during or after pregnancy, so no equation for these problems was relevant. A significant *p*-value was set at 0.05. The analyses were performed with the computer program PASW Statistics 18.

Results

Returned were 169 questionnaires (response rate 64%). One participant did not give birth and the results of six others were not correctly transferred from the web to the dataset, which led to 162 included women (Table 1). Most women are between 25 and 34 years, and 89.5% of the participants had either finished intermediate or higher occupational education. Hardly any other health problems were mentioned besides UI; hay fever or a lot of sneezing was most commonly experienced (Table 1). Women experiencing UI during pregnancy had more often varices than women who did not experience UI ($\chi^2 = 14.905$; $df = 1$; $p < 0.001$).

Of 76 women who reported UI at any moment, 52 had UI after the last pregnancy. Of these women 22 report UI before and during pregnancy and 21 UI started during pregnancy. Only nine women report the onset of UI after delivery. Of the 24 women who did not have UI postpartum, 17 had UI during their last pregnancy.

Table 3. — Logistic regressions for the association between risk factors and UI.

Block	OR	UI during pregnancy CI of 95%		<i>p</i>	OR	UI postpartum CI of 95%		<i>p</i>
		lower	upper			lower	upper	
Maternal age BMI	1.067	0.965	1.179	0.205	1.004	0.907	1.112	0.941
Parity	1.082	1.006	1.164	0.033	1.035	0.963	1.113	0.347
Cesarean birth	1.447	0.965	2.170	0.074	1.190	0.785	1.804	0.412
POP	1.034	0.414	2.584	0.942	0.861	0.328	2.258	0.761
R ²	1.754	0.561	5.489	0.334	2.631	0.872	7.943	0.086
	0.086				0.043			
Maternal age BMI	1.027	0.922	1.145	0.626	0.989	0.884	1.106	0.843
Parity	1.083	1.005	1.167	0.035	1.032	0.959	1.110	0.398
Cesarean birth	1.388	0.919	2.095	0.119	1.163	0.764	1.770	0.483
POP	1.114	0.437	2.841	0.822	0.878	0.332	2.324	0.793
Physical work	1.778	0.556	5.684	0.332	2.619	0.863	7.942	0.089
No physical work ref.								
in years: 0-5	0.368	0.096	1.416	0.146	0.776	0.220	2.741	0.694
> 6	1.445	0.598	3.494	0.414	1.434	0.586	3.510	0.430
R ²	0.113				0.051			
Maternal age BMI	1.034	0.926	1.155	0.553	0.983	0.876	1.102	0.768
Parity	1.079	0.999	1.165	0.053	1.027	0.953	1.107	0.484
Cesarean birth	1.230	0.797	1.899	0.349	1.071	0.686	1.673	0.762
POP	1.282	0.485	3.390	0.616	1.140	0.414	3.138	0.800
Physical work	1.541	0.468	5.070	0.477	2.423	0.777	7.555	0.127
No physical work ref.								
in years: 0-5	0.400	0.101	1.584	0.192	0.880	0.243	3.186	0.846
> 6	1.447	0.588	3.562	0.421	1.483	0.592	3.714	0.400
Family history (no FH is ref.)								
Yes	2.641	1.069	6.523	0.035*	2.399	0.935	6.157	0.069
I don't know	1.332	0.596	2.975	0.485	2.578	1.101	6.038	0.029*
R ²	0.149				0.100			

* statistically significant: $p < 0.05$. UI = urinary incontinence; OR = odds ratio; CI = confidence interval; BMI = body mass index; R² = Coefficient of determination, POP = pelvic organ prolapse, for POP and cesarean birth, FH = family history: 0 = no (ref.) and 1 = yes.

Almost half of the women were primiparae. Women with three or more children reported more often UI during pregnancy or afterwards than women with fewer children, although not statistically significant ($p = 0.525$). UI and family history are significantly related both during and after pregnancy (Table 2).

Further analysis (not in table) shows that, of the 76 women who reported UI before and/or during and/or after pregnancy, 24 women (34%) reported a family history of UI and 52 were not aware of a family history or had no family history, whereas only 16 (19%) out of 84 women without UI reported a family history ($X^2 = 3.43$; $df = 1$; one-tailed $p = 0.05$). In the whole sample, 53 women were unaware of their UI family history and 69 women reported not having a family history of UI.

Table 3 shows the results of the logistic regression analyses that were performed to define the association between potentially mediating factors and UI. Table 3 also shows that BMI is significantly associated with UI during pregnancy ($p = 0.035$), (block 1 and 2), but the association disappears when family history is entered in the equation (block 3). Besides, BMI is not associated with UI postpar-

tum. Of all the known risk factors, only family history is associated with UI during pregnancy ($p = 0.035$). Women with a mother or their mother's mother who has experienced UI had 2.6 times more often UI during their pregnancy. No significant relationship is found between family history and UI shortly after pregnancy. However, women who reported that they did not know whether their mother or their mother's mother had experienced UI did have a higher risk for UI shortly after pregnancy. This rather large group contains women with and without a family history of UI. Exploration of the relation between severity of UI (ICIQ-UI SF sum-score) and family history did not yield significant results (data not shown).

Discussion

First, results of the present study point at a significant role of family history as a determinant for UI during pregnancy, as reported earlier [11]. Other studies also show a relation between UI and family history/genetics [10, 12]. The relationship between family history and UI shortly after pregnancy is less clear. Second, a longer continuum

than often assumed (with UI starting during or after pregnancy) seems to exist of UI. Of 76 women who reported UI at any moment, 52 had UI after the last pregnancy and 22 of these women report UI already before and during pregnancy, and for 21 women UI started during pregnancy, whereas only nine women report the onset of UI after delivery. Third, interestingly for BMI, a statistically significant relationship with UI during pregnancy was seen which disappeared when family history was added to the regression. Vaginal delivery itself does not seem to cause the onset of UI for most women. In practice, focus is often directed towards mode of delivery and avoiding injury at delivery in order to prevent pelvic floor dysfunction including UI. For UI however, this may not be the main and only inciting factor. Later in life, pregnancy and vaginal delivery are found to disappear as a risk factor for UI [1], but women who *experience UI during pregnancy* are at higher risk for consistent UI and should be counseled on the importance of timely prevention of pelvic floor dysfunction [20]. Overweight is described as an independent modifiable risk factor for UI [11, 21]. The question is whether mothers' BMI before pregnancy or mothers' weight gain during pregnancy is relevant. Wesnes *et al.* found that weight gain during pregnancy was associated with UI during pregnancy but not after vaginal delivery [22]. The present authors found a significant role of BMI before pregnancy for the occurrence of UI during pregnancy, but only when family history was not included in the analysis. Possibly, family history also plays a role in BMI before pregnancy and hence, this may have confounded the positive relationship between BMI and UI during pregnancy in the same direction.

In the present study, 53 women were unaware of their UI family history, which supports earlier statements that patients are hardly aware of their family history [23]. However, family history may provide interesting information for early detection of populations at risk. Surely, the rather large 'I don't know'- group contained both women with and without a family history of UI, and this group had a significantly higher risk for UI after pregnancy. The number of women who did know their family history may have been too small to show a statistically significant relationship with UI after pregnancy.

Clinical implications

The present authors included one question to measure family history to assess the influence of the family history via the mother's (grand)mother, but sisters, fathers, as well as grandfathers can also experience UI. Potential risk factors for men are age, lower urinary tract symptoms and infections, functional and cognitive impairment, neurological disorders, and prostatectomy [1]. Therefore, including the sister's and father's history might increase the strength of the relationship between UI and family history, which may now be underestimated. Adding more questions about family history can increase validity and reliability.

Strength and limitations

Before drawing any conclusions on the basis of the present findings, the following needs to be considered. The study population of 162 postpartum women with an acceptable response rate of 62%, is comparable to the average Dutch population, with regards to the number of cesarean births, the average parity, and maternal age [24]. Selection bias for this Web-based survey seems unlikely since 95% of Dutch households have internet access and 94 to 98% of Dutch women aged between 16-54 use the internet weekly [25]. Women hardly reported physically heavy work. This reduces extrapolation of the results to women who do have heavy physical work. On the other hand, data were rather complete because the Web-based system did not allow for missing items on most questions.

One of the potential limitations of this study is that it relies on self-reported retrospective data instead of medical records. Consequently, there is a chance on recall bias where people report inaccurate or incomplete information for questions about UI in the past and family history [26]. Moreover, as the study is cross-sectional, the authors can only test for statistical associations and not for causal relationships.

Recommendations for research and clinical practice

The relationship between family history and pelvic floor disorders including UI must be further explored and a family history questionnaire for UI can assure validity and reliability of measurements. Accurate family history information can be used to identify populations at risk [15]. Family history is a known risk factor for many chronic diseases, including cancer, diabetes, and asthma [23]. For instance, a positive impact on cancer screening adherence was achieved with the use of family history questionnaires [15]. Therefore, a family history questionnaire may be an easy and inexpensive way to define risk groups for UI. Wilson *et al.* developed the, not yet validated, UR-CHOICE scoring system which provides women with prelabour advice regarding prevention of pelvic floor disorders. This system includes characteristics of mother and child, but also family history and pelvic floor disorders history [27]. If women are at risk of developing pelvic floor disorders, a multidisciplinary screening and supervised PFMT program like Motherfit [16] can be started. Next to this, longitudinal studies about the natural course of UI [9], and the relation of family history with other predisposing, inciting, and intervening factors for UI are needed. Therefore, both in primary and secondary obstetric care, the present findings may have clinical implications as family history may help to identify women at risk for UI.

Conclusions

Family history of UI is associated with UI during pregnancy. Awareness of relevant family history among researchers, healthcare providers, and the population is needed.

More research is needed whether adding family history questions on UI in prepartum consultations improves prevention of UI by a preventive pelvic floor muscle training program. This can improve quality of life of women and might reduce healthcare costs.

References

- [1] Milsom I., Altman D., Lapitan M., Nelson R., Sillén N., Thom D.: "Committee 1. Epidemiology of urinary (UI) and faecal (FI) incontinence and pelvic organ prolapse (POP)". In: Abrams P., Cardozo L., Khoury S., Wein A., (eds). Incontinence 4th International Consultation on Incontinence, Paris July 5-8, 2008. Plymouth: Health Publication Ltd., 2009, 86.
- [2] Haylen B.T., De Ridder D., Freeman R.M., Swift S.E., Berghmans B., Lee J., et al.: "An international urogynecological association (IUGA)/international continence society (ICS) joint report on the terminology for female pelvic floor dysfunction". *Neurourol. Urodyn.*, 2010, 29, 4.
- [3] Boyle R., Hay-Smith E.J., Cody J.D., Mørkved S.: "Pelvic floor muscle training for prevention and treatment of urinary and fecal incontinence in antenatal and postnatal women: A short version Cochrane review". *Neurourol Urodyn.*, 2014, 33, 269. Epub 2013 Apr 24.
- [4] DeLancey J.: "The hidden epidemic of pelvic floor dysfunction: Achievable goals for improved prevention and treatment". *Am. J. Obstet. Gynecol.*, 2005, 192, 1488.
- [5] Murphy M., Holzberg A., van Raalte H., Kohli N., Goldman H., Lucente V., et al.: "Time to rethink: an evidence-based response from pelvic surgeons to the FDA Safety Communication: "UPDATE on Serious Complications Associated with Transvaginal Placement of Surgical Mesh for Pelvic Organ Prolapse". *Int. Urogynecol. J.*, 2012, 23, 5.
- [6] Dumoulin C., Hunter K.F., Moore K., Bradley C.S., Burgio K.L., Hagen S., et al.: "Conservative management for female urinary incontinence and pelvic organ prolapse review 2013: Summary of the 5th international consultation on incontinence". *Neurourol Urodyn.*, 2014. Nov 15. doi: 10.1002/nau.22677. [Epub ahead of print].
- [7] Albers-Heitner P., Berghmans B., Nieman F., Lagro-Janssen T., Winkens R.: "How do patients with urinary incontinence perceive care given by their general practitioner? A cross-sectional study". *Int. J. Clin. Pract.*, 2008, 62, 508.
- [8] DeLancey J.O.L., Kane Low L., Miller J.M., Patel D.A., Tumbarello J.A.: "Graphic integration of causal factors of pelvic floor disorders: an integrated life span model". *Am. J. Obstet. Gynecol.*, 2008, 199, 610.e1.
- [9] Brækken I.H., Majida M., Ellström Engh M., Holme I.M., Bø K.: "Pelvic floor function is independently associated with pelvic organ prolapse". *BJOG*, 2009, 116, 1706.
- [10] Söderberg M.W., Byström B., Hammarström M., Malmström A., Ekman-Ordeberg G.: "Decreased gene expression of fibrillin-1 in stress urinary incontinence". *Neurourol Urodyn.*, 2010, 29, 476.
- [11] Solans-Domenech M., Sanchez E., Espuna-Pons M., Pelvic Floor Research Group (Grup de Recerca del Sòl Pelvià; GRESP): "Urinary and anal incontinence during pregnancy and postpartum: incidence, severity, and risk factors". *Obstet. Gynecol.*, 2010, 115, 618.
- [12] Ertunc D., Tok E.C., Pata O., Dilek U., Ozdemir G., Dilek S.: "Is stress urinary incontinence a familial condition?" *Acta Obstet Gynecol Scand.*, 2004, 83, 912.
- [13] Lince S., van Kempen L., Vierhout M., Kluivers K.: "A systematic review of clinical studies on hereditary factors in pelvic organ prolapse". *Int Urogynecol J.*, 2012, 23, 1327.
- [14] Valdez R., Yoon P.W., Qureshi N., Green R.F., Khoury M.J.: "Family History in Public Health Practice: A Genomic Tool for Disease Prevention and Health Promotion". *Annu. Rev. Public Health*, 2010;31(1):69.
- [15] Reid G.T., Walter F.M., Brisbane J.M., Emery J.D.: "Family history in public health practice: a genomic tool for disease prevention and health promotion". *Public Health Genomics*. 2009, 12, 73.
- [16] Albers-Heitner P., Berghmans B.: "MotherFit! Een belangrijke kans voor de bekkenfysiotherapie en NVFB-ZwangerFit!® 'Kwaliteitsverbetering van de zorg ter preventie van urine-incontinentie bij post partum vrouwen: haalbaarheid van een multidisciplinair geprotocolleerd programma bestaand uit cliënt informatie & educatie, beoordeling en groepstraining". *NVFB Bulletin*. 2009, 21, 24.
- [17] Stafne S.N., Salvesen K., Romundstad P.R., Torjusen I.H., Mørkved S.: "Does regular exercise including pelvic floor muscle training prevent urinary and anal incontinence during pregnancy? A randomised controlled trial". *BJOG*, 2012, 119, 1270.
- [18] Avery K., Donovan J., Peters T., Shaw C., Gotoh M., Abrams P.: "ICI-Q: a brief and robust measure for evaluating the symptoms and impact of urinary incontinence". *Neurourol. Urodyn.*, 2004, 23, 322.
- [19] Abrams P., Avery K., Gardener N., Donovan J.: "The International Consultation on Incontinence Modular Questionnaire: www.icq.net". *J. Urol.*, 2006, 175, 1063.
- [20] van Brummen H.J., Bruinse H.W., van de Pol G., Heintz A.P., van der Vaart C.H.: "Bothersome lower urinary tract symptoms 1 year after first delivery: prevalence and the effect of childbirth". *BJU Int.*, 2006, 98, 89.
- [21] Snooks S., Swash M., Mathers S., Henry M.: "Effect of vaginal delivery on the pelvic floor: a 5-year follow-up". *Br. J. Surg.*, 1990, 77, 1358.
- [22] Wesnes S.L., Hunskaar S., Bo K., Rortveit G.: "Urinary incontinence and weight change during pregnancy and postpartum: a cohort study". *Am. J. Epidemiol.*, 2010, 172, 1034.
- [23] Weir E.: "Using a family history tool to prevent chronic diseases". *CMAJ*, 2005, 172, 631.
- [24] Stichting Perinatale Registratie Nederland: "10 jaar Perinatale Registratie in Nederland. De grote lijnen". Utrecht: Stichting Perinatale Registratie Nederland, 2011.
- [25] Eurostat, Data in focus 50/2010. Available at: <http://ec.europa.eu/eurostat/documents/4168041/5947493/KS-QA-10-050-EN.PDF/4ab62190-2216-4dd4-a67f-d589e007cd3e?version=1.0>
- [26] Portney L.G., Watkins M.P.: "Foundations of clinical research". 3rd ed. Upper Saddle River, NJ: Pearson Prentice Hall, 2009, 892.
- [27] Wilson D., Dorman J., Milsom I., Freeman R.: "UR-CHOICE: can we provide mothers-to-be with information about the risk of future pelvic floor dysfunction?" *Int. Urogynecol. J.*, 2014, 25, 1449.

Address reprint requests to:
 H.F.A. MOOSSDORFF-STEINHAUSER, MSc
 Pelvic Care Center Maastricht
 Maastricht University Medical Center
 P.O. Box 5800, 6202 AZ Maastricht
 (The Netherlands)
 e-mail: heidi.moosdorff@gmail.com

Complete longitudinal vaginal septum resection. Description of a bloodless new technique

I. Chatzipapas, D. Zacharakis, L. Michala, T. Grigoriadis, P. Antsaklis, A. Protopapas

First Department of Obstetrics and Gynecology, National and Kapodistrian University of Athens, "Alexandra" Hospital, Athens (Greece)

Summary

Purpose of investigation: To describe a novel approach for longitudinal vaginal septum (LVS) resection. *Materials and Methods:* Two cases of young girls with a uterus didelphys and a longitudinal vaginal septum. The technique consisted in grasping the vaginal septum with a laparoscopic 33-cm long bipolar cutting forceps, five-mm in diameter, and divided it to its midportion towards the two cervixes. *Results:* In both cases, the procedure was straightforward, uncomplicated, completed within three minutes and the patients were discharged four hours later. It was associated with minimal blood loss, short recovery time, absence of local ischemia, and optimum healing process. *Conclusion:* The authors believe that surgical safety, efficacy and operative result make bipolar cutting forceps a tailored option for LVS resection.

Key words: Uterus didelphys; Longitudinal vaginal septum; Bipolar cutting forceps.

Introduction

Uterine anomalies are thought to affect approximately one to two percent of women, depending on the population that is assessed. Although the majority is asymptomatic and can remain undetected, a proportion is linked to sexual, reproductive, and obstetric complications and will need investigation and specialist management [1]. The aim of this article was to describe a novel approach regarding surgical management of longitudinal vaginal septum (LVS).

Materials and Methods

The authors present two cases of young girls having a uterus didelphys and a complete LVS. The first one was a 19-year-old girl that coincidentally suffered from congenital thrombocytopenia. Her usual platelet count was ranged between 15,000 and 20,000. Her condition became evident due to difficulty at coitarche and bleeding because of trauma to the septum during intercourse. The second case concerned a 21-year-old girl presenting with severe dysmenorrhea and dyspareunia since her first sexual relations.

Results

The operations were performed under general anesthesia with the patients in stirrups and in both cases the same surgical technique was used. The urinary bladder was emptied with a catheter. The external genitalia and vagina were prepped in the standard fashion.

The vaginal septum was grasped with a laparoscopic 33-cm long bipolar cutting forceps five-mm in diameter and

divided to its midportion towards the two cervixes (Figure 1). The bipolar cutting forceps incorporates precision bipolar forceps for grasping and coagulation, and a surgical cutting blade positioned between the forceps jaws to allow transection of the coagulated tissue. The bipolar forceps was connected to an electrosurgery unit set at 40 W. Repeated applications of the bipolar diathermy were performed, as necessary for complete septum excision.

Both procedures were straightforward, uncomplicated, and completed within three minutes. They were also associated with minimal blood loss despite the patient's bleeding diathesis in the first case. The immediate postoperative period was uneventful and the patients were discharged four hours later. In both cases postoperative follow-up revealed a wide vagina with a perfectly healed incision (Figure 2). The girls reported no further difficulties with intercourse.

Discussion

Uterine anomalies are most commonly classified using the American Fertility Society revised classification, which identifies seven different classes [2]. Uterus didelphys is a rare congenital malformation, occurring in approximately 0.1%–0.5% of women, although the exact occurrence is difficult to determine because it may go undetected in the absence of medical and reproductive complications [3]. It arises from a defect in the lateral fusion of the Müllerian ducts. Uterus didelphys is often associated with a LVS, which results from an incomplete resorption of the vaginal

Revised manuscript accepted for publication August 27, 2014

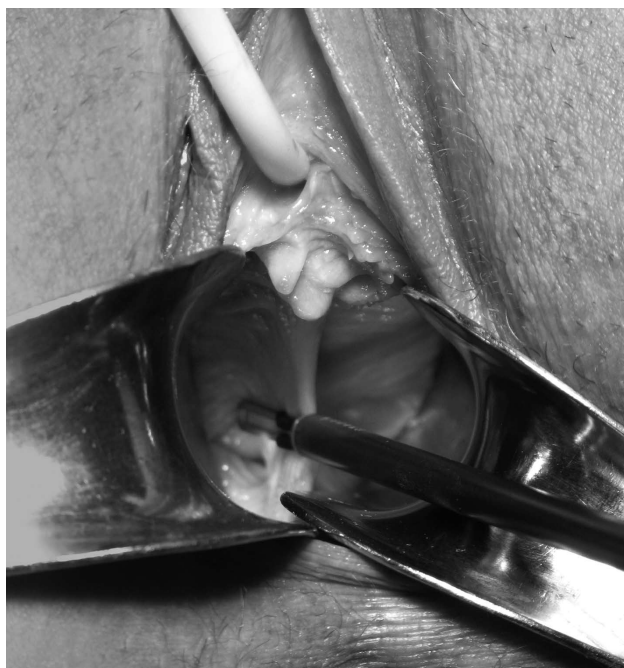

Figure 1. — Vaginal application of a laparoscopic bipolar cutting forceps to resect the vaginal septum.

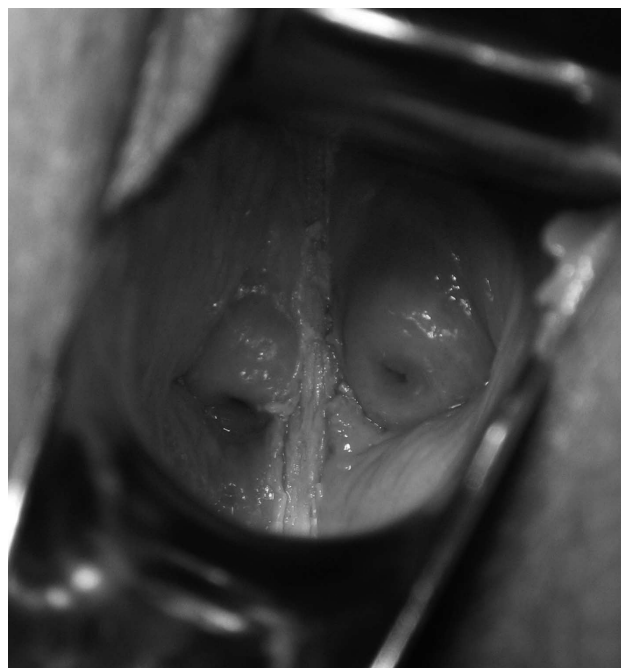


Figure 2. — Vaginal canal after the septum is fully resected (Case 1).

septum during embryogenesis of the vagina. LVS is defined as complete when it extends throughout the full length of the vagina from cervix to introitus [4,5].

A LVS is often asymptomatic, but may be associated with dyspareunia, postcoital bleeding or difficulty to insert a tampon. Diagnosis is readily made, by speculum examination, which will reveal the septum. Interestingly, the majority of patients, such as the present one, manage to become sexually active, as one side of the vagina is wider than the other and penetration is easier on this side, which will thereby be gradually further dilated [4].

Although metroplasty for the unification of the two uterine cavities has been abandoned because of increasing reports of affected fertility outcomes [6], vaginal septa are usually surgically removed to improve symptomatology. The usual approach that is classically described involves the excision by scissors after the application of Kelly or Kocher forceps on either side of the septum to prevent any blood loss. The edges are then sutured for hemostasis with 3-0 absorbable sutures [7].

Vaginal septum resection using a harmonic scalpel has been described in the past [8]. However, the fact that additional sutures were used in that particular case report, may suggest that coaptive coagulation is less effective for hemostasis than diathermy. The use of the bipolar cutting forceps appears to be a safe and effective innovative method for resection of LVS. The present authors' approach is unique, combining the accuracy of a laparoscopic instrument in vaginal surgery. Reinforcing sutures are not required, as this

resection technique offers excellent hemostasis, without lateral tissue damage from thermal spread. The short recovery time, the absence of local ischemia, and the optimum healing process are also very important advantages of this surgical technique, which may possibly be completed under local anesthesia.

Conclusion

To the authors' knowledge, this is the first case where bipolar cutting forceps have been used for treatment of a LVS. Although a higher number of cases are needed to verify the present findings, the authors believe that surgical safety, efficacy, and operative results make bipolar cutting forceps a tailored option for resection of LVS.

References

- [1] Shulman LP.: "Müllerian anomalies". *Clin. Obstet. Gynecol.*, 2008, 51, 214.
- [2] American Fertility Society: "The American Fertility Society classifications of adnexal adhesions, distal tubal occlusion, tubal occlusion secondary to tubal ligation, tubal pregnancies, Mullerian anomalies and intrauterine adhesions". *Fertil. Steril.*, 1988, 49, 944.
- [3] Heinonen P.K.: "Uterine didelphys: a report of 26 cases". *Eur. J. Obstet. Gynecol. Reprod. Biol.*, 1984, 15, 345.
- [4] Haddad B., Louis-Sylvestre C., Poitout P., Paniel B.J.: "Longitudinal vaginal septum: a retrospective study of 202 cases". *Eur. J. Obstet. Gynecol. Reprod. Biol.*, 1997, 74, 197.
- [5] Heinonen P.K.: "Uterine didelphys: a report of 26 cases". *Eur. J. Obstet. Gynecol. Reprod. Biol.*, 1982, 13, 253.

- [6] Kowalik C.R., Goddijn M., Emanuel M.H., Bongers M.Y., Spinder T., de Kruif J.H., Mol B.W., Heineman M.J.: "Metroplasty versus expectant management for women with recurrent miscarriage and a septate uterus". *Cochrane Database Syst. Rev.*, 2011, 6, CD008576.
- [7] Lee R.: "Atlas of gynecologic surgery". Philadelphia: WB Saunders, 1992, 33.
- [8] Rose S.M., Peterson C.M.: "A novel approach for resection of a vaginal septum". *J. Pediatr. Adolesc. Gynecol.*, 2009, 22, 69.

Address reprint requests to:
D. ZACHARAKIS, M.D.
First Department of Obstetrics and Gynecology
Alexandra General Hospital, University of Athens
78 Vas. Sofias Aven
11528 Athens (Greece)
e-mail: dimzac@hotmail.com

Comparing maternal and perinatal outcomes in pregnancies complicated by preeclampsia superimposed chronic hypertension and preeclampsia alone

W.S. Hu, Y. Feng, M.Y. Dong, J. He

Women's Hospital, School of Medicine, Zhejiang University, Hangzhou (China)

Summary

Aim: The study was to determine whether preeclampsia with superimposed chronic hypertension results in worse maternal and perinatal outcomes than preeclampsia alone. **Materials and Methods:** A retrospective study involving 850 pregnant women was conducted and divided into two groups: preeclampsia superimposed on chronic hypertension (group A, n= 84) and preeclampsia alone (group B, n= 766). The maternal and fetal outcomes of all subjects were collected and analyzed. **Results:** There were no significant differences between the two groups in baseline information. However, the systolic and diastolic blood pressures in group A were significantly higher than those in group B ($p < 0.05$). The average interval between the onset of preeclampsia and the termination of pregnancy was significantly longer in group A as compared to group B. The incidence of serious maternal complications showed no differences between the two groups ($p > 0.05$). It showed a higher rate of neonatal respiratory distress syndrome and intracranial hemorrhage in group A than in group B ($p < 0.05$). **Conclusions:** Women in group A had higher risks of maternal and perinatal outcomes as compared to women in group B.

Key words: Chronic hypertension; Pre-eclampsia; Pregnancy outcome.

Introduction

Hypertensive disorders in pregnancy compose approximately 10% of pregnancies and are the leading causes of maternal, fetal and neonatal morbidity, and mortality worldwide [1, 2]. In the USA, hypertensive disorders in pregnancy affect 12%-22% of all pregnancies and 17.6% of maternal deaths can be attributed directly to hypertension [3]. Among the hypertensive disorders of pregnancy, chronic hypertension complicates 5% and because the recent increase in obesity and gestational age among pregnant women, the rates with chronic hypertension are expected gradually increased as well [4]. Several studies have demonstrated a higher risk of preterm birth, fetal death, and placental abruption among women with chronic hypertension who developed superimposed preeclampsia compared with women who had preeclampsia alone [5-7]. It has been speculated that the underlying vascular abnormalities in women with chronic hypertension cause an escalation of complications when preeclampsia develops [8].

Although several studies have evaluated perinatal outcomes among women with chronic hypertension in combination with or without superimposed preeclampsia [7, 9], there are no large-scale, randomized, controlled trials comparing the outcomes of pregnancy between women with preeclampsia superimposed on chronic hypertension and those with preeclampsia alone. In the current study, mater-

nal and neonatal outcomes between women with preeclampsia superimposed on chronic hypertension and those with preeclampsia alone were compared. The authors, therefore, carried out a population-based study to determine whether preeclampsia superimposed on chronic hypertension was associated with increased adverse maternal and perinatal outcomes. They anticipate that the results of our study will provide a theoretical basis in the counseling and treatment of pregnancies in women with preeclampsia superimposed on chronic hypertension.

Materials and Methods

Between July 1, 2008 and June 30, 2012, 52,685 gravidas were delivered at the Obstetrics and Gynecology Hospital of the Zhejiang University School of Medicine. Among them, 850 (1.619%) had preeclampsia. The women were separated into two groups such that 84 women with preeclampsia superimposed on chronic hypertension (0.167% of the total number of women and 9.88% of women with preeclampsia) constituted group A and group B included 766 women with preeclampsia alone (1.45% of the total number of women and 90.12% of women with preeclampsia). The diagnosis of hypertension was made in accordance with international standards used to determine hypertensive disorders in pregnancy [10].

Women with mild preeclampsia attended regular prenatal visits where monitoring of symptoms and daily blood pressure and body weight checks were conducted. Urine protein was checked every two to three days. Fetal growth and development, as well as placental functioning, were monitored regularly. Commencing at 34 weeks

Revised manuscript accepted for publication October 2, 2014

Table 1. — *Clinical data of the two groups.*

	Preeclampsia superimposed on chronic hypertension (Group A)	Preeclampsia (Group B)	<i>p</i> value
Case number	84	766	
Age (years)	33.3	29.9	<0.001
BMI (kg/m ²)	28.91	28.45	0.526
Blood pressure (mmHg)			
Systolic blood pressure	167.9	156.6	0.001
Diastolic blood pressure	107.6	100.4	0.001
Onset of illness (weeks)	31.5	33.6	0.008
≤ 34 weeks gestation (case number)	48	336	
> 35 weeks gestation (case number)	36	430	0.020
Termination of pregnancy (weeks)	34.8	35.7	0.118
≤ 34 weeks (case number)	33	231	
> 35 weeks (case number)	51	535	0.086
Interval between onset of preeclampsia and termination of pregnancy (weeks)	3.34	2.10	<0.001

of gestation, the fetal heart rate was monitored on a weekly basis. The treatment plan focused on additional rest, a low-salt diet, and antihypertensive therapy. For those women with blood pressure levels $\geq 160/110$ mmHg, antihypertensive medications were administered. Ideal systolic and diastolic blood pressures were considered to be 140 ~ 155 mmHg and 90 ~ 105 mmHg, respectively. Blood pressure levels were checked to ensure that they did not decline sharply or drop significantly below ideal pressure levels. Labetalol (50 ~ 100 mg, two to three times per day) was the preferred anti-hypertensive therapy. If the condition was stable, the women could expect a full-term pregnancy. If the women had a higher risk of serious maternal complications, such as placental abruption, HELLP syndrome and eclampsia, the pregnancy was terminated immediately.

Hospitalization was preferred for women with severe preeclampsia. Magnesium anti-spasmodics and sedatives were prescribed along with anti-hypertensive treatment, supplemented with diuretic therapy if necessary. If the fetus was mature, women were treated for 24 to 48 hours, followed by termination of the pregnancy. In cases where the fetus was immature, women were given glucocorticoids to promote fetal lung maturation. For those showing an improvement in their condition, pregnancy was continued and monitored closely; however, if no improvement was noted after 48 hours of active treatment, fetal lung maturity was promoted followed by termination of the pregnancy at 28 weeks of gestation.

All statistical analyses were conducted using SPSS16.0. A *p*-value of < 0.05 was considered to represent a statistically significant difference between the groups.

Results

Comparisons of clinical data between the two groups

Pregnancy clinical characteristics for women are shown in Table 1. A total of 898 women were found to have preeclampsia between July 1, 2008 and June 30, 2012. Of the 898

Table 2. — *Comparison of pregnancy outcomes between the two groups.*

	Preeclampsia superimposed on chronic hypertension (Group A)	Preeclampsia (Group B)	<i>p</i> value
Severe preeclampsia (percentage)	66 (78.57%)	574 (74.93%)	0.463
Early severe preeclampsia (percentage)	48 (57.14%)	336 (43.86%)	0.020
Operative delivery rate (percentage)	82 (97.62%)	689 (89.95%)	0.022
Diabetes	4 (4.76%)	53 (6.92%)	0.453
Maternal complications and co-morbidities (percentage)	26 (30.95%)	220 (28.72%)	0.669
HELLP	2	7	0.212
Eclampsia	0	4	0.507
Abruption	7	33	0.08
Postpartum hemorrhage	2	9	0.353
Oligohydramnios	2	53	0.108
ICP	9	70	0.637
Renal diseases	2	11	0.503
Heart diseases	0	22	0.116
Other	2	11	0.503
Total	26	220	0.340

women with preeclampsia, 84 (9.4%) women in group A had chronic hypertension with superimposed preeclampsia, 850 (94.6%) women in group B had preeclampsia alone. Women in group A were older than those in group B (33.3 years vs 29.9 years, $p < 0.001$). While two groups had a similar body mass indexes ($p = 0.526$). Women in group A had higher systolic and diastolic blood pressures than those in group B ($p = 0.001$). Although the average gestational age in group A was lower than the average gestational age in group B ($p = 0.008$), the average gestational ages at which pregnancies were terminated were similar between the two groups ($p = 0.118$). The average interval between the onset of preeclampsia and the termination of pregnancy was 3.34 weeks in group A and 2.1 weeks in group B ($p < 0.001$).

Comparison of pregnancy outcomes

Table 2 displays risk estimates of adverse maternal and neonatal outcomes between the two groups. The ratio of women with severe preeclampsia was not significantly different ($p = 0.463$); however, the ratio of women with severe preeclampsia having early onset was significantly higher in group A ($p = 0.020$). There were only two natural deliveries in group A. The remaining 82 gravidas underwent cesarean sections (operative delivery rate = 97.62%). In group B, 77 women had natural deliveries, seven gravidas had cesarean sections, and 682 gravidas had lower uterine segment cesarean sections (operative delivery rate = 89.95%). Thus, the operative delivery rate in group A was significantly higher than the rate in group B ($p = 0.022$). There were not signifi-

Table 3. — Neonatal outcomes between the two groups.

	Preeclampsia superimposed on chronic hypertension (Group A)	Preeclampsia (Group B)	<i>p</i> value
Total	84	766	
FGR (percentage)	15 (17.86%)	156 (20.37%)	0.002
Gestational age (weeks)			
< 28	0	18 (2.35%)	
28~32	24 (28.51%)	121 (15.80%)	
33~34	9 (10.71%)	92 (12.01%)	
35~36	22 (26.19%)	137 (17.89%)	
≥ 37	29 (34.52%)	398 (51.56%)	0.002
Perinatal death			
Stillbirth	0	9	
Induction	0	20	
Neonatal death	2 (2.38%)	2 (0.26%)	0.007
Neonatal complications	33 (39.29%)	103 (13.45%)	<0.001
Hypoxic-ischemic encephalopathy	0	2 (0.26%)	0.639
Intracranial hemorrhage	18 (21.43%)	44 (5.74%)	0.001
Respiratory distress syndrome	11 (13.10%)	55 (7.18%)	0.054
Retinopathy	2 (2.38%)	2 (0.26%)	0.007
Necrotizing enterocolitis	2	0	<0.001
Transfer to NICU	35 (41.67%)	282 (36.81%)	0.383
NICU stay	20.8	17.7	0.522

cantly different in overall maternal complications or co-morbidities such as HELLP syndrome, eclampsia, placental abruption, postpartum hemorrhage, oligohydramnios, intrahepatic cholestasis of pregnancy (ICP), kidney disease, and heart disease between the two groups. However, women in group A were more likely to suffer serious complications such as HELLP, eclampsia, placental abruption, and postpartum hemorrhage, than those in group B (13.10% vs 6.92%; $p = 0.001$).

Comparison of neonatal outcomes

Table 3 displays a comparison of neonatal outcomes between the two groups. In group A, there were 15 cases of neonates with fetal growth restriction (FGR), all occurring in pregnancies with early-onset severe preeclampsia. In group B, there were 156 neonates with FGR, which occurred in pregnancies with early-onset severe, late-onset severe or mild preeclampsia. The women in group A had the lower incidence of FGR than those in group B (17.8% vs 18.3%, $p = 0.002$). Gestational age was directly related to the prognosis of newborns, as the composition of the two groups differed ($p = 0.002$). In the current study, women in group A delivered after 28 weeks of gestation. In group B, 18 women delivered before 28 weeks of gestation, including nine gravidas who underwent labor induction. The percentage of neonates delivered before 32 weeks of gestation was higher in group A than in group B and this difference was

associated with an increase in adverse neonatal outcomes. There were no stillbirths in group A, whereas there were nine stillbirths in group B. Of 20 gravidas in group B who underwent labor induction, nine were induced before 28 weeks of gestation and 11 had umbilical blood flow after 28 weeks of gestation with absent diastolic flow. Two neonatal deaths were reported in both groups (the neonates died after family withdrew treatment) and the incidence between the two groups was significant ($p = 0.007$). The neonates of women in group A were more likely to suffer adverse outcomes predominantly neonatal respiratory distress syndrome and intracranial hemorrhage, than those in group B. There were no differences in neonatal transfer rates to the neonatal intensive care unit (NICU) or the average length of NICU stay between the two groups ($p = 0.383$ and 0.522 , respectively).

Discussion

The percentage of adults with chronic hypertension in developed countries is between 25% and 30%. In the past two decades, the incidence of chronic hypertension has also increased in China. In the current study, the incidence of preeclampsia superimposed on chronic hypertension was significantly lower than the previously reported rate [11] and there are several possibilities to explain this observation. First, incidences lower than those reported in the US and Europe may have been attributable to differences in geography, ethnicity, or reproductive ages. Second, the records from the Chinese health care system may have been incomplete due to the mobility of the Chinese population. Therefore, hospital-based statistics may not be entirely representative or generalizable.

Several studies have evaluated that pregnancies in women with preeclampsia superimposed chronic hypertension are at an increased risk of adverse perinatal outcomes that include fetal growth, restriction, preterm birth, placental abruption, and intrauterine growth [12-15]. Placental insufficiency is recognized as the most common cause of fetal growth restriction among clinically healthy [16]. Ferrazzani *et al.* indicated an association between chronic hypertension and SGA only when superimposed with preeclampsia [17]. In the current study, the authors evaluated maternal and neonatal outcomes in women with preeclampsia with or without chronic hypertension and the data from the current study indicated that pregnancies complicated by preeclampsia superimposed on chronic hypertension represented a serious threat to maternal and neonatal health and survival.

In the current study, the operative delivery rate was significantly higher in group A than in group B and may have been associated with oligohydramnios, ICP, or other complications. Oligohydramnios may be caused by poor placental erosion closely associated with gestational hypertension and small vessel disease. Whether or not small vessel disease is more severe in women with preeclampsia superimposed on chronic hypertension than in women with preeclampsia alone remains

to be confirmed. There were no maternal deaths or differences in overall maternal complications and co-morbidities between the two groups; however, serious complications such as HELLP, eclampsia, placental abruption, and postpartum hemorrhage, were higher in group A than in group B.

Results from the current study showed that women with preeclampsia superimposed on chronic hypertension had a significantly lower rate of FGR, suggesting chronic hypertension itself does not increase the incidence of FGR. Indeed, preeclampsia induces systemic small artery spasm and ischemia resulting in decreased uteroplacental perfusion and may be a key factor in the triggering of FGR. Moreover, preeclampsia also induces various adverse outcomes, including an infiltration barrier, shallow placental implantation, endothelial dysfunction, immune imbalance, placental vascular acute atherosclerosis, placental dysfunction, and drastically reduced blood flow. As a result, the fetus develops chronic hypoxia and the incidence of FGR is dramatically increased, further suggesting that preeclampsia is a major risk factor for FGR.

The women in the current study were able to reach 35 weeks of gestation after active treatment and the majority of neonatal outcomes were good; however, in comparing neonatal complications, group A had higher incidences than group B. Group A had a relatively earlier onset of preeclampsia and the proportion of births before 32 weeks of gestation was higher than in group B. The neonatal mortality and growth rates in group A were associated with existing social factors and the economic status of the parents.

As compared to preeclampsia alone, preeclampsia superimposed on chronic hypertension triggered early onset of severe preeclampsia, early onset of severe illness, and high blood pressure among women; however, there were no significant differences in gestational ages between the two groups. Results from the current study suggested that even in women with preeclampsia superimposed on chronic hypertension, systematic treatment, proper expectations, and close monitoring of mother-infant conditions could improve the prognosis. All women in the current study delivered after 28 weeks of gestation, with significant improvements observed in newborn prognosis. Therefore, a profound health-care system with proper prenatal care for pregnant women, along with active treatment plans and strict control on the termination of pregnancy, could ensure safety and improve maternal neonatal outcomes for women with preeclampsia superimposed on chronic hypertension.

In conclusion, the present data indicate that women with chronic hypertension who developed superimposed preeclampsia had a longer average interval between the onset of preeclampsia and the termination of pregnancy, high systolic and diastolic blood pressures, and severe maternal complications than women with superimposed preeclampsia alone and also have a significantly increased risk of several adverse neonatal outcomes. Women with preeclampsia superimposed with hypertension have elevated risks of intervention-related

events compared with women with preeclampsia alone. This may be the result of earlier disease onset, so consideration of expectant management of early onset preeclampsia superimposed chronic hypertension is reasonable in the absence of contraindications.

Acknowledgements

This work was financially supported by Natural Scientific Foundation of Zhejiang Province (LY13H040004).

References

- [1] de Swiet M.: "Maternal mortality: confidential enquiries into maternal deaths in the United Kingdom". *Am. J. Obstet. Gynecol.*, 2000, 182, 760.
- [2] Waterstone M., Bewley S., Wolfe C.: "Incidence and predictors of severe obstetric morbidity: case-control study". *BMJ*, 2001, 322, 1089.
- [3] Walker J.J.: "Preeclampsia". *Lancet*, 2000, 356, 1260.
- [4] Chappell L.C., Enye S., Seed P., Briley A.L., Poston L., Shennan A.H.: "Adverse perinatal outcomes and risk factors for preeclampsia in women with chronic hypertension: a prospective study". *Hypertension*, 2008, 51, 1002.
- [5] Rey E., Couturier A.: "The prognosis of pregnancy in women with chronic hypertension". *Am. J. Obstet. Gynecol.*, 1994, 171, 410.
- [6] Vanek M., Sheiner E., Levy A., Mazor M.: "Chronic hypertension and the risk for adverse pregnancy outcome after superimposed preeclampsia". *Int. J. Gynaecol. Obstet.*, 2004, 86, 7.
- [7] McCowan L.M., Buist R.J., North R.A., Gamble G.: "Perinatal morbidity in chronic hypertension". *BJOG*, 1996, 103, 123.
- [8] Creasy R.K., Resnik R., Iams J.D., Lockwood C.J., Moore T.R.: "Creasy & Resnik's maternal-fetal medicine: principles and practice" *Philadelphia: Saunders*, 2009, 651.
- [9] Sibai B.M., Abdella T.N., Anderson G.D.: "Pregnancy outcome in 211 women with mild chronic hypertension". *Obstet Gynecol.*, 1983, 61, 571.
- [10] Cunningham F.G., Leveno K.J., Bloom S.L.: "Williams Obstetrics, 22nd ed". New York: McGraw-Hill, 2005, 761.
- [11] Tuuli M.G., Rampersad R., Stamilio D.: "Perinatal outcomes in women with preeclampsia and superimposed preeclampsia: do they differ?" *Am. J. Obstet. Gynecol.*, 2011, 204, 1.
- [12] Vanek M., Sheiner E., Levy A., Mazor M.: "Chronic hypertension and the risk for adverse pregnancy outcome after superimposed preeclampsia". *Int. J. Gynecol. Obstet.*, 2004, 86, 7.
- [13] Marik P. E.: "Hypertensive disorders of pregnancy". *Postgrad. Med.*, 2009, 121, 69.
- [14] Ferrer R.L., Sibai B.M., Mulrow C.D., Chiquette E., Stevens K.R., Cornell J.: "Management of mild chronic hypertension during pregnancy: a review". *Obstet. Gynecol.*, 2000, 96, 849.
- [15] Chappell L. C., Enye S., Seed P., Briley A.,L., Poston L. Shennan A. H.: "Adverse perinatal outcomes and risk factors for Preeclampsia in women with chronic hypertension - A prospective study". *Hypertension*, 2008, 51, 1002.
- [16] Baschat A. A., Hecher K.: "Fetal growth restriction due to placental disease". *Semin. Perinatol.*, 2004, 28, 67.
- [17] Ferrazzani S., Caruso A., Decarolis S., Martino I. V., Mancuso S., "Proteinuria and Outcome of 444 Pregnancies Complicated by Hypertension". *Am. J. Obstet. Gynecol.*, 1990, 162, 366.

Address reprint requests to:
J. HE, M.D.
Women's Hospital, School of Medicine
Zhejiang University
No. 1 Xueshi Road
Hangzhou 310006 (China)
e-mail: jinghe2014@yeah.net

Unilateral sacrospinous ligament fixation (USLF) with a mesh stabilizing anchor set: clinical outcome and impact on quality of life

M.U. Karacaoglu, E.S. Ozyurek, S. Mutlu, E. Odacilar

Istanbul Bagcilar Research and Training Hospital, Obstetrics and Gynecology Department, Sokak Bağcilar, Istanbul (Turkey)

Summary

Genital prolapse is one of the most significant problems which lowers the quality of life measures of middle and older aged women. A continuously growing number of women are being operated due to this indication. *Objective:* This study intends to assess the clinical outcome and the impact on quality of life of uterine sacrospinous ligament fixation (USLF) conducted with a mesh stabilizing anchor set in the present clinic following vaginal hysterectomy. *Materials and Methods:* Twenty-one patients, diagnosed with genital prolapse and for whom vaginal hysterectomy and (USLF) with the Surelift mesh stabilizing anchor set were performed from April 2010 to June 2013, were assessed in this study. Posterior colporrhaphy was performed in all cases, as well. The cuff level was used to assess the anatomical recovery one year following the surgery. Postoperative relaxation of the vaginal cuff line below the hymenal level was defined as failure. Quality of life (P-QOL) questionnaires validated for Turkish women were used preoperatively and on their first year to assess patient satisfaction. Clinical outcome and impact on quality of life were analyzed in all these cases by using *t*-test for paired samples. *Results:* The mean age of the patients was 67.4 (min-max:43-84) years; mean parity 5.4 (min-max: 2-13). The mean operation time was 56 ± 12 minutes. The mean postoperative follow-up period was 21.4 months. Preoperative mild bleeding (two), postoperative severe pain (three), and micturition problems (one) were found. Therapeutic results and patient satisfaction were evaluated in the 12th month postoperatively: In 18 / 21 (85%) patients, the cuff was located above the hymenal ring. P-QOL scores validated for Turkish women were 52.5 ± 12.9 preoperatively and 11.08 ± 7.9 postoperatively (*t*-test for paired samples revealed a significant difference; $p = 0.04$). *Conclusion:* The treatment of genital prolapse through the abdominal route includes the sacrocolpopexy operation with or without hysterectomy. This method, most of the time, requires a laparotomy if not performed by a specifically trained laparoscopist. It has a longer operation time and mesh erosions are feared complications compared to vaginal route. In sacrospinous fixation cases added to vaginal hysterectomy, operation times are shorter and especially preferable in patients where medical problems coexist. Operative success and patients' satisfaction seems to be provided by this technique.

Key words: Genital prolapse; Sacrospinous ligament fixation; Anchoring system; P-QOL questionnaires.

Introduction

Genital prolapse is prevalent in 30% of middle and older aged group women. This is one of the most important conditions having an unfavorable impact on the quality of life (QOL) and also a leading indication for hysterectomy [1].

An epidemiological analysis has also revealed that 11% of women will have to be operated because of genital prolapse within their lifetimes [2]. Apart from environmental factors, inherited factors as well, have been shown to play an important role in the pathogenesis of genital prolapse [3, 4]. Cuff prolapse complicating hysterectomies postoperatively are a great cause for frustration for the patient as much as for the surgeon. In curing this condition, vaginal sacrospinous fixation is an important alternative to the abdominal sacrocolpopexy operation. In choosing the appropriate operation, the patient's age, accompanying medical problems, previous operations, and certainly the surgeon's experience have to be considered. There have been many previous studies

conducted to compare these two operations [5, 6]. In a recent Cochrane data review comprised of 14 randomized studies: while abdominal sacrocolpopexy was found to result with lower rates of dyspareunia and recurrence rates than vaginal sacrospinous fixation, it is more expensive, takes longer time to operate, and associated with longer intervals to return to normal activities [7]. Sacrospinous fixation is frequently preferred to provide support for weak cardinal-uterosacral complexes in vaginal cuff prolapse cases [8, 9]. Nicholls and Cruikshank have suggested sacrospinous fixation following vaginal hysterectomies. [10, 11] Schraffordt *et al.* in review analysing the therapeutical choices in the treatment of pelvic organ prolapse have stated that in the presence of pelvic organ prolapse, despite the lack of randomized controlled prospective studies it would be better not to perform a vaginal hysterectomy [12]. In our clinical practice, we perform vaginal hysterectomies because for most of our patients.

Revised manuscript accepted for publication November 10, 2014

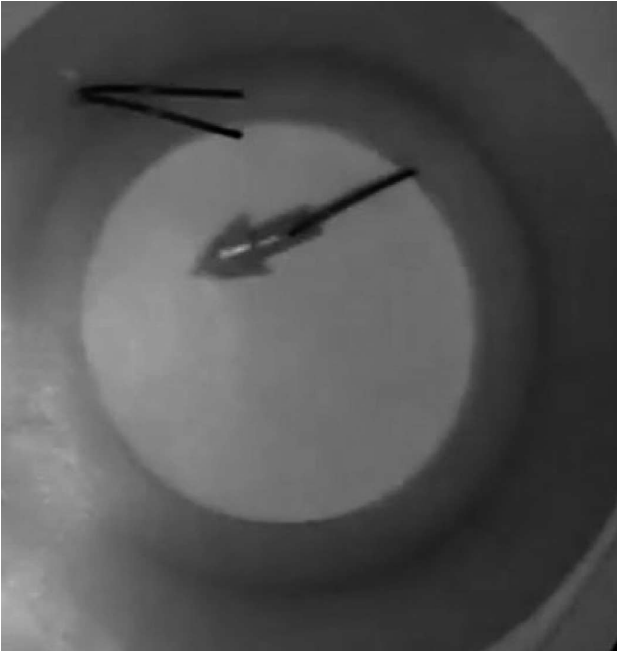


Figure 1. — The mesh stabilizing anchor: an anchoring tip connected to prolene suture material both manufactured with late absorbable suturing material.

Over the past decade the quality of life questionnaires are found to be reliable in women with genital prolapse, therefore the present authors have decided to use them to evaluate the clinical outcome of (USLF) using a Surelift mesh stabilizing anchor set.

Materials and Methods

Twenty-one cases who were diagnosed with genital prolapse and operated with vaginal hysterectomy and sacrospinous fixation at the Bagcilar Research and Training Hospital were retrospectively analyzed. The ages, parities, degrees of genital prolapse, the presence of cystocele or rectocele, and presence of accompanying incontinence were noted. Quality of life (P-QOL) questionnaires validated for Turkish women were done preoperatively. [13]

The preoperative examinations were conducted in the supine position during valsalva. The POP-Q grading was used to grade the genital prolapse. The urocanic tests to assess the incontinence were conducted while keeping the prolapsed portion repositioned in the vagina.

Following vaginal hysterectomy, starting from the cuff at the seven o'clock point the vagina was incised for five to six cm to enter the rectovaginal space in the right mediolateral direction. The right ischial spine was palpated and bluntly dissected and exposed. At two to three cm medial to this spine, a Surelift mesh stabilizing anchoring set (Figure 1) was used to implant a knit of prolene through the sacrospinous ligament (Figure 2). At this stage of the procedure, the authors took care to avoid injuring the pudendal vessels/nerves and the sacral plexus. The free end of this prolene was then sutured with a free needle through the midline submucosally and fixed with a hemostat to be knotted after clos-

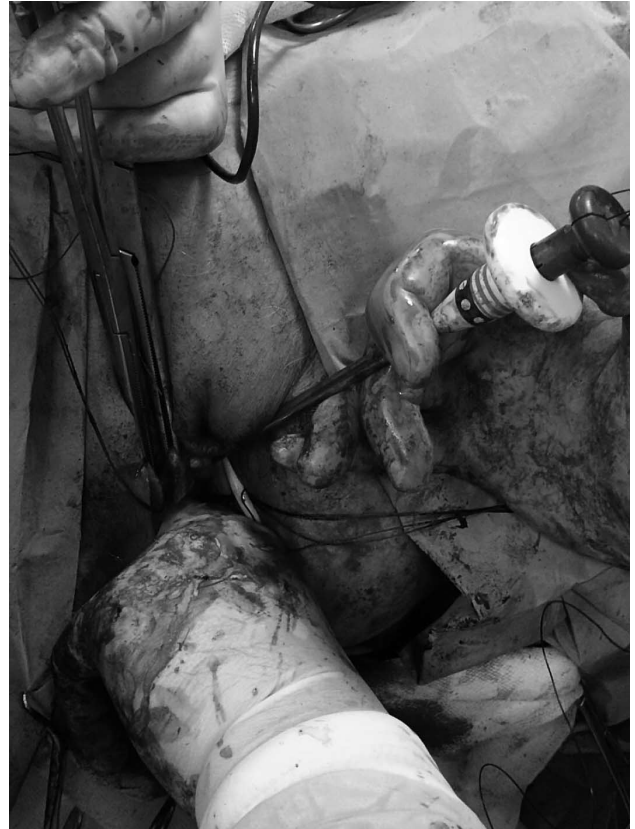

Figure 2. — The anchoring tip is fixed through the dissected right pararectal space to the right sacrospinous ligament with the control and guidance of the left index finger.

ing the vaginal cuff and about half of the posterior vaginal incision for lifting the whole prolapsed segment. The operation time stopwatch was started at the instance when the vaginal hysterectomy and the anterior colporrhaphy were completed. The actual operation time is supposed to be measured from when the incision is made to access the pararectal space to when the vaginal mucosa is completely closed. A colporrhaphy posterior was performed for all the cases while a colporrhaphy anterior was only added when a more than grade 2 cytocele was present. All the preoperative and postoperative complications were noted. After being discharged, the patients were called back for a routine control at one month and every six months thereafter. At their one-years postoperative control, the therapeutic goal was considered to be a favorable support of the cuff above the hymenal ring with valsalva, in the supine position, namely a state of cuff prolapse no higher than stage 2. Patient satisfaction evaluation with the P-QOL questionnaire was carried out again at the end of the first year.

Results

The mean age and parity of the cases were 67.4 ± 5.2 [43-84] and 5.4 ± 1.1 [2-13], respectively. In grading of genital prolapse: while 16 of the cases were POP-Q grade 4, the other five cases were grade 3. While the number of cases with cystoceles higher than grade 2 were six, those

Table 1. — The study group (n=21).

Mean age		67.4 ± 5.2 years
Mean parity		5.4 ± 1.1
Degree of genital prolapse	(Stage 3)	5 patients
	(Stage 4)	16 patients
Cystocele > Stage 2		6 patients
Rectocele > Stage 2		11 patients
Presence of incontinence		2 patients

Table 2. — Surgical operation characteristics (n=21).

Mean operation time	56 ± 12 minutes
Preoperative mild bleeding	2 patients
Postoperative severe pain complaint	3 patients
Postoperative micturition problems	1 patients

Table 3. — Clinical outcome (n=21).

Mean postoperative follow-up	214 ± 4.1 months
Cuff located above the hymenal line*	18/21 (85%)
Patient satisfaction (P-QOL scores)**, α	
Preoperative:	52.5 ± 12.9
Postoperative:	11.08 ± 7.9

*Postoperative evaluation in the 12th month; **Postoperative evaluation in the 12th month with the P-QOL questionnaire validated for Turkish women (Seven *et al.*); α: Two values compared with the *t*-test for paired samples; significant difference ($p = 0.04$).

with rectoceles higher than grade 2 were 11. While an anterior colporrhaphy was performed for the six cystoceles graded 2 or higher, a posterior colporrhaphy was performed for all the cases. A tension free obturator tape operation was added for two cases with stress incontinence. The characteristics of the study group is summarized in Table 1. While the operating times were longer in the initial cases, they became shorter as the surgeons acquired more experience. The operation environment was not very hemorrhagic except in two cases where mild bleeding which were easily controlled were encountered. Three of the cases postoperatively complained of a sharp inguinal pain radiating to the ipsilateral femoral area. The pain was alleviated with oral analgesics. Bladder drainage was kept for eight hours for cases who were also treated with TOT or anterior colporrhaphy. In one case where a micturition difficulty was experienced, the bladder drainage was kept for 24 hours. Findings at operation are presented in Table 2.

The mean postoperative follow-up period was 21.4 months. During the postoperative follow-up, the cuff level was maintained above the hymenal ring level in 18 / 21 (85%) patients. According to P-QOL test scores, pre-operative: 52.5 ± 12.9 and post-operative: 11.08 ± 7.9 were found. Two values were compared with the *t*-test for paired samples; significant difference ($p = 0.04$) P-QOL scores, analyses are summarised in Table 3.

Discussion

Genital prolapse cases are treated by the suspension of the cuff to sacral promontorium with a mesh. It was first defined by Lane [14]. This technique has been shown to be superior to other approaches in restituting the normal vaginal axis and capacity [15, 16]. The success rate has been reported to be as high as 90% and the long term results are not as well defined. The unfavorable consequences of the operation include postoperative urinary incontinence, dyspareunia, synthetic mesh erosion, and serious bleeding due to sacral venous plexus injuries [17, 18]. Mesh erosions are observable in two to 2.7% of the cases [18]. Sacrospinous fixation was initially defined by Miyazaki *et al.*, initially being performed bilaterally, but later profoundly unilateral with refined experience [19]. In fact, there has been so far no differences reported among the two approaches [20]. The vaginal route is more effective for treating pelvic organ prolapses [21]. Uterine preservation with sacrospinous hysteropexy looks more promising as a treatment option for prolapse though there is still insufficient evidence [22]. Anterior vaginal wall relaxations have been reported to be more common following sacrospinous fixations by some authors and the present authors routinely add anterior compartment repair as well [23]. Due to impairing the normal vaginal axis in contrast to the sacrocolpopexy operation, this may not be the ideal approach in sexually active women [24]. For the older women, the procedure can be performed even under locoregional anesthesia. In fact, the success rates are as high as 85-100%.

Although the present long term results are still pending, the short and midterm results are satisfying. In conclusion, the present authors suggest that unilateral sacrospinous fixation using the mesh stabilizing anchor set following vaginal hysterectomy is an effective, safe, and easy approach in the treatment of genital prolapse.

References

- [1] Babalola E.O., Bharucha A.E., Melton L.J. 3rd, Schleck C.D., Zinsmeister A.R., Klingele C.J., Gebhart J.B.: "Utilization of surgical procedures for pelvic organ prolapse: a population-based study in Olmsted County, Minnesota, 1965-2002". *Int. Urogynecol. J.*, 2008, 19, 1243. doi: 10.1007/s00192-008-0613-z. Epub 2008 May 27.
- [2] Olsen A.L., Smith V.J., Bergstrom J.O., Colling J.C., Clarc A.L.: "Epidemiology of surgically managed pelvic organ prolapse and urinary incontinence". *Obstet. Gynecol.*, 1997, 4, 501.
- [3] Dietz H.P.: "The aetiology of prolapse". *Int. Urogynecol. J.*, 2008, 19, 1323.
- [4] Sottner O., Zahumensky J., Krcmar M., Brtnicka H., Kolarik D., Driak D., Halaska M.: "Urinary incontinence in a group of primiparous women in the Czech Republic". *Gynecol. Obstet. Invest.*, 2006, 62, 33. Epub 2006 Mar 2.
- [5] Carey M.P., Dwyer P.L.: "Genital prolapse: vaginal versus abdominal route of repair". *Curr. Opin. Obstet. Gynecol.*, 2001, 13, 499.
- [6] Benson T.J., Lucente V., McClellan E.: "Vaginal versus abdominal reconstructive surgery for the treatment of pelvic support defects: a prospective randomized study with long-term outcome evaluation". *Am. J. Obstet. Gynecol.*, 1996, 175, 418.

- [7] Maher C., Baessler K., Glazener C.M.A., Adams E.J., Hagen S.: "Surgical management of pelvic organ prolapse in women". *Cochrane Database Syst. Rev.*, 2004, 4, CD004014.
- [8] Lantzsch T., Goepel C., Wolters M., Koelbl H., Methfessel H.D.: "Sacrosplous ligament fixation for vaginal vault prolapse". *Arc. Gynecol. Obstet.*, 2001, 3, 21.
- [9] Demirci F., Ozdemir I., Somunkiran A., Topuz S., Iyibozkurt C., Duras Doyran G., et al.: "Perioperative complications in abdominal sacrocolpopexy and vaginal sacrosplous ligament fixation procedures". *Int. Urogynecol. J. Pelvic Floor Dysfunct.*, 2007, 18, 257.
- [10] Nichols D.H.: "Sacrosplous fixation for massive eversion of the vagina". *Am. J. Obstet. Gynecol.*, 1982, 142, 901.
- [11] Cruikshank S.H., Cox D.W.: "Sacrosplous fixation at the time of transvaginal hysterectomy". *Am. J. Obstet. Gynecol.*, 1990, 162, 1611.
- [12] Schraffordt D.V., Koops S.E., Vaart C.H.: "Vaginal surgery for uterine descent: which options do we have? A literature review". *Int. Urogynecol. J.*, 2008, 20, 349.
- [13] Memnun Seven, AygulAkyuz, Cengiz Han Acikel: "Validation of the prolapsus-related Quality of life Questionnaire (P-QOL) in a selected Turkish population". *TAF Prev. Med. Bull.*, 2008, 7, 317.
- [14] Lane F. E.: "Repair of posthysterectomy vaginal vault prolapse". *Obstet. Gynecol.*, 1962, 20, 72.
- [15] Benson J. T., McClellan E.: "The effect of vaginal dissection on the pudendal nerve". *Obstet. Gynecol.*, 1993, 82, 387.
- [16] Grunberger W., Grunberger V., Wierrani F.: "Pelvic promontory fixation of the vaginal vault in sixty-two patients with prolapse after hysterectomy". *J. Am. Coll. Surg.*, 1994, 178, 69.
- [17] Sutton G. P., Addison W. A., Livengood C. H. III, B.Hammond C.: "Life-threatening hemorrhage complicating sacral colpopexy". *Am. J. Obstet. Gynecol.*, 1981, 140, 836.
- [18] Iglesia C. B., Fenner D. E., Brubaker L.: "The use of mesh in gynecologic surgery". *Int. Urogynecol. J. Pelvic Floor Dysfunct.*, 1997, 8, 105.
- [19] Miyazaki F. S.: "Miya Hook ligature carrier for sacrosplous ligament suspension". *Obstet. Gynecol.*, 1987, 70, 286.
- [20] Randall C. L., Nichols D.H.: "Surgical treatment of vaginal inversion". *Obstet. Gynecol.*, 1971, 38, 327.
- [21] Roovers J.P., van der Vaart C.H., van der Bom J.G., van Leeuwen J.H., Scholten P.C., Heintz A.P.: "A randomised controlled trial comparing abdominal and vaginal prolapse surgery: effects on urogenital function". *BJOG*, 2004, 111, 50.
- [22] Hefni M.A., El-Toukhy T.A.: "Long term outcome of vaginal sacrosplous colpopexy for marked uterovaginal and vault prolapse". *Eur. J. Obstet. Gynecol. Reprod. Biol.*, 2006, 127, 257. Epub 2005 Dec 27.
- [23] Colombo M., Milani R.: "Sacrosplous ligament fixation and modified McCall culdoplasty during vaginal hysterectomy for advanced uterovaginal prolapse". *Am. J. Obstet. Gynecol.*, 1998, 179, 13.
- [24] Lovatsis D., Drutz H. P.: "Vaginal surgical approach to vaginal vault prolapse: considerations of anatomic correction and safety". *Curr. Opin. Obstet. Gynecol.*, 2003, 15, 435.

Address reprint requests to:

E.S. OZYUREK, M.D.

Specialist in Obstetrics and Gynecology

Istanbul Bagcilar Research and Training Hospital

Obstetrics and Gynecology Department

Sisli Kustepe Mah Tomurcuk

Str Izmen Site A1 9/43

80310 Istanbul (Turkey)

e-mail: eozyurek@yahoo.com

Correlation of the system of cytokines in moderate and severe preeclampsia

A. Markova Daneva¹, M. Hadži-Lega¹, M. Stefanovic²

¹ Department of Obstetrics & Gynecology, Medical Faculty, Ss. Cyril and Methodius University, Skopje (Republic of Macedonia)

² Department of Obstetrics & Gynecology, Medical Faculty, Nis (Republic of Serbia)

Summary

Objective of the study: To study the production of pro-inflammatory (IL-1 β , IL-2, IL-6, IL-8) and anti-inflammatory (IL-4, IL-10) cytokines in pregnancy complicated by preeclampsia in the third trimester. *Institution:* University Clinic of Gynecology and Obstetrics, Skopje, Republic of Macedonia. *Material and Methods:* Fifty women with pregnancies complicated by preeclampsia in the third trimester and 50 women with physiological pregnancy. Levels of IL-1 β , IL-2, IL-6, IL-8, IL-4, and IL-10 were measured by using a solid-phase enzyme immunoassay. Statistical data processing was done using the application program SPSS for Windows 13, 0. To describe the distribution of analyzed variables, descriptive methods (mean, median, minim and max) were used. *Results:* In pregnancies complicated by preeclampsia, there are increased levels of proinflammatory cytokines and a change in the behaviour of opposing pools. Most pronounced changes in the levels of proinflammatory cytokines were observed in mild preeclampsia. In severe preeclampsia there was reduction of the concentration of anti-inflammatory cytokines IL-4 and IL-10. *Conclusion:* The use of assessment cytokine profile monitoring of health status of women with preeclampsia is expedient.

Key words: Cytokines; Severe preeclampsia; Moderate preeclampsia; Correlation.

Introduction

One of the major concerns of modern medicine and molecular biology is the examination of the role of cytokines in the pathogenesis of various diseases. In clarifying the nature of immune responses, cytokines have participated in all the immune mechanisms and inflammatory reactions [1]. System disorders of cytokines leads to changes of immune competent cells, changes in immune homeostasis, and generally to disruption of the normal functioning of the immune system [2-4].

Changing spectrum of cytokines in the dynamics of gestational process deserves special attention due to their important function of immunomodulation. The process of change in cytokine levels during pregnancy is an important telltale of body's adaptive reaction in pregnant women. The regulation of the synthesis of cytokines during pregnancy is aimed at restructuring the intracellular interactions links to allow normal functioning of organs and body system of the mother and the genetically different fetus [5, 6]. Especially important is not only the change in the level of certain cytokines, but also the ratio of opposite pools, because it may reflect the activity and severity of the pathological process and the level of adaptation - compensatory reactions [7-12]. Imbalance of cytokines plays an integral role in the development of functional inferiority of immune competent cells and the pathogenic mechanisms of many diseases [13].

The evaluation of cytokine status in various forms of pathological pregnancy bears special interest owing to the changes in serum concentrations of cytokines, which have numerous biological effects, for they may be indicators of immune system diseases. [14-16].

In recent years, the leading role of immunological disorders in the pathogenesis of preeclampsia has often been evaluated. According to the literature, the development of preeclampsia is accompanied by pronounced changes in cytokine profile [17-19]. According to the modern concepts, preeclampsia is regarded as systemic and local level development to inflammatory response conditioned by hyper-activation of phagocytes [20]. Many researchers state that the pregnancy complicated by preeclampsia activates an entire range of pro-inflammatory cytokines, the high concentration of which is an unfavorable factor reflecting the activity and severity of the pathological process [21, 22]. Sequence authors inform that the preeclampsia ratio of pro-inflammatory and anti-inflammatory cytokines in peripheral blood increases substantially [23].

The purpose of this research is to study the formation of pro-inflammatory (IL-1 β , IL-2, IL-6, IL-8) and anti-inflammatory (IL-4, IL-10) cytokines in pregnancy complicated by preeclampsia of different degree in the third trimester.

Revised manuscript accepted for publication October 28, 2014

Materials and Methods

Examination of the cytokine profile in serum was conducted in 50 women with pregnancies complicated by varying degrees of preeclampsia in the third trimester of gestation hospitalized at the University Clinic of Gynecology and Obstetrics, Skopje, Republic of Macedonia. The severity of preeclampsia was determined according to the definition of the World Health Organization. Control group consisted of 50 women in the third trimester of normal pregnancy. Both groups were comparable for age, number of pregnancies, and births.

The level of IL-1 β , IL-2, IL-4, IL-6, IL-8, and IL-10 was determined using a commercial test, using reagents from ELISA research kits. Cytokine levels in the serum were measured by the "sandwich" method of solid -phase enzyme immunoassay using double antibody. As a standard for comparison of each reaction used were recombinant cytokines. The detection was done by "Victor" immunoassay analytics. According to the titration of standard samples calibration graphs were made for each cytokine, as determined by their level in the range of detected concentrations (1-2000 pg/ml). Statistical data processing was done using the SPSS 13.0 software for Windows.

Descriptive methods (mean, median, minim and max) were used to describe the distribution of analyzed variables. Categorical variables were analyzed with chi-square test and Fisher's exact test, whereas quantitative variables were analyzed with Student's t-test for independent samples, Mann-Whitney U test (Z), Analysis of Variance (F), and Kruskal-Wallis ANOVA (H) test. To be considered statistically significant, differences between groups were set at $p < 0.05$, and to be highly significant, value was at $p < 0.01$.

Results

A survey showed that in pregnancy complicated by preeclampsia, the level of all cytokines essentially changes compared with their level in physiological pregnancy. Thus, directional change was identified even in a lighter form of preeclampsia, i.e., elevated levels of pro- and anti-inflammatory cytokines except for IL-10, where in a downward trend in severe preeclampsia is recorded. Table 1 shows the comparative values of serum concentrations of IL-2, IL-4 and IL-6 in the studied groups.

The average concentrations of IL-2 in the group with preeclampsia was 41.6 ± 34.9 pg/ml, 37.6 ± 27 pg/ml in the group with moderate preeclampsia, and 45.7 ± 41.6 pg/ml in

Table 1. — Comparative values of IL-2, IL-4, and IL-6 in moderate, severe preeclampsia, and control groups.

Variable	Groups			
	PE N=50	Moderate PE (mPE) N=25	Severe PE (sPE) N=25	Control (CO) N=50
IL-2	41.6 \pm 34.9	37.6 \pm 27	45.7 \pm 41.6	16 \pm 8.3
mean \pm SD,	35.4	31.5	40.5	13.7
median, range	7.4 – 220.6	7.45 – 108.8	8.2 – 220.6	4.3 – 36.9
PE/CO Z=5.6 $p < 0.01^{**}$				
mPE/ sPE / CO/ H=31.9 $p < 0.01^{**}$		mPE/CO $p < 0.01^{**}$	sPE/CO $p < 0.01^{**}$	mPE/ sPE $p = 0.4$
IL-4	0.62 \pm 1.02	0.74 \pm 1.26	0.51 \pm 0.71	0.39 \pm 0.12
mean \pm SD,	0.36	0.37	0.35	0.36
median, range	0.14 – 6.75	0.25 – 6.75	0.14 – 3.91	0.27 – 0.87
PE/CO Z=1.49 $p = 0.14$				
mPE/ sPE / CO/ H=10.1 $p = 0.006^{**}$		mPE/CO $p = 0.003^{**}$	sPE/CO $p = 0.6$	mPE/ sPE $p = 0.01^*$
IL-6	16 \pm 42.1	18.3 \pm 42.1	13.8 \pm 42.9	2.8 \pm 9.6
mean \pm SD,	1.38	1.74	1.15	1.02
median, range	0.66 - 185	0.66 - 185	0.73 - 185	0.42 – 68.4
PE/CO Z=2.6 $p = 0.01^*$				
mPE/ sPE / CO/ H=7.8 $p = 0.02^*$		mPE/CO $p < 0.01^{**}$	sPE/CO $p = 0.1$	mPE/ sPE $p = 0.2$

* $p < 0.05$; ** $p < 0.01$

the group with severe preeclampsia. Average value of IL-2 was the lowest in the control group, at 16 ± 8.3 pg/ml. Statistical analysis as highly significant ($p < 0.01$) confirmed differences in serum concentrations of IL-2 among pregnant women with preeclampsia and healthy pregnant women. Healthy pregnant women have highly significant lower values of IL-2 compared to pregnant women with preeclampsia, both in regards to pregnant women with symptoms of moderate preeclampsia, and to those with severe symptoms of preeclampsia. Group with moderate preeclampsia showed insignificant ($p = 0.4$) lower values of IL-2 in serum as compared with pregnant women with severe preeclampsia.

The group of patients with preeclampsia, which included those with medium and with severe preeclampsia, had in-

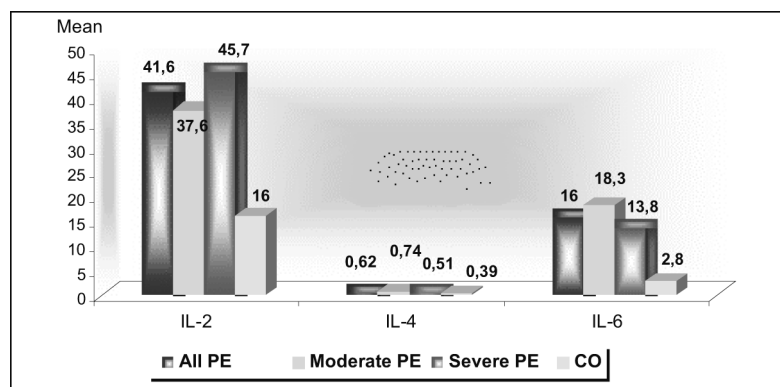


Figure 1. — Mean value of IL-2, IL-4, and IL-6 in moderate, severe preeclampsia, and control groups.

Table 2. — Comparative values of IL-8, IL-10, and IL-1 β in moderate, severe preeclampsia, and control groups.

Variable	Groups			
	ALL PE (PE) N=50	Moderate PE (mPE) N=25	Severe PE (sPE) N=25	Control (CO) N=50
IL-8	46.4±117.2	57.1±93.6	35.7±138	13.6±33.1
Mean ±SD,	6.31	8.11	5.99	6.03
median, range	2.39 - 697	3.05 - 259	2.39 - 697	1.2 - 237
PE/CO Z=0.4	p = 0.7			
mPE/ sPE / CO/H=3,6	p = 0,17			
IL-10	23.2±40.7	45.5±48.4	0.8±0.4	4.2±6.7
Mean ±SD,	1.36	27.28	0.75	1.47
median, range	0.2 - 164	0.56 - 164	0.2 - 2.12	0.44 - 26.28
PE/CO Z=0.6	p = 0.5			
mPE/ sPE / CO/		mPE/CO	sPE/CO	mPE/ sPE
H=37.68	p < 0.01**		p < 0.01**	p < 0.01**
IL-b	6.6±25.7	1.9±4.9	11.3±35.7	1.8±7.4
Mean ±SD,	0.78	0.67	0.95	0.665
median, range	0.42 - 131	0.42 - 24.67	0.49 - 131	0.13 - 53
PE/CO Z=2.3	p = 0.02*			
mPE/ sPE / CO/		mPE/CO	sPE/CO/	mPE/ sPE
H=9.8	p < 0.01**		p < 0.01**	p = 0.04*

*p < 0.05 ; **p < 0.01

significant ($p = 0.14$) higher values of IL-4 in serum, compared with the control group. Insignificant was the difference between the group with severe preeclampsia and the control group ($p = 0.6$), while the group with moderate preeclampsia had highly significant values higher than the control group ($p < 0.003$), comparing the group with severe preeclampsia ($p < 0.01$). Average serum concentrations of IL-4 was the lowest in the group of healthy pregnant women - 0.39 ± 0.12 pg/ml, while the group of pregnant women with symptoms of moderate preeclampsia had the highest average values of 0.51 ± 0.71 pg/ml. The group which included all pregnant women with symptoms of preeclampsia had averages of IL-4 from 0.62 ± 1.02 pg/ml.

Pregnant women with preeclampsia had highly significant ($p = 0.01$) higher values of IL-6 in serum compared to

normotensive pregnant women, a variation due to the highly significant difference between pregnant women with moderate preeclampsia and healthy pregnant women. The difference between women with severe preeclampsia and healthy pregnant women was insignificant ($p = 0.1$). Both subunits of pregnant, medium, and severe preeclampsia, insignificantly differed in IL-6 values in serum. The average serum concentrations of IL-6 amount was 16 ± 42.1 pg/ml or 18.3 ± 42.1 pg/ml in the group with moderate preeclampsia, and 13.8 ± 42.9 pg/ml in the group with severe preeclampsia. Normotensive pregnant women had the lowest average value of IL-6 in serum from 2.8 ± 9.6 pg/ml. Mean value of IL-2, IL-4 and IL-6 in patients with moderate and severe preeclampsia, and control group are presented in Figure 1.

Pregnant women with preeclampsia and healthy pregnant women had insignificant ($p = 0.7$) different values of IL-8 in serum, and pregnant women with moderate and with severe preeclampsia had insignificant higher values compared to the control group ($p = 0.17$). Average values, median, and lowest and highest values of IL-8, IL-10, and IL-1 β in the analyzed groups are presented in Table 2.

Statistical analysis confirmed insignificant differences in the values of IL-10 in serum among pregnant women with moderate preeclampsia and healthy pregnant women ($p = 0.5$), but the statistically highly significant ($p < 0.01$) difference among moderate preeclampsia / severe preeclampsia / control group was due to the lower values of this interleukin in severe preeclampsia group, comparing moderate preeclampsia in relation to the control, and due to the highly significant lower values when comparing control in relation to moderate preeclampsia group. Average concentrations of IL-10 in serum amounted to 23.2 ± 40.7 pg/ml in the group with preeclampsia, that is, 45.5 ± 48.4 pg/ml in the group of moderate preeclampsia, and 0.8 ± 0.4 pg/ml in the group with severe preeclampsia. In normotensive group, the average serum concentration of IL-10 was 4.2 ± 6.7 pg/ml.

Patients with preeclampsia had significantly ($p = 0.02$) higher serum concentrations of IL-b compared to nor-

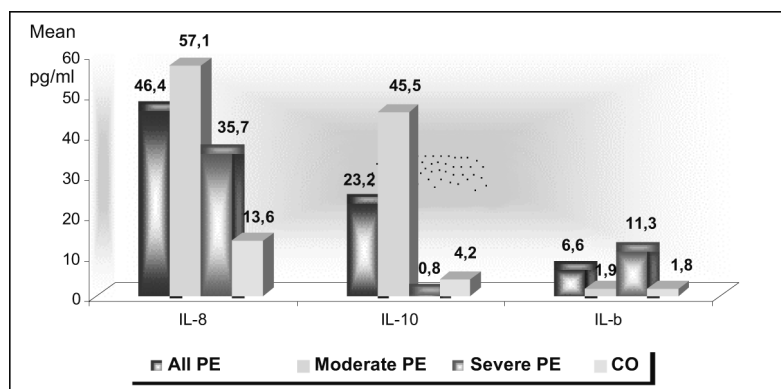


Figure 2. — Mean levels of IL-8, IL-10, and IL-1 β in moderate, severe preeclampsia, and control groups.

motensive, due to the highly significant ($p < 0.01$) higher concentrations in the group of severe preeclampsia versus control group, while the difference observed in moderate form of preeclampsia and control group was statistically insignificant ($p = 0.5$). Statistically significant, whereas $p = 0.04$, was the difference between the two subgroups of preeclampsia. The lowest average value of IL-1 β was 1.8 ± 7.4 pg/ml, as registered in the control group, with similar average values measured in the group with moderate preeclampsia, while the highest average value in the group with severe preeclampsia measured 11.3 ± 35.7 pg/ml. Mean levels of IL-8, IL-10 and IL-1 β in patients with moderate and severe preeclampsia and control group are presented in Figure 2.

Discussion

An analysis of the results of the present research, showed that the largest changes in the concentrations of pro-inflammatory cytokines were seen in moderate preeclampsia. In moderate preeclampsia there was increased synthesis of these cytokines, as the level of IL-10 and IL-8 reaches maximum values. In severe preeclampsia, the level of pro-inflammatory cytokines (IL-4) either remained elevated or did not differ from the values characteristic of physiological pregnancy. Thus, the survey showed that the cytokine profile in pregnancies complicated by preeclampsia did not only increase the levels of pro-inflammatory cytokines, which coincides with the results of other studies [24, 25], but it also amended the ratio of opposite pools. However, changes in the cytokine level depending on the gravity of preeclampsia in the present study did not differ from the dynamics identified in other studies. Thus, many researchers argue that the concentration of IL-1 β significantly rises with increasing severity of preeclampsia and reaches maximum values during severe preeclampsia [26]. An analogous situation was the change in the concentration of other pro-inflammatory cytokines (IL-6 and TNF- α), which increased with the worsening of the disease [27]. Based on elevated concentrations of pro-inflammatory cytokine array, researchers come to the conclusion that there are signs of systemic inflammatory response of preeclampsia [26, 28]. Some authors emphasize the increased synthesis of IL-2 in the third trimester of pregnancy complicated by preeclampsia, thereby significantly increasing the proportions of TNF- α / IL-4 and IL-2 / IL-4 [29]. Based on the data obtained, they are drawing conclusions about the prevalence of Th-1 immune response in this pathology.

A comparison of changes in cytokine profile with increasing severity of preeclampsia allow us to determine the levels of compensation of this pathological condition which reflect the degree of implementation and functional reserve of various mechanisms to maintain homeostasis. The first phase of the changes seen in mild preeclampsia is manifested by an increase when creating all studied cytokines,

except IL-4 and IL-10. During the second phase IL-1 β and TNF- α begin to decrease, ceding to further increment in the levels of IL-8 and IL-6, which suppress the inflammatory reaction occurring as antagonists of IL-1 β and TNF- α . In that period, the limiting role of IL-10 weakens and manifests itself by reduced levels compared with values in normal pregnancy, and hence indicates weakening of the compensatory mechanisms. The third phase, which can be called decompensated, is characterized by the absence of significant differences in the levels of IL-1 β and IL-6, compared with the same level during normal pregnancy. This occurs in the background of increased concentrations of other pro-inflammatory cytokines and reduced levels of anti-inflammatory cytokines IL-4 and IL-10.

In regards to changes whereby anti-inflammatory cytokine concentrations in severe preeclampsia take place in the opposite direction, moderate phase can be considered a critical stage during complicated pregnancy, which comes as the most functional strain to the homeostatic system. It can be assumed that with the effect of moderately aggressive factors acting as initiators of mediator synthesis for intercellular interaction (with moderate preeclampsia), the development of the immune response is regulated by the interaction of cytokines and their antagonists. Through the increasing severity of the pathological process, there is reduction in the impact of regulatory factors that limit the systemic effect, thus causing enhanced creation of cytokines that are activated immunocytes. At a certain stage of this process, spending of functional reserves of mononuclear cells occurs, resulting in a state of decompensation characterized by "leukocyte depression" in which the synthesis of immunoregulatory factors significantly reduces.

Conclusion

Sufficient evidence from animal and human studies has now been gathered to reveal the pathogenesis of preeclampsia on the basis of the influence of cytokines both in the placenta and in the periphery. A unifying hypothesis for preeclampsia is that inadequate trophoblast invasion and remodeling of spiral arteries stimulate placental ischemia and hypoxia via intermittent perfusion of the placenta; this results in an increased release of trophoblast microparticles into the maternal circulation followed by increased production of maternal pro-inflammatory cytokines and activation of maternal endothelial cells. This is proposed to eventually lead to "systemic, diffuse endothelial cell dysfunction" - the fundamental pathophysiological feature of this syndrome.

While understanding the etiology and pathophysiology of preeclampsia is certainly of interest from a basic medical science perspective, it also has important implications for the treatment and management of this dangerous complication. There is renewed optimism that basic and clinical

research, which was instrumental in elucidating the pathogenesis of this disease, will lead to the rational design of interventions for the management and treatment of this important and common complication of pregnancy. In this way, the results of the present study show that pregnancy complicated by preeclampsia are taking significant immunological changes. Disorders in the immune system are associated with the severity of a particular complication of gestational process.

References

- [1] Carty D.M., Anderson L., Duncan C.N., Baird D.P., Rooney L.K., Dominiczak A.F., Delles C.: "Peripheral arterial tone: assessment of microcirculatory function in pregnancy". *J. Hypertens.*, 2012, 30, 117.
- [2] Chistyakova G.N., Gaziyeva I., Remizova I.: "Assessment of the cytokine systems in gestosis-complicated pregnancy: Akušerstvo i ginekologija". *Russie*, 2006, 2, 25.
- [3] Ness R.B., Roberts J.M.: "Epidemiology of hypertension". In: Roberts J., Cunningham F., Lindheimer M. (eds). *Chesley's hypertensive disorders in pregnancy*, 2nd ed. Stamford, 1999, 43.
- [4] Raghupathy R., Al-Azemi M., Azizieh F.: "Intrauterine growth restriction: cytokine profiles of trophoblast antigen-stimulated maternal lymphocytes". *Clin. Dev. Immunol.*, 2012, 2012, 734865. doi: 10.1155/2012/734865. Epub 2011 Oct 31.
- [5] Bowen J.M., Chamley L., Keelan J.A., Mitchell M.D.: "Cytokines of the placenta and extra-placental membranes: roles and regulation during pregnancy and parturition". *Placenta*, 2002, 23, 257.
- [6] Sibai B.M.: "Preeclampsia as a cause of preterm and late preterm (near-term) births". *Semin. Perinatol.*, 2006, 13, 16.
- [7] Keelan J.A., Mitchell M.D.: "Placental cytokines and preeclampsia". *Front. Biosci.*, 2007, 12, 2706.
- [8] Borzychowski A.M., Sargent I.L., Redman C.W.: "Inflammation and pre-eclampsia". *Semin. Fetal Neonatal Med.*, 2006, 11, 309.
- [9] Saito S., Shiozaki A., Nakashima A., Sakai M., Sasaki Y.: "The role of the immune system in preeclampsia". *Mol. Aspects Med.*, 2007, 28, 192.
- [10] Davison J.M., Lindheimer M.D.: "New developments in preeclampsia". *Semin. Nephrol.*, 2004, 24, 537.
- [11] Cunningham F.G., Leveno K.L., Bloom S.L., Hauth J.C., Gilstrap L.C., Wenstrom K.D.: "Williams obstetrics". 22nd ed. New York: McGraw-Hill Co., 2005, 1237.
- [12] Sibai B.M.: "Preeclampsia: an inflammatory syndrome?" *Am. J. Obstet. Gynecol.*, 2004, 191, 1061.
- [13] Brewster J.A., Orsi N.M., Gopichandran N., McShane P., Ekbote U.V., Walker J.J.: "Gestational effects on host inflammatory response in normal and pre-eclamptic pregnancies". *Eur. J. Obstet. Gynecol. Reprod. Biol.*, 2008, 140, 21.
- [15] Villar J., Carroli G., Wojdyla D., Abalos E., Giordano D., Ba'aqeel H., et al.: "Preeclampsia, gestational hypertension and intrauterine growth restriction, related or independent conditions?" *Am. J. Obstet. Gynecol.*, 2006, 194, 921.
- [16] Menzies J., Magee L.A., MacNab Y.C., Ansermino J.M., Li J., Douglas M.J., Gruslin A.: "Current CHS and NHBPEP criteria for severe preeclampsia do not uniformly predict adverse maternal or perinatal outcomes". *Hypertens. Pregnancy*, 2007, 26, 447.
- [17] Hladunewich M., Karumanchi S.A., Lafayette R.: "Pathophysiology of the clinical manifestations of preeclampsia". *Clin. J. Am. Soc. Nephrol.*, 2007, 2, 543.
- [18] Lindheimer M.D., Umans J.G.: "Explaining and predicting preeclampsia". *N. Engl. J. Med.*, 2006, 355, 1056.
- [19] Maynard S., Epstein F.H., Karumanchi S.A.: "Preeclampsia and angiogenic imbalance". *Ann. Rev. Med.*, 2007, 59, 61.
- [20] Xia Y., Ramin S.M., Kellems R.E.: "Potential roles of angiotensin receptor-activating autoantibody in the pathophysiology of preeclampsia". *Hypertension*, 2007, 50, 269.
- [21] McMaster M.T., Zhou Y., Fisher S.J.: "Abnormal placentation and the syndrome of preeclampsia". *Semin. Nephrol.*, 2004, 24, 540.
- [22] Von Dadelszen P., Menzies J., Gilgoff S., Xie F., Douglas M.J., Sawchuck D., et al.: "Evidence-based management for preeclampsia". *Front. Biosci.*, 2007, 12, 2876.
- [23] Sibai B.M., Barton J.R.: "Expectant management of severe preeclampsia remote from term: patient selection, treatment, and delivery indication". *Am. J. Obstet. Gynecol.*, 2007, 196, 514.e1.
- [24] Irgens H.U., Reisaeter L., Irgens L.M., Lie R.T.: "Long-term mortality of mothers and fathers after preeclampsia: population-based cohort study". *BMJ*, 2007, 323, 1213.
- [25] Carty D.M., Delles C., Dominiczak A.F.: "Novel biomarkers for predicting preeclampsia". *Trends Cardiovasc. Med.*, 2008, 18, 186.
- [26] Kang L., Chen C.H., Yu C.H., Chang C.H., Chang F.M.: "Interleukin-1 β gene is not associated with preeclampsia". *Taiwan J. Obstet. Gynecol.*, 2012, 51, 240.
- [27] Prins J.R., Gomez-Lopez N., Robertson S.A.: "Interleukin-6 in pregnancy and gestational disorders". *J. Reprod. Immunol.*, 2012, 95, 1.
- [28] Funai E.F., Friedlander Y., Paltiel O., Tiram E., Xue X., Deutsch L., et al.: "Long-term mortality after preeclampsia". *Epidemiology*, 2005, 16, 206.
- [29] Carty D.M., Delles C., Dominiczak A.F.: "Preeclampsia and future maternal health". *J. Hypertens.*, 2010, 28, 1349.

Address reprint requests to:
A. DANEVA MARKOVA, M.D., Ph.D.
Department of Obstetrics and Gynecology
State University Hospital of Skopje
50 Divizija Street, 34/1-12
1000 Skopje (Republic of Macedonia)
e-mail: anadaneva@yahoo.com

Effects of piroxicam administration on pregnancy outcome in intrauterine insemination (IUI) cycles: a randomized clinical trial

A. Zarei¹, M. Mahboubi², M.E. Parsanezhad¹, S. Alborzi¹, M. Younesi², G. Madadi¹

¹ Division of Infertility, Department of Obstetrics and Gynecology, School of Medicine, Shiraz University of Medical Sciences, Shiraz

² Department of Obstetrics and Gynecology, School of Medicine, Shiraz University of Medical Sciences, Shiraz (Iran)

Summary

Background: Uterus contractibility is considered a powerful prognostic factor in predicting the embryo transfer outcome. Moreover, uterine contractions are known to be stimulated by prostaglandins which are produced by cyclooxygenase from arachidonic acid. As such, suppressing the inflammatory response and contractions using anti-inflammatory and relaxant agents is expected to result in increased success rate of embryo transfer and artificial insemination. **Objective:** To investigate the effect of piroxicam administration on the success rate in intrauterine insemination (IUI) cycles in patients presenting with unexplained infertility. **Materials and Methods:** This randomized, placebo-controlled clinical trial included 260 women with unexplained infertility undergoing IUI cycles. Patients were randomly assigned to receive either piroxicam ten mg/day on days 4-6 after IUI or placebo (control group). The main outcome measures were number of IUI cycles, pregnancy, abortion, and multiple pregnancy rates. **Results:** The pregnancy rate was found to be 25 (19.2%) and 16 (12.3%) in piroxicam and control groups, respectively ($p = 0.039$). Five patients (3.8%) in piroxicam group experienced twin pregnancy whereas only three patients (2.3%) in control group had twin pregnancy ($p = 0.361$). The pregnancy rate per cycle was also significantly higher in those who received piroxicam as compared to controls (11.16 vs. 6.66; $p = 0.021$). **Conclusion:** Administration of piroxicam after IUI is associated with decreased number of cycles, as well as increased pregnancy rate and pregnancy rate per cycle in IUI cycles. However, piroxicam did not have any effect on abortion, multiple pregnancy, and ongoing pregnancy rates.

Key words: Piroxicam; Intrauterine insemination; Pregnancy rate; Abortion rate; Multiple pregnancy rate.

Introduction

Artificial insemination which involves injection of washed sperm into the female genital tract without sexual intercourse is a treatment for couples suffering from male factor infertility [1]. So far, many methods have been introduced and used for artificial insemination of which intracervical and intrauterine insemination are extensively employed in clinical practice. Intrauterine insemination (IUI) is the best method of artificial insemination being studied and widely used [2]. In IUI, the processed, washed, and concentrated sperm specimens are placed into the uterine cavity using the transcervical catheterization. IUI possesses the highest success rate amongst all artificial insemination methods [1].

In assisted reproduction techniques including in vitro fertilization (IVF) and intracytoplasmic sperm injection (ICSI), the implantation failure is the main limiting step in successful pregnancy. Furthermore, the implantation failure may result from several factors including the increased uterine myometrial activity. Uterine receptivity is also affected by several factors which cannot be recognized due to its complex nature. These factors include complex mor-

phological and biochemical changes of the endometrium [3]. By direct visualization of endometrium using high resolution probes, uterus is found to have three distinct patterns of contractibility which potentially affect the outcome of IVF after embryo transfer [4]. It has been shown that the embryo transfer as an aggressive method, induces endometrial contractibility which may contribute to implantation failure. Several other factors have been shown to be responsible for uterine response leading to embryo implantation failure. These include the direct myometrial stimulation by drugs, hyperphysiological hormonal levels, endometrial inflammation secondary to direct manipulation of the endometrium, cervical canalization-induced uterus dynamic responses, and the psychological stress during cycles [5].

Uterus contractibility is now considered a powerful prognostic factor to predict the embryo transfer success rate [6]. It is also known that uterine contractions are stimulated by prostaglandins that are produced by cyclooxygenase (COX) from arachidonic acid. As such, suppressing the inflammatory response and contractions using anti-inflammatory and relaxant agents are expected to result in increased success

Revised manuscript accepted for publication January 13, 2015

rate of embryo transfer and artificial insemination. COX and prostaglandin production can be irreversibly blocked by nonsteroidal anti-inflammatory drugs (NSAIDs) [7]. It is therefore hypothesized that administering NSAIDs in patients who undergo IVF or IUI cycles would suppress the uterine contractility response of the endometrium and potentially results in an increased success rate. Piroxicam is a member of NSAIDs family which is shown to be effective in alleviating dysmenorrhea [7]. Thus its use is expected to possibly result in favorable effects in patients undergoing IVF or IUI cycles.

Along these lines, Moon *et al.* showed that administering piroxicam increases the implantation- as well as pregnancy rates in patients undergoing IVF and embryo transfer. The favorable effects of piroxicam were more remarkable in subjects younger than 40 years and those who suffered from tubal, male factor infertility or endometriosis [8]. In a similar study, Firouzabadi *et al.* reported that administering a single dose piroxicam improves both implantation and pregnancy rates in IVF cycles [9]. Nevertheless, the possible beneficial effects of piroxicam on the success rate of IUI has not been yet investigated. The above gap prompted the present authors to design and implement the current trial to investigate the effect of piroxicam administration on improving the success rate of IUI cycles in females suffering from unexplained infertility.

Materials and Methods

Patients

This randomized clinical trial was carried out in two tertiary healthcare centers affiliated with Shiraz University of Medical Sciences, over a 20-month period from August 2012 to April 2014. The authors included patients referring to infertility clinics of Ghadir Mother and Child Hospital and Motahari Clinic during the study period. Patients who had unexplained infertility were recruited. Infertility was defined as one year of unprotected intercourse without conception. In general, infertility is described as 'unexplained' when standard investigations including semen analysis, tubal patency tests, and assessment of ovulation fail to identify any abnormalities or a specific diagnosis. In order to find the etiology of infertility, partner's semen analysis, hormonal assay including prolactin, thyroid stimulating hormone (TSH), prolactin (to rule out hypophyseal adenomas), follicle-stimulating hormone (FSH), luteinizing hormone (LH) (to rule out ovarian dysfunction such as premature ovarian failure), hysterosalpingogram (HSG), laparoscopy and hysteroscopy (to rule out uterine/tubal factor including peritubular adhesions and endometriosis) were performed in all patients. All examined women had normal plasma concentrations of LH, FSH, and progesterone; normal renal and hepatic function tests; normal complete blood counts; normal HSG, laparoscopy and hysteroscopy and negative pregnancy tests. The authors excluded subjects with polycystic ovaries in transvaginal ultrasonography, those who had autoimmune disorders, and were found to have endometriosis. Patients who entered this blinded trial were matched for age, body-mass index (BMI), and the duration of infertility.

All participants were asked to sign written informed consents before enrollment. The study protocol was approved by the institutional review board (IRB) of Shiraz University of Medical

Sciences under the ethics committee approval code CT-89-5351, assigned in January 2012. The entire protocol was reviewed, approved, and given the Iranian Clinical Trials Code (IRCT) 2013021911790N2.

Study protocol

A total number of 298 women were screened for eligibility to enter the study. All patients underwent complete history and physical examination with all positive findings recorded in their files. The study protocol as well as side effects and benefits were fully explained to all patients and informed written consents were obtained. Patients were then randomly assigned to two groups based on a computer random digit generator using their registration number. Group A (n=130) received ten-mg capsules of piroxicam on days 4-6 after IUI while group B (n=130) received placebo.

Clomiphene citrate (100 mg/PO/day) was administered for five days from day 5 to day 9 of the cycle, and recombinant FSH was injected intramuscularly at 150 units/day from cycle day 8. Vaginal sonography was performed on the 11th day of the cycle and based on the size and number of stimulated follicles, recombinant FSH was continued until at least one dominant follicle with size of >18 mm was identified. Then, 5,000-10,000 units of human chorionic gonadotropin (hCG) was injected intramuscularly, if serum E2 level was below 1,500 pg/ml. IUI was performed 36 hours after hCG injection. Each patient underwent up to three cycles of IUI. β -hCG was checked if the patient experienced one week missed period. Moreover, pregnancy was documented by transvaginal sonography, at six to seven weeks of gestation. Main outcome measures were the number of IUI cycles, pregnancy rate (detected by positive β -hCG), abortion rate, and multiple pregnancy and ongoing pregnancy rates (calculated by subtracting abortion from pregnancy rates). All investigators except the statistician were blinded to the study protocol.

Statistical analysis

Based on 90% power to detect significant differences between the corresponding variables ($p = 0.05$, two-sided), 100 patients were required in each group. To compensate the possible none valuable data, the authors enrolled 130 participants in each group. The statistical software package SPSS, version 15.0 was used for data analysis. The paired *t*-test was employed to compare results within groups, the independent *t*-test to compare results between the groups, and the χ^2 test to compare proportions. Data were reported as mean \pm SD. $P < 0.05$ was considered significant.

Results

A total of 289 patients with unexplained infertility were consecutively selected to undergo IUI cycles and were screened for eligibility out of which 14 were excluded, 13 did not meet the inclusion criteria, and 11 refused to participate in the study. Given the above, a total of 260 subjects were randomly assigned to two study groups, each including 130 patients. All patients followed the study and none of them were lost to follow-up. Therefore, the final number of patients was 260 (Figure 1). The mean age of the patients was 28.9 ± 5.1 (range 18-43) years and the mean duration of infertility was 4.6 ± 4.1 (range 1-23) years.

The overall pregnancy rate and pregnancy rate per cycle were 15.7% and 8.8%, respectively. The pregnancy rate (defined by positive β -hCG) was found to be 25 (19.2%) and 16 (12.3%) in piroxicam and control groups, respec-

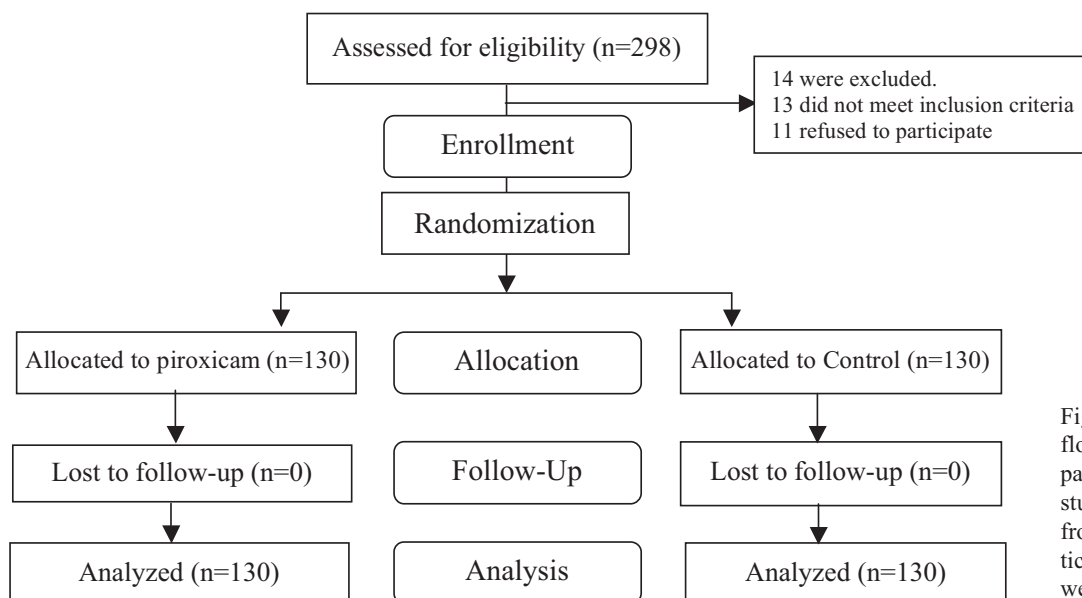


Figure 1. — The study flow chart. All enrolled patients followed the study protocol and data from a total of 130 participant in each group were analyzed.

Table 1. — The outcomes of IUI cycles in infertile patients treated with piroxicam vs. control subjects.

	Piroxicam (n=130)	Control (n=130)	p-value
Age (years)	28.8 ± 4.7	28.9 ± 5.3	0.873
Infertility duration (kg/m ²)	4.6 ± 3.9	4.7 ± 4.1	0.890
Number of IUI cycles	224	240	0.001
Pregnancy rate (%)	25 (19.2%)	16 (12.3%)	0.039
Single pregnancy (%)	20 (15.3%)	13 (10%)	0.028
Abortion rate (%)	5 (3.8%)	5 (3.8%)	0.823
Twin pregnancy (%)	5 (3.8%)	3 (2.3%)	0.361
Pregnancy rate per cycle (%)	11.16	6.66	0.021
Ongoing pregnancy (%)	20 (15.3%)	11 (8.4%)	0.098

tively. The pregnancy rate was significantly higher in piroxicam group ($p = 0.039$). The prevalence of abortion was found to be five (3.8%) in piroxicam group and five (3.8%) in control groups ($p = 0.823$). Five patients (3.8%) in piroxicam group vs. three patients (2.3%) in control group had twin pregnancy. However the difference was not statistically significant ($p = 0.361$). The pregnancy rate per cycle was also significantly higher in patients who received piroxicam as compared to controls (11.16 vs. 6.66; $p = 0.021$). The study results are outlined in Table 1.

Table 2. — The pregnancy rate in IUI cycles.

	1st cycle	2nd cycle	3rd cycle	p-value
Pregnancy	13 (5%)	26 (10%)	2 (0.7%)	0.013
No pregnancy	92 (35.5%)	84 (32.3%)	43 (16.5%)	

Of those who conceived during the study period (41 patients), 25 (9.6%) conceived in the first cycle of the IUI while 34 (13.1%) during the second cycle of IUI, and seven (2.7%) during the third cycles. Using chi-square test, it was shown that two cycles of IUI is was associated with higher pregnancy rate ($p = 0.013$) (Table 2). The pregnancy rate in different IUI cycles in both study groups is demonstrated in Table 3.

Discussion

In this randomized clinical study the authors attempted to investigate the effects of piroxicam administration on IUI outcomes. They found that piroxicam administration was associated with higher pregnancy rate following IUI cycles. Piroxicam use resulted in a higher pregnancy rate per cycle of IUI. However piroxicam was not found to have any favorable effect on abortion rate, multiple pregnancy rate, and

Table 3. — Pregnancy rate in different IUI cycles in both study groups.

	Piroxicam (n=130)			Control (n=130)		
	1st cycle	2nd cycle	3rd cycle	1st cycle	2nd cycle	3rd cycle
Pregnancy	8 (6.2%)	16 (12.3%)	1 (0.7%)	5 (3.8%)	10 (7.6%)	1 (0.7%)
No pregnant	56 (43.1%)	26 (20%)	23 (17.7%)	36 (27.7%)	58 (44.9%)	20 (15.3%)

the ongoing pregnancy rate following IUI cycles. This is the first study investigating the effect of piroxicam on IUI outcomes, hence no comparison with other studies is possible.

The pregnancy rate and pregnancy rate per cycle of IUI in this study was similar to those previously reported by Alborzi *et al.* [10]. They performed a randomized clinical trial including 110 patients with unexplained, male factor, and cervical factor infertility undergoing IUI cycles using either single or double insemination per cycle methods. The overall pregnancy rate and the pregnancy rate per cycle were reported to be 38.2% and 8.6%, respectively. Comparable to the present findings, most patients conceived in the first two cycles of treatment. The pregnancy rate as well as pregnancy rate per cycle of IUI in this study was comparable to the present results (pregnancy rate and pregnancy rate per cycle of 15.7% and 8.8%, respectively).

Piroxicam is an anti-inflammatory agent and since the uterine contractibility is responsible for implantation failure in IVF and IUI cycles, its administration in patients undergoing IUI and IVF cycles is expected to yield beneficial effects. This hypothesis has been tested by several authors [8, 9, 11]. In this regard, Moon *et al.* performed a prospective, randomized, double-blinded placebo-controlled clinical study including 188 consecutive cycles of fresh IVF-embryo transfer (ET) and 78 cycles of frozen-thawed ET being randomly assigned to receive piroxicam (ten mg piroxicam) and placebo, one to two hours before ET [8]. The primary outcomes were implantation and pregnancy rates. They found that the implantation rate and pregnancy rate increased significantly by 18.7% and 46.8%, respectively, in patients receiving piroxicam as compared to the placebo group (8.6% and 27.6%, respectively). Those who were younger than 40 years of age as well as patients who suffered from tubal, male infertility factor or endometriosis had a significantly higher pregnancy rates with piroxicam. It has been concluded that piroxicam administration before ET increases both implantation- and pregnancy rates. This favorable effect was appeared to be more prominent in patients younger than 40 years and those who suffer from tubal, male factor infertility or endometriosis [8]. Piroxicam is classified as Group C drugs in pregnancy (according to FDA classification). Up to now, no report has warned of the association between the administration of piroxicam or other NSAIDs and preterm birth, low birth weight or congenital malformations. In line with this, earlier reports [8, 9] have shown that piroxicam in limited dose is safe during the pregnancy or implantation period.

Dal Prato and Borini performed another randomized clinical trial in order to determine the effect of piroxicam on the ET outcome [11]. They enrolled 200 women suffering from tubal, male, endometriosis or unexplained factor infertility aging 28-43 years. Patients were randomly assigned to receive ten mg piroxicam or placebo one to two hours prior to ET. The investigation did not find any significant difference

between the two study groups in terms of positive β hCG (37% vs. 47%) and the pregnancy rate (34% vs. 38%). The study also reported no significant difference between groups with regard to the abortion rate. The effect of piroxicam was shown to be independent of age, BMI, the duration and various etiologies of infertility. This report further suggested that single dose administration of piroxicam before ET in patients undergoing IVF is of no beneficial effects [11].

In a similar study by Firouzabadi *et al.*, the effect of single dose administration of piroxicam before ET was examined in 180 fresh IVF-ET cycles in which patients were randomly assigned to receive ten mg piroxicam or placebo one to two hours before ET [9]. According to their results, piroxicam administration increased the implantation (12.3% vs. 7.7%) as well as pregnancy rates (25.5% vs. 10%), as compared to placebo. They also found that abortion rate was significantly lower in those who received piroxicam (1% vs. 5%). The beneficial effects of piroxicam in IVF-ET outcomes can be further established in future well-designed studies. Although several studies have investigated the effects of piroxicam administration on IVF-ET outcome, no study has addressed this issue in IUI cycles. To the best of the present authors knowledge, this is the first study to investigate such issue.

The beneficial effects of piroxicam on IVF and IUI outcomes can be summarized in two points. Firstly, the uterine contractibility is reduced by administering piroxicam. Based on the evidence from earlier reports, during the spontaneous cycles, non-conceptional cycles has more endometrial wave-like activity compared to conceptional cycles [12]. In addition, it has also been shown that high frequency contractions of uterus are associated with poorer IVF-ET, implantation and pregnancy outcomes [4]. It can be concluded that uterine contractibility is associated with poorer pregnancy outcomes in IUI and IVF cycles. Prostaglandins, being synthesized by COX, are responsible for stimulating uterine contractions [7]. Therefore, blockade of the COX using NSAIDs can result in decreased uterine contractibility and in turn increases the implantation outcome following IUI or IVF cycles. Secondly, the uterine blood supply and flow is increased following the use of NSAIDs including piroxicam. Previous studies have shown that aspirin administration is associated with increased implantation and pregnancy rates following IVF cycles [13]. Moreover, findings have indicated that the favorable effects of aspirin are attributed to increased uterine blood flow [13].

The utero-placental unit of human is colonized by hematopoietic cells of which 65–70% are natural killer (NK) cells and 10–20%, are antigen presenting cells (APCs). NK cells regulate the invasion of trophoblast. On the other hand, decidual NK cells induce vascular growth needed to establish an adequate decidua. Decidual cells (DCs) begin and coordinate the immune response [5]. These cells are gathered in the pregnant uterus before implantation and will remain in the deciduas until the end of

the pregnancy. A recent study showed that without the uterine DCs, severe impairment of implantation will result [14]. Another study, carried out on a mice model, showed that the spontaneous abortion rate is decreased by therapy with DCs [7]. In conclusion, administration of piroxicam was shown to be associated with increased pregnancy rate in IUI cycles. However, piroxicam did not yield any effect on abortion and multiple pregnancy rates [15]. In other words, the opposition which is necessary for implantation requires an inflammatory- followed by an anti-inflammatory responses. The present evidence further suggests that inflammation is necessary for implantation. Thus, suppressing this beneficial inflammation by administering NSAIDs will result in decreased implantation rate or increased abortion rate. As demonstrated by Bernabeu *et al.*, indomethacin does not affect the initial inflammatory response required for implantation [5]. These results are consistent with animal studies showing that indomethacin does not affect the implantation in rats [16]. However, with piroxicam, as a different NSAID, the present authors observed favorable results suggesting no effect on the inflammatory response of endometrium in such a negative way.

Conclusion

In conclusion, administration of piroxicam after IUI was found to be associated with increased pregnancy rate and pregnancy rate per cycle in IUI cycles. Meanwhile, piroxicam administration yielded no notable effect on abortion, multiple pregnancy, and ongoing pregnancy rates.

References

- [1] Guzik D.S., Carson S.A., Coutifaris C., Overstreet J.W., Factor-Litvak P., Steinkampf M.P., *et al.*: "Efficacy of superovulation and intrauterine insemination in the treatment of infertility. National Cooperative Reproductive Medicine Network". *N. Engl. J. Med.*, 1999, 340, 177.
- [2] Besselink, D.E., Farquhar, C., Kremer, J.A., Marjoribanks, J., O'Brien, P.: "Cervical insemination versus intra-uterine insemination of donor sperm for subfertility". *Cochrane Database Syst Rev.*, 2008, CD000317.
- [3] Tabibzadeh S., Babaknia A.: "The signals and molecular pathways involved in implantation, a symbiotic interaction between blastocyst and endometrium involving adhesion and tissue invasion". *Hum. Reprod.*, 1995, 10, 1579.
- [4] Fanchin, R., Righini C., Olivennes F., Taylor S., de Ziegler D., Frydman R.: "Uterine contractions at the time of embryo transfer alter pregnancy rates after in-vitro fertilization". *Hum. Reprod.*, 1998, 13, 1968.
- [5] Bernabeu R., Roca M., Torres A., Ten, J.: "Indomethacin effect on implantation rates in oocyte recipients". *Hum. Reprod.*, 2006, 21, 364.
- [6] Fanchin R.: "Assessing uterine receptivity in 2001: ultrasonographic glances at the new millennium". *Ann. N. Y. Acad. Sci.*, 2001, 943, 185.
- [7] Dawood, M.Y.: "Nonsteroidal antiinflammatory drugs and reproduction". *Am. J. Obstet. Gynecol.*, 1993, 169, 1255.
- [8] Moon H.S., Park S.H., Lee J.O., Kim K.S., Joo B.S.: "Treatment with piroxicam before embryo transfer increases the pregnancy rate after in vitro fertilization and embryo transfer". *Fertil. Steril.*, 2004, 82, 816.
- [9] Firouzabadi R.D., Ghandi S., Tayebi N.: "Effect of administration of single dose piroxicam before embryo transfer on implantation and pregnancy rates in IVF cycles". *J. Biol. Sci.*, 2007, 7, 123.
- [10] Alborzi S., Motazedian S., Parsanezhad M.E., Jannati S.: "Comparison of the effectiveness of single intrauterine insemination (IUI) versus double IUI per cycle in infertile patients". *Fertil. Steril.*, 2003, 80, 595.
- [11] Dal Prato L., A. Borini A.: "Effect of piroxicam administration before embryo transfer on IVF outcome: a randomized controlled trial". *Reprod. Biomed. Online*, 2009, 19, 604.
- [12] Jland M.M., I., Evers J.L., Dunselman G.A., Volovics L., Hoogland H.J.: "Relation between endometrial wavelike activity and fecundability in spontaneous cycles". *Fertil. Steril.*, 1997, 67, 492.
- [13] Rubinstein M., Marazzi A., Polak de Fried E.: "Low-dose aspirin treatment improves ovarian responsiveness, uterine and ovarian blood flow velocity, implantation, and pregnancy rates in patients undergoing in vitro fertilization: a prospective, randomized, double-blind placebo-controlled assay". *Fertil. Steril.*, 1999, 71, 825.
- [14] Plaks V., Birnberg T., Berkutzi T., Sela S., BenYashar A., Kalchenko V., *et al.*: "Uterine DCs are crucial for decidua formation during embryo implantation in mice". *J. Clin. Invest.*, 2008, 118, 3954.
- [15] Laskarin G., Kammerer U., Rukavina D., Thomson A.W., Fernandez N., Blois S.M.: "Antigen-presenting cells and materno-fetal tolerance: an emerging role for dendritic cells". *Am. J. Reprod. Immunol.*, 2007, 58, 255.
- [16] Gupta U., Malhotra N., Varma S.K., Chaudhury R.R.: "Effect of intrauterine administration of antiprostaglandin drugs on implantation in the rat". *Contraception*, 1981, 24, 283.

Address reprint requests to:
 GOOYA MADADI, M.D.
 Infertility Research Center
 Department of Obstetrics and Gynecology
 School of Medicine
 Shiraz University of Medical Sciences
 P.O. Box 7134814336
 Shiraz (Iran)
 e-mail: gmadadi@sums.ac.ir

Efficiency of GnRH analogues in treating large functional ovarian cysts

S. Zervoudis¹, G. Iatrakis², E. Tomara³, A. Bothou³, P. Peitsidis², G. Mastorakos⁴

¹ Rea Hospital Breast Dept, Technological Educational Institute of Athens, Athens

² Department of Obstetrics & Gynecology, Technological Educational Institute of Athens, Athens

³ University of Athens, Midwifery Department, Technological Educational Institute of Athens, Athens

⁴ University of Athens, Clinical Endocrinology, Aretaieio Hospital, Athens (Greece)

Summary

Aim: The aim of this study was to determine the potential therapeutic benefit of a single administration of a GnRH analogue in premenopausal women presenting large functional ovarian cysts (FOCs) (diameter > five cm). *Materials and Methods:* Fifty-one patients (median age 37.4 years) diagnosed with ovarian cysts, presumed benign based on transvaginal and/or transabdominal ultrasound, were divided in three study groups. Patients of group A received no medication whereas patients of groups B and C were treated with a single administration of a GnRH analogue and combined oral contraceptives, respectively. Patients were re-examined after a three-month period. Three of the 51 patients were lost in follow-up or stopped the treatment. *Results:* Complete resolution of the ovarian cysts was observed in eight (50%), 14 (70%), and eight (67%) patients of groups A, B, and C, respectively. No side effects were observed in either of the three groups. The positive therapeutic effect in group B did not reach statistical significance compared with the two other groups ($p > 0.05$). *Conclusion:* A new option of treating large FOCs through a single-dose of a GnRH analogue is proposed and should be carefully considered. Further research is needed in order to evaluate GnRH analogues as an alternative treatment.

Key words: Functional ovarian cysts; GnRH analogues; Benign ovarian tumors.

Introduction

Functional ovarian cysts (FOCs) are common and may occur in women of all ages, mainly in those of reproductive age [1]. Usually, FOCs are either follicular cysts or corpus luteum cysts that develop during the physiologic procedure of ovulation [2]. Most of them are incidentally found during bimanual gynecological (pelvic) examination and/or ultrasound. In general, they remain asymptomatic until their resolution [3]. If a FOC is found during pelvic examination, further evaluation with transvaginal and/or transabdominal ultrasound is required [4].

In order to evaluate a patient with a FOC, the anatomic position, the size and the morphology of the mass, age, and the reproductive status of the patient should be considered [5]. The prevalence of FOCs varies from almost 8% to 18% depending on the criteria of the studies and the pre- or postmenopausal status [6]. Prevalence, in premenopausal women reaches 8% while in postmenopausal women it is about 14% (with annual incidence of 8%). Fifty percent of these FOCs will persist for at least one year [7, 8]. The age of the patient has a strong impact on the differential diagnosis [9].

In addition, according to ultrasound and clinical features, the clinicians can exclude urgent conditions and malignancy [3]. Color Doppler can be used as complementary mean of evaluation in order to report the blood flow in the

ovarian mass [10, 11]. Other markers of malignancy result from magnetic resonance imaging and laboratory tests such as CA 125, HE4, TATI, and CA72.4 [5, 12]. However, the conclusive diagnosis of the type of the ovarian mass will be given through surgical exploration and histopathologic evaluation. Depending on the type of the adnexal mass, as well as on the clinical and the laboratory findings, the clinicians will determine the therapeutic and follow-up strategies.

In case of FOCs, the therapeutic use of combined oral contraceptives (COCs) is considered a "classic" approach [10]. Based on recently published data, the COCs by inhibiting pituitary gonadotropins suppress follicular growth and ovulation, reduce the risk of cyst occurrence, and eventually prevent the formation of new ones [2]. Unfortunately, there are no other therapeutic agents that block the pituitary-ovarian axis and are extensively studied and tested in humans. In this study, the authors investigated an alternative hormonal approach that could be efficacious in large FOCs and compared it to the use of COCs that is the use of GnRH analogues.

Materials and Methods

Fifty-nine premenopausal female patients, who participated in this clinical study, were consecutively diagnosed during a three-

Revised manuscript accepted for publication January 19, 2015

year period (2011-2013) in Rea Maternity Hospital (Athens, Greece) with one ovarian cyst sizing more than five-cm in diameter. This diagnosis came up incidentally during pelvic examination. All participants underwent transvaginal ultrasound (including color Doppler ultrasound) and suspicious findings were discovered in eight patients. Serum CA 125 and HE4 were measured in all participants. The latter tumor marker was measured considering that, commonly, it is not increased in benign conditions as conversely happens with the CA 125 marker. In the 51 patients considered malignancy-free after the ultrasound examination, the levels of these markers remained within normalcy, as expected. Women lost to follow-up and those with suspicious findings in ultrasonography were excluded from the study. None of the 51 patients included in the study was suffering from a severe disease including breast or endometrial cancer and none was pregnant or breastfeeding. Written informed consent was signed from all participants.

The selected dose of the GnRH agonists was a single dose of 11.25 mg of triptorelin while the treatment with COCs contained 30 mcg of ethinyl estradiol and 3 mg of drospirenone. The 51 consecutively selected patients separated in three groups with similar characteristics. Participants randomly assigned to receive their medication during the first appointment after clinical examination. Group A, consisted of 16 patients and received no medication for these FOCs. In groups B and C, 22 and 13 patients were included, respectively. Patients of group B were treated with a single dose of a GnRH analogue while patients of group C received a treatment with COCs. Two patients of group B decided not to adhere to the suggested treatment and one patient in group C was lost to follow-up. Thus, the final number of patients included in this study was 48 (with a median age of 37.4 years). A new appointment was arranged after three months for a transvaginal ultrasound test, which was performed by the same gynecologist with the same ultrasound imaging machine.

Results

After the second visit, complete resolution of the FOCs was observed in eight patients of group A (50%), in 14 patients (70%) of group B, and in eight patients of group C (67%) (Figures 1, 2). Treatment with the GnRH analogue in group B was well-tolerated. The number of patients with resolved FOCs in this group, did not show statistically significant difference as compared with the patients of the two

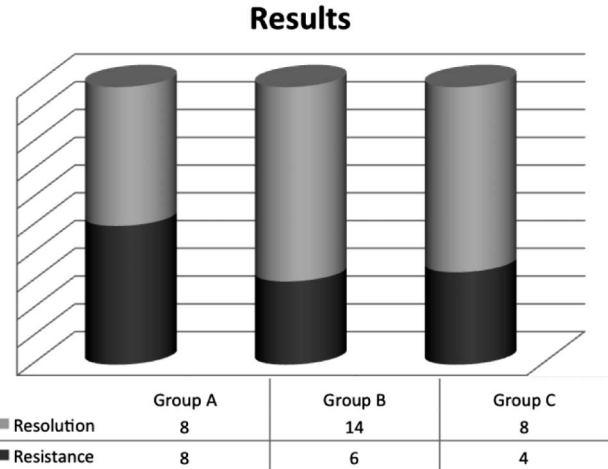


Figure 1. — Results for each study group expressed as percentages.

other groups studied ($p > 0.05$). The size of the FOCs of the patients of all groups studied that did not resolve remained unchanged while none of the patients studied presented new FOCs during the study duration.

Discussion

As it is aforementioned, the efficiency of GnRH analogue alone as treatment of FOCs in otherwise healthy women has not been studied before. They were used once in a randomized blind clinical trial for the treatment of bovine ovarian cysts [13]. Also, there were used in some other studies, as co-treatment with tamoxifen in women with breast cancer who had developed ovarian cysts [14-16]. The ovarian cyst formation is a relatively common side effect of tamoxifen either in premenopausal or postmenopausal women with breast cancer. In the women of a prospective controlled study, the cure rate of the ovarian cyst was 97% [14].

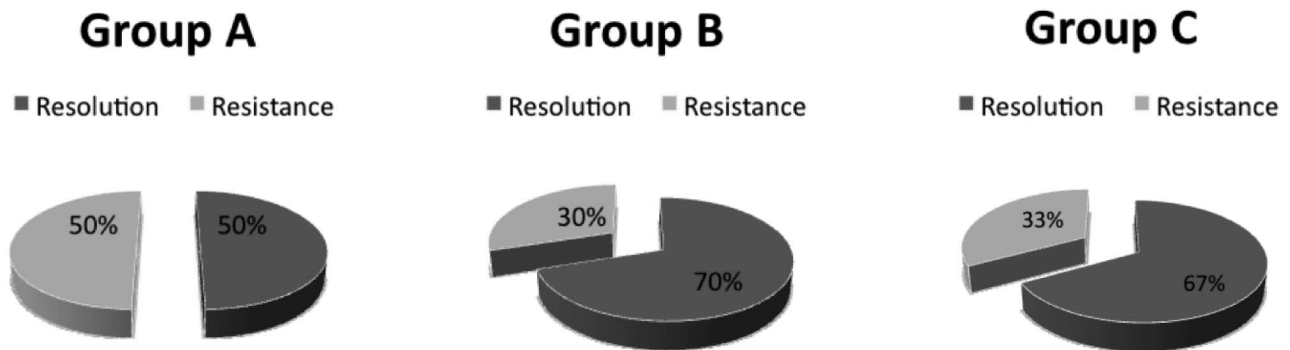

Figure 2. — Results for each study group, expressed as percentages.

For the general population, the use of COCs reduces the risk of development cyst of FOCs, due to the resulting suppression of follicular growth and ovulation [17]. However, the current low-dose COCs are at disadvantage because they cannot succeed the suppression of all follicular activity [18, 19] while high-dose COCs seem to protect against cyst development [20] with probable more side effects.

Considering the effects of COCs, it was hypothesized that they may decrease the size and hasten the resolution of the existing cysts. Both of these hypotheses were demolished after a Cochrane review, which included the results of eight randomized trials with a total number of 686 women treated by any type of COCs [21]. The conclusion appeared to be the same for all cysts, either for those that were bearing upon ovulation induction or those that occurred spontaneously. Consequently, the actual predominant recommendation is that COCs are not to be used for this purpose [18, 21].

Conclusion

Given the aforementioned results, GnRH analogues could be a new alternative therapeutic proposal. Although GnRH analogues are used successfully in different gynecologic conditions [22], it is the first time that a single administration of a GnRH analogue is used successfully in women with FOCs. Further studies with increased number of patients could alter the future recommendations and confirm this new therapeutic indication.

References

- [1] Helm C.W.: "Ovarian cysts". *Medscape*, 2014. Available at: <http://emedicine.medscape.com/article/255865-overview>
- [2] Horlen C.: "Ovarian cysts: a review". *US Pharm.*, 2010, 35, 1.
- [3] American College of Obstetricians and Gynecologists: "ACOG Practice Bulletin No. 83: Management of adnexal masses". *Obstet. Gynecol.*, 2007, 110, 201.
- [4] Le T., Giede C., Salem S., Lefebvre G., Rosen B., Bentley J., et al.: "Initial evaluation and referral guidelines for management of pelvic/ovarian masses". *J. Obstet. Gynaecol. Can.*, 2009, 31, 668.
- [5] Muto G.M.: "Approach to the patient with an adnexal mass". *UptoDate*, 2013. Available at: <http://www.uptodate.com/contents/approach-to-the-patient-with-an-adnexal-mass>
- [6] Ross E.K., Kebria M.: "Incidental ovarian cysts: when to reassure, when to reassess, when to refer". *Cleve. Clin. J. Med.*, 2013, 80, 503.
- [7] Borgfeldt C., Andolf E.: "Transvaginal sonographic ovarian findings in a random sample of women 25–40 years old". *Ultrasound Obstet. Gynecol.*, 1999, 13, 345.
- [8] Greenlee R.T., Kessel B., Williams C.R., Riley T.L., Ragard L.R., Hartge P., et al.: "Prevalence, incidence, and natural history of simple ovarian cysts among women >55 years old in a large cancer screening trial". *Am. J. Obstet. Gynecol.*, 2010, 202, 373.
- [9] Hoffman S.M.: "Differential diagnosis of the adnexal mass". *UptoDate*, 2014. Available at: <http://www.uptodate.com/contents/differential-diagnosis-of-the-adnexal-mass>
- [10] Muto M.G.: "Management of an adnexal mass". *UptoDate*, 2014. Available at: http://www.uptodate.com/contents/management-of-an-adnexal-mass?source=search_result&search=management+of+adnexal+mass&selectedTitle=1~122
- [11] American College of Obstetricians and Gynecologists: "The role of the obstetrician-gynecologist in the early detection of epithelial ovarian cancer. Committee Opinion No. 477". *Obstet. Gynecol.*, 2011, 117, 742.
- [12] Wiwanitkit V.: "CA-125 and risk of malignancy index for screening for malignancy in fertile aged females with ovarian cyst, which is more cost effectiveness?" *Indian J. Med. Paediatr. Oncol.*, 2013, 34, 72.
- [13] Dinsmore R.P., White M.E., Guard C.L., Jasko D.J., Perdrizet J.A., Powers P.M., Smith M.C.: "A randomized double blind clinical trial of two GnRH analogues for the treatment of cystic ovaries in dairy cows". *Cornell. Vet.*, 1987, 77, 235.
- [14] Kourounis G., Zervoudis S., Michail G., Fotopoulos A.: "Tamoxifen induced ovarian cysts in postmenopausal breast cancer patients treated with GnRH agonists: a prospective controlled study". *Obstetrica si Ginecologia*, 2005, LIII, 79.
- [15] Shulman A., Cohen I., Altaras M.M., Maymon R., Ben-Nun I., Tepper R., Beyth Y.: "Ovarian cyst formation in two pre-menopausal patients treated with tamoxifen for breast cancer". *Hum. Reprod.*, 1994, 9, 1427.
- [16] Shusan A., Peretz T., Mor Yosef S.: "Therapeutic approach to ovarian cysts in tamoxifen-treated women with breast cancer". *Int. J. Gynecol. Obstet.*, 1996, 52, 249.
- [17] Thomain A., Daraï E., Chabbert-Buffet N.: "Medical treatments of presumed benign ovarian tumors". *J. Gynecol. Obstet. Biol. Reprod. (Paris)*, 2013, 42, 774.
- [18] American College of Obstetricians and Gynecologists: "ACOG Practice Bulletin No. 110. Noncontraceptives uses of hormonal contraceptives". *Obstet. Gynecol.*, 2010, 115, 206.
- [19] Holt V., Cushing-Haugen K.L., Daling J.R.: "Oral contraceptives, tubal sterilization, and functional ovarian cyst risk". *Obstet. Gynecol.*, 2003, 102, 252.
- [20] Brun J.L., Le Touzé O., Leng J.J.: "Traitement médical et chirurgical des kystes de l'ovaire fonctionnels". *J. Gynecol. Biol. Reprod.*, 2001, 30, 4S41.
- [21] Grimes D.A., Jones L.B., Lopez L.M., Schulz K.F.: "Oral contraceptives for functional ovarian cysts". *Cochrane Database Syst. Rev.*, 2014, 4, CD006134.
- [22] Zervoudis S., Iatrakis G., Navrozoglou I.: "Reproduction after breast cancer". *Best Pract. Res. Clin. Obstet. Gynaecol.*, 2010, 24, 81.

Address reprint requests to:
S. ZERVOUDIS, M.D., Ph.D.
Rea Hospital
Suggrou Avenue 383
Palaio Faliro, 17564 (Greece)
e-mail: szervoud@otenet.gr

In vitro fertilization outcomes in obese women under and above 35 years of age

F. Vural¹, B. Vural², Y. Çakıroğlu²

¹ Department of Obstetrics and Gynecology Clinic, Haydarpaşa Numune Teaching Hospital, Istanbul

² Department of Obstetrics and Gynecology, Kocaeli University, Faculty of Medicine, Kocaeli (Turkey)

Summary

Purpose: To explore the impact of obesity on in vitro fertilization (IVF) outcomes and comparing the results with regards to age groups. **Materials and Methods:** This retrospective cohort recruited 780 women that underwent IVF. Women with polycystic ovarian syndrome (PCOS) were excluded from the study. Women under and above 35 years were categorized into three groups as normal weight, overweight, and obese. The main outcome measures were ovarian response, oocyte maturity, and clinical pregnancy rates. **Results:** Despite oocyte count and fertilization rate that decreased in both younger and older obese women, this difference was not statistically significant. After age matched-normal weight controls, the clinical pregnancy rates were significantly decreased in older obese women. On the other hand, poor ovarian response observed significantly in young obese women without effect on pregnancy rates. **Conclusion:** These results suggested that obesity in young and old women has different outcomes and different steps of IVF process may be affected.

Key words: BMI; Obesity; IVF; ICSI; Ovarian response.

Introduction

Obesity is associated with detrimental health consequences and it is a major public health problem with increasing incidence worldwide. Approximately half of the reproductive age women are overweight or obese [1]. Beside its health consequences, as hypertension, type II diabetes, coronary heart diseases, stroke, and gastrointestinal diseases, obesity has also a deleterious effect on reproductive functions [2-4].

The effect of obesity on reproductive system is a multifactorial and complex mechanism and results in disturbances of the hypothalamic pituitary axis, ovarian, and endometrial functions [5]. The effect of body weight changes on natural fecundity have been well demonstrated with decreased ovulation, increased time until pregnancy, and increased rates of miscarriages [6]. The impact of obesity on in vitro fertilization (IVF) outcomes is a debatable subject [7]. There are several studies with controversial results. Some of the previous studies showed lower ovarian response, lower pregnancy rates, decreased oocyte and embryo quality, while others showed no significant effect [5-10]. The impact of obesity on IVF outcomes is inconsistent with ongoing scientific discussion [7].

There are several causes of discrepancies in the previous studies, such as heterogeneity of the body mass index (BMI) classification, controlled ovarian hyperstimulation (COH) protocol, studied population that includes polycystic ovarian syndrome (PCOS) and old age women [7, 8]. Thus, standardized classification of body mass index (BMI)

in the studies and exclusion of PCOS will give a chance of reproducibility and reliability of results [8]. There are few studies adjusting confounders [9, 10]. Age is also one of the most important factors in IVF success [11-13]. Furthermore the embryo quality is effected from patient age and sperm quality. For this reason the authors designed a study with adjusting the confounding factors age, PCOS, and male factor. The aim of the study was to explore the impact of obesity, overweight, and normal weight on ovarian response, oocyte maturity, embryo quality, and clinical pregnancy rates of women underwent IVF, excluding PCOS, male factor infertility cases, and comparing outcomes with regards to ages under and above 35 years.

Materials and Methods

This study was conducted in women who underwent the IVF procedure in the Assisted Reproductive Unit of Kocaeli University, from 2011 to 2013. A total of 780 patients enrolled in the study. Data was collected retrospectively from hospital files. PCOS, male factor infertility, previous failed attempt of IVF, frozen-thawed embryo, BMI less than 18.5 kg/m², and ovarian stimulation other than GnRH antagonist protocol were excluded. This study was approved by the Ethic Committee of Kocaeli University.

Baseline evaluation

All patients had a routine infertility evaluation as ultrasonography, day 3 hormonal evaluations (serum FSH, LH, E₂, AMH, DHEAS, TSH, free T₄ levels), hysterosalpingography, and semen analysis. BMI is an index as weight in kilograms divided by the square of the height in meters (kg/m²). Patients were categorized

Revised manuscript accepted for publication November 3, 2014

Table 1. — The comparison of the characteristic findings of Groups 1, 2, and 3.

	Group 1	Group 2	Group 3	<i>p</i> value
Age	32.3 ± 3.2	33.4 ± 17.0	33.2 ± 4	0.246
Infertility duration (years)	5.6 ± 3.7	7.5 ± 4.8	8.7 ± 0.5	0.000
Gravidity	0.3 ± 0.9	0.4 ± 0.9	0.6 ± 1.1	0.06
Parity	0.08 ± 0.5	0.05 ± 0.2	0.14 ± 0.4	0.229
Abortion	0.2 ± 0.7	0.2 ± 0.7	0.3 ± 0.8	0.390
Previous molar pregnancy	0.02 ± 0.4	0.00 ± 0.06	0.00	0.768
Previous biochemical pregnancy	0.04 ± 0.4	0.03 ± 0.2	0.06 ± 0.5	0.766
FSH level (mIU/ml)	8.2 ± 4.4	7.8 ± 3.8	7.7 ± 3.4	0.339
LH level (mIU/ml)	5.4 ± 3.4	4.7 ± 2.7	4.4 ± 2.3	0.04
E ₂ level (pg/ml)	56.6 ± 49	57.2 ± 104	55.5 ± 35	0.980
AMH (ng/ml)	1.5 ± 1.7	1.6 ± 2.3	1.5 ± 1.5	0.830
DHEAS (ug/dl)	176 ± 108	194 ± 106	168 ± 84	0.350
Total gonadotropin dose	2721 ± 1225	2739 ± 1102	2968 ± 1044	0.287
COH days	8.8 ± 2.5	8.9 ± 2.1	9.1 ± 2.1	0.467
Total oocyte retrieved	8.4 ± 7.4	7.6 ± 6.0	6.7 ± 5.6	0.487
M II oocyte count	6.4 ± 5.9	5.8 ± 4.3	4.7 ± 3.7	0.03
Embryo count	3.2 ± 3.1	2.8 ± 2.4	2.3 ± 1.7	0.07
Embryo quality (% of 8 cell embryos & low fragmentation)	90%	85%	85%	0.342
Fertilization rate	69.5 ± 31.7	65.6 ± 30.1	66.6 ± 34.4	0.456
Cycle cancellation rate (%)	10	13	14	0.772
Clinical Pregnancy rates (%)	33	25.1	16.9	0.02

into three classes according to the BMI classification of the WHO. BMI < 25 kg/m² was accepted as normal weight women (Group 1, n=452), BMI 25-30 kg/m² were accepted as overweight (Group 2, n=230), and BMI ≥ 30 kg/m² were accepted as obese (Group 3, n=98).

IVF protocol

COH stimulation was performed via antagonist protocol and the dosage of gonadotropins were adjusted and individualized according to ovarian response of patients. The monitorization of COH stimulation was done via serum estradiol levels and follicular size was followed by transvaginal ultrasonography. Recombinant hCG was administered subcutaneously when follicles obtained 17-18 mm in size. Oocytes retrieval was carried out under transvaginal ultrasound under sedation-analgesia. Intracytoplasmic sperm injection (ICSI) was performed for all patients. Patients were categorized as normal, poor, and hyper-responders with regards to oocyte count retrieved (OR). OR less than 3 was accepted as a poor ovarian response. OR equal to 3-15 were accepted as normal ovarian response. The oocytes were categorized according to nuclear maturation grading as metaphase II (M II) (mature oocytes) and non-metaphase II. Clinical pregnancy is defined as ultrasonographically detected gestational sac, thus biochemical pregnancies were excluded.

The main measure outcomes were clinical pregnancy rates, fertilization rates, oocyte maturity, and total oocyte counts.

Analysis

Statistical evaluation was conducted with SPSS 18.0. A *p* value < 0.05 was accepted as statistically significant. All data were evaluated in 95% confidence interval. Descriptive statistics were expressed in absolute numbers and percentages for nominal data, and continuous variables were expressed as mean values and standard deviations. The comparison of groups was done by ANOVA test and χ^2 -test (or Fisher's exact test if appropriate). The homogeneity of variances analyzed by Levene and Welch test. The factors affecting pregnancy rates were analyzed by logistic regression analysis.

Results

A total of 780 patients categorized into three groups with regards to BMI. Group 1 was normal weight women (n= 452). Group 2 was overweight women (n= 230) and Group 3 was obese women (n=98). The characteristics of women, basal hormonal evaluations and IVF outcomes of the general population are summarized in Table 1. The duration of infertility was significantly increased in Groups 2 and 3 compared to Group 1 (*p* < 0.05). The comparison between Groups 2 and 3 was similar as regard to age, gravidity, parity, and abortion. All the hormonal values were similar, except LH level of Group 1 that was significantly higher than Groups 2 and 3 (*p* < 0.05). The length of stimulation and gonadotropin dose increased while total oocytes retrieved, MII oocytes, embryo count, fertilization rates, and clinical pregnancy rates decreased in obese women compared to normal weight controls. Among these differences the reductions in MII oocytes (*p* = 0.03) and clinical pregnancy rates (*p* = 0.03) reached statistical significance. Logistic regression analysis was done to assess clinical pregnancy rates. Obesity, antral follicle count (AFC) less than 5, and age above 35 years were the independent variables entered into an equation to predict pregnancy rates. According to this equation, age was the only independent variable affecting pregnancy outcomes (*p* < 0.05) [Age above 35 years (RR: 3.09, *p* = 0.01), obesity (RR:0.639, *p* = 0.564), basal AFC < 5 (RR: 0.563, *p* = 0.336)].

Younger group (< 35 years old)

The IVF outcomes of women under 35 years of age is presented in Table 2. The obese women compared to age matched normal weight controls. OR, oocyte maturity, fer-

Table 2. — The comparison of Groups 1, 2, and 3 in women under 35 years age.

	Group 1	Group 2	Group 3	<i>p</i> value
Age	29.5 ± 3.2	30.3 ± 3.6	31.1 ± 2.8	0.182
Total oocytes retrieved	9.7 ± 7.7	8.3 ± 6.1	7.5 ± 6.1	0.203
Infertility duration (years)	5.1 ± 2.7	8.2 ± 4.8	7.2 ± 3.3	0.006
M II oocyte count	6.4 ± 4.3	6.5 ± 3.5	4.7 ± 3.9	0.087
Embryo count	3.0 ± 3.3	3.0 ± 2.5	2.4 ± 1.8	0.099
Embryo quality (eight-cell embryos & low fragmentation)	92%	90%	91%	0.189
Fertilization rate	75.5 ± 28.0	67 ± 26.5	68.9 ± 20.6	0.101
Gonadotropin dose	2632 ± 1035	2665 ± 882	2916 ± 730	0.088
Poor ovarian response rate (%)	16.8	24.8	33.3	0.04
Cycle cancellation rate	10	14.4	9.2	0.211
Pregnancy rate	35	26.9	28.5	0.311

Table 3. — The comparison of IVF outcomes of Groups 1, 2, and 3 in women above 35 years age.

	Group 1	Group 2	Group 3	<i>p</i> value
Age	38.5 ± 2.4	39.9 ± 5	39.1 ± 2.7	0.215
Infertility duration (years)	6.0 ± 4.7	6.7 ± 5.5	9.0 ± 5.5	0.01
Total oocyte retrieved	4.6 ± 4.9	5.5 ± 5.0	5.6 ± 4.8	0.641
M II oocyte count	3.4 ± 2.4	4.4 ± 3.2	2.7 ± 2.5	0.959
Embryo count	2.1 ± 2.1	2.2 ± 1.7	2.1 ± 1.6	0.984
Embryo quality (eight-cell embryos & low fragmentation)	92.4%	84.3%	81.8%	0.271
Fertilization rate	71.6 ± 29.6	71.7 ± 25.7	69 ± 39.9	0.945
Total gonadotropin dose	3110 ± 1229	2695 ± 878	2789 ± 1485	0.964
Stimulation duration(days)	9.0 ± 2.7	8.5 ± 2.1	8.1 ± 3.0	0.867
Poor ovarian response rate (%)	55	45	41	0.341
Cycle cancellation rate (%)	28	18	32	0.509
Pregnancy rate (%)	24.5	21	10	0.02

tilization, and pregnancy rates decreased while gonadotropin dose and stimulation days increased. However, this difference did not reach statistical significance ($p > 0.05$). The duration of infertility in obese women was significantly increased ($p < 0.05$). Young obese women had significantly increased poor ovarian response rate (33%) compared to Group 1 (16.8 %) and Group 2 (24.8 %) ($p < 0.05$).

Older group (>35 years old)

The IVF outcomes of women above 35 years of age is presented in Table 3. In older obese women, the pregnancy rates decreased significantly ($p < 0.05$). The duration of infertility in obese women was significantly increased ($p < 0.05$). Fertilization rate and M II oocyte count decreased despite an increase in total oocytes retrieved. The cycle cancellation rates increased. However this differences did not reach statistical significance. The clinical pregnancy rates were significantly decreased ($p = 0.02$) in older obese women (10 %) compared to Group 1 (24.5%) and Group 2 (21%).

Discussion

Obesity is related to variety of reproductive disturbances and its relation to reproduction is complex and not fully understood. Since obesity has become a worldwide epidemic,

this leads to more obese or overweight women attending fertility clinics. The impact of obesity on IVF outcomes is inconsistent with ongoing scientific discussion [1-4]. Considering the discrepancies in previous studies and adjusting the confounding factors, the present authors designed a study to explore the impact of obesity on IVF, comparing outcomes with regards to age groups.

In this study, the length of stimulation and gonadotropin dose increased while OR, MII oocytes, fertilization, and clinical pregnancy rates decreased in obese women compared to normal weight controls. Among these differences, the reductions in M II oocytes and clinical pregnancy rates reached statistical significance. Regression analysis showed that clinical pregnancy rates were independently affected by age. Variety of former publications have shown that fertility potential decreases after the mid-thirties. Furthermore, previous studies emphasized that oocyte cytoplasmic abnormalities were observed after 35 years [9-11]. However, most of the previous studies related obesity and IVF outcomes are unable to adjust age [7, 8]. For this reason the present authors categorized women as above and under 35 years age and searched IVF outcomes in specific age groups.

Ovarian response is an important factor in IVF success. Several studies have been done on this subject [12-17]. Former studies showed increased duration of gonadotropin

stimulation, higher cancellation rates, and lower ovarian response [12-17]. However some other studies showed no significant effect on ovarian response and in addition some studies found decreased gonadotropin requirements [7, 18-20]. In this study, young women with BMI ≥ 30 kg/m² had an increased need of gonadotropin dose, duration, and decreased amount oocytes retrieved. However this difference was not statistically significant. The rate of poor ovarian response significantly increased in young obese women. Old obese women gonadotropin dose decreased and oocytes retrieved increased, but this difference was not statistically significant.

Another important factor in IVF success is obtaining good quality oocytes that are defined as M II oocytes. The impaired oocyte quality may contribute to decreased conception rates. Several studies have shown detrimental effect of obesity on oocyte quality, maturity, and counts [14, 15, 20-22]. In this study both in young and old obese group M II oocytes decreased compared to age-matched normal weight controls; however this reduction was not statistically significant. Another surrogate marker of oocyte quality is fertilization rates. Some of the studies showed reduction in fertilization rates of obese women [23, 24], but some others did not observe weight related decrease in fertilization rates. [14, 15, 21, 25]. In this search, the present authors found a slight reduction in fertilization rates of younger and old obese women; however this comparison was insignificant. Embryo quality decreased in obese women, but this was not statistically significant.

Some studies reported significant differences in pregnancy, implantation, and miscarriage rates between obese and non-obese women [7,12]. In this study, the clinical pregnancy rates of older obese women were significantly decreased compared to overweight and normal weight older women (10%, 21%, 24%; $p = 0.02$); however, a slight decrease in pregnancy rates of younger obese women did not reach statistical significance. In younger obese women oocyte count, maturity, and pregnancy rates decreased and gonadotropin dose increased compared to age matched normal weight controls; however, this difference did not reach statistically significance. Younger obese women had significantly increased poor ovarian response rate. Older obese women comparing older normal weight women had significantly decreased pregnancy rates without significant effect on oocyte count, maturity, and fertilization rates.

This study has some limitations. Similar to the present study, a majority of the previous studies were retrospectively design. This may be a limitation factor in the studies, because the present authors have no data regarding the smoking status of women and weight of males. Despite this limitation, design of women is satisfactory with the use of standard WHO classification, exclusion of PCOS, and male factor infertility cases, and consideration of different age groups make the results valuable. Further studies with

prospective design with standard BMI classification and adjusting confounding factors as PCOS, age, smoking, and male body weight are needed. This study addressed the necessity of adjusting confounding factors in obesity and fertility studies.

Conclusion

The impact of obesity on IVF outcomes in younger and older obese women have different results. Comparing age-matched normal weight women, obesity increased the risk of poor ovarian response in younger women and decreased pregnancy rates in older women. These results suggest that different steps of IVF process may be affected in women under and above 35 years of age. Prospectively designed further studies are needed in younger and older obese women with poor ovarian response.

References

- [1] Linné Y.: "Effects of obesity on women's reproduction and complications during pregnancy". *Obes. Rev.*, 2004, 5, 137.
- [2] Hedley A.A., Ogden C.L., Johnson C.L., Carroll M.D., Curtin L.R., Flegal K.M.: "Prevalence of overweight and obesity among US children, adolescents, and adults 1999-2002". *JAMA.*, 2004, 291, 2847.
- [3] Pasquali R., Pelusi C., Genghini S., Cacciari M., Gambineri A.: "Obesity and reproductive disorders in women". *Hum. Reprod. Update.*, 2003, 9, 359.
- [4] Practice Committee of American Society for Reproductive Medicine: "Obesity and reproduction: an educational bulletin". *Fertil. Steril.*, 2008, 90, 21.
- [5] Jungheim E.S., Travieso J.L., Carson K.R., Moley K.H.: "Obesity and Reproductive Function". *Obstet Gynecol Clin North Am.*, 2012, 39, 479.
- [6] Metwally M., Ledger W.L., Li T.C.: "Reproductive endocrinology and clinical aspects of obesity in women". *Ann. N. Y. Acad. Sci.*, 2008, 1127, 140.
- [7] Tamer Erel C., Senturk L.M.: "The impact of body mass index on assisted reproduction". *Curr. Opin. Obstet. Gynecol.*, 2009, 21, 228.
- [8] Metwally M., Cutting R., Tipton A., Skull J., Ledger WL, Li TC: "Effect of increased body mass index on oocyte and embryo quality in IVF patients". *Reprod Biomed Online.*, 2007, 15, 532.
- [9] Rittenberg V, Seshadri S, Sunkara SK, Sobaleva S, Oteng-Ntim E, El-Toukhy T: "Effect of body mass index on IVF treatment outcome: an updated systematic review and meta-analysis." *Reprod Biomed Online.*, 2011, 23, 421.
- [10] Shah DK, Missmer SA, Berry KF, Racowsky C, Ginsburg ES: "Effect of obesity on oocyte and embryo quality in women undergoing in-vitro fertilization". *Obstet Gynecol.*, 2011, 118, 63.
- [11] Balaban B, Urman B: "Effect of oocyte morphology on embryo development and implantation". *Reprod Biomed Online.*, 2006, 12, 608.
- [12] Baird D.T., Collins J., Egozcue J., Evers L.H., Gianaroli L., Leridon H., et al.: "ESHRE Capri Workshop Group: "Fertility and ageing". *Hum. Reprod. Update.*, 2005, 11, 261.
- [13] Leridon H.: "Can assisted reproduction technology compensate for the natural decline in fertility with age? A model assessment". *Hum. Reprod.*, 2004, 19, 1548.
- [14] Esinler I., Bozdogan G., Yarali H.: "Impact of isolated obesity on ICSI outcome". *Reprod. Biomed. Online.*, 2008, 17, 583.
- [15] Dokras A., Baredziak L., Blaine J., Syrop C., VanVoorhis B.J., Sparks A.: "Obstetric outcomes after in vitro fertilization in obese and morbidly obese women". *Obstet. Gynecol.*, 2006, 108, 61.

- [16] Mulders A.G., Laven J.S., Eijkemans M.J., Hughes E.G., Fauser B.C.: "Patient predictors for outcome of gonadotrophin ovulation induction in women with normogonadotrophic anovulatory infertility: a meta-analysis". *Hum. Reprod. Update*, 2003, 9, 429.
- [17] Bellver J., Busso C., Pellicer A., Remohí J., Simón C.: "Obesity and assisted reproductive technology outcomes". *Reprod. Biomed. Online*, 2006, 12, 562.
- [18] Martinuzzi K., Ryan S., Luna M., Copperman A.B.: "Elevated body mass index (BMI) does not adversely affect in vitro fertilization outcome in young women". *J. Assist. Reprod. Genet.*, 2008, 25, 169.
- [19] Dechaud H, Anahory T, Reyftmann L, Loup V, Hamamah S, Hedon B: "Obesity does not adversely affect results in patients who are undergoing in vitro fertilization and embryo transfer". *Eur J Obstet Gynecol Reprod Biol.*, 2006, 127, 88.
- [20] Frattarelli JL, Kodama CL: "Impact of body mass index on in vitro fertilization outcomes". *J Assist Reprod Genet.*, 2004, 21, 211.
- [21] Wittemer C., Ohl J., Bailly M., Bettahar-Lebugle K., Nisand I.: "Does body mass index of infertile women have an impact on IVF procedure and outcome?" *J. Assist. Reprod. Genet.*, 2000, 17, 547.
- [22] Carrell D.T., Jones K.P., Peterson C.M., Aoki V., Emery B.R., Campbell B.R.: "Body mass index is inversely related to intrafollicular HCG concentrations, embryo quality and IVF outcome". *Reprod. Biomed. Online*, 2001, 3, 109.
- [23] Matalliotakis I., Cakmak H., Sakkas D., Mahutte N., Koumantakis G., Arici A.: "Impact of body mass index on IVF and ICSI outcome: a retrospective study". *Reprod. Biomed. Online*, 2008, 16, 778.
- [24] Salha O., Dada T., Sharma V.: "Influence of body mass index and self-administration of hCG on the outcome of IVF cycles: a prospective cohort study". *Hum. Fertil. (Camb.)*, 2001, 4, 37.
- [25] Bellver J., Ayllón Y., Ferrando M., Melo M., Goyri E., Pellicer A., et al.: "Female obesity impairs in vitro fertilization outcome without affecting embryo quality". *Fertil. Steril.*, 2010, 93, 447.

Address reprint requests to:

F. VURAL M.D.

Orhan mah. Bağtepe sok. Erenkaya park evleri.

A2-2 Bağçeşme / İzmit 41100

Kocaeli (Turkey)

e-mail: vuralbirol@yahoo.com.tr

Feasibility of prophylactic laparoscopic appendectomy in obese patients

H. Wang, C. Lu, J. Zhao, L. Gao, X. Li, J. Hou, A. Zhou

Department of Obstetrics and Gynaecology, The 260th Hospital of PLA, Shijiazhang (China)

Summary

Purpose: To investigate the feasibility of prophylactic laparoscopic appendectomy in obese patients. **Materials and Methods:** A retrospective study was performed in obese patients undergoing total laparoscopic hysterectomy (TLH) alone (66 patients, TLH group) or in combination (55 patients, THL+LA group) with laparoscopic appendectomy (LA) between 2007 and 2012. Operation time, intraoperative bleeding volume, postoperative exhaust time, analgesic use, and the incidence of major complications, hospital stay and cost of hospitalization were compared. **Results:** The operation time was longer in THL+LA group than in TLH group ($p < 0.05$), while the intraoperative bleeding volume, postoperative exhaust time, postoperative morbidity, the incidence of major postoperative complications, and hospitalization time were not significantly different between the two groups. **Conclusion:** It is safe and feasible for obese patients to undergo simultaneous LA and prophylactic appendectomy, and the combined procedure does not increase the risk of infection of hysterectomy and avoids reoperation of patients due to the recurrence of appendicitis.

Key words: Laparoscopy; Hysterectomy; Appendicitis; Appendectomy; Obesity.

Introduction

Obese patients are the high-risk population for various surgical operations. For those whose lesions are in the abdominopelvic cavity, laparotomy was the most common before laparoscopic surgery was well established. Because of the physiological characteristics of obesity, longer incision is needed in obese patients than in normal patients for better exposure in the traditional laparotomy. In obese patients with relative low resistance, metabolic disease and hypertrophic abdominal wall, this would increase the risk of infection of the surgical incision or fat liquefaction, as well as the trauma. With the development and improvement of laparoscopic techniques and equipment, a considerable number of the laparoscopic operations that were considered taboo in obese patients can now be performed, such as total laparoscopic hysterectomy (TLH) and laparoscopic appendectomy (LA) [1]. As people's health consciousness increases, appendectomy is frequently requested by patients undergoing gynecologic operations. The combined surgery was disputed because of difficulty in selecting the operation indications, increase in operation time and the risk of infection, and possible financial overburden on the patient. However, with advancements in science and technology and availability of effective antibiotics, combined gynecological and surgical procedures have been proposed [2]. Since January 2007, the authors have performed appendectomy in obese patients undergoing LA. These patients had chronic and recurrent appendicitis with a history of repeated attacks. All operations were performed under the informed con-

sent of patients. In this study, a retrospective cohort study was performed to compare these patients with patients from the same periods who underwent THL.

Materials and Methods

General information

The study included 318 obese patients that underwent LA between January 2007 and December 2012 in the present department. Fifty-six and 66 cases that underwent TLH or THL and LA, respectively, were selected for retrospective analysis. As shown in Table 1, the general data were similar between the two groups of patients.

The study was approved by the ethics committee of the present hospital, and informed consent was obtained from each patient who voluntarily participated the study. Patients were included if their body mass index (BMI) was ≥ 28 kg/m²; they had clear indications of TLH and had a history of chronic appendicitis and more than two conservative treatments. The patients requested an appendectomy with signed informed consent; their gynecological surgery was completed by a chief physician with aid of two to three residents and appendectomy was completed by a deputy physician in general surgery department and had no taboo of laparoscopic operation. Patients were excluded if they had severe anemia and needed blood transfusion, serious heart, lung, liver, kidney and other complications, or over five days of therapy for these diseases, were conducting other gynecologic operation, and had a history of pelvic or abdominal operation or a fixed and unmovable uterus in gynecological examination.

Surgical procedure

The patients were subjected to general anesthesia and laid flat on supine position in the Trendelenburg position.

Hysterectomy: a one-cm incision was made along the upper edge of umbilicus. With the abdominal pressure set at 13 mmHg, the sec-

Revised manuscript accepted for publication December 18, 2014

Table 1. — Patients' data.

Clinical data	TLH+LA group (n=56)	TLH group (n=66)	<i>p</i> value
Age	44.3±6.7	42.2±7.2	0.10
BMI	28.8±1.4	29.1±1.2	0.21

Complication

Diabetes	17	21	0.086
Hypertension	32	40	0.70
Coronary heart disease	21	23	0.76
History of cerebral embolism	2	3	0.85

Size of uterus

Transverse diameter	8.4±4.1	8.2±4.8	0.81
Longitudinal diameter	11.8±3.6	12.4±4.4	0.42

TLH: total laparoscopic hysterectomy; LA: laparoscopic appendectomy; size of uterus based on B ultrasound.

ond and third ports were inserted from the left side of the abdomen, and the fourth port inserted from the right side of the abdomen. If the intestinal fat and tubes were found to seriously affect the operation field, auxiliary puncture port may have been added. The uterus was handled in an auxiliary manner with a uterine manipulator. The round ligament of the uterus, ovarian ligament, and fallopian tube near the uterus were coagulated and cut off using bipolar electric electrodes after pushing aside the intestinal fat with the modified Parthenocissus clamp. The uterus was lifted up with a uterine manipulator by the assistants, and opened for bladder peritoneum. The bladder was then posteriorly push from both sides to separate the broad ligament and the anterior and posterior leaves were cut open. The tissues around the uterine veins and arteries were separated, and the veins were coagulated by bipolar electric electrodes. The bilateral veins and arteries were dissected and cut off near the uterus. The cut ends were coagulated. At this point, the uterus body became black due to ischemia. A uterus lifting apparatus was inserted into the vagina and cut into vaginal fornix along the edge using unipolar electric electrode. The dissected uterus body was removed from the vagina. The vagina stump was plugged with sterile gloves, wrapped with gauze after stopping the bleeding to prevent leakage, and left unsutured.

LA: after hysterectomy, auxiliary puncture holes were made to examine the appendix and the surrounding lesion with the patient's body tilted at 10° to the left. The appendix was located down the ascending colon and the head of appendix was grasped with toothless grasping forceps. The mesoappendix was spread and the appendix vascular was coagulated piecewise with bipolar electric electrodes. The appendix was cut off at the root. The appendix root was clipped with biological clip 0.2 - 0.3 cm from the root and the distal end was coagulated by bipolar electric electrodes and cut off with an ultrasonic knife. If the root of appendix had severe edema, it was sutured with no. 4 thread in form of a figure "eight", or covered with the great omentum when necessary. The appendix was placed in a specimen bag and taken out from the vagina.

Suture of vaginal stump: the abdominopelvic cavity was washed with saline solution and the vaginal stump and peritoneal reflection were closed continuously with no. 2-0 absorbable catgut.

Preoperative and postoperative treatment: the patients were intravenously injected with 1,000 mg of ceftazole sodium 30 minutes before surgery. After operation, they were given oral or intramuscular injection of analgesic drugs according to their conditions. Antibiotics were used for routine infection prevention. When intestinal function was restored (venting), patients were asked to eat. Patients were followed-up at least once after discharge.

Table 2. — Parameters of patients in the two groups during and after the surgery.

Clinical data	TLH+LA group (n)	TLH group (n)	<i>p</i> value
Number of cases	56	66	

Surgery-related

Operation time (min)	138.2±34.3	122.4±26.5	0.0049
Bleeding (ml)	88.3±45.4	101.2±62.6	0.20
Postoperative exhaust (d)	2.5±0.8	2.2±1.0	0.07
Postoperative morbidity	4 (7.1%)	4 (6.0%)	0.81
Hospital stay (d)	5.2±0.8	5.3±1.0	0.55
Hospital cost (RMB)	7294.6±928.8	6930.4±912.6	0.03

Complication

Total	3 (5.4%)	3 (4.5%)	0.83
Incision infection	1 (1.8%)	2 (3.0%)	0.89
Pelvic abscess	1 (1.8%)	1 (1.5%)	0.55
Intestinal obstruction	0 (0%)	0 (0%)	0
appendiceal stump fistula	0 (0%)	0 (0%)	0
Phlebitis of lower extremity	1 (1.8%)	0	0.93

TLH: total laparoscopic hysterectomy; LA: laparoscopic appendectomy.

Observation

In this study, the parameters observed were as follows: (1) operation time (the time from making skin incision to the end of surgery when the wound hole was closed with a band aid or suture; hysterectomy time was the time to remove the uterus from vagina and to coagulate the vaginal stump); (2) the amount of bleeding during operation; (3) postoperative exhaust time; (4) postoperative morbidity (two times >38°C); (5) the number of postoperative analgesic use; (6) the days of hospital stay; (7) the hospitalization expenses (the sum of all hospitalization costs); (8) the incision infection (cases); (9) the pelvic abscess (cases); (10) small bowel obstruction (cases); and (11) the appendiceal stump fistula (cases).

Statistical analysis

Data were processed using the statistical software SPSS19.0. Numbers between the groups were tested using χ^2 test and measurements were tested using *t* test. Differences with *p* < 0.05 were considered statistically significant.

Results

The parameters for the two groups were analyzed and are presented in Table 2. Due to large amount of abdominal contents and exposure difficulty, two patients suffered mesenteric injury in TLH+LA group, one intestinal contusion, and one peritoneal subcutaneous emphysema during the Veress needle puncture. The total intraoperative complication rate was 7.1% (4/56). In TLH group, there was one case of mesenteric injury and one case of peritoneal subcutaneous emphysema. The total intraoperative complication rate was 3% (2/66), which was significantly lower than that of TLH+LA group (*p* < 0.05). In postoperative pathological observation, there were 49 cases of chronic appendicitis, one case of suppurative appendicitis and six cases of simple appendicitis.

Among the 56 cases followed up, 48 (88%) were followed up for six to 12 months with average of 7.5 months. One case

in TLH+LA group had vaginal bleeding 20 days after the surgery and had polyps in the vaginal stump. The patient was given LEEP conization to stop bleeding. Seven days later, she was found cured without other complications such as chronic abdominal pain and appendix stump inflammation.

Discussion

The advantages of laparoscopic surgery for prophylactic appendectomy in obese patients

In obese patients, due to thick abdominal wall and accumulation of intraperitoneal mesenteric fat, it is often difficult to expose in traditional laparotomy. The advantage of laparoscopic surgery is small wound, wide operation space, clear vision and long-distance operation with slender instruments, and quick recovery [3-5]. Obesity was considered to be a risk factor of adverse events in perioperative period [6-9]. The combined surgery of adjacent diseased organs has been less frequent due to fear of increased operation time and complications such as infection. There are few reports on prophylactic appendectomy after hysterectomy on obese patients. In the present study, the operation time in TLH+LA group was longer than that of TLH group due to expected additional time for appendectomy ($p < 0.05$). However, there was no difference in the amount of bleeding during operation, postoperative morbidity, postoperative exhaust time, and hospital stay between the two groups ($p > 0.05$), illustrating that TLH+LA group did not increase the amount of bleeding and infection rate, and that postoperative recovery was similar in the two groups. However, due to the sample size, this conclusion can only be applied to the combined surgery in this study.

The advantages of prophylactic laparoscopic appendectomy in obese patients

All basic principles of surgical operation should be followed when conducting combined laparoscopic surgery for obese patients. The objective should be to safely and effectively treat the main lesions while making efforts to treat minor abdominal and associated gynecological diseases. For prophylactic appendectomy, the principle of operation of appendectomy should be followed and patients should be strictly selected based on indications, not just their request. In the TLH+LA group, the intraoperative complications was 7.1%, not different from that of the TLH group ($p > 0.05$). Most of the complications occurred as mesenteric injury and intestine contusion. This might be due to more celiac content and exposure difficulty in the obese patients, leading to frequent pushing and moving of the intestine and omentum during the procedures. The above complications are unique to laparoscopic surgery. In the TLH+LA group, incision infection, pelvic abscess, intestinal obstruction, and deep phlebitis rate were 1.8% (1/56), 1.8% (1/56), 0% (0/56), 1.8% (1/56), respectively, and were not different from those in the TLH group ($p > 0.05$), indicating that prophylactic appendectomy following laparoscopic hysterectomy did not increase the inci-

dence of complications. In both groups, no patients was found to have appendiceal stump fistula, showing that LA is well established.

Cost reduction

Economically, the regulation is that for the same cut, the charge is reduced in half. Therefore, when charged one time for equipment use, the TLH+LA group was more expensive than the TLH group. However, the combined procedure eliminated duplicated charges for equipment, anesthesia, operation fee, and bed. The increased cost with the combined surgery and operation fee was much smaller than the sum of two separate surgeries. Furthermore, it avoided suffering of patients for two operations. Therefore, the combined surgery has significant social and economic benefits and had advantages for obese patients.

In summary, prophylactic appendectomy following laparoscopic hysterectomy can eliminate the effect of obesity with advantages such as less bleeding, faster postoperative recovery, and lower cost. It also avoids trauma and risk in subsequent surgery. As long as the indication for prophylactic appendectomy is strictly controlled, the surgery is safe and effective. It is therefore a clinical option for obese patients.

References

- [1] Heinberg E.M., Crawford III B.L., Weitzen S.H., Bonilla D.J.: "Total laparoscopic hysterectomy in obese versus nonobese patients". *Obstet. Gynecol.*, 2004, 103, 674.
- [2] Enochsson L., Hellberg A., Rudberg C., Fenyö G., Gudbjartson T., Kullman E., et al.: "Laparoscopic vs open appendectomy in overweight patients". *Surg. Endosc.*, 2001, 15, 387.
- [3] Eltabbakh G.H., Piver M.S., Hempling R.E., Recio F.O.: "Laparoscopic surgery in obese women". *Obstet. Gynecol.*, 1999, 94, 704.
- [4] Shen C.C., Hsu T.Y., Huang F.J., Huang E.Y., Huang H.W., Chang H.Y., et al.: "Laparoscopic-assisted vaginal hysterectomy in women of all weights and the effects of weight on complications". *J. Am. Assoc. Gyn. Lap.*, 2002, 9, 468.
- [5] Bardens D., Solomayer E., Baum S., Radosa J., Gräber S., Rody A., et al.: "The impact of the body mass index (BMI) on laparoscopic hysterectomy for benign disease". *Arch. Gynecol. Obstet.*, 2014, 289, 803.
- [6] Kheterpal S, Han R, Tremper KK, Shanks A, Tait AR, O'Reilly M, et al.: "Incidence and predictors of difficult and impossible mask ventilation". *Anesthesiology*, 2006, 105, 885.
- [7] Juvin P, Lavaut E, Dupont H, Lefevre P, Demetriou M, Dumoulin J.L., et al.: "Difficult tracheal intubation is more common in obese than in lean patients". *Anesth. Analg.*, 2003, 97, 595.
- [8] Eichenberger A.S., Proietti S., Wicky S., Frascarolo P., Suter M., Spahn D., et al.: "Morbid obesity and postoperative pulmonary atelectasis: an underestimated problem". *Anesth. Analg.*, 2002, 95, 1788.
- [9] Dindo D., Muller M.K., Weber M., Clavien P.A.: "Obesity in general elective surgery". *Lancet*, 2003, 361, 2032.

Address reprint requests to:

A. ZHOU, M.D.

Department of Obstetrics and Gynaecology

The 260th Hospital of PLA

No. 346 Shengli North Street

Shijiazhang 050041 (China)

e-mail: zhouailing88@yeah.net

The early pregnancy volume measurements in predicting pregnancy outcome

G. Batmaz¹, A. Aksoy², S. Aydin¹, P. Ozcan¹, C. Dane³, B. Dane¹

¹ Bezmialem University, Faculty of Medicine, Department of Gynecology and Obstetrics, Istanbul

² Nenehatun Hospital, Department of Obstetric and Gynecology, Erzurum

³ Haseki Training and Research Hospital, Department of Gynecology and Obstetrics, Istanbul (Turkey)

Summary

Objective: The authors' aim was to develop a logistic regression model based on the ultrasonographic parameters on maternities which are showing a healthy improvement process during the first trimester of pregnancy. **Material and Methods:** Using 2D transvaginal ultrasound imaging, the crown rump length (CRL), yolk sac (YS), and gestational sac (GS) diameters were recorded in 225 women with gestational age <11 weeks. Simplified $V = 0.523 \times \text{length} \times \text{height} \times \text{width}$ formula was used for the volume calculations. The results which ended in abortion were not included in the study. **Results:** Linear regression analyses between yolk sac volume (YSV), $YSV = 0.026 + 0.0018 \times \text{CRL}$ ($r^2: 0.15; p < 0.001$), gestational sac volume (GSV), $GSV = -9.6 + 1.7 \times \text{CRL}$ ($r^2: 0.52; p < 0.001$), and embryo volume (EV), $EV = -1.64 + 0.18 \times \text{CRL}$ ($r^2: 0.4; p < 0.001$), and CRL was made and a linear relationship was detected. The volume measurements showed a meaningful correlation with the week of pregnancy. The space in the GS (GS volume-embryo volume) increased as the age of pregnancy became older ($r^2 = 0.46; p < 0.001$). **Discussion:** The first volume value was made in the first trimester by transvaginal ultrasonography, which showed a correlation with the age of pregnancy.

Key words: Early pregnancy volume measurements; Nomogram.

Introduction

The first trimester is the most critical period in the pregnancy process in which the formation of placenta and embryo occurs. This is the period when many pathological conditions can appear, and the embryo is in its most vulnerable state to external factors. Many researchers have studied various criteria to diagnose gestation prognosis to inform couples who are waiting for a successful pregnancy outcome by examining the ultrasonographic parameters and maternal demographic characteristics acquired before the 12th week of pregnancy [1, 2].

During diagnostic ultrasound in early pregnancy, evaluation of embryo and gestational sac (GS) has significance. For example, the GS and cranium-rump length (CRL) can be determined by measuring the gestational age and the examination of yolk sac (YS) can indicate the current problems at an early stage.

In the early period (six to ten weeks), 7.5% of the fetuses which have been identified as alive may end in abortion. The most important ultrasonographic marker of fetal loss compared to CRL was reported to be the presence of small gestational sacs [3]. According to the result of another study, it has been determined that after the diagnosis of alive gestation process, possibility of fetal loss rate decreases to 3.4 % [4].

Many authors reported that first trimester volume measurements can be able to predict gestations which end in abortion and chromosomal defects [5-7].

In this study, for the events not ending in abortion, the authors aimed at creating and evaluating a linear regression model based on ultrasonographic parameters.

Materials and Methods

This prospective cohort study was performed in Bezmialem University, Faculty of Medicine, Department of Obstetrics and Gynecology, Istanbul, Turkey, between January 2013 and January 2014. Two hundred twenty-five (225) subjects, who consulted at the hospital with a pregnancy doubt, wanted to keep the fetus alive, did not have repetitive abortions, had a healthy singleton pregnancy, between 6⁺⁶ and 10⁺⁶ weeks, were included in this study. The mothers who had diabetes mellitus, hypothyroidism, hypertension and autoimmune diseases, multiple pregnancy, and over 40 years of age were excluded from the study. A detailed medical history of all pregnant women included in the study were taken. As maternal age demographic data, previous pregnancy history (gravidity, parity, abortion, curettage), date of last menstrual period (LMP), smoking, and vaginal bleeding data from the current pregnancy was recorded.

The patients were studied once with transabdominal sonography using an endocavitary 5- to 9-MHz transducer by a single sonographer (G.B.) experienced in performing these examinations. The presence of intrauterine pregnancy and YS, fetal pole

Revised manuscript accepted for publication January 12, 2015

Table 1. — EV, GA, GSV, and YSV according to gestation weeks.

GA	n	YSV (cm ³)				GSV (cm ³)				EV (cm ³)			
		5 th	50 th	95 th	Median	5 th	50 th	95 th	Median	5 th	50 th	95 th	Median
6 w	9	0.01	0.027	0.05	0.03	1.87	5.65	14.00	5.65	0.05	0.08	0.50	0.125
7 w	60	0.02	0.04	0.095	0.04	3.35	9.7	22.5	8	0.095	0.66	1.03	0.3
8 w	68	0.02	0.058	0.10	0.06	8.4	18.3	37.2	17	0.35	1.11	2.06	0.99
9 w	46	0.02	0.069	0.11	0.07	9.0	27.1	57.4	23.5	1.37	2.42	3.97	2.18
10 w	12	0.01	0.075	0.195	0.05	14.85	51.7	92.7	44	3.19	5.22	8.77	4.77

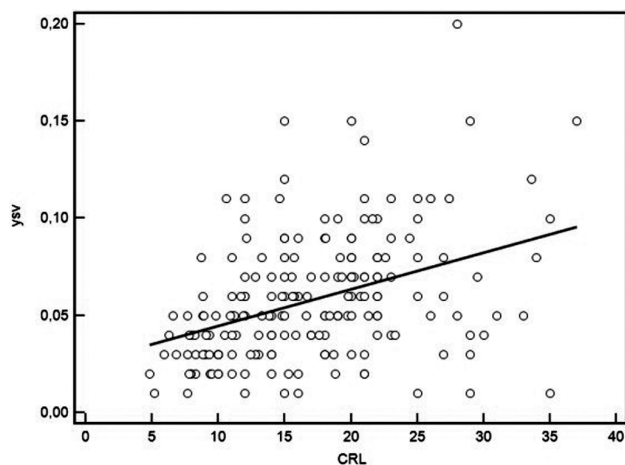


Figure 1. — Relation between CRL and YSV.

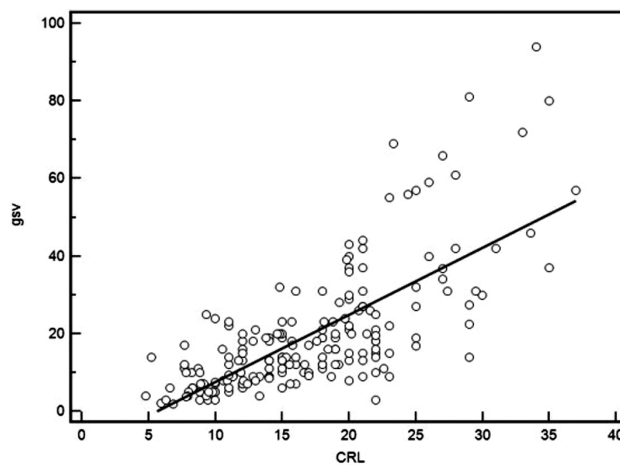


Figure 2. — Relation between CRL and GSV.

presence in gestational sac detected by the help of detailed ultrasonography reviews of each patient. In order to measure average GS, inner wall sac diameter-length of the chorionic liquid surface level, width, and height (three orthogonal diameters) were measured in millimeters (mm) and then an average was made. Gestational week was determined by measuring CRL by its longest distance in mm. In order to calculate, average YS diameter, the length of the outer surface, width, and height (three orthogonal diameters) were measured and an average was made in mm. Volume measurements were done by using a simplified formula for the volume of a prolate ellipsoid: $V = 0.523 \times \text{length} \times \text{height} \times \text{width}$ [8]

Data were collected on an Excel spreadsheet and analyzed using the software SPSS, version 15.0. Scatter graphs were generated to evaluate the correlation between yolk sac volume (YSV), gestational sac volume (GSV), embryo volume (EV), and CRL. Regression models were constructed using YSV, GSV, and EV as the dependent and CRL as the independent variables. A p value < 0.05 was considered significant.

Approval for this study was obtained from the Local Institutional Review Board of the Faculty of Medicine, Bezmialem University. Informed consent was obtained from all participants.

Results

Twenty-four (24) patients out of the 225, who were included in the study, could not be reached and 11 pregnancies were excluded from the study because of abortion. One hundred and ninety (190) women between six and ten

weeks' gestation, who met the eligibility criteria, were enrolled in the study. The median maternal age (\pm SD) was 28 ± 5.2 years (range 19–40). One hundred twenty-one (121) women (63.7%) were parous and 69 women (36.3%) were nulliparous.

The median CRL was 16 ± 6.7 mm (range, 4.8–37). The mean YSV varied from 0.027 to 0.075 cm³ between six and ten weeks, respectively. Medians and 5th and 95th centiles for each measurement by weeks of gestational age are shown in Table 1. The YSV positively correlated with the CRL, and the linear regression of its values also yielded better a correlation. The following equation describes this relation: $YSV = 0.026 + 0.0018 \times \text{CRL}$ ($r^2: 0.15; p < 0.001$) (Figure 1). The mean YS diameter positively correlated with the CRL, and the following equation describes this relation: $YS = 3.8 + 0.05 \times \text{CRL}$ ($r^2: 0.15; p < 0.001$).

Mean GSV ranged from 5.65 cm³ at six weeks to 51.7 cm³ at ten weeks. Medians and 5th and 95th percentiles for each measurement by weeks of gestational age are shown in Table 1. There was a moderate positive correlation between GSV and CRL. The following equation describes this relation: $GSV = -9.6 + 1.7 \times \text{CRL}$ ($r^2: 0.52; p < 0.001$) (Figure 2). The mean GS diameter (MSD) positively correlated with the CRL, and the following equation describes this relation: $MSD = 16.6 + 0.91 \times \text{CRL}$ ($r^2: 0.56; p < 0.001$).

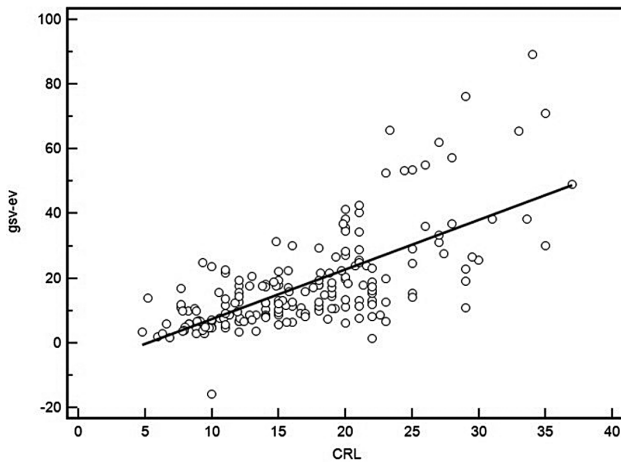


Figure 3. — Relation between CRL and GSV-EV.

Mean EV ranged from 0.08 cm³ at six weeks to 5.2 cm³ at ten weeks. Medians and 5th and 95th centiles for each measurement by weeks of gestational age are shown in Table 1. There was a moderate positive correlation between EV and CRL. The following equation describes this relation: $EV = -1.64 + 0.18 \times CRL$ ($r^2: 0.4; p < 0.001$)

As the gestational age became higher, the area outside (GSV - EV) of the embryo in the GS increased ($r^2 = 0.46; p < 0.001$) (Figure 3).

Discussion

Due to socio-cultural reasons, advanced maternal age has been increasing in recent years and how pregnancy will continue or what the results will be in continuing pregnancies is unknown. Therefore, predicting pregnancy outcome studies in recent years shifted to the much earlier stages of the pregnancy. For this reason, various sonographic parameters are used in the early weeks of pregnancy, such as localization and size of the GS [8], the relationship between GS and the average size of the CRL [9-12] and, the size and shape of the YS [13, 14]. GS, YS, and ability to set EV allow the formulation of age-related pregnancy percentile. There are several published analyses which examine the relationship between first trimester ultrasonographic volume parameters and pregnancy outcome [5, 6, 15]. Earlier studies showed that YS size began to decrease and disappeared towards to the end of first trimester, besides seeing the YS before monitoring fetal pole indicated no valuable prediction on pregnancy outcomes [16, 17]. YS diameter is two to five mm in the 7th and 10th weeks in two-dimensional US and the average value is 2.0 ± 2.0 mm [18]. In the present study, the average YS diameter was 4.7 mm; maximum value 7.9 mm, and minimum value 2.7 mm.

A study conducted that the YS diameter was correlated with gestational age and it was found to increase progres-

sively with gestational week [19]. In the present study, YS diameter increased with gestational week and was found to be positively associated with the CRL. Bagratee *et al.* conducted a study that showed that first trimester YSV reference intervals increased in a linear fashion for up to ten weeks, then up to 11 weeks it plateaued and decreased afterwards. They suggested that it was caused by decreased vascularization [20]. The present study were similar to these studies. However, when evaluating the results, it was seen that the YS size increased with gestational age, while the two-dimensional measurements correlated more significantly. In the first trimester, the GS consists of amniotic and celomic cavity and it reflects the embryonic development environment. GSV measurements can help to distinguish between normal and abnormal pregnancies.

When the fetal pole is seen without fetal cardiac activity in late pregnancy, the diagnosis of missed abortion cannot be questioned. However, in early pregnancy, it can be difficult to diagnose. The fetal pole is not very clear in this period, and GSV measurements may facilitate the diagnosis of failed pregnancy. In a study comparing missed miscarriage and ongoing pregnancy, larger mean gestational diameter and GSV were identified compared to CRL and embryo volume. Furthermore, it showed that volumetric measurements can have diagnostic value [15]. The first volumetric assessment of first trimester using three-dimensional US was a small pilot study made by Steiner *et al.* They described a linear relationship between gestational age and GSV by using three-dimensional US measurements [21].

In the present study, the results were similar to earlier studies; the authors found that GSV increased in a correlated manner with CRL with gestational age [18, 22]. Some studies showed that GSV has predictive value for failed pregnancy outcomes [5, 6, 23]. Falcon *et al.* conducted a study showing that GS measurements according to gestational week, seem to be normal size in early pregnancy of fetuses with trisomy 18, trisomy 21, and Turner syndrome, while fetuses with triploidy and trisomy 13 GS were demonstrated significantly smaller [7]. Also, Papaioannou *et al.* conducted another study which showed one in four of the abortion cases, median GSD was below the 5th percentile [1]. This reveals the importance of early ultrasonography. Average GS diameter is associated with gestational age and fetal growth. Bromley *et al.* reported that when MSD - CRL is less than five mm, it corresponds to a 94% abortion rate; when it is more than five mm, abortion rate is 8% [10]. However, in this study growth parameters and the linear relationship between them were examined in healthy pregnancies but were not compared to miscarriages and healthy pregnancies.

A combination of several variables in determining the value of a failed pregnancy outcome is better than a single variable, although this may not be always practical or clinically appropriate. In subsequent studies, easily formalized methods which can be applied to clinical practice should be developed.

The limitation of this study is the small number of patients. However, the power of the study is that all patients were examined by the same researcher in the same center.

In conclusion, assessing the early pregnancy volumetric parameters using linear regression models can assist in predicting failed pregnancy outcomes and to determine appropriate management. However, much more extensive studies are needed with larger groups of patients.

References

- [1] Papaioannou G., Syngelaki A., Maiz N., Ross J.A., Nicolaides K.H.: "Ultrasonographic prediction of early miscarriage". *Hum Reprod.*, 2011, 26, 1685.
- [2] Oates J., Casikar I., Campain A., Müller S., Yang J., Reid S., Condous G.: "A prediction model for viability at the end of the first trimester after a single early pregnancy evaluation". *Aust. N. Z. J. Obstet. Gynaecol.*, 2013, 53, 51-7.
- [3] Makrydimas G., Sebire N.J., Lolis D., Vlassis N., Nicolaides K.H.: "Fetal loss following ultrasound diagnosis of a live fetus at 6-10 weeks of gestation". *Ultrasound Obstet. Gynecol.*, 2003, 22, 368.
- [4] Tannirandom Y., Sangsawanq S., Manotaya S., Uerpairojkit B., Samritpradit P., Charoenvithya D.: "Fetal loss in threatened abortion after embryonic/fetal heart activity". *Int. J. Gynaecol. Obstet.*, 2003, 81, 263.
- [5] Figueras F., Torrents M., Muñoz A., Comas C., Antolin E., Echevarria M., et al.: "Three-dimensional yolk and gestational sac volume. A prospective study of prognostic value". *J. Reprod. Med.*, 2003, 48, 252.
- [6] Babinszki A., Nyari T., Jordan S., Nasseri A., Mukherjee T., Coperman A.B.: "Three-dimensional measurement of gestational and yolk sac volumes as predictors of pregnancy outcome in the first trimester". *Am. J. Perinatol.*, 2001, 18, 203.
- [7] Falcon O., Wegzyn P., Faro C., Peralta C.F.A., Nicolaides K.H.: "Gestational sac volume measured by three-dimensional ultrasound at 11 to 13+6 weeks' gestation: relation to chromosomal defects". *Ultrasound Obstet Gynecol.*, 2005, 25, 546.
- [8] Verwoerd-Dikkeboom C.M., Koning A.H., Hop W.C., Rousian M., Van Der Spek P.J., Exalto N., et al.: "Reliability of three dimensional sonographic measurements in early pregnancy using virtual reality". *Ultrasound Obstet. Gynecol.*, 2008, 32, 910.
- [9] Nyberg D.A., Laing F.G., Filly R.A.: "Threatened abortion: sonographic detection of normal and abnormal gestational sac". *Radiology*, 1986, 158, 379.
- [10] Bromley B., Hatlow B.L., Laboda L.A., Benacerraf B.R.: "Small sac size in the first trimester: a predictor of poor fetal outcome". *Radiology*, 1991, 178, 375.
- [11] Dickey R.P., Olar T.T., Taylor S.N., Curolle D.N., Matulich E.M.: "Relationship of small gestational sac-crown-rump length differences to abortion and abortus karyotypes". *Obstet. Gynecol.*, 1992, 79, 554.
- [12] Nazari A., Check J.M., Epstein R.M., Dietterich C., Farazner S.: "Relationship of small-for-dates sac size to crown-rump length and spontaneous abortion in patients with a known date of ovulation". *Obstet. Gynecol.*, 1991, 78, 369.
- [13] Reece E.A., Scioscia A.L., Pinter E., Hobbins J.C., Green J., Mahoney M.J., et al.: "Prognostic significance of the human yolk sac assessed by ultrasonography". *Am. J. Obstet. Gynecol.*, 1988, 159, 1191.
- [14] Lindsay D.J., Lovett I.S., Lyons E.A., Levi C.S., Zheng X.H., Holt S.C., Dashefsky S.M.: "Yolk sac diameter and shape at endovaginal US: predictors of pregnancy outcome in the first trimester". *Radiology*, 1992, 183, 115.
- [15] Acharya G., Morgan H.: "First-trimester, three-dimensional transvaginal ultrasound volumetry in normal pregnancies and spontaneous miscarriages". *Ultrasound Obstet. Gynecol.*, 2002, 19, 575.
- [16] Gulbis B., Jauniaux E., Cotton F., Stordeur P.: "Protein and enzyme patterns in the fluid cavities of the first trimester gestational sac: relevance to the absorptive role of secondary yolk sac". *Mol. Hum. Reprod.*, 1998, 4, 857.
- [17] Hessert M.J., Juliano M.: "Fetal loss in symptomatic first-trimester pregnancy with documented yolk sac intrauterine pregnancy". *Am. J. Emerg. Med.*, 2012, 30, 399.
- [18] Rôlo L.C., Nardoza L.M., Araujo Júnior E., Nowak P.M., Moron A.F.: "Yolk sac volume assessed by three-dimensional ultrasonography using the VOCAL method". *Acta Obstet. Gynecol. Scand.*, 2008, 87, 499.
- [19] Tan S., Gülden Tangal N., Kanat-Pektas M., Sirin Özcan A., Levent Keskin H., Akgündüz G., et al.: "Abnormal sonographic appearances of the yolk sac: which can be associated with adverse perinatal outcome?". *Med. Ultrason.*, 2014, 16, 15.
- [20] Bagratee J.S., Regan L., Khullar V., Connolly C., Moodley J.: "Reference intervals of gestational sac, yolk sac and embryo volumes using three-dimensional ultrasound". *Ultrasound Obstet. Gynecol.*, 2009, 34, 503.
- [21] Steiner H., Gregg A.R., Bogner G., Graf A.H., Weiner C.P., Staudach A.: "First trimester three-dimensional ultrasound volumetry of the gestational sac". *Arch. Gynecol. Obstet.*, 1994, 255, 165.
- [22] Müller T., Sütterlin M., Pöhls U., Dietl J.: "Transvaginal volumetry of first trimester gestational sac: a comparison of conventional with three dimensional ultrasound". *J. Perinat. Med.*, 2000, 28, 214.
- [23] Goldstein S.R., Kerenyi T., Scher J., Papp C.: "Correlation between karyotype and ultrasound findings in patients with failed early pregnancy". *Ultrasound Obstet. Gynecol.*, 1996, 8, 314.

Address reprint requests to:
 G. BATMAZ, M.D.
 Orhan Veli Kanık Cad. Gün Sk
 Mihrabata Sitesi B Blok, No: 5-7 Daire: 20
 Kavacık- Beykoz, Istanbul (Turkey)
 e-mail: drgoncabatmaz@yahoo.com

Early fetal heart ultrasonography as additional indicator for chromosomopathies

A. Dmitrovic¹, K. Jeremic^{1,2}, U.M. Babic¹, M. Perovic⁴, T. Mihailovic³, D. Opric^{1,5}, N. Zečević⁴,
M. Gojnić-Dugalić^{1,2}

¹ Clinical Center of Serbia, Clinic of Obstetrics and Gynecology, Belgrade

² Medical Faculty, University of Belgrade, Belgrade, Belgrade

³ Ultramedica Clinic, US Medical School, Belgrade

⁴ University Clinic of Gynecology and Obstetrics "Narodni front", Belgrade

⁵ Institute of Pathology, Medical faculty University of Belgrade, Belgrade (Serbia)

Summary

Objective: First trial of estimating values of scans of fetal heart structures (FHS) in first trimester of pregnancy, as more primary facts of possible chromosomopathies. **Materials and Methods:** The study included 2,643 fetuses that were examined in first trimester of pregnancy on Sono CT convex (C5-2MHz), endovaginal (ev 8-4MHz), and linear transducers (L12-5MHz) during a period of eight years. Fetal heart was evaluated using appropriate software with broad-band transducers and color Doppler, Sono CT, and HD ZOOM technologies. The scan was performed by three experienced physicians. FHS were based on: left and right ventricle morphology; AV valves (atrioventricular) position and existence of primal ostium; relationship of left ventricle outflow tract (LVOT) and right ventricle outflow tract (RVOT) and great vessels on three vessel view (3VV) and estimation of ductal and aortic arch. **Results:** Several developments, one being the ability to identify fetuses at risk for cardiac defects combining nuchal translucency (NT), ductus venosus (DV) Doppler, and evaluation of tricuspid regurgitation, have prompted reconsideration of the role of the first trimester prognostic factor of fetal evaluation. In low-risk pregnancies group, 36 (1.8%) fetuses were found to have congenital heart disease (CHD), and in high-risk pregnancies the number of fetuses with CHD was 75 (12%). Genetic amniocentesis or chorionic villus sampling (CVS) was performed in all fetuses with CHD. Forty-two (37.8%) fetuses with CHD were found to have chromosomal anomalies. Out of 111 fetuses with CHD 39 (35.1%) had an nuchal translucency (NT) above three mm. Out of 42 fetuses with chromosomal anomalies and CHD, 29 (69%) had an increased NT. **Conclusion:** Using first trimester fetal echosonography constitutes a further step in the earlier recognition of chromosomopathies, even in low risk groups. Still further steps are necessary as all facts of good clinical practice. In order to offer further benefits during pregnancies, improvements in diagnostics are still required.

Key words: Chromosomopathies; First trimester; Early diagnosis; Fetal echocardiography; Cardiac defects.

Introduction

A second-trimester fetal echocardiography is the gold standard for prenatal evaluation of fetal cardiac structure and function. Prenatal detection of congenital heart disease (CHD) is limited to the second trimester because screening programs among the unselected population are usually performed during the routine second-trimester scan. The segmental approach provides a consistent and detailed evaluation of cardiac anatomy and situs, and allows demonstration of the majority of fetal cardiac defects [1, 2]. First trimester fetal cardiac examination has largely been restricted to high-risk patients. The majority of CHDs, however, occur in low-risk patients [3].

Several developments, one being the ability to identify fetuses at risk for cardiac defects combining nuchal translucency (NT), ductus venosus (DV) Doppler, and evaluation of tricuspid regurgitation, and another - the role of the first trimester fetal cardiac examination, can predict chromosomopathies [3-5].

The association of CHDs with Trisomy 21 was reported many years ago and heart defects remain one of the most common and lethal abnormalities present postnatally in individuals affected by Down syndrome [4, 5]. However, even in specialized centers, expert cardiac study is performed only on fetuses with an NT increased above the 99th centile [6].

The present authors designed this study to assess the accuracy of fetal echocardiography at first trimester using a high-frequency, broad-band linear probe in pregnancies both with low and high risk for Trisomy 21. The examinations were performed by the physicians experienced in genetic sonography and fetal echocardiography [7-9].

Materials and Methods

This was a prospective study conducted between June 2005 and August 2013, during which the authors examined 2,643 fetal hearts between 12th and 14th week of gestation. This was planned

Revised manuscript accepted for publication December 18, 2014

Table 1. — Number of fetuses with CHD in high and low risk groups of pregnancies.

Group		CHD		Total
		Yes	No	
Low risk	Count	36	1974	2,010
	% within group	1.8%	98.2%	100%
High risk	Count	75	558	633
	% within group	11.8%	88.2%	100%
Total	Count	111	2532	2,643
	% within group	4.2%	95.8%	100%

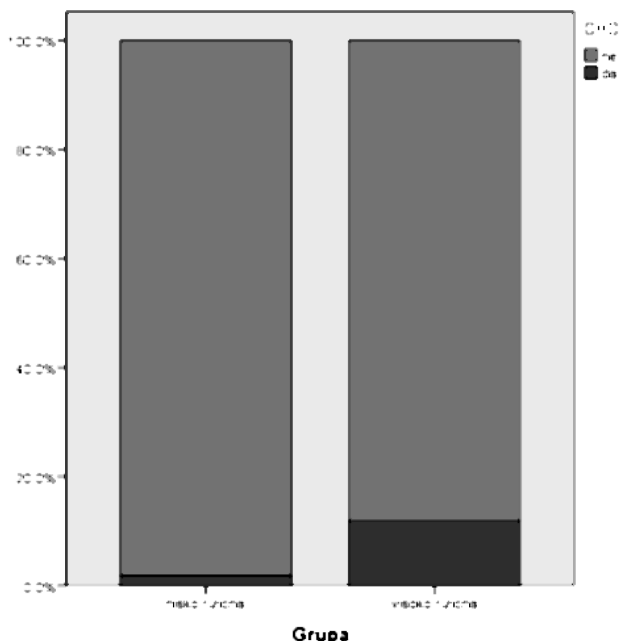


Figure 1. — Percentage of fetuses with CHD in high and low risk pregnancy groups.

as a validation study in low-risk population and patients with risk factors for congenital heart disease (pre-gestational diabetes, epilepsy, family history of congenital heart defects, maternal exposure to teratogens and pregnancy upon an assisted reproductive technology). The authors obtained approval from the Institutional Ethics Committee for the study and a written consent from each participant. The exclusion criteria were: multifetal pregnancies, missed abortions, and high obese women.

All fetuses were examined by ultrasound-trained pediatric radiologists and obstetricians. Operators were using the same protocol as one used in the second and the third trimesters and applying color-Doppler (CD) flow mapping for morphological evaluation of the four chambers and great vessels [1, 10, 11]. The authors were usually able to visualize the following anatomic landmarks using a gray-scale, two dimensional (2D) and CD modalities: four-chamber view, position of ascending aorta (LVOT), descending aorta, heart size, cardiac axis, two equal-sized atria, position of right and left ventricles, position of two opening atrioventricular valves, two great arteries crossing, three-vessel view (3VV) and three-vessel and trachea view (3VT), two great arteries of equal diameter, V configurations

Table 2. — Coordination of NT and CHD (yes: NT > 3 mm; no: NT < 3 mm).

	Frequency	Percentage
Yes	39	35.1
No	72	64.9
Total	111	100.0

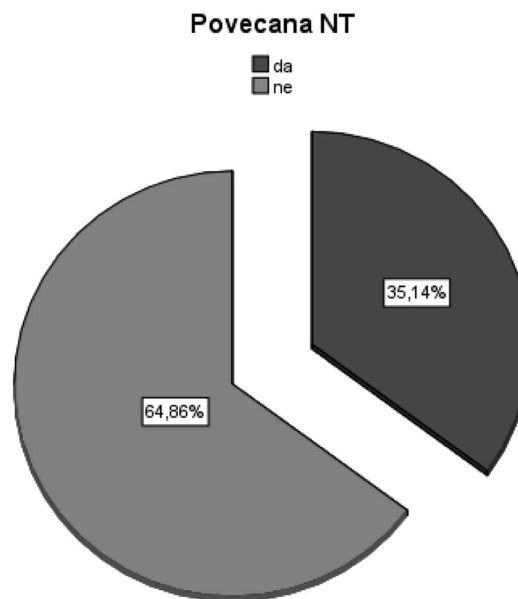


Figure 2. — NT distribution of pregnancy with NT and CHD (yes: increased NT > 3 mm; no: NT < 3 mm).

and similar size of aortic and ductal arch, aortic and ductal arch in sagittal view, ductus venosus (DV) Doppler, diastolic filling of left ventricle, exclusion of tricuspid regurgitation, and forward flow in both arches.

In case of abnormal scan, non invasive genetics from maternal blood and chorionic villus sampling (CVS) was routinely offered for genetic analysis together with multidisciplinary counseling before decision on termination of pregnancy (TOP). Cases with inconclusive scans were rescheduled at 16 weeks of gestation.

When the pregnancy continued, the fetuses underwent a complete ultrasound scan and echocardiography examination at 26th and 32th week of gestation. The prenatally established diagnosis was confirmed, modified or changed according to postnatal echocardiography, surgery or autopsy findings.

All scans were carried out transabdominally using either a 12-5 MHz linear (L) broadband probe, C 8-4ev MHz transvaginal (ev) broadband probe, convex broad band probe 5-2MHz (C). The authors also used a Sono CT, high definition zoom (HD Zoom), software for fetal echocardiography at first trimester, broadband CD, color-power angio (CPA), and cineloop.

The SPSS statistical software package (release 18) was used to assess statistical significance if appropriate, with the level of significance set at 0.05.

Table 3. — Correlation of CHD - NT chromosomal abnormalities (increased NT > 3 mm: yes; no: NT < 3 mm).

	Frequency	Percentage
Yes	29	69.0
No	13	31.0
Total	42	100.0

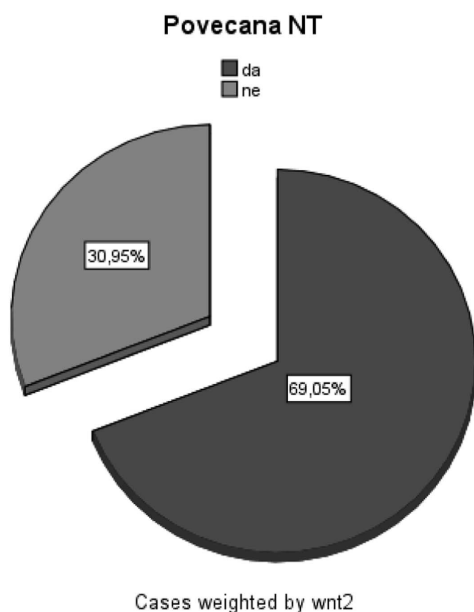


Figure 3. — Percentage of pregnancies with CHD and chromosomal abnormalities with elevated NT (yes: NT > 3 mm; no: NT < 3 mm).

Results

Within an eight-year period the authors examined 2,811 pregnancies in the first trimester, and the fetal heart was examined in 2,643 pregnancies; 2,010 patients had low-risk pregnancies, while there were 633 high-risk pregnancies. The median maternal age was 37 (range, 19-45) years. The median crown-rump length was 68 (range, 46-84) mm. The total number of fetuses with CHD was 111 (4.2%), while there were 2,532 fetuses without CHD (Table 1).

In low-risk pregnancies 2,010 cases group, 36 (1.8%) fetuses were found to have CHD, and in high-risk pregnancies 633 cases the number of fetuses with CHD was 75 (11.8%). Genetic amniocentesis or CVS was performed in all fetuses with CHD (Table 1, Figure 1). In all cases in which the authors detected possible CHD, the chromosomal abnormalities were found in 42 cases (37.8%).

Statistically analyzing the coordination of NT and CHD, the authors found a large statistical importance ($p > 0.01$). Out of 111 fetuses with CHD, 39 (35.1%) had an NT above three mm (Table 2, Figure 2). In correlation with CHD-NT-

Table 4. — Correlations of chromosomopathies with CHD and NT measurements.

Grupa	CHD		NT		Total
			Yes	No	
		Count	39	72	111
		% within group	35.1%	64.9%	100.0%
	Hromosom anomaly	Count	29	13	42
		% within group	69.0%	31.0%	100.0%
Total		Count	68	85	153
		% within group	44,4%	55,6%	100.0%

High statistical importance ($X^2 = 14.192; p < 0.001$).

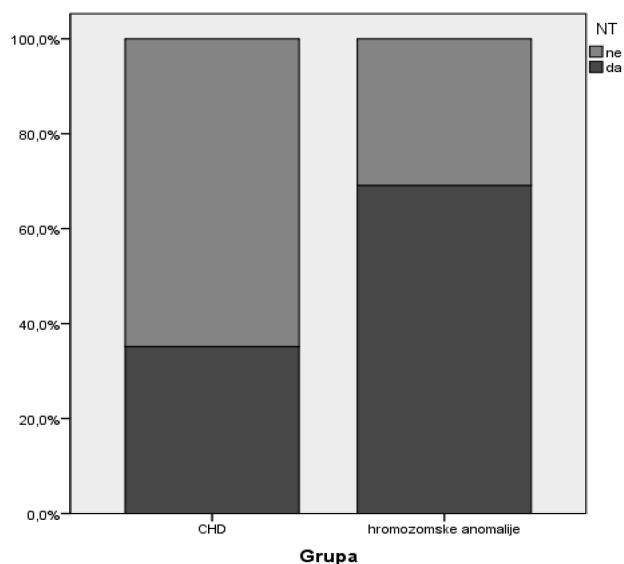


Figure 4. — Percentages of elevated NT (above 3 mm) measurements in fetuses with CHD and with fetuses with chromosomal anomalies.

chromosomal anomalies, 42 fetuses with chromosomal anomalies and CHD, 29 (69%) had an increased NT. It is statistically significant ($p > 0.01$) (Table 3, Figure 3).

The present results confirm the importance of NT nuchal translucency as an important parameter of chromosomopathies, and the correlation of NT with congenital heart defect CHD as additional parameter of precise diagnosis (Table 4, Figure 4).

Discussion

Analyzing the second trimester scan, the authors identified two major cardiac defects (both VSD) that had been missed in the first trimester scan. In review of the first trimester DVD clips, the heart appeared normal. The authors will have to perform even large studies, because they missed statistical importance in this number.

In cases with inadequate views at the first trimester scan, a normal heart was documented by a later scan or

after birth. Among different cardiac abnormalities, the present authors considered the predominant minor abnormality as disproportion of the ventricles and/or the great arteries. This minor cardiac defect was diagnosed between 11th-14th week and the follow-up data were available for eight patients. In this number of eight continuing pregnancies with diagnosis of disproportion ventricles and the great arteries, coarctation of the aorta was diagnosed at the mid-trimester scan.

Although the authors used three different probes, they failed to appropriately examine the fetal heart with any of these probes in 168 (6%) fetuses, hence they were not included in efficiency tests of ultrasound fetal heart diagnostics. To obtain the scan the authors used two L probes (L 12-5MHz), ev probe (ev 8-4MHz) and C probe (C 5-2 MHz). The basic reason for this was due to the fact that the pregnant woman habitus and the fetal position, i.e. its spine was in a parallel position to ultrasound waves.

The four-chamber heart view was obtained in all patients, and all parameters were demonstrated in 2,331 (92.1%) patients without CHD. Demonstration of individual parameters was somewhat variable. With CD, chamber situs was accessible in 97%, whereas without CD application it was possible to determine chamber situs in not more than 67%. DV assessment was possible in 91% of cases within the predicted time frame, while the assessment of the left chamber end-diastolic filling was possible in 99% of cases. At 3VV and 3VT, the authors were able to visualize the great arteries in 98%, while the “b” sign (the straight line of the pulmonary artery surrounded by aortic arch), “V” sign (the connection of the aorta and ductus arteriosus), and “X” sign (the crossing of the main pulmonary artery with the aorta) were seen in 96%. Ductal and aortic arches were seen in 91% and 93%, respectively, and forward flow with CD in both arches was determined in 97%. All parameters necessary for fetal heart analysis required the use of CD. Doppler was used in end-diastolic chamber flow and in DV. The use of CD was mandatory in estimation of the chambers situs, position of the aorta, estimation of AV valves, interventricular septum, foramen ovale, and aortic and ductal arches. DV with PI > 2.0 and more was found in 51 (45.9%) fetuses with CHD. Tricuspid regurgitation was found in 150 (7.5%) euploid fetuses, 22 (55%) of the 42 fetuses with chromosomal anomaly, and 42 (37,8%) with CHD. Separation of the “e” and “a” waves was found in 37 (33.3%) of the 111 fetuses with CHD. In 11 cases, the authors performed an additional examination in the 16th week, before the decision on possible pregnancy continuation or TOP.

CHD is the most common defect in human fetuses and affect approximately 0.3% to 0.8% of live births [12]. Prenatal detections of CHD are important because they allow searches for chromosomal, additional structural, and genetic abnormalities, with a potential for reduction of neonatal morbidity and mortality [13].

Technology progress in ultrasound hardware and software is likely to have contributed to the high success rate in the early assessment of fetal heart. Persico *et al.* [14], while using 4-8 MHz frequency probe were not able to scan 15% of fetuses. Different authors have reported different degrees of success of examination in the first and early second trimester scan, while using the same frequency probes - L 15-8MHz and L 15MHz, namely 99% [6, 7] and 75% [15], respectively. Rizzo *et al.* [16] achieved performance in fetal heart scan (92.4%) using a 4-8MHz probe from 18th–24th week of gestation. Turan *et al.* [17], using the same probe and the ultrasonic equipment, achieved performance of 85% but much earlier, suggesting that pregnancy period in which the scan was performed did not significantly limit the level of their performance in fetal heart scan.

Overall, the median (range) accuracy, sensitivity, and specificity, as well as the positive and negative likelihood ratios, for the identification of fetuses with congenital heart defects were 79% (77%-83%), 90% (70%-96%), 59% (58%-93%), 2,35 (2.05-9.80), and 0,18 (0.08-0.32), respectively [18]. 2D ultrasound remains superior to spatiotemporal image correlation 4D-STIC at 11-14 weeks, unless volumes of good to high quality can be obtained [19].

Conclusion

The importance of fetal heart scan in the first trimester of gestation can be substantiated by the following facts: the significance of a mandatory fetal heart scan, lies also in the fact that one-third of fetuses with CHD (37.8%) also had chromosomal anomalies, which corresponds to the data from nine studies reported between 1961 and 2008 [20]. This signifies that the test on ultrasonic markers for chromosomal anomalies would not reveal two-thirds of fetuses with a heart defect not accompanied by a chromosomal anomaly. Moreover, for the sake of confirming this assertion, only 35.1% of fetuses with CHD had an increased NT, which is increased only in 69% in fetuses with both chromosomal anomaly and CHD.

The 1.8% of fetuses with CHD in low risk patients is few times higher than referenced to in literature, which can be explained with a higher average age of pregnant women which is in the present series around 37 years. The CHD percentage is considerably higher in high-risk pregnant women, being 12%. Such a high CHD incidence imposes the obligation of performing a mandatory fetal heart scan, both in low and high risk pregnancies.

In conclusion, this study can be used as additional parameter by standard protocol tests with NT, nasal bone, Doppler of DV, and echogenic intestines, to become one of helping markers in earlier detection of chromosomopathies in even low risk group patients.

References

- [1] Yagel S., Cohen S.M., Achiron R.: "Examination of the fetal heart by five short-axis views: a proposed screening method for comprehensive cardiac evaluation". *Ultrasound Obstet. Gynecol.*, 2001, 17, 367.
- [2] Huggon I.C., Ghi T., Cook A.C., Zosmer N., Allan L.D., Nicolaides K.H.: "Fetal cardiac abnormalities identified prior to 14 weeks gestation". *Ultrasound Obstet. Gynecol.*, 2002, 20, 22.
- [3] Hafner E., Schuller T., Metznerbauer M., Schuchter K., Philipp K.: "Increased nuchal translucency and congenital heart defects in a low risk population". *Prenat. Diagn.*, 2007, 27, 164.
- [4] Cleves M.A., Hobbs C.A., Cleves P.A., Tilford J.M., Bird T.M., Robbins J.M.: "Congenital defects among lieborn infants with Down syndrome". *Birth Defects Res. A. Clin. Mol. Teratol.*, 2007, 79, 657.
- [5] Byard R.W.: "Forensic issues in Down syndrome fatalities". *J. Forensic Leg. Med.*, 2007, 14, 475.
- [6] Bellotti M., Fesslova V., Gasperi C., Rognoni G., Bee V., Zucca I., et al.: "Reliability of the first-trimester cardiac scan by ultrasound-trained obstetricians with high-frequency transabdominal probes in fetuses with increased nuchal translucency". *Ultrasound Obstet. Gynecol.*, 2010, 36, 272.
- [7] Mihailovic T., Stimec B.V., Terzic M., Dmitrović A., Micic J.: "The absence of the Vomer in the first and early second trimester of pregnancy - a new marker of trisomy 21 and trisomy 13". *Ultrascall. Med.*, 2011, 32, 1.
- [8] Mihailovic T., Terzic M., Dmitrovic A.: "Linear transducer reliability estimation for fetal heart morphology and Down's risk assessment in the first trimester of pregnancy". *J. Perinatal. Med.*, 2009, 37, 903.
- [9] Mihailovic T., Terzic M., Dmitrovic A., Micic J., Maricic S.: "Linear transducer for fetal echocardiography at first trimester of twin pregnancy". *J. Matern. Fetal Neonatal. Med.*, 2010, 23, 425.
- [10] Allan L.: "Technique of fetal echocardiography". *Pediatr. Cardiol.*, 2004, 25, 223.
- [11] Allan L., Dangel J., Fesslova V., Marek J., Mellander M., Oberhansli I., et al.: "Recommendations for the practice of fetal cardiology in Europe". *Cardiol. Young.*, 2004, 14, 109.
- [12] Hoffman J.I.E., Kaplan S.: "The incidence of congenital heart disease". *J. Am. Coll. Cardiol.*, 2002, 39, 1890.
- [13] Jaeggi E.T., Sholler G.F., Jones O.D.H., Cooper S.G.: "Comparative analysis of pattern, management and outcome of pre/versus postnatal diagnosed major congenital heart disease: a population-based study". *Ultrasound Obstet. Gynecol.*, 2001, 17, 380.
- [14] Persico N., Moratalla J., Lombardi C.M., Zidere V., Allan L., Nicolaides K.H.: "Fetal echocardiography at 11-13 weeks by transabdominal high-frequency ultrasound". *Ultrasound Obstet. Gynecol.*, 2011, 37, 296.
- [15] Lombardi C.M., Bellotti M., Fesslova V., Cappellini A.: "Fetal echocardiography at time of the nuchal translucency scan". *Ultrasound Obstet. Gynecol.*, 2007, 29, 249.
- [16] Rizzo G., Capponi A., Pietrolucci M.E., Capece G., Cimmino E., Colosi E., et al.: "Satisfactory rate of Post processing visualization of standard fetal cardiac views from 4-dimensional cardiac volumes acquired during routine ultrasound practice by experienced sonographers in peripheral centers". *J. Ultrasound Med.*, 2011, 30, 93.
- [17] Turan S., Turan O.M., Torresdes K.T.Y., Harman C.R., Baschat A.A.: "Standardization of the first-trimester fetal cardiac examination using spatiotemporal image correlation with tomographic ultrasound and color Doppler imaging". *Ultrasound Obstet. Gynecol.*, 2009, 33, 652.
- [18] JEspinoza J., Lee W., Viñals F., Martinez J.M., Bennasar M., Rizzo G., Belfort M.: "Collaborative Study of 4-Dimensional Fetal Echocardiography in the First Trimester of Pregnancy". *J. Ultrasound Med.*, 2014, 33, 1079.
- [19] Votino C., Cos T., Abu-Rustum R., Dahman Saidi S., Gallo V., Dobrescu O., et al.: "Use of spatiotemporal image correlation at 11-14 weeks gestation". *Ultrasound Obstet. Gynecol.*, 2013, 42, 669.
- [20] DeVore G.R.: "Genetic sonography: the historical and clinical role of fetal echocardiography". *Ultrasound Obstet. Gynecol.*, 2010, 35, 509.

Address reprint requests to:
 M. GOJNIĆ DUGALIĆ, M.D., Ph.D.
 Clinical Center of Serbia
 Clinic of Obstetrics and Gynecology
 Dr Koste Todorovića, 26
 11000 Belgrade (Serbia)
 e-mail: miroslavagojnicdugalic@yahoo.com

Analysis of rectal injuries resulting from laparoscopic peritoneal vaginoplasty (Luohu operation)

A. Le¹, Z. Wang¹, L. Shan¹, T. Xiao¹, G. Luo², Y. Shen³

¹ Department of Obstetrics and Gynecology, Affiliated Shenzhen Nanshan People's Hospital of Guaongdong Medical University, Shenzhen

² Department of Obstetrics and Gynecology, Affiliated Shenzhen Luohu People's Hospital of Guaongdong Medical University, Shenzhen

³ Department of Obstetrics and Gynecology, Union Hospital, Tongji Medical College, Huazhong University of Science and Technology, Wuhan (China)

Summary

Objective: To explore the causes of rectal injuries during laparoscopic peritoneal vaginoplasty (Luohu operation) and assess measures that can be taken to increase safety of the operation. **Materials and Methods:** Data of patients with rectal injuries that occurred during Luohu vaginoplasty were analyzed retrospectively. **Results:** Three hundred and six patients received Luohu vaginoplasty. Rectal injuries occurred in 13 patients (4.2%). All patients recovered after intraoperative repair or postoperative rectovaginal fistula repair, performed within three to six months. Full display of the anatomical structures at the bottom of the pelvic cavity and successful construction of the vaginal tunnel are the two most important requirements for reducing the risk of rectal injury in laparoscopic vaginoplasty. In repair of fistulae postoperatively, it is important that resection of tissues or scars around the fistulae be avoided in order to reduce the chance of a injuries caused by diverting colostomy or colostomy closure. **Conclusion:** Laparoscopic vaginoplasty is a generally safe procedure, but rectal injury can occur. Retaining the tissues or scars around the rectovaginal fistula can be successfully repaired, either when they are recognized during the operation or within a few months postoperatively.

Key words: Laparoscope; Peritoneal vaginoplasty (Luohu operation); Rectal injury; Rectovaginal.

Introduction

Artificial vaginoplasty is widely used in treating congenital aplasia of the uterus and upper part of the vagina, also known as Mayer-Rokitansky-Küster-Hauser (MRKH) syndrome. About 0.15 million women in China reportedly have the MRKH syndrome. Fortunately, increasing numbers of hospitals and clinicians now can provide vaginoplasty. Several methods are used for artificial vaginoplasty, including vaginal reconstruction with sigmoid colon or ileum, which have provided satisfactory results and are widely accepted by patients and clinicians [1]. Laparoscopic peritoneal vaginoplasty (Luohu's operation) has the advantages of other laparoscopic operations, and it provides a fully exposed surgical field, maintains a relatively stable environment in the pelvic cavity, reduces the risk of pelvic and abdominal adhesions, provides cosmetically acceptable abdominal incisions, and helps alleviate patients' psychological stress [2].

The authors performed Luohu vaginoplasty in 306 patients (150 Luohu operation I and 156 Luohu operation II) between November 2001 and October 2012. Rectal injuries occurred in 13 of the patients. They have now analyzed their experience with the operations and considered preventive measures that might increase their safety.

Materials and Methods

General information

All the patients were unmarried. Their mean age was 24.5 ± 3.2 SD years. No abnormalities were found with preoperative gynecologic examinations, and all the patients had normally developed external genitalia. The vaginal vestibules were 0.5-2.5 cm deep. Ultrasonic examination did not reveal ovarian tumors in all patients, but rudimentary uterus was found in 296 patients and infantile uterus in ten patients. The chromosome karyotype of all patients was 46XX.

Operation

The bowel was prepped for three days prior to the operation, and oral intestinal antibiotics were prescribed. Patients took a no-residue diet the day before the operation and fasted during the last 12 hours. They were given a cleansing enema the night before and the morning of the operation. The operation was carried out under intravenous anesthesia with endotracheal intubation, and with patients in head-low hip-high lithotomy position. Luohu operation II was performed from January 2008. Ten-mm trocars were inserted through an umbilical site and through an incision at McBurney's point; a third trocar (five-mm) was inserted through an incision in the left lower abdomen. The pelvic cavity was explored carefully for evaluation of the rudimentary uterus, connective tissue cords, bilateral ovaries and oviducts, relaxation of the perineum, and location of the anterior rectal wall (in order to define the extent and location of the bladder rectum lacunae).

Revised manuscript accepted for publication January 19, 2015

Luohu operation I

For this operation, the authors designed a peritoneal push rod, 55 cm long and 1.8 cm in diameter, with a 30° angle between its head (1.8 cm) and body. A hole ten-cm away from the rod's end allowed the insertion of a metal stick, ten-cm long and 0.5 cm in diameter, for help in manipulating the rod and keeping its head upwards. The operation was laparoscopically assisted. An epidural needle for administration of block anesthesia was inserted through the middle of the vaginal vestibule to the bladder rectum lacunae until the needle point could be seen, but the peritoneum remained intact. Two hundred milliliters of physiologic saline solution, containing six units of pituitrin and 0.1 ml of epinephrine, were injected to form a water cushion at the pelvic peritoneum. The needle was withdrawn slowly during the injection to make sure the tissues for formation of a vaginal tunnel were filled with the solution. A pair of large, curved pliers were inserted through the hole into the vaginal vestibule to divide the gap between the bladder and rectum. The gap was further detached digitally to form a vaginal tunnel, with two- to three-finger capacity and extension beyond the pelvic peritoneum. The peritoneum at the end of the vaginal tunnel was detached completely.

The laparoscope was inserted through the trocar located at McBurney's point. The trocar at the umbilical site was withdrawn, the incision was extended to 18 cm, and the peritoneal push rod was inserted through the incision into the abdominal cavity. The push rod was manipulated through the vaginal tunnel in order to push the pelvic peritoneum at the bladder rectum lacunae toward the opening of the tunnel at the vaginal vestibule through the vaginal tunnel. The peritoneum at the end of the push rod and the mucosa at the outer side of the vaginal tunnel were sutured with 3/0 absorbable line. A cruciate incision was made on the peritoneum, and the push rod was withdrawn through the tunnel to form the vaginal introitus. Purse-string sutures of synthetic thread (size 1) were placed along the rudimentary uterus, pelvic peritoneum, and anterior rectal wall to form the upper end of the vagina. The bottom of the pelvis was closed. A condom filled with vaseline gauze was placed in the vaginal tunnel to help form the vagina, and the bilateral labia minora was sutured sufficiently to prevent the condom from slipping out.

Luohu operation II

Laparoscope-assisted examinations were performed as in the Luohu operation I. A puncture needle (size 22, without needle core) for epidural anesthesia was inserted through the gap between the bladder and rectum toward the peritoneum beyond the fiber cord. Two hundred milliliters of physiologic saline solution, containing six units of pituitrin and 0.1 ml of epinephrine, were injected to form a water cushion until the peritoneum became thin, white, and bulging toward the pelvic cavity. The needle was withdrawn slowly during the injection to ensure that the gap was filled with the solution. A pair of medium-sized, curved pliers were inserted through the vaginal vestibule mucosa to divide the gap between the bladder and rectum, forming a vaginal tunnel of two- to three-finger capacity and extending beyond the pelvic peritoneum. A suction flusher was used to help guide formation of the vaginal tunnel from the pelvic peritoneum posterior to the fiber cord to the peritoneum at the vaginal vestibule. A mould (size 1), 2.2 cm in diameter, was inserted through the tunnel to push the bladder upward and form a bulge of the peritoneum. The peritoneum and tissues at the bottom of the pelvic cavity at the end of the mould were incised to create a tunnel connecting the vaginal vestibule and the abdominal cavity. Another mould (size 2-6), 2.5 to 3.5 cm in diameter, was used to gradually dilate the tunnel. The peritoneum was pushed through the tunnel and treated as described in the Luohu operation I.

Results

Rectal injuries

Thirteen patients incurred rectal injuries related to the operations. Eleven had a single perforation in the anterior rectal wall, one had two lesions in the anterior wall, and one had damage in the anterior rectal wall outside the pelvic peritoneum and inside the abdomen cavity. The perforations detected in the anterior rectal wall during the operation were of two to five cm; those discovered later were of 0.5 to 2.5 cm. All the patients were treated successfully. In one patient, the laparoscopic procedure was converted to a laparotomy, and a sigmoid colon vaginoplasty was performed. One patient received immediate repair, but a rectovaginal fistula was found seven days later; she recovered after a laparoscope-assisted ileal vaginoplasty was performed. Seven patients recovered after immediate repair followed by Luohu vaginoplasty. Three patients, who also received immediate repair, then Luohu vaginoplasty, developed rectovaginal fistulae, requiring repair a half year later. The patient with two rectal injuries (one inside the abdomen cavity and one outside), had laparoscope-assisted repair of the upper fistula and repair of the lower fistula through the vagina.

Treatments for rectal injuries diagnosed during the vaginoplasty

If rectovaginal fistula was identified during the operation, the fistula was fully exposed and digitally pushed up from the anus (for larger fistula, an Allis clamp was used to stretch the edge of the fistula). The rectal wall around the fistula was sutured with intermittent sutures, leaving the rectal mucosa intact. Another intermittent, inverting embedding suture was placed to reinforce the first layer of the sutures. The levator ani muscle around the vagina was stretched with an Allis clamp, and the closure was reinforced by the placement of additional interrupted mattress sutures. The edge of the peritoneum at the bottom of the pelvic cavity was stretched downward and anastomosed with vestibular mucosa to cover the vaginal wall. Postoperatively, the patients were asked to take a no-residue diet for five to seven days and to scrub the perineum twice daily; antibiotics for five to seven days were prescribed. Several days after the operation, the vaginal tunnel was expanded (by means of digital manipulation rather than with the use of the mould).

Treatments for rectal injuries diagnosed after the vaginoplasty

Some patients noticed leakage of gas or stool from vagina soon after the operation, suggesting the existence of rectal injuries. However, the fistulae could not be fixed immediately because of inflammation and edema, so they were repaired three to six months later. After vaginoplasty, the patients took a low-residue diet for ten days to reduce the

volume of stool. Intestinal anti-inflammatory agents were administered orally, and the patients were asked to rinse the vaginal tunnel with Iodophor (0.1%) one to two times/day and scrub the perineum. Endoscopic examination of the vaginal tunnel was strictly limited in order to avoid expansion of the fistula. In preparation for the reparative operation, the patients took low-residual food for three days, then a liquid diet the day before the operation. Intestinal antibiotics were administered for three days before the operation. The vaginal tunnel was rinsed once every day for three days, and a cleansing enema was given the night before and on the morning of the operation.

For the operation, the patients were placed in the lithotomy position and given lumbar or sacral anesthesia. The fistula on the posterior wall of the vaginal tunnel was fully exposed. The surgeon pushed the fistula up with his index finger through the anus. Dilute epinephrine solvent was injected into the vaginal mucosa around the fistula to form a cushion, which helped divide the tissues and reduce bleeding. With a sickle-shaped surgical blade, a circular incision 0.5 cm from the fistula was made into the fascial layer. The edge of the incision was pulled up with tissue forceps, and the mucosa and tissues of the rectal wall around the fistula were outward divided for about two cm with the sickle-shaped surgical blade. The vaginal mucosa was also inward divided, for about two mm. The scars at the edge of the fistula were not resected. Purse-string sutures (size 1 suture silk) were placed along the edge of the fistula, with the rectal mucosa remaining intact. For fistula larger than two cm, interrupted mattress sutures also were placed. To reinforce the first layer of the closure, interrupted embedding sutures (size 1 suture silk) were placed on the submucosal connective tissues. The vaginal mucosa was sutured with absorbable thread (0/3), and an Iodophor-soaked gauze roll was placed in the vaginal tunnel. The patients were asked to take a no-residue diet for five to seven days and to scrub the perineum twice daily. Antibiotics for five to seven days were prescribed. Several days later, the vaginal tunnel was expanded (by means of digital manipulation rather than with the mould).

Discussion

Laparoscopic peritoneal vaginoplasty (Luohu operation) has become a widely used treatment for congenital aplasia of the vagina and uterus (MRKH syndrome). The procedure has several advantages over the modified laparoscopic Vecchietti vaginoplasty [3]: it is not restricted by length of the sigmoid colon or mesenteric vessels, it does not cause organ damage; unlike sigmoid colon vaginoplasty, it does not have the smell of intestinal secretions, it is not restricted by the development of vestibular mucosa or the position of the urethral orifice, and it does not have complications, such as recurrent urinary tract infections. However, other complications, such as

rectal injury, may be associated with the laparoscopic peritoneal operation. In this series, rectal injury occurred in 13 of 306 (4.2%) patients during the formation of the vaginal tunnel. Rectal injury with laparoscopic peritoneal vaginoplasty usually occurs below the peritoneal reflection. In the present series, the injury was located below the reflection in 12 patients and both above and below the reflection in one patient. Treatment for rectal injuries below the peritoneal reflection may include colostomy, repair of rectal fistula, presacral open drainage, and rinsing of the distal rectum. Colostomy can help prevent infection, presacral drainage can reduce the risk of abscess in the gap around the rectum, and rinsing the distal rectum can minimize contamination with stool and the abnormal migration of intestinal flora. However, Cleary *et al.* [4] have reported that patients with small rectal injuries and mild contamination, who were treated with immediate primary repair of the fistula, did not have increased rates of disability rate and mortality. In another study, Levine *et al.* [5] retrospectively analyzed data from 30 patients with rectal injuries located below the peritoneal reflection. They concluded that colostomy is not indicated for patients who do not have injury to main organs, those with OIS score lower than II, and those who have been treated within eight hours after the injury; these patients can be treated with primary repair. Gonzalez *et al.* [6] have reported that patients do not benefit from presacral drainage or distal rectum rinse.

Repair of rectovaginal fistulae is very difficult due to their anatomic characteristics. Failure of the primary operation increases the difficulty of the second operation, and failure of the second operation reduces the success rate of the third operation to about 55% [7-9]. Thus, the present authors believe that it is important that the primary operation be successful. Reconstruction of the anterior rectal wall to restore the "high pressure area" in the rectum and anal canal is critical in the repair of rectovaginal fistulae. In the authors' operations, they found that tissues around the fistulae were very weak, so they removed only necrotic adjacent tissues; normal tissue was not detached. Also, in order to maintain good blood supply to the tissues and reduce the tension on them, they did not resect scars. In contrast to intestinal fistula, which can cause general peritonitis or even death, rectovaginal fistulae, which are not located in the abdomen cavity, usually do not cause serious systemic consequences. Thus, the authors did not construct colostomies in any of their patients. One advantage of avoiding colonoscopy is that patients do not have the risk of injury or morbidity associated with diverting colostomy or colostomy closure.

Pushing the peritoneum down is critical in laparoscopic peritoneal vaginoplasty. The pelvic peritoneum at the bladder rectum lacunae is commonly chosen to minimize the injury caused by the procedure. Surgeons must be very careful to avoid pushing the anterior rectal wall down along with the

peritoneum; thus, the rectal wall must be identified clearly before the peritoneum is resected. In the present authors' operations, the peritoneum generally appears thin and off-white, whereas if the rectal wall is also pushed down, the tissues below the head of the push rod are thicker and light red. If pushing the anterior rectal wall down cannot be avoided, the peritoneum above the head of the push rod should be resected and sutured, and the anus should be examined after the operation in order to avoid suturing the rectal wall together with the vestibular tunnel entrance mucosa. The entire operation must be carried out with laparoscopic assistance and the surgeon should frequently touch the devices (such as the end of the suction tube), which have been inserted by the assistants through the trocar, and guide the detaching and expansion of the gap between the bladder and rectum in order to fully divide the peritoneum at the bottom of pelvic cavity.

Luohu vaginoplasty is a relatively uncomplicated procedure, but other methods of vaginoplasty are available if the Luohu operation fails. Clear display of the anatomical structures at the bottom of the pelvic cavity and successful construction of the vaginal tunnel are the two most important requirements for reducing the risk of rectal injury during vaginoplasty. Rectovaginal fistulae should be repaired during the operation if they are recognized; if not recognized until later, they should be repaired within three to six months if possible. Tissues around the fistula should not be detached, and the scars should not be resected in order to avoid injuries that might require colostomy.

References

- [1] Jo E.J., Lee Y.Y., Kim T.J., Choi C.H., Lee J.W., Bae D.S., Kim B.G.: "Management and outcome of rectal injury during gynecologic laparoscopic surgery". *J. Minim. Invasive Gynecol.*, 2013, 20, 166.
- [2] Davies, M.C., Creighton S.M.: "Vaginoplasty". *Curr. Opin. Urol.*, 2007, 17, 415.
- [3] Nakhil, R.S., Creighton S.M.: "Management of vaginal agenesis". *J. Pediatr. Adolesc. Gynecol.*, 2012, 25, 352.
- [4] Cleary R.K., Pomerantz R.A., Lampman R.M.: "Colon and rectal injuries". *Dis. Colon Rectum*, 2006, 49, 1203.
- [5] Levine J.H., Longo W.E., Pruitt C., Mazuski J.E., Shapiro M.J., Durham R.M.: "Management of selected rectal injuries by primary repair". *Am. J. Surg.*, 1996, 172, 575.
- [6] Gonzalez R.P., Phelan H. 3rd., Hassan M., Ellis C.N., Rodning C.B.: "Is fecal diversion necessary for nondestructive penetrating extraperitoneal rectal injuries?" *J. Trauma*, 2006, 61, 815.
- [7] van der Hagen S.J., Soeters P.B., Baeten C.G., van Gemert W.G.: "Laparoscopic fistula excision and omentoplasty for high rectovaginal fistulas: a prospective study of 40 patients". *Int. J. Colorectal Dis.*, 2011, 26, 1463.
- [8] Ommer A., Herold A., Berg E., Furst A., Schiedeck T., Sailer M.: "German S3-Guideline: rectovaginal fistula". *Ger. Med. Sci.*, 2012, 10, Doc15. doi: 10.3205/000166. Epub 2012 Oct 29.
- [9] Nassar O.A.: "Primary repair of rectovaginal fistulas complicating pelvic surgery by gracilis myocutaneous flap". *Gynecol. Oncol.*, 2011, 121, 610.

Address reprint requests to:

Y. SHEN, M.D.

Department of Obstetrics and Gynecology

Union Hospital, Tongji Medical College

Huazhong University of Science and Technology

Jie Fan Road, No. 1277, Wuhan (China)

e-mail: leaiwen@126.com

-1195 A/G promoter variants of the cyclooxygenase-2 gene increases the risk of pain occurrence in endometriotic women

H. Wang, L. Sun, M. Jiang, L. Liu, G. Wang

Department of Gynecology, Dalian Hospital of Gynecology and Obstetrics, Dalian (China)

Summary

Objective: The aim of this study was to evaluate the association between -1195 A/G polymorphism in cyclooxygenase-2 (COX-2) gene and the risk of pain occurrence in women with endometriosis (EM). **Materials and Methods:** -1195 A/G polymorphism in the promoter region of COX-2 gene was analyzed in 32 EM patients with pain, 28 EM patients without pain, and 29 healthy controls in a Chinese population using a PCR-RFLP assay. **Results:** AA homozygote carriers and A allelic frequencies for -1195 A/G polymorphism in COX-2 gene were significantly increased in EM patients compared with the healthy controls ($p < 0.001$). In addition, further subgroup analysis revealed that the AA genotype and A allele of the -1195 A/G variant were present at a significantly higher frequency in the severe pain group than those in the mild and moderate pain groups. Compared with the controls, the risk of developing EM was 2.86-fold higher in individuals with -1195 AA containing the haplotype, and the risk of developing pain was 2.33-fold higher in EM patients with -1195 AA containing the haplotype. **Conclusions:** These findings suggest that the -1195 A/G on the promoter region of COX-2 gene may increase the risk of pain occurrence in EM women, possibly by affecting the rate of gene expression, especially in patients with the pain phenotype.

Key words: Endometriosis; Pain; Cyclooxygenase-2; Single nucleotide polymorphism.

Introduction

Endometriosis (EM) is a common chronic benign disease in women of reproductive age, but the exact etiology of this disease remains controversial. Pelvic pain is one of the most main clinical symptoms affecting approximately 70% EM patients, and considerably reduces the quality of life in affected women. However, the mechanism of EM-related pain is unclear.

Some current studies [1] suggest that inflammatory response is one of the important factors. Cyclooxygenase-2 (COX-2) is the key rate-limiting enzyme in the conversion of phospholipid arachidonic acid to prostaglandins (PG) via increasing prostaglandin E₂. The production of PG catalyzed by COX-2 is involved in inflammation and pain response by multiple pathways in different tissues in the body [2]. In this way, COX-2 may contribute to the progression and continuity of EM. Studies [3, 4] suggested that COX-2 expression was significantly increased in the eutopic endometria, ectopic endometria, and ovarian endometriotic tissue of EM women, and was associated with dysmenorrhea. It implied possible roles of hyperperistalsis in the pathogenesis of EM, particularly in the view of COX-2 and PGE [5]. COX-2 inhibition induces regression of endometrial grafts by suppression of angiogenesis and stimulation of apoptosis [6]. COX-2 inhibitors are believed to be a safe, effective, and low-cost therapy in the management of pelvic pain associated with EM, and were also proposed for use to treatment

pelvic pain in the early stage of EM [7]. The single nucleotide polymorphism of COX-2 may play an important role in genetic susceptibility to the development of EM and adenomyosis. So far, there has been little information about the correlation between -1195 A/G gene polymorphism and the risk of pain occurrence in EM patients, and the potential association of -1195 A/G haplotype with different degrees of pain in EM has not been assessed in Chinese women. The primary purpose of this study was to investigate the effect of -1195 A/G polymorphism in COX-2 gene on pain occurrence in endometriotic women and assess the strength of this association (if any) using odds ratios (ORs) with 95% confidence intervals (CIs).

Materials and Methods

Subjects

Included in this study were all patients who underwent open or laparoscopic surgery for pathologically confirmed ovarian endometrial cysts in Dalian Obstetrics and Gynecology Hospital from June 2010 to May 2011. This study was conducted in accordance with the Declaration of Helsinki. This study was conducted with approval from the Ethics Committee of Dalian hospital of gynecology and obstetrics. Written informed consent was obtained from all participants.

Classification of clinical phenotypes

According to the presence or absence of dysmenorrhea, 60 EM patients who fulfilled the revised American Fertility Society (r-

Revised manuscript accepted for publication October 8, 2014

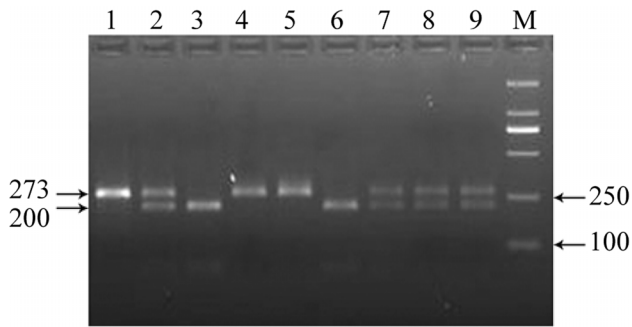


Figure 1. — The electropherogram of -1195 A/G polymorphism genotype in COX-2 gene. Sample 1, 4 and 5 are AA homozygotes (273bp); 3 and 6 lanes are GG homozygotes (200bp and 73bp); 2, 7, 8, and 9 lanes are GA heterozygotes (273bp, 200bp, and 73bp).

AFS) score of Stage III-IV were divided into two groups: 32 in the pain group and 28 patients in the non-pain group. According to the preoperative visual analogue pain scale (VAS) score, the 32 patients in the pain group were further divided into three groups: 1-3 points as light pain, 4-6 as moderate pain, and 7-10 as severe pain. Additional 29 healthy subjects eliminated EM were selected randomly from healthy outpatients who underwent routine physical examination and ultrasound during the same period. The mean age in the EM group was 39.80 ± 2.67 years, which was essentially the same as the control group (37.36 ± 3.04 years). All the included women were Chinese Han nationality with normal menstrual cycles without histories of smoking, chronic pelvic inflammatory disease, hypertension, diabetes, nephropathy, or genetic disease in the families, nor did they administer any hormonal drug at least three months before surgery. Peripheral whole venous blood (two ml) was taken from all the participants, treated with EDTA anticoagulant, and stored at -70°C until analysis.

Genotype analysis

Genomic DNA was extracted from the peripheral whole blood using the genomic DNA extraction kit. Genotyping was performed by polymerase chain reaction (PCR) and restriction fragment length polymorphism (RFLP). The COX-2 gene -1195 A/G PCR primers were the following: 5'-CCC TGA GCA CTA CCC ATGAT-3' (Forward) and 5'-GCC CTT CAT AGG AGATAC TGG-3' (Reverse) [8]. The PCR reaction system was carried out in a final volume of 50 μl by initial denaturation at 98°C for two minutes, followed by 30 amplification cycles: 98°C during ten seconds for denaturation, 60°C during ten seconds for annealing,

and 68°C during 30 seconds for extension, and finally, 68°C during five minutes for ending extension. The digested products were then electrophoresed on 2% agarose gel stained with ethidium bromide and examined under transillumination (Figure 1). Each gel was assessed independently by two observers unaware of the status of the subjects. If there was any conflict, sample genotyping was repeated.

Sequence analysis of each set of PCR amplification products was performed by cutting gel purified DNA sequencing in the ABI377 automatic sequencing instrument on COX-2 -1195 sites to verify whether the mutation was consistent with gel electrophoresis. -1195 points homozygous were AA and GG, and the heterozygous was GA (Figure 2).

Statistical analysis

For statistical analysis, the observed numbers of each COX-2 -1195 A/G genotype were compared with those expected for population in Hardy-Weinberg equilibrium by using the χ^2 test. The Pearson's χ^2 -test was used to analyze the distribution of genotype frequencies between groups. OR and 95% CI were used as the criteria of the association between the genotype and the diseases or pain. A p value < 0.05 was considered statistically significant. Statistical analyses were performed with the statistical package for social sciences (SPSS version 13.0).

Results

The distribution of -1195 A/G genotypes in COX-2 gene showed no significant difference when compared with that predicted from the Hardy-Weinberg genetic equilibrium for either EM patients or controls, indicating that the distribution achieved genetic equilibrium and had group representativeness.

A/G polymorphism in subjects

There was significant difference between EM patients and controls in the distribution of COX-2 -1195 A/G genotypes or in the allelic frequencies (Table 1). The AA genotype and A allele frequency in the EM group were significantly higher than those in the normal control group ($p < 0.05$). The AA genotype and A allele frequency in the endometriotic pain group were significant higher than those in patients without endometriotic pain and the normal control group ($p < 0.05$). In contrast, the GG genotype and G allele frequencies in the normal control group were more prevalent than those in the endometriotic pain group ($p < 0.05$).

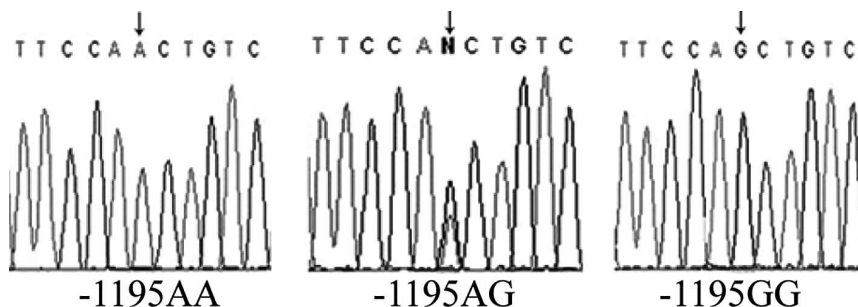


Figure 2. — The single nucleotide polymorphic sequencing result of -1195 A/G in COX-2 promoter region; the arrow indicates a single base change.

Table 1. — COX-2 gene -1195 A/G genotypes and allelic frequencies in endometriotic pain, non-endometriotic pain, and control groups.

Group	n	-1195 A/G genotypes (%)			A/G allelic frequencies (%)	
		GG	GA	AA	G	A
EM	60	17(28.33)	24(40.00)	19(31.67)*	58(48.33)	62(51.67)*
Endometriotic pain	32	7(21.88)	11(34.38)	14(43.75)*#	25(39.06)	39(60.94)*#
Non-endometriotic pain	28	10(35.71)	13(46.43)	5(17.86)	33(58.93)	23(41.07)
Control	29	14(48.28)	12(41.38)	3(10.34)	40(68.97)	18(31.03)

Note: *Compared with control group, $p < 0.05$; #compared with non-endometriotic pain group, $p < 0.05$.

Table 2. — COX-2 gene -1195 A/G genotypes and allelic frequencies in different degrees of pain in EM and control groups.

Group		n	GG	GA	AA	G allele	A allele
Endometriotic pain	Mild	10	2(20.00)	5(50.00)	3(30.00)	9(45.00)	11(55.00)
	Moderate	10	2(20.00)	4(40.00)	4(40.00)	8(40.00)	12(60.00)
	Severe	12	2(16.67)	3(25.00)	7(58.33)*	7(29.17)	17(70.83)*
Control		29	14(48.28)	12(41.38)	3(10.34)	40(68.97)	18(31.03)

Note: *Compared with control group, $p < 0.05$.

Table 3. — Correlation analysis of the -1195 AA genotype.

Group	-1195 AA	-1195 non AA	OR (95%CI)
EM	19 (31.67)	41 (68.33)	2.86 (1.25-7.44)
Control	3 (10.34)	26 (89.66)	
Endometriotic pain	14 (43.75)	18 (56.25)	2.33 (1.09-5.62)
Non-endometriotic pain	5 (17.86)	23 (82.14)	

A/G polymorphism in EM group

The data concerning the COX-2 promoter -1195 A/G polymorphism in different degrees of endometriotic pain are shown in Table 2. The AA genotype and A allele frequency were significantly higher in the severe pain group than those in the mild and moderate pain groups and the normal control group ($p < 0.05$).

The correlation of AA genotype and pain degree

The results of correlation analysis between the -1195 AA genotype and endometriotic pain are shown in Table 3. It was found that the risk of developing EM in individuals carrying two A alleles was 2.86-fold as high as that in the normal control group (95% CI = 1.25 - 7.44). The risk of developing endometriotic pain in EM patients with -1195 AA containing haplotype was 2.33-fold as high as that in the EM patients without pain (95% CI = 1.09 - 5.62).

Discussion

COX is an enzymatic protein existing in two isoforms: COX-1 and COX-2. It is involved in the synthesis of PGE₂ from PGG₂. COX-2 is an important rate-limiting enzyme in PG synthesis. It is related to the inflammatory response, pain, and fever, and is involved in inflammatory processes and tumor occurrences [9]. The expression of COX-2 was high in ectopic endometrial cells as compared with that in eutopic endometrial cells [10]. The release of PG in ectopic endome-

trial cells is believed to be involved in the pathogenesis of EM [11]. COX-2 is an inducible enzyme responsible for catalysing the formation of PG and thromboxane in inflammatory settings [12]. Single nucleotide polymorphisms (SNP) of the COX-2 gene may influence gene transcription and PG production in the pelvis.

COX-2 has a variety of gene polymorphisms and the promoter region of a variety of enhancers and transcription control element can activate special transcription factors by altering the transcriptional activity of the gene to control the expression of COX-2. Genetic variation of the promoter region is an important factor to affect the regulation of gene transcription [13].

Several studies [4, 14] have suggested that COX-2 expression is increased in eutopic and ectopic endometrial cells, in ovarian endometriotic tissue of EM patients, and may be related to the pathogenesis of EM. The peritoneal fluid of EM patients can promote the proliferation of endometrial stromal cells, and also induce COX-2 gene expression and enhance PGE₂ secretion in endometrial stromal cells via the MAPK pathway [15]. The COX-2 isoform is an inducible enzyme responsible for PG synthesis in various inflammatory conditions.

COX-2 promoter region -1195 locus is located in the core of the c-Myb transcription factor recognition sequence with G > A single nucleotide polymorphism. The A allele allows the promoter to bind to the transcription factor c-Myb, thus increasing the transcriptional activity of GA or AA genotype, and the susceptibility to disease. A → G mutation significantly reduced COX-2 mRNA transcription [16]. Reports in recent years indicate that COX-2 -1195 G > A single nucleotide polymorphism may play role in increasing susceptibility to EM in China women [17]. The present results showed that the genotype frequencies of -1195 were significantly different in the EM group as compared with controls, which is consistent with the previous reports.

EM is a chronic inflammatory disease characterized by implantation and growth of endometrial tissue outside of the

uterus [18]. COX-2 catalyzes phospholipid arachidonic acid synthesis of PG, which directly activates nociceptors, causing pain, but on the other hand also improves peripheral membrane excitability of primary afferent neurons to reduce feelings nociceptors pain threshold, and increases sensory nerve endings of the sensitivity of the inflammatory mediators. Several studies [19] have shown high expression of COX-2 in ovarian endometrial cyst, eutopic, and ectopic endometrial cells, which may be related to the pathogenesis of EM. The use of COX-2 specific inhibitors is believed to be a safe, effective, and low-cost treatment for EM-associated pelvic pain and may be also proposed in the early stage of EM [20]. However, these results only explain the possible association between COX-2 protein expression and endometriotic pain without confirming whether the COX-2 gene polymorphism is associated with the risk of developing endometriotic pain. The present results showed that there was a significant difference in AA genotype and A allele frequency in COX-2 -1195 between patients with endometriotic pain and those without endometriotic pain and normal controls. In addition, the AA genotype and A allele frequency were significant higher in the severe pain group than those in the controls. -1195 G > A single nucleotide gene polymorphism in COX-2 was related to the risk of developing endometriotic risk, and the A allele indicated a high risk of the occurrence of endometriotic pain.

In summary, COX-2 gene is closely related to the development and progression of EM, implying that COX-2 may be an important factor affecting the susceptibility to EM, and a basic target for the treatment of EM. By far, no study has evaluated the possible relationship between the degree of pain and -1195 A/G polymorphism of COX-2 gene. The A allele of -1195 in COX-2 significantly increased the risk of morbidity and endometriotic pain in the present research. Further study regarding the -1195 G > A gene polymorphism in COX-2 gene is needed to clarify the pathogenesis of endometriotic pain and find the molecular intervention action site on endometriotic pain so as to develop new therapeutic targets for the treatment of EM and endometriotic pain.

Acknowledgments

This study was funded by Dalian Municipal Science and Technology Plan Project (Project number: 20110659).

References

- [1] McKinnon B., Bersinger N.A., Wotzkow C., Mueller M.D.: "Endometriosis-associated nerve fibers, peritoneal fluid cytokine concentrations, and pain in endometriotic lesions from different locations". *Fertil. Steril.*, 2012, 97, 373.
- [2] Shahedi K., Lindström S., Zheng S.L., Wiklund F., Adolfsson J., Sun J., et al.: "Genetic variation in the COX-2 gene and the association with prostate cancer risk". *Int. J. Cancer.*, 2006, 119, 668.
- [3] Cho S., Park S.H., Choi Y.S., Seo S.K., Kim H.Y., Park K.H., et al.: "Expression of cyclooxygenase-2 in eutopic endometrium and ovarian endometriotic tissue in women with severe endometriosis". *Gynecol. Obstet. Invest.*, 2010, 69, 93.
- [4] Matsuzaki S., Canis M., Pouly J.L., Wattiez A., Okamura K., Mage G.: "Cyclooxygenase-2 expression in deep endometriosis and matched eutopic endometrium". *Fertil. Steril.*, 2004, 82, 1309.
- [5] Li X., Gong X., Zhu L., Leng J., Fan Q., Sun D., et al.: "Stretch magnitude and frequency-dependent cyclooxygenase 2 and prostaglandin E2 up-regulation in human endometrial stromal cells: possible implications in endometriosis". *Exp. Biol. Med.*, 2012, 237, 1350.
- [6] Laschke M.W., Elitzsch A., Scheuer C., Vollmar B., Menger M.D.: "Selective cyclo-oxygenase-2 inhibition induces regression of autologous endometrial grafts by down-regulation of vascular endothelial growth factor-mediated angiogenesis and stimulation of caspase-3-dependent apoptosis". *Fertil. Steril.*, 2007, 87, 163.
- [7] Kilico I., Kokcu A., Kefeli M., Kandemir B.: "Regression of experimentally induced endometriosis with a new selective cyclooxygenase-2 enzyme inhibitor". *Gynecol. Obstet. Invest.*, 2014, 77, 35.
- [8] Shi J., Misso N.L., Kedda M.A., Horn J., Welch M.D., Duffy D.L., et al.: "Cyclooxygenase 2 gene polymorphisms in an Australian population: association of the -1195 G > A promoter polymorphism with mild asthma". *Clin. Exp. Allergy*, 2008, 38, 913.
- [9] Moran E.M.: "Epidemiological and clinical aspects of nonsteroidal anti-inflammatory drugs and cancer risks". *J. Environ. Pathol. Toxicol. Oncol.*, 2002, 21, 193.
- [10] Ota H., Igarashi S., Sasaki M., Tanaka T.: "Distribution of cyclooxygenase-2 in eutopic and ectopic endometrium in endometriosis and adenomyosis". *Hum. Reprod.*, 2001, 16, 561.
- [11] Chishima F., Hayakawa S., Sugita K., Kinukawa N., Aleemuzzaman S., Nemoto N., et al.: "Increased expression of cyclooxygenase-2 in local lesions of endometriosis patients". *Am. J. Reprod. Immunol.*, 2002, 48, 50.
- [12] Gurdol F., Cakmakoglu B., Dasedemir S., Isbilen E., Bekpinar S., Isbir T.: "765 G→C and -1195 A→G Promoter Variants of the Cyclooxygenase-2 Gene Decrease the Risk for Preeclampsia". *Genet. Test. Mol. Biomarkers*, 2012, 16, 435.
- [13] Zhao D., XU D., Zhang X., Wang L., Tan W., Guo Y., et al.: "Interaction of cyclooxygenase-2 variants and smoking in pancreatic cancer: a possible role of nucleophosmin". *Gastroenterology*, 2009, 136, 1659.
- [14] Khan K.N., Kitajima M., Fujishita A., Hiraki K., Matsumoto A., Nakashima M., et al.: "Pelvic pain in women with ovarian endometrioma is mostly associated with coexisting peritoneal lesions". *Hum. Reprod.*, 2013, 28, 109.
- [15] Liu Y., Hu J., Shen W., Wang J., Chen C., Han J., et al.: "Peritoneal fluid of patients with endometriosis promotes proliferation of endometrial stromal cells and induces COX-2 expression". *Fertil. Steril.*, 2011, 95, 1836.
- [16] Zhang X., Miao X., Tan W., Ning B., Liu Z., Hong Y., et al.: "Identification of functional genetic variants in cyclooxygenase-2 and their association with risk of esophageal cancer". *Gastroenterology*, 2005, 129, 565.
- [17] Wang Y.F., Qu Y.E., Yang M.: "Study on the relationship between polymorphism of the COX-2 gene and endometriosis and adenomyosis". *Shan Dong Medical Journal.*, 2007, 47, 22.
- [18] Gan X.L., Lin Y.H., Zhang Y., Yu T.H., Hu L.N.: "Association of an interleukin-16 gene polymorphism with the risk and pain phenotype of endometriosis". *DNA Cell. Biol.*, 2010, 29, 663.
- [19] Banu S.K., Lee J., Speights V.O. Jr., Starzinski-Powitz A., Arosh J.A.: "Cyclooxygenase-2 regulates survival, migration, and invasion of human endometriotic cells through multiple mechanisms". *Endocrinology*, 2008, 149, 1180.
- [20] Cobellis L., Razzi S., De Simone S., Sartini A., Fava A., Danero S., et al.: "The treatment with a COX-2 specific inhibitor is effective in the management of pain related to endometriosis". *Eur. J. Obstet. Gynecol. Reprod. Biol.*, 2004, 116, 100.

Address reprint requests to:

H. WANG, M.D.

Department of Gynecology

Dalian Hospital of Gynecology and Obstetrics

No.1 Dunhuang Road

Dalian city 116033

Liao Ning Province (China)

e-mail: hualiwangcn@163.com

Evaluation of female athlete triad and gynecological complaints in young Turkish female athletes

P. Solmaz Hasdemir¹, O. Oral², E. Calik¹, M. Ulusoy³, R. Varol², H. Tayfun Ozcaker¹

¹ Celal Bayar University Medical School, Department of Obstetrics and Gynecology, Manisa

² Ege University Physical Education and Sports College, Department of Health Sciences, Izmir

³ Celal Bayar University Medical School, Department of Family Physics, Manisa (Turkey)

Summary

Purpose: Female athlete triad (FAT) is a serious healthcare concern in the young female population. The aim of this study was to determine the prevalence and clinical characteristics of FAT and its relationship with gynecologic complaints of young Turkish female athletes. **Materials and Methods:** This was a cross-sectional survey and included 87 female athletes involved in a variety of sports as a case group and 85 sedentary female university students from Ege and Celal Bayar Universities. All subjects completed a questionnaire consisting of 32 separate questions assessing eating behavior, menstrual status, gynecologic and systemic complaints, psychological problems, and sexual history. SPSS 21.0 was used for statistical analysis. **Results:** This survey involved 172 females in between to 30 years of age. The age of menarche was found to be significantly lower in the sedentary group ($p = 0.00$). Late menstruation and oligo-amenorrhea were notable complaints among the athletes, and body mass index (BMI) was found to be statistically lower in the athletic group ($p = 0.00$). Cold hands and hair loss were seen more often in the sedentary group compared to the athletic group ($p < 0.05$). According to a logistic regression analysis, independent variables (BMI, menstrual status, and bone fractures) were found to be statistically insignificant ($p > 0.05$). **Conclusions:** Excessive sports activity can be hazardous in young female population. Lower BMI might be related to menstrual irregularity. Young female population should be informed about this relationship, especially athletes who are particularly at risk. Certain precautions should be taken into consideration in this population in order to get benefits of sports activity.

Key words: Anorexia nervosa; Amenorrhea; Bone health; Disordered eating; Energy deficiency; Female athlete triad; Menstrual irregularity.

Introduction

Female athlete triad (FAT) was identified as the association of the three distinct conditions of an eating disorder, amenorrhea, and osteoporosis by the American College of Sports Medicine in 1997 [1, 2]. The triad is now described as a medical condition often observed in physically active girls and women and involves any one of the following three components: low energy availability (EA) with or without disordered eating, menstrual dysfunction, and low bone mineral density (BMD) [3]. Clinical manifestations including eating disorders, functional hypothalamic amenorrhea, and osteoporosis could be seen in untreated subjects.

Obviously, habitual exercise is beneficial to the health and well-being of girls and women. Proper EA is very important for maintaining the physiological processes of the body [4]. EA refers to the amount of dietary energy remaining after exercise for all other physiological processes and is calculated as follows: dietary energy intake minus exercise energy expenditure [5]. Energy intake that is chronically inadequate to compensate for energy expenditure results in insufficient stored energy to maintain physiological processes; this condition is known as

low EA. Low EA may be the result of losing more energy than is gained through food intake or of restricting energy intake [1]. Girls and women participating in sports that emphasize a low body weight are more likely than other active females to restrict their EA [6].

When EA is too low, physiological mechanisms reduce the amount of energy used for cellular maintenance, thermoregulation, and reproduction [7]. The type of amenorrhea caused by low EA is classified as functional hypothalamic amenorrhea. Ovarian function is suppressed by an abnormally slow frequency of luteinizing hormone pulses in the blood. In animal experiments, reducing energy intake by more than 33% causes infertility and delays puberty [8, 9].

Amenorrhea results in an estrogen-poor environment, which has a negative effect on bone formation. Compromised bone health increases the risk of fractures during the entire lifespan, highlighting the long-term health consequences of FAT. Stress fractures are often a clinical manifestation of low bone mass [10].

The potentially irreversible consequences of these clinical conditions emphasize the critical need for the prevention, early diagnosis, and treatment of FAT.

Revised manuscript accepted for publication April 27, 2015

Table 1. — Menstrual status and complaints of the athletes and sedentary groups.

		Athlete (%)	Sedentary (%)	<i>p</i> -value
Menstrual status	Premenarche	26.4	0	0.00*
	Normal	58.6	90.6	
	Oligo-menorrhoea	4.6	3.5	
	Menorrhagia or menstruation > 7 days	1.1	4.7	
	First menstruation > 15 years	5.7	0	
	First menstruation >15 years + oligo-menorrhoea	3.4	1.2	
Dysmenorrhoea		44.8	57.6	0.09
Analgesic use for dysmenorrhoea		28.7	42.4	0.06
PMS		36.8	54.1	0.02*
Inconvenience of menstruation	No	43.7	24.7	0.99
	Sometimes	31	0	
	Yes	25.3	75.3	

PMS: premenstrual syndrome, **p* < 0.05 value shows statistically significance.

Materials and Methods

This was a cross-sectional survey and included 87 female athletes involved in a variety of sports as a case group and 85 sedentary female university students from Ege and Celal Bayar Universities as a control group. All subjects completed a questionnaire consisting of 32 separate questions assessing eating behavior, menstrual status, gynecologic and systemic complaints, psychological problems, and sexual history. Written informed consent was obtained from each subject (and from the parents of those < 18 years of age), and all procedures for recruitment and the conduct of the study were approved by the Institutional Review Board.

Inclusion criteria included being ten to 30 years of age and participation on a varsity sports team at a very high level of physical activity (physical exercise at least three to four days a week for about 1.5 to three hours a day). Exclusion criteria included pregnancy, known metabolic or systemic disease, and/or medication usage. Females ten to 30 years of age who did not participate regularly in sports activities (less than two times a week for about 20 minutes a day) were included in the study as the sedentary group.

SPSS 15.0 was used for the statistical analysis. A descriptive analysis was conducted, the difference of variables between groups was analyzed, and a Mann Whitney test was used to examine the nominal and abnormally distributed variables. Potential factors that related to engaging in sports activity were analyzed using a logistic regression model. Results were assessed as follows: a *p*-value < 0.05 was considered statistically significant and a *p*-value > 0.05 was considered statistically insignificant at a 95% confidence interval.

Results

This survey included 172 females (87 athletic and 85 sedentary females) ten to 30 years of age. The median age was 20 years for the athletes and 18 years for the sedentary group (*p* = 0.00). The median age for starting sports was nine years; 54% of the athletes were involved in gymnastics, 18.4% were involved in folk dancing, 6.9% were involved in volleyball, and the remaining athletes were involved in handball, rugby, tennis, and other types of dance. The median age for menarche was 14 years for the athletes and 13 years for the sedentary group. The age of menarche was found to be significantly lower in the seden-

Table 2. — Comparison of the pulse rate, BMI values, and the complaints related with bone health between athletes and sedentary cases.

	Athlete	Sedentary	<i>p</i> -value
Pulse rate	84.26 ± 12.77	80.93 ± 6.2	0.00*
BMI	19.69 ± 2.49	21.41 ± 2.94	0.00*
Bone fracture history	19.5	12.9	0.24
BMD measure	4.6	8.2	0.33
Musculoskeletal injury in last six months	24.1	3.5	0.00*

BMI: Body- mass index, BMD: bone mineral density.

**p*<0,05 value shows statistically significance.

tary group (*p* = 0.00). Menstrual status and complaints related to menstruation are detailed in Table 1. Sports activity seems to be a protective factor against premenstrual syndrome (PMS) (*p* = 0.02).

The pulse rate varied between 62 and 118 and was found to be statistically higher in the athletic group, and BMI was found to be statistically lower in the athletic group (Table 2). The Spearman's correlation analysis revealed a weak but significantly negative relationship between the age of menarche and BMI (36.8%) (correlation is significant at the 0.01 level [two-tailed]). There was no difference between the two groups in terms of previous bone fractures or BMD measurement, but musculoskeletal injury in the last six months was seen in the athletic group more often than in the sedentary group (*p* = 0.00) (Table 2).

Bradycardia, orthostatic hypotension, and cold/discholored hands and feet may be signs of eating disorders. Both groups were asked to answer some questions about complaints related to low EA, dry skin, cold hands and feet, hair loss, late wound healing, hypotension, breast concerns, incontinence, and fatigue. Interestingly, the present authors found hand and foot coldness and hair loss occurred more frequently in the sedentary group compared to the athletic group (*p* < 0.05) (Table 3).

Table 3. — Comparison of the complaints related with low energy availability between athletes and sedentary cases.

Complaints		Athlete (%)	Sedentary (%)	p-value
Dry skin	Yes	34.5	34.1	0.96
	No	65.5	65.9	
Cold hands and feet	Yes	52.9	68.2	0.04*
	No	47.1	31.8	
Hair loss	Yes	46	75.3	0.00*
	No	54	24.7	
Late wound healing	Yes	13.8	17.6	0.49
	No	86.2	82.4	
Hypotension	Yes	28.7	21.2	0.25
	No	71.3	78.8	
Complaints with breast	Yes	14.9	12.9	0.71
	No	85.1	87.1	
Incontinence	Yes	3.4	2.4	0.67
	No	96.6	97.6	
Fatigue	Never	5.7	0	0.23
	Sometimes	50.6	69.4	
	Frequently	36.8	25.9	
	Always	6.9	4.7	

* $p < 0.05$ indicates statistical significance in complaints between two groups.

There was no significant difference in terms of depression history between the groups (5.7% vs. 7.1%, respectively; $p = 0.73$). Similarly, there was no statistical significance regarding mood status between the athletic and sedentary groups; 72.4% of the athletic group and 81.2% of the sedentary group described their daily mood as “good” ($p = 0.11$). Diagnosed eating disorders were not observed in either group.

The subjects were asked about their sexual activity and chosen method of contraception, and the answers are summarized in Table 4. Interestingly, 11 of 12 sexually active athletes stated they did not use any contraception.

Using a binary logistic regression model, sports activity was used as the dependent variable and BMI, menstrual status, and bone fractures were used as the independent variables. Using this model, the authors found a 25.6% correlation between the dependent and independent variables. This model accurately predicted the outcomes of 41.3% of the athletic group and 96.5% of the sedentary group. Based on the logistic regression analysis, the independent variables (BMI, menstrual status, and bone fractures) were found to be statistically insignificant ($p > 0.05$). This indicated that BMI, menstrual status, and bone fractures did not affect being physically active.

Discussion

This is the first study about FAT and its relationship with gynecologic complaints conducted on young female athletes in the Mediterranean region that also involved control subjects.

Table 4. — Sexually activity and contraception rates of the athletes and sedentary cases.

		Athlete	Sedentary
Sexually active	No	48	50
	Yes	12	2
	Did not want to say	27	33
Contraception	No	11	1
	Yes	1	1
	Did not want to say	27	33

The prevalence of FAT was 1–2% in different studies when three components of FAT were taken into consideration [11, 12]. In the present study, there was no athlete who had all three of the triad components because eating disorders and symptoms with related with low EA did not exist in our study population.

The American Society of Reproductive Medicine Practice Committee defined the age of primary amenorrhea as 15 because menarche occurs at an earlier age [13]. The prevalence of menstrual dysfunction in athletes differs in the literature (6–79%) [14]. The prevalence of amenorrhea varies widely according to sport, age, amount of training, and body weight [15]. Sports activity caused late onset menarche and oligo-amenorrhea in the present athletic group compared to the sedentary group, similar to the findings of Hoch *et al.* and Nichols *et al.* [11, 12]. The prevalence of oligo-amenorrhea was found to be 14.8% in the present study, which was lower than in previous studies (54% and 23.5%, respectively) [11, 12].

Only two of the present subjects had a history of both bone fractures and menstrual disorders (amenorrhea and oligo-menorrhea). Although none of the subjects had diagnosed eating disorders, the BMI of the two subjects mentioned above was 19.81 and 19.05. Hoch *et al.* showed that low BMI is a risk factor for low BMD [11]. Approximately 90% of the peak bone mass acquired before age 20 and bone mineralization is estrogen-dependent. Thus, menstrual irregularities, including oligo- and amenorrhea, are associated with reduced BMD [16, 17]. Feldmann *et al.* showed there is low awareness regarding this relationship among American high school athletes and their coaches [18].

According to the American College of Sports Medicine recommendations, BMD should be assessed after a stress or low-impact fracture and after a total of six months of amenorrhea, oligo-amenorrhea, disordered eating, or an eating disorder [19]. Only two of 14 subjects with oligo-amenorrhea had BMD measured and only three BMD measurements were taken in 21 cases of bone fractures in the present study group. This situation highlighted the lack of information about FAT in Turkey.

Knowledge of FAT is important before commencing nutritional counseling for individuals at risk of FAT or some of its components. The first aim of treatment is to increase

EA and calcium, vitamin D, and vitamin K supplementation [19].

In conclusion, excessive sports activity can be hazardous in young female population. Lower BMI might be related to menstrual irregularity. Young female population should be informed about this relationship, especially athletes who are particularly at risk. Certain precautions should be taken into consideration in this population in order to get benefits of sports activity.

References

- [1] Manore M.M., Kam L.C., Loucks A.B., International Association of Athletics Federations: "The female athlete triad: components, nutrition issues, and health consequences". *J. Sports Sci.*, 2007, 25, 61.
- [2] Otis C.L., Drinkwater B., Johnson M., Loucks A., Wilmore J.: "American College of Sports Medicine Position Stand: The female athlete triad". *Med. Sci. Sports Exerc.*, 1997, 29, 1.
- [3] Joy E., De Souza M.J., Nattiv A., Misra M., Williams N.I., Mallinson R.J., et al.: "2014 female athlete triad coalition consensus statement on treatment and return to play of the female athlete triad". *Curr. Sports Med. Rep.*, 2014, 13, 219.
- [4] Mallinson R.J., De Souza M.J.: "Current perspectives on the etiology and manifestation of the "silent" component of the Female Athlete Triad". *Int. J. Womens Health*, 2014, 6, 451.
- [5] Loucks A.B., Thuma J.R.: "Luteinizing hormone pulsatility is disrupted at a threshold of energy availability in regularly menstruating women". *J. Clin. Endocrinol. Metab.*, 2003, 88, 297.
- [6] Wardle J., Haase A.M., Steptoe A.: "Body image and weight control in young adults: International comparisons in university students from 22 countries". *Int. J. Obes. (Lond.)*, 2006, 30, 644.
- [7] Wade G.N., Schneider J.E., Li H.Y.: "Control of fertility by metabolic cues". *Am. J. Physiol.*, 1996, 270, 1.
- [8] Holehan A.M., Merry B.J.: "The control of puberty in the dietary restricted female rat". *Mech. Ageing Dev.*, 1985, 32, 179.
- [9] McShane T.M., Wise P.M.: "Life-long moderate caloric restriction prolongs reproductive life span in rats without interrupting estrous cyclicity: Effects on the gonadotropin-releasing hormone/luteinizing hormone axis". *Biol. Reprod.*, 1996, 54, 70.
- [10] Barrack M.T., Gibbs J.C., De Souza M.J., Williams N.I., Nichols J.F., Rauh M.J., et al.: "Higher incidence of bone stress injuries with increasing female athlete triad-related risk factors: a prospective multisite study of exercising girls and women". *Am. J. Sports Med.*, 2014, 42, 949.
- [11] Hoch A.Z., Pajewski N.M., Moraski L., Carrera G.F., Wilson C.R., Hoffmann R.G., et al.: "Prevalence of the female athlete triad in high school athletes and sedentary students". *Clin. J. Sport Med.*, 2009, 19, 421.
- [12] Nichols J.F., Rauh M.J., Lawson M.J., Ji M., Barkai H.S.: "Prevalence of the female athlete triad syndrome among high school athletes". *Arch. Pediatr. Adolesc. Med.*, 2006, 160, 137.
- [13] Practice Committee of the American Society for Reproductive Medicine: "Current evaluation of amenorrhea". *Fertil. Steril.*, 2004, 82, 266.
- [14] Loucks A.B.: "Methodological problems in studying the female athlete triad". *Med. Sci. Sports Exerc.*, 2006, 38, 1020.
- [15] Redman L.M., Loucks A.B.: "Menstrual disorders in athletes". *Sports Med.*, 2005, 35, 747.
- [16] Bailey D.A., Martin A.D., McKay H.A., Whiting S., Mirwald R.: "Calcium accretion in girls and boys during puberty: a longitudinal analysis". *J Bone Miner Res.* 2000;15:2245.
- [17] Myerson M., Gutin B., Warren M.P., Wang J., Lichtman S., Pierson R.N. Jr.: "Total body bone density in amenorrheic runners". *Obstet. Gynecol.*, 1992, 79, 973.
- [18] Feldmann J.M., Belsha J.P., Eissa M.A., Middleman A.B.: "Female adolescent athletes' awareness of the connection between menstrual status and bone health". *J. Pediatr. Adolesc. Gynecol.*, 2011, 24, 311.
- [19] Nattiv A., Loucks A.B., Manore M.M., Sanborn C.F., Sundgot-Borgen J., Warren M.P.: "American College of Sports Medicine. American College of Sports Medicine position stand. The female athlete triad". *Med. Sci. Sports Exerc.*, 2007, 39, 1867.

Address reprint requests to:
 P. SOLMAZ HASDEMIR, M.D.
 Celal Bayar University School of Medicine
 Department of Obstetrics & Gynecology
 Manisa 45000 (Turkey)
 e-mail: solmazzydiz@yahoo.com

Case Reports

Cesarean delivery via a transverse uterine fundal incision for the successful management of a low-lying placenta and aplastic anemia

S. Matsuzaki, K. Yoshino, K. Mimura, T. Kanagawa, T. Kimura

Department of Obstetrics and Gynaecology, Osaka University Graduate School of Medicine, Osaka (Japan)

Summary

Purpose: To present a case report on the successful management of a low-lying placenta and aplastic anemia. Aplastic anemia is a rare but serious disorder that is often characterized by severe pancytopenia. Because of the rarity of aplastic anemia, a pregnancy complicated by it is rarely encountered by obstetricians. Moreover, placenta previa (low-lying placenta) complicated by aplastic anemia has not been previously reported. **Materials and methods:** The authors present the first reported case of placenta previa with aplastic anemia in a patient who had undergone a previous cesarean delivery. **Results:** They successfully managed this case by making a transverse uterine fundal incision during an elective cesarean delivery. This incision minimized blood loss and enabled good visualization of the source of bleeding in the lower uterine segment. Bleeding was stemmed by suturing the source of bleeding. **Conclusion:** The authors propose that this procedure should be considered for patients with low platelet counts and abnormal placentation.

Key words: Aplastic anemia; Pancytopenia; Placenta previa; Transverse uterine fundal incision.

Introduction

Aplastic anemia is a blood disorder characterized by blood cell deficiencies caused by failure of bone marrow development. Aplastic anemia is rare with a reported incidence of two to four cases per million people per year [1]. It is considered a high risk in pregnancy because of associated pancytopenia [2]. Placenta previa (including low-lying placenta) is a well-known cause of high-risk pregnancy, particularly in women with a history of a previous cesarean delivery [3]. The incidences of placenta previa and placenta accreta are increasing [3]. Placenta accreta requires cesarean delivery and often results in severe obstetric hemorrhaging; thus, it is associated with higher maternal morbidity. Challenges associated with cesarean delivery techniques possibly contribute to increased maternal blood loss and morbidity. Here the authors report the first case of aplastic anemia complicated by low-lying placenta in a patient who had undergone a previous cesarean delivery. The case was successfully managed by making a transverse uterine fundal incision.

Case Report

A 30-year-old female (gravida 2, para 1) was referred to the present hospital from a private clinic because of pregnancy complicated by aplastic anemia at 11 weeks of gestation. She was di-

agnosed with mild aplastic anemia at 24 years of age. Prior to pregnancy, her laboratory data showed a relatively low white blood cell count of approximately 4,000 cells/ μl , a hemoglobin level of approximately 9.0 g/dl, hematocrit of approximately 25.0%, and a low platelet count of approximately $100 \times 10^3/\mu\text{l}$. Since pancytopenia was mild, no medications were prescribed.

The subject had undergone one previous cesarean delivery because of labor arrest due to cephalopelvic disproportion. She had no complications during the pregnancy or during the labor. However, she suffered post-operative endometritis and required antibiotic therapy (gentamicin and clindamycin) for several days.

The subject's current pregnancy was uneventful except for placenta previa that was revealed by an ultrasound examination at 26 weeks of gestation. The placenta was localized at the anterior uterus, and there were no placental lacunae observed. However, magnetic resonance imaging revealed a focal loss in the zone between the anterior uterine myometrium and placenta; therefore, the patient was considered at risk for potential placenta accreta and associated obstetric hemorrhage (Figure 1A). Fetal growth was appropriate for gestational age.

During pregnancy, her pre-pregnancy laboratory data showed a relatively low white blood cell count of approximately 5,000 cells/ μl , a hemoglobin level of approximately 9.0 g/dl, and a low platelet count of approximately $90 \times 10^3/\mu\text{l}$. A cesarean section was scheduled for the 37th week of gestation. Her preoperative platelet count was $93 \times 10^3/\mu\text{l}$. Given the risk of placenta accreta, the authors decided to avoid an incision into placenta. They considered two techniques for cesarean delivery: (I) a vertical uterine incision and (II) a transverse uterine fundal incision. Since her platelet count

Revised manuscript accepted for publication October 2, 2014

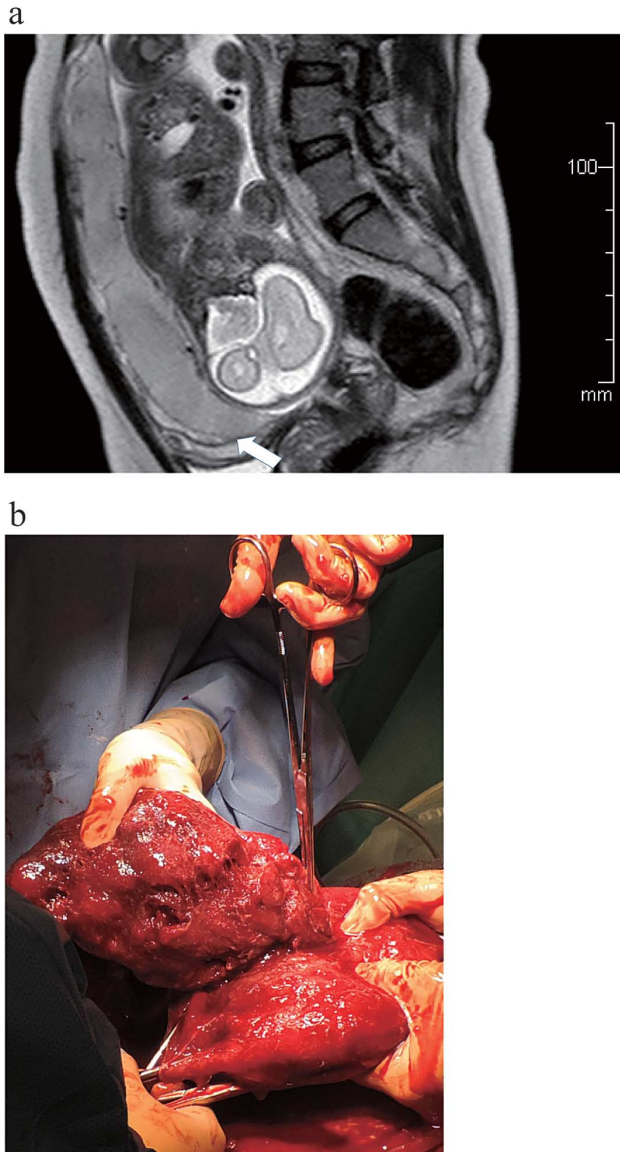


Figure 1. — a) Magnetic resonance imaging was performed at 28 weeks of gestation. The white arrow indicates the focal loss of the zone between the anterior uterine myometrium and the placenta. From these observations, potential placenta accreta is suspected. b) A transverse incision into the uterine fundus is performed. Using this approach, the placenta and minimize bleeding can be avoided. The entire uterine cavity is visualized, thereby enabling to identify the source of the bleeding in the lower uterine segment.

was relatively low, they selected the transverse uterine fundal incision to decrease intraoperative bleeding. After a midline abdominal incision was performed, they made a transverse incision across the uterine fundus to avoid the low-lying placenta in the anterior uterus. The incision caused minimal bleeding, and a healthy female weighing 2,860 g was delivered successfully. The placenta was spontaneously delivered, which indicated no placenta accreta, but bleeding from the lower uterine segment continued. From the fundal incision, the authors could easily observe the entire uterine cavity (Fig-

ure 1B), including the source of bleeding from the lower uterine segment. Consequently, they applied sutures to stop the bleeding. After hemostasis was achieved, the abdomen was closed. The total blood loss was approximately 1,500 ml. After surgery, the patient's blood pressure was 100/60 mmHg, and her pulse rate was 80 beats/min. A hemogram revealed a hematocrit of 31.4%, a hemoglobin level of 10.5 g/dl, and a platelet count of $96 \times 10^3/\mu\text{l}$. The patient had an uncomplicated postoperative course and was discharged on postoperative day 7 in good condition.

Discussion

A pregnancy complicated by aplastic anemia is rare, and only a small number of case reports describing aplastic anemia in pregnancy [2, 4, 5] have been reported. The relationship between aplastic anemia and pregnancy is uncertain, but literature suggests that they are not strongly associated [6]. In the present case, mild pancytopenia was observed before the pregnancy; however, it did not deteriorate during pregnancy.

Placenta accreta is one of the most significant complications of pregnancy because of the risk of heavy obstetric hemorrhage. The incidence of placenta accreta is associated with the number of cesarean deliveries [7]. In addition to multiple cesarean deliveries, placenta previa is one of the most serious risk factors for placenta accreta [3]. In the present patient, in addition to the above complications, aplastic anemia and a relatively low platelet count was observed. A cesarean section can be performed if the platelet count is more than $50 \times 10^3/\mu\text{l}$ [8]. However, in cases of placenta previa, the risk of possible placenta accreta should be considered. In cases of placenta previa and placenta accreta, particularly those with a low platelet count, a transverse incision into the uterine fundus effectively avoids an incision into the placenta and subsequently decreases fetal and maternal blood loss [9-12]. The present authors' methods of uterine transverse fundal incision were previously described [11]. The transverse uterine fundal incision is a useful technique for cesarean sections in patients with placenta previa that covers the entire uterine anterior wall and no major complications have been reported [9-12]. Another useful method to decrease postpartum hemorrhage for placenta previa is the insertion of the Bakri balloon [13, 14]. However, for patients with aplastic anemia characterized by pancytopenia including a low white blood cell count, such as in the present case, the Bakri balloon may cause postoperative infection; thus, a cesarean section with a transverse uterine fundal incision is a better alternative. In addition to these merits, another advantage of this technique is that the operating obstetrician can directly observe the placenta through the surgical wound. The authors could easily observe the entire uterine cavity from the fundal incision and were able to limit the bleeding by suturing the source of bleeding in the uterine cavity. In the present case, the amount of blood loss from the separation site of the placenta was relatively large due to the low platelet count. The authors believe that these points are

particularly important for patients with low platelet counts and possible placenta accreta. However, one drawback of this procedure is the limited data regarding the effect on subsequent pregnancies. Additional studies on patients with aplastic anemia and previous cesarean sections who have further pregnancies are required to determine the efficacy of this procedure on such patients.

Conclusion

In summary, the authors successfully managed this case by performing a transverse incision across the uterine fundus to minimize blood loss. Therefore, this procedure should be considered for patients with a low platelet count and abnormal placentation.

Acknowledgements

The authors thank A. Yagi and K. Sakiyama for their secretarial assistance.

References

- [1] Young N.S.: "Acquired aplastic anemia". *Ann. Intern. Med.*, 2002, 136, 534.
- [2] Shetty A., Anwar S.Q., Acharya S.: "Aplastic anaemia in pregnancy". *J. Obstet. Gynaecol.*, 2011, 31, 77.
- [3] Belfort M.A.: "Placenta accreta". *Am. J. Obstet. Gynecol.*, 2010, 203, 430.
- [4] Ohba T., Yoshimura T., Araki M., Miyoshi J., Yonemura Y., Matsuura K., *et al.*: "Aplastic anemia in pregnancy: treatment with cyclosporine and granulocyte-colony stimulating factor". *Acta. Obstet. Gynecol. Scand.*, 1999, 78, 458.
- [5] Stibbe K.J., Wildschut H.I., Lugtenburg P.J.: "Management of aplastic anemia in a woman during pregnancy: a case report". *J. Med. Case Rep.*, 2011, 5, 66.
- [6] Oosterkamp H.M., Brand A., Kluin-Nelemans J.C., Vandenbroucke J.P.: "Pregnancy and severe aplastic anaemia: causal relation or coincidence?" *Br. J. Haematol.*, 1998, 103, 315.
- [7] Silver R.M., Landon M.B., Rouse D.J., Leveno K.J., Spong C.Y., Thom E.A., *et al.*: "Maternal morbidity associated with multiple repeat cesarean deliveries". *Obstet. Gynecol.*, 2006, 107, 1226.
- [8] Gernsheimer T., James A.H., Stasi R.: "How I treat thrombocytopenia in pregnancy". *Blood*, 2013, 121, 38.
- [9] Shukunami K., Hattori K., Nishijima K., Kotsuji F.: "Transverse fundal uterine incision in a patient with placenta accreta". *J. Matern. Fetal Neonatal Med.*, 2004, 16, 355.
- [10] Kotsuji F., Nishijima K., Kurokawa T., Yoshida Y., Sekiya T., Banzai M., *et al.*: "Transverse uterine fundal incision for placenta praevia with accreta, involving the entire anterior uterine wall: a case series". *BJOG*, 2013, 120, 1144.
- [11] Matsuzaki S., Yoshino K., Kajimoto E., Tanaka Y., Mimura K., Kanagawa T., *et al.*: "Successful management of placenta percreta by cesarean hysterectomy with transverse uterine fundal incision". *Int. J. Reprod. Contracept. Obstet. Gynecol.*, 2014, 3, 447.
- [12] Nishida R., Yamada T., Akaishi R., Kojima T., Ishikawa S., Takeda M., *et al.*: "Usefulness of transverse fundal incision method of cesarean section for women with placentas widely covering the entire anterior uterine wall". *J. Obstet. Gynaecol. Res.*, 2013, 39, 91.
- [13] Kumru P., Demirci O., Erdogdu E., Arisoy R., Ertekin A.A., Tugrul S., *et al.*: "The Bakri balloon for the management of postpartum hemorrhage in cases with placenta previa". *Eur. J. Obstet. Gynecol. Reprod. Biol.*, 2013, 167, 167.
- [14] Kavak S.B., Atilgan R., Demirel I., Celik E., Ilhan R., Sapmaz E.: "Endouterine hemostatic square suture vs. Bakri balloon tamponade for intractable hemorrhage due to complete placenta previa". *J. Perinat. Med.*, 2013, 41, 705.

Address reprint requests to:
S. MATSUZAKI, M.D.
Department of Obstetrics and Gynaecology
Osaka University Graduate School of Medicine
2-2 Yamadaoka, Suita
Osaka 565-0871 (Japan)
e-mail: zacky@gyne.med.osaka-u.ac.jp

Ganglioneuroblastoma during pregnancy – A rare case report

M.A. Moga¹, A. Daniilidis², N.F. Bigiu³, C. Andrei⁴, K. Dinas⁵, D.G. Festila⁶

¹Obstetrics and Gynecology, Transilvania University of Brasov, Brasov (Romania)

²Obstetrics and Gynecology, Hippokratia General Hospital, Aristotle University of Thessaloniki, Thessaloniki (Greece)

³Transilvania University of Brasov, Brasov (Romania)⁴ “Dr. I. A. Sbarcea” Clinical Obstetrics and Gynaecology Hospital, Brasov (Romania)

⁵Hippokratia General Hospital, Aristotle University of Thessaloniki, Thessaloniki (Greece); ⁶University of Medicine and Pharmacy Iuliu Hatieganu, Faculty of Dental Medicine, Maxillo-Facial Surgery and Radiology Department, Cluj-Napoca (Romania)

Summary

Purpose: To report a rare case of ganglioneuroblastoma encountered rarely in adults, especially during pregnancy. **Materials and Methods:** The authors present a case of ganglioneuroblastoma relapse during the third trimester of pregnancy in a patient previously treated for ganglioneuroblastoma who had a eight-year disease-free interval. Late manifestation of neurological symptoms (vestibular syndrome, nystagmus, slightly right motor deficit) was perhaps influenced by the hormonal pregnancy effects. In this case the option was for caesarean section under general anesthesia at 36 weeks. **Results:** Based on MRI result, the neurosurgical consultation stated the need of postpartum brain tumor excision. Recovery of the mother was complication-free with persistent, constant postoperative neurological symptoms. It resulted in a healthy newborn, not requiring special follow-up. **Conclusions:** Pregnancy and brain tumor have mutual negative effect on the patient. Therapeutic management in this case was a medical dilemma regarding mode setting and timing of delivery, taking into account the maternal-fetal risk-benefit.

Key words: Ganglioneuroblastoma; Pregnancy; MRI; Caesarian section.

Introduction

Ganglioneuroblastoma is a neuroblastic tumor containing malignant elements characteristic to neuroblastoma and benign elements found in ganglioneurinoma [1].

Intracranial tumors are extremely rare in pregnancy [2]. By their rarity and their diagnosis in the last trimester of pregnancy, intracranial tumors have an increased risk of maternal and fetal morbidity and mortality. Cranial tumors tend to increase and become symptomatic in the last trimester of pregnancy, while the exact causes are not entirely known [3]. Management of these cases should evaluate whether the mother's and the fetus' well-being are jeopardized. A multidisciplinary team will recommend the optimal time for delivery, as determined by the fetal lung maturity and mother's neurological condition [4].

The authors present a rare case of a 36-week pregnant woman with recurrence of ganglioneuroblastoma, eight years after complete surgical removal. The patient underwent caesarean section under general anesthesia with favorable postoperative outcome. So far, there are no well-established protocols regarding the management of intracranial tumors (especially ganglioneuroblastoma) in pregnant women.

Materials and Methods

Case report

A para 1, 20-year-old woman, was admitted to the present hospital due to irregular uterine contractions and vague neurological symptoms (vestibular syndrome, nystagmus, slightly right motor deficit), in her 36th week of gestation. Eight years earlier, in 2005, she was diagnosed with right parietal lobe ganglioneuroblastoma. She underwent complete surgical removal of the tumor, followed by radiochemotherapy and anticonvulsive therapy with phenytoin for about one year postoperative;y. Six years following treatment, the patient had no radiologic recurrence.

During her current pregnancy she had a routine follow up by her obstetrician. Pregnancy until the 36th week was uneventful and had no neurological symptoms until that point. She underwent the first trimester nuchal translucency ultrasound and the detailed second trimester ultrasound investigations, which were normal. On admission she went through MRI and interdisciplinary consultation by neurologists and neurosurgeons, who established the diagnosis of brain tumor, as a possible relapse of former pathology. Neurological examination revealed vestibular syndrome and nystagmus. Contrast MRI identified in the right parietal lobe, postcentral, a well-shaped image of 32-mm in diameter, nongadolinium-enhanced, sequel-looking (Figure 1). An area of edema with irregular outline in white matter was surrounding it. In the right temporal lobe, adjacent to the sylvian seizure, in hyposignal T2 image showed a nodular-shaped tumor of about seven-mm in diameter with discrete central heterogeneity (gadolinium-enhanced). There was no perilesional oedema. Ventricular system was located in the midline. MRI based neurosurgical consultation determined that the tumor was operable and stated the need of postpartum surgery (excision of the brain tumor). Preoperative the patient received corti-

Revised manuscript accepted for publication October 2, 2014

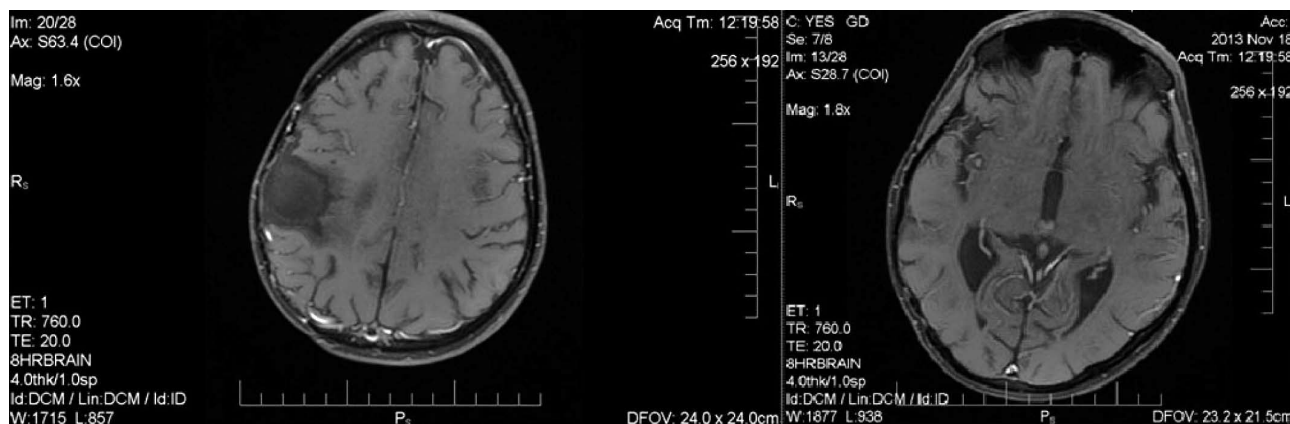


Figure 1. — MRI of recurrent neuroblastoma.

steroid therapy (betamethasone) within 48 hours for fetal lung maturation and perilesional brain edema control.

Results

An emergency caesarean was performed under general anesthesia five days after admission, with no intraoperative or postoperative complications. A live female infant of 2,670 grams with a 9 Apgar score was delivered. Fetal lung maturity was achieved by administration of betamethasone. Post-section fetal recovery was uneventful. Postoperatively the mother had persistent, constant neurological symptoms. When discharged home, the patient was recommended ambulatory neurosurgical exam in order to establish the opportunity of surgery targeting the brain tumor.

Discussion

Ganglioneuroblastoma is a tumor of the sympathetic nervous system that arises from primitive sympathogonia and is composed of both mature gangliocytes and immature neuroblasts and has intermediate malignant potential [5]. These tumors are rare. They occur in fewer than five out of one million children each year [6]. Ganglioneuroblastomas are extremely rare in adults, with only about 50 cases documented in people over the age of 20, and only five cases observed in the adult brain [7]. According to the present authors' knowledge, there are no reports in the literature of ganglioneuroblastoma presenting during pregnancy [8].

Objectification of brain tumor by contrast MRI was necessary to establish the subsequent therapeutic management, although in literature there are not enough studies to determine the safe use of contrast in pregnancy [9]. MRI is probably the imaging diagnostic procedure of choice and should be performed when a brain tumor is suspected [10].

Before pregnancy the patient was declared cured, as there was no clinical nor radiological tumor relapse in

eight years. It is not well-established whether pregnancy-induced changes have any kind of tumorigenic effect, or if it is just a coincidence. There might be a relationship between pregnancy hormones and the rate of brain tumor growth mediated through specific intracellular receptors [11]. Pregnancy is an aggravating factor for brain tumours, on which it acts via three mechanisms: acceleration of tumor growth, increase of peritumoral edema, and the immunotolerance to foreign tissue antigens [12]. Normal physiological changes during the pregnancy, such as increased levels of gonadotropins and augmented fluid volume status may accelerate the growth of some types of brain tumors [13].

Intrauterine growth restriction (IUGR) and oligohydramnios is associated with a higher rate of pregnancy complications and increased fetal morbidity and mortality, and thus, delivery should be considered [14]. Treatment of brain tumor in pregnancy requires an integrated multidisciplinary approach, which includes neurosurgeons, ophthalmologists, radiologists, obstetricians, and neonatologists [15].

Indications about the mode of delivery are controversial. The optimal timing to recommend craniotomy and neurosurgical removal of the tumor will depend on the mother's neurological condition, the histological tumor type, as well as on the gestational age. In a study published in 2011, ten patients with brain tumors were diagnosed during pregnancy, prior to craniotomy, five patients had caesarean sections, two had vaginal deliveries, and in three patients, the delivery took place after the brain tumor was removed [16].

In the present case a caesarean section was performed under general anesthesia. General anesthesia is safe and dependable for operative delivery in pregnant women with intracranial tumor. Tracheal intubation allows maternal hyperventilation thereby controlling raised intracranial pressure. Hemodynamic stability is readily achieved to maintain cerebral perfusion [17].

Conclusion

It is not clear if tumor relapse was influenced by the metabolic and hormonal changes induced by pregnancy. The proper management of pregnant women with brain tumors requires an integrated multidisciplinary approach, in order to assess all maternal-fetal risks and benefits.

References

- [1] Robertson H.E.: "Das Ganglioneuroblastom ein besonderer Typus im System der Neurome". *Virchows Arch. [Pathol. Anat.]*, 1915, 63, 147.
- [2] Pavlidis N.A.: "Coexistence of pregnancy and malignancy". *The Oncologist*, 2002, 7, 279.
- [3] Armon C., Berman S.A.: "Neurologic disease and pregnancy". *Medscape reference*, 8 nov 2012. Available at: <http://emedicine.medscape.com/article/1149405-overview#aw2aab6b4>
- [4] Wu J., Ma Y.H., Wang T.L.: "Glioma in the third trimester of pregnancy: Two cases and a review of the literature". *Oncol. Lett.*, 2013, 5, 943.
- [5] Lonergan G.J., Schwab C.M., Suarez E.S., Carlson C.L.: "Neuroblastoma, ganglioneuroblastoma, and ganglioneuroma: radiologic-pathologic correlation". *Radiographics*, 2002, 22, 911.
- [6] Vorvick L.J., Chen Y.B.: "Ganglioneuroblastoma". *A.D.A.M. Medical Encyclopedia*, Feb 7, 2012. Available at: <http://www.ncbi.nlm.nih.gov/pubmedhealth/PMH0002408/>
- [7] Schipper M.H., van Duinen S.G., Taphoorn M.J., Kloet A., Walchenbach R., Wiggenraad R.G., Vecht C.J.: "Cerebral ganglioneuroblastoma of adult onset: two patients and a review of the literature". *Clin. Neurol. Neurosurg.*, 2012, 114, 529.
- [8] Chen B.F., Manjusha R., Al-Samarai S., Rajeswary J.: "First reported case of ganglioneuroblastoma in pregnancy and a review of the literature". *Obstet. Med.*, 2014, 7, 128
- [9] Black P., Morokoff A., Zauberman J., Claus E., Carroll R.: "Meningiomas: science and surgery". *Clin. Neurosurg.*, 2007, 54, 91.
- [10] Awada A., Watson T., Obeid T.: "Cavernous angioma presenting as pregnancy-related seizures". *Epilepsia*, 1997, 38, 844.
- [11] Isla A., Alvarez F., Gonzalez A., García-Grande A., Perez-Alvarez M., García-Blazquez M.: "Brain tumor and pregnancy". *Obstet. Gynecol.*, 1997, 89, 19.
- [12] Depret-Mosser S., Jomin M., Monnier J.C., Vinatier D., Bouthors-Ducloy A.S., Christiaens J.L., Krivosic-Horber R.: "Cerebral tumors and pregnancy. Apropos of 8 cases". *J. Gynecol. Obstet. Biol. Reprod.*, 1993, 22, 71.
- [13] Poisson M., Pertuiset B.F., Hauw J.J., Philippon J., Buge A., Moguilewsky M., et al.: "Steroid hormone receptors in human meningiomas, gliomas and brain metastases". *J. Neurooncol.*, 1983, 1, 179.
- [14] Golan A., Lin G., Evron S., Arieli S., Niv D., David M.P.: "Oligohydramnios: maternal complications and fetal outcome in 145 cases". *Gynecol. Obstet. Invest.*, 1994, 37, 91.
- [15] Khalil E. Rajab and Nouf Behzad N.: "Brain Tumor in Pregnancy". *Bahrain Medical Bulletin*, Mar 2013, 35. Available at: http://www.bahrainmedicalbulletin.com/march_2013/Brain-Tumour.pdf
- [16] Lynch J.C., Gouvêa F., Emmerich J.C., Kokinovrachos G., Pereira C., Welling L., Kislakov S.: "Management strategy for brain tumour diagnosed during pregnancy". *Br. J. Neurosurg.*, 2011, 25, 225.
- [17] Chang L., Looi-Lyons L., Bartosik L., Tindal S.: "Anesthesia for cesarean section in two patients with brain tumours". *Canadian Journal of Anesthesia*, 1999, 46, 61.

Address reprint requests to:
 B. NICUSOR-FLORIN, M.D.
 Faculty of Medicine
 Nicolae Balcescu Str., Nr. 56,
 500019 Brasov (Romania)
 e-mail: nicusorbigiu@yahoo.com

Umbilical intra-abdominal vein varix: a case report and review of the literature

**G. Viridis¹, A. Gulotta¹, C. Cherchi², G. Spanedda², M.G. Olzai², G. Ambrosini³,
S. Dessole¹, G. Capobianco¹**

¹ *Gynecologic and Obstetric Clinic, Department of Surgical, Microsurgical and Medical Sciences. University of Sassari, Sassari*

² *Neonatal Intensive Care Unit (NICU), University of Sassari, Sassari;* ³ *Gynecologic and Obstetric Clinic, University of Padua, Padua (Italy)*

Summary

Fetal umbilical intra-abdominal vein varix (FIUV) is a rare congenital malformation characterized by focal dilatation of the umbilical vein. The authors report a case of pregnant woman at 32 weeks of gestation with a fetus affected by dilatation of an intra-abdominal portion of the umbilical vein. They performed continuous ultrasound and cardiotocographic monitoring, from admission to the delivery. They describe the case and perform a review of the literature.

Key words: Umbilical vein varix; Three dimensional (3D) sonography; Fetal vascular anomalies.

Introduction

The fetal intra-abdominal umbilical vein varix (FIUV) is a rare condition characterized by focal dilatation of the umbilical vein of the fetus with a diameter which is at least 50% wider than the adjacent umbilical vein diameter, or an intra-abdominal umbilical vein segment dilated to \geq nine mm [1, 2]. Some authors have defined FIUV as a measurement that is more than two standard deviations above the mean for gestational age [3-5]. It is believed that the dilatation of the umbilical vein may result from a structural failure of the vessel's wall, given by a congenital weakness or by a progressive parietal thinning.

The first description of a FIUV varix [6] reported the presence of varicose segment to be a high risk of neonatal mortality. In the last 30 years approximately, 150 cases of isolated FIUV varices have been described [7]; as a result of that, the neonatal prognosis was found to be substantially better than that reported in older studies [8]. The neonatal outcome is favorable if the finding is isolated and there are no associated morphological anomalies [9, 10], and if it is excluded the presence of a thrombus.

In case of FIUV varix, the fetal morphological anomalies, most commonly encountered with the support of ultrasound examination, are: cardiac anomalies, fetal hydrops, fetal anemia-related anomalies, anomalies of the umbilical vessels, and intrauterine growth restriction (IUGR) [8, 11, 12].

In this report, the authors present a case of a FIUV varix not associated with ultrasound morphological anomalies, or intra-aneurismal thrombosis.

Case Report

A healthy 37-year-old woman, was referred to the present Department at 32 weeks and 0 days of pregnancy, for a second level ultrasound examination. The patient was a primipara, non-smoker, and with no history of haemostasis disorders.

The combined test showed a risk of 1: 7453 of trisomies. Due to more mature age, the patient underwent amniocentesis that revealed a normal karyotype 46, XX female. The patient was treated with corticosteroids, in order to induce fetal lung maturity.

The two-dimensional ultrasound images revealed the presence of a vascular formation, anechoic cystic mass measuring 19.9 x 20.2 mm with laminar flow (not turbulent), suggestive of varicosities of the umbilical vein in the intra-abdominal extra hepatic portion (Figure 1). The dilatation was studied by three dimensions reconstruction (3D) (Figure 2).

The umbilical artery Doppler velocimetry showed a P.I. of 0.9 (normal). No appreciable ultrasound morphological anomalies in various anatomical regions were detected. The amniotic fluid index (AFI) was always regular in all the consecutive ultrasound measurements. The patient was subjected to ultrasound and color Doppler evaluation every 48 hours and to a cardiotocographic assessment twice a day. Cardiac malformations and wall motion abnormalities, with color-Doppler fetal echocardiogram, were excluded. The assessment of the peak systolic velocity of the middle cerebral artery (PSV-MCA) showed a value of 90 cm / second (mild anemia). However, there were no ultrasound indirect signs of fetal anemia such as hydrops, pericardial effusion or ascites. Then, the authors performed emergency caesarean section, for a non-reassuring cardiotocography, at 34 weeks and four days of gestational age.

A live female newborn, weighing 2,080 grams (55° percentile), length 44 cm (51° percentile), head circumference 315 mm (68° percentile), with a round of umbilical cord around the neck, with 7 Apgar score at the first minute was delivered. A 580-gram placenta, with velamentous cord insertion (cord length of 45 cm), underwent histological examination: an amount of focal ischemic

Revised manuscript accepted for publication July 6, 2015

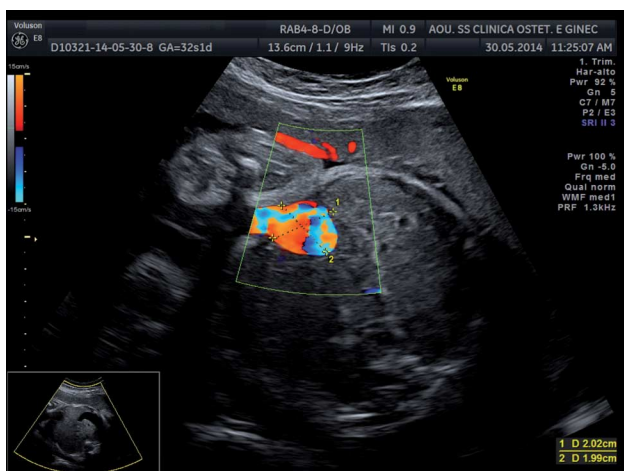


Figure 1. — Vascular, anechoic cystic mass measuring 19.9 x 20.2 mm with laminar flow (not turbulent), of the umbilical vein in the intra-abdominal extra hepatic portion.

infarction areas were discovered, as well as multiple intervillous fibrin deposits. In correspondence of the varix, pathologic examination showed marked perivascular extravasation erythrocyte, but no thrombosis was detected.

Immediately after birth, neonatologists observed a respiratory distress, associated with costal retractions, which resolved spontaneously within two hours after birth without the need of respiratory support and oxygen administration. At admission, in neonatal intensive care unit (NICU), the newborn reported severe anemia (Hb 5.7 g / dl, Ht 16.3%), with modest reticulocytosis, leading to blood transfusion in the first day of extra uterine life.

In the first hours of life, a sub-ependymal bilateral bleeding spontaneously resolved, without jaundice (total bilirubin 1.5 mg/dl) and with a normal coagulation profile. Hematologic consultation excluded the presence of hemoglobinopathies because of a severe anemia. The dosage of fetal hemoglobin and direct Coombs test, on neonatal blood, resulted within normal value. Chest x-ray, abdomen-pelvis ultrasound and echocardiogram, were within normal range.

Discussion

The finding of a FIUV varix is an unusual case. In recent years the importance of this finding is increased [2, 13]. The reason is related to an improvement of the ultrasound equipment, and a more mature awareness of the sonographer towards this case.

In case of a dilated intra-abdominal umbilical vein, it should be necessary to perform a detailed morphological evaluation of the fetus, verifying the absence of major malformations, soft markers, cardiac anomalies. The ultrasound monitoring is always necessary for the surveillance of all the cases in which there is anemia or fetal distress [14].

An analysis of the cases in the literature highlights that is necessary to verify the absence of a thrombus in the dilated segment of the umbilical cord, which in turn blocks the fetal venous circulation and causes sudden fetal death; it is mandatory to evaluate by fetal echocardiography indirect signs of cardiac failure such as hydrops, edema, and pericardial effusion [15, 16].

Evaluation of the flow within the dilated tract, as turbulent flow, rather than laminar, poses a greater risk of premature birth and small for gestational age fetus (SGA) [10].

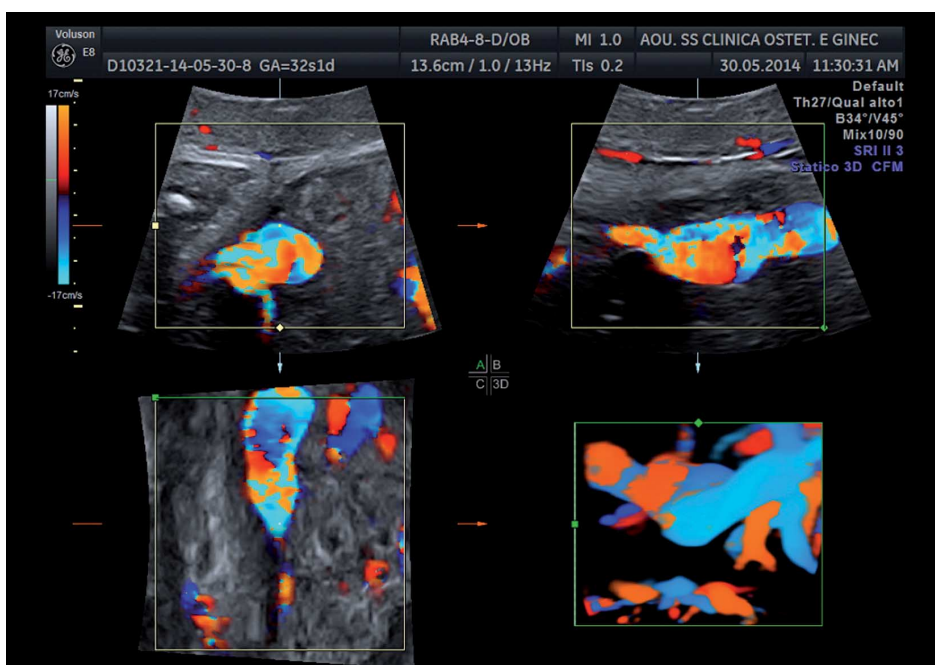


Figure 2. — 3D reconstruction of intra-abdominal umbilical vein varix.

In cases of doubt, color Doppler has been used successfully to distinguish these anomalies from other pathologies, such as duplication cysts, mesenteric, hepatic, choledochal and urachal cysts, and other cystic lesions originating from the cord [14]. In order to exclude the presence of chromosomal abnormalities it is indicated to complete the diagnostic process of the patient with karyotyping.

There is not yet an unanimous obstetrician clinical protocol, especially if the varicose vein is diagnosed early (about 22 weeks). In the present Clinic the authors monitored the pregnancy with ultrasound and color Doppler every 48 hours, and with an cardiocotographic assessment twice a day.

According to the present authors' experience, and the evidence in the literature, there are no contraindications for vaginal delivery, unless occurring complications that require the performance of cesarean section. As demonstrated by Mankuta *et al.* [3], if the FIUV varix is as an isolated anomaly, the management of these pregnancies, should not be aggressive as in the past, inducing labor at 36 weeks instead of 34 as was done previously.

References

- [1] Ahmadi F., Vosough Taghi Dizaj A., Irani BSc. Sh.: "Prenatal Diagnosis of fetal umbilical vein varix in an intracytoplasmic sperm injection conception: A Case Report". *Iran J. Radiol.*, 2007, 4, 117.
- [2] Bertocchini A., Falappa P., D'Ambrosio G., Monti L., Grimaldi C., Del Prete L., *et al.*: "Prehepatic portal hypertension with aneurysm of the portal vein: Unusual but treatable malformative pattern". *J. Pediatr. Surg.*, 2014, 49, 436.
- [3] Mankuta D., Nadjari M., Pomp G.: "Isolated fetal intra-abdominal umbilical vein varix. Clinical importance and recommendations". *J. Ultrasound Med.*, 2011, 30, 273.
- [4] Ipek A., Kurt A., Tosun O., Gümüř M., Yaziciođlu KR, Ařık E, *et al.*: "Prenatal diagnosis of fetal intra-abdominal umbilical vein varix: report of 2 cases". *J. Clin. Ultrasound*, 2008, 36, 48.
- [5] Yagel S., Kivilevitch Z., Cohen S.M., Valsky D.V., Messing B., Shen O., *et al.*: "The fetal venous system, part II: ultrasound evaluation of the fetus with congenital venous system malformation or developing circulatory compromise". *Ultrasound Obstet. Gynecol.*, 2010, 36, 93.
- [6] Fuster J.S., Benasco C., Saad I.: "Giant dilatation of the umbilical vein". *J. Clin. Ultrasound*, 1985, 13, 363.
- [7] Turner K.C., Bohannon W.T., Atkins M.D.: "Portal vein aneurysm: a rare occurrence". *J. Vasc. Nurs.*, 2011, 29, 135.
- [8] Fung T.Y., Leung T.N., Leung T.Y., Lau T.K.: "Fetal intra-abdominal umbilical vein varix: what is the clinical significance?". *Ultrasound Obstet. Gynecol.*, 2005, 25, 149.
- [9] Byers B.D., Goharkhay N., Mateo J., Ward K.K., Munn MB, Wen TS.: "Pregnancy outcome after ultrasound diagnosis of fetal intra-abdominal umbilical vein varix". *Ultrasound Obstet. Gynecol.*, 2009, 33, 282.
- [10] Weissmann-Brenner A., Simchen M.J., Moran O., Kassif E., Achiron R., Zalel Y.: "Isolated fetal umbilical vein varix: prenatal sonographic diagnosis and suggested management". *Prenat. Diagn.*, 2009, 29, 229.
- [11] Valsky D.V., Rosenak D., Hochner-Celnikier D., Porat S., Yagel S.: "Adverse outcome of isolated fetal intra-abdominal umbilical vein varix despite close monitoring". *Prenat. Diagn.*, 2004, 24, 451.
- [12] Rahemtullah A., Lieberman E., Benson C., Norton M.E.: "Outcome of pregnancy after prenatal diagnosis of umbilical vein varix". *J. Ultrasound Med.*, 2001, 20, 135.
- [13] Lu M., Kakani N., Romagnoli C., Yue L., Xiong W., An S., *et al.*: "Two- and three-dimensional sonographic diagnosis of fetal intra-abdominal umbilical vein varix: a case report". *J. Clin. Ultrasound*, 2012, 40, 586.
- [14] Akar M., Dilli D., Sandal G., Öncel MY, Erdeve Ö, Dilmen U.: "Prenatally Diagnosed Umbilical Vein Aneurysm with Good Prognosis". *J. Clin. Ultrasound*, 2012, 40, 368.
- [15] Zalel Y., Lehavi O., Heifetz S., Azeinstein O., Dolitzki M., Lipitz S., *et al.*: "Varix of the fetal intra-abdominal umbilical vein: prenatal sonographic diagnosis and suggested in utero management". *Ultrasound Obstet. Gynecol.*, 2000, 16, 476.
- [16] Viora E., Sciarone A., Bastonero S., Errante G., Campogrande M.: "Thrombosis of umbilical vein varix". *Ultrasound Obstet. Gynecol.*, 2002, 19, 212.

Address reprint requests to:
G. CAPOBIANCO, M.D., Ph.D.
Gynecologic and Obstetric Clinic
Sassari University, Department of Surgical
Microsurgical and Medical Sciences
Viale San Pietro 12, 07100 Sassari (Italy)
e-mail: capobsass@tiscali.it

Rectovaginal fistula caused by retained colpotomy cup after surgery

Y.S. Kwon¹, S. Ki You¹, K. Shil Im², A. Suk Kim³

¹ Department of Obstetrics and Gynecology, College of Medicine, University of Ulsan, Ulsan University Hospital, Ulsan

² Department of Anesthesiology and Pain Medicine, Uijeongbu St Mary's Hospital, College of Medicine, Catholic University of Korea, Seoul

³ Department of Anesthesiology and Pain Medicine, College of Medicine, University of Ulsan, Ulsan University Hospital, Ulsan (Korea)

Summary

Colpotomizer instruments are commonly used in laparoscopic hysterectomy to easily manipulate the uterus. This is the case of a forgotten colpotomy cup retained in the vagina for five years, which led to a rectovaginal fistula. A 54-year-old woman without knowledge of presence of the foreign body visited with chronic abdominal pain and foul odorous discharge. Rectovaginal fistula caused by the retained forgotten colpotomy cup was found upon examination.

Key words: Colpotomy cup; Rectovaginal fistula.

Introduction

Rectovaginal fistulas are a relatively common obstetric complication and are related cancer therapeutic irradiation. However, few cases of foreign body related rectovaginal fistula have been reported [1-4] in which rectovaginal fistula was caused mainly by lack of diligence by the physician.

Colpotomizer laparoscopic hysterectomies have become more common in gynecological surgery. However, there was a very extremely rare case, in which colpotomy cup, a part of colpotomizer, was forgotten and retained in the vagina, and the patient discharged. She was unaware of the mishap for five years, despite chronic foul odorous vaginal discharge. Here the authors report an unusual case of rectovaginal fistula caused by the retained colpotomy cup.

Case Report

A 54-year-old woman visited the present Department of Obstetrics and Gynecology complaining of chronic abdominal pain for several years. The patient had an unusual gynecologic history and was undergoing a total laparoscopic hysterectomy (TLH) for diffuse uterine adenomyosis with severe menorrhagia at local hospital. However, upon insertion of laparoscope, severe intestinal and omental adhesions to the uterus were found, so the operator stopped the surgical treatment. Almost all the cases of TLH in that hospital were performed using a colpotomizer.

The surgeon informed the patient of the failed TLH, she was then discharged, and did not take any further clinical examinations for the diffuse uterine adenomyosis, choosing to wait for menopause and to take pain killing measures.

The patient went through the menopause about one year after TLH attempt, and did not partake in sexual intercourse. For five

years, she had chronic symptoms, which included: a foul odorous vaginal discharge, lower abdominal discomfort, and vaginal contamination of feces upon defecation with mild to moderate severity. Recently, the symptoms were aggravated and the patient decided to attempt treatment, and thus visited the present department.

In the lithotomy position, inspection of vagina showed the presence of a foreign body contaminated with fecal material. The patient was admitted for further evaluation, and a colonoscopy (Figure 1) and abdomino-pelvic computed tomography (APCT)

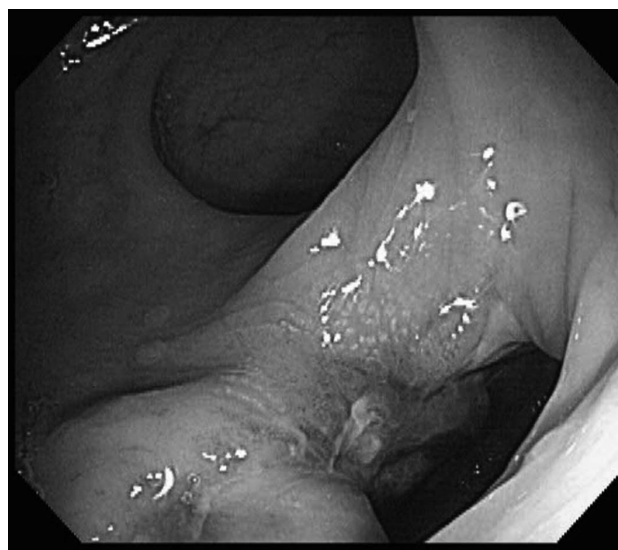

Figure 1. — A 3.0-cm sized large rectovaginal fistula at ten cm from the anal verge on colonoscopy can be seen.

Revised manuscript accepted for publication October 2, 2014

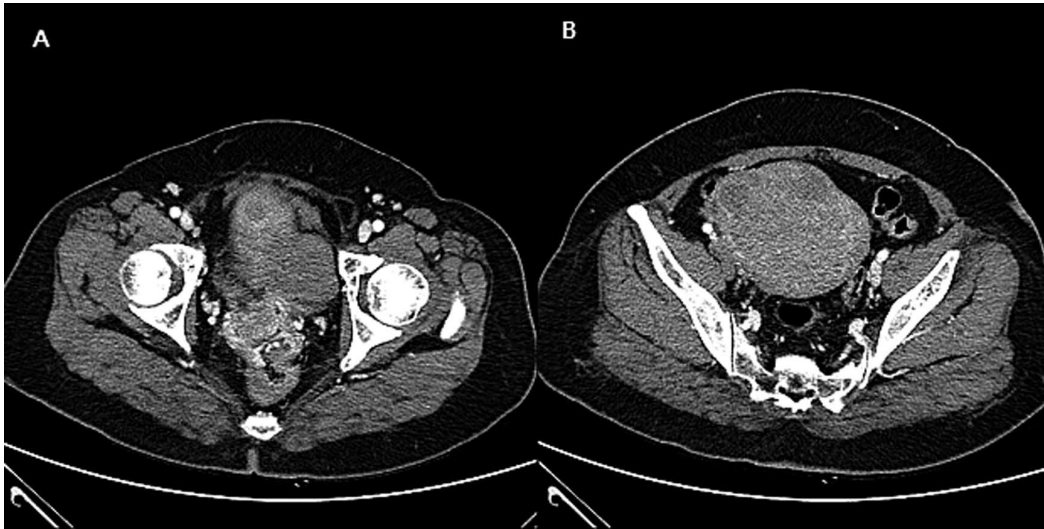


Figure 2. — A 4.0 x 3.5-cm opaque apparatus foreign body in vagina with gross perforation in vaginal wall and anterior rectal wall; chronic fistulous tract formation by posterior tip of foreign body. A circa five-cm subserosal myomas in uterine corpus (A). Smooth moderate enlargement of uterine corpus; ill-defined diffuse thickening of myometrium; adenomyosis suggested (B).

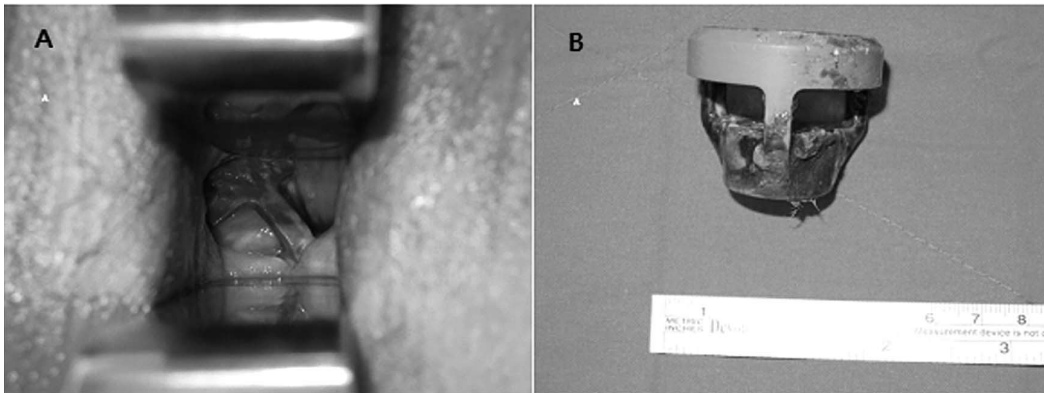


Figure 3. — The colpotomy cup is located in the upper vagina of the patient contaminated with feces (A). The foreign body is expelled (B).

(Figure 2) were performed. A diagnosis of rectovaginal fistula caused by a retained colpotomy cup was made, and surgical treatment was planned.

The retained colpotomy cup was removed transvaginally under general anesthesia (Figure 3), before the main operation, which was a total abdominal hysterectomy with bilateral salpingo-oophorectomy, fistulectomy with primary repair, and ileostomy. The patient was discharged 16 days after the operation without any major complications, and a take-down ileostomy was planned at three months later.

Discussion

Rectovaginal fistula caused by a foreign body in the vagina has been rarely reported. The retained foreign bodies in the vagina are usually non-surgical instruments. However, in this case the foreign body was a colpotomy cup, and is the first report of rectovaginal fistula caused by colpotomy cup in the literature.

In gynecologic surgery, colpotomizer is often used efficiently for laparoscopic surgery with easy manipulation of uterus, especially in TLH. There are several steps to pre-

vent colpotomizer instruments being left behind, these include: expulsion of the uterus through vagina together with the used colpotomizer in TLH, and counting all the surgical instruments before and after operation at least twice, and finally a vaginal inspection; dressings should then be performed by the operator at the in-patient and out-patient base follow-up. In this case, because TLH was completed due to pelvic adhesion, expulsion of the uterus did not occur; this is why the usual removal of colpotomizer and counting of instruments were not performed by the operating team. The patient, then did not take the routine out-patient follow up. Moreover, women in the menopause often opt not to be sexually active, therefore there is less chance for discovery of the foreign body in the vagina by her sexual partner.

A rectovaginal fistula must be surgically managed with underlying uterine adenomyosis combined pelvic adhesion. Before the operation, controlling of chronic inflammation with elevated C-reactive protein (CRP) with antibiotics for seven days, and cleaning of vagina and rectosigmoid were

performed to make the operation safe and protect from postoperative wound complication, such as dehiscence of the sutured wound.

The present authors report a rare case of rectovaginal fistula caused by a colpotomy cup left behind, with the main cause being negligence. Also, it is important to carefully follow up a patient after any form of surgery, in this case immediate discovery of the foreign body by either the patient or medical team would have protected from postoperative complication, especially, rectovaginal fistula as in the present case.

References

- [1] Anderson PG., Anderson M.: "An unusual cause of rectovaginal fistula". *Aust. N. Z. J. Surg.*, 1993, 63, 148.
- [2] Meniru GI., Moore J., Thomlinson J.: "Aerosol cap and rectovaginal fistula: unusual findings at routine cervical smear". *Int. J. Gynecol. Obstet.*, 1996, 52, 179.
- [3] Carey R., Healy C., Elder DE.: "Foreign body sexual assault complicated by rectovaginal fistula". *J. Forensic Leg. Med.*, 2010, 17, 161.
- [4] Hanavadi S., Durham-Hall A., Oke T., Aston N.: "Forgotten vaginal pessary eroding into rectum". *Ann. R. Coll. Surg. Engl.*, 2004, 86, W18.

Address reprint requests to:

K.SHIL IM, M.D.

Department of Anesthesiology and Pain Medicine
Uijeongbu St Mary's Hospital College of Medicine

The Catholic University of Korea

271 Cheonbo-ro, Uijeongbu-si

Gyeonggi-do 480-717 (Korea)

e-mail: idonga@catholic.ac.kr

Peripartum cardiomyopathy: a case of patient with triplet pregnancy

B. Kastratović Kotlica¹, A. Četković², S. Plešinac¹, Đ. Macut³, M. Ašanin⁴

¹ Clinic of Gynecology and Obstetrics, Clinical Center of Serbia, School of Medicine, University of Belgrade

² Clinic of Gynecology and Obstetrics, Clinical Center of Serbia, Belgrade; ³ Clinic for Endocrinology, Diabetes and Metabolic Disorders, Clinical Center of Serbia, School of Medicine, University of Belgrade, Belgrade

⁴ Cardiology Clinic, Clinical Center of Serbia, School of Medicine, University of Belgrade, Belgrade (Serbia)

Summary

Peripartum cardiomyopathy (PPCM) is a rare but potentially devastating complication of pregnancy associated with heart failure due to left ventricular systolic dysfunction occurring within the last month of pregnancy and five month postpartum with no obvious other cause of heart failure and no pre-existing heart disease. In the present case report the authors present a woman who developed PPCM on the day after she delivered by cesarean section in 35th weeks of gestation of triplet pregnancy conceived after ovarian stimulation and insemination. A treatment with diuretics, ACE inhibitors, antiarrhythmics, low weight heparin, antibiotics and bromocriptine was applied and resulted in complete recovery. In conclusion, timely detection and initiation of treatment are important factors for complete recovery of patients with PPCM.

Key words: Heart failure; Peripartum cardiomyopathy; Infertility treatment.

Introduction

Peripartum cardiomyopathy (PPCM) is a rare but potentially devastating complication of pregnancy associated with heart failure due to left ventricular systolic dysfunction occurring within the last month of pregnancy and five month postpartum with no obvious other cause of heart failure and no pre-existing heart disease [1]. Classical symptoms of this condition, such as worsening dyspnea or ankle swelling, are often attributed to the hemodynamic stress of pregnancy, which frequently lead to delay in the diagnosis of PPCM [1]. There are several predictors of unfavorable outcome that include increasing maternal age, multiple pregnancies, history of hypertension, late onset of symptoms following delivery, non-Caucasian origin, and delayed diagnosis [2].

Despite significant improvements in the management of heart failure, the morbidity and mortality related to this condition remain significant, with mortality rates of between 9% and 32%, and cardiac transplantation required in up to 10% of survivors [3, 4].

Case Report

A 33-year-old woman with polycystic ovarian syndrome and infertility was successfully treated with clomiphene citrate. She had undergone intrauterine insemination “swim up” and triple pregnancy was conceived. Because of uterine contractions, she received intravenous tocolytic therapy for two days during sec-

ond and progesterone vaginally 200 mg twice daily, during third trimester of pregnancy. Her blood pressure was normal during each hospitalization and she had no signs or history of previous cardiovascular disease. The patient delivered by cesarean section in 35th weeks of gestation with three healthy newborns with following measures: male 1,800 g/Apgar score 5/7, male 2,100 g/Apgar score 5/6, and female 1,730 g/Apgar score 4/5. One day after delivery patient developed symptoms of cardiovascular and respiratory dysfunction with neurological symptoms presenting in the form of five convulsive attacks. Initial examination revealed a blood pressure of 130/80 mmHg, a regular pulse of 130 bpm, an elevated jugular venous pressure (JVP), and inspiratory crepitations in the left lung.

Initial blood results revealed slightly elevation of creatine kinase MB fraction 52 U/l (normal range 0.1–40.0) and markedly elevated AST 142 U/l (normal range <37), lactate dehydrogenase 1,288 U/l (normal range 226–460), brain natriuretic peptide (BNP) 1,835 pg/ml (normal range <18.4 pg/ml), while blood count, urea, and electrolytes were all within normal range. Blood gas analysis was: pH 7.49, pCO₂ 3.7, pO₂ 19.3, oxygen saturation 78%. Chest X-ray showed cardiomegaly with left basal shadowing and left pleural effusion. ECG showed sinus tachycardia of 130 bpm without significant change in S-T segment. Echocardiography revealed a dilated left ventricular internal diameter of 5.5 cm with global hypokinesis, impaired left ventricular (LV) systolic function, and ejection fraction (EF) of 25–30%. CT scan of endocranium showed normal findings without ischemic or vascular lesions. The patient was transferred to the intensive care unit, and because she developed respiratory insufficiency, she was immediately intubated and placed on mechanic ventilation, with dobutamine and furosemid started to treat heart failure, anti-edematous therapy (manitol), anti-aggregation therapy (low weight heparin), anti-

Revised manuscript accepted for publication August 5, 2014

convulsive (MgSO₄), ACE inhibitors, xylocaine because of the sporadic ventricular extra systolic arrhythmias, digitalis, antibiotics (teicoplanin, meropenem, vancomycin), and bromocriptine.

Concurrently LV function improved, heart failure and respiratory insufficiency symptoms and signs decreased. On the third day after delivery she was extubated, on the repeated chest X-ray done on the 10th day after delivery there was no plural effusion. Echocardiography was done on the 18th day after delivery revealing normal dimension of the left ventricle, EF was 64%, no pericardial effusion was detected, BNP level was reduced to 411 pg/ml after three weeks of delivery, and to 156 pg/ml after two months. Patient was discharged from the hospital on the 22nd day after delivery.

Discussion

PPCM is a pregnancy associated myocardial disease that is heterogeneous and seems to have important phenotypic variations in different geographical regions, so it is difficult to formulate uniform recommendations for the treatment of this condition [5]. The etiology of PPCM is still unknown, and many potential causes have been proposed but not proven, such as viral myocarditis, abnormal immune response to pregnancy, inadequate response to increased hemodynamic burden of pregnancy, hormonal abnormalities, inflammation, and apoptosis [6]. Prolonged tocolytic therapy also could be a possible cause of PPCM, but it is not determined whether it has direct influence or if it just unmasks a preexisting subclinical disease [7]. Recent investigations in large cohorts of familial dilated cardiomyopathy reveal that genetic etiologies may be identified in a substantial fraction of women with PPCM [8].

The treatment for PPCM is similar to that for other forms of heart failure and consists of angiotensin-converting enzyme inhibitors that are used to reduce afterload by vasodilatation if PPCM occurs after pregnancy, β -blockers used to treat tachycardia and arrhythmias, diuretics that reduce preload, and because of a high incidence of thromboembolic complications in these patients, the use of heparin is also necessary.

Several recent reports have noted that bromocriptine and prolactin antagonist cabergoline could preserve LV function in PPCM [9]. The treatment of PPCM with bromocriptine was based on the study results that increased oxidative stress could lead to an increased expression and activity of the cathepsin-D, which is responsible for cleaving the 32-kDa form of prolactin to a smaller fragment which possesses antiangiogenic, proinflammatory, and vaso-constrictory properties and could cause dilated cardiomyopathy [1].

The present patient with acute PPCM, who in addition to standard therapy for heart failure, received also bromocriptine and had a successful recovery despite initially dramatic clinical presentation. Regarding the risk factors for development of PPCM, the present patient had triplet pregnancy and once received intravenous tocolytic therapy during sec-

ond trimester of pregnancy. Positive response to applied therapy in this case could be attributed to LV diastolic dimension and systolic function (left ventricle ejection fraction -LVEF). A multivariate analysis by Goland *et al.* in 187 patient with PPCM [10] found that LVEF >30% and LV end-diastolic dimension < 55mm were significantly related to LV recovery, suggesting a relationship between the degree of initial myocardial insult and recovery.

In conclusion, timely detection and initiation of treatment are important factors for complete recovery of patients with PPCM. The identification of predictors of LV recovery may help stratify patients who would benefit from more invasive and expensive forms of therapies. Even with full recovery, some additional risk of relapse remains present in patients with PPCM.

References

- [1] Dalzell J., Jackson C., Gardner R.: "An update on peripartum cardiomyopathy". *Expert Rev. Cardiovasc. Ther.*, 2011, 9, 1155.
- [2] Gunderson E., Croen L., Chiang V., Yoshida C., Walton D., Go A.: "Epidemiology of peripartum cardiomyopathy". *ACOG*, 2011, 118, 583.
- [3] Kelly D., Hickey P., Davies J., Leong N.G., Chin D.: "Acute management of pregnancy associated cardiomyopathy with cardiac resynchronization therapy". *Eur. J. Heart Failure*, 2007, 9, 542.
- [4] Blatt A., Svirski R., Morawsky G., Uriel N., Neeman O., Sherman D., *et al.*: "Short and long-term outcome of pregnant women with preexisting dilated cardiomyopathy: an NTproBNP and echocardiography-guided study". *IMAJ*, 2010, 12, 613.
- [5] Elkayam U.: "Clinical characteristics of peripartum cardiomyopathy in the United States". *J. Am. Colleg. Cardiol.*, 2011, 58, 659.
- [6] Sliwa K., Hilfiker-Kleiner D., Petrie M.C.: "Current state of knowledge on etiology, diagnosis, management, and therapy of peripartum cardiomyopathy: a position statement from the heart failure association of European Society of Cardiology Working Group on Peripartum Cardiomyopathy". *Eur. J. Heart Fail.*, 2010, 12, 767.
- [7] Ivanovic B., Tadic M., Maksimovic R., Orbovic B.: "Could it have been better? A patient with peripartum cardiomyopathy treated with conventional therapy". *Vojnosanit. Pregl.*, 2012, 69, 526.
- [8] Anderson J.L., Horne B.D.: "Birthing the genetics of peripartum cardiomyopathy". *Circulation*, 2010, 121, 2157.
- [9] Abe T., Amano I., Sawa R., Akira S., Nakai A., Takeshita T.: "Recovery from peripartum cardiomyopathy in a Japanese woman after administration of bromocriptine as a new treatment option". *J. Nippon Med. Sch.*, 2010, 77, 226.
- [10] Goland S., Bitar F., Modi K.: "Evaluation of the clinical relevance of baseline left ventricular ejection fraction as a predictor of recovery or persistence of severe dysfunction in women in the United States with peripartum cardiomyopathy". *J. Cardiac Fail.*, 2011, 17, 426.

Address reprint requests to:

A. ČETKOVIĆ, M.D.

Clinic of Gynecology and Obstetrics

Clinical Center of Serbia

Milentija Papovića, 33

Belgrade (Serbia)

e-mail: aleksa_cetkovic@vektor.net

Chronic renal failure, diabetes mellitus type-II, and gestation: an overwhelming combination

E.N. Kontomanolis¹, S. Panagoutsos², P. Pasadakis², Z. Koukouli¹, A. Liberis¹

¹Department of Obstetrics & Gynecology, Democritus University, Alexandroupolis

²Department of Nephrology, Democritus University, Alexandroupolis (Greece)

Summary

This case report highlights on a child-bearer with chronic renal failure and diabetes mellitus type-II. Chronic renal failure (CRF) with diabetes mellitus (DM) type I in gestation is a rare case of a high-risk pregnancy. What is of significance though in this gestation, is that conception was achieved with the patient treated by a dialysis program. Furthermore, neither hypertension nor intrauterine growth restriction (IUGR) were detected and the patient was normotensive throughout gestation with no clinical signs of anemia. Strict and frequent application of the dialysis programs eradicates the uremic intrauterine environment, reduces the amniotic fluid volume, eliminates the chances of uterine rupture, leads to a longer gestation, increases the newborn's birth weight, and offers an optimal fetal survival rate; this is of note mainly in patients with cesarean sections reported in their medical history. To eliminate the complications of a premature delivery, the present authors had to find the right time point to give birth to this baby taking into account lung maturity, amniotic fluid volume, and preservation of the anatomical uterine integrity.

Key words: Chronic renal failure; Diabetes, hypertension; Fetal growth retardation; Renal dialysis.

Introduction

Chronic renal failure (CRF) is end-stage kidney disease; CRF subjects require the application of frequent dialysis programs in order to survive. CRF is associated with menstrual disturbances, fetal loss, and infertility. Pregnancy superimposed on CRF with diabetes mellitus (DM) type II may prove to have an adverse impact on the mother and increases the incidence of obstetric implications, such as sudden onset of elevated arterial blood pressure, intrauterine growth restriction, premature delivery, and polyhydramnios.

Case Report

The patient, a 32-year-old rhesus positive, non-smoker Greek female, gravid 1, para 2, with a pre-pregnancy weight of 65 kg was diagnosed with end stage renal disease (ERSD) in 2007 during her first pregnancy and she was started hemodialysis in December 2007. The patient conceived, six years after maintenance hemodialysis (three four-hour sessions weekly). Despite the risks of prematurity and neonatal morbidity, the patient opted to continue with the pregnancy. After confirmation of gestation, treatment of dialysis was increased up to four hours daily (six sessions/week). The patient did not develop anemia (Ht=38%, Hb=12.1 gr/dl). Erythropoietin's dose was increased from a mean weekly dose of 9,000 units to 18,000 units during pregnancy. Low-dose aspirin was suggested to prevent preeclampsia.

She visited the outpatient clinic in the present Fetal Medicine Department at 13 weeks of gestation as dated by her last menstrual period. Her nuchal translucency (NT=1.80 mm) was within normal

range. She had an important medical history of insulin-dependent diabetes since the age of 13 and one female child delivered at 32 weeks with cesarean section due to deterioration of renal function—weighing 1,530 grams with an uneventful neonatal period. She was on twice-daily short-acting monocomponent insulins injections subcutaneously for her diabetes. Viral serology markers for parvovirus, toxoplasma, cytomegalovirus, and rubella, HIV, HBV, HCV, HSV, and RPR were negative. Clinical examination was normal and no allergies were reported. During her follow-ups, fetal well-being was monitored through serial scanning, assessment of the biophysical profile, and Doppler measurements; *growth pattern was within normal range*. Her second level scan at 22 weeks including cervical length assessment (CL≈3.7mm) showed no anatomical anomalies. Fetal echo revealed no signs of congenital heart disease with a baseline fetal heart rate of 135 beats per minute.

The patient revisited again the clinic for her growth scan at 27 weeks and ultrasound showed polyhydramnios (AFI≈24). Fetal growth (EFBW≈1,030 grams) was calculated by measurement of biparietal (BPD) and occipitofrontal (OCF) diameters, abdominal circumference (AC), and femur length (FL). Admission to the obstetric ward was suggested because of the severely amniotic fluid increase and the consequent premature contractions. During hospitalization, normal blood glucose titer was retained owing to a strict diabetic control; the amniotic fluid index increased up to 26. The patient was on daily hemodialysis; the average concentration of the pre-dialysis and post-dialysis urea were between 80 mg/dl and 45 mg/dl respectively; serum creatinine levels were no more than 5.8 mg/dl and 3.6 mg/dl, respectively. The increased frequency of hemodialysis sessions assisted in achieving normal biochemistry with regards to acid-base and electrolyte balance, avoid marked shifts in intravascular volume, and maintain a friendly metabolic environment for the fetus. The authors were being ex-

Revised manuscript accepted for publication November 3, 2014

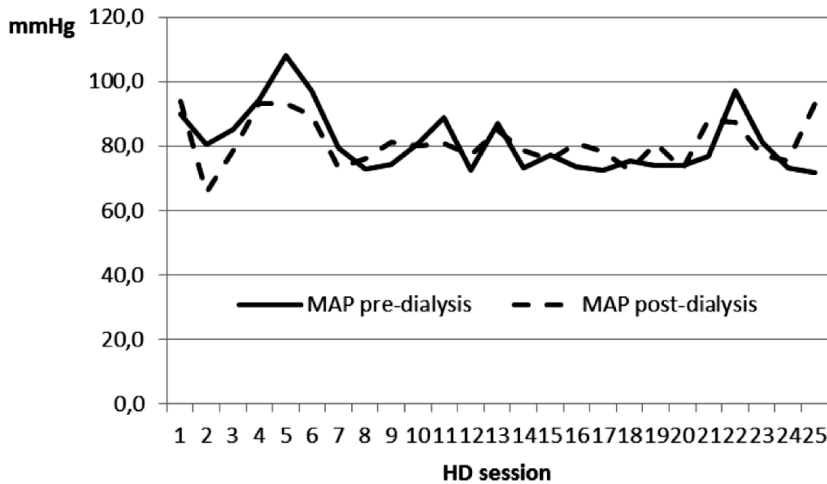


Figure 1. — Pre- and post-dialysis Mean Arterial Pressure (MAP) during the last 25 hemodialysis (HD) sessions.

tremely careful regarding administration of tocolysis due to total failure of the kidneys. She was administered anticoagulant therapy with low-molecular-weight heparin (LMWH) at therapeutic doses throughout renal therapy. Her blood pressure was within normal range (maximum 120/60 mm/Hg) (Figure 1). She developed neither vascular nor neurologic complications in regards to her diabetes mellitus. The marked antenatal surveillance with the use of high resolution ultrasound scanning in combination with daily haemodialysis preserved the normality of the blood volume of the patient and guaranteed a healthy intrauterine environment for the baby's survival. As gestation progressed, biophysical profile was performed weekly and kidney clearance procedures were intensified in order to limit the emergence of polyhydramnios. Doppler assessment of the umbilical and middle cerebral arteries detected no signs of fetal distress.

Taking into account the presence of polyhydramnios, chronic renal failure, and fetal growth curve, a cesarean section was scheduled at 30+3 weeks. Lung maturation was induced with 12 mg betamethasone at 29 weeks (two doses separated in 24 hours). During the cesarean section, complete rupture of the uterine wall was observed. A female baby weighing 1,730 grams was born with Apgar scores of 6 at nine minutes and 7 at five minutes, and the neonate required medical attention; despite considerable efforts in the neonatal ward, the baby of the patient survived ten days. A patent arterial duct, that failed to disintegrate postnatally, contributed significantly to her neonatal death.

Discussion

Gestation is a physiological event that induces kidney function alterations; the stage of renal function is the vital parameter that outlines the course of a gestation and its neonatal outcome. The combination of end-stage renal failure and pregnancy is infrequent. Long-term dialysis therapy is absolutely essential in ESRF; a term used alternatively for chronic renal failure. A considerable number of patients with CRF are asymptomatic, until uremic symptoms appear. The occurrence of a preterm delivery or a baby with fetal growth restriction carries a risk for the appearance of ESRF post-partum. Obstetric management embraces the assessment of

renal function, blood pressure, and antenatal monitoring.

Irregular menstrual cycles, anovulation, nausea, and fetal loss appear frequently in dialysis patients. The co-existence of chronic renal impairment and diabetes mellitus in gestation predisposes to a declining renal function and the appearance of obstetric complications: hypertensive crisis, low hematocrit values, polyhydramnios, growth retardation, early uterine contractions, and uremia [1]. Women on chronic dialysis as a result of end-stage renal insufficiency have reduced fecundability; their babies are often born before the 36th week of gestation, and they are of low birth weight; the mean date of delivery in renal patients is approximately 32 weeks. Despite the improved fetal outcome, a large number of pregnancies fail to reach a full-term delivery with the number of neonatal deaths still remaining high [2]. Clinical researchers observed that a long term hemodialysis therapy program applied on polyhydramnios parturients reduced the incidence of uterine rupture and affected positively the fetal survival outcome [1-3]. Intensifying hemodialysis by increasing the number the frequency of treatments reduces amniotic fluid volume; it is considered to be the essential therapeutic means for a favorable fetal outcome. Despite significant improvement on pre-pregnancy counselling, antenatal surveillance and neonatal care units, infant survival can approach the figure of 50%. Pre-eclampsia and poly- hydramnios require careful attention since they might exert a strong impact on maternal and fetal health. In ESRF, fetal demise can occur early in the second trimester, but the risk of intrauterine death is existent in all three trimesters of gestation; fetal viability is a crucial parameter in renal subjects [4]. Hypertension is indicated as the dominating peril in renal patients. Any type of hypertensive disease (i.e., preeclampsia, chronic hypertension) predisposes to renal damage. Pre-existing kidney disease associated with hypertension renders women susceptible to pre-eclampsia. A common complication in pregnant women

with renal impairment is the incidence of preeclampsia along with a deteriorating kidney function. CRF is responsible for poor placentation and its cognate endothelial dysfunction; obstruction of the glomerular capillaries is the distinguishing feature of kidney damage in pre-eclamptic women. Newborns are subject to growth retardation, preterm delivery, and a higher possibility for hospital admittance. Women of childbearing age, who are on dialysis for chronic renal failure, should be specifically advised prenatally on the possible implications of a preterm delivery with neurodevelopmental delay—a possible consequence of impaired dominant hemispheric maturation—and even worse of a devastating fetal outcome [5]. An analysis of the medical literature illustrates that chronic renal failure is encountered in 0.03% to 0.12% of the parturient cases. Additionally, kidney patients are liable to have comorbidities, i.e., cardiac or lung disease, diabetes or anemia [6]. Regardless of the intensive dialysis programs and the wary prenatal surveillance, a uremic intrauterine environment can be lethal for the growing embryo [7-9]. A constant uterine environment with no abrupt changes in fluid volume and no hypotensive episodes guarantees a favorable prognosis for the neonate. Infant survival is the most challenging part in kidney patients, since the fetus is struggling to grow in a hostile uterine environment; neonatal demise is anticipated more frequently compared to the general population [10]. Given these thoughts, these gestations are deemed to be high risk and childbearers should be counselled by experts on the field to illustrate the utmost hardships and risks throughout the course of gestation. The potential complications of neonatal death and increased maternal morbidity are present, despite the precise application of the obstetric protocols and the efficient management of the polyhydramnios.

References

- [1] Chao A.S., Huang J.Y., Lien R., Kung F.T., Chen P.J., Hsieh P.C.C.: "Pregnancy in women who undergo long-term hemodialysis". *Am. J. Obstet. Gynecol.*, 2002, 187, 152.
- [2] Chen P.J., Liu C.M., Chang S.D., Lin Y.T., Soong Y.K.: "Elevated second trimester maternal serum hCG in patients undergoing hemodialysis". *Prenat. Diagn.*, 1999, 19, 955.
- [3] Malik G.H., Al-Harbi A., Al-Mohaya S., Dohaimi H., Kechrid M., Shetaia M.S., et al.: "Pregnancy in patients on dialysis—experience a referral center". *J. Assoc. Physicians India*, 2005, 53, 937.
- [4] Tan L.K., Kanagalingam D., Tan H.K., Choong H.L.: "Obstetric outcomes in women with end-stage renal failure requiring renal dialysis". *Int. J. Gynaecol. Obstet.*, 2006, 94, 17.
- [5] Sato J.L., De Oliveira L., Kirstaian G.M., Sass N.: "Chronic kidney disease in pregnancy requiring first-time dialysis". *Int. J. Gynaecol. Obstet.*, 2010, 111, 45.
- [6] Fischer M.J., Lehnerz S.D., Hebert J.R., Parikh C.R.: "Kidney disease is an independent risk factor for adverse fetal and maternal outcomes in pregnancy". *Am. J. Kidney Dis.*, 2004, 43, 415.
- [7] Gomez F., De La Gueva R., Wauters J.P., Lemarchand-Beraud T.: "Endocrine abnormalities in patients undergoing long term hemodialysis. The role of prolactin". *Am. J. Med.*, 1980, 68, 522.
- [8] Ginsberg E., Owen W.F. Jr.: "Reproductive endocrinology and pregnancy in women on hemodialysis". *Semin. Dialysis*, 1993, 6, 105.
- [9] Toma H., Tanabe K., Tokumoto T., Kobayashi C., Yaqisawa T.: "Pregnancy in women receiving renal dialysis or transplantation in Japan: a nationwide survey". *Nephrol. Dial. Transplant.*, 1999, 14, 1511.
- [10] Smith W.T., Darbari S., Kwan M., O'Reily-Green C., Devita M.V.: "Pregnancy in peritoneal dialysis: A case report and review of adequacy and outcomes". *Int. J. Urol. Nephrol.*, 2005, 37, 145.

Address reprint requests to:
 E.N. KONTOMANOLIS, M.D., Ph.D.
 Michael Papadaki Street 222
 Ekali 14578, Athens (Greece)
 e-mail: mek-2@otenet.gr

Prenatal diagnosis of Binder's syndrome: report of two cases

S. Mutlló Cantarell¹, L. Serra Azuara¹, S. Pina Pérez¹, J. Lleberia Juanos¹,
F. Mellado Navarro¹, M. Corona Martínez²

¹ Prenatal Diagnosis Department, Obstetrics and Gynecology, Hospital Universitari Parc Taulí, Sabadell, Barcelona

² Director of the Prenatal Diagnosis Department, Obstetrics and Gynecology, Hospital Universitari Parc Taulí, Sabadell, Barcelona (Spain)

Summary

Objective: Binder syndrome is a rare congenital malformation presenting an abnormal maxilla's development associated to other characteristic facial features, like absence or decreased nasal bridge, short nasal columella, convex upper lip with associated dental Angle Class III malocclusion, atrophy of the nasal mucosa, and absence of the frontal sinus. Mental retardation and other clinical signs may also be present. Two cases of Binder syndrome were diagnosed at 22 weeks of gestation during the second trimester ultrasound (2D). **Cases Report:** The first feature detected, in both cases, was a flattened fetal nose in the mid-sagittal plane. Further controls objectivated absence of the naso-frontal angle and a mild hypertelorism. In both cases the parents were informed of the findings and the impossibility of excluding other associated features diagnosed after birth. Once the differential diagnosis was performed, one of the couples decided to terminate the pregnancy. The findings postmortem confirmed the diagnosis. In the second case, the newborn presented the phenotype previously detected, however, a normal psychomotor development was eventually evidenced. **Conclusion:** The Binder syndrome is an uncommon clinical entity with a recognizable congenital condition characterized by a retruded midface and an extremely flat nose. The exact birth prevalence remains unknown. It is important to understand that Binder's syndrome has a variable prognosis, depending on the other associated features it presents. When diagnosed, an accurate differential diagnosis has to be performed.

Key words: Binder syndrome; Maxillo-facial dysplasia; Prenatal diagnosis.

Introduction

Binder syndrome or also known as maxillo-nasal dysplasia or maxillo-nasal dysostosis, is a rare congenital malformation characterized by an abnormal development of the maxilla and the nasal complex. Initially described by Zuckerman [1] in 1882, it was Binder [2] who, in 1962, reported three cases and described the six most remarkable characters of the syndrome: facial dysmorphism secondary to a naso-maxillary hypoplasia, absence or decreased nasal bridge, short nasal columella, convex upper lip with associated dental Angle Class III malocclusion, atrophy of the nasal mucosa, and absence of the frontal sinus (not obligatory).

Patients with Binder syndrome have a typical facial appearance, including midfacial hypoplasia with verticalized nasal bones, flattened tip and alar wings, acute naso-labial angle, and the presence of a naso-frontal angle measuring between 150° and 160° (compared to the normal value of 135°); these eventually result in a concave midfacial profile [3] caused by the hypoplasia of the upper maxilla and its retroposition. Most patients have some or all of the features described, depending on the severity of the syndrome.

Since it was described in 1962, more than 200 cases have been reported. The first prenatal diagnosis case of Binder's phenotype was published in 2000 [4]. The diagnostic triad was formed by a nasal flattening in the mid-sagittal profile, a

verticalization of the nasal bones and a maxilla's retroposition. The next case was published in 2005 by Cuillier *et al.* [5]

It is important to remark that hypertelorism, exophthalmos, occult spina bifida, and mental retardation can be associated. Cervical spine malformations have been described in 50% of patients, being the most common the atlas and axis, anterior or posterior, with defects or the fusion of the vertebrae [6]. Proencephalon [7] irregularities, and strabismus [8] are also associated.

Some authors consider that the disorder does not represent a single nosologic entity and that the use of the word 'syndrome' or 'dysplasia' is inappropriate. They suggest the use of Binder 'phenotype' [9] or 'association' or a 'symptom' as a non-specific abnormality of the naso-maxillary complex, possibly related (in many cases) to prenatal deficiency of vitamin K, warfarin embryopathy or chondrodysplasia punctata (CDP).

Two cases of Binder syndrome were diagnosed at 22 weeks of gestation using two- and three-dimension ultrasound. The first sign was an isolated flattened fetal nose in the mid-sagittal plane. Further ultrasound imaging showed the absence of the naso-frontal angle, giving impression of flat forehead and small fetal nose. Complementary imaging tests confirmed the sonographic diagnosis adding hypertelorism and exophthalmos in one of the two cases.

Revised manuscript accepted for publication December 18, 2014

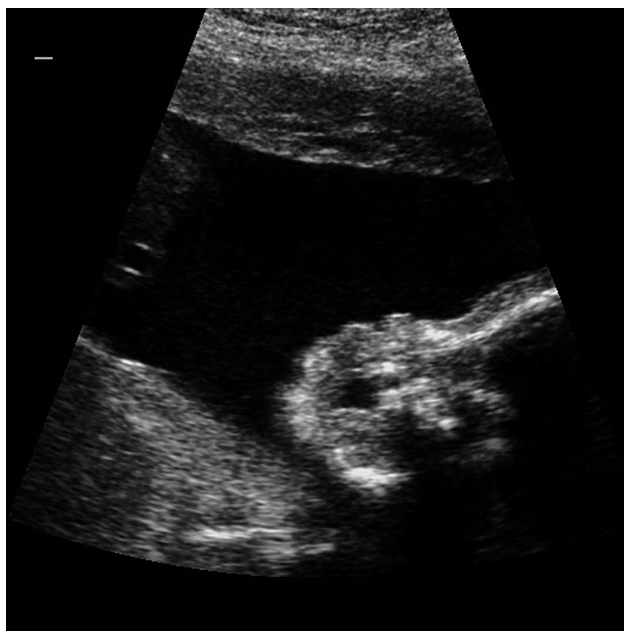

Figure 1. — Ultrasound Image shows a sagittal fetal facial profile at 22 weeks of gestation. A marked nasal hypoplasia can be observed, with a superior lip prominence.

Case Report

The first case included a 22-year-old, nullipara, with no relevant medical records, and all the analytical controls and first trimester ultrasound markers in the limit of normality, that attended at week 22 of gestation for a routine morphological ultrasound scanner. The examination was performed using a two-dimensional high-definition ultrasound.

The fetus biometrics corresponded to gestational age and female genitalia were present. During the examination, a nasal hypoplasia with reduced naso-frontal angle was identified and a mild hypertelorism was also detected. (Figure 1) No other structural abnormalities were seen. These findings were confirmed with an MRI (Figure 2)

An amniocentesis was performed to exclude chromosomal abnormalities, resulting in euploid female karyotype (46 XX). The sonographic findings were presented at the fetal medicine committee of the present center (formed by geneticists, radiologists, pediatricians, gynecologists, and biologist experts in prenatal diagnosis) and concluded that the most probable diagnosis was Binder syndrome. Unable to exclude other disorders and pathologies with a postnatal diagnosis, the couple decided to voluntarily terminate pregnancy.

The post-mortem findings documented a facial dysmorphism, with a nasal hypoplasia, a short columella, and a flat mild face. A mild hypertelorism and a slight exophthalmos were also present. No other significant findings were found (Figure 3).

The second case included a 29-year-old nullipara, with history of chronic venous insufficiency controlled without treatment, that attended for a routine screening examination. She had no obstetrical relevant records, with a low risk first trimester screening. At 22.3 weeks of gestation, morphological second trimester ultrasound was performed. The fetus with female external genitalia, had measurements corresponding to gestational age and a nasal hypoplasia accompanied by polyhydramnios and single umbilical

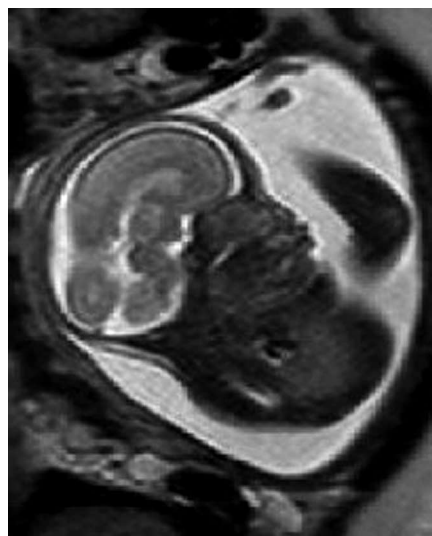

Figure 2. — Fetal MRI (sagittal profile). Nasal hypoplasia in a 22 gestational week fetus.

artery was documented. No other facial or fetal abnormalities were observed. A normal female karyotype was obtained and fetal MRI confirmed the diagnosis. The case and the ultrasound findings were presented in the committee of prenatal diagnosis, and the most reliable diagnosis was the Binder syndrome. The family was informed of the prognosis and the possible postnatal associations (mental retardation, dental malocclusion, etc.) and they decided to continue pregnancy.

At 25.5 weeks of gestation, the patient was admitted in hospital for premature rupture of membranes. Antibiotics, tocolytic treatment, and fetal lung maturity were established.

During the admission the patient presented alteration of some laboratory parameters compatible with HELLP syndrome (hemolytic anemia, elevated transaminases, and thrombocytopenia). Normal blood pressure was reported and no proteinuria was observed. Fetal welfare assessments were made, evidencing normal umbilical artery and middle cerebral artery (MCA) Doppler and a reactive pattern in the non-stress test. At 27.6 weeks of pregnancy, the laboratory parameters began to worsen and the ultrasound control reported an impairment of the MCA. In view of the risk that existed for the pregnant woman and assuming that in any time the clinical conditions could change, the Obstetric team decided to terminate the pregnancy. A 1,020 gram baby was born by cesarean section. She was admitted in the neonatal unit for prematurity with good outcome. The post-natal examination revealed a marked nasal hypoplasia accompanied by a decreased fronto-nasal angle without other associated abnormalities (Figure 4). The mother had a posterior good clinical evolution. At day 57 of life, the baby was discharged with a normal cerebral ultrasound scan. In posterior controls (six and 12 months later), a normal psychomotor development was evidenced.

Discussion

The identification of a normal fetal profile through the ultrasound examination during the second trimester of pregnancy is important to exclude facial abnormalities [10] as micrognathia, macroglossia (associated with Down syndrome) or a concave front related to microcephaly [11]. Although Binder's syndrome is uncommon, its prenatal

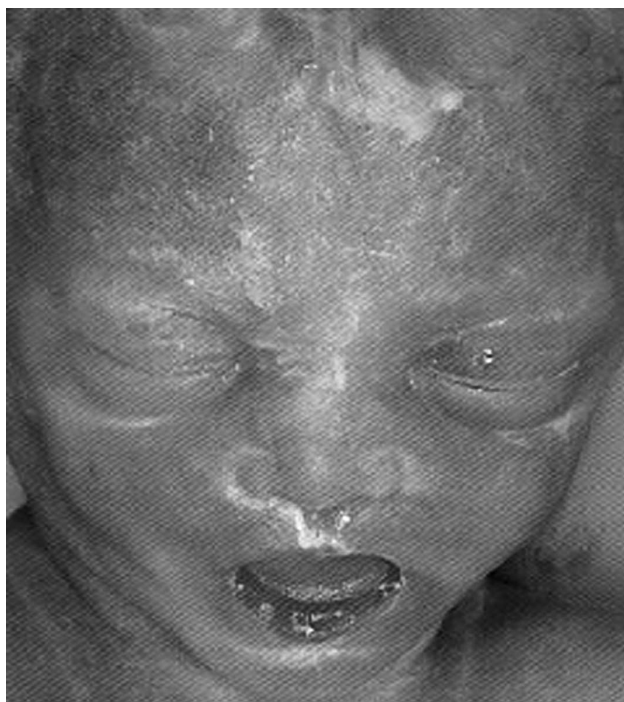

Figure 3. — Post-mortem findings. Mild hypertelorism confirmed in the fetal autopsy (22 gestational weeks).

diagnosis is possible if a flattened medium sagittal profile or a nasal hypoplasia is detected in the ultrasound examination.

Once the alteration is identified, it is necessary to perform a detailed neurosonography, an accurate facial examination, as well as, a review of the fetus morphology to exclude out other associated anomalies which could lead to other entities [12]. CDP is one of the differential diagnoses to consider. Although nasal hypoplasia is also present in this entity, other features as scoliosis and asymmetric rib cage could be encountered. This syndrome (CDP) is included in a heterogeneous group of skeletal dysplasias, and it is characterized by the radiographic appearance of a dotted cartilage (punctate calcifications) skeletal or extra-skeletal, secondary to abnormal calcium deposition during the formation of endochondral bone, occurring up to the 12 years of age [13]. Other associated features include facial dysmorphism, respiratory distress, mental retardation, and congenital cataracts.

Some authors consider Binder syndrome and CDP are related [14], as they share a similar phenotypic appearance, including a verticalized midface and a nasal hypoplasia. In fact, Sheffield *et al.* [15] in 1989 reviewed 103 cases of CDP and concluded that Binder syndrome should be classified as a mild form or symptom of CDP [16]. Sheffield *et al.* pointed out that most patients with Binder syndrome seek medical attention in adolescence. Indeed by this age, the diagnostic radiologic features of CDP could have dis-

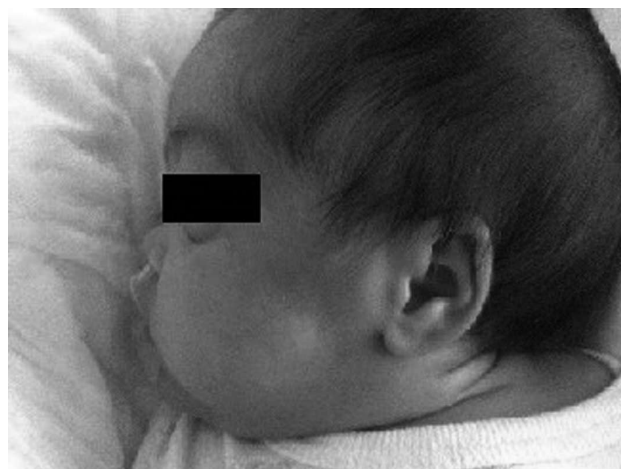

Figure 4. — Facial profile of a 57-day newborn (corrected gestational age 36 weeks) with nasal hypoplasia with convex upper lip.

appeared and therefore the diagnosis is often not considered. Other authors consider it as two separate entities.

Other diagnoses also need to be excluded when nasal hypoplasia and facial abnormalities are detected, such as a fetal vitamin K deficiency [17, 18], a maternal consumption of warfarin or alcohol especially in the first trimester of pregnancy. The Robinow syndrome (hypertelorism, limb hypoplasia, fusion of vertebrae, brachydactyly and/or cleft palate); the Stickler syndrome, (myopia, deafness and spondylo-epiphyseal dysplasia) or the Apert syndrome (in which the craniosynostosis commonly documented causes ocular subluxation due to the orbital hypoplasia) also have to be considered.

The etiology, prevalence, and type of inheritance, are not entirely clear. However, it has been suggested that the maxillo-nasal dysplasia is a result of a concurrent process induced by the forebrain and the vertebrae, which would justify the increased incidence of vertebral alterations associated with the syndrome [19].

Holmström and Gewalli described an inhibition of the ossification center that would normally form the lateral and inferior borders of the piriform aperture during the fifth and sixth gestational weeks, leading to a localized hypoplasia of the upper jaw, thus resulting in a retracted columellar/lip junction and lack of the normal triangular flare in the lower part of the columella: features commonly seen in patients with Binder syndrome [20]. Other suggested associations include birth trauma [21] and genetic factors [22], although in most cases, the expression of the syndrome is a result of sporadic mutations. Several authors describe families with dominant pattern of inheritance. For example, Olow-Nordenram [23] reported a 36% positive family history in 97 patients with Binder syndrome. This fact would be explained by either autosomal recessive inheritance with reduced penetrance or by multifactorial inheritance [24].

In the Binder syndrome, the facial malformation appear usually isolated; however, in a few cases it can be associated to mental retardation [25], alterations of the cervical vertebrae, other skeletal defects, hypertelorism, and strabismus: a fact that impoverishes the prognosis. Decreased intelligence does not seem to be a significant feature in Binder syndrome. In a review of cases, only seven out of 108 patients presented mental retardation [26, 27]. Four of them had additional features (Down Syndrome, cleft palate, strabismus), while the other three had poor school performances. The diagnosis of Binder syndrome is clinical and differential diagnosis is extensive, and although many diagnoses can be excluded, many others cannot.

The prognosis of a fetus with a case of isolated maxillo-nasal dysostosis is excellent. However, the finding of this isolated malformation with a normal karyotype usually has good prognosis and the possibility of being surgically corrected [28]. The treatment differs depending on the degree of affectation and the facial anomalies presented. If the maxillo-nasal dysplasia is diagnosed postnatally, and if it is isolated, surgical correction is the elective choice [29].

In the first case described, the nasal hypoplasia was associated with an absent naso-frontal angle and a slight hypertelorism. The post-mortem findings correlated with the phenotypes of infants and children diagnosed with Binder syndrome. The phenotypic traits detected sonographically did not correlate with the parent's profile. This caused major emotional stress; furthermore, the small risk of mental retardation was unacceptable to them. Both reasons were decisive to request a termination of pregnancy. This case highlights some of the ethical issues that arise when morphological abnormalities are detected on 20 weeks ultrasound. It also questions the diagnosis of abnormalities for which there is no confirmatory diagnostic tests. The fact that several differential diagnostics have to be considered, also determines the decision of the parents.

Conclusions

Binder syndrome is an uncommon clinical entity with a recognizable congenital condition characterized by a retruded midface and a extremely flat nose. The exact birth prevalence remains unknown. It is important to understand that Binder syndrome has a variable prognosis, depending on the other associated features it presents. Therefore when diagnosed in utero, it is important to examine exhaustively the facial features and detect fetal abnormalities that could deteriorate the prognosis. Furthermore, informing and advising the family from a multidisciplinary perspective guides them to make a more accurate decision, while always considering that an isolated nasal hypoplasia without chromosomal abnormalities associated has, in most cases, good prognosis and a satisfactory surgical correction is possible.

References

- [1] Zuckerkandl E.: "Fossae paranasales: normale und pathologische". *Anat. Nasenhöhle*, 1882, 1, 48.
- [2] Binder K.H.: "Dysostosis maxillo-nasalis, ein arhinen-cephaler Missbildungskomplex". *Dtsch. Zahnärztl. Z.*, 1962, 438.
- [3] Drafi W., Ulrike B., Hoffmann B.: "Nasal correction in maxillo-nasal dysplasia (Binder's syndrome): a long-term follow up study". *Br. J. Plast. Surg.*, 2003, 56, 199.
- [4] Cook K., Prefumo F., Presti F., Homefray T., Campbell S.: "The prenatal diagnosis of Binder syndrome before 24 weeks of gestation: case report". *Ultrasound Obstet. Gynecol.*, 2000, 16, 578.
- [5] Cuillier F., Cartault F., Lemaire P., Alessandri J.L.: "Maxillo-nasal dysplasia (binder syndrome): antenatal discovery and implications". *Fetal Diagn. Ther.*, 2005, 20, 301.
- [6] Resche F., Tessier P., Delaire J., Tulasne J.F.: "Craniospinal and cervicospinal malformations associated with maxillo-nasal dysostosis (Binder syndrome)". *Head Neck Surg.*, 1980, 3, 123.
- [7] Ferguson J.W., Thompson R.P.J.: "Maxillo-nasal dysostosis (Binder Syndrome) a review of the literatura and case reports". *Eur. J. Orthod.*, 1985, 7, 145.
- [8] Quarrel O.W., Koch M., Hughes H.E.: "Maxillo-nasal dysplasia (Binder's syndrome)". *J. Med. Genet.*, 1990, 27, 384.
- [9] Levaillant J.M., Moeglin D., Zouiten K., Bucourt M., Burglen L., Soupre V., et al.: "Binder phenotype: clinical and etiological heterogeneity of the so-called Binder maxillo-nasal dysplasia in prenatally diagnosed cases, and review of the literatura". *Prenat. Diagn.*, 2009, 29, 140. doi: 10.1002/pd.2167.
- [10] Bronshtein M., Blumenfeld I., Zimmer E.Z., Ben Ami M., Blumenfeld Z.: "Prenatal sonographic diagnosis of nasal malformations". *Prenat. Diagn.*, 1998, 18, 447.
- [11] Gorlin R.J., Cohen M., Levin L.: "Syndromes of the head and neck". 3rd ed. Oxford: Oxford University press, 1990.
- [12] Holmstrom H.: "Clinical and pathologic features of maxillo-nasal dysplasia (Binder's syndrome) Significance of the prenasal fossa on etiology". *Plast. Reconstr. Surg.*, 1986, 78, 559.
- [13] Garnier A., Dager S., Eurin D., Parisi I., Parenti G., Garel C., et al.: "Brachytelephalangic chondrodysplasia punctata with severe spinal cord compression: report of four cases". *Eur. J. Pediatr.*, 2007, 166, 327.
- [14] Sheffield L.J., Halliday J.L., Jensen F.: "Maxillo-nasal dysplasia and chondrodysplasia punctata". *J. Med. Genet.*, 1991, 28, 503.
- [15] Sheffield L.J., Halliday J.L., Danks D.M., Rogers J.G., Poulos A., Morrison N.: "Clinical, radiological and biochemical classification of chondrodysplasia punctata (abstract)". *Am. J. Hum. Genet.*, 1989, 45, A64.
- [16] Colin E., Touraine R., Levaillant J.M., Boussion F., Ferry M., Guichet A., et al.: "Binder phenotype in mothers affected with autoimmune disorders". *J. Matern. Fetal. Neonatal. Med.*, 2012, 25, 1413. doi: 10.3109/14767058.2011.636105. Epub 2011 Dec 7.
- [17] Howe A.M., Webster W.S., Lipson A.H., Halliday J.L., Sheffield L.J.: "Binder's Syndrome due to prenatal vitamin K deficiency: a theory of pathogenesis". *Aust. Dent. J.*, 1992, 37, 453.
- [18] Winter R.M., Baraister M.: "Multiple congenital anomalies: a diagnostic compendium". London: Chapman & Hall, 1991, 75.
- [19] Couly G.: "Embriogénese et malformations de la face et du cou". *Med. Foet. Echo. Gynecol.*, 2000, 44, 42.
- [20] Holmström H., Gewalli F.: "Long-term behavior of three different grafts in nasomaxillary reconstruction of Binder syndrome: an analysis by digitalized measurements". *Plast. Reconstr. Surg.*, 2008, 122, 1524.
- [21] Noyes F.B.: "Case report". *Angle Orthod.*, 1939, 9, 160.
- [22] Olow-Nordenram M., Valentin J.: "An etiologic study of maxillo-nasal dysplasia Binder's syndrome". *Scand. J. Dent. Res.*, 1987, 96, 69.
- [23] Olow-Nordenram M.: "Maxillo-nasal dysplasia (Binder's syndrome). A study of craniofacial morphology, associated malformations and familial relationships". *Swed. Dent. J. Suppl.*, 1987, 47, 1.

- [24] Gross- Kielselstein E., Har- Even Y., Navon P., Brnaski D.: "Familial variant of maxillonasal dysplasia?" *J. Craniofac. Genet. Dev. Biol.*, 1986, 6, 331.
- [25] McCollum A.G., Wolford L.M.: "Binder syndrome: Literature review and long term follow-up on two cases". *Int. J. Adult Orthod. J.*, 2002, 18, 82.
- [26] Deshpande S.N., Juneja M.H.: "Binder's syndrome (maxillonasal dysplasia) different treatment modalities: Our experience". *Indian J. Plast. Surg.*, 2012, 45, 62. doi: 10.4103/0970-0358.96588..
- [27] Horswell B.B., Holmes A.D., Barnett J.S., Lavant B.A.: "Maxillonasal dysplasia: a critical review and case study". *J. Oral. Maxillofac. Surg.*, 1987, 45, 114.
- [28] Olow-Nordernarm M., Valentin J.: "An etiologic study of maxillonasal dysplasia--Binder's syndrome". *Scand. J. Dent. Res.*, 1988, 96, 69.
- [29] Holmström H.: "Surgical correction of the nose and midface in maxillonasal dysplasia (Binder's syndrome)". *Plast. Reconstr. Surg.*, 1986, 78, 568.

Address reprint requests to:
S. MUTLLÓ CANTARELL, M.D.
Av. Marqués de Montoliu nº4 6-6
43002 Tarragona (Spain)
e-mail: silviamutllo@gmail.com

Idiopathic massive fetomaternal hemorrhage in the third trimester of pregnancy causing neonatal death

X. Peng, C. Liu, B. Peng

Department of Obstetrics and Gynecology, West China Second University Hospital, Sichuan University, Chengdu (China)

Summary

Fetomaternal hemorrhage (FMH), which can occur throughout pregnancy, is still a poorly understood clinical condition. It is very difficult to be timely diagnosed and often results in poor pregnancy outcomes. Here the authors reported two rare cases of silent massive FMH of unknown cause in the third trimester of pregnancy, which presented with non-reactive fetal heart rhythm or decreased fetal movement at the very beginning, and resulted in severe fetal anemia and neonatal deaths. A pregnant woman at late pregnancy with a complain of unspecific signs such as decreased fetal movement should arouse a high index of clinical suspicion of idiopathic FMH, and an urgent ultrasound or lab tests detecting FMH could be suggested. Considering emergent delivery versus expectantly management will depend upon acute or chronic FMH, gestational age, results of fetal testing, availability of experienced personnel, and procedural difficulty.

Key words: Fetomaternal hemorrhage; Fetal movement; Fetal anemia; Neonatal death.

Introduction

Fetomaternal hemorrhage (FMH) refers to entry of fetal erythrocyte into maternal circulation during pregnancy, which can cause fetal anemia and maternal hemolysis. It was first proposed by Wienes in 1948 and later was confirmed by Chown in 1954 [1]. Small amount of FMH which is less than 0.1 ml occurs in most pregnancies and it has no effect on fetus. Massive FMH greater than 150 ml can affect the pregnancy outcome by causing severe fetal anemia, unexpected stillbirth, and neonatal death. The perinatal mortality caused by massive FMH is up to 33~50% [1]. However, most cases of FMH are idiopathic or "silent" and may remain undiagnosed until delivery. The authors recently encountered two rare cases of silent massive FMH of unknown cause in the third trimester of pregnancy, which presented with non-reactive fetal heart rhythm or decreased fetal movement at the very beginning, and resulted in severe fetal anemia and neonatal deaths.

Case Report

Case 1, a 27-year-old woman, gravida 1, para 0, was admitted to hospital at 39+5 gestation weeks because of a small amount of vaginal bleeding with no associated abdominal pain or rupture of membrane over the preceding three days. During the pregnancy, there was no complications and exposure to any infectious agent or abdominal trauma or invasive obstetric procedures. Her blood type was A-type, Rh positive, with a recent negative antibodies screening. The cervix was found to be uneffaced and undilated. Repeated fetal cardiotocograph (CTG) after admission showed non-reactive pattern with reduced variability of the baseline but the biophysical profile obtained by ultrasound was normal (score

= 8/8). The fetal movement of maternal perception was normal too. Eighteen hours after admission, the fetal CTG showed non-reactive pattern with sinusoidal wave. The emergency cesarean section under general anesthesia was performed immediately for suspicious fetal distress. Severe meconium stained amniotic fluid was found during the operation. A very pale male infant weighing 3,200 grams was delivered without edema. Apgar scores were 6, 8, and 8 at one, three, and five minutes, respectively. The baby was transferred to the NICU immediately. The arterial pH, hemoglobin level, hematocrit and reticulocytes of the infant at birth were 6.91, 33 g/L, 11.7%, and 22.12%, respectively. The blood type of the baby was AB-type, Rh positive. Meanwhile, the authors found the maternal hemoglobin F (HbF) detected by high-performance liquid chromatography (HPLC) and α -fetoprotein (AFP) were 3.7% and >1000.0 ng/ml, respectively, which were much higher than normal. The estimated FMH volume was 185 ml [2]. The histopathology results of the placenta and umbilical cord were unremarkable. The baby required a number of blood transfusions, and suffered from severe acidosis, electrolyte disturbances, respiratory distress, hepatic failure and disseminated intravascular coagulation. However, the baby showed adverse reaction to the treatments including blood transfusion, fluid expansion, homeostasis correcting, and coagulation rectification, and died 48 hours after birth.

Case 2, a 29-year-old woman, gravida 1, para 0, was admitted to hospital at 38 +3 gestation weeks with decreased fetal movement. Regular prenatal care was normal and her blood type was B-type, Rh positive. She had a history of diminished fetal movement one day before admission without visiting doctor. She had neither abdominal pain, vaginal bleeding nor rupture of membrane. An infant was delivered by emergency cesarean section under general anesthesia two hours after admission because of non-reactive pattern with decreased variability of fetal CTG and low biophysical profile by ultrasound (score = 5/8). Severe meconium stained amniotic fluid was found during the operation. A very pale 2,600-gram female infant was delivered without edema.

Revised manuscript accepted for publication January 12, 2015

Apgar scores were 1, 3, and 5 at one, three, and five minutes, respectively. The baby was transferred to NICU immediately. The arterial pH, hemoglobin level, hematocrit, and reticulocytes of the infant at birth were 7.08, 29 g/L, 9.4%, and 10.11%, respectively. The blood type of the baby was O-type, Rh positive. Maternal HbF detected by HPLC and AFP were 4.3% and 1580.9 ng/ml, respectively, which were significantly higher than normal. The estimated FMH volume was 215 ml [2]. Histological examination of the placenta revealed non-specific chorangiosis, including little intervillous thromboses and calcification lesions. There were no signs of hemorrhage, vascular tumor or intraplacental hematomas. The umbilical cord was normal too. The neonate required intensive treatment, including a number of blood transfusions and ventilator support for severe acidosis, electrolyte disturbances, respiratory distress, hepatic failure, kidney failure, and disseminated intravascular coagulation secondary to massive FMH. The baby was in very serious condition after blood transfusion, fluid expansion, homeostasis correcting, and coagulation rectification. Intensive care was withdrawn at 72 hours after discussion with the parents, due to severe intraventricular hemorrhage.

Discussion

The two cases reported here were both rare massive FMH with unknown reason at late pregnancy which lead to severe fetal anemia and neonatal death. The incidence of massive FMH was estimated ranging from 0.2-0.9 per 1,000 births [3]. The real reason is unknown but it was speculated that a disruption of the trophoblast cell in the fetal-maternal interface may allow a large amount of fetal erythrocytes entering from the higher pressure fetal circulation into the intervillous space where they eventually enter into maternal circulation [2].

The risk factors causing FMH include blood type incompatibility, abdominal trauma, amniocentesis, external cephalic inversion, hypertensive disorders or placental and umbilical cord abnormalities, such as choriocarcinoma [4, 5]. However, the two rare cases reported here are idiopathic in origin, spontaneous, and uncomplicated near-term pregnancies.

Identifying the timing of the onset is very important in the management of FMH. Unfortunately, this issue seems to be unresolved by far. Observational reports suggest that a slow loss of up to 30% of blood volume for fetal can be tolerated and hydrops from anemia (fetal Hgb < 60 g/L) develop for several days (four to six days), while with acute blood loss the chance for fetal damage is significantly higher. Moreover, hyperacute hemorrhage occurring within minutes to an hour before delivery is fatal, and the Hgb and Hct for neonate at birth might be normal [6]. Thus, the lack of hydrops at birth in the two babies, despite a very low Hgb, may give some clues of the timing of the hemorrhage. The authors speculated that the hemorrhage in the two cases occurred within only one or two days before delivery.

Clinical presentations of FMH are frequently uncharacteristic and may be completely overlooked, thus diagnosis remains very difficult and relies mainly on a very high index of clinical suspicion. Decreased or absent fetal movements

was the most common warning presentation. Next, a typical response is to perform a fetal CTG or biophysical profile. A non-reactive pattern of fetal CTG with reduced variability of the baseline has also been described as a presenting CTG abnormality in FHM patients [2]. Sinusoid pattern in fetal CTG and fetal hydrops, traditionally equated with severe fetal anemia, were classic presenting signs. In this study, only case 2 had a decrease of fetal movement, following non-reactive pattern of fetal CTG and low biophysical profile. In case 1, repeated non-reactive pattern of fetal CTG and sinusoid wave in the end prompted an emergent cesarean section, although the fetal movement and biophysical profile were normal after admission. Thus, selective or persistent monitoring of the fetal condition for suspected FMH is necessary. In both cases, there was no observable risk factor leading to massive FMH and it was not suspected by clinical doctor in the first instance and missed during the very moment of rescue. Unfortunately, negative neonatal outcomes were obtained in both cases, although the authors had performed emergency cesarean section as soon as possible and had transferred babies to NICU for the following intensive treatments.

Although rapid diagnosis of FMH may not be available as the clinical presentations are non-specific, the detection of HbF is helpful in the diagnosis and treatment of FMH. HPLC was developed in recent years for the separation and determination the concentration of HbF in maternal circulation, which is much more simple, rapid, and effective than the standard K-B test [7]. Maternal serum concentration of α -AFP is another simple and easy-detecting index of diagnosing FMH, but the levels vary significantly during pregnancy [8]. The concentrations of HbF and AFP in both cases of this report were significantly higher than normal, and massive FMH were confirmed by perinatal outcome. The value of Doppler sonography for the fetal middle cerebral artery (MCA) has been proven to predict fetal anemia recently. An increase of fetal middle cerebral artery peak systolic velocity (MCA-PSV) was considered as the sign of moderate or severe fetal anemia because of increased cardiac output and declined blood viscosity [4, 9]. However, these two cases were unsuspected for FMH at the very beginning, resulting in the MCA-PSV that was not timely examined. These cases raised the recommendation to all patients in the third trimester of pregnancy presenting with decreased fetal movements, and repeated abnormal fetal CTG or low biophysical score of unknown reason should have a HbF test for mother or MCA-PSV performed for fetus to identify silent FMH.

In summary, the authors report two rare cases of neonatal deaths of full term fetuses with uneventful antenatal periods, where idiopathic massive FMH was an unexpected finding. FMH is still a poorly understood clinical condition. A pregnant woman in late pregnancy with a complaint of unspecific signs such as decreased fetal movement should always be referred to hospital for fetal testing (fetal CTG, biophysical profile or both). An abnormality on fetal

testing with unknown reasons should arouse clinical suspicion of FMH, and an urgent ultrasound or lab tests detecting FMH should be suggested. Once diagnosis is suspected, appropriate management, for example, considering emergent delivery versus expectantly management will depend upon acute or chronic FMH, gestational age, status of fetal testing, availability of experienced personnel, and procedural difficulty [2]. Given the inherent unpredictability of FMH and its potential for perinatal death, delivery should be considered when the risks of continuing the pregnancy appear to outweigh the risks of prematurity.

Acknowledgements

The present work was supported by the National Natural Science Foundation of China, Beijing, China (Grant number 81070460), and the Applied Basic Research Programs of the Scientific and Technological office of Sichuan Province (2015JY0134).

References

- [1] Sebring E.S., Polesky H.F.: "Fetomaternal hemorrhage: incidence, risk factors, time of occurrence, and clinical effects". *Transfusion*, 1990, 30, 344.
- [2] Wylie B.J., D'Alton M.E.: "Fetomaternal hemorrhage". *Obstet. Gynecol.*, 2010, 115, 1039.
- [3] de Almeida V., Bowman J.M.: "Massive fetomaternal hemorrhage: Manitoba experience". *Obstet. Gynecol.*, 1994, 83, 323.
- [4] Kawano R., Takemoto S., Shimamatsu K., Hori D., Kamura T.: "Fetomaternal hemorrhage with intraplacental chorioangioma". *J. Obstet. Gynaecol. Res.*, 2013, 39, 583.
- [5] Mahendru A., Gajjar K., Bashir T.: "Idiopathic chronic fetomaternal haemorrhage presenting with reduced fetal movements". *J. Obstet. Gynaecol.*, 2007, 27, 848.
- [6] Christensen R.D., Lambert D.K., Baer V.L., Richards D.S., Bennett S.T., Ilstrup S.J., Henry E.: "Severe neonatal anemia from fetomaternal hemorrhage: report from a multihospital health-care system". *J. Perinatol.*, 2013, 33, 429.
- [7] Chambers E., Davies L., Evans S., Birchall J., Kumpel B.: "Comparison of haemoglobin F detection by the acid elution test, flow cytometry and high-performance liquid chromatography in maternal blood samples analysed for fetomaternal haemorrhage". *Transfus. Med.*, 2012, 22, 199.
- [8] Kim Y.A., Makar R.S.: "Detection of fetomaternal hemorrhage". *Am. J. Hematol.*, 2012, 87, 417.
- [9] Cosmi E., Rampon M., Saccardi C., Zanardo V., Litta P.: "Middle cerebral artery peak systolic velocity in the diagnosis of fetomaternal hemorrhage". *Int. J. Gynaecol. Obstet.*, 2012, 117, 128.

Address reprint requests to:

B. PENG, M.D.

Department of Obstetrics and Gynecology
West China Second Hospital, Sichuan University
No. 20, 3rd Section, South Renmin Road
Chengdu 610041, Sichuan (China)
e-mail: pengbin-a111@163.com

A rare occurrence of three consecutive autosomal trisomic pregnancies in a couple without offspring

F. Burada^{1,2}, S. Sosoi², D. Ilescu³, M. Ioana², D. Cernea³, S. Tudorache³

¹Department of Medical Genetics, University of Medicine and Pharmacy from Craiova, Craiova

²Human Genomics Laboratory, University of Medicine and Pharmacy from Craiova, Craiova

³Department of Obstetrics and Gynecology, Prenatal Diagnostic Unit, University of Medicine and Pharmacy Craiova, Craiova (Romania)

Summary

Background: Trisomies are the most common chromosomal abnormalities, being a major cause of pregnancy loss in the first trimester. Data from preimplantation embryos support the concept of recurrent aneuploidy in women with recurrent abortion. **Case:** The authors report a rare case with three different consecutive trisomic pregnancies: 47,XY,+21, 47,XX,+9, and 47,XX,+18. All pregnancies resulted from the same relationship and no consanguinity was present. Standard clinical cytogenetic analysis indicated that both members had normal peripheral blood karyotype, with no evidence of mosaicism in either patient or her partner. **Conclusion:** The present report supports the hypothesis that some women have a higher risk for nondisjunction than others of the same age. Counseling a couple with recurrent trisomies is difficult and future research on genetics of cell division are required to assist them.

Key words: Recurrent trisomies; Pregnancy; Prenatal ultrasound; Meiosis nondisjunction.

Introduction

Trisomies are the most common chromosomal abnormalities in human pregnancy and occur in approximately 4% of clinically recognized pregnancies. Moreover, 30% of spontaneous miscarriages caused by numerical chromosome abnormalities have a trisomy and it is associated with increased maternal age, rising from very low incidence at age 20–24 up to 35% at age 40–44 years. This chromosomal imbalance is usually not compatible with life and will result in a miscarriage in the first trimester in most cases, making it the leading cause of pregnancy loss in this period [1, 2]. Only three autosomal trisomies [13, 18, 21] and the three sex chromosome trisomies (XXY, XXX, and XYY) are compatible with live birth. Data from preimplantation embryos support the concept of recurrent aneuploidy in women with recurrent abortion [3]. The authors report a rare case with three different consecutive autosomal trisomic pregnancies in a couple with normal karyotype and no living offspring.

Case Report

A 40-year-old woman, gravida 2, para 0, was referred to Prenatal Diagnostic Unit (PDU), Emergency University Hospital, Craiova, Romania for the first trimester genetic, extended structural sonographic evaluation and genetic counseling. The patient had no medical or surgical history. The pregnancy evolution was clinically normal up to this point. Detailed two-dimensional, three-dimensional, and four-dimensional ultrasound examination was performed, using a Voluson 730 E8 machine at 11+6 weeks

of amenorrhea. Corpus luteum was present on the right ovary. Many abnormalities were noted in terms of genetic markers and structural features: generalized subcutaneous edema, large nuchal translucency (9.7 mm), absent nasal bone (Figures 1a and 1b), and facial angle (90.78°). The cardiac sweep was consistent with complete atrio-ventricular septal defect data. Also spatial-temporal image correlation datasets were obtained. Spectral Doppler interrogation showed holosystolic regurgitation at the site of the common A-V valve and absent a wave at the site of Arantius ductus venosus. Normal images were obtained in terms of: intracranial translucency value, choroid plexus symmetry, anterior bony palate, orbits, surface rendering face, abdominal insertion of umbilical cord, situs, stomach image, diaphragm, spine, bilateral limbs, bladder, three-vessels cord, amniotic fluid, cervical length, uterine arteries pulsatility index. Crown-rump length (CRL) was consistent with menstrual dates (55.4 mm). She was screened positive for trisomy 21 at the combined test. After counseling, the couple accepted the invasive maneuver (chorionic villus sampling). Conventional karyotyping confirmed trisomy 21 (Figure 2a) and the couple requested surgical termination of pregnancy (TOP). The evolution after TOP was uneventful.

After eight months, the patient self-referred to the PDU for another dating scan, at 9+6 WA, after several days of vaginal spotting. The examination revealed missed abortion: medium gestational sac (GS) diameter 20 mm (corresponding at 6+3WA), opaque yolk sac (YS), and no visible embryo (Figure 1c). Corpus luteum present on the left ovary. TOP by aspiration technique was performed, with normal postoperative evolution. Cytogenetic analysis of product of conception showed a non-mosaic trisomy 9 pattern (karyotype 47,XX,+9) (Figure 2b).

After another three months, the patient presented again to the PDU, for a new pregnancy dating scan, at 10+0 WA. The CRL of the embryo was 22.5 mm (corresponding to 9+0 weeks embryo) and the embryonic heart rate was 178 beats/minute. There was a normal

Revised manuscript accepted for publication December 10, 2014

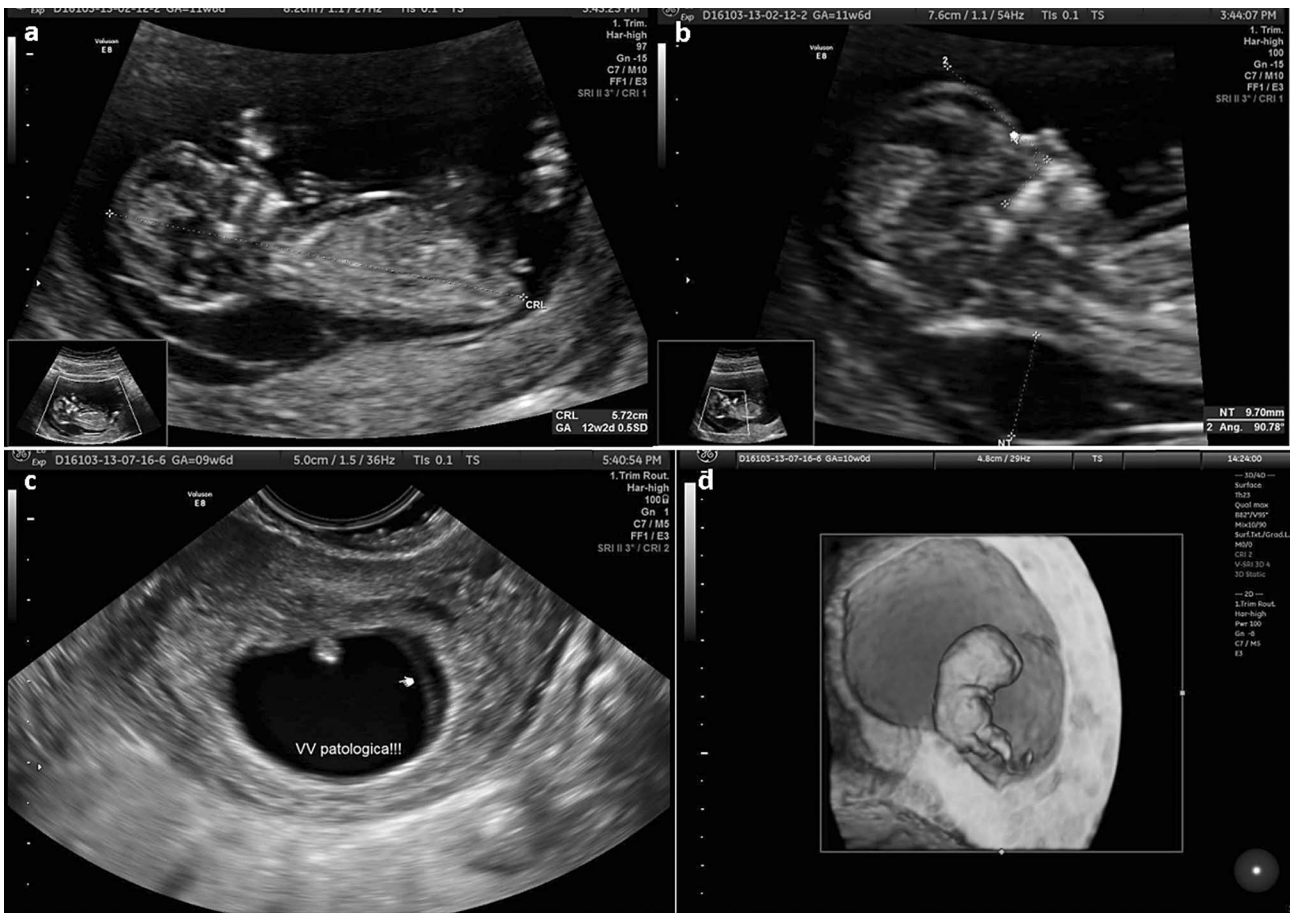

Figure 1. — a) Sagittal section of the fetus, crown-rump length measurement. Generalized subcutaneous edema. b) Fetal profile: absent nasal bone, large nuchal translucency, and abnormal facial angle. c) Missed abortion: small gestational sac, opaque yolk sac, and no visible embryo. d) Recent embryonic demise (9+5 WA), three-dimensional surface rendering of the gestational sac, amniotic cavity and embryo, normal cephalic/trunk differentiation, and normal limbs. No heart motion was present.




Figure 2. — Partial karyotypes: a) Trisomy 21, b) Trisomy 9, and c) Trisomy 18.

cephalic/trunk differentiation, the limbs were normal, a normal looking extraembryonic coelomic and amniotic cavity were found (Figure 1c). The GS had a normal aspect and tonus, the medium diameter was slightly smaller than expected (52.1 mm), the YS had normal ultrasound features (spherical, anechoic, diameter 5.6 mm). The normal topography (fundal) of the trophoblastic tissue and the normal (central) insertion of the umbilical cord was noted. The cervical length and the uterine arteries velocities were also normal.

After nine days, the patient requested re-examination in the PDU, due to decreased pregnancy subjective symptoms (nausea and engorgement). The scan showed recent embryonic demise (CRL 28.6 mm, corresponding at 9+5WA). TOP was again performed. The conventional G banding analysis from product of conception revealed trisomy 18 in all cells (Figure 2c).

Discussion

The authors report a rare case with three different consecutive trisomic pregnancies. All pregnancies resulted from the same relationship. The couple was healthy and no consanguinity was present. Standard clinical cytogenetic analysis

indicated that both parents had normal peripheral blood karyotype, with no evidence of mosaicism in either patient or her partner.

At the first trisomy (47,XY,+21), the father was 31-years-old, and the mother 40-years-old. Eight and 11 months later, they had two pregnancies that ended spontaneously at nine to ten weeks of gestation: 47,XX,+9 and 47,XX,+18.

Despite the high frequency of human aneuploidy and advances in genetic analysis, less is known about the factors that modulate the recurrence risk. It was stated that trisomy recurrence can occur through three possible mechanisms: chance alone due mainly to maternal age, parental mosaicism or meiotic errors that increase rates of chromosome nondisjunction.

In the present case, the first pregnancy was affected by trisomy 21 and occurred in a 40-year-old mother. The risk of a subsequent trisomy 21 after a previous pregnancy with trisomy 21 is known to be increased, but is still unclear whether the risk of other trisomies runs in a similar way. The recurrence risk is dependent by the maternal age at the first affected pregnancy, and appears to be greater in younger women than older women [4, 5]. The recurrence risk for 21 is more increased than the age-related for a future pregnancy if the previous trisomy 21 pregnancy occurs in more than 30-year-old mothers. Robinson *et al.* investigated 54 couples with recurrent aneuploidy generally involving different chromosomes and found that the mean maternal age at the time of spontaneous abortion with chromosomal abnormality was 38 years, suggesting that increased maternal age was the major predisposing factor [6].

Also, the risk for the same trisomy subsequent to trisomy 13 or 18 appears to be increased [5, 7]. Warburton *et al.* reported a significantly increased risk of different trisomies following a trisomy 21 diagnosis. The standard morbidity ratio (SMR) was 2.3 for heterotrissomy, after an index trisomy 21, regardless of maternal age at the first trisomy. After a nonviable trisomy diagnosed in a spontaneous abortion, the SMR for a viable trisomy at prenatal diagnosis in a subsequent pregnancy was 1.8. Furthermore, they also found that following any of trisomy 13, 18, or 21, XXX or XXY, the risk of a different trisomy was significantly increased, supporting the hypothesis that some women have a higher risk for nondisjunction than others of the same age [7].

Parental gonadal mosaicism is a condition in which the precursors to gametes contain a mixture of two or more genetically different populations, one population of cells containing the normal genetic material, while the other contains a DNA mutation or chromosome anomaly.

Parental gonadal mosaicism could explain an increased risk of subsequent pregnancies of the same chromosome (homotrissomy), although it cannot explain an increased recurrence risk for a different trisomy (heterotrissomy) [8, 9].

In the present case the subsequent next two pregnancies were affected by autosomal heterotrissomy: trisomy 9 and trisomy 18, and parental gonadal mosaicism for trisomy

could be ruled out. Mosaicism may be difficult to diagnose due to its low level or tissue-specific distribution: the trisomic cell line is sometimes documented only in ovary biopsies or germ cells, while other tissues (blood lymphocytes and skin) appear diploid [10, 11]. A father with elevated frequencies of correspondingly aneuploid sperm was identified in a family with four consecutive trisomic pregnancies: 47,XXY and 47,XYY were live births; 47,XX,+15 and 47,XX,+22, that were spontaneously aborted over a three-year period [12]. The parental origin of extrachromosome was determined only in the XXY child, by molecular methods. The extra Y was presumably derived from a paternal meiotic error, and for both autosomal trisomies the origin has not been established. Aneuploid sperm are present in low frequencies in most healthy men [13] and an increased risk associated with high frequencies of aneuploid sperm was found in some recurrent trisomies [12, 14, 15]. These findings suggest that in some rare cases recurrent trisomic pregnancies may have a paternal basis.

Meiotic nondisjunction is the mechanism leading to the majority of trisomy and in most cases occurs by chance. Autosomal trisomies are predominantly of maternal origin, while sex chromosomal trisomies have substantial paternal origins [16]. The risk to nondisjunction increases with advancing maternal age and seems to be more frequent in women over the age of 35. Mutations in genes that control oocyte maintenance and meiosis, variations in recombination frequency, genetic changes such as mitochondrial deletions, and aging processes in the ovary may increase predisposition to meiotic errors [1, 9].

In the present case, the authors suggest that factors associated with an increased risk of meiotic errors are involved in recurrence of different trisomies and the supplementary chromosome in all three pregnancies arose in maternal meiosis. Their hypothesis is supported by two studies, which found in almost all trisomies of recurrent pregnancies the error was of maternal origin, whereas paternal errors account for 7% of meiotic origin trisomies among spontaneous abortions [6, 17].

In conclusion, the present report supports the hypothesis that some women have a higher risk for nondisjunction than others of the same age. A closer supervision of women who have had one trisomic pregnancy is necessary based on their history alone. Counseling a couple with recurrent trisomies is difficult and future research on genetics regarding meiosis is required to assist them.

References

- [1] Warburton D.: "Biological aging and the etiology of aneuploidy". *Cytogenet. Genome Res.*, 2005, 111, 266.
- [2] ESHRE Capri Workshop Group: "Genetic aspects of female reproduction". *Hum. Reprod. Update.* 2008, 14, 293.
- [3] Rubio C., Buendia P., Rodrigo L., Mercader A., Mateu E., Peinado V., *et al.*: "Prognostic factors for preimplantation genetic screening in repeated pregnancy loss". *Reprod. Biomed. Online.* 2009, 18, 687.

- [4] Morris J.K., Mutton D.E., Alberman E.: "Recurrences of free trisomy 21: analysis of data from the National Down Syndrome Cytogenetic Register". *Prenat. Diagn.* 2005, 25, 1120.
- [5] De Souza E., Halliday J., Chan A., Bower C., Morris J.K.: "Recurrence risks for trisomies 13, 18, and 21". *Am. J. Med. Genet. A.*, 2009, 149A, 2716.
- [6] Robinson W.P., McFadden D.E., Stephenson M.D.: "The origin of abnormalities in recurrent aneuploidy/polyploidy". *Am. J. Hum. Genet.* 2001, 69, 1245.
- [7] Warburton D., Dallaire L., Thangavelu M., Ross L., Levin B., Kline J.: "Trisomy recurrence: a reconsideration based on North American data". *Am. J. Hum. Genet.* 2004, 75, 376.
- [8] Hulten M.A., Patel S.D., Tankimanova M., Westgren M., Papadogiannakis N., Jonsson A.M., *et al.*: "On the origin of trisomy 21 Down syndrome". *Mol. Cytogenet.*, 2008, 1, 21.
- [9] Bianca S., Ingegnosi C., Cataliotti A., Ettore G.: "Multiple aneuploidy recurrence risk". *Am. J. Med. Genet. A.* 2006, 140A, 1888.
- [10] Nielsen K.G., Poulsen H., Mikkelsen M., Steuber E.: "Multiple recurrence of trisomy 21 Down syndrome". *Hum. Genet.* 1988, 78, 103.
- [11] Cozzi J., Conn C.M., Harper J., Winston R.M., Rindl M., Farndon P.A., *et al.*: "A trisomic germ cell line and precocious chromatid segregation leads to recurrent trisomy 21 conception". *Hum. Genet.* 1999, 104, 23.
- [12] Tomascik-Cheeseman L.M., Lowe X.R., Eskenazi B., Kidd S., Nath J., Moore D. 2nd, *et al.*: "A father of four consecutive trisomic pregnancies with elevated frequencies of associated aneuploid sperm". *Am. J. Med. Genet. A.* 2006, 140A, 1840.
- [13] Eskenazi B., Wyrobek A.J., Kidd S.A., Lowe X., Moore D. 2nd, Weisiger K., *et al.*: "Sperm aneuploidy in fathers of children with paternally and maternally inherited Klinefelter syndrome". *Hum. Reprod.* 2002, 17, 576.
- [14] Morton N.E., Chiu D., Holland C., Jacobs P.A., Pettay D.: "Chromosome anomalies as predictors of recurrence risk for spontaneous abortion". *Am. J. Med. Genet.* 1987, 28, 353.
- [15] Carrell D.T., Wilcox A.L., Lowy L., Peterson C.M., Jones K.P., Erickson L., *et al.*: "Elevated sperm chromosome aneuploidy and apoptosis in patients with unexplained recurrent pregnancy loss". *Obstet. Gynecol.* 2003, 101, 1229.
- [16] Lamb N.E., Hassold T.J.: "Nondisjunction--a view from ringside". *N. Engl. J. Med.* 2004, 351, 1931.
- [17] Robinson W.P., Bernasconi F., Lau A., McFadden D.E.: "Frequency of meiotic trisomy depends on involved chromosome and mode of ascertainment". *Am. J. Med. Genet.* 1999, 84, 34.

Address reprint requests to:

F. BURADA, M.D, PhD.

Department of Medical Genetics

University of Medicine and Pharmacy of Craiova

2-4 Petru Rares Street

200349 Craiova (Romania)

e-mail: buradaflorin@gmail.com

Successful conservative treatment of a cervical ectopic pregnancy at 13 weeks

S. Kadija^{1,2}, A. Stefanovic^{1,2}, K. Jeremic^{1,2}, M. Radojevic², R. Cerovic-Popovic², M. Srbinovic²,
I. Likic-Ladjevic^{1,2}

¹ Faculty of Medicine, University of Belgrade, Belgrade; ² Clinic for Gynecology and Obstetrics, Clinical Center of Serbia, Belgrade (Serbia)

Summary

Background: Cervical ectopic pregnancy is a potentially life-threatening condition due to the unexpected occurrence of uncontrollable bleeding from the cervix. **Case Report:** A 39-year-old secundigravida was admitted with amenorrhea of 12 weeks and four days due to suspected cervical pregnancy, without bleeding. The ultrasonography revealed a gestational sac at the anterior wall of the isthmic-cervical part with a single viable fetus, with crown-rump length (CRL) of 59 mm and regular heart rate. The serum β -human chorionic gonadotropin (β -hCG) level on admission was 143.416 mIU/l. Two possible therapeutic options were considered, (1) systemic methotrexate treatment and (2) uterine artery embolization with gelatine sponge. The first was rejected due to gestational age, viable fetus, high β -hCG level, and CRL, and the later was rejected by the vascular surgeons due to lack of experience. The curettage was performed. After the evacuation, prostin was administered into cervix accompanied with tamponade. On the next day β -hCG level was 44.342 mIU/l and the following day ultrasonography revealed the oval non-homogenous formation in the cervical cavity (blood clots or residual trophoblastic tissue); β -hCG level was 36.501 mIU/l. The reintervention was performed on the fifth day after the curettage and 200 ml of coagulated blood was aspirated; β -hCG level was 16.432 mIU/l. Since the isthmic-cervical part was slightly dilated (23 mm) seven days after the curettage, systemic methotrexate treatment (100 mg intramuscular) was initiated. Serum β -hCG level on the second and fourth day after methotrexate were 12.553 mIU/l and 8,900 mIU/l, respectively. The second dose of 100 mg of methotrexate was administered intramuscular seven days after the first dose. Three days after, β -hCG level was 2.329 U/l and ultrasound scan revealed normal isthmic-cervical finding. **Conclusion:** The present case report showed efficient fertility sparing conservative treatment, dilatation and curettage, of 13 week cervical pregnancy followed by systemic methotrexate.

Key words: Cervical ectopic pregnancy; Fertility-sparing treatment.

Introduction

Cervical ectopic pregnancy is a potentially life-threatening condition due to unexpected occurrence of uncontrollable bleeding [1]. The incidence of cervical ectopic pregnancy is very low ranging from 0.005% to 0.1% [2]. The etiology of cervical pregnancy is unclear. Potential contributing factors are the following: previous curettage, Asherman's syndrome, previous cesarean delivery, previous uterine or cervical surgery, in vitro fertilization, and older maternal age [3].

Case Report

A 39-year-old secundigravida was admitted to the Intensive Care Unit with amenorrhea of 12 weeks and four days due to suspected cervical pregnancy. Patient had previous cesarean delivery five years prior to admission. She was referred from regional hospital where cervical pregnancy had not been recognized in sixth gestational week during evaluation of mild vaginal bleeding, and progesterone had been administered. At admission to the present authors' department, patient complained of mild pelvic pain and pressure. Vaginal examination showed regular-sized cervix, no bleeding, and closed external

cervical os. The transvaginal ultrasonography revealed a gestational sac in isthmic-cervical part with a single viable fetus, with crown-rump length (CRL) of 59 mm and regular heart rate and obvious movements. Chorion was invading anterior cervical wall. Cesarean section scar on front isthmical wall was neat. Uterine cavity revealed thick endometrium without gestational sac. The serum β -human chorionic gonadotropin (β -hCG) level on admission was 143.416 mIU/l. Escherichia coli and Candida were isolated from cervical and vaginal smears, so adequate systemic antibiotics were administered.

Since the patient had strong desire for preserving the uterus and her condition was not life threatening, the authors considered possible conservative treatments. After revising the literature, no study with satisfactory outcome after conservative treatment of cervical pregnancy of this gestational age was found, hence the authors were considering two possible therapeutic options. One of them was systemic methotrexate treatment and the other was uterine artery embolization with gelatine sponge. Vascular surgeons were consulted but the proposition was rejected since they had no experience with such technique and they were concerned about the outcome and potential complications. Since patient's condition became unstable, considering all relevant facts, the authors could only try to perform curettage being aware of possible massive bleeding and potential hysterectomy. Before the procedure, patient was informed about all potential complications and written consent was obtained.

Revised manuscript accepted for publication January 12, 2015

On obtaining sterile smears, controlled by transabdominal ultrasonography, cervical and uterine cavity dilatation and curettage was performed and the fetus and most of the trophoblastic tissue were evacuated. The intraoperative assessment indicated high risk for uterine perforation on the caesarian scar, therefore the evacuation was aborted although the entire trophoblastic tissue had not been evacuated. Several single sutures were placed on implantation site and prostin was administered into cervix accompanied with cervical and vaginal tamponade. Systemic wide-spectrum antibiotics and uterotonic drugs (oxytocin and methylergometrine) were administered. On the day following the curettage, β -hCG level was 44.342 mIU/l. Two days after the curettage, transvaginal ultrasonography suggested that cervical cavity was filled with oval non-homogenous formation sized 38 x 23 mm, featuring blood clots or residual trophoblastic tissue; β -hCG level was 36.501 mIU/l. Since the ultrasonographic finding was the same five days after the curettage, it was decided to perform reintervention and approximately 200 ml of coagulated blood was aspirated; β -hCG level was 16.432 mIU/l. Two days after the second intervention (seven days after curettage), isthmic-cervical part was slightly dilated (23 mm) and filled with non-homogenous content, so systemic methotrexate treatment (100 mg intramuscular) was initiated. Serum β -hCG level was decreasing during the second and fourth day after methotrexate administration and were 12.553 mIU/l and 8.900 mIU/l, respectively. Since ultrasound scan seven days after the first dose of methotrexate revealed that non-homogenous formation was still present although less, the second dose of 100 mg of methotrexate was administered. Three days after the second methotrexate dose, β -hCG level was 2.329 U/l and ultrasound scan revealed normal isthmic-cervical finding. Subsequent monitoring showed a steady decline of β -hCG values, which dropped below detectable limits a month after the procedure, and also by that time, the woman had her next menstrual period. At the moment, the patient is under oral contraceptive therapy and it is planned that this treatment is to last for six months.

Discussion

Because cervical pregnancy is so infrequent, no randomized controlled trials of treatment options exist. Case reports may add new knowledge, particularly on new ways of minimizing the risk of hysterectomy. Most patients with cervical ectopic pregnancy are women with low parity; thus, the current treatment tendency is to preserve reproductive function. The main problem with nonsurgical treatment of cervical ectopic pregnancy is the possibility of a life-threatening hemorrhage before or after pregnancy evacuation [4].

The goal of methotrexate administration is to selectively kill the cytotrophoblastic tissue of ectopic pregnancy while preserving fertility. The single dose protocol describes the administration of 50 mg/m² of methotrexate given by intramuscular injection without the use of leucovorin. The reported success rate of systemic methotrexate administration differs among various authors. Presence of fetal cardiac activity, CRL greater than ten mm, gestational age greater than nine weeks, and initial serum hCG levels greater than 10,000 mIU/ml have been considered as poor prognostic factors with high failure rates. However, ex-

ceptions have been described, and some authors suggest that it may be worthwhile to start treatment with intramuscular methotrexate [5, 6].

Embolization of the uterine artery has been well described and may be the best option of treatment of cervical pregnancy, which does not respond to systemic methotrexate, even up to 12 weeks of gestation [7]. Embolization with gelfoam considerably reduces circulation in the catheterized region for about 24 hours and provides only temporary occlusion of the vessel for two to six weeks. It is often done bilaterally, but unilateral embolization can be used when angiography indicates unequal disposition of the arterial connections supplying the embryo. This may be preferable because less pelvic pain and fewer cases of temporary or consistent amenorrhea as the sequel of tissue ischemia occur [8]. All patients usually experience some degree of cramp pelvic pain after the embolization procedures, mostly on the first day, resolving within a week. Most of the women conceived after this procedure and delivered healthy newborns at term. Cervical dilatation and curettage performed after uterine artery embolization provides more secure removal of the pregnancy, shortens follow-up, and reduces cost. Initial angiographically directed embolization reduces the risks for the surgical procedure and appears to be the method of choice when treatment with methotrexate fails [9].

Since no study with satisfactory outcome after conservative treatment of cervical pregnancy of this gestational age was found, hCG level was greater than 10,000 (143.416 mIU/l), CRL was greater than ten mm (59 mm) and amenorrhea was greater than nine weeks (13 weeks), the authors excluded the possibility of treatment with methotrexate, as a single strategy and prior to surgical evacuation, and decided to attempt dilation and curettage.

Conclusion

The present case report showed that conservative treatment, dilatation and curettage, of 13-week cervical pregnancy followed by methotrexate administration was efficient. Reproductive ability of the patient was preserved, which was the main goal.

References

- [1] Nadisauskiene R., Vaicekavicius E., Taraseviciene V., Simanaviciute D.: "Conservative treatment of cervical pregnancy with selective unilateral uterine artery embolization". *Medicina (Kaunas)*, 2007, 43, 883.
- [2] Pantelis A., Daniilidis A., Dinas K.: "Conservative treatment of a 7 week cervical ectopic pregnancy after intra-uterine insemination". *Hippokratia*, 2013, 17, 95.
- [3] Hirakawa M., Tajima T., Yoshimitsu K., Irie H., Ishigami K., Yahata H. *et al.*: "Uterine artery embolization along with the administration of methotrexate for cervical ectopic pregnancy: technical and clinical outcomes". *AJR Am. J. Roentgenol.*, 2009, 192, 1601.

- [4] Heikinheimo O., Leminen A., Cacciatore B., Rutanen E.M., Kajanoja P.: "Advanced cervical pregnancy: uterus sparing therapy initiated with a combination of methotrexate and mifepristone followed by evacuation and local hemostatic measures". *Acta Obstet. Gynecol. Scand.*, 2004, 83, 211.
- [5] Zakaria M.A., Abdallah M.E., Shavell V.I., Berman J.M., Diamond M.P., Kmak D.C.: "Conservative management of cervical ectopic pregnancy: utility of uterine artery embolization". *Fertil. Steril.*, 2011, 95, 872.
- [6] Moon H.S., Hyun J.H., Kim K.S., Kim H.J., Moon S.E., Koo J.S.: "Use of Tuohy needle for intraamniotic methotrexate injection through the cervical canal in a cervical pregnancy after failure of systemic methotrexate therapy". *Am. J. Obstet. Gynecol.*, 2010, 202, e4.
- [7] Burbank F.: "History of uterine artery occlusion and subsequent pregnancy". *AJR Am. J. Roentgenol.*, 2009, 192, 1593.
- [8] Chaudhary V., Sachdeva P., Kumar D., Arora R., Banavaliker J., Khan M.: "Conservative management of cervical pregnancy: a report of two cases". *J. Reprod. Med.*, 2013, 58, 451.

Address reprint requests to:
S. KADIJA, M.D.
Clinic for Gynecology and Obstetrics
Clinical Center of Serbia
Koste Todorovica 26
11000 Belgrade (Serbia)
e-mail: sasha.kadija@gmail.com

Abdominal lithopedion formation with 30 years of evolution: report of a case

Yali Yang^{1,2}, Hong Zhou³, Jin Guo¹, Wei Su⁴, Hong Shen²

¹Department of Pathology, Second People's Hospital of Yunnan Province, Kunming; ²Department of Pathology, School of Basic Medical Science, Southern Medical University, Guangzhou; ³Department of Teaching Affairs, Second People's Hospital of Yunnan Province, Kunming; ⁴Department of Ultrasound, Second People's Hospital of Yunnan Province, Kunming (China)

Summary

The incidence of abdominal pregnancy is very rare, long-retained abdominal pregnancy undergoing fetal death and evolving to a lithopaedion is even more scarce. The authors report the case of a 60-year-old woman who discovered an abdominal mass 31 years ago that was recently identified intraoperatively as lithopaedion. Although imaging had revealed a low-level echogenic mass in the cavity, nobody had considered the possibility of a lithopaedion before the operation. The authors strongly suggest identifying the small skeletal frame through imaging that will be a very important preoperative sign that will lead to a diagnosis, otherwise neglected in the past years.

Key words: Abdominal lithopedion; Fetal death; Calcification.

Introduction

Lithopaedion (stone baby) is the name given to an extrauterine pregnancy that evolves to fetal death and calcification. Litho means “stone” and pedion means “child”, hence the term lithopedion explains its pathomechanism. The authors report the case of a 60-year-old woman who discovered an abdominal mass 31 years ago and recently identified intraoperatively as lithopaedion.

Case Report

A 60-year-old, gravidity 3, para 3, woman was admitted to the present hospital with complaint of an abdominal mass. She had a uterine-incision delivery in 1979 and had been menopausal for 31 years, when the abdominal mass was discovered in 1982. Physical examination revealed a hard mass sized in 10 x 8 cm in the right of the lower abdomen, with tenderness. The women had not complained of augmentation of the mass for years, which was accompanied with a weight sensation, and an aching in inferior belly and pars sacralis. She did not receive regular treatment until this hospitalization. Her pain was relieved after taking some medication. The abdominal X-ray and computerized tomography (Figure 1) showed the presence of a low-level echogenic mass in the right pelvic cavity (10.8 x 8.8 cm); teratoma and ectopic pregnancy were not excluded. Her gynecologic history included regular menstrual bleeding before menopause. The gynecologic examination revealed a solid, obscure activity mass in right adnexa, sized in 10 x 8 cm. The physical examination revealed slight tenderness but not rebound tenderness.

On gross pathologic examination, the mass showed as an oval tumor with a stony, hard calcified capsule. After cutting it, there were costal bone, cranium, limbs long bones and yellow muddy

fluid (Figure 2). After decalcification, the mass was sectioned and found to be composed of mummified tissues includes bones, muscles, skin, and cartilage, identified as a lithopedion (Figure 3).

Discussion

Lithopedion is the result of an undiagnosed and untreated dead fetus in the abdominal. The dead fetus dries up and calcifies, which then generates a solid mass referred to as lithopaedion. The lithopedion can be retained decades of years (four to 60 years) in the maternal abdominal cavity. The age of patients on the date of diagnosis varied greatly from 23 to 100 years [1], often being older than 40 years. Fetal death occurs between the third month to full term of pregnancy which can then evolve into a lithopedion.

Lithopedions are generated within following specific conditions: (1) the pregnancy is extrauterine: includes tubal, ovarian, intra-abdominal, and horn pregnancies; (2) fetal death occurs after three months of pregnancy: if it occurs earlier than the third month while the fetal bones are cartilaginous, it will be absorbed completely; (3) fetal death is sterile: if it becomes infected then it will be absorbed; (4) fetal death is not diagnosed and treated on time; (5) local conditions exist for calcium precipitation and deposit [2, 3]. Then the fetal death will cause dehydration and calcification evolving into a lithopedion.

Lithopedion are classified into three subtypes according to the calcified position of the membranes and the

Revised manuscript accepted for publication December 18, 2014

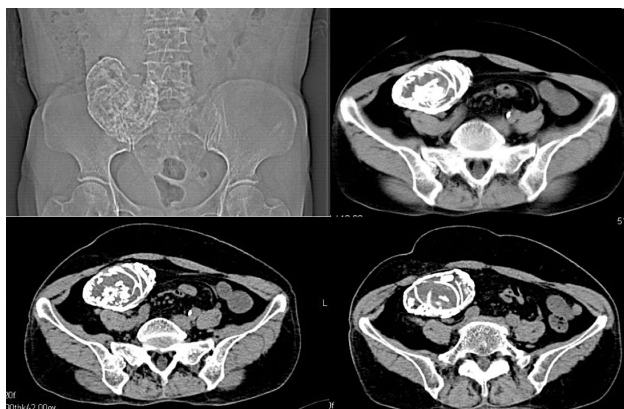


Figure 1. — Abdominal X-ray and computerized tomography showing a low-level echogenic mass in the right pelvic cavity.

fetus [4]: (1) lithokelyphos: only the membranes are calcified; (2) lithokelyphopedion: both the membranes and the fetus are calcified; (3) true lithopedion/lithotecnon: only the fetus is calcified. This latter subtype belongs to the first subtype since the lithopaedion has only calcified membranes.

In most cases the diagnosis of lithopedion is confused until an operation is performed. An ultrasound will reveal a low-level echogenic mass which will be diagnosed as ovarian tumours, myomas, inflammatory masses, epiploon calcifications, and urinary tract or bladder tumours. It is very difficult to diagnose lithopedion before operation since it often shows as mass in the abdomen. Although the clinical history will give some clues on its diagnosis, almost all reported cases were diagnosed only intraoperatively or postoperatively. In this case, after carefully studying the computerized tomography images, the authors discovered the skeletal frame of small size which could be clearly seen, especially the costal bones (Figure 1). This will be a very important sign for diagnosis before an operation is performed. Because both the lithokelyphopedion and the true lithopedion types retain the fetal figure remarkable well by calcifying it, not to mention that the bones are dramatically well-preserved. As for the lithokelyphos type, which has only calcified membranes, the bones can also be well-preserved since bone substance is quite stable for many years after fetal death just as in the present case. This will also be a very important sign for a diagnosis before an operation is performed.

Most cases present with an asymptomatic evolution until it is occasionally found; some with a palpable abdominal or pelvic masses, may have weight sensation in the abdomen, pelvic pain, compressive urinary bladder, and rectal symptoms. The lithopedion retained in the ab-



Figure 2. — Gross pathologic examination showing an oval tumor with a stony, hard calcified capsule.

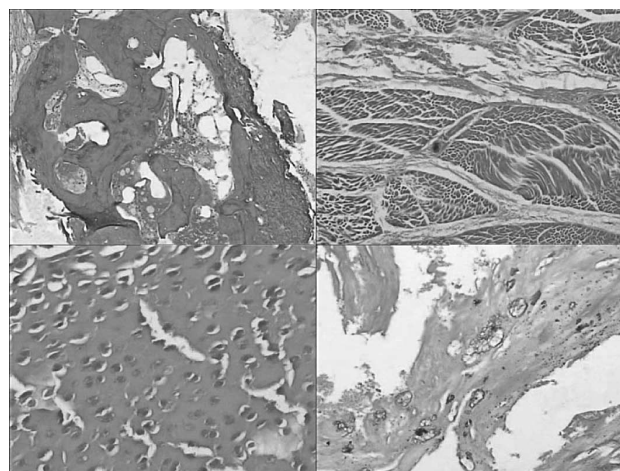


Figure 3. — HE staining showing the mass composed of mummified bones, muscles, skin, and cartilage (x100, x100, x200, and x200).

dominal cavity will cause complications such as intestinal adherence, intestinal obstruction, volvulus, stula formation, pelvic abscess, and some fetal parts can extrude into the abdominal wall, rectum or vagina [5, 6], and may cause rectal and urinary bladder perforations [2,7].

The most proper procedure of lithopedion is surgical removal, which is a simple procedure with mild bleeding, and can decrease or avoid possible future complications in elderly patients.

References

- [1] Lachman N., Satyapal K.S., Kalideen J.M., Moodley T.R.: "Lithopedion: a case report". *Clin. Anat.*, 2001, 14, 52.

- [2] Frayer C.A., Hibbert M.L.: "Abdominal pregnancy in a 67-year-old woman undetected for 37 years. A case report". *J. Reprod. Med.*, 1999, 44, 633.
- [3] Spirtos N.M., Eisenkop S.M., Mishell D.R.: "Lithokelyphos: A case report and literature review". *J. Reprod. Med.*, 1987, 32, 43.
- [4] Cave P.: "Note on Lithopaedion". *Br. Med. J.*, 1937, 1, 383.
- [5] Mishra J.M., Behera T.K., Panda B.K., Sarangi K.: "Twin lithopaedions: a rare entity". *Singapore Med. J.*, 2007, 48, 866.
- [6] Jain T., Eckert L.O.: "Abdominal pregnancy with lithopedion formation presenting as a pelvic abscess". *Obstet. Gynecol.*, 2000, 96, 808.
- [7] Irick M.B., Kitsos C.N., O'Leary J.A.: "Therapeutic aspects in the management of a lithopedion". *Am. Surg.*, 1970, 36, 232.

Address reprint requests to:
HONG SHEN, M.D.
Department of Pathology, School of Basic Medical
Southern Medical University
No. 1023, South Shatai Road, Baiyun District
Guangzhou (China)
e-mail: shenhong2010168@163.com

A rare complication of colporrhaphy anterior procedure: vesicovaginal fistula due to foreign body

O. Birge¹, D. Arslan², E. Kinali³, C. Karaca³

¹ Department of Obstetrics and Gynecology, Sudan Nyala Turkey Research and Education Hospital, Nyala

² Department of Urology, Sudan Nyala Turkey Research and Education Hospital, Nyala

³ Department of General Surgery, Sudan Nyala Turkey Research and Education Hospital, Nyala (Sudan)

Summary

Iatrogenic vesicovaginal fistula (VVF) is one of the possible complications after gynecologic operations. However, fistula formation owing to a forgotten foreign body is a rare condition. Infectious complications and subsequent vesicovaginal perforation due to foreign body is difficult to diagnose since it is an unlikely condition. Delays in diagnosis and treatment can lead to serious morbidities and even mortality. This paper aims to discuss a VVF case developed after anterior colporrhaphy owing to forgotten gauze.

Key words: Iatrogenic vesicovaginal fistula; Anterior colporrhaphy.

Introduction

Vesicovaginal fistula (VVF) is an abnormal passage or aperture between genital system and urinary system. However, VVF is a rather rare condition in developed countries; it is more common in socio-economically underdeveloped and poor regions of the world such as Africa, Arabic peninsula, and Asia [1]. VVF frequently develops secondary to birth trauma, radiotherapy, genital cancers, and gynecologic surgery. There are numerous reports of VVF cases owing to foreign bodies. However, these reports usually cover insertion of foreign bodies into the vagina of victims of rape or result of sexual fantasies [2]. Fistula formation following vaginal surgical procedures is an extremely rare condition and to the best of the present authors' knowledge, there is no report regarding this. Hereby, they discuss a case of VVF in a patient owing to a forgotten surgical sponge who underwent a transvaginal operation.

Case Report

A 35-year-old female patient with previous seven healthy births and regular menstrual cycles was admitted to the present clinic with complaints of abdominal and pelvic pain that was occasionally accompanied by nausea, vomiting, dysuria, and polyuria. She had a history of cystocele repair seven months prior. She was on her period during the physical examination. Vaginal examination revealed a hyperemic eroded area approximately one-cm in diameter in the junction between cervix and vagina. Uterus was normal in the ultrasonic examination. However, a mass containing hyperechogenic areas, arising from left ovary that was protruding into the bladder trough its left wall was revealed. CT showed an irregular mass, with calcified areas and containing air bubbles that was extending posterior to the blad-

der (Figure 1). Due to poor conditions and lack of medical instruments, the present authors could not perform a cystoscopy. The patient was scheduled for surgery with possible diagnoses of pelvic abscess, tumor invading bladder or dermoid tumor. Operative examination revealed a myomatous uterus and a 2 x 3 cm cystic formation involving right tuba that had necrosis and/or granulose structures on cross-sectional examination. Advancing dissection soon revealed that the mass was proceeding to bladder from the posterior wall. Bladder was transected and an immediate foul smell was noticed. There was an approximately three- to four- cm long opening beginning right adjacent to orifice of left ureter and advancing posteriorly to the bladder wall. When the mass inside the opening was examined, its structure was textile and confirmed that it was a forgotten surgical sponge from the previous operation (Figure 2). The sponge was gently taken out

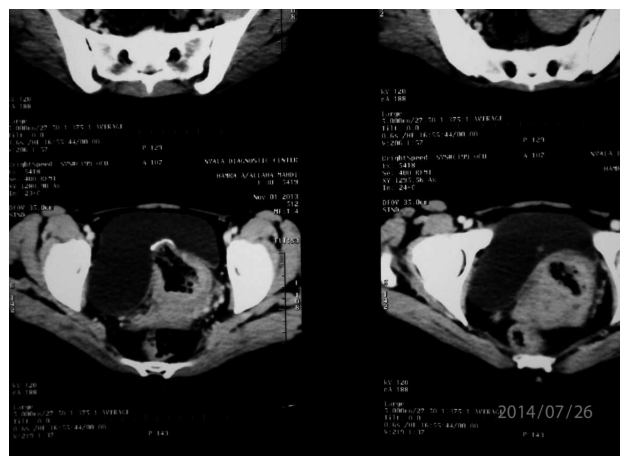


Figure 1. — MRI before operation.

Revised manuscript accepted for publication January 12, 2015

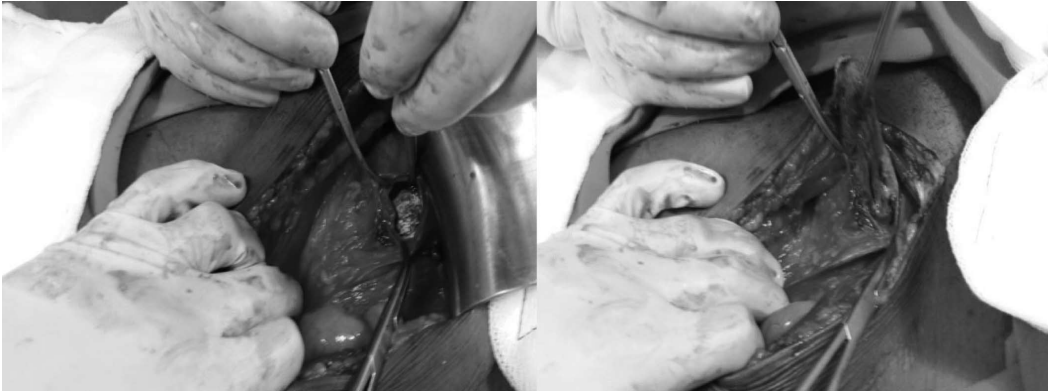

Figure 2. — Intraoperative view immediately after the transection of the bladder.

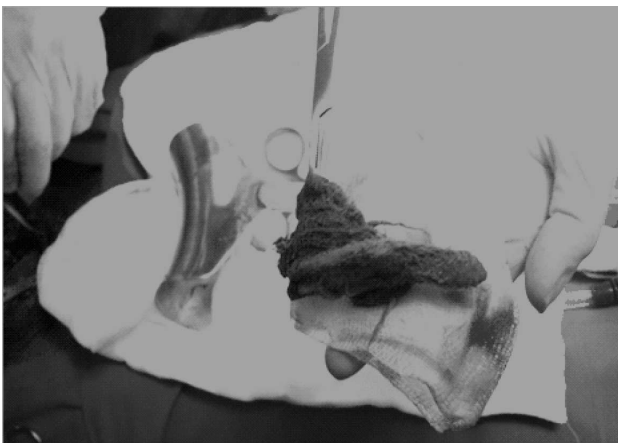

Figure 3. — Postoperative view of foreign body.

via forceps (Figure 3). Fistula tract was also checked with digital examination. When viewed from posterior wall of the bladder, the opening was reaching as far as cervico-vaginal junction and there were also erosions on the vaginal wall with partial necrotic areas. After debridement of granulation and necrotic tissues, fistula orifice was stitched with 2-0 polyglactin sutures inside the bladder and with 3-0 vicryl sutures from outside wall. Additional repair with 2-0 polyglactin sutures were used for primary repair of the vagina. Procedure was finished after placing 22 French tri-way Foley catheter in the bladder and a sump drain in the operation site.

Discussion

Unexpected complications can always occur during treatment of surgical diseases. Forgotten foreign bodies are one of those complications and often referred as gossypiboma, spongionoma or textiloma [3, 4]. Gossypiboma is the general term used for abscess or granulomatous formations owing to forgotten surgical instruments such as sponges and other material in the abdominal cavity after the operations. Its incidence in abdominal and/or pelvic operations is approximately 1/1,000 to 1/1,500 [5]. This incidence even rises in emergent operations or among obese patients [6-8].

Gossypiboma can present as acute or chronic clinic settings. Abscess formation, sepsis or generalized peritonitis are among the most common acute settings. The present authors assume that the smelly vaginal discharge and pelvic pain of their patient can easily be attributed to these. However, chronic symptoms can be non-specific and can present as obstruction, adhesion, and fistula formation [9]. Risk of fistula formation rises with the time the foreign body remains in the body [10]. Migration of foreign body through the body is possible but an extremely rare condition [11]. When the history of a transvaginal operation was taken into account regarding the present patient, is strongly possible to assume that the sponge would have migrated from the operative field eroding its way to the bladder.

There are some reports of VVF cases following transvaginal operations for cystocele and incontinence due to operative trauma or erosion caused by used meshes [12, 13]. There are also some reports of VVF cases following colpoperforatory anterior operations [14]. However, causative factor for these cases were reported as thinning of the bladder wall due to extensive dissection and operative trauma. To the best of the present authors' knowledge, there is no reported case of VVF owing to a forgotten surgical sponge during anterior colpoperforatory.

Forgotten foreign bodies after surgical procedures are rather challenging and complicated conditions. They can easily be mistaken for an abscess, tumor or other serious conditions radiologically. Retained sponges may be seen on US as cystic masses with echogenic, wavy stripes in the center, and casting acoustic shadows [15]. Pelvic gossypiboma in CT presents as a heterogeneous hypodense mass with a central spongiform pattern containing air bubbles [16]. Owing to similar radiologic properties, the present authors' pre-diagnoses for their patient were abscess, tumor or due to present calcifications a dermoid cyst.

Gossypibomas generally require re-operation as soon as they are diagnosed as complications and morbidity are high [6]. The present case was immediately operated after initial diagnostic evaluations.

Conclusion

Being rare condition, forgotten foreign bodies and their acute and chronic complications should always be kept in mind due to serious mortality and morbidities caused by this condition.

References

- [1] De Ridder D.: "Vesicovaginal fistula: a major healthcare problem". *Curr. Opin. Urol.*, 2009, 19, 358.
- [2] Donaldson J.F., Tait C., Rad M., Walker S., Lam T.B., Abdel-Fattah M., Swami S.K.: "Obstructive uropathy and vesicovaginal fistula secondary to a retained sex toy in the vagina". *J. Sex. Med.*, 2014, 11, 2595.
- [3] Cheng T.C., Chou A.S., Jeng C.M., Chang P.Y., Lee C.C.: "Computed tomography findings of gossypiboma". *J. Chin. Med. Assoc.*, 2007, 70, 565.
- [4] Madan R., Trotman-Dickenson B., Hunsaker A.R.: "Intrathoracic gossypiboma". *AJR Am. J. Roentgenol.*, 2007, 189, W90-1.
- [5] Kopka L., Fischer U., Gross A.J., Funke M., Oestmann J.W., Grabbe E.: "CT of retained surgical sponges (textilomas): pitfalls in detection and evaluation". *J. Comput. Assist. Tomogr.*, 1996, 20, 919.
- [6] Bani-Hani K.E., Gharaibeh K.A., Yaghan R.J.: "Retained surgical sponges (gossypiboma)". *Asian J. Surg.*, 2005, 28, 109.
- [7] Gawande A.A., Studdert D.M., Orav E.J., Brennan T.A., Zinner M.J.: "Risk factors for retained instruments and sponges after surgery". *N. Engl. J. Med.*, 2003, 348, 229.
- [8] Mason L.B.: "Migration of surgical sponge into small intestine". *JAMA*, 1968, 205, 938.
- [9] Gaurav, A., Singh R.: "3D QSAR pharmacophore, CoMFA and CoMSIA based design and docking studies on phenyl alkyl ketones as inhibitors of phosphodiesterase 4". *Med. Chem.*, 2012, 8, 894.
- [10] Dhillon J.S., Park A.: "Transmural migration of a retained laparotomy sponge". *Am. Surg.*, 2002, 68, 603.
- [11] Dux M., Ganten M., Lubienski A., Grenacher L.: "Retained surgical sponge with migration into the duodenum and persistent duodenal fistula". *Eur. Radiol.*, 2002, 12, S74.
- [12] Firoozi F.: "Transvaginal mesh for prolapse repair: what is all the controversy about?" *Curr. Urol. Rep.*, 2011, 12, 323.
- [13] Kokanali M.K., Doğanay M., Aksakal O., Cavkaytar S., Topçu H.O., Özer İ.: "Risk factors for mesh erosion after vaginal sling procedures for urinary incontinence". *Eur. J. Obstet. Gynecol. Reprod. Biol.*, 2014, 177, 146-50.
- [14] Stelmachów J., Borkowski A., Zawada E., Wypych K.: "Late vesicovaginal fistula after colporrhaphy for urinary incontinence". *Ginekol. Pol.*, 1992, 63, 204.
- [15] Sugano S., Suzuki T., Iinuma M., Mizugami H., Kagesawa M., Ozawa K., et al.: "Gossypiboma: diagnosis with ultrasonography". *J. Clin. Ultrasound*, 1993, 21, 289.
- [16] Nemati M.H.: "Mediastinal gossypiboma simulating a malignant tumour". *Interact. Cardiovasc. Thorac. Surg.*, 2012, 15, 783.

Address reprint requests to:
 D. ARSLAN, M.D.
 Department of Urology
 Sudan Nyala Turkey Research and Education Hospital
 West Alezza District - Southern Nyala No. 1
 Nyala (Sudan)
 e-mail: denars35@gmail.com

Successful management of recurrent pregnancy-related thrombotic thrombocytopenia purpura: case report and review

H. Chen, L. Luo, J. Cai, Y. Wu, B. Liu, Z. Wang

Department of Obstetrics and Gynecology, the First Affiliated Hospital of SUN Yat-sen University, Guangzhou (China)

Summary

Thrombotic thrombocytopenic purpura (TTP) is a rare but potentially devastating complication of pregnancy. The authors report a case of a successful treatment of recurrent TTP complicating pregnancy. A review of the literature shows that recurrent TTP complicating pregnancy is uncommon and fresh frozen plasma exchange is important treatment; if the patient was treated properly, the pregnant showed favorable prognosis.

Key words: Thrombotic thrombocytopenic purpura; Pregnancy, Plasmapheresis.

Introduction

Thrombocytopenia during pregnancy is common, and an asymptomatic reduction in platelets count is found near term in about 5% of normal pregnancies [1]. However, thrombotic thrombocytopenic purpura (TTP) is a serious and rare complication of pregnancy, the incidence of is only one in 25,000 pregnancies [2] and it was associated with a high maternal and fetal mortality which approached 80% without a proper treatment [3].

The authors report a 26-year-old pregnant woman who presented initially with severe thrombocytopenia in the 36th+1 week of gestation. Her past medical history included thrombocytopenia and neurologic dysfunction during last delivery five years ago and plasma exchange therapy was successfully used. Immediate plasmapheresis treatment was initiated in this case, then immunoglobulin and dexamethasone infusions, followed by platelet infusion. A male neonate was delivered by cesarean section in the 36th+4 week of gestation with uncomplicated postnatal development. After delivery, this patient's platelet count increased to normal values. This case shows interesting aspects of TTP during pregnancy and a close cooperation between obstetricians, nephrologists, and pediatricians is necessary for a favorable outcome of the pregnancy.

Case Report

A 26-year-old pregnant woman was transferred to the tertial perinatal care center of The First Affiliated Hospital of Sun Yat-sen University for termination of the pregnancy due to the diagnosis of a severe thrombocytopenia without obvious bleeding in the 36th+1 week of gestation. Initial laboratory studies demonstrated severe thrombocytopenia ($10 \times 10^9/L$), proteinuria (7.122

g/L/24 hours), and mild hemolytic anemia (hemoglobin 92 g/L). In her early stage of pregnancy, there were documented normal hemoglobin, platelet values, and normal urine test result.

Past medical history revealed a similar event occurring during last pregnancy five years ago. She was transferred to the present hospital after cesarean section due to persistent thrombocytopenia, postnatal bleeding, and neurologic dysfunction. Platelet and plasma infusion did not work. The findings of bone marrow puncture were consistent with TTP and then, plasmapheresis, plasma, and immunoglobulin infusion were given. Cyclosporine and prednisone treatment followed and her platelet count recovered to normal values. After that she had her blood checked routinely every year and the result was normal. There were no other illnesses in the past.

Upon physical examination, the patient was sane and well cooperative. Her skin and mucosa were pale, and multiple petechiae were seen in her right leg. The patient had no fever or edema and blood pressure was normal. The remaining physical examination findings were unremarkable. Obstetrical ultrasound showed an appropriate for gestational age developed fetus without signs of structural abnormality, normal amniotic fluid, and fetal echocardiography. Additional laboratory examinations revealed a negative Coombs test, antinuclear (ANA) double stranded DNA-antibodies and normal levels of complement C3, C4 and CH 50. Blood smear showed 2.5% schistocytes and lactate dehydrogenase (LDH) was 1410 U/L. Detailed laboratory tests results showed in Table 1. A working diagnosis of TTP was made.

This case was presented at Medical Grand Rounds joined with plasma experts, then, termination of pregnancy, plasmapheresis, immunoglobulin, and glucocorticoid steroid were recommended to the patient. Emergency plasmapheresis therapy with substitution of fresh frozen plasma or albumin (50 ml/kg body weight) and immunoglobulin (0.4 g/kg body weight), and prednisone (60 mg) infusions was started before the delivery.

However, after two days of treatment, her platelets remained at a very low level ($9-12 \times 10^9/L$) and hemolytic anemia was aggravated (hemoglobin dropped from 92 to 72 g/L). Then, a de-

Revised manuscript accepted for publication January 13, 2015

Table 1. — *Laboratory tests results.*

Variables (normal values)	Before admission	On admission	Day 2	Day 3	Day 4 (prepartum)	Day 4 (postpartum)	Day 5	Day 6	Day 7
Hb (g/L) (110-150)	92	96	90	72	68	97	82	88	95
PC ($\times 10^9/L$) (100-300)	10	12	9	12	53	93	101	153	211
Sr. bil. (umol/L) (22-30)		30.7		35	13	15.4	9.1		
Direct bil. (umol/L) (6-19)		30.7		35	13	15.4	9.1		
AST (U/l) (1-37)	66	56		34	26	28		32	
ALT (U/l) (1-40)	37	26		24	18	22		43	
ALP (U/l) (0-110)	104	99		46	62	77		59	
Sr. urea (mmol/L) (2.9-8.6)	5.3	5.6		6.0	4.6	4.4	4.9	5.5	
Sr. creat. (umol/L) (53-115)	62	55		58	59	54	57	69	
PTT (seconds) (14-21)		17.5	17.1	18.5	17.5	15.8	17.5	16.9	
INR		1.08	1.03	1.10	1.03	0.88	0.93	0.82	
FDP ($\mu g/ml$) (<10)		9.1							
d-Dimer (mg/dl) (<0.5)		353							
Fibrinogen (mg/dl) (2-4)		2.34	2.76	1.29	1.48	2.21	2.0	2.22	
LDH (U/l) (114-140)	1410	853		582	295	435		307	
Proteinuria	++		+++	7.122		+			

PC: platelet count, Hb: hemoglobin, AST: aspartate aminotransferase, LDH: lactate dehydrogenase, ALT: alanine aminotransferase, ALP: alkaline phosphatase, sr. bil.: total serum bilirubin, sr. creat: serum creatinine, NA: not available, PTT: partial thromboplastin time, INR: international normalized ratio, FDP: fibrin degradation products.

cision of platelet infusion (one unit) was made to try to avoid peripartum bleeding especially cerebral hemorrhage. Once the platelets value increased to $50 \times 10^9/L$, cesarean section was carried out. During operation, the patient received four units of packed red blood cells, 400 ml fresh frozen plasma, and one unit of platelets. The total blood lost was 400 ml and the patient's vital signs were stable during perioperative period. A male neonate weighing 2.54 kg was delivered and Apgar score was 5, 8, 9, at one, five, and ten minutes. The child had a normal blood routine test result and no other complication. After operation the patient was transferred to SICU for postoperative observation. Her platelet value recovered to $93 \times 10^9/L$ soon after delivery without any other special treatment and $101 \times 10^9/L$ next morning. Her proteinuria decreased dramatically from 3+ prepartum to 1+ postpartum. She was then transferred to general postnatal ward two days later and discharged three days after delivery with a stable normal value of platelets ($153-211 \times 10^9/L$). This patient and her baby both were in good condition in postpartum follow up of six weeks and three months.

Discussion

TTP is a spectrum of syndromes characterized by thrombocytopenia and microangiopathic hemolytic anemia, manifested by an elevated blood LDH concentration and red blood cell fragments. It is one of the few hematologic emergencies. Untreated, most patients will die, however prompt and appropriate treatment allows most patients not only to survive but to recover, with favorable long-term outcome. It classically occurs in patients with a hereditary or acquired lack of ADAMTS13, a metalloproteinase that cleaves large multimers of von Willebrand factor. Other TTP-like syndromes, including TTP associated with pregnancy, organ transplantation, and certain medications, likely have different underlying causes and may require different treatment.

TTP is rare. The estimated annual incidence of all TTP syndromes is about 11 cases per million in the general population [4]. However, patients who have experienced one episode of pregnancy-related TTP are at increased risk in future pregnancies. In many large series, 20% or more of the included patients developed disease during pregnancy or the immediate postpartum period [5]. This is one of few cases of a successful treatment of a patient with recurrent TTP related to pregnancy. Despite the satisfactory outcome, the case raises a number of questions that are discussed.

TTP is classically characterized by the pentad of microangiopathic hemolytic anemia (MAHA), thrombocytopenia, neurologic dysfunction, fever, and renal disease. However, due to the importance of initiating therapy promptly for this disorder, any patient with MAHA and thrombocytopenia that is otherwise unexplained should be considered to have TTP. Of the other clinical manifestations, neurologic dysfunction is most common in classical TTP. Involvement of organs such as the pancreas, heart, and others are demonstrable pathologically, and may lead to complications such as pancreatitis, myocardial infarction, and cardiac arrhythmia. TTP may be difficult to discern from other disease such as preeclampsia, HELLP (hemolysis, elevated liver enzymes, and low platelets) syndrome, HUS (hemolytic uremic syndrome), and acute fatty liver. Thus, the differential diagnosis in a pregnant patient presenting with such manifestations is complex, and, in some cases, achieving a definitive diagnosis may not be possible.

In this case, the patient had thrombocytopenia and anemia, an elevated blood LDH concentration, and blood smear showed 2.5% schistocytes; no blood pressure change; ALT and AST levels were normal; no obvious de-

Table 2. — Comparison of articles regarding recurrent pregnancy-related TTP.

No.	Study and year	Patient no.	No. of TTP episodes related to pregnancy	Main treatments	Outcome of pregnancy	Obstetric complication	Outcome of patient
1	Nikolaou M., <i>et al.</i> [11], 2012	1	3	Fresh frozen plasma exchange	Termination of pregnancies	Not mentioned	Survived
2	Keiser SD., <i>et al.</i> [12], 2012	2	Not mentioned	Not mentioned	Not mentioned	Not mentioned	Not mentioned
3	Raman R. [13], 2011	1	2	Fresh frozen plasma exchange	G1: IUFD G2: preterm live birth	Preeclampsia	Survived
4	Richter J. [14], 2011	1	2	Tinzaparin treatment and octaplas infusions	G1: SA G2: term live birth	Preeclampsia	Survived
5	Lam K. [15], 2010	1	2	fresh frozen plasma exchange	G1: IUFD G2:	G1: preeclampsia G2: fetal distress	Survived
6	Stella C.L. [16], 2009	2	4	Plasmapheresis	Live birth	Not mentioned	Survived
7	Kato R. [17], 2009	1	4	Fresh frozen plasma exchange	G1-G3: IUFD G4: live birth	G1: HELLP syndrome and placental abruption	Survived
8	Scully M. [18], 2006	2	4	Low-dose aspirin, low molecular weight heparin and fresh frozen plasma exchange	G1: Second-trimester foetal losses G2: live birth	Not mentioned	Survived
9	Vesely S.K. [19], 2004	19	30	Fresh frozen plasma exchange	Live birth at last pregnancy	Not mentioned	Survived
10	Ducloy-Bouthors A.S [20], 2003	1	2	Fresh frozen plasma exchange	Not mentioned	Not mentioned	Survived
11	Ezra Y. [21], 1996	2	5	Aspirin, dipyridamole	G1-3: IUFD Last pregnancy: live birth	Not mentioned	Survived
12	Natelson E.A. [22], 1985	1	2	Evacuation of the uterus	Recovery soon after evacuation	No	Survived

G: gestation; IUFD: intrauterine fetal death; SA: spontaneous abortion; HELLP: hemolysis, elevated liver enzymes, and low platelets.

teriorated renal function and coagulation function. Furthermore, she had a previous history of pregnancy-related TTP. Therefore, although there was no neurologic dysfunction and no fever, she was considered as recurrent pregnancy-related TTP and was treated promptly to avoid progression to other important organs such as kidney or heart.

Why is the incidence of TTP is increased in pregnancy uncertain? Some studies suggest that TTP usually presents prior to 24 weeks; however, pregnancy-associated TTP can occur in the third trimester or during the postpartum period as well [6]. Patients with pregnancy-associated TTP are at increased risk for the development of recurrent TTP in subsequent pregnancies just like this case. The mortality rate from thrombotic microangiopathies during pregnancy has significantly improved since plasmapheresis therapy has become the standard treatment. In a review of 166 cases of pregnancy-associated TTP between 1955–2006, a maternal mortality of 26% was described [7].

Plasmapheresis the primary treatment for TTP and sometimes plasma infusion (PI) is effective, too. Comparison of plasmapheresis and PI in the treatment of TTP was carried out by the Canadian Apheresis Study Group [8], which reported that plasmapheresis was superior to PI. They performed a randomized trial in which 102 patients with TTP

received either plasmapheresis or PI. Patients who received plasmapheresis had a better initial response, a higher survival rate, and a lower rate of relapse than patients receiving PI. The Japanese TTP Study Group [9] made a therapeutic protocol in which a smaller volume of fresh frozen plasma (FFP) was used in the treatment with PI. The efficacy of plasmapheresis and PI was similar. These findings established plasmapheresis as the treatment of choice for TTP. TTP is different from other autoimmune diseases such as idiopathic thrombocytopenia purpura, in which the primary treatments are immunosuppressive agents. Some evidence exists for treating TTP with immunosuppressive agents [10], but the primary treatment should be plasmapheresis.

The management of TTP during pregnancy is much like common patients, with plasmapheresis yielding a very high response rate. The role of corticosteroids in the management of TTP has not been determined through randomized studies and corticosteroids used alone is not recommended. Periodic plasma infusions appear to be helpful, but a specific protocol has not been developed and treatment must remain empiric. Importantly, unlike preeclampsia and the HELLP syndrome, termination of pregnancy does not induce remission of TTP, however, it is suggested to deliver after fetal lung maturation because of the high mortality of the disease.

Treatment of TTP in pregnancy with plasmapheresis can produce similar outcomes to that of non-pregnant population as pregnancy does not impair the response to plasmapheresis. Untreated TTP not only results in poor maternal outcomes, but also fetal death and intrauterine growth restriction due to placental infarcts. Successful treatment can result in the delivery of a normal sized infant, and successful pregnancies have occurred in women receiving maintenance plasma infusions preconception. Delivery is recommended only for patients who do not respond to plasmapheresis. Guidelines have been developed for the optimal plasmapheresis regime, and these include recommendations for diagnosis and treatment of TTP in pregnancy.

The present authors reviewed some articles about recurrent pregnancy-related TTP (Table 2). Recurrent TTP complicating pregnancy is relatively rare and fresh frozen plasma exchange is crucial treatment for life saving; if the patient was treated promptly and properly, the pregnant outcome was always favorable.

Conclusions

In conclusion, this case shows that prompt and proper management of recurrent pregnancy-associated TTP is possible with a good outcome and the close cooperation between obstetricians, nephrologists, and pediatricians yielded the successful outcome of the pregnancy. Pregnancy is a risk factor for manifestation and relapse of severe TTP.

Acknowledgement

The authors would like to thank Forevergen Biosciences for assistance with a valuable discussion.

References

- [1] Parnas M., Sheiner E., Shoham-Vardi I., Burstein E., Yermiahu T., Levi I., *et al.*: "Moderate to severe thrombocytopenia during pregnancy". *Eur. J. Obstet. Gynecol. Reprod. Biol.*, 2006, 128, 163.
- [2] Gerth J., Schleussner E., Kentouche K., Busch M., Seifert M., Wolf G.: "Pregnancy-associated thrombotic thrombocytopenic purpura". *Thromb. Haemost.*, 2009, 101, 248.
- [3] Shamseddine A., Chehal A., Usta I., Salem Z., El-Saghir N., Taher A.: "Thrombotic thrombocytopenic purpura and pregnancy: report of four cases and literature review". *J. Clin. Apher.*, 2004, 19, 5.
- [4] Crowther M.A., George J.N.: "Thrombotic thrombocytopenic purpura: 2008 update". *Cleve. Clin. J. Med.*, 2008, 75, 369.
- [5] McCrae K.R.: "Thrombocytopenia in pregnancy". *Hematology Am. Soc. Hematol. Educ. Program*, 2010, 2010, 397.
- [6] Prakash J.: "The kidney in pregnancy: A journey of three decades". *Indian J. Nephrol.*, 2012, 22, 159.
- [7] Martin J.J., Bailey A.P., Rehberg J.F., Owens M.T., Keiser S.D., May W.L.: "Thrombotic thrombocytopenic purpura in 166 pregnancies: 1955-2006". *Am. J. Obstet. Gynecol.*, 2008, 199, 98.
- [8] Rock G.A., Shumak K.H., Buskard N.A., Blanchette V.S., Kelton J.G., Nair R.C., *et al.*: "Comparison of plasma exchange with plasma infusion in the treatment of thrombotic thrombocytopenic purpura. Canadian Apheresis Study Group". *N. Engl. J. Med.*, 1991, 325, 393.
- [9] Hattori A., Tatewaki W.: "Treatment of thrombotic thrombocytopenic purpura--retrospective analysis on Japanese patients and review. Japan TTP Research Group". *Nihon Rinsho*, 1993, 51, 178.
- [10] George J.N., Woodson R.D., Kiss J.E., Kojouri K., Vesely S.K.: "Rituximab therapy for thrombotic thrombocytopenic purpura: a proposed study of the Transfusion Medicine/Hemostasis Clinical Trials Network with a systematic review of rituximab therapy for immune-mediated disorders". *J. Clin. Apher.*, 2006, 21, 49.

Address reprint requests to:

Z. WANG, M.D.

Department of Obstetrics and Gynecology

The First Affiliated Hospital of

SUN Yat-sen University

Zhongshan Er Road No. 58

Guangzhou 510080 (China)

e-mail: chenhaitiansci@163.com

Uterine rupture in pregnancy: two case reports and review of literature

A. Pontis¹, C. Prasciolu¹, P. Litta², S. Angioni¹

¹Division of Gynecology and Obstetrics, Department of Surgical Sciences, University of Cagliari, Cagliari

²Department of Obstetric and Gynecology, University of Padua, Padua (Italy)

Summary

Rupture of a gravid uterus is an obstetric emergency. Risks factors include a scarred uterus but also spontaneous rupture of an unscarred uterus during pregnancy is possible. The authors present two cases of a spontaneous complete uterine rupture during pregnancy. The first case had only a past history of dilatation and curettage for abortion; the second case had a past history of dilatation and curettage for abortion and a monolateral laparoscopic salpingectomy for ectopic pregnancy. They presented with abdominal pain and after ultrasound scan, uterine ruptures were diagnosed. These cases show that there should be a high index of suspicious of uterine rupture in a gravid woman with a history of curettage for the possible presence of misunderstood uterine scar and in women with a past history of salpingectomy with or without corneal resection. Appropriate counseling and close follow-up might help to avoid such obstetrical catastrophes. To provide more insight into the possible risk factors for prelabor uterine rupture in pregnancy, a literature review was performed.

Key words: Uterine rupture; Dilatation and curettage; Uterine scar.

Introduction

Rupture of a gravid uterus is a rare surgical and obstetric emergency. The most accredited definition is from Plauche *et al.*: “those cases of complete separation of the wall of the pregnant uterus with or without expulsion of the fetus” [1]. Uterine rupture is more prevalent in less developed than in developed countries [2]. Risks factors include previous uterine surgery such as cesarean section, laparotomic or laparoscopic myomectomy, hysteroscopic surgery, iatrogenic uterine perforation, multiparity, previous instrumental abortion, inappropriate augmentation of labor, application of fundal pressure, placenta accreta, trauma, and congenital uterine anomalies [2-5]. It is possible to classify uterine rupture according to etiology: a) spontaneous rupture of previous scar (cesarean section, myomectomy etc); b) traumatic rupture of previous scar (version in obstetrics, accident, etc); c) spontaneous rupture of unscarred uterus; d) traumatic rupture of unscarred uterus.

Symptoms of uterine rupture are severe abdominal pain of sudden onset, palpable fetal body parts, cessation of contractions, signs of intraperitoneal bleeding, and all the features correlated to the hemorrhage that could lead to maternal and fetal (fetal distress, bradycardia) deterioration of vital signs leading up to shock. Less common symptoms are epigastric pain, shoulder pain (right-sided or bilateral), abdominal distension and paralytic ileus, ematuria, hypertonic uterus, altered uterine contour, and

fluid thrill. Often there is minimal external bleeding but an important internal bleeding with blood in the broad ligament and extaperitoneal spaces could be detected with an ultrasound examination. The typical ultrasound manifestations of uterine rupture are the empty uterus and the gestational sac above the uterus. Other sonographic findings are intrauterine blood and large uterine mass with gas bubbles [6]. Hruska *et al.* reported the importance of the MRI examination for assessment of pregnant patients in case of uterine rupture [7]. Treatment of uterine rupture is an early surgical intervention and previous hemodynamic stabilization of the patient where possible. It is necessary to correct hypovolemia after securing airway and oxygen administration. Maternal mortality is 0.44% and it resulted from hemorrhage, shock, sepsis, disseminated intravascular coagulation, pulmonary embolism, ileus paralyticus, peritonitis, and renal failure. It is possible to reduce fetal and maternal mortality with a prompt intervention, less than 18 minutes from onset of prolonged deceleration to delivery [8]. The authors present two cases of a spontaneous complete uterine rupture at a gestational age of 27 weeks in a 29-year-old patient and 34 weeks in a 38-year-old patient after previous misunderstood perforation. The cases were managed at the University of Cagliari (Hospital San Giovanni di Dio, Cagliari).

The first case had a past history of dilatation and curettage for abortion. The second case had a past history of di-

Revised manuscript accepted for publication April 23, 2015

lation and curettage for abortion and a monolateral salpingectomy laparoscopy for ectopic pregnancy. They presented with abdominal pain of sudden onset. After ultrasound scan, uterine rupture was diagnosed and an emergency laparotomy was performed and the following evaluation of the medical history gave a strong suspicion of a misunderstood perforation in the previous D&C. To provide more insight into the possible risk factors for prelabor uterine rupture in gravid, a literature review was performed.

Case Report

Case 1

The patient was 29-years-old, secondgravida, nulliparous with a gestational age of 27 weeks. She had previous appendectomy surgery and a dilatation and curettage for abortion 12 year prior. She reported a regular course of pregnancy until the moment when she arrived at the authors' Department for intense pelvic pain associated with a reduction in blood pressure (BP: 70/40). On physical examination a contracted uterus was appreciated and the ultrasound evaluation showed a placental detachment and free fluid in the peritoneal cavity; a fetal heart beat was present. An emergency laparotomy was performed for cesarean section to remove the fetus and placenta due to the occurrence of hemodynamic instability with anemia (hemoglobin 6 g/dl) and hypovolemic shock. After removal of the fetus and placenta and suction of 2,000 cc of hemoperitoneum, the uterus had a three-cm tear at the level of the left side wall of the uterine body; the authors performed a suture in double-layer with Vicryl n°1 in the breach of the uterine section and in the left side wall tear. During surgery 500 ml of whole blood was transfused to the patient, and another 500 ml was transfused after surgery. A male infant was delivered (Apgar 2-4; weight 950 grams) and the patient had an uneventful recovery. The child currently presents mild neurological deficits to a lower limb.

Case 2

The patient was a 38-year-old woman, gravida four, para one with a gestational age of 34 weeks. She had had in 2006 a dilatation and curettage for abortion and in 2007 a left salpingectomy laparoscopy for ectopic pregnancy. The patient presented at the authors' Department for pelvic pain and the uterus appear contract. A transabdominal ultrasound evaluation showed the presence of a corpuscular flap on the left hypocondrium with a 30-mm maximum thickness and a corpuscular hepato renal ground water with a 25-mm maximum thickness. Considering the subsequent hemodynamic instability of the patient (hemoglobin values from 8.7 g/dl to 6.6 g/dl) but a reassuring pattern at fetal monitoring, emergency cesarean delivery under general anesthesia was performed. After removal of the fetus and placenta and suction of 2,000 cc of haemoperitoneum, a seven-cm transverse full-thickness myometrial tear was observed at the bottom of the uterus; the authors performed a suture in double layer with Vicryl n°1. During surgery two units of blood and another unit after surgery were transfused. A male infant was delivered (Apgar 3-7; weight 2,530 grams) and the patient had an uneventful recovery. The child currently does not present any problems.

Discussion

Uterine rupture in an unscarred uterus

Uterine rupture in an unscarred uterus is a rarely and unpredictable obstetric complication. Real incidence of rup-

tured uterus is difficult to determine because of unknown causes of maternal deaths due to obstetric shock. The incidence of rupture of the unscarred uterus is inferior to one in 10,000 pregnancies in the most-developed countries [9]. Rachagan *et al.* reported a incidence that varied from 0.3/1000 to 7/1000 [10]. Sun *et al.* reported a rate of 0.012% [11].

The most important risk factors for unscarred uterine rupture are multiparity, the inappropriate use of oxytocin, mid-forceps delivery, uterine over-distention due to the presence of twin pregnancy, previous curettage, and congenital anomalies. The most common sign in women with a uterine rupture without a scar is shock, followed by uterine bleeding, severe abdominal pain, and easily palpable fetal parts. Traditionally, primigravidae and unscarred uteri are considered immune to rupture, but the present authors found in literature some cases of nulliparous with a previous history of diagnostic hysteroscopy and uterine perforation at 35 weeks [12]. The past history of curettage, diagnostic or operative hysteroscopy, can suggest an unknown uterine perforation [13]. Multiparity is a important risk factor and many cases in literature are described [14, 15]. Tarney *et al.* described a case of uterine rupture in third trimester of an unscarred uterus in a quadruplet pregnancy in a 30-year-old woman that had not undergone previous surgeries; a high-order gestations may be an independent risk factor for uterine rupture [16]. Mamour *et al.* described a case of spontaneous uterine rupture during pregnancy at 35 weeks of an unscarred uterus before labour; her obstetrical history revealed a multipara patient with a history of four pregnancies that ended spontaneously by vaginal delivery. In this case high parity was recognized as major risk factor of spontaneous uterine rupture in unscarred uterus. A such case described Sun *et al.* where high parity was the only risk factor in a patient who presented upper abdominal discomfort and vomiting for three days; during emergency laparotomy, the entire amniotic sac was found in the peritoneal cavity with a rupture of the uterine fundus. The literature describes cases where multiparity is the main risk factor [17]. Another risk factor is an abnormal adherence of placenta to the uterine wall without interposition of deciduas basalis. Placenta percreta is the rarest form but may complicate the pregnancy with acute severe hemorrhage [18]. Pierzynsky *et al.* reported a case of uterine rupture due to placenta percreta in otherwise uncomplicated pregnancy; a 35-year-old, gravid 5, para 5, at 15 weeks two days gestation with negative history of uterine scarring developed symptoms of incipient hypovolemic shock and on exploratory laparotomy found a midline uterine rupture infiltrated by the placenta. Abnormal placentation should be taken into consideration also in women in the second trimester who have no history of uterine instrumentation [19].

Also, Xia *et al.* reported a case of uterine rupture that was associated with placenta accreta with a spontaneous uterine perforation in the second trimester of pregnancy with mul-

tiple perforations of an unscarred uterus revealed by hemoperitoneum at 22 weeks. Emergency total hysterectomy was performed [20]. Another risk factor is the use of prostaglandins and oxytocin to induce labor [21, 22]. Cuelar Torriente presented a case of silent uterine rupture in an unscarred uterus during pregnancy at third trimester abortion by use of mifepristone and misoprostol in a patient who had a history of intrauterine procedures. They suggested that this uterine rupture resulted from an unrecognized perforation in a previous intrauterine manipulation. Many cases have been reported of uterine rupture in an unscarred uterus during second trimester pregnancy termination with intravaginal misoprostol [23]. Chang *et al.* reported a case of a multiparous who had a previous vaginal birth delivery and who was labor-induced with PGE2 and oxytocin. Even if one of the most risk factors are incorrect administration of oxytocin in multiparous woman, in this case the authors excluded the possibility to an augmentation of labor and stressed on the possibility of a silent rupture due to a previous pregnancy [24]. Also, adenomyosis can be a risk factor for uterine rupture due to the weakening of the uterine muscle fibers; in a case report with review of literature, Nikolaou *et al.* reported a rare case of spontaneous uterine rupture of an unscarred uterus caused by adenomyosis in the early third trimester [25-27]. Agarwal *et al.* reported a case of intrapartum unscarred uterine fundal rupture in a case of drug abuse. A careful history of drug abuse must be elicited when the common causes of uterine rupture have been excluded or the rupture site is unusual. There are other described cases of uterine rupture associated with cocaine abuse [28, 29].

Also, the cause of uterine rupture could be uterine diverticulum, frequently misunderstood and reported as uterine sacculation. Uterine diverticulum has a narrow connection with the uterine cavity and a thicker wall than in sacculation. While uterine sacculation is usually observed during pregnancy, diverticulum is usually detected in non-pregnant women. Uterine diverticula as a complication during pregnancy are rare. Rajah *et al.* reported a primigravida woman in whom an MRI revealed uterine diverticulum in the 22 weeks of gestation. A cesarean section was performed in the 31st week. The diverticulum originated from the posterolateral wall of the uterine body and did not contain the fetus. The diverticulum was not excised due to surgical risks. The authors considered that the underlying etiology for the diverticulum may have been congenital because this patient was primigravida with no prior cervical or uterine procedure [30]. Matsubara *et al.* described a case of a primigravida woman with a thin anterior uterine wall, a feature compatible with incomplete uterine rupture; her condition was detected by abdominal palpation and ultrasound. This case suggest that an unscarred primigravida pre-labor uterus can show the features of incomplete rupture even in the absence of discernable risk factors and that abdominal palpation and ultrasound may be useful in diagnosis. They suspected a rupture uterine diverticulum [31].

In literature there are six cases with uterine rupture in case of uterus congenital anomalies; five are related to the presence of bicornuate uterus, and only one relates to septate uterus. Damiani reported the first case of uterine rupture in a septate uterus; the authors assumed that it could lead to uterine overdistension due to the presence of the medial sept [32], but also to the history of a D&C which could have caused an unknown perforation or a weakness of uterine wall [33]. Often a lack in anamnesis can miss important risk factors for uterine rupture.

Uterine rupture in scarred uterus

Due to an improvement rate of cesarean births, several large studies have identified the risks of maternal morbidities associated with a trial of labor after cesarean delivery. Uterine rupture during labor is a serious and uncommon obstetrical complication that can lead to severe prognosis for the mother and her child if not immediately diagnosed and treated. Rupture of the uterus in labor is also associated with cessation of labor pain, recession of presenting fetal body parts, cervical lacerations, and vaginally palpable uterine defect. One series reported that 81% of patients with uterine rupture during labor have evidenced fetal distress prior to the onset of bleeding or abdominal pain [34, 35]. The American College of Obstetricians and gynecologists (ACOG) suggested that a trial of labor among patients with a previous cesarean section is reasonable. The percentage of uterine rupture in case of trial of labor is reported to range from 0.5% to 1%, is associated with cessation of labor pain, recession of presenting fetal body parts, cervical lacerations, vaginally palpable uterine defect, fetal distress. Rodriguez *et al.* reported that 81% of patients with uterine rupture during labor have evidence of fetal distress prior to the onset of bleeding or abdominal pain [35]. Ho *et al.* reported a case of uterine and bladder rupture during the second stage of labor in a 39-year-old patient with a previous cesarean section [36]. The risk of uterine rupture is higher in patients undergoing induction of labor after previous cesarean section when compared with that in spontaneous labor. Lin *et al.* reported a higher rate of rupture in patients inducted with misoprostol and oxytocin, and suggested that the risk of rupture was higher in patients with multiple prior cesarean section [37]. Even if the American College of Obstetricians and Gynecologists Practice Patterns Committee concluded the oxytocin was not contraindicated for induction and augmentation of labour; based on the current literature, the use of oxytocin increase the risk of uterine rupture [38-40]. Grobman *et al.* reported that if the woman has an anamnesis of one prior vaginal delivery and one prior cesarean section, the risk of uterine rupture in labor is similar to the normal population [41].

Bujold *et al.* analyzed the cervical status before labor induction [42]. Although not statistically significant, the au-

thors found a trend towards a higher rate of uterine rupture in patients with a lower modified Bishop's score before labor induction. Harper *et al.* reported an increase of the risk in women with a cervical exam of < 2 cm and 2 to 3.9 cm at the initiation of oxytocin: "Women who received oxytocin starting at > 4 cm had a similar risk of uterine rupture as women who labored spontaneously" [43]. It seems to be important to consider the maximum dose of oxytocin for induction. Cahill *et al.* suggested that an upper limit of 20 mU/minute seems related to a reasonable risk of uterine rupture (1%) compared with upper doses ranging from 20 and 30 mU/minute, which are related to a risk of uterine rupture that ranged from 2.9% and 3.6% [44].

Another risk factor is the number of previous cesarean deliveries, as reported by Miller *et al.* that found a percentage of 1.7% of uterine rupture in patients with more than two cesarean sections, compared with a 0.6 % in case of single previous cesarean section [45]. Stamilio *et al.* reported a higher risk of uterine rupture if the interpregnancy interval was less than six months, with a percentage of uterine rupture of 2.7% [46]. A surgical risk factor is the type of suturing. The single-layer locked continuous suturing was associated with a higher uterine rupture risk than double layer closure [47]. Cahill *et al.* reported that women with twin gestations are less likely to attempt a VBAC, but they are not more likely to fail a VBAC trial or experience a major morbid event compared with women with singleton gestations [48]. Even though uterine rupture is a rare complication the consequences are of great clinical significance. The choice of a VBAC should be discussed with the patient because it could be important in their decision-making process. Uterine rupture may also be associated to oral misoprostol administration for induction of labor for termination of pregnancy. Chapman *et al.* found the incidence of uterine rupture was significantly higher among women with a prior cesarean section (three years 3.8% vs. one year 0.2%). All four uterine ruptures were in pregnancies of 22-24 weeks' gestation and had oxytocic induction agents [49].

Lu *et al.* reported an unusual case of uterine rupture caused by intra-amniotic ethacridine used for second trimester pregnancy termination with the expulsion of the fetus into the broad ligament through the lateral wall [50]. In contrast to second and third trimester uterine rupture, uterine rupture during the first trimester is an extremely rare complication, but as well life threatening cause of intraperitoneal hemorrhage. Some cases of a spontaneous first trimester rupture of the pregnant uterus following a previous cesarean section are described in literature [51]. Often first trimester uterine ruptures are related to scar dehiscences after previous cesarean sections [52]. Sliutz *et al.* postulated their hypotheses that all first trimester uterine ruptures are caused by scar implantation of the trophoblast [53].

Conclusions

Rupture of the non-labouring uterus is rare event in which the life of both the mother and the child are in danger. Spontaneous ruptures are almost always intrapartum and risk factors that can predispose to uterine rupture are a cesarean section scar, advanced maternal age, uterine abnormalities, grand multiparity, macrosomic fetus, cephalopelvic disproportion, and uterine trauma from prior instrumentation from abortion, version and oxytocin stimulation [54-60]; also risk factors associated with early uterine rupture in pregnancy include iatrogenic uterine perforation during hysteroscopy procedures, previous salpingectomy, and corneal resection following ectopic pregnancy and myomectomy laparoscopy or laparotomy [61, 62]. Other less common causes are placenta increta, congenital anomalies, trauma, and sacculation of entrapped retroverted uterus. Rupture of a cesarean section scar is usually considered to be the most common predisposing factor [63]. Rupture in a uterus without previous surgery is rare and most often associated with grand multiparity and long, obstructed labour, whereas traumatic rupture is often secondary to mechanical intervention, such as forceps delivery. The incidence ranges from one in 8,000 to one in 15,000 deliveries [64, 65]. It has been suggested that predisposing risk factors to such unexpected uterine rupture may include uterine diverticulae [66], arteriovenous malformation, and injudicious oxytocic stimulation [67]. Uterine rupture can also occur without these factors. Manouana *et al.* reported a case of uterine rupture during labour in which no predisposing factor existed, be it medical, surgical, gynecological or obstetrical [68]. In our cases, the patients had previous episodes of uterine curettage for missed abortion. We think that their patients may have had uterine scar from a unnoticed incomplete or complete uterine perforation during curettage. The perforation may have been situated at the uterine fundus and subsequently the products of conception of the current pregnancy may have embedded in that region, so that following continuous distension of the uterus with evolving pregnancy, there was a stretch of the weakened area leading finally to rupture and protrusion of the amniotic sac with the placenta into the peritoneal cavity. This hypothesis has already been made by Bevan *et al.* [69]. In literature there are few described cases of uterine rupture in pregnancy preceded by a dilatation and curettage for abortion because the lesion uterine remains most often misunderstood [70-72]. Also, in the latter case, the patient in the past had underwent a monolateral salpingectomy for ectopic pregnancy; it is believed that salpingectomy with corneal resection attenuates uterine musculature at the corneal region which can lead to a subsequent rupture of the uterus in the early course of pregnancy. The presence in history of previous minor surgery, such as curettage, should be considered a possible risk factor for uterine rupture during labor but also in the second trimester, resulting in a greater focus on the patient's symptoms during pregnancy and the

delivery. The postoperative course of previous interventions should investigate important symptoms such as fever or delayed discharge.

The presented cases show that there should be a high index of suspicious of uterine rupture in a gravid woman with a history of curettage for the possible presence of uterine scar misunderstood or for the presence of uterine scar understood and in women with a past history of salpingectomy with or without corneal resection.

Uterine rupture should be considered in the differential diagnosis in all pregnant patients who present with acute abdomen, show fluid collection in the peritoneal cavity, and have specific risks factors.

References

- [1] Plauchè W.C., Von Almen W., Muller E.: "Catastrophic uterine rupture". *Obstet Gynecol.*, 1984, 64, 792.
- [2] Syed S., Noreen H., Kahloon L.E., Chaudhri R.: "Uterine rupture associated with the use of intravaginal misoprostol during second trimester pregnancy termination". *J. Park Med. Assoc.*, 2011, 61, 399.
- [3] Capobianco G., Angioni S., Dessole M., Cherchi P.L.: "Cesarean section: to be or not to be, is this the question?" *Arch. Gynecol. Obstet.*, 2013, 288, 461.
- [4] Litta P., Leggieri C., Conte L., Dalla Toffola A., Multinu F., Angioni S.: "Monopolar versus bipolar device: safety, feasibility, limits and perioperative complications in performing hysteroscopic myomectomy". *Clin. Exp. Obstet. Gynecol.*, 2014, 41, 335.
- [5] Litta P., Conte L., DeMarchi F., Saccardi C., Angioni S.: "Pregnancy out come after hysteroscopic myomectomy". *Gynecol. Endocrinol.*, 2014, 30, 149.
- [6] Bedi D.G., Salmon A., Winsett M.Z., Fagan C.J., Kumar R.: "Ruptured uterus: sonographic findings". *J. Clin. Ultrasound*, 1986, 14, 529.
- [7] Hruska K.M., Coughlin B.F., Coggins A.A., Wiczky H.O.: "MRI diagnosis of spontaneous uterine rupture of an unscarred uterus". *Emerg. Radiol.*, 2006, 12, 186.
- [8] Bujold E., Gauthier R.J.: "Risk of uterine rupture associated with an interdelivery interval between 18 and 24 months". *Obstet. Gynecol.*, 2010, 115, 1003.
- [9] Punguyre D., Iserson K.V.: "A ruptured uterus in a pregnant woman not in labor". *Pan Afr. Med. J.*, 2011, 8, 2.
- [10] Rachagan S.P., Raman S., Balasundram G., Balakrishnan S.: "Rupture of the pregnant uterus-a 21 years review". *Aust. N. J. Obstet. Gynaecol.*, 1991, 31, 37.
- [11] Sun H.D., Su W.H., Chang W.H., Wen L., Huang B.S., Wang P.H.: "Rupture of a pregnant unscarred uterus in an early secondary trimester: a case report and brief review". *J. Obstet. Gynecol. Res.*, 2012, 38, 442.
- [12] Uccella S., Cromi A., Bogani G., Zaffaroni E., Ghezzi F.: "Spontaneous prelabor uterine rupture in a primi gravida: a case report and review of the literature". *Am. J. Obstet. Gynecol.*, 2011, 205, 6.
- [13] Nkwabong E., Kouam L., Takang W.: "Spontaneous uterine rupture during pregnancy: case report and review of literature". *Afr. J. Reprod. Health*, 2007, 11, 107.
- [14] Gurudut K.S., Gouda H.S., Aramani S.C., Patil R.H.: "Spontaneous rupture of unscarred gravid uterus". *J. Forensic Sci.*, 2011, 56, 263.
- [15] Sakr R., Berkane N., Barranger E., Dubernard G., Darai E., Uzan S.: "Unscarred uterine rupture-case report and literature review". *Clin. Exp. Obstet. Gynecol.*, 2007, 34, 190.
- [16] Tarney C.M., Whitecar P., Sewell M., Grubish L., Hope E.: "Rupture of an unscarred uterus in a quadruplet pregnancy". *Obstet. Gynecol.*, 2013, 121, 483.
- [17] Sun H.D., Su W.H., Chang W.H., Wen L., Huang B.S., Wang P.H.: "Rupture of a pregnant unscarred uterus in an early secondary trimester: a case report and brief review". *J. Obstet. Gynecol. Res.*, 2012, 38, 442.
- [18] Blè R.K., Adjoussu S., Doukoure B., Gallot D., Olou N., Koffi A., et al.: "Placenta percreta: a rare etiology of spontaneous uterine perforation in the second trimester of pregnancy". *Gynecol. Obstet. Fert.*, 2011, 39, 11.
- [19] Pistofidis G., Makrakis E., Balinakos P., Dimitriou E., Bardis N., Anaf V.: "Report of 7 uterine rupture cases after laparoscopy myomectomy: update of the literature". *J. Minim. Invasive Gynecol.*, 2012, 19, 762.
- [20] Xia X., Fan L., Xia Y., Fang Y.: "Uterine rupture during pregnancy". *Clin. Exp. Obstet. Gynecol.*, 2011, 38, 286.
- [21] Dane B., Dane C.: "Maternal death after uterine rupture in an unscarred uterus: a case report". *J. Emerg. Med.*, 2009, 37, 393.
- [22] Fatfouta I., Villeroy de Galhau S., Dietsch J., Eicher E., Perrin D.: "Spontaneous uterine rupture of an unscarred uterus during labor: case report and review of the literature". *J. Gynecol. Obstet. Biol. Reprod.*, 2008, 37, 200.
- [23] Cuellar Torriente M.: "Silent uterine rupture with the use of misoprostol for second trimester termination of pregnancy: a case report". *Obstet. Gynecol. Int.*, 2011, 2011, 584.
- [24] Chang C.Y., Chou S.Y., Chu I.L., Hsu C.S., Chian K.H., Chow P.K.: "Silent uterine rupture in an unscarred uterus". *Taiwan J. Obstet. Gynecol.*, 2006, 45, 250.
- [25] Nikolaou M., Kourea H.P., Antonopoulos K., Geronatsio K., Adonakis G., Decavalas G.: "Spontaneous uterine rupture in a primigravid woman in the early third trimester attributed to adenomyosis: a case report and review of the literature". *J. Obstet. Gynecol. Res.*, 2013, 39, 727.
- [26] Locci R., Nisolle M., Angioni S., Foidart J.M., Munaut C.: "Expression of the gamma 2 chain of laminin-332 in eutopic and ectopic endometrium of patient with endometriosis". *Reprod. Biol. Endocrinol.*, 2013, 11, 94.
- [27] Pisanu A., Deplano D., Angioni S., Ambu R., Uccheddu A.: "Rectal perforation from endometriosis in pregnancy: case report and literature review". *World J. Gastroenterol.*, 2010, 16, 648.
- [28] Agarwal R., Gupta B., Radhakrishnan G.: "Rupture of intrapartum unscarred uterus at the fundus: a complication of passive cocaine abuse?" *Arch. Gynecol. Obstet.*, 2011, 283, 53.
- [29] Palmer J.M., Indermaur M.D., Tebes C.C., Spellacy W.N.: "Placenta increta and cocaine abuse in a grand multipara leading to a second trimester rupture of an unscarred uterus: a case report". *South Med. J.*, 2008, 101, 834.
- [30] Rajiah P., Eastwood K.L., Gunn M.L., Dighe M.: "Uterine diverticulum". *Obstet. Gynecol.*, 2009, 113, 525.
- [31] Matsubara S., Shimada K., Kuwata T., Usui R., Suzuki M.: "Thin anterior uterine wall with incomplete uterine rupture in a primigravida detected by palpation and ultrasound: a case report". *J. Med. Case Rep.*, 2011, 17, 5.
- [32] Damiani G.R., Gaetani M., Landi S., Lacerenza L., Barnaba M., Spellecchia D., Pellegrino A.: "Uterine rupture in a nulliparous woman with septate uterus of the second trimester pregnancy and review in literature". *Int. J. Case Rep.*, 2013, 4, 259.
- [33] Billhovde L., Tawfik J., Hill D.A.: "Prelabor third trimester uterine rupture in an unscarred uterus with occlusion by fetal small parts: a case report". *J. Reprod. Med.*, 2010, 55, 437.
- [34] Hofmeyr G.J., Say L., Gulmezoglu A.M.: "Who systematic review of maternal mortality and morbidity: the prevalence of uterine rupture". *BJOG*, 2005, 112, 1221.
- [35] Rodriguez M.H., Masaki D.I., Phelan J.P., Diaz F.G.: "Uterine rupture: are intrauterine pressure catheters useful in the diagnosis?" *Am. J. Obstet. Gynecol.*, 1989, 161, 666.
- [36] Ho S.Y., Chang S.D., Liang C.C.: "Simultaneous uterine and urinary bladder rupture in an otherwise successful vaginal birth after cesarean delivery". *J. Chin. Med. Assoc.*, 2010, 73, 655.
- [37] Lin C., Raynor B.D.: "Risk of uterine rupture in labor induction of patients with prior cesarean section: an inner city hospital experience". *Am. J. Obstet. Gynecol.*, 2004, 190, 1476.

- [38] Zelop C.M., Shipp T.D., Repke J.T., Cohen A., Caughey A.B., Lieberman E.: "Uterine rupture during induced or augmented labor in gravid women with one prior cesarean delivery". *Am. J. Obstet. Gynecol.*, 1999, 181, 882.
- [39] Aslan H., Unlu E., Agar M., Ceylan Y.: "Uterine rupture associated with misoprostol labor induction in women with previous cesarean delivery". *Eur. J. Obstet. Gynecol. Reprod. Biol.*, 2004, 113, 45.
- [40] Landon M.B., Hauth J.C., Leveno K.J., Spong C.Y., Leindecker S., Varner M.W., et al.: "Maternal and perinatal outcomes associated with a trial of labor after prior cesarean delivery". *N. Engl. J. Med.*, 2004, 351, 2581.
- [41] Grobman W.A., Lai Y., Landon M.B., Spong C.Y., Leveno K.J., Rouse D.J., et al.: "Prediction of uterine rupture associated with attempted vaginal birth after cesarean delivery". *Am. J. Obstet. Gynecol.*, 2008, 199, 30.e1.
- [42] Bujold E., Gauthier R.J.: "Risk of uterine rupture associated with an interdelivery interval between 18 and 24 months". *Obstet. Gynecol.*, 2010, 115, 1003.
- [43] Harper L.M., Cahill A.G., Boslaugh S., Odibo A.O., Stamilio D.M., Roehl K.A., Macones G.A.: "Association of induction of labor and uterine rupture in women attempting vaginal birth after cesarean: a survival analysis". *Am. J. Obstet. Gynecol.*, 2012, 206, 51.e1.
- [44] Cahill A.G., Waterman B.M., Stamilio D.M., Odibo A.O., Allsworth J.E., Evanoff B., Macones G.A.: "Higher maximum doses of oxytocin are associated with an unacceptably high risk for uterine rupture in patients attempting vaginal birth after cesarean delivery". *Am. J. Obstet. Gynecol.*, 2008, 199, 32.
- [45] Miller D.A., Diaz F.G., Paul R.H.: "Vaginal birth after cesarean: a 10-year experience". *Obstet. Gynecol.*, 1994, 84, 255.
- [46] Stamilio D.M., DeFranco E., Paré E., Odibo A.O., Peipert J.F., Allsworth J.E., et al.: "Short interpregnancy interval: risk of uterine rupture and complications of vaginal birth after cesarean delivery". *Obstet. Gynecol.*, 2007, 110, 1075.
- [47] Roberge S., Chaillet N., Boutin A., Moore L., Jastrow N., Brassard N., et al.: "Single- versus double-layer closure of the hysterotomy incision during cesarean delivery and risk of uterine rupture". *Int J Gynaecol Obstet.*, 2011, 115, 5.
- [48] Cahill A.G., Stamilio D.M., Odibo A.O., Peipert J.F., Stevens E.J., Macones G.A.: "Does a maximum dose of oxytocin affect risk for uterine rupture in candidates for vaginal birth after cesarean delivery?" *Am. J. Obstet. Gynecol.*, 2007, 197, 495.e1.
- [49] Chapman S., Crispens M.A., Owen J., Savage K.: "Complications of mid-trimester pregnancy terminations: the effect of prior cesarean delivery". *Am. J. Obstet. Gynecol.*, 1996, 174, 356.
- [50] Ye L., Yang T., Luo H., Li Q.: "Diagnosis of uterine rupture with ultrasound: an unusual presentation with extrusion of fetus into the broad ligament at second trimester". *Journal of Medical Ultrasound*, 2012, 20, 173.
- [51] Dabulis S.A., McQuirk T.D.: "An unusual case of hemoperitoneum: uterine rupture at 9 weeks gestational age". *J. Emerg. Med.*, 2007, 33, 285.
- [52] Ismail S.I., Toon P.G.: "First trimester rupture of previous caesarean section scar". *J. Obstet. Gynaecol.*, 2007, 27, 202.
- [53] Sliutz G., Sanani R., Spängler-Wierrani B., Wierrani F.: "First trimester uterine rupture and scar pregnancy". *Med. Hypotheses*, 2009, 73, 326.
- [54] Paydar M., Hassanzadeh A.: "Rupture of the uterus". *Int. J. Gynecol. Obstet.*, 1978, 15, 405.
- [55] Waish C.A., Baxi L.V.: "Rupture of the primigravid uterus: a review of the literature". *Obstet. Gynecol. Surv.*, 2007, 62, 327.
- [56] Sweeten K.M., Graves W.K., Athanassiou A.: "Spontaneous rupture of the unscarred uterus". *Am. J. Obstet. Gynecol.*, 1995, 172, 1851.
- [57] Isah A.Y., Nwobodo E.I., Tunau K.A., Sununu Y.T.: "Ruptured uterus in a booked patient". *Niger J. Clin. Pract.*, 2011, 14, 499.
- [58] Ahmadi S., Nouira M., Bibi M., Boughi Zane S., Sadi H., Chaib A.: "Rupture uterine sur uterus sain gravide. A propos de 28 case". *Gynecol. Obstet. Fertil.*, 2003, 31, 713.
- [59] Al Salem M.H., Makhseed M., Ahmed M.A., Gupta M.: "Rupture of the gravid uterus: experience of the maternity hospital, Kuwait". *Med. Principles Pract.*, 2000, 9, 97.
- [60] Arbab F., Boulieu D., Bied V., Payan F., Cornage J., Guérin J.F.: "Uterine rupture in first or second trimester of pregnancy after in vitro fertilization and embryo transfer". *Hum. Reprod.*, 1996, 11, 1120.
- [61] Dubuisson J.B., Chavet X., Chapron C., Gregorakis S.S., Morice P.: "Uterine rupture after laparoscopic myomectomy". *Hum. Reprod.*, 1995, 10, 1475.
- [62] Torbè A., Mikolajek-Bedner W., Kałużyński W., Gutowska-Czajka D., Kwiatkowski S., Błogowski W., et al.: "Uterine rupture in the second trimester of pregnancy as an iatrogenic complication of laparoscopic myomectomy". *Medicina (Kaunas)*, 2012, 48, 182.
- [63] Kanagal D.V., Hanumanalu L.C.: "Ruptured rudimentary horn pregnancy at 25 weeks with previous vaginal delivery: a case report". *Case Rep. Obstet. Gynecol.*, 2012, 2012, 985076.
- [64] Barger M.K., Weiss J., Nannini A., Werler M., Heeren T., Stubblefield P.G.: "Risk factors for uterine rupture among women who attempt a vaginal birth after a previous cesarean: a case control study". *J. Reprod. Med.*, 2011, 56, 313.
- [65] Olagbujii B.N., Okonofua F., Ande A.B.: "Uterine rupture and risks factors for cesarean delivery following induced labour in women with one previous lower segment cesarean section". *J. Mater. Fetal Neonat. Med.*, 2012, 25, 1970.
- [66] M'Lellan A.N.: "Rupture of a pregnant diverticulum of the uterus". *Glasgow Med. J.*, 1916, 3, 390.
- [67] Pary E., Wells M., Baxter T., Lane G.: "Recurrent spontaneous rupture in a nulliparous young woman". *Br. J. Obstet. Gynecol.*, 1995, 102, 420.
- [68] Manouana M., Louis O., Lorgeron P., Pettini R., Lameyred D., Meynieu F.: "Rupture spontanée, pendant le travail, d'un uterus non cicatriciel sous analgésie péridurale: a propos d'un cas". *J. Gynecol. Obstet. Biol. Reprod.*, 1995, 24, 557.
- [69] Bevan J.R., Marley N.J.E., Ozumba E.N.: "Uterine rupture, placenta percreta and curettage in early pregnancy. Case report". *Br. Obstet. Gynecol.*, 1985, 92, 642.
- [70] Mair J.: "Rupture of the uterus in labour due to previous perforation of its wall at curettage". *J. Obstet. Gynecol. Br. Emp.*, 1950, 57, 539.
- [71] Fedorkow D.M., Nimrod C.A., Taylor P.J.: "Ruptured uterus in pregnancy: a Canadian hospital's experience". *CMAJ*, 1987, 137, 27.
- [72] Teunissen K.K., Lopriore E., Nijman R.G., Brouwer P.A., Van Kamp I.L.: "Silent uterine rupture, an unusual cause of anhydramnios". *Am. J. Obstet. Gynecol.*, 2007, 196, 8.

Address reprint requests to:
 S. ANGIIONI M.D., Ph.D.,
 Department of Surgical Sciences
 Section of Obstetrics & Gynecology
 University of Cagliari
 Azienda Ospedaliero Universitaria
 Blocco Q
 SS554, 09124 Monserrato (Italy)
 e-mail: sangioni@yahoo.it



EAGC

**EUROPEAN ACADEMY
OF GYNAECOLOGICAL CANCER, EAGC**

Chairman: *Péter Bősze (Hungary)*

Executive Board:

PIERLUIGI BENEDETTI PANICI (Italy)
CARLOS F. DE OLIVEIRA (Portugal)
GIUSEPPE DE PALO (Italy)
SANTIAGO DEXEUS (Spain)
WILLIAM DUNLOP (UK)
STELIOS FOTIOU (Greece)
GERALD GITSCH (Austria)
A. PETER M. HEINTZ (Netherlands)
MICHAEL HOECKEL (Germany)
JAN JACOBS (UK)
JACQUES LANSAC (France)
TIZIANO MAGGINO (Italy)
HARALD MEDEN (Germany)
JOSEPH MONSONEGO (France)
LASZLÓ PÁLFALVI (Hungary)
SERGIO PECORELLI (Italy)
DENIS QUELLEU (France)
STELIO RAKAR (Slovenia)

PIERO SISMONDI (Italy)
CLAES TROPÉ (Norway)
LÁSZLÓ UNGÁR (Hungary)
ANDRÉ VAN ASSCHE (Belgium)
RAIMUND WINTER (Austria)

International Advisory Board

Chairman: *Antonio Onnis (Italy)*

HUGH ALLEN (Canada)
CURT W. BURGER (Netherlands)
ALBERTO COSTA (Italy)
ANDRÉ GORINS (France)
NEVILLE F. HACKER (Australia)
MARIA MARCHETTI (Italy)
STELIOS P. MICHALAS (Greece)
MARIA TERESA OSORIO (Portugal)
ULF ULMSTEN (Sweden)
JAN B. VERMORKEN (Belgium)
GEORGE D. WILBANKS (USA)
JAN ZIELINSKI (Poland)

All questions concerning the Accademy may be sent to:
PETER BOSZE, M.D. - P.O. Box 46 - Budapest 1301 (Hungary)
Phone: +36 1 4290317 - Fax: +36 1 2752172 - E-mail: eagc@cme.hu


www.cme.hu

Administrative Office:
1301 Budapest, P.O. Box 46 - Hungary
Fax (36 1) 4290318 - E-mail: eagc@cme.hu

ISSN: 0390-6663

Clinical and Experimental Obstetrics & Gynecology

an International Journal



I.R.O.G. CANADA, Inc. - 4900 Côte St-Luc - Apt # 212
Montréal, Qué. H3W 2H3 (Canada)
Tel. +514-4893242 - Fax +514-4854513 - E-mail: canlux@qc.airo.com - www.irog.net


Founding Editor
A. Onnis
Montréal (CND)

Editors-in-Chief
M. Marchetti **J.H. Check**
Montréal (CND) *Camden, NJ (USA)*

Assistant Editor
A. Sinopoli
Toronto (CND)

EJGO

European Journal of Gynaecological Oncology



Founding Editor
A. Onnis
Montréal (Canada)

Editors-in-Chief
M. Marchetti **P. Bősze**
Montréal (Canada) *Budapest (Hungary)*

Associate Editor
T. Maggino
Padua (Italy)

Assistant Editor
A. Sinopoli
Toronto (CND)

CLINICAL AND EXPERIMENTAL OBSTETRICS & GYNECOLOGY

Subscription Order Card 2016

Founded in 1974 (ISSN 0390-6663) - Vol. XLIII. Issued bimonthly. All subscriptions are entered on a calendar-year basis. Individual rate is not applicable if payment is made through an Institution.

Subscriptions are entered with prepayment only and are accepted per calendar year only but can be backdated depending on availability. If not cancelled by the end of October, they will be tacitly considered as renewed; cancellations will not be refunded.

Discounts: 10% to book sellers and subscription agencies.

Please enter my subscription at the rate I have checked:

PAPER ISSUE

- Institutional: 700 USD
 Individual: 500 USD
 Single copy: 150 USD

ONLINE ISSUE

- Institutional: 450 USD
 Individual: 270 USD
 Single issue: 100 USD
 Single article: 30 USD

Payment: (USD ONLY)

for PDF file: online through PayPal (all credit cards)

for hard copy

Credit Card: Mastercard Visa Diners

Bank transfer: *Beneficiary:* 7847050 Canada Inc. - 4900 Côte St-Luc, #212 - Montréal, Québec, H3W 2H3 Canada - Account number 00001 003402-402245 SWIFT ROYCCAT2

N° _____ Exp. Date _____

Signature _____ Date _____

An invoice is issued only after payment is processed; no proforma receipts will be issued. The subscription order form is available through the Montréal office (Fax +1-514-485-4513) or Padua office (Fax +39-049-8752018) or through our website www.irog.net

EUROPEAN JOURNAL OF GYNAECOLOGICAL ONCOLOGY

Subscription Order Card 2016

Founded in 1980 (ISSN 0392-2936) - Vol. XXXVII. Issued bimonthly. All subscriptions are entered on a calendar-year basis. Individual rate is not applicable if payment is made through an Institution.

Subscriptions are entered with prepayment only and are accepted per calendar year only but can be backdated depending on availability. If not cancelled by the end of October, they will be tacitly considered as renewed; cancellations will not be refunded.

Discounts: 10% to book sellers and subscription agencies.

Please enter my subscription at the rate I have checked:

PAPER ISSUE

- Institutional: 700 USD
 Individual: 500 USD
 Single copy: 150 USD

ONLINE ISSUE

- Institutional: 450 USD
 Individual: 270 USD
 Single issue: 100 USD
 Single article: 30 USD

Payment: (USD ONLY)

for PDF file: online through PayPal (all credit cards)

for hard copy

Credit Card: Mastercard Visa Diners

Bank transfer: *Beneficiary:* 7847050 Canada Inc. - 4900 Côte St-Luc, #212 - Montréal, Québec, H3W 2H3 Canada - Account number 00001 003402-402245 SWIFT ROYCCAT2

N° _____ Exp. Date _____

Signature _____ Date _____

An invoice is issued only after payment is processed; no proforma receipts will be issued. The subscription order form is available through the Montréal office (Fax +1-514-485-4513) or Padua office (Fax +39-049-8752018) or through our website www.irog.net