



JUNE 4 - 7, 2014

SKOPJE, MACEDONIA

Organized by:



MACEDONIAN SOCIETY OF CARDIOLOGY

In cooperation with:



UNIVERSITY CLINIC OF CARDIOLOGY

Supported by:



EUROPEAN SOCIETY OF CARDIOLOGY

ABSTRACT BOOK

www.msccardiology.org.mk

General sponsor:



**ALKALOID
SKOPJE**

Health above all

www.alkaloid.com.mk

5th MACEDONIAN CONGRESS OF CARDIOLOGY

Organized by:



MACEDONIAN SOCIETY OF CARDIOLOGY

In cooperation with:



UNIVERSITY CLINIC OF CARDIOLOGY

Supported by:



**EUROPEAN
SOCIETY OF
CARDIOLOGY®**

EUROPEAN SOCIETY OF CARDIOLOGY

General sponsor:



**ALKALOID
SKOPJE**

Health above all

www.alkaloid.com.mk

Dear Colleagues,

I am honoured to invite you to participate at the 5th Macedonian Congress of Cardiology with international participation that is going to be held from 4th to 7th June 2014, in Skopje, Republic of Macedonia.


Cardiovascular diseases are still the worldwide leading cause for morbidity and mortality. The main topic of the Congress will be the Acute Coronary Syndrom, Interventional cardiology, Imaging in Cardiovascular Diseases and Peripheral Artery Diseases. Of course, the preventive cardiology, the non-invasive diagnostics, electrophysiology and electrostimulation, congenital and valvular heart diseases, cardiopathies, cardiac surgery, pediatric cardiology will also be given attention. The Congress is organised with plenary sessions by domestic and international experts, symposia, round tables, oral and poster presentations from cardiovascular medicine.

This Congress will enable exchange of experience from diagnostics and medical treatment of cardiovascular diseases, gathering information from the latest experts and scientific achievements and meeting colleagues from the country and abroad.

Prof. Sasko Kedev MD, PhD, FESC, FACC

President of the Macedonian Society of Cardiology

President of the 5-th Macedonian Congress of Cardiology



Congress committees

President

Sasko Kedev

General Secretary

Elizabeta Srbinovska-Kostovska

Treasurer

Jorgo Kostov

Organization Committee

Slobodan Antov	Nikola Bakraceski
Marija Vavlukis	Fatmir Ferati
Lidija Poposka	Agim Zekiri
Marijan Bosevski	Snezana Meskoska
Nela Kostova	Tanja Anguseva
Irena Peovska	

Scientific Committee

Mitko Kjaev	Igor Spirovski
Jelka Davceva Pavlovska	Oliver Kalpak
Lidija Kamcevska Dobrkovic	Emilija Antova
Slavco Tosev	Borjanka Taneva
Samuel Sadikario	Lujza Grueva
Biljana Sidovska	Vesna Bozinovska
Ljubica Georgievska Ismail	Valentina Andova
Lazar Lazarov	Biljana Gjorgjievska
Silvana Jovanova	Vladimir Boskov
Salis Tager	Bekim Pocesta
Zan Mitrev	Marjan Bosev
Branislav Miletic	Emilija Caparoska Velickovska
Rozalinda Kacarska	Frosina Arnaudova Dezulovic
Hristo Pejkov	Emilija Lazarova Trajkova
Magdalena Otljanska	

Local Committee

Savetka Paljoskoska Jordanova
Sasa Kjaeva
Enes Sehu
Aleksandar Jovkovski
Dejan Ristevski

Jane Talevski
Hajber Taravari
Danica Petkovska
Biljana Zafirovska

International Faculty

Branko Beleslin, Belgrade, Serbia
Thomas Binder, Vienna, Austria
Noel G. Boyle, Los Angeles, CA, USA
Esad Brkic, Tuzla, Bosnia and Herzegovina
Rafaelle Bugiardini, Bologna, Italy
Matjaz Bunc, Ljubljana, Slovenia
Vincent Dangoisse, Mont-Godinne, Belgium
Dan Deleanu, Bucarest, Romania
Admir Dedic, Rotterdam, Netherlands
Surya Dharma, Jakarta, Indonesia
Aneta Dimova, Albany, NY, USA
Alma Dzankovic, Sarajevo, BiH
Edina Cenko, Bologna, Italy
Bode Christoph, Freiburg, Germany
Sunil Rao, Durham, NC, USA
Valery Gelev, Sofia, Bulgaria
Allesandro Giordano, Roma, Italy
Marco Gricar, Ljubljana, Slovenia
Robert Hatala, Bratislava, Slovakia
Krasimira Hristova, Sofia, Bulgaria
Petar Hlivak, Bratislava, Slovakia
Mario Ivanusa, Zagreb, Croatia
Vojko Kanic, Maribor, Slovenia
Dimitra Kalimanovska Ostric, Belgrade, Serbia
Jaroslav Kasperzak, Warsaw, Poland
Josef Kautzner, Prague, Czech Republic
Telat Keles, Ankara, Turkey
Kostadin Kitchukov, Sofia, Bulgaria
Rafael Kuperstain, Tel Aviv, Izrael
Miroslaw Kowalski, Warsaw, Poland
Nebojsa Lalic, Belgrade, Serbia
Yves Louvard, Paris, France
Sundeep Mishra, New Delhi, India

Stefan Naydenov, Sofia, Bulgaria
Milan Nedeljkovic, Belgrade, Serbia
Aleksandar Neskovic, Belgrade, Serbia
Marko Noc, Ljubljana, Slovenia
Miodrag Ostojic, Belgrade, Serbia
Necla Ozer, Ankara, Turkey
Samir Pancholy, Scranton, PA, USA
Petr Peichl, Prague, Czech Republic
Ivo Petrov, Sofia, Bulgaria
Brian Pinto, Mumbai, India
Belma Pojskic, Zenica, BiH
Bogdan Popescou, Bucharest, Romania
Sunil Rao, Durham, NC, USA
Arsen Ristic, Belgrade, Serbia
Marco Roffi, Geneva, Switzerland
Nikolai Runev, Sofia, Bulgaria
Evgeny Shlyakhto, S. Petersburg, Russia
Rabhat Sabani, Sofia, Bulgaria
Jadranka Separovic Hanzevacki, Zagreb, Croatia
Georgios Sianos, Thessaloniki, Greece
Goran Stankovic, Belgrade, Serbia
Sinisha Stojkovic, Belgrade, Serbia
Svetliv Tsonev, Sofia, Bulgaria
Igor Tulevski, Amsterdam, Netherlands
Kristian Thygesen, Aarhus, Denmark
Yoto Yotov, Varna, Bulgaria
Imre Ungi, Budapest, Hungary
Dobrin Vassilev, Sofia, Bulgaria
Vasil Velchev, Sofia, Bulgaria
Josip Vincelj, Zagreb, Croatia
Katerina Vitlyanova, Sofia, Bulgaria
Franz Weidinger, Vienna, Austria
Igor Zupan, Ljubljana, Slovenia

Wednesday 04.06.2014 Main Hall

SATELLITE SYMPOSIUM IN CARDIO-DIABETOLOGY

Under the Auspices of **THE AMERICAN AUSTRIAN FOUNDATION**
In Collaboration with **MACEDONIAN SOCIETY OF CARDIOLOGY**

June the 4-th, 2014 - Skopje, Macedonia

- 10:00-10:15 Welcome Address, Introduce Lecturers, Academic Institutions and the Open Medical Institute
Themes:
- 10:15-10:45 **Nebojsa Lalic (Belgrade, Serbia)** Pathophysiology and treatment of Type 2 Diabetes (recent controversies)
- 10:45 -11:15 **Nebojsa Lalic (Belgrade, Serbia)** Diabetes treatment in Hospitalized Patients in ICU
- 11:15 -11:45 **Nebojsa Lalic (Belgrade, Serbia)** Insulin pumps in diabetes treatment
Questions / Discussion
- 11:45-12:00 *Coffee Break*
- 12:00-12:30 **Marijan Bosevski (Skopje, Macedonia)** Coronary Artery Disease and risk equivalents in Diabetes
- 12:30-13:00 **Marija Vavlukis (Skopje, Macedonia)** Non invasive tests in risk stratification of diabetic patients
- 13:00-13:30 **Slobodan Antov (Skopje, Macedonia)** Revascularization strategies in diabetic patient
Questions / Discussion
- 13:30-14:30 *Lunch*
- 14:30-16:30 Case Presentations and discussion
Nela Kostova (Skopje, Macedonia) Noninvasive imaging in patient with diabetes mellitus
Hajber Taravari (Skopje, Macedonia) PCI specifics in diabetic patients
Darko Kitanovski (Skopje, Macedonia) Diabetes mellitus treatment in intensive coronary unit
Irfan Ahmeti (Skopje, Macedonia) Diabetic foot
Filip Lokvenec (Skopje, Macedonia) Diabetes mellitus from the point of view of GP
- 16:30-17:00 Closing Remarks / Certificates Awarded
- 17:00-20:00 REGISTRATION** - open
- 20:00** **Opening ceremony of the V-th Macedonian Congress of Cardiology**
Welcome address
Welcome Cocktail organized by the General sponsor Alkaloid AD, Skopje

- 08:00-10:15 JOINT SESSION WITH EUROPEAN SOCIETY OF CARDIOLOGY:
UPDATE IN ACUTE CORONARY SYNDROME**
Chairpersons: Sasko Kedev, Marco Roffi
**Panellists: Franz Weidinger, Marco Noc, Dan Deleanu,
Kristian Thygesen**
- 08:00-08:15 **Kristian Thygesen (Aarhus, Denmark)** Evolution of the definition in myocardial infarction
- 08:15-08:30 **Marco Roffi (Geneva, Switzerland)** Key Aspects of the ESC STEM Guidelines
- 08:30-08:45 **Sunil Rao (Durham, USA)** Importance of bleeding complications in ACS
- 08:45-09:00 **Franz Weidinger (Vienna, Austria)** Optimal reperfusion therapy in STEMI, from recent studies to registries
- 09:00-09:15 **Marco Noc(Ljubljana, Slovenia)** "Optimal antithrombotic therapy for PPCI, lessons from HEAT-PPCI, BRAVE-4 "
- 09:15-09:30 **Sasko Kedev (Skopje, Macedonia)** TRA vs TFA in PPCI: Macedonian STEMI Registry
- 09:30-09:45 **Dan Deleanu (Bucharest, Romania)** Stent for life, Romania,
- 09:45-10:00 **Miodrag Ostojic (Belgrade, Serbia)** Pharmacoinvasive approach in the treatment of STEMI: lessons learned from the STREAM study
- 10:00-10:15 Discussion
- 10:15-10:30 Coffee break**
- 10:30-12:30 PLENARY SESSION I: HOT TOPICS IN PERCUTANEOUS
CORONARY INTERVENTIONS**
Chairpersons: Yves Louvard, Sunil Rao
**Panellists: Samir Pancholy, Sundeep Mishra, Jorgo Kostov,
Hristo Pejkov**
- 10:30-10:45 **Yves Louvard (Paris, France)** Left Main PCI: Patient selection and technique
- 10:45-11:00 **Sunil Rao (Durham, USA)** Worldwide uptake of radial access
- 11:00-11:15 **Samir Pancholy (Scranton PA, USA)** Radiation exposure and Transradial approach
- 11:15-11:30 **Sundeep Mishra (New Delhi, India)** How to apply bioresorbable stent technology in clinical practice: Has the time of BRS arrived yet?
- 11:30-11:45 **Igor Tulevski (Amsterdam, Netherlands)** How to keep the pace with increasing demand, clicks and bricks
- 11:45-12:00 **Brian Pinto (Mumbai, India)** The Benefits & pitfalls of FFR

- 12:00-12:15 **Rafaele Bugiardini (Bologna, Italy)** Coronary revascularization in stable patients after an acute coronary syndrome: in some but not in others
- 12:15-12:30 Discussion
- 12:30-13:30** **Satelite Symposium , "ALKALOID" AD Skopje**
Speaker: Sasko Kedev (Skopje, Macedonia) Therapeutical strategies for cardiovascular risk factor regulation
Vesna Stojanov (Belgrade, Serbia) Hypertension therapy as a risk factor in the light of the new recommendations
- 13:30-14:00** **Satellite Symposium "Sanofi Aventis" and "Alkaloid Cons"**
Speaker: Sasko Kedev (Skopje, Macedonia) The place of the Enoxaparin in treatment of ACS, according to new guidelines
- 14:00-15:00** **Lunch Session: Case based problem solving session with experts**
Chairperson: Samir Pancholy
Panellists: Vincent Dangoisse, Brian Pinto, Sundeep Mishra, Imre Ungi
- 15:00-17:00** **PLENARY SESSION II: Coronary bifurcations and CTO PCI,**
Chairpersons: Goran Stankovic, George Sianos
Panellists: Dobrin Vassilev, Slobodan Antov, Imre Ungi, Oliver Kalpak
- 15:00-15:15 **Goran Stankovic (Belgrade, Serbia)** Latest update in PCI for Bifurcations: techniques and outcomes
- 15:15-15:30 **Dobrin Vassilev (Sofia, Bulgaria)** Bulgarian registry for distal left main stem stenting with dedicated coronary bifurcation stent
- 15:30-15:45 **Branko Beleslin (Belgrade, Serbia)** FFR assessment in PCI for bifurcations, CTOs and more
- 15:45-16:00 **George Sianos (Thessaloniki, Greece)** Essential CTO update
- 16:00-16:15 **Valery Gelev (Sofia, Bulgaria)** Traditional Antegrade true lumen approach in CTO PCI
- 16:15-16:30 **Sinisha Stojkovic (Belgrade, Serbia)** Retrograde approach in CTO PCI
- 16:30-16:45 **Vojko Kanic (Maribor, Slovenia)** PCI of Left main coronary artery in patients with cardiogenic shock
- 16:45-17:00 Discussion
- 17:00-17:15** **Coffee break**
- 17:15-19:00** **PLENARY SESSION III: Dedicated Transradial Session – part I**
Chairperson: Sunil Rao, Sasko Kedev
Panellists: Samir Pancholy, Brian Pinto, Vincent Dangoisse, Igor Spiroski
- 17:15-17:30 **Samir Pancholy (Scranton PA, USA)** Radial artery preservation strategies

- 17:30-17:45 **Vincent Dangoisse (Mont-Godinne, Belgium)** "D Vin" technique of distal buddy in Jail technique
- 17:45-18:00 **Brian Pinto (Mumbai, India)** Methods to facilitate stent delivery in difficult situations
- 18:00-18:15 **Imre Ungi (Budapest, Hungary)** Transradial access for CTO PCI
- 18:15-18:30 **Surya Dharma (Jakarta, Indonesia)** The best of TRA literature last year
- 18:30-18:45 **Igor Spiroski (Skopje, Macedonia)** Can we use the wrist access for all patients?
- 18:45-19:00 Discussion
- 19:00-20:00** **Satelite Symposium , "KRKA Pharma" Skopje**
"Reaching the target. Reducing the risk"
Speaker: Sasko Kedev (Skopje, Macedonia),
Marco Gricar (Ljubljana, Slovenia)
- Cocktail organized by "Krka Pharma" Skopje**

Thursday 05.06.2014 Hall 2

- 08:00-10:00** **Joint Session Macedonian Society of Cardiology with Bulgarian Working group of cardiovascular risk for women**
Chairpersons: Elizabeta Srbinovska-Kostovska, Katerina Vitlanova
Panellists: Silvana Jovanova, Nikolai Runev, Marijan Bosevski
- 08:00-08:15 **Silvana Jovanova (Skopje, Macedonia)** Gender differences in cardiovascular diseases
- 08:15-08:30 **Stefan Naydenov (Sofia, Bulgaria)** Prevalence of cardiovascular risk factors among women in Bulgaria
- 08:30-08:45 **Svetlin Tsonev (Sofia, Bulgaria)** Intimate differences in ischemia mechanism in coronary artery diseases and cardiac Syndrome X
- 08:45-09:00 **Katerina Vitlanova (Sofia, Bulgaria)** Hemoxygenase-I and chronic heart failure-are there any diagnostic opportunities
- 09:00-09:15 **Elizabeta Srbinovska Kostovska (Skopje, Macedonia)** Role of echocardiography in detection potential source of cardioembolism
- 09:15-09:30 **Marijan Bosevski (Skopje, Macedonia)** Venous thromboembolism , Importance of National Registry
- 09:30-09:45 Discussion
- 10:00-11:00** **Satellite Symposium Sponsored by "General Electric Ultrasound"**
"Three-dimensional echocardiography in clinical practice. Is 3D better than 2D?" Jaroslav Kasprzak (Warsaw, Poland)
- 11:00-13:00** **CHALLENGES AND PITFALLS IN HEART FAILURE TREATMENT**
HFA Focus-Clinical interactive case-based sessions
Chairpersons: Jelka Davceva Pavlovska, Ljubica Georgievska Ismail
Panellists: Katerina Vitlanova, Amra Dzankovic, Marija Vavlukis
- 11:00-11:15 **Ljubica Georgievska Ismail (Skopje, Macedonia)** Heart failure with preserved ejection fraction
- 11:15-11:30 **Elizabeta Srbinovska Kostovska (Skopje, Macedonia)** Chronic Heart failure, what Guidelines say?
- 11:30-11:45 **Marija Vavlukis (Skopje, Macedonia)** Acute heart failure precipitated by acute coronary syndrome , what should we treat first?
- 11:45 -12:00 **Silvana Jovanova (Skopje, Macedonia)** Cardiomyopaties and heart failure: patomorphological and clinical continuum
- 12:00-12:15 **Esad Brkic (Tuzla, Bosnia & Herzegovina)**
 Takotsubo cardiomyopathy, case report
- 12:15-12:30 **Emilija Caparoska Velickovska (Skopje, Macedonia)** Insufficient diuretic response/diuretic resistance, renal impairment and ultra filtration
- 12:30-12:45 **Petar Dejanov (Skopje Macedonia)** Endothelial dysfunction in patients with end-stage renal failure, the interaction between coagulation and inflammation

- 12:45-13:00 Discussion
- 15:00-16:45 PEDIATRIC CARDIOLOGY/ SPORT AND CARDIOLOGY**
Chairpersons: Dimitra Kalimanovska Ostric, Roza Starova
Panellists: Ivan Milev, Vaska Antevska, Stefan Naydenov
- 15:00-15:15 **Dimitra Kalimanovska Ostric (Belgrade, Serbia)** Improved management of grown-up congenital heart diseases
- 15:15-15:30 **Ivan Milev (Skopje, Macedonia)** Percutaneous interventions of heart defects, short and mid-term results
- 15:30-15:45 **Konstandina Kuzevska Maneva (Skopje, Macedonia)** Role of echocardiography in the diagnosis of anomalous pulmonary venous connection
- 15:45-16:00 **Beti Dejanova (Skopje, Macedonia)** Promotion of exercise and sport in cardiovascular diseases protection. Mechanism of action
- 16:00-16:15 **Stefan Naydenov (Sofia, Bulgaria)** Athlete's heart or hypertrophic cardiomyopathy?
- 16:15-16:30 **Rabhat Sabani (Sofia, Bulgaria)** Athlete's heart
- 16:30-16:45 Discussion
- 16:45-17:00 Coffee break**
- 17:00-18:45 MULTIMODALITY NONINVASIVE IMAGING OF CAD PATIENT**
Chairpersons: Aneta Dimova, Igor Tulevski, Daniela Pop Gjorceva
Panellists: Admir Dedic, Marija Vavlukis, Venjamin Majstorov
- 17:00-17:15 **Admir Dedic (Rotterdam, Netherlands)** Cardiac computed tomography in guiding patient management: New approaches and applications
- 17:15-17:30 **Admir Dedic (Rotterdam, Netherlands)** Utility of cardiac magnetic resonance in guiding patient management. Clinical value of cardiac MRI in ischemic heart disease
- 17:30-17:45 **A.Giordano (Roma, Italy)** Positron emission tomography imaging for ischemic heart disease
- 17:45-18:00 **Venjamin Majstorov (Skopje, Macedonia)** Nuclear imaging in guiding patient management and coronary revascularization. Do we need proof of ischemia prior to revascularization? Single photon emission computed tomography for the assessment of viability)
- 18:00-18:15 **Jelka Davceva Pavlovska (Skopje, Macedonia)** Early exercise stress testing after primary percutaneous coronary intervention in the light of scientific data
- 18:15-18:30 **Irena Peoska (Skopje, Macedonia)** What is the best initial treatment strategy for patients with stable ischemic heart disease? The role of noninvasive imaging
- 18:30-18:45 Discussion

Friday 06.06.2014 Main Hall

- 08:15-10:15** **ARRHYTHMIAS AND DEVICE THERAPY, NEWS AND CHALLENGES**
Chairpersons: Lidija Poposka, Igor Zupan
Panellists: Joseph Kautzner, Lidija Dobrkovic, Vladimir Boskov
- 08:15-08:30 **Igor Zupan (Ljubljana, Slovenia)** Current indications for cardiac resynchronization therapy
- 08:30-08:45 **Joseph Kautzner (Prague, Czech Republic)** CRTp versus CRTd
- 08:45-09:00 **Robert Hatala (Bratislava, Slovakia)** CRT in patients with atrial fibrillation
- 09:00-09:15 **Noel G. Boyle (Los Angeles CA, USA)** Recent advances in ICD Programming
- 09:15-09:30 **Petr Peichl (Prague, Czech Republic)** Rhythm or rate control in atrial fibrillation
- 09:30-09:45 **Peter Hlivak (Bratislava, Slovakia)** Drugs or catheter ablation for rhythm control
- 09:45-10:00 **Lidija Poposka (Skopje, Macedonia)** Antithrombotic prophylaxis
- 10:00-10:15 Discussion
- 10:15-10:30** **Coffee break**
- 10:30-12:30** **PERIPHERAL ARTERY DISEASES**
Chairperson: Sasko Kedev, Vasil Velchev
Panellist: Zan Mitrev, Slobodan Antov, Slavco Tosev, Marijan Bosevski
- 10:30-10:45 **Marijan Bosevski (Skopje, Macedonia)** Diagnostic modalities for peripheral artery disease
- 10:45-11:00 **Slobodan Antov (Skopje, Macedonia)** Interventional procedures in peripheral artery disease (Iliac's SFA)
- 11:00-11:15 **Sasko Kedev (Skopje, Macedonia)** Carotid consensus: CAS vs CEA
- 11:15-11:30 **Zan Mitrev (Skopje, Macedonia)** Surgical treatment of carotid disease
- 11:30-11:45 **Ivo Petrov (Sofia, Bulgaria)** Endovascular repair for aortic aneurism and dissection
- 11:45-12:00 **Kostadin Kitchukov (Sofia, Bulgaria)** Renal denervation in the treatment of resistant hypertension
- 12:00-12:15 **Vasil Velchev (Sofia, Bulgaria)** Bulgarian experience with Vessix renal denervation - bipolar technology update
- 12:15-12:30 Discussion

- 12:45-13:45** **Satellite Symposium - "Boehringer Ingelheim"**
Speakers: Sasko Kedev (Skopje, Macedonia) Dabigatran in clinical practice
Lidija Poposka (Skopje, Macedonia) Case report
- 13:45-15:00** **Lunch Session: Case based problem solving session with experts**
Chairperson: Vincent Dangoisse
Panellists: Sunil Rao, Brian Pinto, Sundeep Mishra
- 15:00-16:15** **SESSION on TAVI: Now and Future of Transcatheter Aortic Valve Implantation**
Chairpersons: Telat Keles, Salis Tager
Panellists: Necla Ozer, Matjaz Bunc, Milan Nedeljkovic
- 15:00-15:15 **Necla Ozer (Ankara, Turkey)** Imaging in TAVI
 15:15-15:30 **Matjaz Bunc (Ljubljana, Slovenia)** TAVR up to date and Slovenian experience
 15:30-15:45 **Telat Keles (Ankara, Turkey)** TAVI experience in Turkey
 15:45-16:00 **Milan Nedeljkovic (Belgrade, Serbia)** Initial TAVI experience in Serbia 2014
 16:00-16:15 **Salis Tager (Skopje, Macedonia)** Aortic valve surgery
- 16:15-16:30 Discussion
- 16:45-18:45** **ADVANCE ECHOCARDIOGRAPHY IN DAILY CLINICAL PRACTICE**
Chairperson: Thomas Binder, Elizabeta Srbinovska Kostovska
Panellist: Miroslav Kowalski, Jadranka Separovic Handzevacki, Yoto Yotov
- 16:45-17:00 **Thomas Binder (Vienna, Austria)** Fundamentals of 2D Strain speckle tracking. Can speckle tracking Echocardiography provide additional clinical information?
- 17:00-17:15 **Krasimira Hristova (Sofia, Bulgaria)** Prognostic Value of Myocardial deformation imaging in patient with ischemic cardiomyopathy
- 17:15-17:30 **Jadranka Separovic Handzevacki (Zagreb, Croatia)** How to asses dyssynchrony by strain
- 17:30-17:45 **Aleksandar Neskovic (Belgrade, Serbia)** The challenges of echocardiography in Acute Coronary Syndrome
- 17:45-18:00 **Miroslav Kowalski (Warsaw, Poland)** Strain/strain rate imaging-current applications in heart defects
- 18:00-18:15 **Yoto Yotov (Varna, Bulgaria)** Left atrium: its role in health and disease
- 18:15-18:30 Discussion
- 18:30-19:30** **Satelite Symosium BAYER d.o.o. Ljubljana, Pretstavnistvo Skopje "Xa Factor"**
Speaker: Bode Christoph (Freiburg, Germany)
- 20:00** **Social event: Concert of the Macedonian Philharmonic Orchestra**

Friday 06.06.2014 Hall 2

- 08:30-10:30 Dedicated Transradial Session – part II**
Chairperson: Samir Pancholy
Panellist: Vincent Dangoisse, Brian Pinto, Imre Ungi, Oliver Kalpak
- 08:30-08:45 **Oliver Kalpak (Skopje, Macedonia)** Macedonian registry for acute coronary syndrome
- 08:45-09:00 **Jorgo Kostov (Skopje, Macedonia)** Bioresorbable vascular scaffolds implantation in patients with ACS
- 09:00-09:15 **Hristo Pejkov (Skopje, Macedonia)** Transradial primary percutaneous coronary intervention for the treatment of a patient with cardiogenic shock due to acute total occlusion of unprotected left main coronary artery
- 09:15-09:30 **Igor Spiroski (Skopje, Macedonia)** Retrograde Recanalization of Radial artery occlusion in patients with need for repeated wrist Procedure
- 09:30-09:40 **Marjan Boshev (Skopje, Macedonia)** Navigating through a challenging radial anatomy
- 09:40-09:50 **Ivan Vasilev (Skopje, Macedonia)** Transradial carotid artery stenting
- 09:50-10:00 **Aleksandar Jovkovski (Skopje, Macedonia)** Radial artery anatomical variations
- 10:00-10:15 Discussion
- 10:15-10:30 Coffee break**
- 10:30-11:15 Industry sponsored Symposium – "Pharmas"**
"TRANDOLAPRIL - Modern control of the Hypertension, reduction the risk of Cardiovascular diseases and organ protection"
Speaker: Darco Pocanic (Croatia)
- 11:30-13:00 HOW TO ASSESS OPTIMAL TIME FOR VALVULAR SURGERY - part I**
Chairperson: Salis Tager, Belma Pojskic
Panellist: Elizabeta Srbinovska Kostovska, Rafael Kuperstain, Emilija Antova
- 11:30-11:45 **Emilija Antova (Skopje, Macedonia)** Asymptomatic Aortic Stenosis
- 11:45-12:00 **Rafael Kuperstain (Tel Aviv, Israel)** New insights in low flow, low gradient Aortic Stenosis
- 12:00-12:15 **Snezana Meskova Bongard (Skopje, Macedonia)** Risk stratification in patients with Aortic Regurgitation
- 12:15-12:30 **Tanja Anguseva (Skopje, Macedonia)** Role of 3D transesophageal echocardiography in surgery of the Aortic Diseases
- 12:30-12:45 **Belma Pojskic (Zenica, Bosnia & Herzegovina)** Differences between Guidelines for perioperative risk stratification patients before non cardio surgical operation procedures in Europa and America

- 12:45-13:00 Discussion
- 13:15-14:45 HOW TO ASSES OPTIMAL TIME FOR VALVULAR SURGERY- part II**
Chairperson: Josip Vincelj, Emilija Antova
Panellist: Jadranka Separovic Handzevacki, Tanja Anguseva, Salis Tager
- 13:00-13:15 **Elizabeta Srbinovska Kostovska (Skopje, Macedonia)** Assessment of patients with Mitral Regurgitation
- 13:15-13:30 **Salis Tager (Skopje, Macedonia)** Mitral valve repair/replacement
- 13:30-13:45 **Josip Vincelj (Zagreb, Croatia)** Role of transesophageal echocardiography in assessment of valvular heart diseases
- 13:45-14:00 **Rafael Kuperstain (Tel Aviv, Izrael)** Stress echo in valvular heart diseases
- 14:00-14:15 **Jadranka Separovic Handzevacki (Zagreb, Croatia)** Multiple valve disease
- 14:15-14:30 Discussion
- 15:30-16:30 ECG SEMINAR**
- Petr Peichl (Prague, Czech Republic)** Differential diagnoses of tachycardia with Narrow QRS complex
- Peter Hlivak (Bratislava, Slovakia)** Differential diagnoses of tachycardia with wide QRS complex
- 16:30-18:30 PREVENTION AND REHABILITATION**
Chairpersons: Mario Ivanusa, Slavco Tosev, Samuel Sadikario
Panellist: Magdalena Otljanska, Amra Dzankovic, Nela Kostova
- 16:30-16:45 **Nela Kostova (Skopje, Macedonia)** CV Risk Factors and Preventive Strategies-Novel targets, novel risk factors
- 16:45-17:00 **Magdalena Otljanska (Skopje, Macedonia)** Hypertension, what is new in the Guidelines for Hypertension?
- 17:00-17:15 **Nikolai Runev (Sofia, Bulgaria)** Statins in primary prevention
- 17:15-15:30 **Amra Dzankovic (Sarajevo, Bosnia&Herzegovina)** Microvascular Coronary Disease and therapeutic options
- 17:30-17:45 **Mario Ivanusa (Zagreb, Croatia)** Outpatient rehabilitation of the cardiac patients
- 17:45-18:00 **Marijan Bosevski (Skopje, Macedonia)** Carotid ultrasound measurements in coronary artery patients
- 18:00-18:15 **Slavco Tosev (Skopje, Macedonia)** Diabetic foot , enigma and challenge
- 18:15-18:30 **Valentina Andova (Skopje, Macedonia)** Sexual activity and Heart Diseases
- 18:30-18:45 Discussion
- 20:00 Social event: Concert of the Macedonian Philharmonic Orchestra**

Saturday 07.06.2014 Main Hall

- 09:00-10:00** **Satellite Symposium Sponsored by "General Electric Ultrasound"**
 "Current and future role of imaging in clinical practice"
Bogdan Popescou (Bucharest, Romania)
- 10:00-11:00** **Satellite Symposium - "Alvogen" Skopje**
 "Trimetacor-Heart's friend"
Moderator: Sasko Kedev (Skopje, Macedonia)
Speakers: Dimce Zafirov (Skopje, Macedonia) - Pharmacological profile of Trimetacor
Slavco Tosev (Skopje, Macedonia) - Ischemic heart disease and Trimetacor, clinical experience
- 11:00-13:00** **UPDATES IN CARDIOVASCULAR PATOLOGY**
Chairperson: Evgeny Shlyakhto
Panellists: Rafaele Bugiardini, Aneta Dimova, Arsen Ristic
- 11:00-11:20 **Evgeny Shlyakhto (Saint Petersburg, Russia)** Autonomic Modulation in Heart Failure Patients
- 11:20-11:40 **Rafaele Bugiardini (Bologna, Italy)** Update on the ISACS-TC Registry
- 11:40-12:00 **Edina Cenko (Bologna, Italy)** Technical issues and statistics in the ISACS-TC Registry
- 12:00-12:20 **Aneta Dimova (Albany, NY, USA)** Are women truly different than men when it comes to diagnosis, treatment and outcome of acute coronary event? An unsolved dilemma
- 12:20-12:40 **Aneta Dimova (Albany, NY, USA)** New lipid therapy choices are almost here
- 12:40-13:00 **Arsen Ristic (Belgrade, Serbia)** State of the art in diagnosis and management of myocarditis
- 13:00-13:30 Discussion
- 13:30** **CLOSING REMARKS at the end of the Congress**

Saturday 07.06.2014 Hall 2

09:00- 11:00 Oral Abstract presentations

Chairpersons: Ljubica Georgievska, Fatmir Ferati

Panellist: Zarko Hristovski, Nikola Gjorgov, Oliver Kalpak

- 09:00 -09:10 **Ljubica Georgievska Ismail (Skopje, Macedonia)** Assessment of global longitudinal strain with spackle tracking in patients with heart failure with preserved left ventricular ejection fraction
- 09:10 -09:20 **Zarko Hristovski (Skopje, Macedonia)** Echocardiographic predictors of chronotropic incompetence to exercise in patients with heart failure with preserved ejection fraction
- 09:20 -09:30 **Fatmir Ferati (Skopje, Macedonia)** Analysis of LA function in patients with cardiomyopathy, with or without atrial fibrillation
- 09:30 -09:40 **Nikola Gjorgov (Skopje, Macedonia)** Economic Burden of Atrial fibrillation
- 09:40 -09:50 **Dejan Kovacevic (Skopje, Macedonia)** Management of Atrial Fibrillation
- 09:50 -10:00 **Emilija Lazarova Trajkovska, Lidija Poposka (Skopje, Macedonia)** Anticoagulation in patients with atrial fibrillation and its correlation to current Guidelines-the first Macedonian Registry for atrial fibrillation treatment
- 10:00 -10:10 **I.Martinov (Bulgaria)** Clinical case. Interventional treatment of pulmonary embolism after unsuccessful systemic fibrinolysis
- 10:10 -10:20 **Nikola Bakracheski (Ohrid, Macedonia)** One-year clinical outcome of percutaneous treatment with drug-eluting balloons; results from our Center's Registry
- 10:20 -10:30 **Enver Idoovski (Skopje, Macedonia)** Treatment of postinfarct VSD
- 10:30 -10:40 **Oliver Kalpak (Skopje, Macedonia)** Transradial vs Transfemoral Primary Percutaneous Coronary Intervention for ST Elevation Myocardial Infarction: Two years Follow up
- 10:40-10:50 **Nikola Bakracheski (Ohrid, Macedonia)** Acute arm ischemia: Subclavian artery - Case report
- 10:50 -11:10 Discussion
- 11:10-13:00 Cardiovascular nursing**
- Chairperson: Katerina D.Mircevska, Mirjana Jovanovska, Saska Stojmenova, Suzana Petkovska, Gordana Golubovska, Dafina Ristovska**
- 11:10-11:20 **Dafina Ristovska, Jagoda Miljkovic, Aneta Zarevska, Hasime Saliu (Skopje, Macedonia)** Endovascular intervention procedure, The role of nurse in the treatment of Cardiovascular diseases with Interventional procedure
- 11:20-11:30 **Ance Velkovska, Tanja Zdravkovska, Monika Spasenovska, Spasija Donceva (Skopje, Macedonia)** PCI with Tthromboaspiration in treatment of Acute Myocardial Infarction

- 11:30-11:40 **Maja Manojlovska**, Rozeta Rickova, Radica Smrekova, Dejan Jankov (**Skopje, Macedonia**) Imaging techniques, IVUS, FFR, OCT
- 11:40-11:50 **Anesa Bihorac**, Mujesira Tutic, Aleksandra Antovska, Borce Krmzov (**Skopje, Macedonia**) Treatment of Resistent Hypertension with Renal Denervation
- 11:50-12:00 **Violeta Gijevska**, Aneta Kajcevska (**Skopje, Macedonia**) Protection from Radiation in Angioalab
- 11:20-12:10 **Maja Atanasovska**, Tanja Cenevska, Lence Spasovska, Marina Kostaska, Natalija Pavlovska (**Skopje, Macedonia**) Treatment of patients with acute and chronic heart failure
- 12:10-12:20 **Zaneta Bogevska-Miteva**, G.Boseska, T.Anguseva, Z.Mitrev (**Skopje, Macedonia**) Factors associated with prolonged mechanical ventilation in cardiosurgical patients
- 12:20-12:30 **Nada Andonova**, Slobodanka Jovanova (**Stip, Macedonia**) Experience and Education gained in the University Clinic of Cardiology-Skopje
- 12:30-12:40 G.Bosevska, K.Micevska, B.Popovska, E.Idovski, T.Anguseva, Z.Mitrev (**Skopje, Macedonia**) Preoperative treatment of patient for cardiovascular surgery
- 12:40-12:50 **Divna Lazarova**, Z.Bogoevska-Miteva, T.Anguseva, Z.Mitrev (**Skopje, Macedonia**) Preoperative Intra-aortic Ballon Pump in Patients undergoing Coronary Bypass Surgery
- 12:50-13:00 **Zaneta Bogoevska-Miteva**, T.Anguseva, Z.Mitrev (**Skopje, Macedonia**) Monitoring of intra-hospital infections through the experiences of SHSD "Filip II"
- 13:00-13:10 **G. Boseska**, Z.Bogoeska-Miteva, T. Anguseva, Z.Mitrev (**Skopje, Macedonia**) Can we predict the occurrence of decubitus ulcer
- 13:10-13:20 **Snezana Blazevska**, T.Anguseva, Z.Mitrev (**Skopje, Macedonia**) The role of instrumental technician in cardiosurgery off pump (OPCAB)
- 13:20-13:30 Discussion
- 13:30 CLOSING REMARKS at the end of the Congress**

Thursday 05.06.2014 POSTER PRESENTATIONS

POSTER SESSION - Hall 3

09:00 - 12:00 INTERVENTIONAL CARDIOLOGY

1. Abstract No. **58p**

IVUS guided stenting of the ostial left main coronary artery after late graft failure (case report)

Bakracheski N1, Mitreski S1, Tupare S1, Manchevski D1, Kovacheska-Bashuroska E1, Sheshoski B1, Stefanovski B1

Institute for prevention, treatment and rehabilitation of cardiovascular disease - Ohrid, 1 Macedonia

2. Abstract No. **63p**

Implantation of permanent dual chamber ICD as prevention of sudden cardiac death

Kovacevic D1, Trajkov I1, Dushkoski D1;

K.H. "Acibadem-Sistina", Skopje, Macedonia

3. Abstract No. **67p**

Stabilization of Left Ventricular Lead by means of Coronary Vein Stenting

Gjorgov N. 1, Busljetic O.1, Trajkov I.1, Kovacevic D. 1

KH "Acibadem Sistina" 1 Skopje, Macedonia

4. Abstract No. **73p**

Reverse left ventricular remodeling after surgical correction of Ischemic Mitral Regurgitation

Idoski Enver, Angusheva Tanja, Klincev Milka, Mitrev Zan

Special hospital for surgery "Filip Vtori", Skopje, Macedonia

5. Abstract No. **76p**

Results following reduction ascending aortoplasty

Enver Idoski, Nikola Hristov, Tanja Angusheva, Milka Klinceva, Zan Mitrev

Special hospital for surgery "Filip Vtori", Skopje, Macedonia

6. Abstract No. **77p**

Radiofrequency Catheter Ablation in young patient with WPW Syndrome

Fortomarska Milevska B1, Angelkov L2, Mitreski S1, Kovacheska Bashuroska E1, Sheshoski B1, Aftovska Naumoska I1, Tupare S1, Taneska N1,

Institute for prevention, treatment and rehabilitation of cardiovascular disease, Ohrid, Macedonia1; Institute for cardiovascular diseases Dedinje, Belgrade2, Serbia

7. Abstract No. **79p**

Rate and incidence of pacemaker dependent patients after pacemaker implantation

Boskov V1, Taleski J1, Janusevski F1

University Clinic of Cardiology, Medical Faculty, Skopje, Macedonia

8. Abstract No. **91p**

Six-month follow up of the Echocardiographic parameters in patients with Acute LAD occlusion

Srbinovska-Kostovska E.1, Pejkov H.1, Antov S.1, Kalpak O.1, Andova V.1, Hristova E.1, Kedev S.1

University Clinic of Cardiology, Medical Faculty, Skopje, Macedonia

9. Abstract No. **109p**

Gender-specific Outcomes in Polymer-Free Drug-Eluting Stent (YUKON) Compared with Polymer Based Drug-Eluting Stents in Real-World Coronary Artery Lesions

Trajceski T, Petrovski B, Petrovski Z, Brovina L, Zuna B, Abdushi S, Simonovski K
Spitali Zemres Intermed EDA, Albania

10. Abstract No. **110p**

Severe contrast induced Nephropathy in patients undergoing primary Angioplasty for Acute Myocardial Infarction

Simonovski K, Petrovski B, Petrovski Z, Brovina L, Zuna B, Abdushi S, Trajceski T
Spitali Zemres Intermed EDA, Albania

11. Abstract No. **116p**

Implantation of a single lead VDD pacing system through a persistent left superior vena cava

Taleski J1, Janusevski F1

University Clinic of Cardiology Skopje1 Macedonia

12. Abstract No. **118p**

Bailout procedure in acute massive right coronary artery dissection (case report)

Bakracheski N1, Mitreski S1, Manchevski D1, Kovacheska Bashuroska E1, Sheshoski B1, Stefanovski B1,

Institute for cardiovascular diseases, Ohrid1 Macedonia

13. Abstract No. **122p**

Apert syndrome and ASD II in a Pediatric Patient – A Case Report

Stankovikj V1, Al Soufi M2, Jovanovska V1, Kacarska R1, Kuzevska-Maneva K1, Gjurkova B1, Nonkulovski D1, Neshkovska-Shumenkovska M1, Paskalov G1, Shukarova-Angelovska E1

University Children's Hospital, Skopje, Macedonia1, Al Zahra Medical Centre, Dubai2

14. Abstract No. **127p**

A case of a 26-year old woman with ventricular septal defect and multiple peripheral stenosis of the pulmonary vasculature

Milev I, Zafirovska P, Shpend I, Zimbakov Z, Ampova V, Bozinovska B, Atanasov Z, Veljanovska L, Angjuseva T, Mitrev Z.

Special Hospital for Surgical Diseases "Filip Vtori", Skopje, Macedonia

15. Abstract No. **128p**

Transcatheter repair of paravalvular leaks in high risk patients: a single center experience

Milev I1, Shpend I1, Ampova V1, Zimbakov Z1, Zafirovska P1, Angjuseva T1, Mitrev Z1, *Jaroslav J.2

Special Hospital for Surgical Diseases "Filip Vtori", Skopje, Macedonia1, Cardiovascular Center Brno, Agel Hospital group, Czech Republic2

16. Abstract No. **129p**

Case of giant coronary fistula in a 6-year old girl: transcatheter closure with ante grade approach

Zimbakov Z1, Milev I1, Idrizi S1, Ampova-Sokolov V1, Zafirovska P1, Angjuseva T1, Mitrev Z1, Januska S2

Special hospital for surgical diseases "Filip Vtori", Skopje, Macedonia1, Cardiovascular center Brno, Agel Hospital Group, Czech Republic 2

17. Abstract No. **130p**

Pediatric interventional cardiology, diagnostics and therapeutics: Our experience

Jovanovska V.¹, Sofijanovska A.¹, Kacarska R.¹, Kuzevska Maneva K.¹, Gjurkova B.¹, Neshkovska-Shumenkovska M.¹, Spirovski I.², Nonkulovski D.¹, Stankovikj V.¹, Paskov G.¹

¹University Children's Hospital - Skopje ²University Clinic of Cardiology – Skopje, Macedonia

18. Abstract No. **131p**

Percutaneous balloon valvuloplasty of pulmonary valve stenosis in adolescents and adults

Idrizi S, Milev I, Ampova-Sokolov V, Zimbakov Z, Zafirovska P, Angjuseva T, Mitrev Z

Special Hospital For Surgical Diseases "Filip Vtori", Skopje, Macedonia

19. Abstract No. **132p**

Stenting of aortic coarctation- method of choice in selective patients, a single center experience

Shpend I, Milev I, Atanasov Z, Zimbakov Z, Ampova V, Zafirovska P, Angjuseva T, Mitrev Z.

Special Hospital for Surgical Diseases "Filip Vtori", Skopje, Macedonia

20. Abstract No. **133p**

High grade bilateral carotid artery stenosis in 62-year old patient

Ampova-Sokolov V, Milev I, Idrizi S, Zimbakov Z, Atanasov Z, Veljanovska L, Bozinovska B, Angjuseva T, Mitrev Z

Special hospital for surgical diseases "Filip Vtori", Skopje, Macedonia

21. Abstract No. **136p**

Transradial or transfemoral approach for PCI in patients with Acute Myocardial Infarction with ST elevation

Kamceva G.1, Vavlukis M.2, Kedev S.2

Medical Faculty, University "Goce Delcev", Stip, Macedonia 1, University Clinic of Cardiology, Medical Faculty, Skopje, Macedonia 2

22. Abstract No. **141p**

A Case report of Cardotid Artery Stenting after Recanalization of total occlusion

Lazarova Trajkovska E.1, Kedev S.1

University Clinic of Cardiology, Skopje, Macedonia 1

23. Abstract No. **152p**

Cardiovascular manifestation in Myeloproliferative. Coronary artery Disease as a first manifestation of Policitemia rubra vera (Case report)

Nikolov G., Vrcakovska M., Trajkovski G,

PZU "Center of internal diseases- Srce", Skopje, Macedonia

24. Abstract No. **156p**

Tumor Necrosis Factor Alpha (TNF-A) –Predictor of left ventricular Disfunction

Pejkov H.1, Kedev S.1, Srbinozvska-Kostovska E.1, Panov S.2, Antov S.1, Kostov J.1, Kalpak O.1, Spiroski I.1, Lang I.3

1. University Clinic of Cardiology, Medical Faculty – Skopje, University Ss. Cyril and Methodius, Macedonia, 2. Laboratory of Molecular Biology and Genetics, Faculty of Natural Sciences – Skopje, University Ss. Cyril and Methodius, Macedonia, 3. Cardiology Clinic, AKH – Vienna, Medical University Vienna, Austria

25. Abstract No. **160p**

Temporary transvenous pacing and thrombolytic therapy in the setting of bradyarrhythmias complicating acute myocardial infarction

Janushevski F.

University Clinic of Cardiology- Skopje, Macedonia

26. Abstract No. **171p**

The Automatic Implantable Cardioverter-Defibrillator in Drug-Refractory Ventricular Tachyarrhythmia

Taneski F1, Cipusheva K1, Janushevski F1, Bojovski I1, Kotlar I1, Kitanoski D1, Manev B1
Clinic of cardiology Skopje, Macedonia 1

27. Abstract No. **187p**

Cardiovascular complication associated with HIP Fractures in the elderly

Dacevska Dimitrovska M., 1 Dimitrovski D., 2

JZU Gerontological institute "13 November", Skopje, 1 UK St. Naum Ohridski, Macedonia

Thursday 05.06.2014 POSTER PRESENTATIONS - Hall 3

15:00 - 18:00 ACUTE CORONARY SYNDROME

1. Abstract No. **21p**

The influence of blood pressure on recurrent stroke and myocardial infarction

Dragana Petrovska Cvetkovska, Natalija Dolnec Baneva, Dijana Nikodijevik
University Clinic of Neurology, Faculty of Medicine, Ss Cyril and Methodius University,
Skopje, Macedonia

2. Abstract No. **26p**

Treatment of electrical storm(VT)in patients with ICD – case report

Servini Z., Lozance N.
Clinical Hospital „Dr. T. Panovski”, Bitola, Macedonia

3. Abstract No. **33p**

In which part of the day occurs myocardial infarction most often?

Gjorgjievska Biljana 1

University Clinic of Cardiology1, Skopje, Macedonia

4. Abstract No. **41p**

INTIMATE DIFFERENCES IN ISCHEMIA MECHANISM IN CORONARY ARTERY DISEASE AND CARDIAC SYNDROME X

Tsonev S1, Donova T1, Popova D2, Vladimirova R2, Nyagolov M4, Milanova M4, Matveev M4
Medical University, Sofia1, National Military Hospital,Sofia2, UMHIC “N. I. Pirogov”,Sofia3, Bulgarian Academy of Sciences, Sofia4,Bulgaria

5. Abstract No. **44p**

Acute dissection of the thoracic aorta – recognition in the internal office

Nikolovski S1, Nikolovska J2
Health Center, Kriva Palanka1 Macedonia

6. Abstract No. **49p**

Cardiorenal Syndrome in patients with acute Myocardial Infarction

Balenović D.1, Mataga I.1, Horvat I.1, Prkačin I.2, Šmit I.1, Bedeniković V.1, Živanović
Posilović G.1
General hospital „Dr. Ivo Pedišić“, Sisak,Croatia-1;Internal Clinic, University Hospital
Merkur, Zagreb, Croatia 2

7. Abstract No. 54p

Review on the effects of cardiovascular diseases on the driving ability with professional drivers

Pazeska M., Naumoska R., Samardzioska M.
Zdravstven Dom Prilep, Skopje, Macedonia

8. Abstract No. **71p**

Gender differences in predictive ability of UKPDS model for risk assessment of coronary artery disease in type 2 diabetes patients

Smokovski I1, Milenkovic T2, Cibisev A1, Davceva-Pavlovska J3, Sadikario S3
University Clinic of Toxicology Skopje1 University Clinic of Endocrinology, Diabetes and Metabolic Disorders Skopje2 University Clinic of Cardiology Skopje3 Macedonia

9. Abstract No. **80p**

Angina Pectoris and Coronary Artery Diseases in patients with Aortic Stenosis

Taseski O1 ; Veselinov-Taseska M2
PZU "Med-Interna"1 ; PZU "D-r Taseski"2 Prilep- Macedonia

10. Abstract No. **81p**

TRIMETAZIDINE and Heart Failure

Taseski O1 ; Veselinov-Taseska M2
PZU "Med-Interna"1 ; PZU "D-r Taseski"2 Prilep-Macedonia

11. Abstract No. **82p**

Cardiovascular Complications in Metabolic Syndrome

Veselinov-Taseska M1 ; Taseski O2
PZU "D-r Taseski"1 ; PZU "Med-Interna"2 Prilep-Macedonia

12. Abstract No. **83p**

Efficiency of Amlessa(Amlodipin 10mg + Perindopril 8mg) in patients with arterial Hypertension

Veselinov-Taseska M1 ; Taseski O2
PZU "D-r Taseski" 1 ; PZU "Med-Interna"2 Prilep-Macedonia

13. Abstract No. **97p**

Combination of genetic mutations could lead to myocardial infarction in a very young male adult - CASE REPORT

Klincheva M, Ambarkova Vilarova E, Anguseva T, Milev I, Idoski E, Mitrev Z
Special hospital for surgery diseases "Filip II", Skopje, Macedonia

14. Abstract No. **107p**

Genetic mutation – a reason for Acute Myocardial Infarction in young adult – case report

Bajraktarova Prosheva T 1, Jordanova ;S 1, Lozanche N.2
Department of Internal Medicine, Clinical Hospital Shtip 1; Clinical Hospital Bitola 2

15. Abstract No. **137p**

Rhythm disturbances in patients treated in Cardiac Intensive Care Unit

E. Shehu1, M. Vavlukis1, V. B. Pocesta1, E. Caparoska1, H. Taravari1, D. Kitanoski, I. Bojovski, I. Kotlar, I. Jovanovska, S. Kedev1.
University Clinic for Cardiology, Skopje, Macedonia

16. Abstract No. **143p**

Anti-anginal and anti-ischemic effect of Trimetazidine in patients with stable angina pectoris

Taneva B1, Miletic B1, Tosev S1, Kostova N1, Buseva M1, Lazarova E1
Clinic of Cardiology1, Skopje, Macedonia

17. Abstract No. **149p**

Anemia, renal impairment and in-hospital mortality, in acute worsening chronic heart failure patients

Bojovski I1, Vavlukis M1, Caparovska E1, Pocesta B1, Shehu E1, Taravari H1, Kitanoski D1, Kotlar I1, Janushevski F1, Taneski F1, Jovanovska I1, Kedev S1
University Clinic of Cardiology, Skopje, Macedonia

18. Abstract No. **150p**

Glucoregulation in diabetic and no diabetic patients and the impact on early clinical outcome in patients with acute coronary syndrome

Kitanoski D1, Vavlukis M1, Caparovska E1, Pocesta B1, Shehu E1, Taravari H1, Bojovski I1, Kotlar I1, Jovanovska I1, Kedev S1
University Clinic of Cardiology, Medical Faculty, Skopje, Macedonia

19. Abstract No. **151p**

Early rehospitalizations in patients treated for acute coronary syndrome – can we identify predictors?

Kotlar I, Vavlukis M, Caparovska E, Pocesta B, Shehu E, Taravari H, Kitanoski D, Bojovski I, Taneski F, Janushevski F, Jovanovska I, Kedev S
University Clinic of Cardiology, Skopje, Macedonia

09:00 - 13:00 ECHOCARDIOGRAPHY AND OTHER IMAGING TECHNIQUES1. Abstract No. **17p****Myxoma of the heart**

Tashkova Kirkovska T, Duganovska S, Petrushevska G, Mitrev Z
Institute for Pathology, Medical Faculty, Ss Cyril and Methodius University, Skopje,
Macedonia

2. Abstract No. **27p****Challenges in management the patients with chronic Coronary artery Diseases (Case report)**

Servini Z., Lozance N., Parmakovska S.
Clinical Hospital, Dr. T. Panovski, Bitola, Macedonia

3. Abstract No. **29p****WPW syndrome (pre-excitation syndrome) with polymorphic atypical pains, display the present case (our experiences)**

Mitevski D
Health facility "Multimedika DM"-specialized practice in Internal Medicine and
Cardiology, Kumanovo, Macedonia

4. Abstract No. **34p****Right atrial thrombus in oncology patient - case report**

Hadjiev Vasko 1, Hadjieva Deangelis Natasha 1, Hadjiev Vlado 1, Hadjieva Ratka 1
PHO Diagnostic center "D-r. Hadjiev", Bitola 1 Macedonia

5. Abstract No. **36p****Echocardiographic evaluation of ascending aortic dilatation – our experience**

Topliklieva L. 1
Clinical Hospital Stip, Stip, Macedonia

6. Abstract No. **37p****Early detection of subclinical left ventricular dysfunction and myocardial ischemia in asymptomatic patients with diabetes type II, prognostic value of TDI, myocardial deformation and myocardial perfusion scintigraphy**

Peovska I1, Srbinovska Kostovska E1, Davceva Pavlovska J1, Antova E1, Andova V1,
Otljanska M1, Arnaudova F1, Bosevski M1
Univerzitetska Klinika za Kardiologija, Skopje1, Macedonia

7. Abstract No. **38p**

Optimal therapeutical approach in myocardial ischemia in asymptomatic patients with high cardiovascular risk: role of clinical, laboratory and scintigraphic parameters

Peovska I1, Davceva Pavlovska J1, Vavlukis M1, Kostova N1, Zdravkovska M2, Majstorov V2, Pop Gorceva D2, Zdraveska M2

Univerzitetska Klinika za kardiologija1, Skopje, Institut za Patofiziologija i Nuklearna Medicina2, Skopje, Macedonia

8. Abstract No. **39p**

Clinical value of coronary calcium score and myocardial perfusion scintigraphy in detection of coronary artery diseases in asymptomatic patients with moderate and high cardiovascular risk

Peovska I1, Davceva Pavlovska J1, Lazarevska M2, Stojkovski A2, Zdravkovska M3, Zdraveska M3

Univerzitetska Klinika za Kardiologija1, SKopje, Klinika za Radiologija2, Skopje, Institut za Patofiziologija i Nuklearna Medicina3, Skopje, Macedonia

9. Abstract No. **42p**

Atrial fibrillation, a condition after electrical cardioversion, complications, course of illness (case report)

Mitevski D

Health facility "Multimedika DM", specialized practice in Intrena Medicine and Cardiology, Kumanovo, Macedonia

10. Abstract No. **48p**

Transcranial vascular Color Doppler Angiodynography of the main brain arteries, Diagnosis of Aneurism – Case report

Madžarov S., Novakoska - Dujkovik S., Mangu V., Jankuloska M.

pho POLYCLINIC "CARDIOLAB MADŽAROV", Ohrid, Macedonia

11. Abstract No. **50p**

Cardiorenal effects of Anemia Treatment in predialysis Chronic Renal Diseases

Balenović D.1, Horvat I.1, Prkačin I.2, Počanić D.2, Cavrić G.2

General Hospital „Dr. Ivo Pedišić“, Sisak, Croatia - 1; Internal Clinic, University Hospital Merkur, Zagreb, Croatia - 2

12. Abstract No. **84p**

Acute treatment of deep venous thrombosis with pulmonary embolism and one year follow up

Kovacevic D1, Projevska D1, Dushkoski D1

K.H. Acibadem - Sistina, Skopje, Macedonia

13. Abstract No. **85p**

Exercise test, Nt proBNP and echocardiographic parameters in asymptomatic pts. with severe valvular aortic stenosis

Antova E1, Georgievska-Ismail Lj1, Srbinovska E1, Peovska I1, Otljanska M1, Andova V1, Zanteva-Naumoska M1

University Clinic of cardiology, Skopje, Macedonia

14. Abstract No. **86p**

Nt proBNP and echocardiographic parameters in severe valvular aortic stenosis

Antova E1, Georgievska-Ismail Lj1, Srbinovska E1, Peovska I1, Kostova N1, Davceva-Pavlovska J1, Zanteva-Naumoska M1

University Clinic of Cardiology-1, Skopje, Macedonia

15. Abstract No. **89p**

Detection of rapid progression of coronary artery disease (CAD) in women -Case report

Kostova N.1,Otljanska M.,1 Vavlukis M.1,Pop Gjorceva D.2,Majstorov V.2,Zdravkovska M2,Stojanovski S.2,Kostov I.3

University Clinic of Cardiology -Skopje 1, Institut of pathophysiology and Nuclear medicine-Skopje 2,University Surgery clinic "St Naum Ohridski" , Skopje, Macedonia

16. Abstract No. **92p**

Atypical symptoms in Type A aortic dissection-Case report

Kostova N.1,Otljanska M.,1 Vavlukis M.1,Paljoskoska Jordanova S.1.,Kostov I.2

University Clinic of Cardiology , Skopje 1 , ,University Surgery clinic "St Naum Ohridski"-Skopje 2 , Macedonia

17. Abstract No. **94p**

Secondary tumor in right atrium - Case report

Otljanska M.,1,Kostova N.1,Pejovska I.1, Josifovic Licoska F.,3

University Clinic of Cardiology Skopje 1, University Clinic of Gastroenterohepatology Skopje2, Macedonia

18. Abstract No. **95p**

Total cavo-pulmonary anastomosis in patient with sunge left ventricul, malposition of great arteries and stenosis of pulmonary artery (Case report)

Gjurkova Angelovska B1, Kacarska R1, Maneva Kuzevska K1, Jovanovska V1, Neskovska Sumenkovska M1

Univerzitetska Klinika za detski bolesti, Skopje, Makedonija

19. Abstract No. **96p**

Common Truncus Arteriosus – Case report

Kacarska R., Maneva-Kuzevska K., Gurkova Angelovska B., Sumenkova Neskovska M., Sofijanovska A., Jovanovska B., Paskalov G., Nonkulovski D1 , Cadikovski V. 2

University Clinic of Children Diseases1, University Clinic of Pediatric Surgery2, Skopje, Macedonia

20. Abstract No. **99p**

"Non compaction" cardiomyopathy (case reports) in a correlation with other cardiomyopathies

B. Stefanovska, M. Bogeska Blazhevska

PHO "Kardiomedika Srbinovski", Skopje, Macedonia

21. Abstract No. **102p**

Syncope as the first manifestation of the Wolf-Parkinson-White (WPW) syndrome

M . Bogeska Blazhevska, B . Stefanovska

PHO "Kardiomedika Srbinovski", Skopje, Macedonia

22. Abstract No. **103p**

Correlation of coronary artery occlusion and right ventricular infarction

Andova V./ Srbinovska-Kostovska E.,Georgievska-Ismail Lj.,Kedev S.,Caparoska E., Zafirovska P., Miletic M.

University Clinic of Cardiology, Skopje, Macedonia

23. Abstract No. **105p**

Left atrial thrombus in mitral stenosis with atrial fibrillation

Tupare S1, Fortomarska Mileska B1, Sekuloski R1, Kotlar M1, Kovacheska Bashurovska E1, Sheshoski B1,

Institute for cardiovascular diseases, Ohrid1

24. Abstract No. **106p**

Giant ascending aorta aneurysm

Tupare S1, Fortomarska Mileska B1, Donevsk Z1, Tegovska B1, Zimbova M1

Institute for cardiovascular diseases, Ohrid, Macedonia

25. Abstract No. **111p**

Incidence of acquired aortic stenosis in a group of Echocardiography examined patients in clinical hospital – Stip in the period 01.01.2013 – 31.12.2013

Dr. Jordanova S.1, Dr. Breslieva J.1, Dr. Bajraktarova Proseva T.1, Dr. Josifovska Toflovska S.1

Clinical Hospital , Stip, Macedonia

26. Abstract No. **114p**

Noncompacted miocardium

Paskalov Gj, Kacarska R , Kuzevska-Maneva K , Gjurmova-Angelovska B , Jovanovska V, Neshkovska-Shumenkovska M , Nonkulovski D , Stankovic V.

University children's hospital, Skopje, Macedonia

27. Abstract No. **115p**

Role of echocardiography in the diagnosis of hypoplastic left heart syndrome- case report

Nonkulovski D., Kacarska, Kuzevska-Maneva D., Jovanovska V., Gjurkova B., G.Paskalov G. Stankovikj V., Neshkovska-Shumenkovska M. Sofijanova A. Cardiology Department, University Children's Hospital, Skopje, Macedonia Department of Neonatal and Pediatric Intensive Care Unit, University Children's Hospital, Skopje, Macedonia University Children's Hospital, Skopje, Macedonia

28. Abstract No. **117p**

Left atrial appendage thrombus in a patient in sinus rhythm

Andova V., Srbinovska-Kostovska E, Georgievska-Ismail Lj. University Clinic of cardiology, Medical Faculty, University "St.Cyril&Methodius", Skopje, Macedonia

29. Abstract No. **124p**

Left ventricular strain analysis after percutaneous repair of aortic coarctation

Zafirovska P, Milev I, Shpend I, Zimbakov Z, Ampova V, Georgieva B, Zafirovska J, Angjuseva T, Mitrev Z. Special Hospital for Surgical Diseases "Filip Vtori", Skopje, Macedonia

15:00 - 18:00 DIFFERENT CARDIOVASCULAR TOPICS

1. Abstract No. **138p**

Pulmonary thromboembolism followed by acute myocardial infarction in patient with systemic lupus eritematodus-Antiphospholipid syndrome yes or no! (a case report)

Pocesta B1, Kotlar I1, Vavlukis M1, Pejkov H1, Bosev M1, Caparovska E1, Shehu E1, Taravari H1, Kitanovski D1, Bojkovski I1, Jovanovska I1, Kedev S
University Clinic of Cardiology1, Skopje, Macedonia

2. Abstract No. **140p**

Influence of subclinical Hypothyroidism on the left ventricular systolic and diastolic function

Velkoska Nakova V1, Krstevska B2, Srbinovska Kostovska E3, Jovanova S3, Vaskova O4, Jovanovska Mishevaska S2.

Faculty of medical science, University Goce Delchev, Shtip, R.Macedonia 1
Endocrinology, Diabetes and Metabolic Disorders Clinic, Medical Faculty, University Cyril and Methodius, Skopje, R. Macedonia 2
University Clinic of Cardiology, Medical Faculty, University Cyril and Methodius, Skopje, R. Macedonia 3
Institute of Patophysiology and Nuclear Medicine, Medical Faculty, University Cyril and Methodius4, Skopje, Macedonia

3. Abstract No. **144p**

Arterial Thrombosis of a Patient With Stomach Cancer

Chaparoska-Velichkovska E1, Vavlukis M1, Pocesta B1, Taravari H1, Sehu E1, Andova V1, Kotlar I1, Jovanovska I1, Bojovski I1, Kitanovski D1, Janusevski F1
University Clinic of Cardiology1, Skopje, Macedonia

4. Abstract No. **162p**

Implantation of pacemaker in treatment of Tachycardia-Bradycardia Syndrome

Ivanov M.
University Clinic of Cardiology, Skopje, Macedonia

5. Abstract No. **163p**

Radiofrequency catheter ablation as treatment for atrial flutter at patient with dilatated cardiomyopathy

Gulevska A. Taleski J. Kaeva S
University Clinic of Cardiology, Skopje, Macedonia

6 Abstract No. **169p**

Doctor of Internal medicine

Paljoskovska Jordanova S.1, Caeva S.1. ,Kostova N.1
University Clinic of Cardiology, Skopje, Macedonia

7 Abstract No. **170p**

Team management and the role of patient education in patients with heart failure: Survey based research.

Maneva Samardziska C1, Manev B1.

PZU Prim D-r Samardziski Shtip - Private Health Care institution for General and Internal Medicine, Skopje, Macedonia

8 Abstract No. **172p**

Diagnosis and Treatment of Pulmonary embolism

Cipusheva K1, Taneski F1, Manev B1

University Clinic of Cardiology, Skopje, Macedonia

9. Abstract No. **175p**

Arrhythmias induced cardiomyopathy-reversible dilated cardiomyopathy in patients with atrial fibrillation/flutter with fast ventricular rate

Jovanova S1, Arnaudova-Dezhulovikj F1, Boshev M1, Kamcevska-Dobrkovic L1, Otljanska M1, Kostova N1, Miceva I1

University clinic of cardiology, Medical faculty, Skopje, Macedonia

10. Abstract No. **178p**

Can age be crucial for CRT (cardiac resynchronization therapy) at severe dilated cardiomyopathy with narrow QRS? Case report.

Spasevski Gj1, Kikirkovska E1

University Clinic of Cardiology, Skopje, Macedonia

11. Abstract No. **179p**

Is the "Slow Pathway" potential best approach for AVNRT ablation? Case report.

Kikirkovska E1, Spasevski Gj1

University Clinic of Cardiology, Skopje, Macedonia

12. Abstract No. **22p**

Stroke and atrial fibrillation

Petrovska Cvetkovska D, Dolnenec Baneva N, Nikodijevik D

University Clinic of Neurology, Faculty of Medicine, St Cyril and Methodius University, Skopje, Macedonia

13. Abstract No. **31p**

Upper Extremity Venous Duplex

Gjorgjievska Biljana 1

University Clinic of Cardiology, Skopje, Macedonia

14. Abstract No. **32p**

Subclavian steal

Gjorgjievska Biljana 1

University Clinic of Cardiology, Skopje, Macedonia

15. Abstract No. **62p**

Angioplasty and stenting as first line treatment of peripheral arterial CTO (case report)

Manchevski D1, Bakracheski N1, Zimbova M1, Mitreski S1, Kovacheska Bashuroska E1, Sheshoski B1, Stefanovski B1;

Institute for Cardiovascular Diseases – Ohrid1 , Macedonia

16. Abstract No. **69p**

Hypertension and Metabolic Syndrome in Macedonian Population

Gjorgov N.- 1, Avramovski A. - 1, Ilievski M. - 1, Gjorgova S. - 1, Gjeorgjievski M. - 1, Polyclinic Akus Medikus, Skopje, Macedonia

17. Abstract No. **75p**

Carotid artery disease in patients with coronary artery disease undergoing coronary artery bypass grafting

Fortomarska Milevska B1, Tupare S1, Zimbova M1, Tegoska B1, Doneska G1, Aftovska Naumoska I1, Kovacheska Bashuroska E1, Zhaku R1,

Institute for prevention, treatment and rehabilitation of cardiovascular diseases, Ohrid1, Macedonia

18. Abstract No. **101p**

Radiofrequency ablation as first line treatment of varicose veins – short term clinical outcomes

Bakracheski N1, Zimbova M1, Donevska G1, Tegovska B1, Fortomarska-Milevska B1, Taneska N1, Zhaku R1, Petroska K1, Sheshoski B1;

Institute for cardiovascular diseases, Ohrid1, Macedonia

19. Abstract No. **173p**

Pulmonary thrombembolism associated with Bronchopneumonia

Al-Baragoni S, Bosevski M

University Clinic of Cardiology, Skopje, Macedonia

20. Abstract No. **55p**

Analysis of the main diagnosis in the requirements for assessment of working ability with special reference of the cardiovascular diseases

M.Pazeska R.Naumoska M. Samardzioska

Zdravstven Dom - Prilep, Macedonia

21 Abstract No. **56p**

Participation of Cardiovascular Diseases on ability to drive in professional drivers

Pazeska M., Naumoska R., Samarzdioska M.

Department of Occupational Medicine, Medical Institute – Prilep, Macedonia

22. Abstract No. 190p

Secondary pulmonary fibrosis due to atrial septal defect

Jovanovska Ivana, Kedev S., Stojkovic Jagoda
University Clinic of Cardiology, Skopje, Macedonia

23. Abstract No. 190p

Acute infective pericarditis at 6 years old male

Breslieva J., Spritova E. Jordanova S.
University Clinic of Cardiology, Skopje, Macedonia

Saturday 07.06.2014 Poster Session Hall 3

09:00 - 12:00 NURSING POSTER SESSION

1. Abstract No. **147**

The role of technicians in application of ReoPro

Stojanovski I.

University Clinic of Cardiology, Skopje, Macedonia

2. Abstract No. **42p**

Treatment of patients with acute and chronic heart failure – The role of technicians

Atanasovska M., Canevska T., Spasovska I., Koteska M., Pavloska N., Dojcinoska B.

KH "Acibadem Sistina" 1 Skopje, Macedonia

3. Abstract No. **104p**

The role of medical technicians in stress echocardiography

Stepanivska D., Grozdanovska D., Petkovska D., Jakimovska R., Angelovska O.

University Clinic of Cardiology, Skopje, Macedonia

4. Abstract No. **148p**

The role of technician in patients with Inflammatory heart Diseases

Pancevska J.

University Clinic of Cardiology, Skopje, Macedonia

5. Abstract No. **145p**

Planning and implementation of the health care in department of cardiology intensive care

Ilievska – Petrevska N.

University Clinic of Cardiology, Skopje, Macedonia

6. Abstract No. **164p**

Simultaneous percutaneous treatment of aortic coarctation and patent ductus arteriosus: presentation of two cases

Kostova S, Stojanova V, Rusevska S, Veselinov B, Manailov M, Milev I, Idrizi S, Ampova V, Zimbakov Z, Mitrev Z.

Special Hospital for Surgical Diseases "Filip Vtori", Skopje, Macedonia

7. Abstract No. **184p**

Percutaneous tracheostomy

Konevska S1, Bogoevska-Miteva Z1, Naumoska V1, Boseska G1, Anguseva T1, Mitrev Z1

Special Hospital for Surgical Diseases "Filip Vtori", Skopje, Macedonia

8. Abstract No. **168p**

Transcranial Doppler in diagnosis of patent foramen ovale

Dimiskovska S, Lazevska M, Trajcevska- Gavrilova M, Ristova V, Tasevska V, Alii N, Kostovska S, Ampova V, Zafirovska P, Mitrev Z

Special hospital for surgical diseases "Filip Vtori", Skopje, Macedonia

ABSTRACT BOOK

1. interventional cardiology

1

Abstract No. 46

Theme: **interventional cardiology**

Country: **Macedonia**

Management of Atrial Fibrillation - Restoring Sinus Rhythm

Kovachevikj D, Dushoski D, Petkovska Z, Spasovska A.

Acibadem Sistina, Skopje , Macedonia

The most common heart rhythm disorder represent improper work of the atria-atrial fibrillation and it is present in 2% of the world population. The goals of treatment are to prevent embolic event, to have rhythm control and to restore sinus rhythm.

Restoring the sinus rhythm can be done with medications such as Amiodarone, Flecainide , Propafenon etc. or with electrocardioversion. .

Our study includes data from 307 patients which were hospitalized with atrial fibrillation. 220 patients form 307 patients were male(71,5%) and 87 women(28,5%) with the average age 63 years±12years. 230 patients underwent electrocardioversion, of which 7 were not converted (3%) and 77 patients underwent medications and 30 of them remained in atrial fibrillation. The patients which had electrocardioversion were premedicated with Heparin and Propofol and they were underwent from one to three cardioversions with the force of impact from 300 J to 360 J synchronized. The patients which had restored the sinus rhythm and were without any structural change of the heart continued with the prevention by oral anticoagulant therapy for the following four weeks.

The electrocardioversion therapy on patients in atrial fibrillation has shown a high range percentage in restoring the sinus rhythm and a low range percentage in complications. Restoring the sinus rhythm lowers the risk from embolic complications and improves the quality of life .

Keywords: sinus rhythm, cardioversion

2

Abstract No. 51

Theme: **interventional cardiology**

Country: **Bulgaria**

Clinical case. Interventional treatment of pulmonary embolism after unsuccessful systemic fibrinolysis.

Dr. Ivan Martinov, Dr. Konstantin Stoyanov, Dr. Stanislav Kernov, Assoc. Prof. Maria Milanova

Department of Invasive Cardiology. Multi-profile Hospital for Active Medical Treatment and Emergency Medicine "Pirogov", Sofia, Bulgaria.

Clinical case. Interventional treatment of pulmonary embolism after unsuccessful systemic fibrinolysis.

In randomized trials, systemic PE thrombolysis is associated with a 13% risk of major bleeding

and a 1,8% risk of intracranial hemorrhage. In clinical practice, systemic PE thrombolysis is associated with a 20% risk of major bleeding and a 3% risk of intracranial hemorrhage. In clinical practice, systemic thrombolysis is withheld in up to two thirds of patients with high-risk (massive) PE.

Acute pulmonary embolism (PE) is the third most common cause of death among hospitalized patients. Treatment escalation beyond anticoagulation therapy is necessary in patients with massive PE (defined by hemodynamic shock) as well as in many patients with submassive PE (defined by right ventricular strain). The best current evidence suggests that modern catheter-directed therapy to achieve rapid central clot debulking should be considered as an early or first-line treatment option for patients with acute massive PE, and emerging evidence suggests a catheter-directed thrombolytic (CDT) infusion should be considered as adjunctive therapy for many patients with acute submassive PE.

This clinical case reviews the current approach to endovascular therapy for acute PE in the context of appropriate diagnosis, risk stratification, and management of acute massive PE after unsuccessful systemic fibrinolysis with Actilyse. After partial mechanical fragmentation we did local fibrinolysis with 10 mg Actilyse, then we continued infusion of Actilyse, through pigtail, for 15 hours. Eighteen hours later we made a control selective pulmonary angiogram. The blood flow in the pulmonary artery was restored and directly measured pressure was reduced with 10 mm Hg. In follow-up, seven days after discharge, with single-photon emission computed tomography - 49,6% of total lobe volume was recovered.

Keywords: acute pulmonary embolism, systemic fibrinolysis, catheter-directed thrombolysis.

3

Abstract No. 55 p

Theme: **interventional cardiology**

Country: **Macedonia**

Analysis of the main diagnosis in the requirements for assessment of working ability with special reference of the cardiovascular diseases

M.Pazeska R.Naumoska M.Samarzioska

Zdrastven Dom Prilep

Introduction and purpose of the labor. For the realization of the rights of disability pension insurance, there has to be assessment of the work ability, with diagnose and medical opinion from the Primary Disability Pension Commission, which is obtained by previously sent proposal request prepared by competent doctor. The aim of this article is to determine the most common health reasons for general and occupational disability.

Material and methods: The experimental group is consisted of 88 persons for whom the department of occupational medicine Prilep made expert medical assessment of the working ability of the participants, and the drafts were applied to the Primary Disability Pension Commission. The experimental group is defined by age (average of 50.1 years of age), work experience (average of 20.3 yeas), sex (51 woman, and 37 men), and regard to employment (60 employees, 19 unemployed, and 9 retired). The diseases are classified according to the tenth Revision of the international classification of diseases, and they are statistically processed.

Results: The most frequent main diagnoses In the applications to the Primary Disability Pension Commission are the cardiovascular diseases 31.7%, neoplasms and diseases of the muscle -

skeletal system with the percentage of representation of 18.3 %, and mental disorders in 10.0 % of the applications. With the unemployed persons neoplasms are the major reason in the 36.8% of the cases, and equal representation of mental disorders , cardiovascular diseases, and muscle-skeletal system diseases, with 15.8 % of the requests. The draft assessment of the working capacity was 67% of general disability with proposal for a disability pension, 22.7% professional incompetence with proposal for a change of the working position, 6.8% categorization of disabled person, and 3.4% with proposal for working part time for the particular person. Given the high prevalence of coronary heart disease in the general population, their effect on the working ability of the employees is very understandable. The conclusion would go towards effective prevention, early diagnosis, and treatment of these measures in order to prevent working disability.

Keywords: diseases, employees, cardiovascular diseases, working ability.

5

Abstract No. 58p

Theme: **interventional cardiology**

Country: **Macedonia**

IVUS guided stenting of the ostial left main coronary artery after late graft failure (case report)

Bakracheski N¹, Mitreski S¹, Tupare S¹, Manchevski D¹, Kovacheska-Bashurovska E¹, Sheshoski B¹, Stefanovski B¹

Institute for Cardiovascular Diseases - Ohrid,¹

Aim: To show that stenting of the left main coronary artery is indicated and should be performed in patients with severe stenosis and late graft failure, referring to the ESC guidelines for this kind of interventions; and to show that the optimization of the results using intravascular visualisation is very important, because failure of this kind of stenting, especially in-stent thrombosis could have catastrophic consequences.

Materials and methods: We report a case of a 54 y.o. male patient who presented in the outpatient clinic with stable angina and positive stress testing. Patient has past medical history of implantation of two CABG (LIMA/LAD and RIMA/OM) due to ostial left main stenosis of 95-99% two years before admission. Coronary angiography was performed showing degenerated LIMA\LAD graft and non altered RIMA-OM graft, LMN stenosis of 95-99% an RCA stenosis of 60-70%. Treatment of choice was to perform LMN Stenting with IVUS assessment of the results.

The procedure: Direct Stenting to the ostial LMN was done with implantation of DES Promus Element 4.0x16mm at 18atm and Post Dilatation with non-compliant ballon Pantera Leo) 4.5x12mm at 20atm. IVUS assessment was done after the procedure. The results show optimal stent apposition, optimal protrusion of the stent in the aortic root, and no obstruction of the flow in the left circumflex artery. The intervention went without complications. At the three months follow up the patient is feeling well, he has no chest pain and the results from the stress test are negative.

Conclusion: Left main stenting is beneficial and reasonable in patients with late graft failure and IVUS is particularly helpful in these patients to confirm accurate stent placement in relation to

the LM ostium and bifurcation.

Keywords: Intravascular ultrasound (IVUS); left main stenosis; late graft failure; direct stenting

6

Abstract No. **59**

Theme: **interventional cardiology**

Country: **Macedonia**

Acute arm ischemia: Subclavian artery stenting (case report)

Bakracheski N.⁷, Mitreski S.⁷, Manchevski D.⁷, Stefanovski B.⁷, Sheshoski B.⁷, Kovacheska-Bashuroska E.⁷

Institute for cardiovascular diseases - Ohrid - ⁷

Introduction: Acute arm ischemia is usually not immediately limb threatening due to the rich network of collateral vessels supplying the arm. However, the consequences of a poor outcome can be devastating. Subclavian artery stenosis can be a cause of significant morbidity as it can lead to symptomatic ischemic issues, affecting the upper extremities, brain and in some cases the heart. Atherosclerosis is the most common cause of this condition. In this case, a 56-year-old patient with acute arm ischemia underwent a percutaneous intervention.

Case description: A 56-year-old patient with a medical history for transient pain and paresthesia in the left arm, presented in our hospital with severe pain and coldness in the left hand.

Objectively, the hand felt cooler than the healthy limb and appeared noticeably livid. Doppler imaging of the left arm showed suspected occlusion on the proximal part of left subclavian artery. Immediate angiography (TFA) was performed and 95% stenosis of the left subclavian artery in the proximal part was verified. We proceeded to PTA/Stenting of the left subclavian artery, using 7 Fr Destination catheter. Prior to the stenting, balloon angioplasty was performed, using a 6x20 mm balloon. After that, a 10-8x30 mm self-expanding nitinol stent was implanted and we performed a postdilatation with 6.0x20 mm balloon. The procedure went without complications. Postinterventional medical management consisted of therapy with anticoagulants, antiaggregants and peripheral vasodilators. The patient was clinically much better, without pain and the normal color and warmth of the hand returned. Control doppler imaging of the left arm showed normal flow through the arteries of the left arm, without any stenosis. The patient was discharged on the 7th day. In the follow up, the patient had no clinical symptoms and the control doppler imaging of the left arm, 6 months after the procedure, showed normal flow through the arteries of the left arm, without any stenosis.

Discussion: This case illustrates the importance for medicine practitioners to be aware of the acute arm ischemia causes, symptoms, exam findings, as well as treatment options for their patients. When an intervention is needed, a percutaneous approach is favored over surgical intervention in the current era of angioplasty and stenting. Subclavian stenting is characterized by proven efficacy, without the need for general anesthesia, requiring shorter healing times and length of hospital stay which leads to significant cost savings per procedure.

Keywords: acute arm ischemia, subclavian artery stenting, self-expanding nitinol stent

7

Abstract No. 61

Theme: **interventional cardiology**

Country: **Macedonia**

One-year clinical outcomes of percutaneous treatment with drug-eluting balloons: results from our Center's registry

Bakracheski N.⁷, Mitreski S.⁷, Stefanovski B.⁷, Manchevski D.⁷, Kovacheska-Bashuroska E.⁷, Sheshoski B.⁷

Institute for cardiovascular diseases - Ohrid - ⁷

Aims: Percutaneous coronary intervention (PCI) with paclitaxel-coated drug-eluting balloons (DEB) has been more often used for the treatment of in-stent restenosis (ISR) and small vessel disease. Our aim was to evaluate the clinical efficacy of this strategy in our registry.

Methods and results: A prospective registry from the Institute for cardiovascular diseases, Ohrid enrolled 15 elective consecutive patients, between January 2011 and February 2013, submitted to PCI with 15 DEB (8 native coronary lesions – 53% and 7 ISR – 47%). The median diameter of DEB was 2.5 mm (IQR 2.0-3.0) and the median length was 22.5 mm (IQR 20-30). 12 of the patients (80%) were male, 3 (20%) were female, 14 of them (93%) had chest pain, 47% had previous myocardial infarction, 47% diabetic, 93% with hypertension, 53% had left ventricular dysfunction. Clinical, demographic and angiographic features were evaluated on the index procedure. A primary composite endpoint (MACE) of all cause death, myocardial infarction and target lesion revascularisation (TLR) was evaluated at one year clinical follow up. At one year follow-up (obtained in 100% of the patients), freedom from primary composite end point was 87% (0% death, 0% MI, 13% TLR). In the cases where the intervention was for native coronary disease, freedom from primary composite end point was 100% (for all of the 8 patients). In contrast, in the cases where the intervention was for in-stent restenosis, freedom from primary composite end point was 71%.

Conclusions: Percutaneous coronary intervention with a drug-eluting balloon in real world patients, with various complex settings of lesions, is effective with low major adverse cardiac events at one year of follow up, including target lesion revascularisation. The results are much better (even perfect) when the intervention is for native coronary disease in opposite of in-stent restenosis.

Keywords: Paclitaxel-coated drug-eluting balloon (DEB), in-stent restenosis (ISR), small vessel disease, target lesion revascularisation (TLR)

8

Abstract No. 63p

Theme: **interventional cardiology**

Country: **Macedonia**

Implantation of permanent dual chamber ICD as prevention of sudden cardiac death

**Kovacevic D¹, Trajkov I¹, Dushkoski D¹;
K.H. Acibadem-Sistina, Skopje¹**

Goal: To show one of the possible ways in treatment of sudden cardiac death due to malignant arrhythmias.

Materials and methods: EKG, Echo-cardiogram, EP Study, introducers, catheters for EP Study, Implantation of defibrillator, dual chamber defibrillator, electrodes for defibrillator. Our patient was a 26 year old female with the symptoms of irregular heart rhythm and occasional blackout's. There were no signs of any kind of malignant arrhythmias on EKG or 24h EKG Hollter monitoring. Echocardiography show's left ventricular hypertrophy without obstruction of LVOT. Dye to the upper symptoms our patient was admitted for EP Study. During the Study we induced ventricular tachycardia with wide QRS complex and hemodynamic instability with loss of consciousness. We weren't able to stop the tachycardia with anti – tachycardia pacing, and the VT was stopped with DCES 360w/s, after which we succeeded to gain normal sinus rhythm. Following procedure was implantation of permanent dual – chamber defibrillator which went without any complications. Conclusion: Implantation of pacemaker – defibrillator in patients with proven rhythm instability as a result of some kind of main disease (in our case hypertrophic cardiomyopathy) is method of choice and life – saving procedure in treatment of arrhythmias with hemodynamic instability.

Keywords: EKG, Echo-cardiogram, EP Study, ICD(Implantable cardioverter defibrillator), sudden cardiac death, arrhythmia, hypertrophic cardiomyopathy.

9

Abstract No. 67p

Theme: **interventional cardiology**

Country: **Macedonia**

Stabilization of Left Ventricular Lead by means of Coronary Vein Stenting

Gjorgov N. - ¹, Busljetic O. - ¹, Trajkov I. - ¹, Kovacevic D. - ¹
Acibadem|Sistina Hospital - ¹

Current management of heart failure is a complex and multifaceted discipline in cardiology where the majority of patients with heart failure cannot be managed by drugs alone. In those patients where optimal drug treatment does not provide the desired effect, drug therapy is often combined with implantation of Cardiac Resynchronization Therapy (CRT).

Aim of this paper is to report a case where we present our solution for stabilizing the left ventricular lead (LVL) by stenting the lead within the coronary sinus venous system.

Materials and methods: Our patient is with dilated Cardiomyopathy and wide QRS with LBBB morphology. Patient was in stable sinus rhythm, and could not discriminate the lead dislodgment, but she could identify that she became dyspnoic a month before her scheduled device follow-up. Thorough follow-up confirmed the dislodgement. Dislodgement of the LVL defeats the purpose of CRT implant, thus in many cases rendering the implanted device unnecessary, and in certain percentage of patients it worsens the heart failure. New and identical LVL was implanted taking care to obtain optimal device and lead performance. At the end of the implant procedure it appeared that the LVL occupied anatomical location comparable to the previous implant procedure, location from which it became dislodged. Not wanting to evade the notable pacing parameters, but at the same time trying to avoid another possible LVL dislodgement, it was decided to stabilize the LVL by stenting the LVL within the Coronary Sinus Venous System. A pre-mounted 3.5/9 mm bare metal stent was positioned 10 mm proximal to the proximal electrode, taking into account anatomic angulation of the coronary sinus, and taking care to avoid

the existing angulation of the vein for fear that it might disturb the normal blood flow.
Results: Two and a half year follow-up reveal that the device is functioning properly and in a manner that it was intended to do. The patient has improved and the lead is in the same positioned as when it was implanted.

Conclusion One can never predict with certainty impending dislodgment of a lead, but when lead stability is believed to be compromised, stenting of left ventricular lead is a safe procedure, especially when repositioning a previously dislodged left ventricular lead.

10

Abstract No. **70**

Theme: **interventional cardiology**

Country: **Macedonia**

What is the best initial treatment strategy for patients with stable ischemic heart disease?: The role of noninvasive imaging

Irena Peovska Mitevska

University Cardiology Clinic Skopje Macedonia

Орална презентација за најактуелните ставови, препораки, студии и дилеми во однос на тераписката стратегија кај пациенти со стабилна КАБ, со особен акцент на неинвазивните техники на миокардна визуализација -миокардна сцинтиграфија. Осврт на улогата на најновата студија на ова поле-ISCHEMIA Trial

Keywords: исхемија, КАБ, третман

11

Abstract No. **73p**

Theme: **interventional cardiology**

Country: **Macedonia**

REVERSE LEFTVENTRICULAR REMODELLING AFTER SURGICAL CORRECTION OF ISCHAEMIC MITRAL REGURGITATION

Idoski Enver, Angusheva Tanja, Klinev Milka, Mitrev Zan

Special hospital for surgery, Filip Vtori

Objective: Ischaemic mitral regurgitation (IMR) is associated with a worsening clinical symptoms, a decrease in exercise capacity and a poor prognosis. It is so because the mitral regurgitation (MR) increased volume overload of the left ventricle (LV) leads to a further progression of MR.

Goals: Surgical correction of IMR is associated with reverse LV remodelling.

Materials and methods: The population includes 101 patients with ischaemic cardiomyopathy and IMR 3-4+ scheduled for CABG and mitral valve reconstruction (MVR) during the period of 5 with a 2 year follow up. Seventyseven percent of all the patients were male, mean age 60 of all. All the patients were with New York heart Association NYHA III-IV with mostly threevessel coronary artery disease (CAD). Intraoperative transoesophageal echocardiography (TEE) was made in all patients. After aortocoronary bypass (ACBP) a mitral reductive posterior semicircular suture anuloplasty was made with downsizing rings with 28 ± 2 mm. In the patients with moderate to severe tricuspid regurgitation (TR) a tricuspid semicircular suture anuloplasty was made.

Results: Correction of the ejection fraction (EF) of mean 32% preoperative to 40% postoperative, postoperative, NYHA decreased from III-IV to I-III, leftventricular enddiastolic diameter (LVIDD) decreased from 64mm to 58mm, leftventricular endsystolic diameter (LVIDS) from 47mm to 43 mm, leftventricular enddiastolic volume (LVEDV) from 229 ml to 171ml, (leftventricular endsystolic volume (LVESV) from 155ml to 107ml. Left atrial dimensions decreased from 51mm to 45mm. Mean mechanical ventilation time was 12 hours, mean hospital stay 7 days. Early postoperative mortality (<30 days) in 2 (1,9%) patients with multiorgan failure.

In 2 year period 2 patients needed reoperation because of heart decompensation. Postoperative NYHA was II.

Conclusion: CABG and MVR in patients with IMR leads to a significant reverse remodelling of LV with improved LV contractility, reduction in LV dimensions, LV volumens, left atrial dimensions.

Keywords: left ventricle, remodeling, mitral reconstruction

12

Abstract No. **74**

Theme: **interventional cardiology**

Country: **Macedonia**

Treatment of postinfarctal VSD

Idoski Enver, Angusheva Tanja, Mitrev Zan

Special Hospital for Cardiosurgery Filip II, Skopje, R. Mcedonia

Ventricular septal defect (VSD) appears early after miocardial infraction, with an incidence of about 1-2% of all myocardial infraction. Without surgery the mortality was 54% within the first week and 92% within the first year. References: European Heart Journal (2003).

Purpose of the study: to demonstrate our experience in managment of the AIM complicated with VSD.

Material and methods: In period of 10 years out of 722 CABG + DCR procedures, 6 (0.69%) patients had postinfarctal VSD. Mean age 56,8 (53-60 years), men/women ratio 2/4. All patients were in cardiogenic shock and pulmonary oedema.

Angiography has shown multiple coronary artery disease, in 6/6 patients. The diagnosis was made by TTE, in one patient with TEE.

Results: All patients were with NYHA IV, preoperative stimulated with inotropes. In four patients IABP (intraaortic ballon pump) was plased. One patient preoperative was on assisted mechanical ventilation. Preoperative hospitalisation was 8 days.

All patient were surgically treated.

Average diametar of the VSD was 21,25mm. Change of EF from 31% to 43%. Reduction of EDV from 263.75 + 30ml to 157 ±10ml. Average stay in hospital 28,5 (мин 11, макс 62) days.

At the third, sixth and 12th month after the surgery the patiens had NYHA I-II.

Conclusion: The best choice of treatment for postinfarction VSD is a surgical closing of the VSD. Preoperative stimulation with inotropes and placement of IABP is the most effective method of providing circulatory support while preparing for surgery.

13

Abstract No. **76p**

Theme: **interventional cardiology**

Country: **Macedonia**

Results following reduction ascending aortoplasty

Enver Idoski, Nikola Hristov, Tanja Angusheva, Milka Klinceva, Zan Mitrev

Special hospital for surgery “Filip Vtori”

Objective: Dilatation of the ascending aorta is often encountered during surgery for aortic valve disease. Reduction ascending aortoplasty (RAA) is a technique for reduction of the aortic diameter, resulting in a reduced aortic wall stress and a diminished risk of rupture or dissection. It is an alternative to standard graft replacement of dilated ascending aorta.

The aim of this study: retrospectively analyze the preoperative results and follow up dimensions of the ascending aorta in 50 patients who underwent RAA along with other cardiac procedures in our institution.

Material and methods: Fifty patients with dilation of the ascending aorta with dimensions between 45mm and 55mm that underwent RAA with concomitant cardiac procedures in our institution, were eligible for this study. There were 37 male and 13 females, with average age of 58 ± 10 years. Ejection fraction averaged 41 ± 8 . Measurements of the ascending aortic diameter were performed prior to and directly following surgery, and on average 39 months postoperatively (range: 8-75 months). Preoperative dimensions of the ascending aorta averaged 49 ± 5 mm. From the fifty patients only forty-one patients were available for follow-up.

Results: The diameter of the ascending aorta was significantly reduced in all patients who had undergone RAA ($p < 0.001$). Average dimension of the ascending aorta on first control was 37 ± 5 mm, and on the last follow up, average dimension was 39 ± 7 mm.

Conclusion: Poststenotic ascending aortic dilatation with dimension less than 60 mm and absence of structural abnormality of aortic wall are proper indications for RAA and performed together with valve replacement is a safe and simple procedure, resulting with minimal morbidity, mortality and stable midterm aortic dimensions.

14

Abstract No. **77p**

Theme: **interventional cardiology**

Country: **Macedonia**

RADIOFREQUENCY CATHETER ABLATION IN YOUNG PATIENT WITH THE WOLFF- PARKINSON-WHITE SYNDROME

Fortomarska Milevska B¹, Angelkov L², Mitreski S¹, Kovacheska Bashurovska E¹, Sheshoski B¹, Aftovska Naumoska I¹, Tupare S¹, Taneska N¹, Institute for prevention, treatment and rehabilitation of cardiovascular disease, Ohrid¹; Institute for cardiovascular diseases Dedinje, Belgrade²;

Aim: To show treatment efficacy of radiofrequency catheter ablation of accessory atrioventricular pathways in young patient.

Materials and methods : We report a case an 18 year old male patient. Evaluation of patient s electrocardiographic recordings suggested a presence of Wolff - Parkinson - White syndrome. Diagnosis found incidentally in electrocardiogram taken for other reason (routine exams for

sportsman). Patient was healthy individual without organic heart disease. Trans-thoracic echocardiography examination showed LVDd=55mm, LVDs= 34mm, EF >60%, IVS=10.5mm, LVPW=8MM, RVDd=24mm, LA=36MM, Ao=31mm, mild mitral regurgitation and mild tricuspidal regurgitation. (normal findings). Patient had no symptoms until one year ago, when paroxysmal ectopic rapid heart action developed. Because of the manifest preexcitation the team led by an electrophysiologist decided to perform radiofrequency catheter ablation of the accessory pathway. The procedure: Catheters used: decapolar catheter placed in the CS(coronary sinus) via the left subclavian vein; quadripolar catheter in the RVA (right ventricular apex) and hexapolar catheter in the HIS bundle area via the left femoral vein; quadripolar catheter in the RA(right atrium) and an Thermocool ablation catheter via the right femoral vein. The patient had anterograde ERP of less than 250msec, and retrograde conduction of up to 240msec. Using antegrade mapping the earliest onset of ventricular electrogram in relation to the delta wave was found in the anterolateral part of the tricuspid annulus(-53msec). A single RF lesion was applied with energy of 55W at 60°C for 120sec. After the ablation we registered retrograde VA block. I.V. administration of 30mg adenosine caused AV block, confirming conduction only through the AV node.

Result: After successful intervention we got normal ECG and normal 24-hour Holter ECG monitoring without specific features for WPW syndrome.

Conclusion: Radiofrequency catheter ablation of accessory atrioventricular pathways could be success and safety performed in young patient specially when paroxysmal ectopic rapid heart action develops.

Keywords: radiofrequency catheter ablation, Wolff - Parkinson - White syndrome

15

Abstract No. 78

Theme: **interventional cardiology**

Country: **Macedonia**

Role of echocardiography in the diagnosis of anomalous pulmonary venous connection

Kuzevska-Maneva K¹, Kacarska R¹, Gjurkova-Angelovska B¹, Jovanovska V¹, Neshkovska-Shumenkovska M¹.

University children's hospital, Clinical center¹, Skopje, R. Macedonia

Anomalous pulmonary venous connection (APVC) is a rare congenital cardiac defect which consists of an abnormality of body flow in which all of 4 pulmonary veins (in total) or few of pulmonary veins (in partial) drains into a systemic veins of the right atrium. AIM. The role of echocardiography in the diagnosis of APVC. MATERIALS AND METHODS. We examined 10 children with total and 3 with partial anomalous pulmonary venous connection aged from 1m-18 month (mean 3,8m +/- 2,4) for TAPVC at the time of diagnosis, and from 4m-46 month (mean 17 month +/- 3,4) for PARVC. The diagnosis was performed by use of: clinical signs and symptoms, chest X-ray, 12 channel ECG and 2 Dimensional color-Doppler echocardiography as a main method. RESULTS. Supracardiac connection had 3/10 children, infracardiac 5/10 and infraafragmal connection had 2/10 children with TAPVR. 2 of them had obstruction of pulmonary veins. From the pts with PAPVR 2/3 had anomalous return of 2 pulmonary veins, and 1/3 had anomalous return of one pulmonary vein. All the patient had atrial septal defect type sinus venosus, or fossa ovalis type. They were operated in the foreign cardiosurgery centers and had a good outcome. CONCLUSION. The echocardiography is most useful diagnostic tool in the

diagnosis of APVC, also for follow-up of the operated children from these complex congenital heart diseases.

16

Abstract No. **79p**

Theme: **interventional cardiology**

Country: **Macedonia**

Rate and incidence of pacemaker dependent patients after pacemaker implantation

Boskov V¹, Taleski J¹, Janusevski F¹

University Clinic of Cardiology, Skopje¹

Background:

It is known that pacemaker-dependent (PD) patients have inadequate or even absent intrinsic rhythm and therefore can suffer significant symptoms or cardiac arrest after termination of pacing. Pacemaker dependency testing is routinely performed during the regular follow-up in patients with implanted permanent PM. During the testing a decrease in the base paced rate to 30–40 bpm is done, followed by a close observation for an underlying intrinsic ventricular rhythm or pause longer than 3 seconds after switching off the permanent pacemaker .

Methods: The study included 1140 patients (age range 30-90 years). Indications for pacing were sick sinus syndrome (SSS) in 88 patients, second degree AV block (AVB gr. II) in 271, third degree AV block (AVB gr. III) in 554 and atrial fibrillation (AF) with bradycardia in 227 patients. The mean follow-up was 3.2 +/- 1.5 years. Pacemaker dependency was defined as the absence of an intrinsic rhythm of 30 beats/min during back-up pacing and after switching off the pacemaker . If any significant symptoms of bradycardia developed or if the underlying rhythm did not appear (asystole > 3 s) the pacing was restarted.

Results: Pacemaker dependency was observed in 247 (21 %) of the 1140 patients . In this subgroup pacing indications were SSS in 3 (3%) of 88 patients, AVB gr. II in 19 (7%) of 271, AVB gr. III in 206 (37%) of 554 and AF with bradycardia in 19 (8%) of 227. Patients with AVB gr. III had a significantly higher incidence of PD than patients with SSS or AF . In the same period of time 170 pacemaker reimplantations were made and 80 of them were dependent.

Conclusions: In our study PD occurred in 21% of all patients. Patients with AVB have a significantly higher incidence of PD than patients with SSS or AF.

17

Abstract No. **87**

Theme: **interventional cardiology**

Country: **Macedonia**

Transradial vs. Transfemoral Primary Percutaneous Coronary Intervention for ST Elevation Myocardial Infarction: Two years Follow Up

Kalpak O., Pejkov H., Spiroski I., Kostov J., Antov S., Kedev S.

University Clinic of Cardiology, Skopje

Objective: We have compared the impact of access strategy change on early and two-year outcomes after primary percutaneous coronary intervention using trans-radial access (TRA) versus intervention by trans-femoral access (TFA).

Background: Adoption of TRA was recently proposed as potentially beneficial strategy to improve outcomes of PPCI for STEMI patients.

Methods: We have studied 1808 consecutive patients which underwent TFA (n=646) and TRA (n= 1162) intervention for STEMI at our institution between 2007 and 2010. This was all-comers study regardless patient acute clinical presentation of STEMI. We have compared the cardiac mortality and the MACE rates (composite of death, stroke, re MI and TVR) after two years of follow up.

Results: The majority of deaths occurred as early events in the first 30 days from STEMI. The major difference in early mortality rates was in favor of TRA strategy (5.2% or 60deaths) comparing TFA strategy (10.5% or 68 deaths) (OR 0.46; 95% CI [0.32-0.66], p< 0.001). TRA was also associated with significant 30 days MACE rate reduction (7.3% vs. 12.5%, HR 0.55; 95% CI [0.39-0.76], p< 0.001). Following the first year of follow up additional 1.7% and 1.0% of deaths occurred in both groups respectively. At two years follow up there were 93 deaths (8.0%) mortality rate in TRA group comparing to 90 deaths (13.9%) in TFA group (OR 0.60; 95% CI [0.47-0.89], p=0.001). The difference obtained in the first 30 days between the two accesses strategies have sustained with similar trends for mortality rates in the following two years. Two year MACE rates were in favor of TRA strategy (14.6% Vs 22.1%; OR 0.56; 95% CI [0.43-0.78], p< 0.001). Cumulative survival curves were created to illustrate findings.

Conclusions: Our study confirmed that transradial access strategy for primary coronary intervention is associated with significant early and two years MACE rate reduction comparing to default transfemoral access strategy for primary coronary interventions in STEMI patients. TRA was associated with sustained mortality benefit after two years.

Keywords: TRA , STEMI, primary PCI,

18

Abstract No. 87

Theme: **Интервентна кардиологија**

Country: **Macedonia**

Dvegodisno sledenje po transradijalna nasproti transfemoralna primarna koronarna intervencija zaradi akuten miokarden infarkt

Kalpak O., Pejkov H., Spiroski I., Kostov J., Antov S., Kedev S.

Univerzitetaska Klinika za Kardiologija -Skopje

Cel: Go kompariravme impaktot vrz kline~kiot ishod od promenata na strategijata za arterijski pristap od trans-femoralen (TFA) kon trans-radijalen (TRA) pri primarnata perkutana koronarna intervencija (PKI).

Voved: Primenata na TRA namestoto na TFA neodamna be{e predlozena kako strategija koja moze da go podobri ishodot od primarnata PKI kaj tretmanot na pacientite so akuten ST-eleviran miokarden infarkt (STEMI).

Metodi: Isleduvavme 1808 konsekutivni pacienti i toa 646 TFA i 1162 TRA , kaj koi be{e napravena PKI zaradi STEMI vo nasata institucija vo periodot pome|u noemvri 2007 i dekemvri 2010 godina. Ova studija gi opfa}a bez isklucok , site pacienti, bez ogle na nivnata akutna klinicka prezentacija pri STEMI . Po dve godisno sledenje gi kompariravme stapkata na mortalitet i stapkata na majorni nesakani kardiovaskularni nastani (MNKN) odnosno vkupno stapkata na smrtnost, mozocen udar, povtoren infarkt i povtorna revaskularizacija na interveniranata arterija.

Rezultati : Vo tekot na prvite 30 dena po STEMI bea zabele`ani mnozinstvoto od slucai na smrten ishod kako i od MNKN. Nagjolemata razlika na stapkata na raniot mortalitet vo polza na TRA 5.2% (ili 60 pacienti) nasproti TFA 10.5% (odnosno 68 pacienti) be{e statisticki znacajna (OR 0.46; 95% CI [0.32-0.66], $p < 0.001$). Radijalniot pristap bese asociran so znacajna redukcija na 30 dnevna stapka na MNKN (7.3% vs. 12.5%, OR 0.55; 95% CI [0.39-0.76], $p < 0.001$) . Vo tek na prvata godina be{e zabele`an slicen porast na stapkata ma mortalitet kaj dvete grupi (TRA za 1.7% i za 1.0% kaj TFA). Po dve godini sledewe imase 93 smrtni ishodi ili 8.0% kaj TRA nasproti 90 ili 13.9% kaj TFA grupata (OR 0.60; 95% CI [0.47-0.89], $p = 0.001$) . Razlikata vo mortalitetot od prvite 30 dena pome|u dvete strategii na arterijski pristap bese odr`ana po dvegodi{noto sledewe. Dvegodisnata stapka na MNKN bese vo korist na TRA strategijata (14.6% Vs 22.1%; OR 0.56; 95% CI [0.43-0.78], $p < 0.001$). Bea kreirani kumulativni krivi na prezivuvawe za da se ilustriraat naodite.

Zaklucok: Nasata studija potvrduva deka trans-radijalniot pristap za primarna koronarna intervencija e asociran so znacajna redukcija na raniot i dvogodisniot mortalitet kako i na stapkata na kumulativni nesakani kardiovaskularni nastani sporedeno so trans-femoralnata strategija na pristap kaj interveciite za STEMI pacientite.

Keywords: TRA , STEMI, primary PCI,

19

Abstract No. 91p

Theme: **interventional cardiology**

Country: **Macedonia**

SIX-MONTH FOLLOW-UP OF THE ECHOCARDIOGRAPHIC PARAMETERS IN PATIENTS WITH ACUTE LAD OCCLUSION

Srbinovska-Kostovska E.⁽¹⁾, Pejkov H.⁽¹⁾, Antov S.⁽¹⁾, Kalpak O.⁽¹⁾, Andova V.⁽¹⁾, Hristova E.⁽¹⁾, Kedev S.⁽¹⁾

University Clinic of Cardiology, Medical Faculty – Skopje, University Ss. Cyril and Methodius, Macedonia

Aim of the study. Acute myocardial infarction (AMI) is often accompanied by left ventricular dilatation and impaired left ventricular function, especially in left coronary artery occlusion. The aim of the study was to discover left ventricular function in patients with AMI and 100% occlusion of the left coronary artery, obtained by echocardiography and to discover whether there is an improvement of the left ventricular function early after percutaneous intervention(PCI) and after 6 months' follow.

Methods. We analyzed 32 patients with ST-elevation acute myocardial infarction with complete left coronary artery occlusion undergoing primary percutaneous coronary intervention (PCI). The mean age of the patients were 59,94±9,87 years, 69% of the patients were male and 31% were female. Transthoracic echocardiography (TTE) was performed immediately prior to intervention, 3 days after PCI and at 6 months' follow. Left ventricular diastolic dimension (mm), left ventricular ejection fraction (%) and global longitudinal peak systolic strain(%) by TTE were obtained prior PCI, and were correlated with echocardiographic parameters 3 days after PCI and at 6 months' follow.

Results. The left ventricular dimension (LVEDd) showed increasing in the dimension after revascularization (prior PCI 54,42±0,68mm, 3 days after PCI 56,16±0,70 mm, and after 6 month 57,70±0,87mm). These parameters showed a statistically significant correlation ($r = 0,768$ vs.

$r=0,468$ vs. $r=0,784$; $p<0,01$). Ejection fraction showed improvement after PCI, but didn't show improvement of the global LV function at 6 months' follow (EF prior PCI 45,42% +9,07; 3 days after PCI 47,48% +8,14, and after 6 month 49,01% +7,96). These parameters showed a statistically significant correlation in improvement of global LV function between baseline assessment and after PCI (3 days, 6 mounts' follow- $p<0,001$); ($r=0,737$ vs. $r=0,271$ vs. $r=0,713$). The global longitudinal peak systolic strain (GLPSS) analysis which give information about global longitudinal left ventricular function, showed improvement after revascularization (prior PCI -11,88% +3,32, 3 days after PCI -12,68% +3,59, and after 6 month -13,5% + 3,87). These parameters showed a statistically significant correlation ($r=0,854$ vs. $r=0,623$ vs. $r=0,762$; $p<0,001$).

Conclusion. The results of our study shown that the LV dimension increased during the follow up, and the global LV systolic function improved significant early after PCI, but long-term results contribute with adverse left ventricular remodeling after left coronary artery occlusion despite PCI. Parameters of GLPSS showed better recovery of the LV longitudinal function of the LV.

Keywords: left ventricular dimension, left ventricular function, global longitudinal peak systolic strain, acute myocardial infarction

20

Abstract No. 109p

Theme: **interventional cardiology**

Country: **Albania**

Gender-specific Outcomes in Polymer-Free Drug-Eluting Stent (YUKON) Compared with Polymer Based Drug-Eluting Stents in Real-World Coronary Artery Lesions

Trajceski T, Petrovski B, Petrovski Z, Brovina L, Zuna B, Abdushi S, Simonovski K Spitali Zemres Intermed EDA

Objectives: The impact of gender on outcomes in patients undergone PCI are still not well established considering different models of eluting process of stents. We compared the safety and efficacy of different permanent polymer based drug-eluting stents (PBS) with a polymer-free drug-eluting stent (PFS-Yukon). In unselected real-world patients with coronary lesions of various complexities, we retrospectively compared both stent designs. Methods: A total of 617 lesions in patients with symptomatic CAD were treated with PBS ($n = 383$) or with PFS ($n = 234$). The PBS group consisted of 44(12%) Cypher, 101(26%) Xience, 107(28%) Endeavor, 55(14%) Infinium and 75(20%) Coroflex Please stents, assigned to patients and lesions by shelf disposal and target vessel dimensions. Presence of male gender was not significantly different in both stent groups: 70 (59%) in PFS vs. 313 (63%) in PBS, $p= 0.280$. The primary clinical endpoint of this study was a composite of cardiac death, myocardial infarction and clinical-indicated target vessel revascularisation (MACE). Results: Polymer free stents were non-inferior to polymer- stents for the primary endpoint at 9 months (13 [5.6%] patients vs 21 [5.5%], HR: 0.98 [95% CI 0.48-2.01], p for superiority=0.96). Women were more likely to have smaller vessel reference vessel size (<2.75 mm), and shorter lesions, HR: 0.47 [95% CI 0.29-0.78], $p= 0.03$; HR: 1.66 [95% CI 1.11-2.50], $p= 0.009$. Analysis of MACE after 9 months resulted in 4 (1.7%) definitive stent thrombosis causing MI in PFS vs. 18(4.7%) in PBS treated patients, with borderline significant difference (log rank, $p=0.052$). In the cox proportional regression analysis

of MACE, and Definitive Stent Thrombosis, none of the stents showed different survival according to stratification by presence of gender (HR: 0.91 [95% CI 0.39-2.08], p for superiority=0.82), (HR: 1.45 [95% CI 0.43-4.90], p for superiority=0.55) respectively. Conclusions: Up to 9 months after PCI of real-world coronary lesions, there were no statistically significant differences in MACE in patients in respect of gender, treated with the polymer-free YUKON stent and the group of polymer-based stents.

21

Abstract No. **110** p

Theme: **interventional cardiology**

Country: **Albania**

SEVERE CONTRAST INDUCED NEPHROPATHY IN PATIENTS UNDERGOING PRIMARY ANGIOPASTY FOR ACUTE MYOCARDIAL INFARCTION

Simonovski K, Petrovski B, Petrovski Z, Brovina L, Zuna B, Abdushi S, Trajceski T Spitali Zemres Intermed EDA Pristina

The aim of this research was to access the incidence, clinical predictors and outcome of contrast-induced nephropathy (CIN) with need of renal replacement therapy (dialysis), after primary percutaneous coronary intervention (PCI) for acute myocardial infarction (AMI). CIN is defined as an increase in serum creatinin by either 0.5 mg/dl or by $\geq 25\%$ from baseline within the first 2-3 days after contrast administration, after other causes of renal impairment have been excluded. The incidence is considerably higher in diabetics, elderly and patients with preexisting renal disease, when compared to the general population. The nephrotoxic potential of various contrast agents must be evaluated completely, with prevention as the mainstay of focus as no effective treatment exists. 3234 consecutive AMI patients underwent primary PCI. Recognition of the high risk patient coupled with appropriate peri-procedural management to reduce of incidence of CIN was applied to all patients > vigorous parenteral volume repletion limiting contrast volume, withholding potentially nephrotoxic drugs. As a contrast agent, Iopromide (Ultravist) was used in all procedures. Retrospectively analyzed risk factors, clinical course of severe CIN and outcomes in those with need of dialysis after PCI. Overall severe CIN occurred in 7 (0.2%) patients. Of the 7 patients 2 developed nephropathy with temporary need of dialysis (recovering the renal function) and of the rest 5 started chronic hemodialysis because of End Stage Renal Disease (ESRD). All of the patients receiving dialysis were hypertonic, age > 65 years and 3 of those who developed ESRD had also diabetes the three patients with temporary need of dialysis and baseline Cr clearance was 60ml/min, whereas all those with Cr clearance <60ml/min developed ESRD. In none of the analyzed patients time to reperfusion exceeded 6 hours, or contrast agent volume exceeded 300ml. Patients developing CIN had longer hospital stay than other patients, (15 ± 8 days vs. 9 ± 4 days; $p < 0.002$) and more complicated clinical course. Contrast induced nephropathy complicates Primary PCI. It is associated with higher in-hospital complication and stay. Preventive management can be clinically efficient for the modifiable risk factors, lowering the rate of CIN.

22

Abstract No. **116**p

Theme: **interventional cardiology**

Country: **Macedonia**

Implantation of a single lead VDD pacing system through a persistent left superior vena cava

Taleski J¹, Janusevski F¹

University Clinic of Cardiology Skopje¹

BACKGROUND:

Persistent left superior vena cava (PLSVC) is a structural and asymptomatic heart anomaly that is present in 0.5% of the general population. This heart anomaly is considered benign, but is very frequently associated with other cardiac abnormalities (e.g. ventricular septal defect, atrioventricular septal defect). Usually it is diagnosed unexpectedly at the time of pacemaker implantation. It may complicate pacemaker implantation during subclavian vein puncture and makes lead insertion and positioning into the right ventricle more difficult. It is usually associated with high risk of failure and complications. This case report shows a successful implantation of a single lead VDD pacing system through a persistent left superior vena cava (PLSVC). It also addresses the possible complications during implantation in these cases.

CASE PRESENTATION:

Seventy eight year old male patient with occasional occurrence of dizziness, fatigue and syncope treated as an outpatient, was admitted in the cardiology clinic ward. The patient was in sinus rhythm with heart rate of 85 beats per minute and left bundle branch block on ECG. Arterial blood pressure was 120/80mmHg. 24h Holter monitoring was performed, and paroxysmal complete heart block was discovered. Pacemaker implantation was scheduled for the next day. The procedure was performed with local anesthesia. After the primary incision, left subclavian vein puncture was performed and a guide wire was inserted. PLSVC was diagnosed using contrast, visualizing PLSVC, coronary sinus (CS) and right atrium (RA). VDD pacing lead was inserted, with J-loop through the coronary sinus by pulling back the stylet wire. The VDD pacing lead was placed in the right ventricle apex and the atrial sensing coil was carefully placed in the RA close to CS ostium. Pacemaker control was performed, during which ventricular threshold was 0.375v/0.40ms and atrial sensing was 1.00mv-1.40mv. The next day due to shortness of breath, chest X-ray was performed and pneumothorax was diagnosed. After 3 days with passive drainage, control chest X-ray showed complete resolution of pneumothorax.

DISCUSSION:

PLSVC is a rare congenital vascular abnormality and its usually associated with congenital heart anomalies and disturbances of cardiac rhythm, impulse formation and conduction. As we can see in this case the procedure is very delicate and requires significant knowledge and precision during the puncture, advancing and positioning of the lead. It is very important to point out that even in patients with this kind of anomalies, single VDD pacing lead can have an excellent performance if we can achieve not just a good ventricular position but an atrial sensing position too. Also after the procedure it is important to run a full pacemaker control, to be sure that we have an excellent ventricular and stabile atrial position as we achieved in our case.

Complications as pneumothorax, dissection of the venous wall, coronary sinus occlusion and wall perforation are very common during implantation.

CONCLUSION:

With this case we can see that implantation of single lead VDD pacing system, through PLSVC is feasible and can be successfully performed by an experienced operator.

Keywords: PLSVC, VDD pacing lead,

23

Abstract No. **118p**

Theme: **interventional cardiology**

Country: **Macedonia**

Bailout procedure in acute massive right coronary artery dissection (case report)

Bakracheski N¹, Mitreski S¹, Manchevski D¹, Kovacheska Bashuroska E¹, Sheshoski B¹, Stefanovski B¹,

Institute for cardiovascular diseases, Ohrid¹

Aim:

A challenging case of treating acute massive right coronary artery dissection as a complication during elective PCI

Materials and methods:

68 yo male with history of diabetes mellitus type II, ex smoker, presented with chest pain during minimal effort and occasionally at rest, that relieved with sublingual nitroglycerin. The patient's echocardiography showed mildly reduced ejection fraction (45%) and mild mitral regurgitation. The patient was admitted for elective PCI. The angiography revealed significant complex lesion on the right coronary artery (RCA) 95-99%. Judkins right guiding catheter was introduced, Balance-middleweight guidewire advanced in the RCA and balloon catheter(BC) 1.25x20mm inflated at 10atm. After the balloon dilatation a massive acute coronary artery dissection occurred, with TIMI 0 FLOW, ST elevations and pressure dumping.

Final strategy included – subintimal tracking from the proximal RCA reentering the true lumen at the distal RCA and consecutive stenting. Multiple guidewires, BCs and stents used. TIMI 2-3 Flow restored. Patient haemodynamically stabilized. Treated with DAP and UFH. At discharge, walking telemetry performed with normal findings. At one month follow up the patient is stable, free of symptoms.

Follow up angiography is planned at 6 months after the procedure, or symptom driven.

Conclusion: Acute massive coronary artery dissection is a serious complication of PCI, requiring performance of bailout procedure with individual approach, dependant of the anatomy of the lesion, the severity of the dissection, and the haemodynamics of the patient.

Keywords: Coronary artery dissection; bailout procedure; subintimal tracking;

24

Abstract No. **119**

Theme: **interventional cardiology**

Country: **Macedonia**

Ulogata na medicinska sestra vo tretmanot na kardiovaskularnite zaboluvanja so novi interventni proceduri

D.Ristovska,J.Miljkovik,A.Zarevska,

H.Saliu,S.Janakieva,A.Velkovska,M.Tutik,A.Antovska,D.Jankov,B.Krmzov

University Clinic of Cardiology Skopje

Vo poslednata dekada vo oblasta na interventnata kardiologija e postignat znaacen napredok, kako vo tretmanot na koronarnata arteriska bolest , taka i vo tretmanot na perifernata i karotidna arteriska bolest kako i tretmanot na rezistentna hipertenzija.

Klinikata za Kardiologija gi sledi ovie trendovi i so uspeh rutinski gi izveduva.

Na klinikata za kardiologija vo poslednata godina se izvedeni 12 proceduri so intravaskularen ultra zvuk i 4 proceduri na opticka koherentna tomografija, koj dava moznost za podetalna vizualizacija na koronarniot krven sad so pomos na ultra zvuk ili opticki vlakna, procena na goleminata na koronarnata arterija, golemina na ateromatozna plaka, procent na stenoza na koronarnata arterija, vizualizacija na postoecki tromb. Od posebna vaznost e воведуvanje na metodata za rotablacija koja dava moznost za stentiranje na koronarni arterii koi se so izraziti kalcifikati, kade konvencionalnata interventna procedura ne dava moznost za implantacija na endovaskularna proteza. Takvi proceduri na klinikata vo poslednata godina se izvedeni kaj 6 pacienti. Tretmanot na rezistentna hipertenzija, sto znaci i pokraj воведуvanje na poveke od 5 razlicni lekovi, kaj pacientite sistolniot pritisok ne se namaluva pomalku od 160 mmHG, moze uspesno da se lekuva so renalna denervacija koja vo nasata institucija e izvedena kaj 6 pacienti. Vo poslednata decenija tretmanot na karotidnite stenozii se poveke se izveduva so interventni proceduri. Vкупniот број, kaj koi e izvedena interventna procedura i implantacija na endovaskularni protezi vo karotidnite arterii iznesuvase 421 pacient.

Medicinskata sestra ima znacajna uloga vo pripremata na pacientot, kako i vo samata intervencijata od ovoj tip.

Potrebno e golemo iskustvo i kontinuirana edukacija na medicinskiot personal za da mozat ovie novi interventni proceduri da stanat rutinska procedura vo sekoja laboratorija.

Keywords: PCI ; IVUS ; OCT ; Renal Denervation

25

Abstract No. 121

Theme: **interventional cardiology**

Country: **Macedonia**

Medicinska sestra znacaen faktor vo tretmanot na pacienti so STEMI

Т.Здравковска, А.Бихорац, Р.Ричкова, М.Манојловска, Ж.Котевска, М.Спасовска, С. Ќосовиќ, В.Димовска, Р.Смрекова, С.Донева

University Clinic of Cardiology Skopje

Koronarnata arteriska bolest predstavuva najgolem pricinitel na mortalitetot kako vo svetski ramki taka i vo Republika Makedonija.

Najdobri rezultati vo tretmanot na pacienti so ST segment elevacija miokarden infarkt (STEMI) se dobivaat so interventni proceduri, kade smrtnosta se dvizi pomegu 2-8% dodeka so fibrinoliticka terapija smrtnosta dostignuva i do 18%.

Na klinikata za Kardiologija godina vo 2012 godina se izvedeni 722, vo 2013 godina 744 primarni perkutani intervencii.

Brojot na intervencii se zgolemuva od godina na godina poradi faktot што koronarna arteriska bolest seumte zazema prvo mesto vo morbiditetot i mortalitetot vo drzavata.

Medicinskata sestra igra vazna uloga pri tretman na pacienti so STEMI.

Medicinskata sestra treba da bide dobro educirana za sproveduvanje i kontrola na sterilnosta vo operativniот blok, isklucitelno dobro da go poznavava EKG monitoringot, brzo i efikasno da izveduva reanimacija i da go poznavava sekoj segment od interventnata procedura.

Za seta ovaа da se postigne potrebna e kontinuirana medicinska edukacija vo edinicata za intenzivna koronarna nega, edukacija za sterilnosta vo operativniот blok, kako i aktivno ucestvo na simpoziumi i kongresi po interventna kardiologija.

Keywords: PCI ; STEMI

26

Abstract No. 122p

Theme: **interventional cardiology**

Country: **Macedonia**

Apert syndrome and ASD II in a Pediatric Patient – A Case Report

Stankovikj V¹, Al Soufi M², Jovanovska V¹, Kacarska R¹, Kuzevska-Maneva K¹, Gjurkova B¹, Nonkulovski D¹, Neshkovska-Shumenkovska M¹, Paskalov G¹, Shukarova-Angelovska E¹

University Children's Hospital, Skopje, Macedonia¹, Al Zahra Medical Centre, Dubai²

Background and aims: Apert Syndrome is a rare autosomal dominant disorder characterized by premature fusion of certain bones leading to craniosynostosis, craniofacial anomalies and severe symmetrical syndactily of the hands and feet. Importantly, it may be associated with diverse visceral anomalies. Methods: We present an 11 year-old child diagnosed with Apert Syndrome during infancy that ever since had been clinically followed up on a regular base at our clinic. During the most recent hospitalization, following detailed clinical, laboratory and echocardiographic evaluation, the child was additionally diagnosed with atrial septal defect secundum (ASD II). Results: A systolic ejection murmur had been noted during routine clinical examination in addition to mild cardiomegaly and increased pulmonary vascularity revealed by the patient's chest x-ray. Echocardiography confirmed presence of ASD II with the following dimensions: 16 mm x 12 mm with initial hemodynamic disturbances. The ASD in this patient was resolved by an interventional catheterization procedure consisting of a 20 mm-amplatzer septal device placement at the site of the defect. Early and late postoperative clinical and echocardiography evaluations revealed no complications and complete closure of the defect. The post-interventional treatment included antithrombotic prophylaxis with Aspirin. Following short post-operative hospitalization the child was discharged from the hospital clinically stable with no signs of infection. Conclusions: Anomalies of the cardiovascular and genitourinary tract were found to be most commonly associated with Apert syndrome. Therefore, careful clinical, radiologic and ultrasound evaluations followed by adequate treatment strategies should be included in the regular work up of all Apert newborn infants and pediatric patients.

Keywords: Apert Syndrome, ASD II and Catheterization

27

Abstract No. 125

Theme: **interventional cardiology**

Country: **Macedonia**

Percutaneous interventions of heart defects - short and mid-term results

**Milev I, Idrizi S, Zimbakov Z, Ampova V, Zafirovska P, Angjuseva T, Mitrev Z
Special Hospital for Surgical Diseases "Filip Vtori", Skopje, Macedonia**

AIM: Presentation of short- and mid-term results from the percutaneous interventional procedures in the treatment of congenital and acquired heart defects in our angiographic laboratory

MATERIAL AND METHODS: Between the period of 2003-2014, in our angiographic laboratory 390(225 female, 3months-60 years of age) patients with HD were treated. Dominant part of patients (165) were with atrial septal defect (ASD). Pulmonary stenosis(PS) was treated in 69 patients, patent ductus arteriosus(PDA) in 55 patients, persistent foramen ovale(PFO) in 36

patients, ventricular septal defect(VSD) in 32 patients, aortic coarctation(CoA) in 24, congenital aortic stenosis in 5 patients, mitral paravalvular leak in 5 patients and 2 patients with arteriovenous fistula. All of the patients were diagnosed with transthoracic and transesophageal echocardiography and in some of the patient multi sliced computer tomography (MSCT) was performed. In our study we assessed echocardiographic parameters before and after intervention, peri-interventional complications and clinical follow up of patients postinterventionally. During the interventions mainly occluding devices were used (ASD, VSD, PFO occluders) and in the stenotic lesions balloon catheters and CP Stents were used.

RESULTS: In 96% of the patients complete closure of the defects was succeeded. In 85% of patients with pulmonary stenosis a significant transvalvular pressure gradient reduction was accomplished. All of the patients with coarctation of the aorta had a successful stent implantation treatment and only one patient had unsatisfying result after balloon dilatation of the coarctation. Coronary fistulas were closed with no signs of residual flow. Paravalvular leaks were successfully treated in four patients and one patient had a complication with migration of the device that was surgically removed. Two of the patients with PVL died one week after intervention in the intensive care unit.

CONCLUSION: Short and mid-term results showed that percutaneous interventions for heart defects is efficient, safe and sutured procedure in selected patients with adequate anatomy of the heart defect.

Key words: heart defects, percutaneous treatment

28

Abstract No. 127 p

Theme: **interventional cardiology**

Country: **Macedonia**

A case of a 26-year old woman with ventricular septal defect and multiple peripheral stenosis of the pulmonary vasculature

Milev I, Zafirovska P, Shpend I, Zimbakov Z, Ampova V, Bozinovska B, Atanasov Z, Veljanovska L, Angjuseva T, Mitrev Z.

Special Hospital for Surgical Diseases “Filip Vtori”, Skopje, Macedonia

We present a case of a 26-year old woman that came to our hospital presenting with dyspnea (grade 3), fatigue, dizziness and pulse oximetry measuring 93% saturation. The initial echocardiogram revealed 10 millimeters perimembranous ventricular septal defect (VSD) with a left to right shunt and gradient of 40mmHg. Right ventricular dimensions were moderately increased with significant hypertrophy (10mm right ventricle free wall), and echo Doppler examination showed gradient of 90mmHg over the tricuspid valve. Multi-sliced computer tomography (MSCT) of the pulmonary vasculature showed significant multiple stenosis of the peripheral pulmonary arteries and consequent dilatation of the pulmonary trunk (33mm). Right heart catheterization was performed measuring right ventricular pressure of 95/18mmHg, the right pulmonary artery- 75/45mmHg and second and third branching arteries consecutive pressures of 52/35mmHg and 33/22mmHg. Careful assessment and conciliar analysis led to a decision for closure of the VSD, to achieve postponing right ventricular failure. The intervention was performed using percutaneous endovascular approach using 12 mm VSD septal occluder. One month after the procedure the patients follow up shows clinical improvement (dyspnea – grade 2) with measured 97% saturation with pulse oximetry.

Key words: ventricular septal defect, pulmonary stenosis, percutaneous catheter intervention

Transcatheter repair of paravalvular leaks in high risk patients: a single center experience

Milev I¹, Shpend I¹, Ampova V¹, Zimbakov Z¹, Zafirovska P¹, Angjuseva T¹, Mitrev Z¹, *Jaroslav J.²

Special Hospital for Surgical Diseases “Filip Vtori”, Skopje, Macedonia¹, Cardiovascular Center Brno, Agel Hospital group, Czech Republic²

Percutaneous interventional treatment of paravalvular leaks is complex procedure with variable patient outcome due to the category of patients (high risk patients with co morbidities) and the limited types of specific devices for this intervention.

Between the period of February 2011 and March 2014 in our angiographic laboratory five patients (male 80%, age 53±13) with mitral paravalvular leak were treated with device implantation (one atrial septal occluder, four ventricular septal occluders). All of the patients had previously surgically implanted mechanical mitral valve and two had a second reoperation.

Patients were in deteriorating clinical condition (NYHA III-IV, EF 30±15) due to paravalvular leak (9±2mm diameter) confirmed with transesophageal echocardiography(TEE). The procedure was performed in general anesthesia with 3D TEE guiding with complete closure of the mitral regurgitation (MR) in two patients and reduction to slight MR in three patients. We report one major early complication - embolization of the device, that was subjected to surgical intervention. Second patient died few days after the procedure due to hemolytic syndrome and liver failure. Other 3 (60%) patients had significant improvement of the clinical (NYHA II) and echocardiographic condition.

Transcatheter treatment is a reasonable method of choice for treatment of paravalvular leaks in critically ill and hi-risk patients.

Key words: paravalvular leak, transcatheter repair

Case of giant coronary fistula in a 6-year old girl: transcatheter closure with ante grade approach

Zimbakov Z¹, Milev I¹, Idrizi S¹, Ampova-Sokolov V¹, Zafirovska P¹, Angjuseva T¹, Mitrev Z¹, Januska S²

Special hospital for surgical diseases “Filip Vtori”, Skopje, Macedonia¹, Cardiovascular center Brno, Agel Hospital Group, Czech Republic²

We report a case of 6-year old female patient presenting with palpitation and heart murmur, misdiagnosed as ventricular septal defect in infancy and early childhood. Echocardiography reveals giant ostium of left main coronary artery (LMCA) and continuous flow toward coronary sinus with an intracardiac left to right shunt. Coronarography was performed revealing the giant (23mm in diameter) fistula of the left main coronary artery draining in to the coronary sinus and

right ventricle.

Percutaneous transcatheter closure was performed using a 6F Amplatz left guiding catheter for cannulating the fistula. Through hydrophilic Terrumo wire (0,035') catheter was deep engaged into the fistula, and an Amplatzer vascular plug II (AVP II) 10x7mm was implanted ante grade. After the intervention there was a reduction of the ante grade flow through the fistula with normal drainage of the coronary veins in to the coronary sinus, and normal flow in the LMCA. Patient is asymptomatic two years later and control angiography is without signs of persisting flow through the fistula and normal LMCA flow.

Key words: coronary fistula, transcatheter intervention

31

Abstract No. **130p**

Theme: **interventional cardiology**

Country: **Macedonia**

Pediatric interventional cardiology, diagnostics and therapeutics: Our experience

Jovanovska V.¹, Sofijanovska A.¹, Kacarska R.¹, Kuzevska Maneva K.¹, Gjurkova B.¹, Neshkovska-Shumenkovska M.¹, Spirovski I.², Nonkulovski D.¹, Stankovikj V.¹, Paskov G.¹

¹University Children's Hospital - Skopje ²University Clinic of Cardiology – Skopje

Pediatric interventional cardiology is used for both: therapeutics and diagnostics. Its role is constantly increasing nowadays thanks to the continuous development and improvement of the equipments, skills and different pediatric interventional techniques. Many congenital heart defects previously treated only surgically today can and currently are resolved completely in the cath-lab. Aim and methods: We present our experience in pediatric catheterization within the National project for the development of the neonatal and pediatric cardiac surgery. Until now total of 9 children with different congenital heart defects and of different age underwent cardiac catheterization. All of them were diagnosed by anamnesis, clinical examination and echocardiography. 3 of them underwent diagnostic catheterization: 1 before performing TCPC surgically, 1 before total correction of TOF and 1 neonate with complex cardiopathy for full diagnostics. 6 children underwent therapeutic procedures: 2 with closure of the ASD II and 1 with the PDA closure, with suitable Amplatzer devices. The rest of 3 children underwent balloon-dilatation because of severe PS. Results: All 9 procedures were without any complication during the catheterization, with only one child having short post procedural reaction. 5 of the children who underwent therapeutic catheterization are now completely cured; they'll only need periodical follow up. 1 child with PS was diagnosed with the anomaly of the peripheral left PA during the procedure and will need surgery in the future. 2 of the 3 children with the diagnostic catheterization underwent surgery afterwards, 1 will be operated in the future. Conclusions: interventional cardiac procedures are very useful for the treatment of many congenital heart defects but also necessary for the diagnostic and in decision making for the cardiac surgical procedures. Its role in the future will only increase, replacing the open heart surgeries with the minimal invasive procedures in the treatment of some congenital heart defects. Key words: congenital heart defects, pediatric catheterization, diagnostic and therapeutic procedures

32

Abstract No. 131p

Theme: **interventional cardiology**

Country: **Macedonia**

Percutaneous balloon valvuloplasty of pulmonary valve stenosis in adolescents and adults

**Idrizi S, Milev I, Ampova-Sokolov V, Zimbakov Z, Zafirovska P, Angjuseva T, Mitrev Z
Special Hospital For Surgical Diseases “Filip Vtori”, Skopje**

AIM: The aim of our study is to present our experiences and results of BVP of isolated moderate and severe pulmonary stenosis in adolescents and adults.

MATERIALS AND METHODS: During eleven year period (March 2003-March 2014) in our angiographic laboratory the procedure was applied in 16 patients(57% male) . All of the patients were with moderate and severe isolated pulmonary stenosis with transvalvular gradient of PG> 50 mmHg . Nine (56%) of the patients were adolescents(age 20±5), six(37%) patients were adults(age 37,5±12,5) and one(6%) patient was above 60 years of age. Follow up was performed monthly after the procedure and later on 12-month intervals, assessing echocardiographic and clinical parameters.

RESULTS: There was one unsuccessful treatment in a patient with dysplastic pulmonary valve and significant infundibular hypertrophy who was later subjected to surgical cardiovascular procedure. No major complications peri and post procedure were reported. During the procedure the pulmonary transvalvular pressure gradient was reduced by 30±15mmHg and follow up showed significant reduction of the right ventricular pressure by 50(±15) mmHg.

All of the successfully treated patients had significant clinical and echocardiographic improvement during the follow-up period.

CONCLUSION : Percutaneous balloon valvuloplasty is effective and safe procedure for the treatment of isolated pulmonary valve stenosis in adolescents and adults and is a promising alternative to surgical valvotomy.

Key words: pulmonary valve stenosis, percutaneous treatment, balloon valvuloplasty

33

Abstract No. 132p

Theme: **interventional cardiology**

Country: **Macedonia**

Stenting of aortic coarctation- method of choice in selective patients, a single center experience

Shpend I, Milev I, Atanasov Z, Zimbakov Z, Ampova V, Zafirovska P, Angjuseva T, Mitrev Z.

Special Hospital for Surgical Diseases “Filip Vtori”, Skopje, Macedonia

Percutaneous endovascular stent implantation for aortic coarctation is a well-established method of choice when there is feasible anatomy of coarctated area and peak-to-peak systolic gradient above or equal to 20mmHg.

During the period of March 2010 and March 2014, ten patients (male 70%; age 18, 4±3, 4) were treated with stent implantation of aortic coarctation. All of the patients were symptomatic, with arterial hypertension as the hall mark of the disease. Two (20%) of the patients had previous only transluminal angioplasty (PTA) performed in early childhood. Ninety percent of the patient had

bicuspid aortic valve and in one (10%) patient the disease was combined with patent ductus arteriosus. The average length of the coarctated segment was $8,6 \pm 3,9$ mm with mean systolic peak to peak pressure gradient of $56,8 \pm 17,7$ mmHg. Using long introducers (12-14F), balloon predilatation was performed in 6 patients (60%) and implantation of eight (80%) uncovered and two (20%) covered stents was done. Mean systolic peak-to-peak gradient immediately after the intervention was reduced by 30 ± 10 mmHg.

During the interventions there were two complications reported. One patient suffered aortic tear without dissection and post-interventional spontaneous recovery. In one patient post-interventional occlusion of the right femoral artery was noticed that was successfully resolved with surgical intervention seven days later.

Percutaneous endovascular interventional treatment with stent implantation is relatively safe and efficient procedure and should be the first line therapeutic choice for patients with isolated and short segmental aortic coarctation.

Key words: aortic coarctation, percutaneous endovascular procedure, endovascular stent implantation

34

Abstract No. **133** p

Theme: **interventional cardiology**

Country: **Macedonia**

High grade bilateral carotid artery stenosis in 62-year old patient

Ampova-Sokolov V, Milev I, Idrizi S, Zimbakov Z, Atanasov Z, Veljanovska L, Bozinovska B, Angjuseva T, Mitrev Z

Special hospital for surgical diseases "Filip Vtori", Skopje, Macedonia

Significant carotid stenosis can be a cause for ischemic stroke, transient ischemic attack or cognitive impairment. We present a 62-year old patient that came to our hospital complaining of frequent syncope that started two months ago but intensified the last three days. During the examination, the patient suffered another syncope that is presented with sudden loss of consciousness with the duration of 3-4 seconds. Ultrasound Doppler examination reveals high grade (>95%) stenosis of both internal carotid arteries. Multi-sliced computer tomography (MSCT) confirms the diagnosis verifying 95-99% stenosis bilaterally without any pathologic cerebral lesions. Indication for urgent carotid endarterectomy (CEA) was made. Left carotid artery was operated first with significant improvement of symptoms immediately after the intervention and the second CEA was performed 10 days later. At one year of follow-up period, the patient's clinical condition and ultrasound Doppler status is without pathological findings. Urgent treatment of significant bilateral carotid stenosis is of great importance and can be a life-saving procedure.

Key words: carotid artery disease, carotid endarterectomy, syncope

35

Abstract No. **135**

Theme: **interventional cardiology**

Country: **Macedonia**

Interventional Cardiology Registry 2008-2014

Kalpak O. , Antov S. , Pejkov H., Spiroski I., Kostov J., Kjaev M., Kedev S.

University Clinic of Cardiology Skopje

Over 20 000 patients, over 10 000 PCI; complete Cath-lab registry showing constantly growing

numbers of treated patients from year to year as we adopt radial instead of femoral artery approach. We started with total of 2000 patients and now we have almost 3 000 PCI and more than 5 000 patients for last year. Persistent up-climbing over the years.

36

Abstract No. **136** p

Theme: **interventional cardiology**

Country: **Macedonia**

Трансрадијален или трансфеморален пристап за примарни перкутани коронарни интервенции кај пациенти со акутен миокарден инфаркт со СТ-сегмент елевација

Камчева Г¹, Вавлукис М², Кедев С².

**Факултет за Медицински науки, Универзитет “Гоце Делчев”, Штип, Македонија¹
Универзитетска клиника за Кардиологија, Медицински факултет Скопје,
Македонија²**

Цел: Целта на иследувањето беше да се процени влијаните на „access site“, те. местото на пристап при изведување на перкутани коронарни интервентни процедури (ПКИ), врз краткорочниот клинички тек и исход кај пациентите со СТЕМИ миокарден инфаркт. Метод: Во иследувањето беа вклучени 206 пациенти со дијагностициран СТЕМИ во периодот од јануари 2008 до декември 2010, од источниот регион на Р. Македонија. Пациентите беа третирани со пПКИ со радијален (ТРА) или трансфеморален (ТФА) пристап. Пациентите беа поделени во две споредувани групи во зависност од пристапот на пункција (ТРА вис а вис ТФА). Беше следена појавата на перипроцедурални компликации од типот на: крварење на местото на пристапот, време на флуороскопија, должина на болничкото лекување и рана интрахоспитална смртност. Статистичката обработка беше направена со дескриптивна и споредбена статистика. За континуираните обележја t-test, додека за категоријските Chi square. Статистичката значајност беше дефинирана на ниво 0.05.

Резултати: Од вкупно 206 анализирани лица во периодот 2008-2010 година, кај 167 (81%) испитаници пристапот за интервенција бил трансрадијален (ТРА), додека кај 39 (19%) трансфеморален (ТФА). Со секоја наредна година, трансрадијалниот (ТРА) пристап статистички значајно се зголемува за сметка на трансфеморалниот (ТФА) (χ^2 -тест = 27,01; $df = 2$; $p = 0,000013$).

Перипроцедурални компликации се регистрирани кај вкупно 29 (14,1%) лица. Од нив, кај 25 (12,1%) се следи појава на локален хематом на место на пункција, и тоа кај 14 (8,4%) од 167 пациенти третирани со ТРА, и кај 11(28,2%) од вкупно 39 пациенти третирани со ТФА пристап (χ^2 -тест = 11,65 $df = 1$ $p = 0,000064$). Odds Ratio покажува дека ТРА пристапот го редуира ризикот за појава на локален хематом: OR = 0,23, 95% CI (0,09 - 0,62).

Релативниот ризик изнесува RR = 0,66 (95% CI 0,47-0,94) и покажува дека лицата со ТФА пристап имаат за 0,66 пати поголем ризик да добијат компликации во споредба со лицата каде пПКИ е работена со ТРА пристап. Кај пациентите третирани со ТРА пристап, времетраењето на процедурата е значајно пократко (Mann-Whitney U test: $Z = - 3,05$ $p = 0,0022$). Не беше регистрирана значајна асоцираност на пристапот за пункција со раниот хоспитален морталитет (Fisher exact test: $p = 0,4289$). Флуороскопијата кај нашите испитаници траела просечно 10 +/- 7,7 минути.

Заклучок: ТРА пристапот е побезбеден, споредено со ТФА пристапот. Се одликува со помал ризик од васкуларни компликации на местото на пункција, како и со значајно пократко време на експозиција. Но, независно од тоа за коку е намален ризикот од компликации, од особена важност е наодот дека местото на пристап само посебе не покажа влијание врз раниот хоспитален м орталитет.

Keywords: перипроцедурални компликации, акутен миокарден инфаркт со СТ-сегмент елевација, трансрадијален пристап

37

Abstract No. 141 p

Theme: **interventional cardiology**

Country: **Macedonia**

A CASE REPORT OF CAROTID ARTERY STENTING AFTER RECANALIZATION OF TOTAL OCCLUSION

Lazarova Trajkovska E.¹ Kede S.¹

University Clinic of Cardiology, Skopje¹

PURPOSE:

To present a case of carotid artery stenting of completely occluded carotid artery once recanalization occurs.

METHODS AND RESULTS:

A 70-year-old woman with a history of hypertension and hyperlipidemia (non-smoker, positive family history of coronary artery disease), admitted to cardiac intensive care unit because of inferior acute myocardial infarction and third degree atrioventricular block, treated with percutaneous coronary intervention with stent placed in right coronary artery and temporary placement of pacemaker. During hospitalization, the patient developed a new onset of ischemic cerebrovascular insult with a left-sided hemiparesis due to total occlusion of right medial cerebral artery on computed tomography angiography (CTA). During one year follow up, she presented with couple of transient ischemic attacks without CT evidence of a new ischemic lesion, but with occlusion of left internal carotid artery (ICA) and no significant stenosis of right ICA on CTA, confirmed by carotid angiography. Three years later, a carotid doppler ultrasound was performed that identified almost complete occlusion with minimal recanalization of previously completely occluded left ICA and non-significant right ICA stenosis that prompted carotid artery stenting (stent: Xact 8-6/30mm, balloon pre-dilatation 2.5/20mm). The patient remained asymptomatic at six month follow-up after the stent was placed.

CONCLUSIONS:

Percutaneous carotid stenting may be feasible in appropriately selected symptomatic patients even with a complete occlusion once they demonstrate a recanalization. Doppler ultrasound is an adequate non-invasive procedure for diagnosis and follow-up of carotid artery disease.

Keywords: carotid artery stenting

38

Abstract No. **142**

Theme: **interventional cardiology**

Country: **Macedonia**

Прием на болен со акутен инфаркт на миокардот

Весна Митревска

Универзитетска Клиника за Кардиологија-Скопје, Македонија

Во коронарната единица сестрата го прима пациентот, веднаш го приклучува на монитор, мери притисок, пулс, дишење, воспоставува венска линија, зема крв за лабораториски анализи. Потоа ја спроведува одредената терапијата на пациентот назначена од докторот. Бара брза информација за резултатите од лабораторијата за што го известува и докторот. Најнапред се смирува болката на пациентот со аналгетици, седативи или нитро препарати. Веднаш се дава Aspirin кој по протокол треба да се изцвака, потоа се спрема Heparin и/или тромболитична терапија ако пациентот одбие интервентна процедура. Доколку пациентот прифати коронарофрагија се повикува екипата за интервенција. Докторот му ја објаснува потребата од оваа интервенција на пациентот. Сестрата го припрема пациентот кој за половина час треба да биде спроведен во сала. Таа го спроведува пациентот до салата за интервенции, му помага на пациентот да легне. Сестрата го приклучува на EKG апаратот, со електроди за да може постојано да се прати работата на срцето. Интервенцијата се изведува во строго стерилни услови за кои се грижи сестрата. Се дава локална анестезија, пациентот за цело време е свесен и буден. Сестрата внимава на стерилноста во текот на интервенцијата. По завршената интервенција сестрата го контролира пациентот, ги мери витални знаци, прави преврска на местото на интервенцијата и го следи пациентот по интервенцијата. Го запознава пациентот со понатамошниот тек на третманот, му ги воочува сите ризик фактори кои можат да ја влошат неговата неговата состојба. Улогата на медицинската сестра при приемот на болните со инфаркт и спроведувањето на терапијата, како и во спроведувањето на инвазивните дијагностички процедури е голема.

39

Abstract No. **147**

Theme: **interventional cardiology**

Country: **Macedonia**

Улогата на медицинската сестра/техничар при апликација на РеоПро

Игор Стојановски

Универзитетска Клиника за Кардиологија-Скопје, Македонија

Воведувањето на стентот преставува револуција во интервентната кардиологија. Паралелно со технолошкото усовршување на дизајнот и материјалот од кои се изработуваат стентовите се работело и на пронаоѓање на соодветен фармколошки препарат кој ќе ја оневозможи активацијата на тромбоцитите како механизам кој доведува до тромбозирање на стентот. Со воведувањето на срцевата катетеризација кај пациенти со миокарден инфаркт потврдено е дека токму тромбозата е причина за настанување на миокарден инфаркт. Голем број на студии покажале дека врзувањето на фибриногенот за тромбоцитите игра клучна улога во процесот на тромбоцитната агрегација т.е. до процесот кој води до појава

на тромбоза.

Специфичните антитела GpIIb / IIIa рецептори биле пронајдени преку имунизација на глумци со хумани тромбоцити. Од големиот број на клонови кои биле идентифицирани, клеточната линија 7E3 била избрана за понатамошна студија. Многу преклинички студии ин витро и ин vivo биле изведени за да се одредат карактеристиките на 7E3 антителото и неговите фрагменти да се одреди нивната сигурност и да се одредат режимите за дозирање.

Сите овие студии воделе до развој на еден нов антиромботичен фармаколошки препарат - Absiximab(Рео про).РеоПро е пакуван како раствор од 5мл во тип и боросиликатна стаклена вијала со тефлонски обложен гумен затварач,и алуминиумска обвивка затворена со пластично капаче. Една вијала е спакувана во картонска кутија.

А) Фармакокинетики и фармакодинамика на Absiximab(Рео про).

Absiximab преставува Фаb фрагмент од химеричното моноклонално антитело 7E3. За продукција на Absiximab химеричното 7E3 антитело се обработува со проеолитичен ензим-папин за да се добие Фаb фрегментот. Биле направени неколку студии за да се одредат релативните особини на 7E3 антителото и неговите фрагменти од останатите хумани тромбоцити. Податоците покажале дека 7E3 JгГ антителото и ц7E3 Фаb (Absiximab) се врзуваат со висок афинитет за 80.000 GpIIb / IIIa молекули на секој тромбоцит. Врзувањето на с7E3 е брзо и резултира со доза-зависна инхибиција на тромбоцитната агрегација. Тромбоцитната инхибиција се појавува независно од стимулсот кој се употребува за тромбоцитната агрегација: АДП,колаген,епинеафрин или арахидонска киселина.

Патиштата на тромбоцитна активација завршуваат на како финале заеднички чекор кој доведува до тромбоцитна агрегација. Поради тоа врзувањето на Absiximab за GpIIb / IIIa рецепторот ја превенира тромбоцитната агрегација и формирањето на тромб. И покрај силната инхибација на тромбоцитната агрегација,Absiximab нема особина за инхибација на можност на тромбоцитите за интерреакција во единечниот слој на уништените крвни садови. Absiximab се врзува со висок афинитет за интактниот GpIIb / IIIa ,кој е член на интегринската фамилија на адхезионите рецептори и главниот рецептор на површината на тромбоцитот кој е вклучен во тромбоцитната агрегација. Absiximab ја инхибира агрегацијата на тромбоцитите со превенција наврзување на GpIIb / IIIa. Јакиот анти-ромботичен фармаколошки препарат абцицимаб покажа особина да го намали ризикот од смрт за околу 30% кај пациенти кај кои се извршува перкутана коронарни интервенции вклучувајќи ги балон ангиопластиката,поставување на стент или атеректомија.

40

Abstract No. 152 p

Theme: **interventional cardiology**

Country: **Macedonia**

Кардиоваскуларни манифестации кај миелопролиферативни заболувања Приказ на случај - Коронарна артериска болест како прва манифестација на Полицитемија рубра вера

Др. Николов Горан, Др. Врчаковска Маја, Др. Трајковски Горан

Институција: ПЗУ “Центар за внатрешни болести – СРЦЕ”

Миелопролиферативните заболувања, а особено полицитемија рубра вера доведуваат до кардиоваскуларни инциденти поради предиспозиција кон тромбоза. Во основата на

тромбогенезата лежат повеќе патофизиолошки феномени како: промени во хемореолошките својства на крвта, еритроцитоза, квантитативни и квалитативни промени во тромбоцитите и останати претпоставени механизми. Акутните коронарни синдроми често се појавуваат кај пациенти без познати ризик фактори и со нормални крвни садови. На досегашните аутопсии на коронарните крвни садови не се докажани атеросклеротски промени, ниту тромботични оклузии. Наместо тоа откриена е значајна интимална пролиферација која доведува до мултипли оклузии, но со интактни медија и адвентиција на крвниот сад и се смета дека овој механизам на васкуларна оклузија е алтернативен механизам кај полицитемија вера.

Приказ на случај: Пациентка на 57 годишна возраст, без познати ризик фактори за кардиоваскуларна болест. Поради појава на акутен коронарен синдром направена коронарна интервенција-стентирање на левата десцендентна коронарна артерија, а после 5 месеци рестентирана поради инстен стеноза. 2 години после интервенцијата за прв пат е детектирана тромбоцитоза, а веќе наредната година поставена дијагноза на полицитемија рубра вера.

Заклучок: Коронарната артериска болест може да биде прва манифестација на полицитемија рубра вера.

Keywords: миелопролиферативни заболувања, полицитемија вера, коронарна болест

41

Abstract No. **152p**

Theme: **Интервентна кардиологија**

Country: **Macedonia**

Cardiovascular manifestations of myeloproliferative disorders Case report – Cardiovascular disease is most common and may be the first manifestation of polycythemia rubra vera

Nikolov Goran, MD, Vrcakovska Maja, MD, Trajkovski Goran, MD

Institution: Centre for internal diseases “SRCE”

Myeloproliferative disorders, especially polycythemia rubra vera have been long recognised to predispose to thrombosis. The pathophysiology of thromboembolic events have not been elucidated, but many factors are involved: hemorheologic changes, erythrocytosis, quantitative and qualitative platelet abnormalities and other possible mechanisms. Acute coronary syndromes are often in patients with myeloproliferative disorders without cardiovascular risk factors and with normal coronary arteries. On autopsy the vessels showed neither atherosclerotic changes, nor thrombotic occlusions. Instead, a marked intima proliferation was found leading to multiple occlusions whereas media and adventitia were unchanged. This pattern could be interpreted as alternative mechanism for vascular occlusion in polycythemia.

Case report: The case concerns a woman, 57 years old, without known cardiovascular risk factors. Because of acute coronary syndrome a percutaneous coronary intervention-stenting to left anterior descendent artery was performed, and after five months restenting was done because of instent stenosis.

Two years after the intervention a thrombocytosis was detected for the first time, and the next year polycythemia rubra vera was diagnosed.

Conclusion: Coronary artery disease may be the first manifestation of polycythemia rubra vera.

42

Abstract No. 154

Theme: **interventional cardiology**

Country: **Macedonia**

STENTING OF CHRONIC TOTAL OCCLUSION OF ILIAC ARTERY THROUGH TRANSRADIAL APPROACH

Antov S.¹, Kedev S.¹, Vasilev I.²

¹ **University Clinic of Cardiology, Medical Faculty, University of St Cyril and Methodius, Vodnjanska 17, 1000 Skopje, Macedonia,** ² **Clinical hospital-Bitola,**

PURPOSE: The aim of the study is to show the safety and efficacy of transradial approach (TRA) for treating complex iliac lesions.

METHODS: TRA for treatment of aortoiliac occlusive disease (AIOD) nowadays is more common approach in order to achieve less post-procedural bleeding complications and low mortality. For a period of one year 13 patients (10 male and 3 female with mean age 58,7) with severe iliac disease were treated. Four patients had critical limb ischemia and nine patients had limiting claudications. Present risk factors were: hypertension, hyperlipidemia, smoking and diabetes. Ankle brachial index (ABI) before treatment in all patients was less than 0.5. Eleven patients were in Rutherford Class 3, and two in Rutherford Class 4. According TASC II classification 1 patient was with type D lesion, 4 with type C and 8 with type B.

RESULTS: The interventions were performed using short 6F hydrophilic introducers. Diagnostic peripheral angiogram was done with Pig-tail or Multipurpose 125cm catheters. Guiding catheter 6F MB 125cm was inserted as close as possible to the origin of treated common iliac artery. For crossing the occlusion, coronary CTO wires were used. In two cases we used 0,035" stiff glide wire. After pre-dilatation wires were exchanged with stiff 0,035" 260cm wire. We deployed 15 balloon-expandable and 3 self-expandable stents. In all cases after stent deployment, balloon post-dilatation was done. Procedures were ended with control angiograms. Despite some difficult lesions (TASC II C/D) the overall primary procedural, technical success and acute patency rate was 100%. The secondary patency rate after 3 months follow-up was also 100%. The ankle brachial index (ABI) significantly improved from a mean of 0.46 to 0.90 and 0,94 on three months follow-up. Minor or major complications (hematoma, distal embolization, dissection, rupture, death) were not documented.

CONCLUSION: TRA is safe and efficient for treating complex proximal iliac lesions with low major and minor complications if performed by experienced radial operator. This technique is still limited by the lack of adequate equipment.

Keywords: transradial approach, stenting, peripheral vascular disease, iliac artery occlusion, endovascular interventions

43

Abstract No. 155

Theme: **interventional cardiology**

Country: **Macedonia**

COMPARISON OF TRANSRADIAL VERSUS TRANSFEMORAL APPROACH FOR PRIMARY PCI IN DIABETIC PATIENTS WITH ST-ELEVATED ACUTE MYOCARDIAL INFARCTION

S Antov,¹ O Kalpak,¹ R Sukmawan,^{1,2} J Kostov,¹ I Spiroski,¹ H Pejkov,¹ S Kedev¹
¹ University Clinic of Cardiology, Medical Faculty, University of St Cyril and Methodius,
Vodnjanska ¹⁷, ¹⁰⁰⁰ Skopje, Macedonia

PURPOSE: The aim of the study is to compare the outcome of transradial access (TRA) vs. transfemoral access (TFA) in primary percutaneous coronary intervention (PPCI) for ST elevation myocardial infarction (STEMI) in diabetic patients. Artery access change towards TRA was observed, as potentially beneficial strategy to improve outcomes of intervention for STEMI patients with diabetes.

METHODS: The data of diabetic acute STEMI patients that underwent PPCI were analyzed during transitional access period from default TFA to TRA, within the year of 2007 to 2010. The registry recruited all-comers patients regardless of presentation in acute STEMI. Major bleeding complications, early death rates, and overall MACE rates (composite of death, stroke, re MI and TVR) after 2 years follow-up were compared between TRA and TFA.

RESULTS: There were 364 diabetic patients (age range 43 to 86 years) out of 1808 patients that underwent PPCI in STEMI during that period. Interventions were successfully done in 236 with TRA artery access and 128 with TFA. The 30-days and 1 year mortality rates were lower in TRA compared to TFA (6.4% vs 17.2%, p = 0.001, and 8.5% vs 18.8%, p=0.004, respectively). The 30 days and at 2 years follow-up, MACE rates were favorable for TRA vs TFA group (9.7% vs 18.8%, p=0.021 and at F-up 25.4% vs 35.2%, p=0.034 respectively). The major bleeding and non-CABG bleeding rates were more favorable for TRA than TFA (3.4% vs 13.3%, p<0.001, and 1.3% vs 9.4 %, p=0.001, respectively). The invariable and stepwise multivariable Cox-regression analysis was performed, adjusted hazard ratio was calculated and adjusted Kaplan Meier curves were created.

CONCLUSION: Transradial access strategy for primary coronary intervention is associated with significant early and two years mortality and MACE rate reduction comparing to transfemoral access strategy for primary coronary interventions in diabetic STEMI patients.

Keywords: Transradial, STEMI, diabetic

44

Abstract No. **156** p

Theme: **interventional cardiology**

Country: **Macedonia**

TUMOR NECROSIS FACTOR ALPHA (TNF- α)-PREDICTOR OF LEFT VENTRICULAR DYSFUNCTION

Hristo Pejkov⁽¹⁾, Sasko Kedev⁽¹⁾, Elizabeta Srbinovska-Kostovska⁽¹⁾, Saso Panov⁽²⁾, Slobodan Antov⁽¹⁾, Jorgo Kostov⁽¹⁾, Oliver Kalpak⁽¹⁾, Igor Spiroski⁽¹⁾, Irene Lang⁽³⁾

¹. University Clinic of Cardiology, Medical Faculty – Skopje, University Ss. Cyril and Methodius, Macedonia, ². Laboratory of Molecular Biology and Genetics, Faculty of Natural Sciences – Skopje, University Ss. Cyril and Methodius, Macedonia, ³. Cardiology Clinic, AKH – Vienna, Medical University Vienna, Austria

Introduction. Inflammation has a main role in the pathogenesis of atherosclerosis, as well as in the development, rupture and renewing of the atherosclerotic plaque. Tumor necrosis factor alpha (TNF- α) is pro-inflammatory cytokine and is secreted by the activated macrophages and T cell and takes part as a mediator of vascular inflammation. Although there is evidence that

production of TNF- α is increased in unstable atherosclerotic plaques and its concentrations are raised in patients with acute myocardial infarction, the role of TNF- α as predictor of outcome in these patients is still controversial.

Methods. The study consisted of 38 patients with STEMI treated with PCI and manual thromb aspiration and was designed to evaluate the influence of TNF- α in development of LV dysfunction. The levels of TNF- α were determined by bioassays from the samples of peripheral and intracoronary blood. Blood samples were taken during the PCI and thromboaspiration for STEMI and at 6 months follow up. Transthoracic echocardiography (TTE) was performed after PCI and at 6 months follow – up to assess changes in left ventricular (LV) structure and LV function through measurement of LVEDd, LVED vol, LVEDs, LVES vol, EF and global strain.

Results. The levels of TNF- α in intracoronary samples were significantly higher 60.4 ± 11.5 pg/ml compared with levels of TNF- α in the peripheral blood 54.6 ± 13.6 pg/ml ($p < 0,01$). At 6 months follow up the differences between values of TNF- α in peripheral and intracoronary samples (35.1 ± 21.5 pg/ml vs 45.3 ± 20.0 pg/ml) were also statistically significant ($p < 0,01$).

Results obtained from echocardiography revealed that high levels of significant TNF- α correlate with decrease of EF and global longitudinal strain of left ventricle ($p < 0,01$).

Conclusion The results of our study shown that acute myocardial infarction correlate with rise of levels of circulating TNF- α which contribute to adverse left ventricular remodeling leading to left ventricular dysfunction. TNF- α could be used as predictor of outcome and possibility of development of heart failure in STEMI patients.

Keywords: TNF- α , heart failure, acute myocardial infarction

45

Abstract No. **157**

Theme: **interventional cardiology**

Country: **Macedonia**

Acute heart failure in the context of acute coronary syndrome (a case report)

Vavlukis M¹, Pocesta B¹, Spirovski I¹, Caparovska E¹, Shehu E¹, Taravari H¹, Kotlar I¹, Kitanovski D¹, Bojkovski I¹, Jovanovska I¹, Janusevski F¹, Kedev S¹¹

University Clinic of Cardiology¹, Medical Faculty, Skopje

Right ventricular infarction (RVMI) is associated with acute STEMI myocardial infarction of the inferior wall of the left ventricle, and occurs in 30 to 50 percent of such cases. This condition is associated with higher in-hospital morbidity and mortality compared to patients with a similar infarction territory in the left ventricle. Poor outcome is related to profound hemodynamic and electrical complications, which occur in approximately 50 percent of patients. However, long-term prognosis is generally good for those who survive the event. Urgent revascularization is a major component of therapy for patients presenting with STEMI, and is particularly important for those with HF. But, in the situations of myocardial stunning resulting with heart failure after successful PCI revascularisation, IABP may be the bridge to functional recovery of ischemic but viable myocardium.

We are presenting a case of 62 years old male without known previous history of CAD. Risk factors for CAD - smoking. He was admitted to hospital with chest pain and ECG signs consistent with STEMI on the inferior wall, and in the same time A-V dissociation of third

degree and severe hypotension. Immediate primary PCI was performed (imbedded two BMS (bare metal stents)), accompanied with thromboaspiration, and application of potent triple, antiplatelet/ antithrombotic therapy. But as the patient remained in cardiogenic shock during and after the procedure, IABP was pleased, in adjunction to inotropic agents and diuretic therapy. ECG and echocardiography were conclusive for myocardial infarction on the right ventricle. Coronary arteriography detected severe stenosis of the LAD that can explain the added effect on RCA occlusion. Patient recovery was slow, he stayed in the ICCU until hemodynamically stabile (4 days and that transwrd to the word.

Keywords: acute heart failure, acute coronary syndrome

46

Abstract No. **159**

Theme: **interventional cardiology**

Country: **Macedonia**

Bioresorbable vascular scaffolds implantation in patients with acute coronary syndrome

Kostov J, Davceva-Pavlovska J, Antov S, Kalpak O, Pejkov H, Spiroski I, Kedev S
University Clinic of Cardiology, Medical Faculty, University St.Cyril and Methodius,
Majka Tereza^{17, 1000} Skopje, Macedonia

Background: The term acute coronary syndrome (ACS) refers to any group of clinical symptoms compatible with acute myocardial ischemia and includes unstable angina (UA), non-ST-segment elevation myocardial infarction (NSTEMI), and ST-segment elevation myocardial infarction (STEMI). These high-risk manifestations of coronary atherosclerosis are important causes of the use of emergency medical care and hospitalization. High-risk patients with UA/NSTEMI are often treated with an early invasive strategy involving cardiac catheterization and prompt revascularization of viable myocardium at risk. Transradial approach has important impact in reduction of bleeding and vascular complications. We evaluated the feasibility and the acute performance of the everolimus-eluting bioresorbable vascular scaffolds (BVS) for the treatment of patients presenting with ACS.

Methods and results: The present investigation is a prospective, single-centre study, reporting data after BVS implantation in patients presenting with ACS. Clinical outcomes are reported at the 30-day and 6-month follow-up. Quantitative coronary angiography and optical coherence tomography (OCT) data were also evaluated. The intent-to-treat population comprises a total of 7 patients. The procedural success was 100.0%. In all patients BVS were implanted on left anterior descending artery (LAD). Pre-procedure TIMI-flow was 0 in 42.9% of the patients. After the BVS implantation a TIMI flow 3 was achieved in 100.0% of patients and the post-procedure percentage diameter stenosis was 16.2 +/- 9.1%. No patients had angiographically visible residual thrombus at the end of the procedure. OCT analysis was performed in 5 patients (72.4%) showed that the post-procedure mean lumen area was 7.92 +/- 1.86 mm², minimum lumen area 5.54 +/- 1.60 mm². At the 30-day and 6-month follow-up, target-lesion failure rate was 0%. Non-target vessel revascularization and target vessel myocardial infarction (MI) were not reported. No cases of cardiac death or scaffold thrombosis were observed.

Conclusion: BVS implantation in patients presenting with ACS appeared feasible, with high rate of final TIMI-flow III and good scaffold apposition. Larger studies are currently needed to confirm these preliminary data.

Keywords: Bioresorbable vascular scaffolds, Acute coronary syndrome, Optical coherence tomography

47

Abstract No. **160p**

Theme: **interventional cardiology**

Country: **Macedonia**

Temporary transvenous pacing and thrombolytic therapy in the setting of bradyarrhythmias complicating acute myocardial infarction

F.Janushevski

University Clinic of Cardiology- Skopje

Introduction: Bradyarrhythmias arising in the setting of myocardial infarction (MI) occur in 25% to 30% of patients with acute myocardial infarction (AMI) and result from abnormalities either of impulse formation (i.e., automaticity) or of impulse conduction. In most cases, these abnormalities are due to myocardial ischemia or infarction with necrosis of the cardiac pacemaker sites or conduction system. Other factors responsible for these Brady arrhythmias include altered autonomic influence, systemic hypoxia, electrolyte disturbances, acid–base disorders, and complications of various medical therapies.

Case description: A 70 year old woman, within 2 hours of the onset of chest pain, was admitted in the emergency room, with ECG signs of acute inferior myocardial infarction and complete atrioventricular block with heart rate 30 beats in minute. She was hemodynamically unstable, with slow inadequate respirations, filiform pulsations on carotid vessels and almost immeasurable tension. During the transport to the hospital she had transitory loss of conscious and received 2 mg of atropine intravenously. Immediately on admission, a transvenous pacemaker was inserted using infraclavicular approach through left subclavian vein, with pulse frequency of 70 beats per minute. Inotropic stimulation with dopamine and thrombolytic therapy was included. The patient had remarkable progression in clinical status and hemodynamic parameters. In less than 48 hours after admission the normal heart rhythm has restored. On the 4 day a Trans radial PCI approach was made and BMS was implanted on the right coronary artery.

Discussion: Transvenous pacing combined with adequate thrombolytic therapy showed improvement in treatment of bradyarrhythmias complicating acute myocardial infarction in coronary care units.

Keywords: temporary transvenous pacing; thrombolytic therapy; myocardial infarction; bradyarrhythmia

48

Abstract No. **161**

Theme: **interventional cardiology**

Country: **Macedonia**

Retrograde Recanalization of Radial Artery Occlusion in Patients with Need for Repeated Wrist Procedure

Igor Spiroski, Sasko Kedev

Laboratory for Interventional Cardiology, University Clinic of Cardiology, Faculty of

Medicine, St. Cyril and Methodius, University of Skopje, Republic of Macedonia

PURPOSE: To present a technique of retrograde recanalization of radial artery occlusion with and without balloon dilatation in patients with need for repeated wrist procedure.

METHODS: In our transradial registry during the period of March 2011 – June 2013, we have documented 10,487 transradial procedures. In 317 patients we have found radial artery occlusion (RAO). In 281 ipsilateral transulnar approach (TUA) was performed. We selected the other 36 consecutive patients for retrograde recanalization of RAO. The selected patients were either with present ipsilateral ulnar occlusion or contralateral wrist approach was not available. We performed retrograde recanalization of RAO in 14 patients with balloon dilatation and in 17 patients (from our early practice) without balloon dilatation. In 5 patients (14%) we didn't manage to cross the occluded segment with the wire. Primary outcome was successfully completed procedure. Secondary outcomes were procedural complications: forearm pain, access site bleeding events, clinically evident hand ischemia. Patients with documented anatomic variations of radial artery from previous transradial procedure, such as tortuosity of the vessel and high take off, were excluded from this group. All patients had palpable pulse distal of previous puncture site. We've punctured the radial artery with an inner metallic needle and a plastic cannula. Using radial angiography performed with plastic cannula, we were able to go through the occluded segment with different types of guide wires. After the balloon dilatation, successful catheterization and/or percutaneous coronary intervention were achieved.

RESULTS: The primary outcome was achieved in 26 of 31 patients (83.9%). In patients where we performed balloon dilatation, the primary outcome was achieved in 14 of 14 patients (100%). Forearm pain was present in 13 cases (41.9%). Minor access site bleeding occurred in 5 patients (16.1%) and there was no single case of clinically evident hand ischemia.

CONCLUSION: Retrograde recanalization of the radial artery occlusion is safe and feasible. Balloon dilatation of radial artery occlusion is a key factor for successful catheterization and/or percutaneous coronary intervention. Left TRA or TUA remain a viable option in selected patient.
Keywords: Retrograde recanalization, radial artery occlusion (RAO), trans radial approach (TRA), ipsilateral transulnar approach (TUA)

49

Abstract No. **164** p

Theme: **interventional cardiology**

Country: **Macedonia**

Simultaneous percutaneous treatment of aortic coarctation and patent ductus arteriosus: presentation of two cases

Kostova S, Stojanova V, Rusevska S, Veselinov B, Manailov M, Milev I, Idrizi S, Ampova V, Zimbakov Z, Mitrev Z.

Special Hospital for Surgical Diseases “Filip Vtori”, Skopje, Macedonia

Aortic coarctation is a congenital malformation that can present together with patent ductus arteriosus. Here we present two cases of percutaneous simultaneous intervention for the combined disease.

The first case is a 21- year old female patient that presented with severe headaches due to hypertension. Echocardiographic examination revealed left ventricular hypertrophy, severe coarctation of the descending aorta and mild patent ductus arteriosus (PDA). Multi sliced computer tomography (MSCT) confirmed the diagnosis, after what decision for interventional

treatment was done. Percutaneous transcatheter approach was used with direct implantation of covered stent on the coarctated segment closing the PDA at the same time. The pressure gradient between the ascending and the abdominal aorta was equalized after the intervention with good clinical and echocardiographic status even three years later.

In the second case we present 3-year old girl presenting with repetitive pulmonary infections, dyspnea, high blood pressure and weak arterial pulsations over the lower limbs. After echocardiographic suspicion, MSCT was performed revealing severe coarctation of the aorta with moderate to severe PDA and consecutive pulmonary volume overload. Percutaneous transcatheter balloon dilatation was performed with a drop of the trans aortic gradient for over 50%. After, a transvenous retrograde approach was used to close the PDA with the implantation of an asymmetrical ventricular septal defect occluder with equaling of blood pressure curves in ascending aorta and femoral artery. Twenty four hours later the patient was discharged with good clinical and echocardiographic status. Further follow up will be needed. Percutaneous transcatheter intervention for combined aortic coarctation and patent ductus arteriosus is safe and effective procedure with minimal invasiveness and short hospitalization period.

Keywords: interventional treatment, patent ductus arteriosus, aortic coarctation

50

Abstract No. **165**

Theme: **interventional cardiology**

Country: **Macedonia**

Navigation through a challenging radial anatomy

Boshev M¹, Kedev S¹, Antov S¹, Kostov J¹, Pejkov H¹, Kalpak O¹, Spiroski I¹

University Clinic of Cardiology Skopje, Macedonia¹

Introduction: Transradial access (TRA) has demonstrated several significant benefits over the transfemoral access (TFA). This has led to an extensive experience with TRA worldwide. The benefits of TRA, however, are tempered by an increase in operator's technical demand. One aspect of the TRA that requires serious technical consideration is the occasional difficulty encountered when navigating the vasculature between the point of access (radial artery) and the aorta. Materials and methods: Performing retrograde angiography of the forearm via TRA is the first important advice we recommend in order to get a complete picture of its vascular network and prevent possible complications. Arterial impediments can be categorized in congenital, functional, traumatic, and acquired. Angiography can clearly delineate the cause and arterial level of the impediment and allows creating a specific treatment plan. Some of the techniques to overcome the obstacles include use of hydrophilic introducers, spasmolytic cocktails, different kinds of hydrophilic wires, low profile catheters as well as specific techniques like "push-pull" and "clockwise-counterclockwise" maneuvers.

Conclusion: A default TRA is feasible in routine practice after appropriate operator's training which is associated with certain learning curve. Although right TRA cases can be usually successfully completed, they are extremely challenging and in some cases alternative arterial access site (contralateral TRA, transulnar – TUA, or TFA) may need to be considered. Better results with TRA are expected with increasing procedural volume of operators.

Keywords: transradial access, radial artery, challenging anatomy

51

Abstract No. **166**

Theme: **interventional cardiology**

Country: **Macedonia**

Radial artery anomalies-variations

Jovkovski A¹, Zafirovska B¹, Kedev S¹

Univercity Clinic of Cardiology, Skopje¹

Objective. The aim of this abstract is to present different variations of radial artery anomalies and management of these variations in our centre. Radial artery anomalies can contribute to failure of performing coronary angiography through transradial approach.

Background. TRA is associated with substantially lower bleeding complications than TFA, but technically is a more challenging approach mostly due to anatomic anomalies on the arteries of the arm to the aorta, which may influence the success rate of transradial angiographic diagnostic and interventional procedures. In high volume transradial centers with experienced transradial operators the number of cases with transradial access failure is much lower than in other centers.

Methods. We analyzed data from 10502 consecutive transradial procedures. Radial artery angiography was done in all patients. Patients data, radial artery anatomy and access site bleeding complications were studied. Primary end-point of the study was occurrence of transradial approach failure and need to crossover to another approach in order to finish the procedure.

Results. Anatomical variants were present in 1114 (10.5%) patients. Most frequent variant was high-bifurcating radial artery origin from the axillary and brachial arteries in 733(6,6%) patients, 105(1,0%) had a full radial loop, 152 (1,4%) had extreme radial artery tortuosity, 17(0,16%) had hypoplastic radial artery, 113(1,0%) had tortuous brachial, subclavian and axillary arteries. Anomalies of the aortic arch (arteria lusoria) were present in 6 cases (0.05%). From 1114 patients with anatomic variants, failure in primarily chosen access site occurred in 52 (4,7%). We had successful crossing of anatomical variants in 1062 patients (95, 3%). Highest incidence of cross-over rate was present in the patients with complex radial artery loop 23 (22 %). All other TRA procedures were successfully done through the primary chosen transradial access site with overall procedural success rate of 99, 4% in 10450 patients.

Conclusion. Failure of transradial procedures is associated with anatomical variants located from wrist to aorta. Pre-procedural radial artery angiography gives the operator a chance to successfully plan the strategy for crossing the anomaly. High volume transradial centers with experienced transradial operators can successfully pass through these anomalies and have a lower transradial failure rate.

52

Abstract No. **167**

Theme: **interventional cardiology**

Country: **Macedonia**

Transradial carotid artery stenting

Vasilev I¹, Kedev S¹

University clinic of cardiology, Skopje¹

Background: Recently carotid artery stenting (CAS) has been established as safe and effective treatment in symptomatic patients with moderate and severe stenosis or in asymptomatic patients

with severe stenosis of the internal carotid artery(ICA).The feasibility of the transradial approach in carotid artery stenting has been shown. Radial access is particularly indicated in patients with extensive peripheral vascular disease and patients who have anatomic variations that make cannulation of the common carotid difficult from the femoral approach. An important benefit of the transradial approach is reduction of bleeding and vascular complications. It also offers the advantage of possibly reducing catheter-induced embolization from the aortic arch because transradial catheters do not traverse this area. The purpose of this report is to evaluate the right radial approach (RRA) for CAS. Methods: We performed a retrospective analysis of the data of all patients who undergone transradial (TR) CAS at our center. Demographics, the technique used to deploy the guiding sheath in the common carotid artery, procedural details, results, and complications were evaluated. Results: There were 566 CAS performed in our center. The access sites were 443 transradial, 101 transulnar, 10 transfemoral, and 13 transbrachial. CAS was successful in 566 (100%) patients; The target lesions were 292 (52%) in LICA and 274 (48%) in RICA. Contra lateral carotid occlusions were found in 52 (9%) patients, and 44 (8%) patients underwent bilateral CAS. The specific technique varied with the anatomy , in which ,anchoring technique in 83% of the patients and telescopic in 17%. Distal embolic protection devices were used in 374 (74%) procedures and proximal protection devices in 12 (2%). Adverse events included : 2 major strokes (0.6%), 3 minor strokes (1%), and no myocardial infarction at 30 days. Conclusion:The radial approach is proved to be a feasible and safe strategy in treating significant carotid artery disease. With careful technique and experienced operators, the procedure can be performed with a low complication rate.

53

Abstract No. 171 p

Theme: **interventional cardiology**

Country: **Macedonia**

The Automatic Implantable Cardioverter-Defibrillator in Drug-Refractory Ventricular Tachyarrhythmia

Taneski F¹, Cipusheva K¹, Janushevski F¹, Bojovski I¹, Kotlar I¹, Kitanoski D¹, Manev B¹
Clinic of cardiology Skopje¹

Introduction:The automatic implantable cardioverter-defibrillator continuously monitors the heart, identifies malignant ventricular tachyarrhythmias and then delivers electrical countershock to restore normal rhythm.The available data indicate that the automatic cardioverter-defibrillator can reliably identify and correct potentially lethal ventricular tachyarrhythmias, leading to a substantial improvement in survival in properly selected high risk patients.

Case report: We report a case of thirty two year old male patient, who has a medical history of transitory AFF, repetitive episodes of VT accompanied by loss of consciousness and frequent hospitalizations, in the last four years. In the previous hospitalizations electrophysiological study and ablation has been performed. Despite this procedure and despite the medical therapy, in only two months the patient develops a new episode of VT, which was diagnosed and treated in Cardiovascular centre in Ohrid. He was transported to Clinic for Cardiology-Skopje, for further examinations and treatment. When hospitalised, the patient has been complaining of palpitations and fatigue, 4 days ago. On electrocardiogram AFF with rapid ventricular rate 120/min, was diagnosed, which hours later moved spontaneously in sinus rhythm. Echocardiography examination showed preserved left ventricular function, EF = 60%. Holter monitoring showed rhythm episode of atrial fibrillation lasting 8 hours and spontaneous conversion to sinus rhythm.

MRI showed several scars, most likely after ablation. Also an electrophysiological study has been made, but a hotspot of VT has not been localised. Due to the inability to control medically attacks of ventricular tachycardia, the patient was implanted one chamber ICD with ventricular electrode active fixation. procedure passed the orderly flow without complications. The patient was discharged in good general condition, dual antiarrhythmic, anticoagulant and oral antibiotic therapy.

Conclusion : Sudden cardiac death caused by Drug-Refractory Ventricular Tachyarrhythmia, can be prevented by implantation of The Automatic Implantable Cardioverter-Defibrillator.

Keywords: drug refractory ventricular tachycardia, Implantable Cardioverter Defibrillator

54

Abstract No. **180**

Theme: **interventional cardiology**

Country: **Macedonia**

FACTORS ASSOCIATED WITH PROLONGED MECHANICAL VENTILATION IN CARDIOSURGICAL PATIENTS

**Bogoevska-Miteva Z¹, Boseska G¹, Anguseva T¹, Mitrev Z¹
Special Hospital for Surgical Diseases “Filip Vtori”, Skopje, Macedonia¹**

Aim: To identify if the factors such as: age, sex, type of operation, ejection fraction, comorbidities and NYHA (New York Heart Association) classification score prolong the individual ventilation time in patients following open heart surgery.

Materials and Methods: Retrospective study of 549 consecutive patients, who had open heart surgery from January –June 2009 in our hospital. The data that has been used was collected from their discharge letters. Each risk factor was classified into a separate group (exp. age group : <30 years, 31-50, 51-70, >70 years old). The individual ventilation time was added up and then divided equally to the number of patients in that particular group.

Results: Older patients, above 70 years of age required longer time on mechanical ventilation than the younger ones. Women (7,4 hours) had the need of longer ventilation time than men(7,2h). The number of coronary by-pass grafts had a direct impact on prolonged mechanical ventilation. The longest ventilation time was required by women (13h) and men (11,7h) with acute aortic dissection. Higher NYHA score lead to longer ventilation time in both, men and women. Comorbidities such as: hypertension, hyperlipidemia, diabetes mellitus, acute myocardial infarction, obesity and central vascular incident didn't have any significant impact on ventilation time. The time spent on mechanical ventilation was prolonged in patients with lower ejection fraction, the lower the ejection fraction - the longer the ventilation time. However, in our group of patients, chronic kidney insufficiency in male cardiosurgical patients (9.2h) and chronic obstructive pulmonary disease in female patients (9,7h) had significant impact on the mechanical ventilation time.

Conclusion: Women, older age, multiple by-passes, high NYHA score, low ejection fraction and acute aortic dissection can be early predictors of prolonged mechanical ventilation.

Keywords: prolonged mechanical ventilation, coronary artery disease

55

Abstract No. 181

Theme: **interventional cardiology**

Country: **Macedonia**

Preoperative Intra-Aortic Balloon Pump in Patients Undergoing Coronary Bypass Surgery

Lazarova D¹, Bogoevska-Miteva Z¹, Anguseva T¹, Mitrev Z¹

Special Hospital for Surgical Diseases “Filip Vtori”, Skopje, Macedonia¹

Aim: To assess the effectiveness of preoperative intra-aortic balloon pump (IABP) placement in high-risk patients undergoing coronary bypass surgery (CABG). The primary outcome was hospital mortality and secondary outcome were IABP-related complications (bleeding, leg ischemia, aortic dissection).

Materials and Methods: 7108 patients with CABG surgery had been treated from 2000-2012. 452 (6, 3%) got IABP pre-operatively due to hemodynamic instability as well as positive high risk evaluation. All patients got pre-operatively echo and invasive hemodynamic monitoring (CVP, MAP, SVcO₂, CO, CI and SV).

Results: A total of 452 patients received preoperative IABP. Within 10 minutes after insertion of IABP mean arterial pressure (MAP) increased from 45,5+/-9 to 76,8+/-12 mm Hg. Cardiac index initially fell from 2.0 +/- 0.5 to 1.7 +/- 0.4 L/min/m²; however, when IABP was disconnected, went up to 1.85 +/- 0.4 L/min/m². Urine output (UO) increased by 100%. The positive changes in MAP and UO persisted after 24 h. The pooled odds ratio (OR) for hospital mortality in patients treated with preoperative IABP was 0.41 (95% CI, 0.21–0.82, p=0.01. Only 1 patient who received preoperative IABP developed limb ischemia and she was treated with thrombednatherectomy and patch plasty of the left femoral artery (insertion of IABP catheter site), 47 patients (most of them were on Clopidogrel- anticoagulation tablets) got haematoma at the IABP insertion site. These complications improved after disconnection of IABP.

Conclusion: These analysis show significant results in preoperative use of IABP in high-risk patients in reduction of hospital mortality.

Keywords: IABP, CABG

56

Abstract No. 182

Theme: **interventional cardiology**

Country: **Macedonia**

Monitoring of intra-hospital infections through the experiences of SHSD “Filip Vtori”

Bogoevska-Miteva Z¹, Boseska G¹, Anguseva T¹, Mitrev Z¹

Special Hospital for Surgical Diseases “Filip Vtori”, Skopje, Macedonia¹

Aim: To improve the quality of treatment (in terms of IHI) through continuous monitoring of all factors and indicators of infection and analyzed data obtained from INICC

Introduction: Intra-hospital infections (IHI) are secondary diseases and the most common complications of hospital treatment which prolong hospital stay, increase the cost of treatment, increase mortality and are threat to reduce the quality of life. IHI include: pneumonia - VAP,

surgical wound infections, urinary infections and catheter-associated infections. Monitoring IHI is essential in the intensive care units, where patients are exposed to additional risk factors (invasive monitoring, reduced immunity, parenteral nutrition, mechanical ventilation)
Materials and methods: The data has been collected on daily bases by trained medical personnel, using evident sheets prepared from INICC (International Nosocomial Infection Control Consortium) for patient demographics, comorbidities, use of antibiotics as well as information about the central, peripheral and urinary catheters ("Rosenthal study"). Those sheets are sent to INICC, analyzed and the results are sent back to us, which is a base for the activities of the IHI team.

Results: Our participation in this international prospective cohort study dates back to November 2006 when the percentage of hospital-associated infections was 16%. In conducting the study, its effect on the consciousness of the personnel, continuous education of multidisciplinary teams, rational use of antibiotics (our own microbiology laboratory) the percentage is reduced to 0% the past 17 months.

Conclusion: For successful reduction of hospital-associated infections and effective use of their resources, hospitals should pay special attention to the factors that increase the risk of infection in their patients and to introduce special control and preventive measures. According to our experience, Rosenthal - Study among the others, is a great, cost effective method for achieving that goal.

Keywords: intra-hospital infections, infection control

57

Abstract No. **183**

Theme: **interventional cardiology**

Country: **Macedonia**

Can we predict the occurrence of decubitus ulcer?

Boseska G¹, Bogoevska-Miteva Z¹, Anguseva T¹, Mitrev Z¹

Special Hospital for Surgical Diseases "Filip Vtori", Skopje, Macedonia¹

Aim: To examine the role of different factors in occurrence of decubitus ulcer. A decubitus ulcer (DU) is a pressure sore or what is commonly called a "bed sore". The usual mechanism of forming a DU is from pressure, or it can occur from friction by rubbing against something such as a bed sheet, cast, brace, etc, which compromise blood circulation of the tissue.

Materials and Methods: The data that has been used was taken out from the discharge letters of the patients who were treated/ operated in our hospital. There has been documentation from the nursing staff about the existence of the DU, localization, stage, the use of the antidecubital mattress. The following methods were used to identify the factors that are related to prevention of DU: gender; comorbidities; smoking; primary diagnosis; the type of surgery; the stage of DU; localization;

Results: 2080 patients were admitted in the period from January to December 2011. 40 patients (1.92%) had DU during their stay in hospital. 4 patients (10.25%) were admitted with DU. Higher percentage of women (56,4%) had DU compared to men (43,6%). Analyzing the age groups, the members of the group aged 51 to 70 years showed the highest percentage of existence of DU (56,4%). The comorbidities such as hypertension (76,9%), hyperlipidaemia (53,8%), diabetes(43,6%) and obesity(28,2%) had significant impact on prevalence of DU. 71,9% of patients were nonsmokers. Coronary artery disease (41,0%) and peripheral circulatory

failure (30,8%) were important risk factors. Significant percentage of patients was treated operatively (89,8%). Most abundant was second degree DU. The most frequent localization of DU was tailbone area (76.9%).

Conclusions: Prevention of the DU is far more important than treatment because every patient is an individual and formation of DU is multifactorial and as we can see from the above factors cannot be predicted preoperatively.

Keywords: decubitus ulcer, prevention, factors for DU, CAD

58

Abstract No. **184** p

Theme: **interventional cardiology**

Country: **Macedonia**

Percutaneous tracheostomy

Konevska S¹, Bogoevska-Miteva Z¹, Naumoska V¹, Boseska G¹, Anguseva T¹, Mitrev Z¹
Special Hospital for Surgical Diseases "Filip Vtori", Skopje, Macedonia¹

Aim: To evaluate the nursing activities in treatment of patients with percutaneous tracheostomy. Percutaneous tracheostomy (PT) has gained an increasing acceptance as an alternative to the conventional surgical tracheostomy (ST). In experienced hands, and with proper patient selection, it is safe, easy and quick. An important advantage of PT over ST is that there is no need to move a critically ill patient to the operating room and the rate of stomal infection is very low, as well as easier nursing activities

Material and methods: During last 6 years on 7500 open heart surgeries, 152 patients required long-term ventilation, which was supported by percutaneous tracheostomy with subglottic aspiration port. Ciaglia's method is the most commonly applied. Nursing activities were much easier for mouth care as well as feeding of the patient. Cuff-pressure control was regular, as well as on-time using of voice-tracheostomy canule.

Results: All 152 patients had excellent follow up including respiratory machine weaning in a shorter time, it was easier for feeding and overlapping on a normal food as well as the ability to talk was very important to the patients. We have no noted complication in our group of patients.

Conclusion: Nursing is very important for prevention of the tracheostoma complications which means prevention of tracheomalatio, stoma wound infection and lung infection. Nursing activities give chance for early resocialisation of the patients with tracheostomy.

59

Abstract No. **185**

Theme: **interventional cardiology**

Country: **Macedonia**

УЛОГАТА НА ИНСТРУМЕНТАРКАТА ПРИ КАРДИОВАСКУЛАРНА ОПЕРАЦИЈА НА ПУЛСИРАЧКО СРЦЕ (ОРСАВ)

Блажевска С¹, Ангүшева Т¹, Митрев Ж¹

Специјална Болница за Хируршки Болести "Филип Втори Скопје", Македонија¹

Вовед: Коронарната бајпас-операција на пулсирачко срце (Off-Pump Coronary Artery

By-pass – OPCAB) се изведува без екстракорпорална циркулација (ЕКЦ) која е асоцирана со невролошки, ренални и пулмонални компликации. Но, OPCAB – методата е технички сложена и пропратена со специфични ризици. Инструментарката во секое време треба да биде активно подготвена за брза реакција во случај на дестабилизација на пациентот, итно канилирање и поставување на ЕКЦ.

Цел: Евалуирање на улогата на инструментарката во обезбедување на брз, безбеден тек на операција, одржување на апсолутна стерилност и во итни ситуации, минимизирање на компликации, скратување на болничкиот престој.

Материјали и методи: Покрај самото инструментирање, инструментарките ја контролираат стерилноста на оперативното поле, на оперативниот тим како и на останатиот персонал во салата. При припремата на инструментите и материјалите, гарнирањето на оперативното поле и инструментирање, строго се следат интерните ИСО-стандарди за квалитет. После стернотомија, инструментарката му асистира на операторот при препарирање и дилатирање на а. mammaia, отварање на перикардот, поставување на подржни шавови и стабилизаторот, препарирање и дилатирање на коронарките со микроинструменти. После шиене и проверка на анастомоза, стабилизаторот се вади, се врши хемостаза, се поставуваат дренажи, се затвара градната коска, поткожата и кожата. Цело време, кардиоперфузионистот стои на Standby за случај на итна потреба од ЕКЦ.

Резултати: Во периодот од 01.03.2000 до 01.03.2014 година, од 7257 кардиоваскуларни бајпас операции, 1683 пациенти (23,2 %) се оперирани во OPCAB техника.

Заклучок: Високо стручна подготвеност на оперативниот тим, современа технологија и стандардизација на процедури, овозможува безбедна примена на технички посложена OPCAB-операција.

60

Abstract No. 186

Theme: **interventional cardiology**

Country: **Macedonia**

Transradial primary percutaneous coronary intervention for the treatment of a patient with cardiogenic shock due to acute total occlusion of unprotected left main coronary artery

Pejkov H, Kedev S, Antov S, Kostov J, Kalpak O, Spiroski I, Bosev M, Vasilev I. University Clinic of Cardiology, Medical Faculty-Skopje, Republic of Macedonia

Acute total occlusion of unprotected left main coronary artery (LMCA) is rarely encountered in clinical practice. The incidence cannot be determined precisely, since most of the patients die before hospital admission. Malignant arrhythmias, cardiogenic shock or sudden death due to pump failure develops in most of these patients.

We are presenting a 33-year-old male patient with cardiogenic shock and extensive anterior ST-elevation myocardial infarction due to acute total occlusion of unprotected LMCA, admitted in our hospital 2 hours after chest pain onset.

The patient was treated through the right transradial primary percutaneous coronary angioplasty with 6F EBU guiding catheter. There was an totally occluded unprotected LMCA without any supportive coronary flow to the left system.

On admission in ICU because of the cardiogenic shock (KILIP IV), inotropic stimulation was

started immediately . Therefore, before percutaneous coronary intervention trans-femoral intra-aortic balloon pump was placed. Transradial coronarography revealed total occlusion of distal LMN. Abciximab was administered, and thrombo-aspiration was performed , followed by the implantation of a 3.5 / 24 mm drug-eluting stent and postdilatation with NC balloon 4.0/9 mm and restoration of TIMI III flow. In – lab procedural time was 11 min. However, the patient died after 46 hours, due to refractory left ventricular failure.

Conclusion: Most challenging STEMI cases with totally occluded LMCA could be treated time efficiently through the TRA. However, mortality remains high due to refractory LV failure.

Keywords: Primary percutaneous coronary intervention, Cardiogenic shock, STEMI

61

Abstract No. **187** p

Theme: **interventional cardiology**

Country: **Macedonia**

CARDIOVASCULAR COMPLICATIONS ASSOCIATED WITH HIP FRACTURES IN THE ELDERLY

Dacevska Dimitrovska M.,¹ Dimitrovski D.,²

JZU Gerontological institute³ November ,Skopje,RM,¹ UK St. Naum Ohridski ,Skopje,RM,²

Aim : To overview the complications ,expetialy cardiovascular complications after hip fractures(femoral neck fracure,subtrochanteric fracure) in the elderly,medical treatment and prognosis.The fractures in the elderly are caused by simple falls(more of them at home) and the main risk factor is osteoporosis. Material and methods:55 paciens admitted to intensive care unit were observed,85% female,15 % male,aged 80+-5 yers,clinical feature,EKG,RTG,LAB,simptoms .80% of the fractures were femoral neck fracures ,20 % were subtrochanteric fractures.95 %of them were admited 7-14 days after surgical treatment,5 % were treated only with immobilisation(without surgery) .Only in 14% of the npatients the prevention of osteoporosis has been done before falls.Results:Depends of preexisting multimorbidity and medical care after hip fracures.All of the patiens were addmited to intensive care unit . Some of them already have had some complications ,some of them developed complications within the hospitalisation in our institution.Medical complications expetialy cardiovascular complications are most common and fatal too.Notised complications: Heart failure because of infection (pneumonia ,UTI ,preexisting heart failure) developed in 85% of the patients,Deep venous thrombosis in 18% of the patients besides the prevention with anticoagulants,presure ulcers 10% at the moment of addmision ,70% after 30 days of immobility,chest infection 70%,urinary tract infections 60%(all the patients were catheterisated),dementia 15 %.Complications are often more than two ones.Medical treatment is multidisciplinary. Prognosis is very poor,Hip fractures are very dangerous episodes and the risk od dying is high(85%).Heart failure associated with pneumonia is a leading cause of death in the elderly at all.

Conclusion :Intensive medical treatment and prevention of complications is a priority. The prevention(primary,secondary,tertiary) of the osteoporosis is at the same time a prevention of the hip fractures. If the patient survive rehabilitaion is needed but is is very hard at that age.Half of them need assistance for self care.

Kay words: hip fractures, cardiovascular complications,prevention.

62

Abstract No. 189

Theme: **interventional cardiology**

Country: **Macedonia**

Предоперативна подготовка на пациент за кардиохируршки третман

Бошевска Г¹, Мицева К¹, Поповска Б¹, Идоски Е¹, Ангешева Г¹, Митрев Ж¹

Специјална болница за хируршки болести "Филип Втори", Скопје, Македонија

Вовед: Во комплетното лекување на многубројните болести важна е здравствената нега.

Најважна улога на медицинската сестра е спроведување на здравствена нега на болниот, а тоа подразбира и подготовка на пациентот за оперативен зафат.

Цел: За да се овозможи и подобри здравствената нега на пациентот се користат најновите научни сознанија. Едно од барањата е современа тимска работа каде во составот на секоја тим задолжително е и медицинската сестра.

Методи: Медицинската сестра учествува во разни фази на дијагностички, терапевтски, профилактични, рехабилитациони постапки каде има незаменлива улога почнувајќи од примањето на болниот во здравствената установа па се до неговото отпуштање дома.

Резултати: Голема и незаменлива е улогата на предоперативната подготовка. Истата треба добро да се осмисли и да се организира за да не загрози безбедноста на пациентот и неговата здравствена состојба.

Заклучок: Организираната предоперативна подготовка на пациентите за кардиохируршки третман го намалува ризикот од интраоперативни и постоперативни компликации.

63

Abstract No. 194

Theme: **interventional cardiology**

Country: **Macedonia**

Can we predict the occurrence of decubitus ulcer?

Sultancev A¹, Boseska G¹, Bogoevska-Miteva Z¹, Anguseva T¹, Mitrev Z¹

Special hospital for Surgical diseases "Filip Vtori", Skopje, Macedonia¹

Aim: To examine the role of different factors in occurrence of decubitus ulcer. A decubitus ulcer (DU) is a pressure sore or what is commonly called a "bed sore". The usual mechanism of forming a DU is from pressure, or it can occur from friction by rubbing against something such as a bed sheet, cast, brace, etc, which compromise blood circulation of the tissue.

Materials and Methods: The data that has been used was taken out from the discharge letters of the patients who were treated/ operated in our hospital. There has been documentation from the nursing staff about the existence of the DU, localization, stage, the use of the antidecubital mattress. The following methods were used to identify the factors that are related to prevention of DU: gender; comorbidities; smoking; primary diagnosis; the type of surgery; the stage of DU; localization;

Results: 2080 patients were admitted in the period from January to December 2011. 40 patients (1.92%) had DU during their stay in hospital. 4 patients (10.25%) were admitted with DU.

Higher percentage of women (56,4%) had DU compared to men (43,6%). Analyzing the age groups, the members of the group aged 51 to 70 years showed the highest percentage of existence of DU (56,4%). The comorbidities such as hypertension (76,9%), hyperlipidaemia (53,8%), diabetes(43,6%) and obesity(28,2%) had significant impact on prevalence of DU.

71,9% of patients were nonsmokers. Coronary artery disease (41,0%) and peripheral circulatory failure (30,8%) were important risk factors. Significant percentage of patients was treated operatively (89,8%). Most abundant was second degree DU. The most frequent localization of DU was tailbone area (76.9%).

Conclusions: Prevention of the DU is far more important than treatment because every patient is an individual and formation of DU is multifactorial and as we can see from the above factors cannot be predicted preoperatively.

Keywords: decubitus ulcer, prevention, factors for DU, CAD

2. Echocardiography and other imaging techniques in cardiology

1

Abstract No. 9

Theme: **Echocardiography and other imaging techniques in cardiology**

Country: **Macedonia**

Analysis of LA function in patient with cardiomyopathy, with or without atrial fi

Fatmir F., Karemani N.¹ Uzairi N¹. Preshova A¹, Karemani M¹, GP Ferati A¹

Clinical Hospital Tetovo

The objective of the study is to analyze the function of the left atrium (LA) in patients with chronic cardiomyopathy (KMP) with or without atrial fibrillation (AF), and in patients with paroxysmal AF.

For that purpose, we analysed the LA function through determining the ejection fraction (EF) of LA, volume of LA, EF of the LV and global longitudinal strain (GLS) of LA. The given results of the analyzed groups have been compared with the results of the control group, which have no recorded heart disease, just like the groups themselves.

Material

48 persons have been analyzed, 13 of them in the control group, persons without known cardiac disease, 12 patients with paroxysmal AF, medically converted, 11 patients with KMP in permanent AF, 12 patients with KMP in sinus rhythm (SR).

Methodes

Echocardiography was made with ultrasound Philips "Sonos 7500" with 3D option. Analysis of images was made with software "Cardiac Performance Analysis package" (TomTec Imaging Systems GmbH) with 2D strain option

Conclusions

1. Atrial fibrillation brings to a lowering of the LA function
2. Converting AF in sinus rhythm (SR) brings to a big improvement of the LA function
3. Increase of the LA volume is a characteristic, which occurs after converting the AF in SR and which is due to the improvement of the reservoir function of LA after the conversion of AF.
4. A more pronounced difference is being registered between the patients with CMP with

permanent AF and patients with CMP with sinus rhythm (SR), whereas patients with CMP in SR, had bigger LA compared to the patients with KMP in permanent AF.

5. In patients with chronic CMP in SR, normal LA function has been registered

Key words: Left atrium (LA), Cardiomyopathy (KMP), Atrial fibrillation (AF), Sinus rhythm (SR), ejection fraction of LA (EF of LA), Global longitudinal strain of Left atrium (GLS of LA).

2

Abstract No. 17 p

Theme: **Echocardiography and other imaging techniques in cardiology**

Country: **Macedonia**

Myxoma of the heard

Tashkova Kirkovska T, Duganovska S, Petrushevska G, Mitrev Z

Institute for Pathology, Medical Faculty , Ss Cyril and Methodius University

Myxoma of the heard

The paper is treated benign tumor of the heart - the heart myxoma of 25 year old man.

At the Institute for pathology was submitted biopsy material that was macroscopic and histological processed by standard techniques and histochemical (reticulin, Van Gieson, elastin, PAS) and immunohistochemical analysis (Acin, Desmin).

Material is penduculated elastic soft tumor mass measuring 3x2.6x2sm, with white gray color and bleeding areas. At the periphery is visible soft connective tissue capsule. At dissection in haemorrhagic zones are recognized dilated vascular spaces filled with thrombotic masses.

Histological analysis of tissue sections showed that the tumor is constructed of individual polygonal and elongated cells embedded in the myxomatous matrix.

The tumor is present with areas dominated acellular myxomatous component , and cellular areas where cells are grouped into bands and chains with present numerous delicate blood vessels around which are fresh and old hemorrhages .

Cardiac myxomas originate from primitive connective tissue of the septum. These are rare tumors , but the most common primary tumors of the heart in adults . They can also occur at other sites.

Approximately 86 % of heart myxoms are localized in the left atrium . Usually they are penduculated wuth loop attached to interatrial septum . Their main symptoms are hemodynamic obstruction , embolization and sudden cardiac death.

The treatment of choice is surgical excision , and after removal patients are usually asymptomatic and have a normal lifespan .

Findings from our analyzed case confirmed the clinical diagnosis, cardiac myxoma , which is benign noninfiltrative, attached to the interatrial septum tumor with secondary thrombosis

3

Abstract No. 18

Theme: **Echocardiography and other imaging techniques in cardiology**

Country: **Macedonia**

Echocardiographic predictors of chronotropic incompetence to exercise in patients with heart failure with preserved ejection fraction

Hristovski Z¹, Projevska-Donegati D¹, and Georgievska-Ismail Lj²

Clinical Hospital “Acibadem-Sistina”, Skopje, Macedonia¹ University Clinic of cardiology,

UKIM, Skopje, Macedonia²

Objective: Exercise intolerance in patients with heart failure with preserved ejection fraction (HFpEF) is most often attributed to diastolic dysfunction (DD); however, chronotropic incompetence (CI) could also play an important role. We intended to examine if there are predictive echocardiographic parameters of DD for impaired chronotropic response to exercise. **Methods:** Patients (n=140) with unexplained dyspnea and/or exercise intolerance who fulfill clinical and/or echocardiographic criteria of HFpEF presence underwent symptom-limited exercise test using treadmill (ETT) according to Bruce protocol. Patients were divided according to the presence of CI which was defined as the failure to achieve 85% of the age-predicted maximum heart rate and/or heart rate reserve (HRR) of $\leq 80\%$.

Results: Comparison of the groups with (n=97) and without CI (n=43) didn't show any statistical significant difference regarding demographic and clinical characteristics except for resting HR which was significantly lower (p=0.008) as well as beta blockers which were significantly more frequently present (p=0.012) in patients with CI in comparison with those without. Patients with CI had a higher mean E-wave velocity, E/A ratio, increased E/E' septal, lateral as well as average ratio and abnormal IVRT/TE-e' index all consistent with elevated LV filling pressures. E/E' average ratio > 15 was statistically insignificantly more frequently present in patients with CI. In addition, CI was significantly related to E' septal (r =0.244; p=0.004) and E' average (r=0.189; p=0.025) as well inversely related to E/E' septal ratio (r = -0.189; p = 0.025). By multivariate analysis, E/A ratio (R²=0.268, β =-13.7, 95%CI -27.17-(-0.218)) and value of E' septal (R²=0.211, β =5.01, 95%CI 1.91-8.24, p=0.002) appeared as statistically significant independent echocardiographic predictors of lower HRR %. The results were similar when percent of achieved age-predicted HR was considered as dependent variable and E' septal was unic significant independent predictive parameter of lower increase of HR during exercise (R²=0.305, β = 3.761; 95%CI: 1.786-5.736; p=0.0001).

Conclusion: Patients with HFpEF frequently have chronotropic incompetence to graded exercise which may partly be predicted with echocardiographic parameters that are consistent with elevated LV filling pressures.

Keywords: Keywords: heart failure with preserved ejection fraction; diastolic dysfunction; left ventricular filling pressure; chronotropic incompetence

4

Abstract No. **19**

Theme: **Echocardiography and other imaging techniques in cardiology**

Country: **Bulgaria**

Athlete`s heart or hypertrophic cardiomyopathy?

Shabani R

Department of Internal diseases "Prof. St. Kirkovich", Medical university of Sofia

Sudden unexpected deaths of young trained athletes are highly visible events with substantial in physician and lay communities. Intensive endurance training is able to cause a distinct pattern of functional and structural changes of the cardiovascular system. In an unknown proportion of athletes a so called "athlete`s heart" develops. There is an overlap between this type of physiologic cardiac hypertrophy and mild forms of hypertrophic cardiomyopathy (HCM). Because of this data a great interest in distinguishing these two diagnoses exists.

Echocardiography is the method of choice. The athlete`s heart shows an accentric biventricular

hypertrophy with wall thicknesses under 15 mm and a moderately dilated left ventricle(LVEDD up to 58 mm). HCM is commonly characterized by asymmetric left ventricular hypertrophy with a reduced LV-diameter. Systolic function is normal in highly trained athletes and the majority of HCM patients as well. There are important differences regarding diastolic function with even increased early diastolic filling. In case of HCM diastolic dysfunction (mostly relaxation disturbances) occurs in the majority of patients and is therefore inconsistent with an athlete`s heart. If the diagnosis could not be stated using echocardiography, methods like cardiac-MRI can provide further information. A correct diagnosis may on the one hand prevent some athletes from sudden cardiac death. On the other hand sportsmen with an athlete`s heart are reassured and able to continue as competitors.

Keywords: cardiac hypertrophy, athlete, sudden cardiac death

5

Abstract No. 24

Theme: **Echocardiography and other imaging techniques in cardiology**

Country: **Macedonia**

Assessment of global longitudinal strain with speckle-tracking in patients with heart failure with preserved left ventricular ejection fraction

Georgievska-Ismail Lj,¹ Hristovski Z,² Projevska-Donegati D,²

¹. University Clinic of cardiology, UKIM, Skopje, Macedonia ². Clinical Hospital “Acibadem-Sistina”, Skopje, Macedonia

Background: Left ventricular (LV) global longitudinal strain (GLS) is a measure of the active shortening of the LV in the longitudinal direction, which can be assessed with speckle-tracking echocardiography providing direct information on abnormalities of LV deformation despite preserved LV ejection fraction (LVEF). The aim of the present study was to use sensitive echocardiographic methods to assess LV function in a population of patients with heart failure with a preserved LV ejection fraction (HFpEF) in order to detect early changes and thus identify those at increased risk.

Methods: We assessed myocardial systolic and diastolic function in 148 patients (62.74±9.83 y; 37.2% men and 62.8% women) with unexplained dyspnea and/or exercise intolerance who fulfill clinical and/or echocardiographic criteria of HFpEF presence using 2D echocardiography and tissue Doppler imaging. Myocardial deformation was assessed using 2D speckle tracking software.

Results: HFpEF patients had preserved LVEF (65.59±6.94%) and GLS of -16.99±5.29%. GLS was positively related to BMI (r= 0.33; p=0.0001), current smoking (r= 0.216; p=0.008) and diabetes mellitus presence (r= 0.179; p=0.030). There was significant negative relation between LVEF and GLS (r=-0.237; p=0.004) and positive relation with wall motion abnormality score index (r=0.249; p=0.002). As for diastolic echocardiographic parameters GLS was negatively related to E' septal (r =-0.337; p=0.0001), E' lateral (r =-0.284; p=0.0001), E' average (r=-0.361; p=0.0001) as well positively related to E/E' septal ratio (r = 0.170; p = 0.039) and E/E' average ratio (r = 0.171; p = 0.038). On multivariate regression analysis of diastolic variables, GLS was independently related to E' average (β =-1.45, 95%CI -2.095 to -0.795, p=0.0001). When number of segments with GLS of < 12% was taken as dependent variable in multivariate regression analysis, GLS was independently related to E/E' septal ratio (β = 0.015; 95%CI: 0.003-0.026;

p=0.003).

Conclusion: The assessment of GLS with speckle-tracking echocardiography identified individuals with subclinical LV systolic dysfunction despite preserved LVEF. Patients with greater impairment of GLS had greater diastolic dysfunction consistent with elevated LV filling pressure, thus it may be implicated increased risk and/or worse prognosis.

Keywords: Heart failure with preserved ejection fraction, global longitudinal strain, 2D-speckle-tracking

6

Abstract No. 27p

Theme: **Echocardiography and other imaging techniques in cardiology**

Country: **Macedonia**

Предизвици при менаџирање на пациенти со СКАБ/презентација на случај

Сервини Ж., Лозанче Н., Пармаковски С.

Клиничка болница „Др. Т. Пановски,, Битола

За разлика од нестабилната АП која бара брзо решавање на проблемот и коронарографија за повторно воспоставување на проток во засегнатиот крвен сад, пациентите со стабилна АП (СКАБ) се подвргнуваат на низа дијагностички постапки според водичот од 2013 г. со следните критериуми 1. Типични симптоми 2. Претест на веројатноста (РТР) 3. Функционално и анатомско решавање на миокардната исхемија. Можната или позната СКАБ вклучува голем спектар на симптоматски пациенти исто како и асимптоматски пациенти со позната КАБ. Врз основа на (РТР) се класифицираат во 3 групи 1. РТР под 15% не се потребни натамошни иследувања 3. РТР над 85% треба веднаш да се испратат на ИСА 2. РТР 15 до 50 % пациенти кои треба да бидат подвргнати на натамошни функционални испитувања и тоа EF < 50% и типични симптоми треба да се подложат на ИСА, EF < 50% и пациентот е без симптоми треба да се продолжи со натамошни функционални испитувања./Нормална EF стрес имедиинг техники. Презентација на случај: Пациент, маж на 65г. се јавува заради замор при пешачење по нагорнина пратен со граден дискомфорт. Анамнестички дава податоци за ХТА од пред 10г, St post NONSTEMI пред 1г. , дизлипидемија, обезност. По утврден РТР 66 до 85% направена е МИОКАРДНА ПЕРФУЗИОНА ТОМОСЦИНТИГРАФИЈА (СПЕКТ) која покажа изразена хиперфузија од трансмурален тип во базалните , средните и апикалните сегменти на инфериорниот ѕид на левата комора и самиот апекс за време на стрес која е потпоно реверзибилна во регија на апекс и апикален сегмент на инфериорен ѕид за време на рест. Хипокинезија во базалниот и сегмент на инфериорниот ѕид на левата комора. EF > 60% како во стрес така и во рест. Направена коронарографија наод на коронарните артерии без сигнификантни лезии. Пациентот поставен на ОМТ и на контролен преглед после 2 месеци се јавува ослободен од симптоми . Заклучок Дијагнозата на СКАБ се базира на низа постапки кои вклучуваат тријажа на симптомите, одредување на РТР и особено воведувањето на стрес имедиинг техниките во менаџирање на пациенти со РТР 15 до 85% со што јасно може се дефинира натамошното менаџирање на СКАБ. Отсуството на значајна лезија на епикардните коронарни артерии утврдено коронарографски кај симптоматски пациенти со позитивен наод на стрес имедиинг техниките не го исклучува присуството на СКАБ.

7

Abstract No. 29p

Theme: **Echocardiography and other imaging techniques in cardiology**

Country: **Macedonia**

WPW syndrome (pre-excitation syndrome) with polymorphic atypical pains, display the présent case (our experiences)

Mitevski D

Health facility "Multimedika DM"-specialized practice in Internal Medicine and Cardiology, Kumanovo, Macedonia

Purpose: Display of our experiences in a young patient with pre-excitation syndrome, which can often mimic lesion post infarction, hypertrophy of the right or the left ventricle of the heart and block the right and left branch!

Material: It is a 18-year-old who is actively engaged in sports with body height of 192 cm and weight of 82 kg, which in the first half of 2013 appeared in our medical facility for a medical internist specialist cardiology review!

Methods : The electrocardiogram was registered sinus rhythm with HR = 58/min , abbreviated P - Q interval of 90 ms , expanded QRS complex , positive delta wave in DI , aVL , precordial plumbed V2 - V6 , and I - position Q in DII , DIII and aVF ! Anamnestic , after a lengthy discussion data was obtained for occasional palpitations and fatigue after training easy !

Here 's done a complete diagnostic cardiology , coronary stress test (negative, achieved 100 % of cardio - respiratory capacity) , 24 h ECG Holter monitoring where they are registered and validated changes described above during the entire monitoring . Echocardiography finding was the physiological limits of normal ventricular segmental kinetics without outbursts of normal valve apparatus . Laboratory analyzes were made then , all results were within the limits of normal and cardiac - specific enzymes in the normal range ! The boy was on our set of small doses of Ca - antagonist (tbl. Verapamil 40 mg 2x1) with an indication of pause in terms of physical activity and sports , and the need for further consultation with our Cardiology Clinic in Skopje! Our findings colleagues were fully confirmed ! After the decision was made to review the family to Belgrade is made electrophysiological study with ablation of Kent bundle ! In the beginning of 2014 in our health institution was made with a control diagnostic conclusion to withdraw already described changes in standard ECG and 24 h Holter ECG monitoring !

Conclusion end keywords: WPW frequency of the syndrome in the general population ranges from 0.1 to 0.3% and the treatment and further treatment is individual, according to symptomatology, age, physical exposure, etc.. In our case it is about a young boy who is actively engaged in sports is that after I performed electrophysiological study and further indication of free sports (with regular internist cardiac control) is not impaired enormous personal life in the future!

8

Abstract No. 34 p

Theme: **Echocardiography and other imaging techniques in cardiology**

Country: **Macedonia**

Right atrial thrombus in oncology patient - case report

Hadjiev Vasko¹, Hadjieva Deangelis Natasha¹, Hadjiev Vlado¹, Hadjieva Ratka¹
PHO Diagnostic center "D-r. Hadjiev", Bitola¹

Background: Atrial masses in oncology patients are not uncommon. Most frequent are metastatic deposits from the caval system and in situ thrombi, as a result of cytotoxic effects of chemotherapy. Echocardiography in general can not give precise histologic diagnosis. For definite lesion estimation more detailed investigations are needed, such as transoesophageal echocardiography (TEE) and heart magnetic resonance imaging (cardiac MRI). Aim of the study: The importance of regular periodic complete echocardiographic evaluation, as a noninvasive screening tool, for oncology patients, in order to detect early cardiovascular complications and starting prompt treatment. Material and methods: Transthoracic echocardiography examination (TTE) is realised according to the standard protocol and recommendations from the European association of echocardiography (now EACVI) made by Phillips HD11XE machine, S1-3 cardiologic probe, ECG electrodes included. Case report: 46 year old female oncology patient (breast carcinoma) operated and treated with neoadjuvant chemotherapy which was ordained thru jugular catheter in USA. In routine TTE examination echogenic mass with dimensions 23 mm x 22 mm in right atrium is detected. Other investigations are made including TEE and cardiac MRI. The lesion is diagnosed as right atrial thrombus and oral anticoagulant therapy (OAC) Rivaroxaban (Xarelto) 20 mg is introduced once daily. In our center we did a control TTE examination. The patient is free of symptoms, with normal echocardiographic parameters for age and gender (LVDD 45 mm, LVDs 29 mm, IVSD 9 mm, PWDd 8 mm, EF 66% - Simpson BP MOD, FS 35%, Ao val. 29 mm, Ao asc. 27 mm, LA 27 mm, E/A 1,3, DT 206ms, E'lat. 15 cm/s, E'sep. 11 cm/s, E/E'avg 6, TAPSE 22 mm, Sa'TASV 13 cm/s). In right atrium, on standard apical four chamber view (A4C), a hyperechogenic, heteroechogenic, ellipsoid tumor formation, attached to right atrial posterior wall by pedicle, is detected, measuring 16,1 mm by 12,7 mm. The mass is mobile with irregular oscillating movements, but is not causing any obstruction to tricuspid valve flow (functional tricuspid stenosis) on 2D, Color/PW/CW Doppler. The mass is with reduced dimensions in contrast to the last TTE control. Conclusion: Toxic effects of chemotherapy are one of the leading causes of damaging heart and its structures, including endocardium. In order to detect this damage and to start early and proper treatment, regular complete echocardiography studies have to be made focused not only on heart function, but on whole cardiac structures as well.

Keywords: oncology patient, cytostatic chemotherapy, transthoracic echocardiography, atrial mass, transoesophageal echocardiography, heart magnetic resonance imaging, right atrial thrombus, oral anticoagulant therapy.

9

Abstract No. **36** p

Theme: **Echocardiography and other imaging techniques in cardiology**

Country: **Macedonia**

Echocardiographic evaluation of ascending aortic dilatation – our experience

Topliklieva L¹

Clinical Hospital Stip¹

BACKGROUND: Aortic dissection is a life-threatening condition. There is an increased risk of aortic dissection in patients with aortic dilatation. AIM: To show the most common causes of ascending aortic dilatation in our clinical experience. MATERIALS AND METHODS: The

echocardiographic evaluation of the aorta is a routine part of the standard echocardiographic examination. Results of ascending aortic dilatation (diameter 40-50 mm) were found with the measurement of the aortic diameter at typical locations. In the period of two years, from 548 patients who were examined with echocardiography, 62 patients were with ascending aortic dilatation. RESULTS: From 62 patients (38 male, 24 female, all at the age of 44-65), with a history of chronic hypertension were 36 (58.1%), with aortic valvular stenosis were 20 (32.3%) and 6 (9.7%) were with diseases such as collagen-vascular and inflammatory diseases. CONCLUSION: The most prevalent risk factor for ascending aortic dilatation was chronic hypertension. About one third of the patients were with a finding of aortic valvular stenosis. The echocardiographic evaluation of chronic hypertension is essential for the early discovery of ascending aortic dilatation as one of its most important complications.

Keywords: ascending aortic dilatation, chronic hypertension, echocardiography

10

Abstract No. 37 p

Theme: **Echocardiography and other imaging techniques in cardiology**

Country: **Macedonia**

Rana detekcija na subklinicka levo komorna disfunkcija i miokardna ishemija kaj asimptomatski pacienti so dijabetes tip 2: prognosticka uloga na tkiven Dopler, parametri na miokardna deformacija i miokardna perfuziona scintigrafija

Peovska I¹, Srbinovska E¹, Davceva Pavlovska J¹, Antova E¹, Andova V¹, Otljanska M¹, Arnaudova F¹, Bosevski M¹

Univerzitetaska Klinika za Kardiologija, Skopje¹

Celi: Procena na dijagnostickata i prognosticka uloga na parametrite na sistolna i dijastolna LK funkcija, tkivniot Dopler, longitudinalnata LK funkcija, kako i prisustvoto na miokardna ishemija kaj asimptomatski pacienti so dijabet tip 2.

Materijal i metodi: Isledeni se 45 asimptomatski pacienti so dijabet tip 2, bez predhodno poznata ili dokazana koronarna arteriska bolest (KAB). Kaj ispitanicite napravena e 2D ehokardiografija so cel procena na sistolna i dijastolna LK funkcija. Za procena na LK dijastolna funkcija evaluirani se tkiven Dopler - tkivni brzini na nivo na medijalen i lateralen mitralen anulus (e' , odnos E/e'), pulsen dopler na transmitralen protok (E bran, A bran, E/A odnos, DT na E bran, traewe na A bran), protok niz pulmonalni veni (traewe na A bran, odnos A/Adur), volumeni na leva predkomora. Globalnata i regionalna LK longitudinalna funkcija (GLS) odreduvana e so speckle-tracking metoda (automatic functional imaging – AFI). Miokardna perfuziona scintigrafija (MPS) so radioizotop Tc-99m sestamibi izvedena e za procena na prisustvo na miokardna ishemija. Koristen e 17 segmenten model za kvantitativna i semikvantitativna procena na miokardna perfuzija i funkcija. Pacientite se sledeni 12 meseci. Evaluirana e pojavata na nesakani srcevi zbidnuvanja (nova gradna bolka, revaskularizacija, miokarden infarkt, nestabilna angina pectoris, srceva slabost).

Rezultati: Najdena e znacajna korelacija pomegu globalnata longitudinalna funkcija (GLS) so E/e ($r=0.510$; $p=0.00$) so miokardnata ishemija ($r=0.592$; $p=0.001$). Znacajno poniski vrednosti na GLS (-14.9 ± 1.6) i signifikantno povisok E/e (9.13 ± 2.14) najden e kaj dijabeticarite vo odnos na referentnite vrednosti na ovie parametri kaj zdrava populacija. Miokardna ishemija e najdena kaj 12 umerena i teska ishemija ($>10\%$ od miokardot na levata komora). Reducirana LKEF $<50\%$ e

najdena kaj 8 pacienti. Perkutana miokardna revaskularizacija napravevna e kaj 5 pacienti so minimum umerena ishemija. Eden pacient e hospitaliziran poradi nestabilna angina pektoris. Nezavisni prediktori za nesakani srcevi zbidnuvawa vo periodot na sledewe bea umerena i teska miokardna ishemija OR 2.7 (95% CI 1.8–3.9) i OR 3.8 za prisustvo na dijabet nad 10 godini (95% CI 2.3–5.7).

Zaklucok: Ehokardiografskite parametri za procena na regionalna i globalna longitudinalna LK funkcija se ednostavni indikator za rana detekcija na LK disfunkcija kaj dijabetската populacija. Nezavisni prediktori za nesakani KV zbidnuvanja kaj isleduvanite pacienti bea prisustvoto i tezinata na miokardna ishemija i traenjeno na dijabetot.

Keywords: miokardna ishemija, miokardna scintigrafija, ehkardiografija

11

Abstract No. 38 p

Theme: **Echocardiography and other imaging techniques in cardiology**

Country: **Macedonia**

Optimalen terapijski pristap voden od prisustvo na miokardna ishemija kaj asimptomatski pacienti so visok kardiovaskularen rizik: uloga na klinicki, laboratoriski i miokardni scintigrafski parametri

Peovska I¹, Davceva Pavlovska J¹, Vavlukis M¹, Kostova N¹, Zdravkovska M², Majstorov V², Pop Gorceva D², Zdraveska M²

Univerzitetska Klinika za kardiologija¹, Skopje, Institut za Patofiziologija i Nuklearna Medicina², Skopje

Celi: Evaluacija na prevalenca na miokardna ishemija kaj asimptomatski pacienti so visok kardiovaskularen (KV) rizik, procena na vlijanieto na klinicki, laboratoriski i miokardni scintigrafski (MPS) parametri vrz finalnata terapijska odluka.

Metodi: Evaluirani se 60 asimptomatski pacienti so visok KV rizik, kaj koi e napravena miokardna perfuzionna scintigrafija (MPS SPECT) za detekcija na koronarna arterijska bolest (KAB). Koristen e 17 segmenten model za kvantitativna i semikvantitativna analiza MPS skenovite so pomos na perfuzioni i funkcionalni skorovi. Lesna ishemija e definirana kako sumiran diferencijalen perfuzionen skor (SDS <4 ili <10% od miokardotna levata komora), umerena ishemija SDS 4-7 ili 10-15% od miokardot na LK i teska ishemija SDS >7 ili nad 15% LK miokard. Kaj site pacienti napravena e kompletna laboratoriska analiza, vklucuvajki lipiden status, 24 casovna albuminurija, EKG vo mir i optovaruvanje. Koristena e logisticka regresiona analiza za procena na vlijanieto na klinickite i laboratoriski parametri vrz prisustvoto na miokardna ishemija. Procenuvano e vlijanieto na goleminata i prisustvoto na miokardna ishemija vrz terapijskata odluka.

Rezultati: Stres inducirana ishemija e najdena kaj 19 pacienti (33%), fiksni defekti kaj 8 pacienti (13%) i mesani defekti kaj 5 pacienti (9%). Vo prosek goleminata na ishemijata iznesuvanje 10%. Lesna ishemija e najdena kaj 12 pts (64%), umerena ishemija kaj 5 pacienti (26%), a teska ishemija kaj 2 pacienti.

Teskata ishemija bese vo korelacija so traeweto na dijabetot. Sest pacienti so teska ishemija imaa ST segment depresija >2mm pri stres studijata, povisok indeks na zidno zadebeluvanje i pad na levo komorna ezeckiona frakcija (LVEF) >5% pri optovaruvanje (p<0.01). Logistickata regresiona analiza za predikcija na stres inducirana ishemija pokaza OR 2.4 (95% CI 1.7–3.6) za stres inducirani EKG promeni i OR 3.9 za prisustvo na dijabet nad 10 godini (95% CI 2.3–6.6).

Sedum pts so ishemija nad >10% bez upateni na koronarna anigografija. Pacientite so ishemija <10% bea tretirani medikamentozno so rigorozna kontrola na rizik faktori.

Zaklucok: MPS e vredna metoda za predklinicka procena na miokardna ishemija i kaj asimptomatski pacienti so visok karidovaskularen rizik. Metodata ovozmozuva soodvetna terapiska odluka kaj ova grupu pacienti.

Keywords: miokardna ishemija, SPECT, tretman

12

Abstract No. 39 p

Theme: **Echocardiography and other imaging techniques in cardiology**

Country: **Macedonia**

Klinicka vrednost na koronaren kalcium skor i miokardna perfuziona scintigrafija vo detekcija na koronarna arteriska bolest kaj

asimptomtski pacienti so umeren i visok kardiovaskularen rizik

Peovska I¹, Davceva Pavlovska J¹, Lazarevska M², Stojkovski A², Zdravkovska M³, Zdraveska M³

Univerzitetska Klinika za Kardilogija¹, SKopje, Klinika za Radiologija², Skopje, Institut za Patofiziologija i Nuklearna Medicina³, Skopje

Celi: Koronarniot kalciumski skor (SAS) e parameter za neinvazivna dijagnoza na koronarna ateroskleroza. Celta na studijata procena na klinickata vrednost na SAS i miokardnata perfuziona scintigrafija (MPS) vo evaluacija na koronarna arteirska bolest (KAB) kaj pacienti so umeren kardiovaskularen rizik.

Materijal i metodi: Kaj 45 pacienti (26 so umeren i 19 so visok kardiovaskularen rizik (procenet so evropskiot Heart SCORE) bez predhodno poznat KAB, procenet e CAC so pomos na povekeslojna kompjuterizirana tomografija so cel evaluacija na suspektna KAB. Procenuven e globalen i CAC po vaskulareni regii, a skorot e gradiran spored Agatston edinici: <10 (neznacajna kalcifikacija na koronarni arterii; 11-100 lesna kalcifikacija; 101-400 umerena kalcifikacija; 401-1000 teska kalcifikacija na koronarni arterii. Pacientite so CAC >400 se upatuvaa na MPS spored evropskite preporaki. MPS Gated SPECT e izvedena po ednodneven protokol vo mir i po farmakolosko optovaruvanje so radiopreparat Tc-99m sestamibi, a skenivite se analizirani po 17 segmenten model so pomos na perfuzioni skorovi. Pravena e komparacija na dvete metodi koi isleduvaat razlicni aspekti na KAB, i procenuvana e moznosta za reklasifikacija na kardiovasuklarniot rizik.

Rezultati: 17 pacienti imaa CAC <100 Agatston edinici, 13 pacienti imaa CAC >400 (612+/- 104) i bea upateni na MPS. Kaj 8 pts (17%) od niv najdena e umerena miokardna ishemija (SDS 7-10 ili >10% od miokardot na levata komora), so SAS 589+/- 124 i istite se invazivno isledeni (PCI so stentirawe na LAD kaj 3 pacienti, LAD i LCx kaj 2 pacienti, PCI so stentiranje na RCA kaj 3 pacienti). Dobiene e visoka korelacija pomegu CAC >400 i MPS proceneta ishemija (r=0,56). Kaj 5 pacienti so umeren KV rizik najden e CAC >400 i prisutna umerena miokardna ishemija kaj 4 od niv, so sto se reklasificirani vo pacienti so visok KV rizik i upateni na invazivno isleduvanje. Nieden pacient so CAC >400 nemase normalen MPS naod. Lesna ishemija e (<10% od miokardot) e najdena kaj 7 pacienti. 4 visoko rizicni pacienti imaa ureden MPS naod so visok CAC skor (632+/-89).

Zaklucok: Koronarniot kalciumski skor i MPS ovozmozuvaat procena na antamoskata i funkcionalna ekspresija na KAB. CAC ovozmozuva reklasifikacija na KV rizik. Ovie

neinvazivni metodi doveduvaat do optimalen terapiski pristap kaj pacienti so umeren i visok KV rizik.

Keywords: miokardna scintigrafija, kalcium skor, koronarna arteriska boleost

13

Abstract No. **40**

Theme: **Echocardiography and other imaging techniques in cardiology**

Country: **Croatia**

Role of transesophageal echocardiography in detection of intracardial masses

Vincelj J¹

Institute of Cardiovascular Diseases, Dubrava University Hospital, School of Medicine, Zagreb, Croatia¹

The diagnosis of intracardial masses is very complicated because clinical findings show a great variety of symptoms. The clinical manifestations of intracardial masses are heart failure, chest pain, stroke, arrhythmias, fever and anemia. Transesophageal echocardiography (TEE) is currently considered as a fundamentally important method for identifying intracardial masses. Approximately 15-20% of cerebral infarctions are cardioembolic in nature. The detection of sources of embolism is the main indication for TEE in many of the medical institutions .

Intracardial masses include tumors, thrombi and vegetations on both native and prosthetic valves. Embolic events are related with various risk factors such as the presence of thrombi in the left atrium, left atrial appendage and in the left ventricle. Recently recognised risk factors are patent foramen ovale, atrial septal aneurysm, mitral valve strands, mitral annular calcification and aortic atherosclerotic plaque. The sensitivity and specificity for TEE in detecting left atrial appendage thrombi is 100%, while only 5-10% for transthoracic echocardiography (TTE). 3D and 4D TEE has been more commonly used in diagnostics in the last ten years. The sensitivity of this new methods in diagnosis of intracardial masses is similar to 2D TEE, while its specificity is much higher (100%). The presence of thrombi in the left atrium is frequently correlated with spontaneous echo contrast which is a sign of low flow state in the atrium. Intracardial masses can easily be detected by TEE. Detection of intracardial masses often represents a difficulty for TTE due to its smaller dimensions or location in the left atrial appendage or the right atrium that cannot be adequately analysed by this technique. Diagnostic problems also occur in patients with poor „echo window“ and patients on mechanical ventilatory support. Several studies have demonstrated a great diagnostic potential and high sensitivity and specificity of TEE in detecting cardiovascular sources of embolism.

Conclusion: TEE is a safe procedure which is more sensitive than TTE for the diagnosis of intracardial masses. TEE is important for risk stratification and influences medical or surgical therapy in patients with thrombus, vegetations, tumor, aortic atheroma and other risk factors for embolic events.

Key words: Transesophageal echocardiography, intracardial masses

14

Abstract No. 42 p

Theme: **Echocardiography and other imaging techniques in cardiology**

Country: **Macedonia**

Atrial fibrillation, a condition after electrical cardioversion, complications, course of illness, case report (our experiences)

Mitevski D

Health facility "Multimedika DM", specialized practice in Intrena Medicine and Cardiology, Kumanovo, Macedonia

Purpose: Atrial fibrillation as an arrhythmia in the elderly is a major and serious risk factor for sudden death. The purpose of this paper is to present a patient with atrial fibrillation.

Case: We analyzed a patient, male, 73 years old, who came for the first time in our clinic with atrial fibrillation in 2010. The patient was obese (height of 195 cm, weight 124 kg). Because of his former profession he had medical examination by an internist and cardiologist every year. Nothing pathological had ever been registered. For the first time, after emotional stress and family tragedy as a provocation, he felt fatigue with difficulty breathing and two chest pains.

We made a 24 h Holter ECG monitoring, in which we registered R - R intervals greater than 2 seconds (18 in number) in the period from 20pm to 06 am, with a drop of up to 25/min HR in a period of wakefulness. Arterial tension was BP = 135/85 mm Hg. He had mild dyslipidemia, on Echocardiography he had normal dimension and preserved LV systolic function, other tests were normal. Electrical cardioversion was made within 7 days after the first review. The procedure was successful, cardioversion and cardiac action was restored to sinus rhythm. After 14 months the patient felt vertigo, fatigue and dyspnea during walking. On 24h Holter ECG was registered atrial fibrillation, with 43 pauses more than 2 seconds. Because of the possibility of sudden death, electrical cardioversion was made, which was successful and heart rate had returned to sinus rhythm. The patient continued on medical therapy. After one year the patient came again in our office with recurrence of fatigue, palpitations, insomnia. The new ECG and the new 24 x ECG Holter monitoring was without atrial fibrillation. We made thyroid hormone status. The increase of TSH was found. We diagnosed hypothyroidism, appropriate therapy was prescribed. Patient is in good condition, without symptoms.

Conclusion: Atrial fibrillation can be a reason for deterioration of clinical condition. Several conditions can be a reason for arrhythmias.

15

Abstract No. 48 p

Theme: **Echocardiography and other imaging techniques in cardiology**

Country: **Macedonia**

TRANSCARANIAL VASCULAR COLOR DOPPLER ANGIODYNOGRAPHY OF THE MAIN BRAIN ARTERIES, DIAGNOSIS OF ANEURYSM - CASE REPORT

Madžarov S., Novakoska - Dujković S., Mangu V., Jankuloska M.

pho POLYCLINIC * CARDIOLAB MADŽAROV * , Ohrid

44 year old female with arterial hypertension, a condition after popliteal deep vein thrombosis,

obesity, a family history positive for cerebrovasc. disease, consult us for Transcranial color Doppler - angiography (TCD) of the brain arteries due to cerebral insult (with left-sided hemiparesis) get about 3 weeks before the examination in our Polyclinic. We performed TCD using sectoral multifrequency probe GE Vivid 3 with a target frequency of 2.5 MHz with transtemporal insonation of standard bilateral approach (for a. cerebri media and the Willis circle arteries imaging) and suboccipital (for basilar artery and branches imaging). From left-sided projection with transtemporal color Doppler in segment fit a. cerebri anterior we got image that impressed on suspected globular formation with diameter cca 9mm, so with color Doppler, that and also with Power angio we concluded that it is very possibility for the aneurysm vessel malformation. The patient was sent to MNR scan with contrast, then was made pancerebral angiography (PA) and it was confirmed our suspicion of nonhaemorrhagic aneurysm localized of the cavernous segment of the left distal internal a. carotis. Lack in locating the aneurysm with TCD compared to the same with the PA we can explain due to proximity of arteries and in terms of superposition in B-mode - 2D view also obtained the impression that it is a. cerebri anterior aneurysm. Subsequently the patient was scheduled for neurovascular surgical treatment and was resolved by placing the stent assisted coiling. Conclusion: Transcranial vascular color Doppler - angiography is multidisciplinary method used in the basic non-invasive (cerebro) vascular diagnostics. Our 6 year experience of using this method in our practice of internal medicine and cardiology contributed most in the differential diagnosis of the major aneurysmal malformations of main branches of the intracranial arteries. Despite such finds are rare, unfortunately so far we have only meager results for complete treated cases as hereinabove. In the hands of experienced personnel TCD is not only useful but it is quite rely noninvasive method in cases indicated above & other risk groups of patients often means preventing the emergence of new and the prevention of recurrent cerebrovascular adverse and fatal accidents. Keywords: transcranial vascular color Doppler, angiography, brain aneurysm

16

Abstract No. 50 p

Theme: **Echocardiography and other imaging techniques in cardiology**

Country: **Croatia**

CARDIORENAL EFFECT OF ANEMIA TREATMENT IN PREDIALYSIS CHRONIC RENAL DISEASE

Balenović D.¹, Horvat I.¹, Prkačin I.², Počanić D.², Cavrić G.²

General Hospital „Dr. Ivo Pedišić“, Sisak, Croatia - ¹; Internal Clinic, University Hospital Merkur, Zagreb, Croatia - ²

Introduction: Cardiovascular (CV) diseases are responsible for the deaths of over 50% of patients (P) with chronic kidney disease (CKD) before starting replaced kidney treatment. More than half of P in predialysis CKD suffer from anemia (A). A increases progression of CKD, is linked to higher CV morbidity and mortality, and has a negative impact on quality of life (QoL).

Predisposing factors of A are: insufficient production of erythropoietin (EPO), suppression of erythropoiesis, decreased lifetime of red blood cells, blood loss and nutritional factors.

Patients and methods: 48 predialysis P (56% age>65) with A (hemoglobin-Hb <11g/dl, measured twice in two weeks) started EPO-beta 4000 IU sc once a week. 31 P (64%) were receiving EPO 7-11 months, 10 P (19%) up to 12 months and 8 P (17%) >18 months. Iron therapy was given orally in 25 P (52%) and parentera in 3 P (6%). Estimated glomerular filtration rate was measured according to the MDRD equation: eGFR-MDRD <60 ml/min/1.73m² (CKD stage 3-

5).

Cardiac status was monitored on the beginning and at the end of the study, with determination of troponin I (TnI) and heart ultrasound.

Results: Hb levels prior to study entry were 8,4 -10,9 g/dL. Elevated TnI levels (due to ischemia caused by A, with no signs of acute coronary incident) was observed in 25% of P. Left ventricular hypertrophy (LVH) was present in 60% of P, 90% had diastolic dysfunction and 10 % reduction of ejection fraction.

38% of P completed the study after one year: P who achieved Hb level 11-12 g/dl had a better QoL, stable renal function without further progression of CKD, lower frequency of hospitalization. Levels of TnI was lower than the initial, control heart ultrasound findings without further progression of LVH and some P had improvement in diastolic function.

Conclusion: Adequate and timely anemia treatment in predialysis CKD can slow the progression to the final stage and slow the development of CV diseases. EPO treatment could have its effects over the effect on endothelin, which has implications on renal and CV physiology and pathophysiology.

Keywords: anemia, cardiovascular disease, left ventricul, predialysis chronic renal disease

17

Abstract No. 64

Theme: **Echocardiography and other imaging techniques in cardiology**

Country: **Bulgaria**

Plasma Heme oxygenase-1 and chronic heart failure: diagnostic opportunities

Vitliyanova K¹, Hairabedian S²

Sofia University "St. Kliment Ohridski", Medical Faculty, Dept. of Internal medicine, pharmacology and clinical pharmacology, pediatrics, epidemiology, infectious and skin diseases, Sofia, Bulgaria¹, Institute of biology and immunology of reproduction, Bulgarian Academy of Sciences, Sofia, Bulgaria²

Objective: We investigated whether Heme oxygenase-1 (HO-1) is changed in cronic heart failure (CHF) patients and whether plasma HO-1 measurements provide a peripheral biomarker of the disease.

Methods: Plasma HO-1, were measured in 24 normal controls (NEC) and in 53 consecitive patients with CHF admitted to the Clinic of Cardiology over the period May 2010 - January, 2011. Systolic dysfunction was defined at left ventricle ejection fraction (LVEF) < 40%.

Standardised protocol was used for collecting information on the investigated variables of interest. Plasma HO-1 and Brain natriuretic peptide (BNP) were measured with immunoassays. Depending on the distribution variables are reported with mean and median. Associations of the variables with HO-1 were investigated with linear regression analyses.

Results: Plasma HO-1 concentrations (ng/ml) were significantly lower in CHF patients (median 2.58, range 0.5-7.3) compared with NEC (median 5.2 range 1.2-12.2) ($p < 0.01$). Circulating BNP levels were not significantly correlated with plasma HO-1 levels. There was a significant negative correlation between HO1 and serum total bilirubin ($p < 0.05$). A negative weak correlations were also observed with functional class ($p < 0.05$) and atrial fibrillation ($p < 0.05$). Plasma levels of HO-1 showed a significant considerable positive correlation with left ventricle (LV) dimensions values. Independent predictive effects on HO-1 levels in multiple regression

analysis ($F=8.2$, $p<0.01$) were explored for the values of the LV end-diastolic volume and atrial fibrillation.

Conclusion: Plasma HO-1 are decreased in patients with CHF. Levels of HO-1 are independently correlated to the degree of cardiac enlargement. Further studies are needed on the concrete mechanisms of the deranged HO-1 regulation in CHF patients.

18

Abstract No. **65**

Theme: **Echocardiography and other imaging techniques in cardiology**

Country: **Macedonia**

Carotid ultrasound measurements in coronary artery patients

Bosevski M

University Cardiology Clinic, Skopje, Macedonia

The study was aimed to determine carotid ultrasound (CU) measurements in coronary artery (CAD) pts and their relations with severity of CAD and presence of risk factors.

CU screening was done in 198 pts with CAD, confirmed with angiography. The study was designed as a cross sectional.

Advanced CU found carotid total plaque thickness (TPT) of 3,08 mm, and area of largest carotid plaque (PA) of 0,23 cm². 75% of pts referred PA greater than 0,10 cm². Echolucent plaques were found in 16% of pts. Multiple regression analysis defined Gensini score and multivessel CAD as independent factors for TPT. PA was independently influenced with presence of dyslipidemia and carotid stenosis.

Results do have importance for CU screening programs in CAD population.

Keywords: carotid ultrasound, carotid plaque, carotid stenosis, coronary artery disease, dyslipidemia,

19

Abstract No. **66**

Theme: **Echocardiography and other imaging techniques in cardiology**

Country: **Macedonia**

EARLY EXERCISE STRESS TESTING AFTER PRIMARY PERCUTANEOUS CORONARY INTERVENTION IN THE LIGHT OF NEW SCIENTIFIC DATA

Davceva Pavlovska J¹

University Clinic of Cardiology, Skopje, R.Macedonia¹

Background: Percutaneous coronary interventions (PCI) are the most frequently performed cardiovascular procedures. Approximately one million percutaneous coronary interventions are performed annually in the United States. There are conflicting opinions and no good consensus as to whether or not patients should undergo routine stress testing post PCI. The charge for a treadmill stress test with myocardial perfusion imaging (MPI) is approximately \$1000. This equates to one billion dollars per year for stress testing alone in this group of patients. Whether or not to perform routine stress tests with MPI post coronary intervention is, therefore, not only an important clinical question, but a major health-care economic issue as well.

The aim of this study: Two questions are still actual: Is early exercise stress testing after

coronary stenting safe? What is the utility of routine exercise treadmill testing early after percutaneous coronary intervention?

Methods: Decision for early stress testing after coronary stent implantation should include following realities: clinical indication, safety of the test, test gain and risk of the test. To solve these dilemmas we have made analysis of some relevant clinical investigations.

Results: Journal of American College of Cardiology(JACC), May 2, 2011: Early exercise after coronary stenting is safe. Rozetta registry is the first prospective study trying to address this question about the utility of routine functional testing after percutaneous transluminal coronary angioplasty. Dr Eisenberg has published the ADORA Trial, a randomized, prospective trial that was underpowered to detect differences in clinical events, but nonetheless concluded that routine functional test post PCI is not indicated. In this study were included 136 patients who underwent routine ETT at 6 weeks post- PCI. ETT was classified as positive, indeterminate, or negative. ETT results were : 23.5% positive, 17.6% interdeterminate and 58.8% negative. At 9 months, the composite events rate was 21.9% in those with positive ETT, 20.8% in those with an indeterminate ETT and 12.5% in those with negative ETT.

CONCLUSIONS: In the current PCI era, medical therapy and stent design have led to better outcomes and subsequently to an overall lower pretest probability of restenosis and MACE. General analysis showed that routine stress testing or stress imaging post – PCI should be discouraged.

Keywords: exercise stress testing, PCI

20

Abstract No. 68

Theme: **Echocardiography and other imaging techniques in cardiology**

Country: **Macedonia**

Economic Burden of Atrial Fibrillation

Gjorgov N. - ¹

Polyclinic Akus Medikus - ¹

Atrial fibrillation is a common cardiac arrhythmia that is characterized with fast and irregular heart rhythm. The fibrillating atria lead to loss of synchronous activity between the atria and ventricles that further leads to heart failure with deterioration of cardiac output, as well as the formation of thrombotic materials within the atria that are often the source of thromboembolic complications.

The incidence of atrial fibrillation is in dramatic rise especially in adult population, and it's considered that one in four persons above the age of forty at some point in their life will suffer from atrial fibrillation. Framingham study clearly associated atrial fibrillation with increase in mortality and the significant rise in ischemic stroke. It also showed that atrial fibrillation often coexists with other cardiovascular conditions that often lead to deterioration of prognosis of these conditions.

In many developed countries management of atrial fibrillation can be viewed as: (1) expenditures toward the health care system; (2) direct expenditures; and (3) non-financial expenditures.

This paper attempts to present certain aspects of the economic burden of management of patients with Atrial fibrillation and the cost toward the Health care system and patients.

Keywords: Atrial fibrillation

21

Abstract No. **84** p

Theme: **Echocardiography and other imaging techniques in cardiology**

Country: **Macedonia**

Acute treatment of deep venous thrombosis with pulmonary embolism and one year follow up

Kovacevic D¹, Projevska D¹, Dushkoski D¹

K.H. Acibadem - Sistina, Skopje¹

Materials and methods: EKG, Echo - cardiogram, CT helical scan, venous ultrasound, biochemical markers, Fybrinolytic therapy.

Our Patient was a 55 years old which was treated for the symptoms of chest pain and dyspnea as a pneumonia for several days. After one week symptoms reoccurred and he was hospitalized treated with unfractionated heparin. Due to non-improvement of the symptoms he was transferred to our hospital and after a confirmation of diagnosis with EKG, Echo-cardiography, Helical CT scan, ultrasound of veins of lower limbs, he was treated with fibrinolytic therapy. Improvement of symptoms were significant in short period of time and he was discharged. Patient was put on an oral anticoagulant therapy with rivaroxaban. The follow up was with regular monthly visits and a control of recanalisation of venous system of right lower limb. Six month's control was performed a Helical CT scan of pulmonary arteries which showed recanalisation of pulmonary arteries in most of the areas, with some residual and organized parts.

Conclusion:

Treatment of deep venous thrombosis with fibrinolytic therapy helps improving patients condition in acute period and improves final outcome in preserving the function of lungs and right side of the heart, as well as function of venous system in lower limbs.

Keywords: EKG, Fybrinolytic therapy, thrombosis, pulmonary embolism, recanalisation.

22

Abstract No. **85** p

Theme: **Echocardiography and other imaging techniques in cardiology**

Country: **Macedonia**

Exercise test, Nt proBNP and echocardiographic paramaters in asymptomatic ptc. with severe valvular aortic stenosis

Antova E¹, Georgievska-Ismail Lj¹, Srbinovska E¹, Peovska I¹, Otljanska M¹, Andova V¹, Zanteva-Naumoska M¹

University Clinic of cardiology-¹

AIM: Assess the significance of the echocardiographic, exercise test (ET) parameters as predictors of occurrence of symptoms and/or death, and relation of the Nt – proBNP value to the echo and ET parameters in asymptomatic ptc with severe AS (ASAS).

MATERIAL: 58 ASAS ptc with normal left ventricle function EF>50%., monitored for 02-36 months with median follow up period of 19.5±10 months.

RESULTS: ECHOCARDIOGRAPHY: LVEDd (mm) 50.9±5.5; LVEDs (mm) 29.3±5.5; EF (%)69.5±5.2; AV_Vmax (m/s) 4.3±0.5; AV_Max Grad (mmHg) 75.5±20.6; AVA (cm2) 0.7±0.2; IVSd (mm) 14.6±1.8; LVPWd (mm) 11.5±1.8.

Ptc with AVA<0.7 cm2 had 6.7 times greater chances to get abnormal answer SBP in ET vs ptc with AVA≥0.7cm2.

25% have annual progression rate of the AV_Vmax \geq 0.3 m/sec/year.
Median Nt - proBNP in ASAS ptc was 404 \pm 425 (pg/ml).
Exercise test (symptom limited, modified standard Bruce protocol treadmill test performed to ptc age \leq 70): 44 ptc (76%) – positive ET and 14 ptc (24%)- negative ET.
Occurrence of event in 30% and they all are in the group with positive ET.
Out of 44 ptc with positive ET, symptoms occurred in 27.3%.
Analysis of predictors of events showed that only occurrence of symptoms during ET with OR 4.63 (95%CI 1.16-18.56) was confirmed as statistically significant (SS) predictor which increases the chances for event by 4.63 times. (p=0.03)
Event free survival for a median follow up period of 19 \pm 10 months (2-36) was found in less than 5% of ptc with symptoms at ET and in 50% of ptc without symptoms at ET.
69% of ptc had abnormal SBP response during ET (if the increase of SBP was less and/or equal to 20 mmHg or in case of SBP drop) and 31% had normal SBP response during ET (where SBP increase is greater than 20 mmHg).
There is SS negative correlation between higher values of Nt-proBNP and small SBP increase during ET (r=-0.21, p=0.03).
Nt-proBNP has positive correlation with: occurrence of ST-segment depression during ET (r=0.28, p<0.03) and occurrence of positive exercise test (r=0.38, p<0.003).
After 36 months, only 21% of the ptc with abnormal SBP response to ET will have event free survival vs. 75% of the ptc with normal BPS response to ET.
The change of SBP during ET with OR 0.95 (95% CI 0.91-0.99) proved as SS predictor in making the decision for referral of ASAS ptc to aortic valve replacement (AVR). (p=0.01).
Conclusion: in addition to the echo parameters, Nt-proBNP from serum and ET parameters only in real ASAS ptc with severe AS have enormous predictive significance in revealing of the risk group that will experience rapid worsening and possible death in order to refer them to AVR in time.

Keywords: valvular aortic stenosis, exercise test, Nt proBNP, echocardiography

25

Abstract No. 86 p

Theme: **Echocardiography and other imaging techniques in cardiology**

Country: **Macedonia**

Nt proBNP and echocardiographic parameters in severe valvular aortic stenosis

Antova E¹, Georgievska-Ismail Lj¹, Srbinovska E¹, Peovska I¹, Kostova N¹, Davceva-Pavlovska J¹, Zanteva-Naumoska M¹

University Clinic of Cardiology-¹

Aim: To assess the significance of Nt-proBNP and echo parameters as predictors for occurrence of symptoms and/or death and identify their interconnection, especially the predictive value of Nt-proBNP in ptc without significant CAD of coronary angiography.

Material: 187 ptc with severe valvular aortic stenosis (AS) with normal LV function with EF>50%. Asymptomatic ptc (ASAS ptc): 61 ptc (33%), monitored for 02-36 months, median follow up period 19.5 \pm 10 months. Symptomatic ptc (SAS ptc): 126 ptc (67%) monitored for 03-88 months, median follow up period 25.4 \pm 16.4 months.

Methods: echocardiography, Nt-proBNP (pg/ml) (serum). Results: ASAS ptc/SAS ptc: LVEDd

(mm) $50.9 \pm 5.5 / 53.1 \pm 5.9$ ($p=0.01$); LVEDs (mm) $29.3 \pm 5.5 / 32.8 \pm 6.8$ ($p=0.001$); EF (%) $69.5 \pm 5.2 / 65.1 \pm 8.4$ ($p=0.0001$); AV_Vmax (m/s) $4.3 \pm 0.5 / 4.7 \pm 0.6$ ($p=0.0001$); AV_Max Grad (mmHg) $75.5 \pm 20.6 / 90.2 \pm 26.2$ ($p=0.0001$); AVA (cm²) $0.7 \pm 0.2 / 0.6 \pm 0.1$ ($p=0.16$); IVSd (mm) $14.6 \pm 1.8 / 15.0 \pm 2.3$ ($p=0.12$); LVPWd (mm) $11.5 \pm 1.8 / 11.9 \pm 2.1$ ($p=0.15$).

SAS ptc with more severe disease have higher values of Nt-proBNP. Nt-proBNP(pg/ml): ASAS ptc 404 ± 425 vs SAS ptc 901 ± 709 , ($t=5.95$, $df=177$, $p<0.0001$) ($n=187$).

We had $n=101$ ptc with severe AS without significant CAD of coronary angiography. Severe AS without CAD (101 ptc) = 708.8 ± 558 pg/ml; severe AS with CAD (41 ptc) = 830.6 ± 626 pg/ml. There is no statistical difference between the median values of Nt-proBNP between these groups ($t=-1.13$ $df=140$, $p=0.25$).

Correlations of NT-proBNP with the echocardiographic parameters: AVA $r= - 0.19$ $p<0.009$; EF $r= - 0.28$ $p<0.0001$; LVEDd $r= 0.23$ $p<0.001$; LVEDs $r= 0.28$ $p<0.0001$; IVSd $r= 0.17$ $p<0.015$; AV_Vmax $r= 0.19$ $p<0.008$; AV_MaxGrad. $r= 0.19$ $p<0.008$; LVM(g) $r= 0.32$ $p<0.0001$; LA(mm) $r= 0.23$ $p<0.001$.

The group with Nt-proBNP exceeding the cut off value of 460 pg/ml, with HR 1.828 (95% CI 1.079-3.099) has greater risk for event ($n=101$). Average survival time is shorter in ptc with Nt-proBNP ≥ 460 pg/ml ($n=187$) ($p<0.004$); which is equal for ptc without CAD ($n=101$) ($p<0.025$).

Optimal cut off value of Nt-proBNP to reveal the existence of symptoms was 460 pg/ml (sensitivity 85%, specificity 72%, positive predictive value 86%, negative predictive value 70%). Greatest predictive power for revealing of symptoms was in Nt-proBNP 0.806 (95% CI 0.731-0.881) $p=0.000$, compared to AVA 0.335 (95% CI 0.251-0.418) $p=0.000$, and AV_Vmax 0.687 (95% CI 0.606-0.767) $p=0.000$.

Conclusion: Nt-proBNP has incremental value as a predictor of future undesired events i.e. worsening of the situation in severe aortic stenosis.

Keywords: valvular aortic stenosis, Nt-proBNP, echocardiography

26

Abstract No. 89 p

Theme: **Echocardiography and other imaging techniques in cardiology**

Country: **Macedonia**

Detection of rapid progression of coronary artery disease (CAD) in women -Case report

Kostova N.¹, Otljanska M.,¹ Vavlukis M.¹, Pop Gjorceva D.², Majstorov V.², Zdravkovska M.², Stojanovski S.², Kostov I.³

University Clinic of Cardiology -Skopje¹, Institut of pathophysiology and Nuclear medicine-Skopje², University Surgery clinic "St Naum Ohridski"-Skopje

Introduction :Coronary artery disease is the leading cause of mortality both in men and women. Major risk factors like diabetes , hypertension , dyslipidemia , smoking leads to rapid progression . Additional states in women as post menopause can contribute. Atypical symptoms and disruption of the microcirculation often lead to delayed recognition and poor prognosis. Early detection and treatment are essential .

Case Report :74 year old women was admitted at the clinic because of frequent chest pains. She had a long history of hypertension, diabetes treated with oral hypoglycemic agents, dyslipidemia, hypothyroidism with stable values of thyroid hormones and chronic thrombocytopenia . The first atypical symptoms (fatigue and dispnea) appeared in 2003. Exercise test was inconclusive .

Myocardial perfusion tomography - SPECT was performed and moderate ischemia in vascular regions of RCA and Cx was detected .Patient was refer to coronary catheterization so percutaneous angioplasty was performed with stenting the both arteries . Atypical chest. pain occurred in 2013 . SPECT MPS detected ischemia in LAD vascular region .Angiography detected multi vessel disease (Syntax score 17), LAD (95 % stenosis), 100% distal RCA, pRCA instent 95 % stenosis , Cx plaque. LAD was revascularized with stenting in October 2010 . After two months typical symptoms (CCCS II) appeared rapidly progressing .In February 2014 MPS detect moderate area of ischemia along the vascular area of LAD and RCA (SSS 12) with ECG changes during pharmacological test in terms of horizontal ST depression of 2 mm in the inferior and lateral leads. Patient was admitted in hospital. Echocardiogram suggests hypokinesia of the inferior and lateral wall , hypertrophy of the septum and moderately reduced left ventricular function . Coronarography in March 2014 found 95 % LAD instent stenosis (treated with the balloon dilatation) , and 30 % instent stenosis of Cx (Syntax score 15) . Patient is on optimal drug treatment to aim rigorous risk factors reduction .

Conclusion: Multiple risk factors can lead to rapid progression of CAD, often presenting with atypical symptoms specially in women .Myocardial perfusion tomography is a powerful tool for detection and risk stratification.

Keywords: Coronary artery disease,MPS

27

Abstract No. 92 p

Theme: **Echocardiography and other imaging techniques in cardiology**

Country: **Macedonia**

Atypical symptoms in Type A aortic dissection-Case report

Kostova N.¹,Otljanska M.,¹ Vavlukis M.¹,Paljoskoska Jordanova S.¹.,Kostov I.²

University Clinic of Cardiology -Skopje¹ ,University Surgery clinic “St Naum Ohridski”-Skopje²

Background - Aortic dissection typically presents with severe chest or back pain. Neurological symptoms may occur because of ischemia of supplying vessels but when presentation is atypical diagnosis can be difficult and delayed. There are few reports of accompanied arterial thrombosis of lower extremities were hypotension or hypercoagulability states can contribute, accompanied venous thrombosis is very rare.

Case report: A 66-year-old man with history of uncontrolled hypertension and smoking was admitted to our hospital with sudden onset of back and lower extremities pain. The back pain was mild and transient accompanied with severe pain in both legs. Patient felt occasional transient back pain two week ago while he was treated with anticoagulant therapy because of deep venous thrombosis on left femoral artery. Persisting symptoms after actual hospitalization were severe pain, paraesthesia and motor deficit in both legs with flaccid paraparesis. There was significant difference in arterial pressure between right and left arm but no hypotension, hemodynamic instability and no pulse deficit on lower limbs. CT was performed and type A aortic dissection was detected with fenestration and calcification of intimal flap from sinus valsalva to aortic bifurcation with compression of true lumen. Supraaortic vessels were involved but with no repercussion on celiac, renal or mesenteric artery flow. Unfortunately patients died immediately after diagnosis was established.

Discussion and conclusions : Aortic dissection is an emergency that often results in death but

diagnosis can be difficult in presents of atypical symptoms .Sudden-onset of neurological symptoms even after transient back pain should be carefully investigated .Neurological deficit of lower extremities may be a component of anterior spinal artery syndrome. Hypercoagulability may provoke thrombosis ,arterial or venous ,particularly in prolonged states.

Keywords: Aortic dissection

28

Abstract No. 94 p

Theme: **Echocardiography and other imaging techniques in cardiology**

Country: **Macedonia**

Secondary tumor in right atrium -Case report

Otljanska M.,¹,Kostova N.¹,Pejovska I.¹, Josifovic Licoska F.,³

University Clinic of Cardiology Skopje¹, University Clinic of Gastroenterohepatology Skopje²

Background : The heart is an unusual site of metastasis from any malignancy but secondary (metastatic tumors)of the heart are more frequent than primary tumors . Metastatic tumors usually arise from lung, breast, renal cancer, melanomas, and lymphomas. Metastases may originate from blood dissemination of cancer cells, direct extension via adjacent tissues, or propagation via the superior or the inferior vena cava to the right atrium.Clinical manifestations of cardiac tumors depend on the size and location of the mass and the infiltration of adjacent tissues rather than the type of the tumor itself. Echocardiography is the main diagnostic tool for the detection of a cardiac mass.

Case Report: A 83-year-old man with recent history of symptoms and signs of congestive heart failure was admitted in our hospital. Progressive shortness of breath ,fatigue , palpitations , peripheral edema and right upperabdominal quadrant discomfort occurred in the last 2 weeks . An electrocardiogram revealed atrial fibrillation with a ventricular rate of 145 beats per minut. Echocardiography showed a 41 mm × 34 mm , spherical inhomogeneous mobile mass on the (lateral)right atrial wall. Laboratory evaluation revealed low hemoglobin 111 g/L, red blood cells $3.6 \cdot 10^{12}/L$, elevated AST41 IU/L,ALT 41 IU/L , direct bilirubin 13 umol/L, indirect bilirubin 9 umol/L, protrombin index 1.53, prolonged PTT 16.4. Ultrasound evaluation showed increased liver with altered microstructure and polycyclic large tumor mass in the right lobe indicated primary hepatic tumor. Liver biopsy confirmed the diagnosis.

Conclusion: Metastatic tumors of the heart are more frequent than primary tumors .They must be carefully investigate to find the primary source. Primary liver tumors are very rear source of secondary tumors of the heart.

Keywords: heart tumor

29

Abstract No. 95 p

Theme: **Echocardiography and other imaging techniques in cardiology**

Country: **Macedonia**

Totalna kavo pulmonalna anastomoza kaj pacient so edinstvena komora, malpozicija na golemite krvni sadovi i stenoza na pulmonalnata arterija (prikaz na slucaj)

Gjurkova Angelovska B¹, Kacarska R¹, Maneva Kuzevska K¹, Jovanovska V¹, Neskovska Sumenkovska M¹

Univerzitetska Klinika za detski bolesti, Skopje, Makedonija

Prikazuvame dete so vrodna srceva mana- edinstvena komora, malpozicija na golemite krvni sadovi, stenoza na pulmonalnata arterija i belodrobna hipertoniija kaj koe e napravena operacija vo dva akta. Dijagnoza na vrodna srceva mana e postavena vo raniot neonatalen period.

Na voзраст od 4 meseci po prethodna kateterizacija e realizirana operacija-bidirekionalna Glen anastomoza (megju vena kava superior i desna belodrobna arterija) i atrioseptomija.

Postoperativniot period bil teok so izrazena hipoksemija, belodrobna hipertoniija i srceva slabost nadminati so soodvetna terapija.

Na voзраст od 3 godini i 3 meseci po prethodna kateterizacija e realizirana vtora operacija - totalna kavo pulmonalna anastomoza. Vo postoperativniot tek deteto imalo obstani pleuralni izlivi, poradi sto e napravena drenaza. Deteto e postaveno na terapija so Sildenafil.

Keywords: vrodni srcevi mani, totalna kavo pulmonalna anastomoza

30 Abstract No. 96p

Theme: **Ехокардиографија и другите имиџинг техники во кардиологијата**

Country: **Macedonia**

TRUNCUS ARTERIOSUS

Kacarska R, Maneva Kuzevska K, Gjorkova Angelovska B, Shumenkova Neshkovska M, Sofijanovska A, Jovanovska V, Pascalov G, Nonkulovski D.¹) Cadikovski V. ²)

University Clinic for Children's Diseases Skopje ¹) University Clinic of Pediatric Surgery Skopje ²)

Truncus arteriosus (T.A) is a rare congenital malformation accounting for about 4% of all heart defects. A single great artery arising from the heart provides systemic, pulmonary and coronary circulation. It contains a single truncal valve (TrV) and overrides both ventricles. Under a single truncal valve (TrV) there is usually also a large ventricular septal defect (VSD). Based on the site of origin of the pulmonary arteries (Pas) from the common arterial trunk four different types of T.A. are recognized. Echocardiography is a standard diagnostic technique. It shows TrV anatomy and function, the origin of Pas, aortic arch anomalies and the location of the VSD.

Aim: To present surgical approach and cardiological follow up in 2 patients with truncus arteriosus.

Case report: We present two patients with this rare anomaly who were diagnosed in infancy (at the age 4 and 6 months). Complete open heart repair was performed with good results during the first year of life. Both children were followed up with ECG, echocardiography ,chest X-ray and CT-scan angiography. Both patients became symptomatic with clinical presentation of heart problem, dyspnea, tachycardia, frequent respiratory infections, poor feeding and poor weight

gain at the age 8 and 12 years respectively. In both cases prompt diagnostic evaluation with chest X-ray and CT scan angiography showed calcification of the conduits. Echocardiography showed hypertrophy of the right ventricle as a result of a restricted conduit of pulmonary artery. Upon primary stabilization with therapy, they were referred to the cardio-surgical center for the replacement of conduits.

Conclusion. TA is a severe congenital cardiopathy that should be meticulously followed up due to the risk of calcification of the implanted conduits.

Keywords: Truncus arteriosus, Congenital heart disease , Conduit

31

Abstract No. **99** p

Theme: **Echocardiography and other imaging techniques in cardiology**

Country: **Macedonia**

“Non compaction” cardiomyopathy (case reports) in a correlation with other cardiomyopathies

B. Stefanovska, M. Bogeska Blazhevaska

PHO KARDIOMEDIKA SRBINOVSKI, Skopje, Macedonia

Aim of the study: The aim of the study is presentation of 2 cases with non compaction cardiomyopathy and their representation in terms of other types of cardiomyopathies in non selected population of patients with cardiovascular diseases in PHO-Kardiomedika Srbinovski in a period of years 2012-2014.

Material and methods: In a period of 3 years we made an analysis of patients with cardiomyopathy using disease history, clinical examination, electrocardiography, Color-Doppler echocardiography and 24-hour Holter ECG monitoring.

Results: Of the analyzed 66 patients with diagnosed cardiomyopathy, 49 (74 %) were male, 17 (26 %) were women, aged 42 to 91, average 68.66 +/- 8.6 years. Of these patients 48 patients (72.8%) were with dilatative ischemic cardiomyopathy, 8 (12.1%) patients with primary dilated cardiomyopathy, 7 (10.6%) with primary hypertrophic cardiomyopathy, 1 (1,5%) with restrictive cardiomyopathy and 2 (3%) patients were with "non- compaction" cardiomyopathy.

Case report number 1: Male patient 44 years old is on a chronic hemodialysis because of polycystic kidney disease. According to the clinical presentation NYHA functional class is III. ECG findings was with signs of volume overload of the left ventricle. Echocardiographic findings showed increased dimensions the left ventricle, with a moderate reduction in global left ventricular systolic function, diastolic dysfunction and trabeculation of the myocardium of the left ventricle. In accordance with echocardiographic criteria this patient was diagnosed as "non-compaction" cardiomyopathy. Holter monitoring showed numerous non specific rhythm disorders (supraventricular extrasystoles, polymorphic ventricular extrasystoles, single and in pairs).

A case report number 2: Male patient aged 41 years, came on a cardiology examination because of irregular heartbeat and fatigue. NYHA functional class was II. Color - Doppler echocardiography showed lightly increased dimensions of the left ventricle, moderate reduction of systolic function of the left ventricle and trabeculation of the distal third of the left ventricle which indicated the diagnosis - "non- compaction" cardiomyopathy. The Holter ECG for 24 hours - 2 % ventricular ectopic activity, with polymorphic ventricular ectopic beats and short

episodes of ventricular tachycardia.

Conclusion: Color Doppler echocardiography plays an important role in the differentiation of types of cardiomyopathy, which is important in terms of strategy for the treatment of patients. The diagnosis of "non-compaction" cardiomyopathy is of great importance because of the risk of developing heart failure, life-threatening arrhythmias and embolic complications, in this type of patients.

Keywords: cardiomyopathy, ischemic, dilatative , hypertrophic , restrictive , non compaction cardiomyopathy.

32

Abstract No. **102** p

Theme: **Echocardiography and other imaging techniques in cardiology**

Country: **Macedonia**

Syncope as the first manifestation of the Wolf-Parkinson-White (WPW) syndrome

M . Bogeska Blazhevska, B . Stefanovska

PHO KARDIOMEDIKA Srbinovski

WPW syndrome is a congenital disorder of the conduction system of the heart which occurs as a result of the presence of an abnormal accessory electrical conduction pathway between the atria and the ventricles of the hearth. Electrical signals travelling down this abnormal pathway (known as the bundle of Kent) may stimulate the ventricles to contract prematurely, resulting in a unique type of tachycardia known as atrioventricular re-entry tachycardia. The electrocardiographic (ECG) recording appears widened QRS complex and the presence of a delta wave . Prevalence rate is 0.1-0.3% in the general population , and in the majority of patients the first symptoms of WPW syndrome occurs between 10-50 years of age.

A case report: Female patient SA , born 1982, first cardiac examination at her 32 years. Ten days before the examination in our institution , after taking blood for laboratory analysis , the patient felt difficult breathing, general weakness, palpitations, transient loss of consciousness, the symptoms that she never felt before. The ECG showed widened QRS complex and the presence of delta wave, suggesting WPW syndrome with normal heart rate, that passed spontaneously in sinus rhythm . The patient objective and laboratory findings were normal. Echocardiographic findings - normal dimensions of the left ventricle with a normal systolic and diastolic function of th left ventricle. There was a indication for 24 -hours Holter monitoring . During Holter ECG monitoring there were recorded a total number of 125,331 QRS complexes. WPW syndrome was present at 54 % of the time of the Holter ECG monitoring with spontaneous transitions to sinus rhythm . In periods when WPW syndrome was present maximum heart rate was 156 bpm, and the heart rate was above 100 bpm in 35 % of the time. Average heart rate was 80 bpm . During Holter ECG monitoring nonsignificant ventricular ectopic activity was registered.

Conclusion : After all examinations and test , we confirmed the presence of WPW syndrome with syncope as first manifestation. There is indication for electrophysiological study in this patient.

Keywords: WPW syndrome, syncope, palpitations, widened QRS complex, delta wave, electrophysiological study.

Correlation of coronary artery occlusion and right ventricular infarction

Andova V, Srbinovska-Kostovska E, Georgievska-Ismail Lj, S.Kedev, E.Caparoska, P.Zafirovska, M.Miletic

University Clinic of Cardiology

Background: Proximal right coronary artery (RCA) occlusion is the culprit commonly responsible for acute right ventricular (RV) infarction (RVI). Although the effects of reperfusion in patients with left ventricular infarction, the benefits in patients with acute right ventricular infarction are less clear.

Methods: In 122 hospitalized patients with acute myocardial infarction we assessed the prevalence and diagnosed accuracy of ECG changes and echocardiographic assessment to identify right ventricular involvement. RVI was diagnosed with the fulfillment of at least two of the following electrocardiographic criteria: ST elevation ≥ 1 mm in the right precordial leads, especially V4R; ST elevation in D3 being more than that in lead D2; reciprocal ST depression in leads D1 and aVI > 2 mm in total and/or ST elevation in D3 being more than depression in lead V2.

Results: Right ventricular involvement was present in 58 patients (47,54). 52 patients with RVI and 59 patients without RVI were treated with emergency angiography. Pathologic changes (stenosis ≥ 50 -99% or occlusion 100%) on right coronary artery was registered in 49 patients with RVI (94.2%) and in 29 (49.2%) without RVI ($p=0.0001$). We used logistic regression analysis as a statistical method where all coronary arteries were independent markers for existence of RVI estimated by electrocardiography. We determined that the patients with pathological changes on RCA for 4.9 times (OR=4.941;95% CI:1.727-14.136; $p=0,003$) have higher risk for RVI than the patients without pathological changes of RCA. This is statistical considerable risk. The analysis determined that the patients with pathological changes of left descendens artery have statistical considerable for 0,2 times lower risk for RVI (OR=0.209;95% CI:0.84-0.524; $p=0.001$). Accuracy of this model to divine present RVI of distribution on pathological changes of coronary artery have 85.7 sensitivity and 65.4 specificity.

The highest sensitivity for present of RVI determined presence of pathological changes of RCA, the highest specificity (to throwing off for present of RVI) have pathological changes of LAD.

The analysis of localisation of RCA pathological changes in patients with RVI demonstrate statistical significant often present of proximal lesion (26patients,55.3%) , middle lesion (8patients,17%) and/or distal lesion (13 patients,27.7%) on coronary artery ($p=0.001$)

Conclusion: RCA occlusion compromising right ventricular branch perfusion commonly results in RV ischemic dysfunction. Pathological changes on proximal RCA demonstrate statistical significant often insensibility in patients with RVI.

Key words: RVI; RCA occlusion; RCA lesion

Улога на медицинската сестра во исведување на стрес ехокардиографија

**Степановска Д, Гроздановска Д, Петковска Д, Јакимовска Р, Ангелковска О
Универзитетска Клиника за Кардиологија**

Стрес ехокардиографијата е семи-инвазивен метод, во која медицинската сестра има големо знаење за успешноста на процедурата. При фармаколошката стрес-ехокардиографија се аплицираат лекови по протокол, а се користат различни протоколи кои ги одредува докторот, во зависност од индикацијата за стрес ехокардиографија и контраиндикациите за примена на лекот-стресор.

Тек на процедура: По одредување на Протоколот кој ќе се спроведува од докторот, во отворената листа на протоколот се запишува телесната тежина и висина, се одредува според таблица дозата на лекот- стресор и во зависност од стресорот се спрема материјалот за апликација. Пред почетокот на процедурата се запишуваат во листата крвниот протисок и срцевата фреквенција, се прави електрокардиограм пред почетокот на процедурата. По пополнувањето на почетните параметри се стартува време за изведување на протоколот кое сестрата го прати заради зголемување на дозите на лекот.

Електрокардиограм се прави и на крај на тестот, но може да биде направен и ако се појави болка или по назнака на доктор доколку се оцени дека тоа е потребно. За спроведување на тестот потребно е да се постави венска линија каде би се аплицирал лекот. Пред почетокот на тестот, во зависност од протоколот се спрема терапија доколку се случат одредени несакани дејства или компликации како појава на болка, промени на ЕКГ, пореметувања на ритмот.

За време на апликација на стресорот може да се јават одредени компликации, од појава на болка без промени на ЕКГ-то до појава на болка и промени на ЕКГ-то, кои можат да бидат причина за прекин на тестот, како и за соодветен дополнителен третман. Во овие случаи медицинската сестра има извонреден значај во забележување на симптомите и акутниот третман на настанатата компликација. Иако ретко, може да се случи и реанимација заради настанати малигни пореметувања на ритмот, за која е неопходно координација на докторот и сестрата во спроведување на соодветна терапија.

Заклучок. Фармаколошката стрес ехокардиографија е метод кој бара спроведување на одредени процедури според протокол, во кои сестрата има значајна улога во спроведувањето на истиот. Исто така има значајна улога при појава на несакани случувања и компликации и нивно надминување.

35

Abstract No. **105** p

Theme: **Echocardiography and other imaging techniques in cardiology**

Country: **Macedonia**

Left atrial thrombus in mitral stenosis with atrial fibrillation

Tupare S¹, Fortomarska Mileska B¹, Sekuloski R¹, Kotlar M¹, Kovacheska Bashuroska E¹, Sheshoski B¹,

Institute for cardiovascular diseases, Ohrid¹

Aim: to present complication of mitral stenosis with atrial fibrillation without anticoagulant therapy

Case report : 65 year old female patient presented with 2 years history of malaise , fatigue, palpitation ,never consultet doctor. ECG showed atrial fibrillation Fr 124/min , precordial systolic murmur 3/6. Indicated transtoracic echocardiography showed normal systolic function severe mitral stenosis mild to moderated regurgitation, tricuspid valve was severely incompetent with estimated PAP 80mmHg. Left atrium was moderately dilated with suspected echogenic formation (narrow ultrasound window) Transoesophageal echocardiography(TEE) was performed with confirmation of severe mitral stenosis MV PGmean14mmHg MVA 1.1cm². TEE revealed echogenic mass/thrombus 45x30mm on the lateral wall of left atrium, also spontaneous echo contrast in left atrial appendage. Indicated surgical treatment, preoperative coronarography finding: RCA 50%

The patient underwent successful mitral valve replacement (Hancock II 29 bio), thrombectomy, tricuspid reconstruction De Vega.

Conclusion: Atrial fibrillation is common finding in patients with mitral stenosis. Frequent complication is thrombus in left atrium. Transoesophageal echocardiography is highly accurate for identifying left atrial thrombi

Keywords: atrial fibrillation, mitral stenosis , thrombus formation, transoesophageal echocardiography

36

Abstract No. **106** p

Theme: **Echocardiography and other imaging techniques in cardiology**

Country: **Macedonia**

Giant ascending aorta aneurysm

Tupare S¹, Fortomarska Mileska B¹, Donevsk Z¹, Tegovska B¹, Zimbova M¹

Institute for cardiovascular diseases, Ohrid¹

Aim: to present unusual case of enormous aortic aneurysm

Case report: Two years ago 76 years old female was admitted to the hospital with shortness of breath, hoarseness, fatigue, ventricular extrasystoles, hypertension. Transthoracic echocardiography examination showed borderline dimension of left ventricle, mild reduction of systolic function, mitral annulus calcification , mild to moderate mitral regurgitation, aortic valve tricuspid with fibrosclerotic changes, AV Vmax 3.7m/s, AVPG= 60/32mmHg, moderate aortic regurgitation. TTE revealed acending aorta aneurysm with 10.5cm diameter. The patient refuses surgical treatment despite consequences. She was advised to take medication for hypertension, regular controls. The patient did not followed the recommendation so the next control was after 2

years. She complains on malaise, but still can do ordinary activities. Control transthoracic echocardiography shows mildly enlarged left ventricle with mild to moderate reduction of systolic function. The ascending aorta aneurysm showed no progression, 10.5 cm diameter, AV Vmax 3.5m/s, AVPG 55/29mmHg, central jet of aortic moderate regurgitation. Meanwhile she has done computed tomography (no documentation) she continues to refuse operation. Conclusion : Risk of aortic aneurysm dissection/rupture correlates with diameter. According to the current ESC guidelines the threshold indicating surgical treatment in bicuspid aortic valve is 50 mm for patients with risk factors, and 55 mm for all other patients. Keywords: ascending aorta aneurysm, transthoracic echocardiography

37

Abstract No. **111** p

Theme: **Echocardiography and other imaging techniques in cardiology**

Country: **Macedonia**

INCIDENCE OF ACQUIRED AORTIC STENOSIS IN A GROUP OF ECHOCARDIOGRAPHY EXAMINED PATIENTS IN CLINICAL HOSPITAL -STIP IN THE PERIOD 01.01.2013 - 31.12.2013

Dr. Jordanova S.¹, Dr. Breslieva J.¹, Dr. Bajraktarova Proseva T.¹, Dr. Josifovska Tofilovska S.¹

Clinical Hospital – Stip

Introduction: Aortic stenosis is an obstruction of blood flow in aortic valves in the systoles of the left chamber. It can be inherited or acquired. The acquired aortic stenosis is a consequence of degenerative calcification of aortic valves in elderly population beyond 65 years of age (approximately 50-60 %) or a consequence of febris rheumatica (less than 10 %). The inherited aortic stenosis occurs due to calcification of bicuspid aortic valve (approximately 30 %). Rare causes of aortic stenosis are as follows: Fabry disease, Paget's disease, SLE, hyperuricemia and infections. Based on the surface of the valve area and the pressure gradient, aortic stenosis is classified as mild, moderate and severe.

Aim: The aim is to establish the incidence of acquired aortic stenosis in patients who have undergone echocardiography examination in an outpatients' department.

Material and methods: A retrospective study of patients in an outpatients' department having undergone echocardiography examination with 2D echocardiography, in the Clinical Hospital – Stip in the period from 01.01.2013 until 31.12.2013. Physical examination, ECG, RTG of lungs and heart and 2D echocardiography have been applied.

Results: The total number of patients examined has been 403, 168 of whom male (41.68 %), and 235 female (58.32). Aortic stenosis has been established in 38 patients (9.42 %). Fourteen (14) of them have been males of 69.64 years of age on average, whereas 24 have been females of 66.15 years of age on average. Aortic stenosis has been ascertained in 8.33 % of the total number of examined males, while aortic stenosis has been established in 10.2 % of the total number of examined females. According to the severity of aortic stenosis, the following results were yielded: mild aortic stenosis in 29 patients (76.32 %), moderate in 6 patients (15.79 %), and severe aortic stenosis in 3 patients (7.89 %).

Conclusion: Incidence of 9.42 % of acquired aortic stenosis has been ascertained and in 67.8 years of age on average. Echocardiography is the best non-invasive diagnostic method of

examination of the aortic valves' anatomy, assessment of their functioning and evaluation for a potential operational treatment.

Keywords: aortic stenosis, incidence, echocardiography.

38

Abstract No. **114** p

Theme: **Echocardiography and other imaging techniques in cardiology**

Country: **Macedonia**

Noncompacted miocardium

Paskalov Gj, Kacarska R , Kuzevska-Maneva K , Gjurkova-Angelovska B , Jovanovska V , Neshkovska-Shumenkovska M , Nonkulovski D , Stankovic V.

University children's hospital, Skopje- Macedonia

Noncompacted miocardium

University children's hospital, Skopje- Macedonia

Authors :

Paskalov Gj, Kacarska R , Kuzevska-Maneva K , Gjurkova-Angelovska B , Jovanovska V , Neshkovska-Shumenkovska M , Nonkulovski D , Stankovic V.

Abstract Noncompacted miocardium is a cardiomyopathy caused by an interruption of the myocardial intrauterine development. In some cases it can be asymptomatic, but in some it can have the usual three clinical symptoms : ventricular arrhythmia, heart failure and systemic thromboemboluses. Case presentation A 13 year old girl comes to the pediatric emergency center complaining of chest pain and fast heartbeat which began three days ago after a long basketball training . Physical exam shows tachycardia (104/bpm) and systolic heart murmur in the fourth left intercostal space. An ECG is made which shows signs of disrupted repolarization of the V5, V6 leads. The echocardiography shows hypertrophy and dilatation of the myocardium with deep recesses of the left ventricle .EF=0.68. FS=34. Lab analysis were assigned with findings of increased levels of CK=285 U/l and CK-MB=25 U/l . After establishing the diagnose of noncompacted myocardium therapy was started with Digoxin, ACE inhibitor, diuretics and Potassium inhibitors.

Conclusion 24 hour Holter is done which doesn't show episodes of non-sinus rhythm, blockage or ectopic activity. Regular check-ups of blood pressure were done and they were normal so we see that that beside the medical condition we have good myocardial activity.

Keywords: Noncompacted miocardium

39

Abstract No. **115** p

Theme: **Echocardiography and other imaging techniques in cardiology**

Country: **Macedonia**

Role of echocardiography in the diagnosis of hypoplastic left heart syndrom-A case Report

D.Nonkulovski,R.Kacarska,K.Kuzevska-

Maneva,V.Jovanovska,B.Gjurkova,G.Paskalov,V.Stankovicj,M.Neshkovska-

Shumenkovska,A.Sofijanova Cardiology Department,University Children's Hospital,Skopje,Macedonia Department of Neonatal and Pediatric Intensive Care Unit,University Children's Hospital,Skopje,Macedonia University Children's Hospital,Skopje,Macedonia

BACKGROUND AND AIMS: Hypoplastic left heart syndrome (HLHS) is characterised by left-sided heart obstruction to blood flow, occurring in fetal life. This leads to underdevelopment of the left ventricle and the left ventricular outflow tract which impairs the systemic circulation making it foramen ovale and ductus arteriosus-dependent in the initial days of life.

MATERIAL AND METHODS: We present a case of a few hours old newborn with a complex congenital heart defect diagnosed by echocardiography after birth.

RESULTS: Cyanosis was noted immediately after the patient was born. It was suspected that this is due to a complex congenital heart defect (CHD). Therefore the child was transferred to the ICU Department at our clinic where it underwent an extensive physical, laboratory, radiology and echocardiographic evaluation. The echocardiogram revealed atretic mitral valve, hypoplastic left ventricle, hypoplastic aorta and a big atrial septal defect secundum. In addition, it showed dilation of the main pulmonary artery and PDA with continuous flow. The aforementioned confirmed the presence of HLHS in this patient. In consultation with the USA cardiac team, treatment with intravenous prostaglandin was immediately started with a plan for future Norwood procedure. However, following 6 days at the ICU the patient's condition got worse with signs of apnea and bradycardia which eventually led to fatal outcome.

CONCLUSIONS: HLHS is a very complex CHD that necessitates urgent surgical treatment soon after birth. Therefore, prompt diagnosis should be highest priority and echocardiography was revealed to be one of the best diagnostic methods. It provides information on the size inter-atrial communication, functionality of atrioventricular valve and size of the aorta which are very useful for planning the future surgical correction. Nevertheless, the operative treatment that follows is very complex. There are two major treatment modalities: cardiac transplantation and functional univentricular palliation consisting of Norwood procedure, Glenn and Fontan operations. Therefore an extensive prenatal cardiologic evaluation is also essential.

Keywords: Hypoplastic left heart,Echocardiography,Congenital heart diseases

40

Abstract No. **117** p

Theme: **Echocardiography and other imaging techniques in cardiology**

Country: **Macedonia**

Left atrial appendage thrombus in a patient in sinus rhythm

Andova V, Srbinovska-Kostovska E,Georgievska-Ismail Lj, University Clinic of cardiology, Medical school, University "St.Cyril&Methodius", Skopje, Republic of Macedonia

Introduction: Cardiogenic emboli have been estimated to be the causative factor in 20%–40% of all stroke cases . Therefore, identification of a cardiac source of embolism in stroke patients is important for proper therapeutic management. The left atrial appendage (LAA) is an important location of thrombus formation and subsequent cardioembolic events .

Methods:The present case was a 41 year-old patient who had experienced a prior cerebral infarction. Magnetic resonance showed cerebral infarction. Electrocardiogram was normal, without morfological abnormality. Transtoracic echocardiogram was normal and echo of carotid

artery was normal. He had not atrial fibrillation on 24 hours Electrocardiogram monitoring. His initial bloodwork showed platelets $500 \times 10^9/L$ (normal value $140 \times 10^9/L$).

We performed transesophageal echocardiography (TEE), which revealed formation of a small thrombus (14×10 mm) in the left atrial appendage (LAA). Warfarin was used for six months post diagnosis of LAA thrombus and then discontinued. After three months, we performed TEE, no thrombus was detected, and no systemic thromboembolic events had occurred.

Echocardiography is essential in establishing the diagnosis in patients with cardiac masses. The differentiation between myxomas and thrombi is sometimes difficult, but is critical in making the right therapeutical decision. Transthoracic and transesophageal echocardiography are the methods of choice for the diagnosis of left atrial appendix masses. Transesophageal echocardiography is a superior method in defining the characteristics of these masses.

Conclusion. Left atrial appendage (LAA) thrombosis is an important cause of cardiogenic cerebral thromboembolism.

Key words: Left atrial appendage; transthoracic echocardiography; transesophageal echocardiography

Keywords: Key words: Left atrial appendage; transthoracic echocardiography; transesophageal echocardiography

41

Abstract No. **124** p

Theme: **Echocardiography and other imaging techniques in cardiology**

Country: **Macedonia**

Left ventricular strain analysis after percutaneous repair of aortic coarctation

Zafirovska P, Milev I, Shpend I, Zimbakov Z, Ampova V, Georgieva B, Zafirovska J, Angjuseva T, Mitrev Z.

Special Hospital for Surgical Diseases "Filip Vtori", Skopje, Macedonia

The purpose of the study was to assess left ventricular function through longitudinal strain analysis in patients one year after percutaneous repair of aortic coarctation. We performed echocardiographic analysis in 10 (age $18 \pm 3,4$; male 70%) patients using GE Vivid 9 where along the standard measurements assessing systolic and diastolic left ventricular function we did speckle tracking longitudinal strain analysis. The global average strain was -17 ± 11 , 8% with dominant reduction in the basal segments of the left ventricle ($-13, 4 \pm 2$, 5%) and increase in the proximal segments ($-26 \pm 2,5$ %). The global average longitudinal strain and the average strain of the basal segments of the left ventricle showed positive correlation with the dimension of the coarctation measured in millimeters ($p=0,046$; $p=0,043$) and negative correlation with the percent of the coarctated segment, compared to the dimension of the descending aorta ($p=0,001$; $p=0,002$). We concluded that smaller dimensions of the coarctated segment of the aorta result with worst systolic function measured with speckle tracking strain analysis after percutaneous repair with endovascular stent implantation.

Key words: aortic coarctation, longitudinal strain, percutaneous intervention

42

Abstract No. 126

Theme: **Echocardiography and other imaging techniques in cardiology**

Country: **Macedonia**

Intraoperative 3D transoesophageal valvular evaluation

Anguseva T, Mitrev Z, Soicovski E, Idoski E, Zimbakov Z, Milev I, Idrizi S, Ampova V, Georgieva B

Special Hospital for surgery Philip II

Background: The aims of this study were to evaluate the feasibility of real-time 3-dimensional (3D) transoesophageal echocardiography in the intraoperative assessment of valvular pathology and to compare this novel technique with 2-dimensional (2D) transoesophageal echocardiography.

Methods: 450 consecutive patients undergoing valvular were studied

prospectively. Intraoperative 2D and 3D transoesophageal echocardiographic (TEE) examinations were performed using a recently introduced TEE probe that provides real-time 3D imaging. Expert echocardiographers blinded to 2D TEE findings assessed the etiology of MR on 3D transoesophageal echocardiography.

Similarly, experts blinded to 3D TEE findings assessed 2D TEE findings. Both were compared with the anatomic findings reported by the surgeon.

Results: At the time of surgical inspection, ischemic MR was identified in 12% of patients, complex bileaflet myxomatous disease in 31%, and specific scallop disease in 25%, aortic stenosis in 20% and insufficiency in 12% of patients. Three-dimensional TEE image acquisition was performed in a short period of time (60 ± 18 seconds) and was feasible in all patients, with optimal (36%)

or good (33%) imaging quality in the majority of cases. Three-dimensional TEE imaging was superior to 2D TEE imaging in the diagnosis of P1, A2, A3, and bileaflet disease ($P < .05$), as well as in aortic stenosis and insufficiency evaluation (leaflet morphology).

Conclusions: Real-time 3D transoesophageal echocardiography is a feasible method for identifying specific valvular pathology in the setting of complex disease and can be expeditiously used in the intraoperative evaluation of patients undergoing valvular repair surgery.

43

Abstract No. 138 p

Theme: **Echocardiography and other imaging techniques in cardiology**

Country: **Macedonia**

Pulmonary thromboembolism followed by acute myocardial infarction in patient with systemic lupus eritematodus-Antiphospholipid syndrome yes or no! (a case report)

Pocesta B¹, Kotlar I¹, Vavlukis M¹, Pejkov H¹, Bosev M¹, Caparovska E¹, Shehu E¹, Taravari H¹, Kitanovski D¹, Bojkovski I¹, Jovanovska I¹, Kedev S¹
University Clinic of Cardiology¹

The antiphospholipid syndrome is an acquired autoimmune condition which is characterized by the occurrence of venous/arterial thrombosis or of specific pregnancy morbidity, in the presence of laboratory evidence of antiphospholipid antibodies. The lack of proper prevention in undiagnosed patients causes severe complications and the most frequent reasons for mortality in

those patients include cerebral stroke, intracerebral hemorrhages, encephalopathy, acute coronary syndromes and pulmonary embolism.

We are presenting the case of 40 years old woman hospitalized at our clinic because of pulmonary thromboembolism confirmed with CT angiography. She had a medical history of systemic lupus erythematosus diagnosed at the age of 16, and ischemic 6 years prior to this hospitalization. Because of the massive pulmonary embolism she was treated with fibrinolytic therapy but, as opposite to our expectations for recovery, two days later she experienced severe chest pain and ECG changes consistent with acute myocardial infarction. Coronary angiography revealed cloths causing occlusion in three main coronary arteries, performed PTA and thromboaspiration (aspirated white clottings), but without successful reperfusion, and the patient had fatal event, and died shortly after word in cardiogenic shock.

The presented case suggests that APS should be considered in every case of hypercoagulability of blood with recurrent thrombosis at an atypical localization, or atypical etiology. The diagnosis can be confirmed in the presence of at least one of the clinical criteria, and one of the laboratory criteria. In our case unfortunately we are missing the laboratory criterion, but according to the clinical picture of the patient, we are strongly convinced that this patient probably suffered from this not so rare autoimmune condition. Investigating for the presence of this syndrome and early diagnosis may have a big influence on the course of the disease. Constant anticoagulant treatment maintaining the INR in the range of 2.0–3.0 not only enables the subsidence of symptoms without any time-limit, but also prevents recurrent incidents of venous-arterial thrombosis in the future.

Keywords: Antiphospholipid syndrome, pulmonary thromboembolism, acute myocardial infarction

44

Abstract No. **140p**

Theme: **Echocardiography and other imaging techniques in cardiology**

Country: **Macedonia**

INFLUENCE OF SUBCLINICAL HYPOTHYROIDISM ON LEFT VENTRICULAR SYSTOLIC AND DIASTOLIC FUNCTION

Velkoska Nakova V¹, Krstevska B², Srbinovska Kostovska E³, Jovanova S³, Vaskova O⁴, Jovanovska Mishevska S².

Faculty of medical science, University Goce Delchev, Shtip, R.Macedonia ¹ Endocrinology, Diabetes and Metabolic Disorders Clinic, Medical Faculty, University Cyril and Methodius, Skopje, R. Macedonia ² University Clinic of Cardiology, Medical Faculty, University Cyril and Methodius, Skopje, R. Macedonia ³ Institute of Patophysiology and Nuclear Medicine, Medical Faculty, University Cyril and Methodius, Skopje, R. Macedonia ⁴

Introduction: Subclinical hypothyroidism (ScH) is defined as a condition of slight increase in serum concentration of thyroid-stimulating hormone (TSH) with normal values of circulating thyroid hormones, free thyroxin (fT4) and triiodothyronine (fT3). Overt hypothyroidism is associated with systolic and diastolic dysfunction. Aim of the study was to assess whether ScH is associated with left ventricular systolic and diastolic dysfunction.

Material and Methods: Seventeen consecutive patients with newly diagnosed ScH and 20 healthy euthyroid patients as a control group, matched by age, sex and body mass index were analyzed. Criteria for diagnosis of ScH were: TSH > 4.2 mU/L, fT4 (10.3-24.45 pmol/L) and fT3 (4.2-8.1

pmol/L). In all patients were determined laboratory analyses (TSH, fT4, fT3, and lipids) and estimated the left ventricular systolic and diastolic function by M-mode, two-dimensional echocardiography, Pulse, Continuous and Color- Doppler, and advanced echocardiography modalities, Tissue Doppler (TDI) and two-dimensional speckle tracking echocardiography. Results: Patients with ScH compared with the control group, had statistically significantly higher values of TSH and lower values of fT4 and fT3. From echocardiography measurements patients with ScH had statistically significant lower ejection fraction, lower quotient s/d (where s is systolic velocity and d is diastolic velocity through the pulmonary veins) and lower longitudinal global strain compared with the control group (62.1 ± 2.1 vs. $58.7 \pm 6.2\%$, $p < 0.05$, 1.27 ± 0.12 vs. 1.06 ± 0.20 , $p < 0.001$, and -0.21 ± 0.01 , vs. $-0.19 \pm 0.01\%$, $p < 0.05$, respectively). Thyroid-stimulating hormone statistically significantly negatively correlated with s/d and s/TDI ($r = 0.43$ and $r = 0.26$ respectively, $p < 0.05$). Free thyroxin statistically significantly negatively correlated with myocardial performance index ($r = 0.17$, $p < 0.05$), and positively with s/d ($r = 0.48$, $p < 0.05$). Conclusion: Subclinical hypothyroidism is associated with a statistically significant reduction in systolic global and global longitudinal systolic function of the left ventricle.

Keywords: Key words: subclinical hypothyroidism echocardiography, systolic dysfunction, diastolic dysfunction.

45

Abstract No. 144 p

Theme: **Echocardiography and other imaging techniques in cardiology**

Country: **Macedonia**

Arterial Thrombosis of a Patient With Stomach Cancer

Chaparoska-Velichkovska E¹, Vavlukis M¹, Pocesta B¹, Taravari H¹, Sehu E¹, Andova V¹, Kotlar I¹, Jovanovska I¹, Bojovski I¹, Kitanovski D¹, Janusevski F¹

Clinic of Cardiology, Skopje, Macedonia¹

Aim: Connection between the arterial thrombosis and the malignant disease

Materials and Methods: Case study of a 39 years old patient suffering from critical limb ischemia. Echocardiography; Doppler of lower extremities; CT of chest and abdomen; gastroscopy; lab tests were performed.

Results: Results showed existence of a clot in the left chamber; clot in the descending aorta; thrombosis in the mesenteric artery; occlusion of a. popliea dex.; para-aortally and gastro-eppiploically increased lymph glands. Gastroscopy showed existence of stomach exulcerations and histo-pathological analysis showed existence of adenoid cancer of the stomach. Lab analyses showed a condition of hyper-coagulation.

Conclusion: A connection exists between the appearance of arterial thrombosis and stomach cancer.

Keywords: arterial thrombosis, cancer

Заштитни мерки при јонизирачко зрачење во кардиолошка ангиографска лабораторија

Виолета Гијевска

Универзитетска клиника за кардиологија, Скопје, Македонија

Врз основа на Законот за заштита од јонизирачко зрачење и радијациона сигурност, Клиниката за Кардиологија ја има донесено програмата за радијациона заштита како интересен документ, со која се дефинираат постапките при работа, обезбедувањето квалитет во работните процедури и функционирањето на апаратите што произведуваат јонизирачко зрачење, а се сместени во ангиографските лаборатории.

Вработените во контролираната зона ја имаат како водич оваа програма во извршувањето на секојдневните работни задачи, која содржи:

1. Технички мерки на заштита опфаќаат опремување на просториите и работните места со апаратура, прибор за работа, лични заштитни и дозиметриски средства за вработените
2. Медицински мерки на заштита: здравствен преглед пред стапување на работа со јонизирачко зрачење, период.систематски прегледи во текот на работата, здравствен преглед по престанок на работата со јонизирачко зрачење

Одговорното лице за некои аспекти од радијационата заштита има одредени должности, односно мора да припреми процедури за влез во контролираните зони, здравствената состојба на работниците и информирање во врска со изворите на јонизирачко зрачење, да направи План за индивидуален мониторинг (носење на ТЛД дозиметри), да направи План за мониторинг на работната средина и класификација на зони. Лицата кои имаат пристап во ангиосала (доктори, сестри, болничари) се под индивидуален дозиметриски мониторинг што како услуга на Клиниката за Кардиологија ја овозможува Лабораторијата за дозиметрија во склоп на Институтот за јавно здравје

Одговорното лице мора да води евиденција и постапки за информирање на работно изложените лица, за радијациона заштита ја прима и ја чува документацијата од индивидуалниот мониторинг, а штом ќе го добие месечниот извештај од Лабораторијата за дозиметрија за дозите регистрирани кај вработените, тој ги известува носителите на дозиметрите за дозата што била прочитана од нивните дозиметри во претходниот месец. Ако некој од вработените има примено доза поголема од толерантната, одговорното лице во разговор со вработениот го реконструира настанот што би можел да предизвика вработениот да прими толкава доза, се консултира со мед.физичар, го известува Директорот на Клиниката и со пишан допис ја известува Дирекцијата за радијациона сигурност.

Улогата на сестрата кај пациенти со воспалителни срцеви заболувања

Јулијана Панчевска

Универзитетска Клиника за Кардиологија-Скопје, Македонија

Улогата на сестрата кај пациентите со воспалителни срцеви заболувања е комплексна, пред се заради специфичноста на оваа група на заболувања и таа започнува веднаш по приемот на болниот во болничкото одделение.

Медицинската сестра се грижи за сместување на болниот, во понатамошниот третман таа учествува во набљудување на пациентот, контрола на виталните знаци (телесна температура - која е особено важна за оваа група на заболувања , пулс , дишење и мерење на крвен притисок) , врши контрола на излачевините (секрети , екскрети) изведува медицинско – технички интервенции што опфаќа спроведување на терапевтски интервенции како земање крв , спроведување на интревенска или орална терапија, учествува во припрема на пациентот за најразлични иследувања (ЕКГ, Ехокардиографија , RTG дијагностика), а дел од овие и самата ги спроведува како што е правењето на електрокардиограмот. Особено важна улога е грижата околу негата на болниот и пружа помош при одржување на личната хигиена на болниот.

Медицинската сестра испраќа најразлични материјали (крв, урина, пунктат) за лабораториски, микробиолошки, цитолошки и др. анализи. Особено важно е навремено и правилно експидирање на анализите до бараната адреса на пр. Хемокултура да се испрати на микробиологија а воедно навреме ги прибере и среди добиените резултати. За секој нов добиен резултат, или за промена во состојбата на болниот го известува докторот.

Заради специфичноста на овие заболувања сестрата преставува администраторот, односно заради можноста за појава на нова инфекција или евентуален извор на контаминација, таа за секој добиен резултат од хемокултура го известува одговорниот за интерхоспитални инфекции во рамките на болницата, овој резултат го забележува во регистарот за заразни заболувања, го информира одговорниот лекар.Потоа во зависност од видот на инфективниот агенс по инструкции на лекарот, превзема мерки за изолација на болниот , висок степен на отстранување на контаминираниот материјал добиен по завршената интервенција кај овој болен.

Имајќи ја предвид долготрајноста на третманот кај лицата со воспалителни срцеви заболувања, особено ако се работи за инфективен ендокардит, кој понекогаш може да биде и по два месеца, а со оглед на тоа дека се работи за лица со компромитиран имунитет кои се изложени на појава на мешана инфекција или супер инфекција , произлегува голема ангажираност и одговорност на медицинскиот персонал, пред се во спречување на овие инфекции и спречување на ширење на инфекцијата.

48

Abstract No. **162** p

Theme: **Echocardiography and other imaging techniques in cardiology**

Country: **Macedonia**

Implantation of pacemaker in treatment of Tachycardia-Bradycardia Syndrome

Ivanov M.

Clinic of Cardiology

Introduction: The Tachycardia-Bradycardia Syndrome is a variant of Sick Sinus syndrome in which slow arrhythmias and fast arrhythmias alternate. It is often associated with ischaemic heart disease and valvular lesions. The tachycardia-bradycardia syndrome consists of paroxysmal atrial fibrillation, flutter or tachycardia followed by sinoatrial block or sinus arrest resulting in Stokes-Adams attacks. Pathology studies and physiologic mechanisms as revealed in electrocardiogram indicate multiple disturbances in the conduction system of the heart (sinus node, atria, and atrioventricular junctional tissues). The electrocardiogram established the diagnosis.

Case description: A 59 year old man was admitted to our hospital because of dizziness, occasional weakness and fast and arrhythmic heart rate. Electrocardiogram on admission showed arrhythmic heart rate (Atrial fibrillation) ~95 beats per minute, without any ST segment changes. Echocardiography was made and showed reduced EF 41%, dilated LV and LA with mild MR. Coronarography was performed with findings of plaques at mCIRC, mRCA, dRCA. Conclusion from placed Holter-ECG was: Atrial fibrillation with maximal frequency 199 bpm, minimum 37 bpm and average 84 bpm. Registered are more RR intervals longer than 2.5 sec. and longest RR interval 3.6 seconds. PVC multifocal, individual and in pairs and sequences as well as episodes of NSVT. VVIR – pacemaker with ventricular electrode thru v.cephalica lat. Sin. was implanted.

Discussion: Pacemaker implantation with supplementary drugs has provided a satisfactory means of therapy. With proper treatment the prognosis of patients with tachycardia-bradycardia syndrome has improved to the extent that the primary determinant of mortality is no longer the arrhythmia but the underlying cardiac and/or systemic pathology.

49

Abstract No. **163** p

Theme: **Echocardiography and other imaging techniques in cardiology**

Country: **Macedonia**

Radiofrequency catheter ablation as treatment for atrial flutter at patient with dilated cardiomyopathy

Gulevska A. Taleski J. Kaeva S

Clinic of Cardiology

Dilated cardiomyopathy is characterized by ventricular dilatation and depressed myocardial contractility. This cardiomyopathy very often correlates with rhythm disorders, like atrial fibrillation or flutter.

Radiofrequency ablation has a success rate over 90%, a low risk of complications and the patient can resume normal activities in a few days.

In this case the point is to evaluate the effects of radiofrequency ablation on the quality of life at patient with atrial flutter in purpose to avoid heart decompensation.

Case description:

A 55 years old man was admitted to our hospital with symptoms as: heart beating, dyspnea, difficult breathing, fatigue and pretibial edema. With medical history for dilatated cardiomyopathy and hospitalisation on clinic for pulmo alergology before 3 months due to lung infection.

Physical examination was notable for irregular heart rhythm with frequency more than 150 b.p.m., weakened bilateral vesicular breathing and pretibial edema.

Laboratory findings demonstrated only lower level of platelets and T3 hormone.

EKG showed arrhythmic heart rate (atrial flutter) more than 150 b. p. m.

Echocardiography showed reduced EF 40%, dilatated chambers LVED 72mm, LA = 52 mm with global reduced kinetics in contribution of CMP dilatated. He was treated with double anti arrhythmic therapy, diuretics, anticoagulant and ace inhibitor. The patient underwent electro physiology study. A 20 polar Halo catheter was inserted in position from CS (coronary sinus) through cavo tricuspid isthmus in to the lateral wall of right atrium.

From intracardial record was monitored catheter counter-clockwise (typical) cavo tricuspid isthmus dependent atrial flutter. After eight ablative lines was followed termination of atrial flutter, EKG showed sinus rhythm with hearth rate 61 b.p.m.

After 10 days spend in our hospital, the patient continued with home therapy using only one anti arrhythmic drug.

Conclusion: The point of this case is to illustrate the meaning of using catheter ablation like therapeutic procedure at patients with atrial flutter. With possibilites that EPS offers, the range of morbidity and mortality at patients with advanced heart failure is reduced and the evolution of further complications are decreased.

50

Abstract No. 168 p

Theme: **Echocardiography and other imaging techniques in cardiology**

Country: **Macedonia**

Transcranial Doppler in diagnosis of patent foramen ovale

Dimiskovska S, Lazevska M , Trajcevska- Gavrilova M, Ristova V, Tasevska V, Alii N, Kostovska S, Ampova V, Zafirovska P, Mitrev Z

Special hospital for surgical diseases “Filip Vtori”, Skopje, Macedonia

During fetal development, a small channel is usually present connecting the left and right atria in the heart. Normally this opening closes during infancy but when it doesn't it is called patent foramen ovale (PFO). Sometimes the PFO could be the cause of stroke, transitory ischemic attack (TIA) and migraine with aura. In diagnosing PFO a method called transcranial Doppler is used. It is Doppler scan of a cerebral artery during Valsalva maneuver that is performed by the patient while at the same time administering physiologic solution that is previously mixed in order to create bubbles. If PFO is present the bubbles during the increased right atrial pressure will transfer to the left atria and we will register the Doppler signals in the cerebral circulation. In patients with positive tests and clinical symptoms (stroke, TIA) there is indication for closure of the PFO with transcatheter intervention using special device- a PFO occluder.

In our diagnostic laboratory from the period of June 2013 to May 2014, two hundred sixty transcranial dopplers were performed. Forty two percent (110) of the transcranial Doppler were positive for PFO. In 30(27%) patients with positive test an interventional treatment was performed.

Transcranial Doppler is simple, low-cost and low time consuming procedure that can be used in diagnosing PFO and further interventional treatment of the patients.

Keywords: transcranial Doppler, patent foramen ovale, interventional treatment

51

Abstract No. **169** p

Theme: **Echocardiography and other imaging techniques in cardiology**

Country: **Macedonia**

Doctor Internal medicine

Savetka PJ¹, Sasa K², Nela K³,¹

Clinic of Cardiology Macedonia, Skopje

Atrial fibrilacion in patients with hyperthyreosis

Purpose: Atrial fibrillation a disease that is usually associated with primary cardiac diseases (arterial hypertension, diabetes mellitus, hyperthyreosis, coronary disease, CMP, heart failure etc)

CASE REPORT: We present a clinical case of 66 years old female patient with symptoms like :palpitations, wheezing, fatigue, crural oedema. Her first hospitalization on the Clinic of Cardiology was in December 2010.

Risk factors: hyperthyreosis, arterial hypertension, diabetes mellitus

Family history: positive (arterial hypertension, diabetes mellitus)

Investigations:

EKG: AFF with HR 170/min

Laboratory: Se 85; Hgb 97; Er 3.7;; Tr 305; Le 8.Glucose 5.6..9.2..11.5..16..7.0;Urea 12.3

Kreatinin 92;CPK 156,CK-MB 41; LDH 394; Na 138; K 4.7... TSH< 0.004; fT4> 77.22; Total T4>309

Echocardiography: LA 50,EF 51% Designated left ventricular dimensions, dilated left atrium with moderate MR. PAH.

Ultrasonography of the lungs: Left side with less liquid. Right side 20 ml yellow liquid.

Cytological diagnosis of lung-points the presence of coagulated protein mass.

Gas analysis: hiposaturacion with hypoxemia and normokapnia. Manifest HRI with compensatory metabolic acidosis.

Basic echotomography of abdomen: Large effusion in the right frenicocostal sinus . Gall bladder with thickened wall and lumen with several large calculi.

Keywords: Conclusion: The most common disorders of the rhythm in patients with atrial fibrillation is hyperthyroidism (supraventricular arrhythmia) despite sinus tachycardia, ventricular extrasystoles with greatest representation in patients over 45 years of age.

52

Abstract No. 170 p

Theme: **Echocardiography and other imaging techniques in cardiology**

Country: **Macedonia**

Team management and the role of patient education in patients with heart failure: Survey based research.

Maneva Samardziska C¹, Manev B¹.

PZU Prim D-r Samardziski Shtip - Private Health Care institution for General and Internal Medicine

Background - Heart failure is defined as chronic, progressive disease that is characterized by frequent hospital admissions and high mortality rates. Successful management of heart failure condition can be reached through continuous education and full patient collaboration; in practice patient education varies considerably.

Objectives - The treatment of patients with heart failure is impossible without their understanding of the disease. To understanding how-to self-control this condition plays important role in controlling the symptoms, progression and in achieving good quality of life. Thus, we work and empower our patients in teams together with health care workers to insure the good results and reduced hospitalizations and acute complications.

Material - The educational program for patients with heart failure includes the education of various clinical disciplines, performed by an interdisciplinary team from qualified healthcare educator. Patients' education should include instructions based on knowledge and appropriate behaviour. Patients must be given instructions with a logical schedule. Various outcome measures were used to estimate the effectiveness of a given educational program.

Method - We conducted survey based investigation on 412 patients with chronic heart failure.

Age, BMI, education, socio-economic status, alcohol consumption, history of disease and other patient characteristics were documented in a questionnaires from October 2013 till April 2014.

Conclusion - Education of patients and their families, helps the patient to cope with the disease, provides psychosocial support and dynamic strategy to monitor and evaluate during the upcoming years of this global approach. This research showed that team approach delivers better results regarding management of heart failure disease.

Keywords: Heart failure, patient education, team work, prevention

53

Abstract No. 172 p

Theme: **Echocardiography and other imaging techniques in cardiology**

Country: **Macedonia**

Diagnosis and Treatment of Pulmonary embolism

Cipusheva K¹, Taneski F¹, Manev B¹

Clinic of Cardiology-Skopje

Introduction: Pulmonary embolism (PE) is a blockage of main artery of the lung or one of its branches by a substance that has travelled from elsewhere in the body through the bloodstream (embolism). PE most commonly results from deep vein thrombosis (a blood clot in the deep veins of the legs or pelvis) that breaks off and migrates to the lung, a process termed venous thromboembolism (VTE). A small proportion of cases are caused by the embolization of air, fat, or talc in drugs of intravenous drug abusers or amniotic fluid. The obstruction of the blood flow

through the lungs and the resultant pressure on the right ventricle of the heart lead to the symptoms and signs of PE.

Case report: We report a case of a 78 year old female patient presented to the hospital with complaint of fatigue, shortness of breath, nausea and vomiting in the last two days. The patient has been traveling by car for 12 hours, in which the symptoms got worse. The patient has a medical history of varicose veins of lower extremities and arterial hypertension. On admission the blood pressure was 50/30mmHg. The initial ECG showed sinus tachycardia 115/min, Q wave in lead D3 and negative T wave in D3, ST segment depression 1-2mm and negative T waves in precordial leads. Beside echocardiogram demonstrated right ventricular dilatation (RVd 55mm), right atrium dilatation (RA 60mm) with signs of severe TR. Signs for pulmonary artery hypertension. SPAP = 65mmHg. The complete blood panel was normal, except of WBC (14.0). The D Dimer test was positive. The patient was given normal saline, O₂, aminophyllin and loading dose of Heparin and Streptokinase intravenously for suspected pulmonary embolism. By next morning patient's shortness of breath has resolved. The patient continued to improve clinically and was discharged home.

Conclusion: Thrombolysis can be life saving in patients with pulmonary embolism, cardiogenic shock or hemodynamic instability.

Keywords: Pulmonary embolism, Thrombolysis

54

Abstract No. 175 p

Theme: **Echocardiography and other imaging techniques in cardiology**

Country: **Macedonia**

Arrhythmias induced cardiomyopathy-reversible dilated cardiomyopathy in patients with atrial fibrillation/flutter with fast ventricular rate

Jovanova S¹, Arnaudova-Dezhulovikj F¹, Boshev M¹, Kamcevska-Dobrkovic L¹, Otljanska M¹, Kostova N¹, Miceva I¹

University clinic of cardiology, Medical faculty, Skopje, Macedonia

Arrhythmias induced cardiomyopathy is defined as a condition characterized with atrial or ventricular myocardial dysfunction as a result of prolonged and increased atrial or ventricular rates. The most common arrhythmias that induced this type of cardiomyopathy are supraventricular arrhythmias and atrial fibrillation. There are no underlying structural heart abnormalities, the cardiomyopathy is reversible state and the diagnosis is retrospective. The prevalence of the disease can be truly estimated as it is mainly described in small series or case reports

We present a small series of seven patients with established diagnosis of cardiomyopathy induced with arrhythmias, as a result of atrial fibrillation and/or flutter, hospitalized to our institution during 2011-2013y. All the patients presented with symptoms and signs of heart failure with ECG at admission consistent with atrial fibrillation/flutter with fast rate. Echocardiographic parameters were consistent with dilated cardiomyopathy with moderately to severe reduced LV systolic function. In all cases there was no structural heart disease, no signs of inflammation or metabolic disturbances. Effective pharmacological antiarrhythmic protocol and heart failure treatment were administered in the patients as soon as possible. In all patients pharmacological conversion to sinus rhythm was achieved and maintained and there was complete resolution of LV systolic dysfunction during the next three months.

Early introduction of effective antiarrhythmic therapy in patients with left ventricular dysfunction (of unknown cause?) and supraventricular arrhythmia with fast rate, echocardiographic follow-up of ventricular function and prevention of future arrhythmia with fast rate are imperative because arrhythmias induced cardiomyopathy is reversible state with good and favorable prognosis

55

Abstract No. 175p

Theme: **Ехокардиографија и другите имицинг техники во кардиологијата**

Country: **Macedonia**

Кардиомиопатија предизвикана од аритмии-реверзибилна дилатациона кардиомиопатија кај пациенти со преткоморна фибрилација/флатер со брза коморна фреквенција

Јованова С¹, Арнаудова-Дежуловиќ Ф¹, Бошев М¹, Камчевска-Добрковиќ Л¹, Отљанска М¹, Костова Н¹, Мицева И

Универзитетска клиника за кардиологија, Медицински факултет, Скопје, Македонија

Кардиомиопатијата предизвикана од аритмии е состојба што се карактеризира со преткоморна или коморна дисфункција како резултат на преткоморна или коморни аритмии. Брзата коморна фреквенција во контекст на суправентрикуларни аритмии и преткоморната фибрилација се најчести пореметувања во срцевиот ритам што се асоцирани со настанување на овој тип на кардиомиопатија. При оваа состојба не постои структурно срцево заболување, реверзибилна е по смирување на срцевиот ритам и нејзината дијагнозата обично е ретроспективна. Преваленцата не е добро дефинирана со оглед на фактот што досега се објавени само мали серии или пак поединечни случаи. Презентираме серија од 7 пациенти дијагностицирани како кардиомиопатија предизвикана од аритмии, како резултат на преткоморна фибрилација и/или флатер, во тек на 3 годишен период. Пациентите презентираа со симптоми и знаци на срцева слабост, со брза срцева коморна фреквенција и ехокардиографски документирана ЛК дилатација и систолна слабост. Кај пациентите не постоеја знаци за воспаление или метаболни нарушувања, а селективната коронарографија исклучи постоење на исхемична етиологија на срцевата слабост. Истовремено со третманот на манифестната срцевата слабост пациентите беа третирани по соодветен фармаколошки антиаритмичен протокол. Кај сите пациенти беше воспоставен нормален синусен ритам и дојде до комплетно возобновување на ЛК систолна функција во период до три месеци од првата презентација. Со оглед дека се работи за реверзибилна кардиомиопатија со најчесто добра прогноза, раното започнување со ефективна антиаритмична терапија е императив кај пациентите со ЛК систолна дисфункција (од непозната причина?) и преткоморни аритмии со брза фреквенција. Кај овие пациенти неопходно е ехокардиографско следење на ЛК функција и превенција на идни пристапи на брз срцев ритам.

56

Abstract No. 178 p

Theme: **Echocardiography and other imaging techniques in cardiology**

Country: **Macedonia**

Can age be crucial for CRT (cardiac resynchronization therapy) at severe dilated cardiomyopathy with narrow QRS? Case report.

Spasevski Gj¹, Kikirkovska E¹

University clinic for cardiology - Skopje¹

Introduction: Dilated cardiomyopathy is a progressive disease of heart muscle that is characterized by ventricular chamber enlargement and contractile dysfunction with normal left ventricular (LV) wall thickness. Dilated cardiomyopathy is the third most common cause of heart failure and the most frequent reason for heart. The occurrence of clinical heart failure caused by cardiotoxicity of chemotherapy treatment is in the range of 1%-5%.

Case description: A 23-year-old Caucasian male, presented to the hospital with complain of fatigue, orthopnea, shortness of breath and peripheral pretibial edema. He reported positive medical history for lymphocytic leukemia threated with Doxorubicin in several occasions. Physical examination was remarkable for peripheral edema, tachycardia, tachypnea and hepatosplenomegaly. Laboratory findings demonstrated mild leukocytosis and increased ESR (erythrocyte sedimentation rate) values. Medical management consisted of intravenous continuous Dopamin stimulation and intravenous diuretics. The patients request for implantation of CRT was refused because no medical indication was founded. The patient was discharged on his own behalf, hemodynamically stable.

Conclusion: Can CRT in severe dilated cardiomyopathy with narrow QRS lead to improvement or offers no benefit, regarding as therapy procedure?

Discussion: There are no studies that which confirm or exclude the advantages and disadvantages of CRT implantation in patients with narrow QRS severe dilated cardiomyopathy. Can the patient age be sufficient ethical indication for implanting CRT.

Keywords: CRT, narrow, QRS, sever, dilated, cardiomyopathy.

57

Abstract No. 179 p

Theme: **Echocardiography and other imaging techniques in cardiology**

Country: **Macedonia**

Is the "Slow Pathway" potential best approach for AVNRT ablation? Case report.

Kikirkovska E¹, Spasevski Gj¹

University clinic for cardiology - Skopje¹

Introduction: Atrioventricular nodal reentrant tachycardia (AVNRT) is an arrhythmia that occurs as the result of functional dissociation of AV nodal conduction into a so-called fast pathway (FP) and slow pathway (SP). This allows for an abnormal electrical circuit to perpetuate in the AV node. AVNRT is the most common cause (about 60%) of paroxysmal supraventricular tachycardia (PSVT). Ablation of the slow pathway in patients with AVNRT can be performed by using either an anatomic or an electrogram mapping approach to identify target sites.

Electrogram recordings may be the "slow potential" as described by Haissaguerre or the "slow pathway potentials" as described by Jackman. In this case is shown how slow pathway potential

could guide safe and effective AVNRT ablation.

Case description: In this case a 67 years old male presented to the hospital with complaint of sudden onset of rapid regular palpitations, fatigue and ECG evidence of PSVT. Physical examination was unremarkable. The patient underwent electrophysiological study. Two quadripolar catheters and one decapolar diagnostic catheter were introduced through right femoral vein and placed in the Coronary Sinus (CS) , right ventricle (RV) and His bundle position. An adequate ventricular effective refractory period (VERP) was achieved with programmed stimulation from the RV catheter. With programmed stimulation from CS was triggered AVNRT and then terminated with burst stimulation from the same position. The ablation catheter was introduced through the right femoral vein and placed in the right postero-septal area, guided from a large and sharp slow pathway potential "Jackman". This site was used to start RF delivery. At the end a successful ablation of the slow pathway was accomplished with one RF application energy. Atrio-ventricular node effective refractory period (AVNERP) was documented (from CS position) as a sign of successful ablation.

Conclusion : This case illustrates the electrogram- based approach. The anatomic and electrogram mapping approaches for ablation of the slow AV nodal pathway are comparable in efficacy and duration. It has been shown that the electrogram- based approach is more effective and there are more differences with respect to the time required for the ablation and duration of fluoroscopic exposure.

Keywords: AVNRT, slow, pathway, ablation, Jackman.

58

Abstract No. **196**

Theme: **Echocardiography and other imaging techniques in cardiology**

Country: **Macedonia**

Assessment of patients with mitral regurgitation

Srbinska Kostovska E.

UNiversity Clinic of Cardiology, Medical faculty, Skopje, Macedonia

According to guidelines for Valvular heart diseases, from ESC, 2012, ACC/AHA 2014 echocardiography is key examination to confirm diagnosis, assess severity and prognosis. But very important task of echocardiography is to differentiate anatomy and mechanism of mitral regurgitation

The normal mitral valve function depends on the coordination of all elements of the complex mitral valve apparatus which includes mitral leaflets, mitral annulus, papillary muscles, chordae tendineae and LV function. Dysfunction of any of these components can be the reason for the occurrence of mitral regurgitation

Primary mitral regurgitation leads to LV overload with progressively increased chamber, tending to reduced valve leaflet coaptation which leads to further worsening of the MR.. Secondary MR is a result of the severe global LV enlargement and dysfunction, wall motion abnormality, LV dyssynchrony. In the case of functional mitral regurgitation there is imbalance between tethering forces and closing forces. The most important components of the tethering forces are annular dilatation, LV dilatation and specificity and papillary muscles displacement , and from the point of closing forces the important components are reduced LV contractility and LV dyssynchrony. Depending of the ratio of the both component, tethering and closing forces, we will have asymmetric pattern of the mitral valve displacement, or symmetric pattern.

There are several parameters important for estimation of the severity of the mitral regurgitation.

They are : Color flow Doppler, Vena contracta ,PISA method, Effective regurgitate orifice area (EROA), Regurgitate volume , which are now included for indication for surgery, in the new Guideline of ACC/AHA 2014

Conclusion: Accurate distinction of the mitral regurgitation, primary or secondary, is important for decisions regarding surgery and predictive risk

- TTE is recommended as a first line imaging modality for mitral valve analysis
- 3D and TEE, and advanced echo modalities are indicated to provide additional information in patients with complex mitral valve lesion
- Quantitative parameters, including vena contracta width, regurgitant volume ,effective regurgitant volume have prognostic significance and are recommended to be obtain from patients with mitral regurgitation
- Estimation of the LA, LV dimension and function, as well as estimated pulmonary hypertension and RV function are important in assessment of optimal time for valvular intervention

Keywords: primary and secondary mitral regurgitation, echocardiography

59

Abstract No. **192**

Theme: **Echocardiography and other imaging techniques in cardiology**

Country: **Macedonia**

Chronic heart failure- What Guidelines says?

Srbinovska Kostovska E.

University Clinic of cardiology, Medical faculty, Skopje, Macedonia

Heart failure can be defined as an abnormality of cardiac structure or function leading to failure of the heart to deliver oxygen at a rate commensurate with the requirements of the metabolizing tissue. Left ventricular adverse remodeling after myocardial injury (myocardial infarction, left ventricular dilatation from other reason, idiopathic cardiomyopathy) has been shown to be a chronic progressive process that contribute for years after the initial faze. Adverse remodeling and gradual dilatation leading to increased LV volumes are major predictors of poor outcomes among heart failure patients.

Accordance with ACC/AHA and ESC Guidelines, there are high risk patients for heart failure, asymptomatic stage of HF, patients with symptomatic heart failure where hemodynamic adaptation and neurohormonal activation are involved, and the end-stage heart failure patients. With increasing the functional classes there is reduction of survival.

Several therapies were found to slow the process of adverse LV remodeling , including beta-blockers and blockers of the renin-angiotensin-aldosteron system. But, despite optimal therapy, left ventricular dyssynchrony in commonly present in heart failure patients, particularly in those with prolonged QRS complex duration. In the guideline for the Treatment of heart failure, from May 2012, indications for CRT is defined, and in Class I, level of evidence A is pts QRS duration bigger than 120 msec, LBBB QRS morphology and EF <35%.

Cardiac resynchronization therapy with or without defibrillators, in several study showed reversal remodeling and significant improvements in LV volumes, reduction the risk of the heart failure progression and death in mildly and symptomatic patents with ischemic and non-ischemic cardiomyopathy. Cardiac resynchronization therapy (CRT) is currently indicated on top of optimal medical therapy for patients with moderate to severe left ventricular (LV) systolic

dysfunction. But, 30- 40% of patients do not respond to CRT, depending on which definition of response is used. One of the reasons of not responding on CRT and poor prognosis after CRT is minimal, or no dyssynchrony. The other reasons are ischemic diseases with too much scar especially lateral wall scar, suboptimal lead placement. But, dyssynchrony can be identified prospectively by echocardiographic Doppler methods.

Novel echocardiographic techniques, including tissue Doppler, color tissue Doppler analysis, strain, strain rate, 3-dimensional echocardiography, tissue synchronization imaging, and other echocardiographic dyssynchrony methods play very important role, especially in selection a patient (responder) for CRT therapy. American Association of Echocardiography issued expert consensus statement which defines different echocardiographic measurements that provide information about different types of dyssynchrony

Keywords: heart failure, adverse remodeling, dyssynchrony

3. Acute Coronary Syndrome

1

Abstract No. 20

Theme: **Acute Coronary Syndrome**

Country: **Bulgaria**

Statins in primary prevention of cardiovascular diseases

Runev N

Department of Internal diseases "Prof. St. Kirkovich", Medical university of Sofia, Bulgaria

Statins are well investigated drugs with proven cardioprotective effects. In secondary prevention trials a significant reduction of all-cause, coronary and cardiovascular (CV) mortality, as well as a CV events rate (myocardial infarction, stroke, revascularizations) was obtained by statin therapy: the lower LDL-C level, the better prognosis.

Meta-analyses with studies of patients with risk factors only (primary prevention) demonstrated a decrease of major coronary and cerebrovascular events (on average by 30% and 19%, respectively) in high risk patients. Moreover, one meta-analysis of individual data in people at low risk (<5% 5-year MVE risk) showed a consistent reduction by statins of major vascular events (-39%) and any vascular death (-20%) per 1.0 mmol decrease in LDL-C.

The current ECS Guidelines for the management of dyslipidemias revealed the most important steps at initiation of statin therapy: 1. Evaluate the total CV risk of the patient; 2. Identify the LDL-C target according to this CV risk level; 3. Calculate the percentage reduction of the baseline LDL-C required to reach the target; 4. Choose a statin and appropriate dose to provide this goal. The initial dose of statin was found to achieve the greatest reduction of LDL-C and the doubling of statin dose would lead to additional LDL-C decrease by 6% only.

So called "standard doses" (20 mg Atorvastatin and 10 mg Rosuvastatin) were able to reduce LDL-C up to -44% and -47%, respectively. Rosuvastatin 5 mg daily was shown to decrease LDL-C up to -41%. The groups of patients with benefit by 5 (10) mg Rosuvastatin for primary prevention could be defined as follows: (1) Moderate CV risk (ESC SCORE: 1%-5%, LDL-C target < 3 mmol/l) and baseline LDL-C \approx 3.9 – 4.9 mmol/l; (2) High CV risk (ESC SCORE: 5%-10%, LDL-C target < 2.5 mmol/l) and baseline LDL-C \approx 3.4 – 4.4 mmol/l; (3) Moderate-

Intensity Statin therapy (according to ACC/AHA Guidelines 2013) – expected LDL-C lowering by approximately 30-50%. However, the patients with diabetes + at least 1 more risk factor or marker of target organ damage have LDL-C goal < 1.8 mmol/l and they will need a higher dose Rosuvastatin.

In conclusion, the high and very high risk patients would have the greatest clinical benefit of statin therapy for primary prevention of myocardial infarction and stroke: earlier is better. In these cases the ESC guidelines are clear: prescribe statin up to the highest recommended dose, or highest tolerable dose to reach the target level (Class I, level A). A significant reduction of total CV risk would be achieved only when the target LDL-C had been reached.

Keywords: statins, primary prevention, cardiovascular diseases

2

Abstract No. **21**

Theme: **Acute Coronary Syndrome**

Country: **Macedonia**

The influence of blood pressure on recurrent stroke and myocardial infarction

**Dragana Petrovska Cvetkovska, Natalija Dolnenec Baneva, Dijana Nikodijevik
University Clinic of Neurology, Faculty of Medicine, Ss Cyril and Methodius University,
Skopje, R. Macedonia**

Background and Purpose: The patients with stroke have high risk of recurrent vascular damage of the heart or brain, especially in the first year after stroke. The uncontrolled blood pressure (BP) increased the risk of stroke recurrence, but also myocardial infarction (MI) and vascular death. We investigated whether high blood pressure increases the risk of stroke recurrence, acute MI or vascular death.

Methods: The study was prospective, open labeled, in duration of 1 year, and included 109 patients with stroke. We evaluated the patients first, 3, 6, and 12 month after stroke. Every visit we measure the BP, and we divided the patients in the two groups: first group with BP <140/80 mmHg, and second group with BP ≥140/80 mmHg. We evaluated the recurrent vascular damage: stroke, MI or vascular death.

Results: There were 18 recurrent strokes among the 109 patients (mean age, 69 years; 53% men) with follow-up blood pressure. The risk ratio for stroke recurrence for diastolic blood pressure ≥80 mm Hg compared with <80 mm Hg was 2.4 (95% CI, 1.41 to 4.12) and for systolic blood pressure ≥140 mm Hg compared with <140 mm Hg was also 2.4 (95% CI, 1.39 to 4.14).

Myocardial infarction had 5 patients first year after stroke, and vascular death had 3 patients, two of them in first 6 month after stroke.

Conclusions: Our results suggested that blood pressure control, reducing stroke recurrence risk, but also risk from cardiovascular disease like acute MI.

Key words: recurrent stroke, blood pressure, myocardial infarction

3

Abstract No. 26 p

Theme: **Acute Coronary Syndrome**

Country: **Macedonia**

Третман на електрична (VT) бура кај пациенти со имплантибилен кардиовертер дефибрилатор / презентација на случај

Сервини Ж. , Лозанче Н.

Клиничка болница „Др. Т. Пановски,, Битола

Бура на VT е животозагрозувачки синдром кој што се дефинира со повторувачки епизоди, најмаку 3 за 24 часа, на VT, VF, или соодветен шок на имплантиран ICD. Успешното лекување на VT бура бара познавање на механизмот на аритмиите и тераписките можности. Откривањето на основната причина за појава на електричната бура е основа за третман. Презантација на случај Пациент, маж на 39 години, со прележан МИ и поставен стент, присутна дилатативна исхемична миокардиопатиа и имплантиран кардиовертер дефиб заради секундарна превенција на VT/VF, се јавува во нашата амбуланта заради 4 удари на ICD во тек на последните 4 часа. Видно воземите, за време на преглед нова епизода на мономорфна VT предизвика нов удар на ICD. Хоспитализиран во коронарна единица, континуирано мониториран. Биохемиски анализи: двојно зголемени кардиоспецифични ензими, Електролитен статус уреден, К 4.5 ммол/л.

Анамнестички/абузус на никотин последните 24 часа. 2 часа пред доаѓање во болница во консултација со својот кардиолог примил максимална доза на Табл. Блоксан и Амiodарон. По приемот пациентот е седиран со амп. Апаурин од 10 мг /и.м и поставена инфузија на 7.3% раствор KCl. Нивото на К во крвта е погигнато на 5,4 ммол/л. Следните 2 часа кај пациентот забележан само еден пеисинг од страна на ICD. Стабитен следните 48 часа , испишан во добра општа состојба со полна терапија за срцева слабост. Заклучок: Бура на VT е животозагрозувачки синдром и може да доведе до левовентрикуларна систолна дисфункција и миокардно оштетување, егзацербација на срцевата слабост. Основа во лекувањето е администрација на бета блокер или/и амиокордин. Доколку наведената терапија не доведе до терминирање на VT бурата аплицирање на KCl за подигнување на нивото на К во серум без разлика на неговото базочно ниво е препорачано решение.

Keywords: VT storm, ICD, Tretman

4

Abstract No. 33 p

Theme: **Acute Coronary Syndrome**

Country: **Macedonia**

In which part of the day occurs myocardial infarction most often?

Gjorgjievska Biljana ¹

University Clinic of Cardiology, Skopje, Macedonia ¹

In the first quarter of 2014, 316 patients with myocardial infarction were admitted to the University clinic of cardiology.

Myocardial infarction timing was divided into four six-hour time periods over 24 hours. The largest number of myocardial infarctions occurred in the morning hours, with 102 patients admitted between 6 a.m. and noon.

Factors such as waking and starting physical activities, the peak of cortisol, and catecholamines which increase blood pressure, increase of activity of the autonomic nervous system in the last REM stage of sleep, all these factors lead to increased myocardial oxygen demand in the first hours of the day. Additionally, the platelets are more adhesive to the vessels, and the activity of the fibrinolytic system is not as active in the morning.

These circadian changes lead to higher risk of myocardial infarction in that specific timing of the morning hours in people with plaques in the coronary arteries. Also, it is important for doctors to be sure that prescribed antihypertensive drugs are still active in the morning when patients need it most.

5

Abstract No. **41** p

Theme: **Acute Coronary Syndrome**

Country: **Bulgaria**

INTIMATE DIFFERENCES IN ISCHEMIA MECHANISM IN CORONARY ARTERY DISEASE AND CARDIAC SYNDROME X

Tsonev S¹, Donova T¹, Popova D², Vladimirova R², Nyagolov M⁴, Milanova M⁴, Matveev M⁴

Medical University, Sofia¹, National Military Hospital, Sofia², UMHIC “N. I. Pirogov”, Sofia³, Bulgarian Academy of Sciences, Sofia⁴

The Cardiac syndrome X (CSX) includes patients, mainly women, with the triad of angina pectoris, a positive exercise-strain test and angiographically smooth coronary arteries. The most manifest clinical symptom in those patients is chest pain that is usually more prolonged and severe in CSX than in patients with epicardial Coronary artery disease (CAD).

Aim of the current study is to explore intimate differences in ischemia mechanism in both groups (CSX and CAD) by assessing biomarkers for endothelial dysfunction (ET-1), growth factor (VEGF) and hormonal disbalance (17 β estradiol, α ER).

Material and Methods: The study was conducted on three group of female patients as follows 35 patients of mean age 57.8 \pm 9.6 years with CSX, 33 with CAD (mean age 63.2 \pm 10.1 years) and a control group of 25 healthy controls (mean age 22 \pm 2.5 years). Blood samples are taken for investigation of the serum levels of vascular endothelial growth factor (VEGF), endothelin 1 (ET1) and 17 β -estradiol. VEGF and ET 1 were determined by the sandwich ELISA. 17 β -estradiol was analysed with immune-histochemical method. Both the control and CAD group were investigated for gene expression of estrogen receptor- α (ER- α) with a Real time (rt) polymerase chain reaction (PCR).

Results: Serum levels of VEGF were significantly higher in both the CSX (57.9 \pm 13.9 pg/ml) and CAD (69.0 \pm 10.1 pg/ml) group as compared to controls (47.7 \pm 8.6 pg/ml). ET 1 levels were higher in CSX group (12.6 \pm 2.01 pg/ml) versus the patients of CAD group (10.1 \pm 16.0 pg/ml) (p=0.013). Patients with CSX showed lower 17 β –estradiol levels as compared to those with CAD (7.55 \pm 9.5 versus 12.2 \pm 9.6 pg/ml, p<0.05). Rt-PCR established that the expression of the target gene responsible for the activity of the ER- α in CAD group was 1.46 times higher than in patients with CSX.

Conclusion: VEGF could be used as a marker of ishaemia in investigated groups of patients. The results in the CSX confirmed endothelial dysfunction in close relationship with the observed hormonal imbalance supported by the lower 17 β -estradiol. Both the 17 β –estradiol and ER- α

expression were higher in the group with CAD suggesting an estrogen independent activation of ER- α via growth factors including the VEGF.

Keywords: Cardiac syndrome X, Coronary artery disease, Ischemia, Biomarkers

6

Abstract No. 44 p

Theme: **Acute Coronary Syndrome**

Country: **Macedonia**

Acute dissection of the thoracic aorta – recognition in the internal office

Nikolovski S¹, Nikolovska J²

Health Center, Kriva Palanka¹

Introduction: Dissection of the aorta is a stratification of its layers – the internal one and the medial one, where blood from its real lumen penetrates and makes this parallel lumen a fake one. Because of the pulsing blood supply this fake lumen spreads ante grade, rarely retro grade in different length and width of the aortic wall, communicating with the real lumen through the intimal cleavage.

Goals of the abstract is to point out that even with modest diagnostic methods it can be set a high suspicion of aortic dissection. This case must be urgently transported to a higher level institution and immediately operated so that the patient could survive.

Material and methods: There have been five cases analyzed with the diagnosis of acute aortic dissection of the thoracic aorta. These cases, which were only based on the dramatic clinical appearance of the patient, the obscure EKG and the characteristic RTG of heart and lungs have been highly suspicious of aortic dissection.

Results: Transthoracic echocardiography and CT have been made where the diagnosis of the acute dissection of the thoracic aorta has been confirmed. Immediate surgical treatment has been committed and now these patients are alive and are feeling well.

Conclusion: Modest diagnostic methods that are available in the internal office from the state sometimes are enough to set up a working diagnosis for this disease using the maximum from studying the clinical appearance of the patient, the EKG and the RTG of heart and lungs.

Keywords: acute dissection, thoracic aorta

7

Abstract No. 49 p

Theme: **Acute Coronary Syndrome**

Country: **Croatia**

CARDIORENAL SYNDROME IN PATIENTS WITH ACUTE MYOCARDIAL INFARCTION

Balenović D.¹, Mataga I.¹, Horvat I.¹, Prkačin I.², Šmit I.¹, Bedeniković V.¹, Živanović Posilović G.¹

General hospital „Dr. Ivo Pedišić“, Sisak, Croatia-¹; Internal Clinic, University Hospital Merkur, Zagreb, Croatia -²

INTRODUCTION: Aim of study was determine the presence of cardiorenal syndrome (CRS) in patients(P) with acute myocardial infarction (AMI).

MATERIALS AND METHODS: 209 patients with AMI were included in the one year period. We have distributed P into nonCRS and CRS groups (1 to 5) by calculating glomerular filtration rate (GFR) of the Cockcroft-Gault equation. We identified cardiovascular risk factors (RF) and followed cardiac complications according to Killip classification and recording of cardiac arrhythmias during AMI treatment.

RESULTS: CRS was significantly represented (62,2%), especially type 1. CRS has increased with age, and the most common was over the age of 70 (54,6%). In the women more often presented CRS (77,6%) than in the men (54,9%) although men have more likely to develop AIM (142:67=M:F). There was no difference in the prevalence of type of AMI (STEMI with CRS 70,8% and without CRS 72,2%; NSTEMI with CRS 29,2% and without CRS 27,8%). Killip class 1 was frequently represented in P without CRS (88,6% vs 67,7%), Killip 2 in P with CRS (22,3% vs 8,9%) while Killip 3 and 4 were equally represented in both. Number of complications was associated with level of creatinine-kinase. Cardiac arrhythmias were more often in CRS, mainly ventricular arrhythmias (tachycardia 16,7% vs 8,7%; ventricular fibrillation 13,0% vs 0%). GFR was negatively associated with level of creatinin and positively with proteinuria. All P usually had hypertension (90,4%). All RF were not significantly different between groups, except for diabetes mellitus (DM) wich was almost twice as prevalent in P with CRS (43,1% vs 24,1%). P treated with Urgent percutaneous coronary intervention (UPCI) are rarely developed CRS.

CONCLUSION: early recognition and detection of presence of renal disease in P with AMI as one of the RF that contribute to a worse outcome of heart disease and unwanted complications. DM confirmed as RF for the development of CRS. UPCI is protective factor in the development of CRS.

Keywords: cardiorenal syndrome, diabetes mellitus, kidney disease, myocardial infarction

8

Abstract No. 54 p

Theme: **Acute Coronary Syndrome**

Country: **Macedonia**

Review on the effects of cardiovascular diseases on the driving ability with professional drivers

M.Pazeska, R.Naumoska, M.Samardzioska

Zdravstven Don Prilep

Introduction and purpose of the labor. The main aim of this article is to determine the involvement of cardiovascular diseases (CVD) on the assessment of driving ability among professional drivers, where because of the specifications of their job, the immediate loss of consciousness or immediate death while driving a motor vehicle endangers the safety of passengers and other traffic participants.

Material and methods : The survey included 358 drivers where driving is their main or minor part of their job, and it was taken in 2012, according to the issuing medical driving certificates. The participants were aged between 20 and 69 years of age, where 346 are men, and 12 of the participants are woman. According to the type of the occupation 48 of them are taxi drivers, 36 of them are driving instructors, and 274 are professional vehicle drivers. The assessment of the ability to drive is performed according o the criteria of the driving manual, and we used standard

statistical methods.

Results and discussion: In terms of the ability to drive most of the participants are assessed as capable – 309 (86.3%), capable with limitation because of the use of medical devices (glasses) 26 (7.3%), participants with shorter time limit than the legally permitted limit because of medical issues were 15 drivers (4.2%), and the remaining 8 drivers or (2.2%) are assessed as not capable of being professional drivers. In 8 cases (53.3%) of the professional drivers with shorter time limitations for driving, the main reason is cardiovascular diseases, and in the cases the remaining 13.3% of the drivers the main reason for their limitation are psychiatric or musculoskeletal diseases. For the drivers assessed as not capable of driving, the leading reason is cardiovascular diseases (3 drivers), and insulin – dependent diabetes (3 drivers). CVB is one of the leading causes of time limitation disability and not being capable of driving, and the prevention and the control of cardiovascular diseases will increase the safety of the drivers and the passengers.

Keywords: professional drivers, cardiovascular diseases, taxi drivers, working ability.

9

Abstract No. 71 p

Theme: **Acute Coronary Syndrome**

Country: **Macedonia**

Gender differences in predictive ability of UKPDS model for risk assessment of coronary artery disease in type 2 diabetes patients

Smokovski I¹, Milenkovic T², Cibisev A¹, Davceva-Pavlovska J³, Sadikario S³

University Clinic of Toxicology Skopje¹ University Clinic of Endocrinology, Diabetes and Metabolic Disorders Skopje² University Clinic of Cardiology Skopje³

Aim:

To compare the predictive ability of United Kingdom Prospective Diabetes Study (UKPDS) model for risk assessment of coronary artery disease (CAD) between male and female type 2 diabetes mellitus patients (T2DM) from Republic of Macedonia

Materials and methods:

Observational study cohort of 835 T2DM patients prescribed insulin treatment from September 2002 till January 2004, whose CAD risk was predicted by UKPDS model at the moment of insulin prescription (baseline). Inclusion criteria were age of 25 to 65 years, absence of cardiovascular and life-threatening disease (e.g. cancer) at baseline. Endpoints were cases with CAD by 01 January 2012.

Results:

356 patients (42.6%) were males, both genders followed for 9.4 ± 0.5 years. Age at diagnosis, duration of diabetes and systolic blood pressure were significantly higher in females (49.0 ± 7.0 vs 47.7 ± 7.4 years, $p < 0.01$; 7.0 ± 4.8 vs 6.3 ± 5.1 years, $p < 0.05$; 147.6 ± 21.5 vs 138.3 ± 18.7 mmHg, $p < 0.001$), smoking significantly higher in males (55.6% vs 21.9%, $p < 0.001$), with no difference in HbA1c, total cholesterol and HDL cholesterol ($9.6 \pm 2.1\%$ vs $9.3 \pm 2.0\%$, $p = \text{NS}$; 5.9 ± 1.3 vs 6.1 ± 1.2 mmol/l, $p = \text{NS}$; 1.3 ± 0.6 vs 1.3 ± 0.7 mmol/l, $p = \text{NS}$). Observed risk (O) was 41.0% (95% CI 35.9-46.3) compared to predicted risk (P) of 26.4% in males ($P/O = 0.64$), and $O = 36.4\%$ (95% CI 33.2-39.8) vs $P = 26.4\%$ in females ($P/O = 0.51$); risk underestimation being significantly higher in females (49% vs 36%, $p < 0.05$).

Conclusion: UKPDS model underestimated the risk for CAD in T2DM patients that could be attributed to the very high national cardiovascular mortality risk. UKPDS model demonstrated

lower underestimation in male compared to female T2DM patients. Recalibration of UKPDS model is needed to improve its predictive ability for CAD in T2DM patients from Republic of Macedonia.

Keywords: Type 2 diabetes, CAD, predicted risk, observed risk, UKPDS model

10

Abstract No. 72

Theme: **Acute Coronary Syndrome**

Country: **United States**

ARE WOMEN TRULY DIFFERENT THAN MAN WHEN IT COMES TO DIAGNOSIS, TREATMENT AND OUTCOME OF ACUTE CORONARY EVENT? AN UNSOLVED DILEMMA.

ANETA .K DIMOVA, M.D. , F.A.C.C, Cardiology and Director of Nuclear Cardiology at Mid Valley Cardiology, St. Peters Health Partners, Albany , N.Y., USA and Dr. JELKA DAVCEVA , University Clinic of Cardiology, Skopje, R. Macedonia (2)

MID VALLEY CARDIOLOGY, ST. PETERS HOSPITAL HEALTH CARE PARTNERS, KINGSTON, NY,USA University Clinic of Cardiology, Skopje, R. Macedonia (2)

Recognize the difference in presentation of cardiac disease in women and select more appropriate approach to diagnosis , treatment and prevention in order to improve outcomes and survival.

Integrate the best evidence we have about benefits vs. risk for women with certain procedures and choose appropriate treatment goal.

Is it truth or a myth that our approach and attitude to women with acute coronary syndrome is different compared to a male patient?

How can we reverse the trend of the last 4 decades and save more women lives claimed by coronary disease, still # 1 cause of death among women in USA.

Look at the USA Women Health initiative Program and USA Effectiveness - based guidelines for women. How does the USA experience compare to others and can this knowledge be applied here .

The international applicability of these guidelines is a critical issue because cardiac disease (CVD) has become a global pandemic among women. Approximately 81% of all CVD deaths in women occur in countries where the guidelines have not been developed, applied or embraced either directly or with slight modifications,

Keywords: women, coronary artery disease, management, ,

11

Abstract No. **80** p

Theme: **Acute Coronary Syndrome**

Country: **Macedonia**

ANGINA PECTORIS AND CORONARY ARTERY DISEASE IN AORTIC STENOSIS

Taseski O¹ ; Veselinov-Taseska M²

PZU "Med-Interna"¹ ; PZU "D-r Taseski"² Prilep- Macedonia

BACKGROUND:angina pectoris(AP) is most frequent symptom in p/s with aortic stenosis(AS), with or without concomitant coronary artery disease(CAD).

OBJECTIVE:to determinate prevalence of CAD in p/s with AS with AP symptoms.

PATIENTS AND METHODS:p/s with severe AS who underwent aortic valve replacement(AVR) and preoperative coronarography from january 2011 to december 2013 were retrospectively analyzed.

RESULTS:28 p/s (range 28-81 y/s, mean age 74 y/s), 17 men and 11 women were analyzed.64% had AP symptoms.Significant CAD(coronary aa.stenosis \geq 50%)was found in 26%.68% of those with significant CAD had AP symptoms. AP symptoms were registered also in 35% of non-CAD p/s.

CONCLUSION:CAD is most frequent present in p/s with severe AS, and AP symptoms have good predictive value.Coronarography should be made always before AV replacement to evaluate operative risk and tactics.

12

Abstract No. **81** p

Theme: **Acute Coronary Syndrome**

Country: **Macedonia**

TRIMETAZIDINE AND HEART FAILURE

Taseski O¹ ; Veselinov-Taseska M²

PZU "Med-Interna"¹ ; PZU "D-r Taseski"² Prilep-Macedonia

OBJECTIVE:to establish efficiency of trimetazidine(TMZ) in p/s with ischemic cardiomyopathy and chronic heart failure (CHF) in achieving better quality of life.

PATIENTS AND METHODS:20 p/s (12 man,8 woman) with medium age of 71 y/s with CHF because of ischemic etiology lasting at least 6 months before study was started were included.All p/s had symptoms of CHF and EF<45%.Excluded were those with recent MI,APNS,LBBB,and severe valvular disease.At the beging and after 9 monts ECG,ergo stres test and echocardiography were made.P/s were asked to fill up "questionary of life quality" containing 5 simple questions about theirs everyday activities.TMZ- tbl.35 mg 2x1 was added to conventional therapy for 9 m/s. Control group was with similar age and med.condition-on conventional therapy only.

RESULTS:ergo stres test:max.exercise time increased for 32% and METS for 23%.Echocardiography:improved systolic LV function by 7% increased EF.Better functional status by achiveing lower NYHA grade. Better quality of life for 50%.

CONCLUSION:TMZ as metabolic drug,added to conventional therapy lead to better quality of life in p/s with CHF of ischemic etiology.

13

Abstract No. **82** p

Theme: **Acute Coronary Syndrome**

Country: **Macedonia**

CARDIOVASCULAR COMPLICATIONS IN METABOLIC SYNDROME

Veselinov-Taseska M¹ ; Taseski O²

PZU "D-r Taseski"¹ ; PZU "Med-Interna"² Prilep-Macedonia

Metabolic syndrome (X-Sy.) is a cluster of condition :arterial hypertension,high blood sugar and cholesterol levels, centripetal obesity- that occur together.

OBJECTIVE:to determinate prevalence of CV complications in p/s with X-Sy.

PATIENTS AND METHODS:54 p/s with X-Sy. were retrospectively analyzed for CV complications from february 2013 to february 2014.37 were man,17 women, range 34-67 years,mean 52 years.

RESULTS:most frequent complication of X-Sy. is coronary artery disease (verified by coronarography) - in 18 p/s (34%). 12 of them underwent PTCA/stenting and in 6 p/s CABG was done.Acute myocardial infarction was found in 6 p/s. 24% had acute stroke or TIA. 3% had both-MI an CVI.Peripheral artery disease was obtained in 14%. In one p/t toe amputation was made because of gangrene.

CONCLUSION:CV events are most frequent in p/s with X-Sy. and lead to increased mortality and morbidity.X-Sy is important socio-economycal problem and complex therapeutical approach should be rigorously applied.

14

Abstract No. **83** p

Theme: **Acute Coronary Syndrome**

Country: **Macedonia**

EFFICIENCY OF AMLESSA(AMLODIPIN 10 MG + PERINDOPRIL 8 MG) IN PATIENTS WITH ARTERIAL HYPERTENSION

Veselinov-Taseska M¹ ; Taseski O²

PZU "D-r Taseski"¹ ; PZU "Med-Interna"² Prilep-Macedonia

OBJECTIVE:to determinate efficiency od Amlessa 10+8 in p/s with uncontrolled arterial hypertension(AH).

PATIENTS AND METHODS:40 p/s with uncontrolled AH were involved in our study. 27 were man, 13 women, age 44-70 y/s, mean 50 y/s.AH was uncontrolled (>140/90mmHg), despite previous drug treatment with other antihypertensive drugs.74% of them were taking whole tablet of Amlessa 10+8 and 26% half a tablet once a day .Arterial blood pressure (BP) was registered at 1-st, 4-th and 8-th week.

RESULTS:mean AH lasting was 7 y/s, mean BP in the beging of the study was 160±10 mmHg for systolic and 97±10 mmHg for diastolic BP. Good control of the BP (<140/90mmHg) was achieved at 1-st week in 38% and in 82% at 8-th week.Side effects: cough in 2 p/s (5%) ant pretibial edema in 3 p/s(7,5%).

CONCLUSIONS:Amlessa is a great antihypertensive drug with good efficiency and tolerance.

Advantages of Amlessa are: once a day dosing, it is combined drug and its components are acting synergistically, leading to better control of the AH.

15

Abstract No. **97** p

Theme: **Acute Coronary Syndrome**

Country: **Macedonia**

Combination of genetic mutations could lead to myocardial infarction in a very young male adult - CASE REPORT

Klincheva M, Ambarkova Vilarova E, Anguseva T, Milev I, Idoski E, Mitrev Z

Special hospital for surgery diseases “Filip II”, Skopje, R. Macedonia

Background: Myocardial infarction is a rare medical event in young people. The main reasons include congenital coronary abnormalities, coronary artery spasm, and coronary thrombosis due to hypercoagulable states (hereditary and acquired). We present a case of a young male adult with myocardial infarction caused by a combination of gene mutations and anticoagulation protein deficiency. Material and methods: A 19 years old young man was admitted to our hospital complaining of chest pain during the last two weeks. He was not obese, an active athlete, and a nonsmoker. He does not consume alcohol regularly, no abuse of drugs. The patient had no hypertension, hyperlipidemia or diabetes mellitus. He had no prior history of cardiovascular events. He has positive family anamnesis for coronary artery disease. Subacute inferior nonST segment myocardial infarction was diagnosed according to the patient’s history, electrocardiographic and laboratory findings. Coronary angiography was performed. It revealed subocclusive thrombus in the proximal, medial and distal part of the right coronary artery (TIMI 2). The other coronary arteries had no stenosis. Percutaneous coronary intervention was performed. Anticoagulant and antiagregant therapy (heparin, acetylsalicylic acid and clopidogrel) according to protocol was started. The hospital stay was uneventful. After discharge blood was drawn according to the guidelines for thrombophilia tests and sent for thrombophilic testing. Results: Homozygous endothelial nitric oxid synthase (eNOS) T-786C mutation, heterozygote prothrombin gene mutation (G-20210-A), and protein S deficiency were verified from the thrombophilia testing. Other thrombophilic tests were normal. Three months after discharge from hospital another coronary angiography was performed. It revealed normal coronary arteries. Conclusion: Combination of genetic mutations and anticoagulation protein deficiency could be a reasonable cause for myocardial infarction in a very young male adult without any other cardiovascular risk factors.

Keywords: genetic mutation, myocardial infarction, young men

16

Abstract No. **107** p

Theme: **Acute Coronary Syndrome**

Country: **Macedonia**

GENETIC MUTATION - REASON FOR ACUTE MYOCARDIAL INFARCTION IN YOUNG ADULT – CASE REPORT

Bajraktarova Prosheva T¹, Jordanova ;S¹, Lozanche N.²

Department of Internal Medicine, Clinical Hospital Shtip¹; Clinical Hospital Bitola²

Introduction: Epidemiologic and clinical trials performed in young people under 45 years old,

showed that the occurrence of AMI in this population is uncommon (2% in GISSI trial), with good prognosis and low mortality. In most of the cases more than 2 risk factors are present (smoking, hyperlipidemia, physical inactivity, obesity, diabetes) typical for coronary disease.

Aim of the study: Presentation of AMI in 23 year old male with MTHFR A1298C gene mutation, responsible for cardiovascular diseases and absence of any risk factors.

Material and methods: The medical history of the 23 year old patient who had extensive anterior AMI was analyzed.

Anamnesis: Typical chest pain in entire precordium, both upper arms and the mandibula, that occurred suddenly during the sleep, perspiring with a cold sweat, without any previous anginas' signs. Sportsman, non-smoker, negative familiar anamnesis.

Auscultation findings on lungs and heart were normal. TA 130/80 mm Hg.

Electrocardiogram- sinus rhythm, HR 111/min. ST elevation up to 4mm in V1-V5 and 0,5-1mm in the inferior leads and QS form in V1-V3 leads. Ventricular fibrillation occurred short after hospitalization, it was converted in sinus rhythm by one DCES.

Coronarography – a stent was placed on the proximal segment of LAD (Endeavor 3,5/30x14atm)TIMI 3 flow.

Biochemistry: elevated troponin levels,CK-MB, AST, LDH.

Echocardiography - mildly reduced ejection fraction 50%. Hypokinesia of the middle and apical segment of anterior wall and IVS, apical dyskinesia.

Genetic examination: 12 genetic mutations and polymorphisms related to high cardiovascular diseases risk were analyzed by the method of reverse hybridization. The patient was genotyped as heterozygote for A1298C mutation in the gene for MTHFR (methylenetetrahydrofolate reductase).

Conclusion: The occurrence of AMI in the young population is uncommon, in particular under the age of 30. In the most cases patients are affected with multiple risk factors in combination with a genetic predisposition. In this case the presence of a gene mutation with high cardiovascular risk is the only proved cause for AMI. The prognosis for that patients is good in case the patients are properly treated in time and they observe the hygienic-dietary recommendations.

Keywords: Key words: Acute myocardial infarction, genetic mutation, young population

17

Abstract No. **137** p

Theme: **Acute Coronary Syndrome**

Country: **Macedonia**

Rhythm disturbances in patients treated in Cardiac Intensive Care Unit

E. Shehu¹, M. Vavlukis¹, V. B. Pocesta¹, E. Caparoska¹, H. Taravari¹, D. Kitanoski, I. Bojovski, I. Kotlar, I. Jovanovska, S. Kedev¹.

University Clinic for Cardiology, Skopje, Macedonia

Aim of the study:

An overview of the prevalence of rhythm disturbances in ICCU treated patients over the one year period.

Material and methods:

Single centre retrospective observational study. From all patients treated in ICCU during the one

year period we separated patients with rhythm disturbances. Observed variables were: age, gender, and type of dysrhythmia, treatment for termination (medical versus electrical cardioversion), basic cardiac condition, major comorbidities, complications and hospital mortality. Statistical analyse: descriptive and comparative analyse was performed with t-test, Chi square test. Statistical significance determined at <0.05.

Results:

464 (14, 2%) of 3257 patients treated in ICCU during 2013, were patients with dysrhythmias. Type of dysrhythmia: 269 (48%) of total arrhythmias were atrial fibrillations, 45 (9,7%) of which, paroxysmal, terminated medically and 17 (3, 7%) with cardioversion. 32 pts. had regular narrow QRS tachycardia, terminated medically (6, 5%), and 2 with cardioversion. Ventricular dysrhythmias were more rare 163 (35, 1% of all, $p<0.000$). Nonsustained ventricular tachycardia (NSVT) was observed in 18 (6, 3%) of patients. The rest were malignant ventricular arrhythmias: 145 (31, 3%), 6, 1% of which SVT and 82 (17, 7%) VF.

Gender distribution: Males predominated (68,1%), they had OR 1.8 ($p=0.004$) to have dysrhythmia, with ventricular arrhythmias predominating (26,7% of total, OR 1,8). In contrary, AF predominated in female patients, with 23,5% (OR 1,5; $p=0.004$), and they were significantly older (66 ± 11 y. vs 61 ± 12 y.; $p<0.000$).

Aetiology: In 24, 1% arrhythmia occurred in patient without known previous cardiac condition, 8,4% of which were malignant ventricular arrhythmias. 30, 1% (22, 4% atrial and 7, and 7% ventricular) of arrhythmias were associated with dilated and ischemic CMP, and 6% in patients with hypertensive or hypertrophic CMP. CAD was in the aetiology of 9, 1% of atrial, and 10, 6% of ventricular dysrhythmias, more precisely patients with ACS.

Mortality rate was vary high (27, 6%), out of which, 13, 6% due to atrial and 14% to ventricular arrhythmias (OR for VT/VF 2,50; $p=0.000$). 14,2% of total mortality was in pts. with ischemic and dilated CMP, 6,3% associated with ACS (malignant ventricular arrhythmias), and 1, 7% were sudden cardiac death patients with unsuccessful resuscitation.

Acute, and acute worsening of chronic renal failure were the most commonly associated comorbidities with hospital mortality in patients with arrhythmias.

Conclusion:

This analyse pointed out to the high risk patient population, in whom arrhythmias are more commonly a consequence of severe cardiac condition that worsens the underlying disease. Treatment of arrhythmias is not necessarily associated with the treatment of arrhythmia per se but also with the treatment of underlying disease.

Keywords: arrhythmia

18

Abstract No. **143** p

Theme: **Acute Coronary Syndrome**

Country: **Macedonia**

Anti-anginal and anti-ischemic effect of Trimetazidine in patients with stable angina pectoris

Taneva B¹, Miletic B¹, Tosev S¹, Kostova N¹, Buseva M¹, Lazarova E¹

Clinic of Cardiology, Skopje, Rep of Macedonia, ¹

The orally administrated antianginal agent Trimetazidine increases cell tolerance to ischaemia by maintaining cellular homeostasis.

The objective is to assess the anti-ischaemic and antianginal efficacy of trimetazidine 35mg taken twice daily by patients with stable angina pectoris. Methods: One hundred and twenty patients with SA were randomised into the trimetazidine group (n=60) and the control group (n=60), the trimetazidine group was subjected to treatment with 70mg of trimetazidine everyday for six months plus conventional treatment with beta-blockers as the control group has. Two exercise tolerance tests (ETTs) were performed (after three months of treatment and at the end of the study), in order to assess the stability of exercise tolerance before angina pectoris and significant ST segment depression.

Results: Time to 1mm ST segment depression was increased by 47 seconds more in the trimetazidine group than in the control group (p=0.005). There was a significant difference evidenced for the time to onset of angina pectoris (p=0.048). No difference between groups was found for safety parameters.

Conclusion: Adjunctive therapy with trimetazidine 35mg twice daily can have a beneficial anti-ischaemic and antianginal effect in patients with stable angina pectoris receiving a conventional therapy with beta-blockers.

Keywords: SA-Stable angina; ETTs-Exercise tolerance tests

19

Abstract No. **145p**

Theme: **Acute Coronary Syndrome**

Country: **Macedonia**

Планирање и спроведување на здравствена нега на одделот за интензивна нега на кардиологија

Николина Илиевска – Петревска

Универзитетска Клиника за Кардиологија-Скопје, Македонија

Планирање на здравствена нега на болниот на одделот за интензивна нега опфаќа утврдување на приоритетот, дефинирање на цели, планирање на интервенции, како и изработка на план на здравствена нега. Се собираат податоци со метода на интервјуа (социјална вештина, планиран разговор на две личности кои имаат меѓусебно комплементарни улоги), опсервација (изглед, функција на делови од телото, се почнува од главата и се продолжува до најдолните делови од телото), набљудување по системи (изглед и функција на делови од телото кои се во врска со поедини системи) и опсервација на психофизичкото функционирање (се собираат податоци за перцепцијата и односот според здравјето, исхраната, елиминацијата, телесната активност, спиењето и одморот, когнитивно – перцептивните функции, перцепција на самиот себе, улогата и односот со другите, сексуалната активност и репродукција, соочување и толеранција на стрес, вредности и ставови), мерење и анализа на документацијата. Содржината на собраните податоци ја дава сестринската анамнеза. Сестринска анамнеза е збирка на податоци за телесните, психолошки и социјалните аспекти на мината и сегашна здравствена состојба како и однесувањето на здравиот или болен пациент, со цел за утврдување за потреба за здравствена нега. Земање на анамнеза кај пациентите во акутна фаза на болеста се сведува на неколку кратки прашања или исклучоци. Ако пациентот е витално загрозен се пристапува кон земање на хетероанамнеза. Се поставуваат прашања од типот:

- Кога настапиле симптомите?
- Кои тегоби болниот ги има сега?
- Кои лекови ги има земено?

- Дали е алергичен на некој лек или контрастно средство (поради евентуална коронарографија)?

Кога болниот е стабилен и може да соработува се зема комплетна анамнеза. Многу е важно да се присоберат податоци за болката; кога почнала, што болниот правел во моментот на појава на болката, колку долго траела и дали е намалена при земање на нитрати или при мирување. При земање на анамнеза се набљудува болниот. Се врши физикален преглед кој е начин на набљудување и вклучува инспекција (визуелно набљудување), аускултација (аудитивно), палпација (тактилно) и перкусија (аудитивно). Важно е да се воочат и други симптоми како што се диспнеја, тахикардија или брадикардија, тахипнеја или брадипнеја, бледило, мачнина, повраќање и немир на болниот, како и други можни симптоми кои можат да не предупредат на развој на компликации.

Целта во процесот на здравствената нега е посакуван, но и реален исход на здравствената нега. Целта мора да биде јасен и прецизен опис на состојбата и однесувањето на болниот. Кога состојбата на болниот е критично или кога е тешко да се предвиди развој на ситуација во иднината, како што е случај на одделот за интензивна нега, се формулираат краткорочни цели. Тие се постигнуваат за неколку минути, часови или денови, се однесуваат на сегашноста и проблеми кои имаат потреба од итно решавање.

20

Abstract No. **149** p

Theme: **Acute Coronary Syndrome**

Country: **Macedonia**

Anemia, renal impairment and in-hospital mortality, in acute worsening chronic heart failure patients

Bojovski I¹, Vavlukis M¹, Caparovska E¹, Pocesta B¹, Shehu E¹, Taravari H¹, Kitanoski D¹, Kotlar I¹, Janushevski F¹, Taneski F¹, Jovanovska I¹, Kedev S¹

University Clinic of Cardiology, Skopje¹

Aim of the study:

The aim of our study was to analyze the impact of anemia and renal impairment, on in-hospital mortality (IHD), in patients with acute worsening chronic heart failure.

Methods:

232 randomly selected patients admitted to ICCU, because of symptoms of HF, were retrospectively analyzed. Analyzed variables: gender, age, risk factors and co-morbidities: HTA, HLP, DM, COPD, CAD, PVD, CVD, anemia (defined as Hgb \leq 10mg/dl), renal failure.

Measured variables: systolic and diastolic BP, Hgb, sodium, BUN, creatinine, length of hospital stay and IHD. Comparative analysis was performed between patients with in-hospital mortality (IHD) and survivors, as a function of anemia and renal impairment.

Statistical analysis: descriptive and comparative analysis, t-test, Chi square, univariate (binary logistic and linear regression) and multivariate linear regression (stepwise backward).

Results:

Mean age 69.6 \pm 11.4, 102 (44%) females and 130 (56%) males, with females being significantly older 72.6 \pm 12.5 vs. 67.7 \pm 10.2 (p=0.002), with significantly higher SBP, DBP and sodium level (p=0.003; 0.002 and 0.028 respectively), and males having HTA more often OR 1.3; p=0.017.

Mean hospital stay was 6.8 \pm 5.8 days, with significant difference between IHD and non IHD

group (7.9+/-4.5 vs. 3.8+/-7.9; p=0.000), with the highest mortality during the first (37.3%) and second hospital day (44.1%). 44 pts. (19%) had anemia, 31(13.4%) had known Chronic Renal Failure (CRF), and 59 (25.4%) had IHD. Anemia was significantly associated with IHD (sig 0.012, Exp B 2.48, sig 0.010), meaning pts. with anemia had 2,5 times greater risk for IHD. CRF per se, was not associated with IHD. Univariate linear regression identified creatinine (beta .180, sig 0.006), and BUN (034, beta .184, sig 0.005), as predictors of IHD. Multivariate stepwise regression model (anemia, CRF, Hgb, BUN, creatinine, sodium) at step 3 (mean square .799, sig 0.002), identified two independent predictors Hgb (beta -.148, sig 0.028), and BUN (beta .163, sig 0.055). Multivariate model that included other known predictors of IHD (EF%, SBP, DBP, CRF, CAD, anemia, Hgb, BUN, creatinine, sodium) at step 8 (mean square 1.537, sig 0.000), identified four independent predictors: EF% (beta -.204, sig 0.002), SBP (beta -.130, sig 0.052) as markers of systolic dysfunction, and again anemia (Exp B 2.2.06, sig 0.041), and BUN (beta .200, sig 0.002).

Conclusion:

Anemia and renal impairment are well known comorbidities associated with HF, that have great impact on course of HF. We confirmed that anemia and BUN, are significantly independent predictors of in hospital mortality in acute worsening CHF.

Keywords: IHD, CHF, CRF, Anemia

21

Abstract No. **150** p

Theme: **Acute Coronary Syndrome**

Country: **Macedonia**

Glucoregulation in diabetic and no diabetic patients and the impact on early clinical outcome in patients with acute coronary syndrome

Kitanoski D¹, Vavlukis M¹, Caparovska E¹, Pocesta B¹, Shehu E¹, Taravari H¹, Bojovski I¹, Kotlar I¹, Jovanovska I¹, Kedev S¹

University Clinic of Cardiology, Medical Faculty, Skopje, R. Macedonia¹

Aim of the study:

The aim of our study was to analyse the impact of glicoregulation before and during the hospital treatment in patients with acute coronary syndrome on early in-hospital clinical outcome (CE).

Methods:

We included in the analyse ACS patients (STEMI, NSTEMI, APNS) treated with PCI, in whom we analysed: demographics, risk profile, basic biochemical variables (Hgb, BUN, creatinine, Na, K), lipid profile (Tg, HDL, LDL Hol, lpa), HgbA1C, admitting glucose level and levels of glucose during the hospitalisation, and TIMI flow before and after PCI procedure. We divided patients in diabetics and non-diabetics. Than based on the level of HgbA1C measured at admition we subdivided diabetics in good (<6.5%), and bed controled (>6.5%) DM, and patients without previously known diabetes in three groups: no diabetics (<5.6%), prediabetics (5.6-6.5), and diabetics (>6.5) HgbA1C. Based on glycaemic levels we divided pts. in groups: good regulation (5-10mmol/L), bed regulation: >10mmol/L epizodes, and <5mmolL aeizodes. We analyzed influence of glikoregulation on biochemical variables and lipide profile, PCI results (TIMI flow), and cardiac events (heart failure, shock, dysrhythmias, GIT bleeding, CVI and cardiac death).

Statistical analyse: descriptive and comparative statistics with t-test, uni and multivariate

analyse. Significance determined at 0.05.

Results:

80 pts. Were included in the analyse (33.8% females and 66.2% males), at mean age of 60.2 ± 10.8 y. Risk profile: 51% had HTA, 6.3% HLP, 36.3% positive family history, 33.8% were diabetics, 61.4% smokers, 5% previous CAD. Mean Hgb 14.6 ± 1.4 mg/dl, BUN 5.9 ± 3.2 , creatinine 80.5 ± 30.6 micromol/L, Na 137.5 ± 3.4 , K 4.2 ± 0.5 . No differences in biochemical and lipide profile was found between groups. Among 53 no diabetic patients prior to ACS, we identified 4 (5%) patients with diabetes ($>6,5$), and 18 (22.5%) with pre-diabetes (5.6-6.5%). Mean TIMI flow was 0.45 ± 0.79 before, and 2.96 ± 0.19 after PCI, $r = -.221$, $p = 0.000$. The single independent predictor in multivariate analyse (included HgbA1C, admitting glycaemic level, glucoregulation and diabetic group) on TIMI flow was admitting glycaemia (beta $-.327$, $p = 0.003$). 12/80 pts. had CE, and again we included same variables and identified two independent predictors of CE: admitting glycaemic level (beta $.386$, $p = 0.007$) and HgbA1C (beta $.254$, $p = 0.070$).

Conclusion:

Stress hyperglycaemia (admission glycaemic level) was found to be significant predictor of PCI results, and together with HgbA1C level of CE in ACS patients treated with PCI.

Keywords: Stress hyperglycemia in Acute coronary syndrome

22

Abstract No. **151** p

Theme: **Acute Coronary Syndrome**

Country: **Macedonia**

Early rehospitalizations in patients treated for acute coronary syndrome – can we identify predictors?

Kotlar I, Vavlukis M, Caparovska E, Pocesta B, Shehu E, Taravari H, Kitanoski D, Bojovski I, Taneski F, Janushevski F, Jovanovska I, Kedev S

University Clinic of Cardiology, Skopje, R. Macedonia

Aim of the study:

The aim of our study was to analyze early rehospitalization rate (defined as 90 days after the acute event) in patients with STEMI, NSTEMI and APNS, in an attempt to identify predictors that can help us recognize patients at risk for readmission.

Methods:

463 randomly selected patients with ACS admitted to ICCU, were retrospectively analyzed. Analyzed variables: type of ACS (STEMI/NSTEMI/APNS), location of MI, gender, age, risk factors and comorbidities: HTA, HLP, DM, COPD, CAD, PVD, CVD, EF %, type of treatment (PCI versus noninvasive), extensiveness of coronary disease, GRACE and TIMI risk score, occurrence and type of morbidity during hospitalization, and reason for rehospitalization (ischemic events, heart failure, malignant arrhythmias etc.). Comparative analysis was performed between patients with early rehospitalization and others. Statistical analysis: descriptive and comparative analysis, t-test, Chi square, univariate (binary logistic and linear regression) and multivariate linear regression (stepwise backward).

Results:

463 patients were enrolled: 68.9% males mean age 60.4 ± 10.9 , and 31.1% females mean age 64.94 ± 12.0 y ($p = 0.000$). MI type: STEMI 75.8%, NSTEMI 11.2%, APNS 13%; MI location:

40.2% anterior, 39,7% inferior, 3% lateral and 3.7% multiple locations (p 0.000). Risk profile: 15.3% HCAD, 27% HF symptoms, 62% HTA, 28.1% diabetes, 5.8% PVD, only 2.6% COPD. Mean BMI was 27±2.9, mean SBP 138.8±28.5mmHg, mean HR 84.3±24.2, mean EF (in 208 pts.) 50.2±10.4%, mean GRACE score (in 72 pts.) was 148.9±60.6, mean TIMI score (in 263 pts.) was 3.9±2.2. 87.5% were treated with PCI procedure, with mean disease's CA 1.84 (range 1-5), median 1 (p 0.000). Hospital morbidity was present in 16% of pts., 6.9% of which were minor bleeding complications, major bleeding complications in 3%, acute HF in 2.4%, pericardial effusions in 1.9%, and 1.1% early stent thrombosis and intervention. Early rehospitalization rate was 6.3% (29/463pts): 14 because of ischemic/thrombotic event (one reinfarction, and one infarction in other CA); 9 because of acute heart failure, 3 because of malignant arrhythmias, and three fatal events.

Univariate predictors of RH: HR (beta .116, r -.217, p 0.002); EF (%) (beta -.234, r -.231, p 0.001). HTA was significantly associated with reduced hospitalization risk (exp B .405, p 0.054), diabetes (exp B 3.45, p 0.001), PVD (expB 2.85, p 0.070), early in-hospital morbidity during the first hospitalization (expB 2.12, p 0.084), and NSTEMI pts. had OR 1.3, and APNS pts. OR 1.16 for rehospitalization (higher but not significantly in comparison to STEMI pts.).

Multivariate model with variables that were found significantly associated with HR, identified two strong independent predictors of early rehospitalization(mean square .424, sig 0.000), EF (beta -.220, p 0.001), and diabetes (t 2.52, p 0.012).

Conclusion:

LV systolic dysfunction was again proven to be a strong predictor of clinical outcome in terms of early hospital readmission in ACS patients no matter how they were treated for ACS, and diabetes was the single strong independent predictor-risk factor for this event.

Keywords: acute coronary syndrome, early rehospitalization, predictors

23

Abstract No. 158

Theme: Acute Coronary Syndrome

Country: Macedonia

Anticoagulation in patients with atrial fibrillation and it's correlation to current guidelines- first Macedonian registry for atrial fibrillation treatment

Lazarova Trajkovska E.¹, Poposka L.¹

University Clinic of Cardiology¹

AIM: The first Macedonian registry for atrial fibrillation (AF) has the goal to monitor the treatment of patients (pts) with AF in Republic of Macedonia (RM) and to see whether or not it's in accord with the new European Society of Cardiology (ESC) guidelines. It's made as a result of need for systematic collection of contemporary data regarding the management and treatment of AF in RM

MATERIAL AND METHODS: The national registry for AF started in 2013 and up to date have been enrolled 165 pts. We conducted a registry of consecutive in- and outpatients with AF presenting to cardiologists in five participating Cardiovascular centers all over RM. All patients with an ECG-documented diagnosis of AF (first diagnosed, paroxysmal, persistent or permanent) were enrolled (35,3% female, 64,7% male). Common comorbidities were hypertension, coronary disease, and heart failure. Amiodarone was the most common antiarrhythmic agent used , while beta-blockers and digoxin were the most used rate control

drugs. Oral anticoagulants (OACs) were used in 80% overall, most often vitamin K antagonists (71.6%), with novel OACs being used in 8.4%. Other antithrombotics (mostly antiplatelet therapy, especially aspirin) were still used in one-third of the patients, and no antithrombotic treatment in only 4.8%.

CONCLUSION: The preliminary data from the first Macedonian registry for AF treatment has shown that oral anticoagulants use has increased, but novel OAC use is still low. Compliance with the treatment guidelines for patients with the high stroke risk scores remains suboptimal.

Keywords: Atrial fibrillation, Registry, Anticoagulation

24

Abstract No. **188**

Theme: **Acute Coronary Syndrome**

Country: **United States**

2014: NEW LIPID THERAPY CHOICES ARE ALMOST HERE

ANETA K. DIMOVA, MD, FACC

**MID VALLEY CARDIOLOGY, DIVISION OF ST. PETERS HEALTH PARTNERS,
ALBANY, NY, USA**

**NEW LIPID RECOMMENDATIONS IN THE USA AND NEW LIPID TRIALS ALREADY
IN PROGRES.**

ARE WE GOING TO CHANGE

25

Abstract No. 195

Theme: Acute Coronary Syndrome

Country: Macedonia

**Stable coronary artery disease through all the diagnostic procedures
in cardiology**

Kaeva S., Andova V. Pejkov H.

Background: Stable coronary artery disease (CAD) is defined as an established pattern of angina pectoris, a history of myocardial infarction (MI), or the presence of plaque documented by catheterization. Coronary artery disease causes roughly 1.2 million heart attacks each year, and more than forty percent of those suffering from a heart attack will die. Early medical examination and diagnosis with all the diagnostic procedures available in cardiology will prevent further more serious cardiovascular events.

AIM: The aim of the study was to highlight the meaning of the diagnostic procedures in cardiology and their role to reveal and prevent SCAD.

CASE REPORT: A 61 year old men was admitted to our hospital with symptoms as dyspnea, difficult breathing, fast and arrhythmic heart rate without any chest pain.

EKG: EKG showed arrhythmic heart rate (atrial fibrillation) ~120 beats per minute, without any ST segment changes.

At examination he had systolic murmur 2/6 at ictus cordis, weakend billateral vesicular breathing, ascit fluid and pretibial and crural oedema.

Echocardiography: showed reduced EF 44%, hypokinetic infero-posterior wall. Dilated LA with mild MR.

RTG pulmo et cor: bilateral bronchopneumonia and pleural effusion .

EHO of lungs with pleural diagnostic puncture: showed transudate

Thyroid gland : euthyroid state

The patient was stabilized and transferred to the department of pulmonology for further examination.

At first check up his symptoms improved, EKG was in sinus rhythm medicamentously converted. Ambulatory stress Echocardiography was made and showed no ischemia only scar tissue in the field of RCA.

Consequently MRI and coronarography were made. The patient had two vessel disease and was treated with DES stent on Cx because of high grade of stenosis (90%). RCA was completely occluded as it was documented with the previous methods.

Conclusion: Different diagnostic tools and methods help us to discover and prevent SCAD.

Besides exercise EKG, stress Echo-imaging and MRI should be more routinely used because of their accuracy and noninvasive approach

4. Peripheral arterial disease

1

Abstract No. 22 p

Theme: **Peripheral arterial disease**

Country: **Macedonia**

Stroke and atrial fibrillation

Petrovska Cvetkovska D, Dolnenec Baneva N, Nikodijevik D

University Clinic of Neurology, Faculty of Medicine, Ss Cyril and Methodius University, Skopje, R. Macedonia

Background and Purpose: The role of the atrial fibrillation (AF) as a determinant of stroke outcome is not well established. The most previous studies focused on this topic, was made on relatively small samples of patients, and represented in the older age groups. One of the biggest multi-centric study in Europe, is the European Community Stroke Project, that included 4462 patients hospitalized for first-in-a-lifetime stroke, conducted in 7 European countries. The purpose of the study was to evaluate clinical characteristics and outcome of stroke associated with AF, in stroke patients, hospitalized at the University Clinic of Neurology, Skopje.

Methods: The study was prospective, open labeled, in duration of three years, and included 1130 patients with supratentorial stroke, hospitalized at the University Clinic of Neurology, Skopje. We analyzed the most common risk factors for stroke. Anatomic-morphological diagnosis was made using computer tomography (CT) of brain. We analyzed the patients with

stroke associated with AF, by the previous uptake of anticoagulants, CT findings (multiple/one lacunar infarction), clinical presentation, but also by disability (Barthel Index) and handicap (Rankin scale).

Results: AF was present in 211 patients (18.6%). AF patients, compared with those without AF, were older (mean= 69.4±11.7), more frequently female (63%), and more often had experienced a previous transient ischemic attack. 79% of patients had multiple infarctions on CT scan, without previous stroke symptoms. With control for baseline variables, AF increased by almost 51% the probability of remaining disabled (multivariate odds ratio 1.39, 95% CI 1.09 to 1.78) or handicapped (multivariate odds ratio 1.53, 95% CI 1.15 to 2.05). Before stroke, only 14.6% of AF patients were on anticoagulants.

Conclusion: Stroke associated with AF has a poor prognosis, but also leaves big residual disabilities and handicapped. The adequate therapy in patients with AF is a major therapeutic challenge for prevention of stroke.

Keywords: stroke, atrial fibrillation, anticoagulants

2

Abstract No. 23

Theme: **Peripheral arterial disease**

Country: **Bulgaria**

Prevalence of cardiovascular risk factors among women in Bulgaria

Naydenov S¹, Runev N¹, Manov M¹, Milanova M², Tsonev S¹, Koshtikova K¹, Dimchovski E¹, Donova K¹,

Department of Internal diseases, “Prof. St. Kirkovich”, Medical University – Sofia, Bulgaria¹, MBALSP “Pirogov”²

Cardiovascular diseases are the leading cause for death among women worldwide.

Object of the study: Evaluation of the risk profile and the control of some correctable cardiovascular risk factors (RF): arterial hypertension (AH), obesity, diabetes mellitus (DM) type 2, dyslipidemia, etc. among women.

Material and methods: A cross-sectional study, including 178 consecutive women mean age 59.8±12.4 (23-87) years. Examinations we performed included measurement of the blood pressure (BP), height, weight, waist circumference (WaC), calculation of body mass index (BMI). Women, included in the study completed an inquiry form, containing questions about presence and control of some cardiovascular risk factors as well as demographic characteristics. Completing a questionnaire, created by the US National diabetes association (US NDA) they were also assessed for the risk of development DM type 2.

Results: Arterial hypertension was the most frequent RF among the women in our study – in 76.96% (n=137), followed by overweight/obesity – 59.6% (n=106), dyslipidemia – 35.95% (n=64), DM type 2 – 12.9% (n=23), smoking 8.4% (n=15), hormone replacement therapy with oestrogenes – 3.4% (n=6). The mean value of the measured systolic BP was 137.6±16.3 (87-194) mmHg and the diastolic BP – 88.2±14.4 (55-124) mmHg. The mean value of the calculated BMI for the whole group was 28.9±3.8 (18-51) and WaC – 96.6±13.4 (56-132) cm. The average calculated risk for DM, assessed by the US NDA questionnaire was 9.52±4.71 (0-20), corresponding to high risk.

Conclusion: Cardiovascular risk among the analyzed group of women is high. Arterial hypertension has a leading role among RF, followed by overweight/obesity and dyslipidemia.

Despite the existing contemporary therapeutical possibilities – medical and non-medical, the control of RF is insufficient.

Keywords: cardiovascular risk, women, control of risk factors

3

Abstract No. 31 p

Theme: **Peripheral arterial disease**

Country: **Macedonia**

Upper Extremity Venous Duplex

Gjorgjievska Biljana¹

University Clinic of Cardiology, Skopje, Macedonia¹

The purpose of venous imaging of upper extremities is to determine if venous thrombosis is present in the deep veins of the upper extremity and neck, and if so, to define its location and extend. Upper extremity DVT is rare but associated with considerable morbidity and mortality. 4-10% of all cases of venous thrombosis may involve the subclavian, axillary or brachial veins. Indications for the upper extremity vein evaluation include swelling, tenderness or pain of the arm or neck, cyanosis of the arm, pulmonary embolism, thrombosed access line. Routinely an upper extremity venous study include only the symptomatic arm. Bilateral examinations are performed on patients with bilateral edema, source of pulmonary embolism, or when requested by the ordering physician.

Case study: 27 year old female awoke with pain and swelling of the left arm. She had history of deep vein thrombosis in the right arm 2 years ago. Venous duplex findings were acute DVT of the subclavian vein and axillary vein to the confluence of the basilic and brachial veins.

Hospitalization and parenteral anticoagulation were recommended to the ordering physician.

Duplex ultrasonography is sensitive and specific, and initial evaluation with ultrasound has been recommended rather than other initial tests including highly sensitive D-dimer or venography.

4

Abstract No. 32 p

Theme: **Peripheral arterial disease**

Country: **Macedonia**

Subclavian steal

Gjorgjievska Biljana¹

University Clinic of Cardiology, Skopje, Macedonia¹

The most common vertebral artery pathophysiology is subclavian steal. In normal circumstances, anterograde flow is maintained in the vertebral arteries. Proximal subclavian stenosis or occlusion can cause ipsilateral vertebral flow to reverse (retrograde), completely or partially, to supply blood flow to the arm. The contralateral vertebral flow increases to provide the flow volume to the arm. Subclavian steal is most commonly diagnosed during Doppler ultrasound examination of the neck arteries. Early systolic deceleration waveform is consistent with subclavian stenosis. Bi-directional flow results from increasing degree of subclavian stenosis. Flow is retrograde in systole but returns to an anterograde direction in diastole. Complete reversal of vertebral artery flow is diagnostic of a full subclavian steal.

Cases of successful correction of subclavian steal with PTA/Stenting at the University Clinic of Cardiology Skopje are reported. Case study 1: complete proximal occlusion of left subclavian

artery. Case study 2: 90% stenosis of left subclavian artery. The clinical presentation, investigations and treatment are described. The both patients underwent percutaneous transluminal angioplasty with stenting using the radial artery approach, with an excellent response. Normalization of flow in the vertebral artery was noted with duplex ultrasound. Subclavian steal occurs more commonly on the left side, but can occur on the right side. PW Doppler spectral analysis of vertebral arteries during ultrasound examination provides necessary information to prove the presence of subclavian steal. Our case studies demonstrated that percutaneous transluminal angioplasty and stenting is safe and effective.

5

Abstract No. **53**

Theme: **Peripheral arterial disease**

Country: **Macedonia**

Venous thrombembolism – Importance of national registries

Bosevski M

University Cardiology Clinic, Skopje, Macedonia

Background. There is a debate regarding importance of national registries vs. multinational ones. A comparison of national vs. international registry on the venous thrombembolism (VT = deep venous thrombosis and/or pulmonary embolism) was done in this paper.

Methods. 19 multinational registries and 5 national ones were found, while searching Clinical trials and Pub Med/Medline. Macedonian registry on VT (2013/14 done) is linked to Macedonian Society of Cardiology' web. Risk factors for VT, modality and duration of treatment and clinical outcome of these pts, as well, have been assessed in our national registry. Results. Most of the registries are dealing with short term prognosis of these pts. Important difference of our registry is follow up for at least 1 year. All of registries are dealing with same drugs and clinical entry data set for risk factors. Some data for registries are suboptimal, as surgical complications. The advantage of national registry is an inclusion of pts nationwide, but not from academic centers only.

Conclusion. These observations have implications for performing a national registry on venous thrombembolism.

Keywords: venous thrombembolism, registry

6

Abstract No. **62 p**

Theme: **Peripheral arterial disease**

Country: **Macedonia**

Angioplasty and stenting as first line treatment of peripheral arterial CTO (case report)

Manchevski D¹, Bakracheski N¹, Zimbova M¹, Mitreski S¹, Kovacheska Bashurovska E¹, Sheshoski B¹, Stefanovski B¹;

Institute for Cardiovascular Diseases – Ohrid¹

Aim:

To show that revascularization using endovascular interventions should be considered first line approach of treatment in patients with peripheral arterial obstruction and lifestyle limiting or disabling claudications, where other non interventional therapies have failed. This treatment

should be considered as a therapy of choice depending on the anatomical level and the extent of arterial obstruction.

Materials and methods:

We analyzed 67 y.o. patient presented with claudications after 50-100 meters (Fontaine class IIb). Using duplex ultrasonography, occlusion of the left superficial femoral artery was diagnosed, and the disease was verified using intra-arterial digital subtraction angiography(DSA). The treatment of choice was angioplasty and stenting of the chronic total occlusion of the left AFS.

The procedure: Percutaneous Transluminal Angioplasty with stenting of the AFS was performed, with implantation of 2 self expandable nitinol stents (Astron pulsar Biotronik 6.0x80mm) and post dilatation with 6.0x40mm Passeo Biotronik balloon catheter with excellent result.

2 months follow up: The patient has significant improvement of the pain free walking distance (>400m). Duplex ultrasonography of the femoral artery shows peak systolic velocity of 90-100sm/sec. Angiography performed 60 days after the procedure showed patency of the placed stents with no in stent stenosis.

Conclusion:

The low morbidity and mortality, the high technical success rate and the acceptable durability of percutaneous transluminal angioplasty and stent implantation, makes it the perfect first line treatment for most arterial obstructions in the femoro-popliteal segment.

Keywords: chronic total occlusion; peripheral artery disease; endovascular revascularization, superficial femoral artery occlusion; self-expandable stent;

7

Abstract No. 69 p

Theme: **Peripheral arterial disease**

Country: **Macedonia**

Hypertension and Metabolic Syndrome in Macedonian Population

Gjorgov N.⁻¹, Avramovski A. ⁻¹, Ilievski M. ⁻¹, Gjorgova S. ⁻¹, Gjeorgjievski M. ⁻¹,

Polyclinic Akus Medikus

Background: Hypertension (HTN) remains a major public health problem and is associated with an increased incidence of all cause and Cardiovascular disease mortality, stroke, coronary heart disease, heart failure, peripheral arterial disease, and renal insufficiency. Many factors contribute to development of metabolic syndrome (MetSy), which in its turn contributes to the perpetuity of hypertension. Dilemma with many doctors is to when, where and how to manage both hypertension and metabolic syndrome.

Methods: All patients undergoing management for hypertension and metabolic syndrome underwent various tests (height, weight, sex, blood pressure, waist circumference, lipid profile, fasting glucose level, glycosylated hemoglobin, fasting Insulin level, Uric Acid and C-reactive protein.

Results: We present data from our management of hypertension and metabolic syndrome which is geared toward increasing endogenous NO levels with dietary reduction of fructose, alcohol, current available medication that increase endogenous availability of NO and reduction of uric acid. Initial results show significant reduction in both systolic and diastolic blood pressure and improvements in most metabolic parameters along with increase in maximum physical capability. Data showed significant correlation ($p<0.05$) for many parameters such as: waist

circumference, body mass index, homeostatic insulin resistance (HOMA-Ir), fasting Insulin, estimated average glucose levels, and uric acid.

Conclusion: We concluded that successful management of hypertension and metabolic syndrome should include augmenting Beta-adrenergic receptor-mediated Nitric Oxide production along with change in dietary habits and change in lifestyle.

Keywords: Hypertension, Metabolic Syndrome

8

Abstract No. **75** p

Theme: **Peripheral arterial disease**

Country: **Macedonia**

Carotid artery disease in patients with coronary artery disease undergoing coronary artery bypass grafting

Fortomarska Milevska B¹, Tupare S¹, Zimbova M¹, Tegoska B¹, Doneska G¹, Aftovska Naumoska I¹, Kovacheska Bashurovska E¹, Zhaku R¹,

Institute for prevention, treatment and rehabilitation of cardiovascular diseases, Ohrid¹

Aim: To evaluate presence of carotid artery disease in patients with coronary artery disease undergoing coronary artery bypass grafting.

Materials: A total of 46 patients undergoing elective coronary artery bypass surgery were preoperatively evaluated for the presence of carotid stenoses by duplex scanning. We followed clinical variables: age, gender, arterial hypertension, tobacco smoking, dyslipidemia and diabetes mellitus with focus on diabetes mellitus. Patients were divided into two groups. The first group was with type 2 diabetes mellitus and the second group was without type 2 diabetes mellitus .

Methods: Atherosclerosis of carotid artery was analysed by duplex ultrasound scanning in the all enrolled patients. A commercially available machine (Vivid 7) with a 10-MHz linear array transducer was used.

Results: Statistics analysis reveal significant difference ($p < 0.05$) between two groups. Carotid artery disease were more frequent in the group with diabetes mellitus ($p = 0.02$).

Conclusion: prevalence of type 2 diabetes mellitus was statistically higher in individuals with coronary artery disease undergoing coronary artery bypass grafting.

Keywords: Carotid artery disease, coronary artery disease, coronary artery bypass grafting

9

Abstract No. **101**p

Theme: **Peripheral arterial disease**

Country: **Macedonia**

Radiofrequency ablation as first line treatment of varicose veins – short term clinical outcomes

Bakracheski N¹, Zimbova M¹, Donevska G¹, Tegovska B¹, Fortomarska-Milevska B¹, Taneska N¹, Zhaku R¹, Petroska K¹, Sheshoski B¹;

Institute for cardiovascular diseases, Ohrid¹;

Aim: Chronic venous insufficiency causes significant morbidity and work disability.

Endovascular radiofrequency ablation is a minimally invasive procedure for treatment of

varicose veins. Our aim was to evaluate the clinical efficacy and safety of this procedure in patients from our registry.

Materials and Methods : A prospective registry from the Institute for cardiovascular diseases - Ohrid enrolled 92 elective consecutive patients, between January 2013 and March 2014, submitted to endovenous radiofrequency ablation of the great saphenous vein (GSV) with Closurefast catheter. 56 of the patients (60%) were female, 36 (40%) were male. Out of them: 36 patients (78%) were in C2, 18 (19%) in C4, and 2 (2%) in C5 according to the Clinical ethiological anatomic and pathologic (CEAP) classification.

The ultrasound guided procedures involved – mapping and marking of the varicose veins, introduction of 7 Fr sheath, advancement of the RF catheter 2cm distal to the sapheno-femoral junction, tumescent anesthesia, final tip position verification, application of radiofrequency energy at 120°C with simultaneous vein compression over the heating element and application of compression bandages and elastic stockings after the procedure.

We assessed the clinical outcomes and performed follow up duplex ultrasound at 3 days, 10 days and 6 weeks after the procedure.

At 3 days 100% of the patients were able to return to their normal activities. Duplex-ultrasound assessment demonstrated: 88 (95%) of the patients with completely occluded GSV and no remaining reflux, 4 patients (4%) presented with aseptic phlebitis of side-branches of GSV, and 6 (6%) had residual paresthesia.

At 10 days after the procedure, 100% of the patients had completely occluded vessel and no remaining reflux, and 2 (2%) patients had residual paresthesia.

6 weeks after the procedure 100% of the patients had completely occluded GSV and there were no residual complications.

Conclusion: Endovenous radiofrequency ablation is a safe minimally invasive procedure with high success rate and low complication rate.

Keywords: varicose veins, completely closed vessel, endovenous radiofrequency ablation

10

Abstract No. **134** p

Theme: **Peripheral arterial disease**

Country: **Macedonia**

Surgical treatment for carotid disease

Mitrev Z, Anguseva T, Hristov N

Special Hospital for surgery Phillip II

Background: Carotid vascular disease is prevalent and results with significant mortality and morbidity when is untreated. The main treatments used include medical therapy, carotid endarterectomy (CAE), and carotid artery stenting (CAS). Results of trials comparing the invasive treatment options are ongoing and have shown somewhat conflicting results.

Methods: Between March 2004 and March 2014 2798 consecutive patients underwent carotid artery surgery. Indication for surgery was established after CT scan evaluation in all patients. We used multivariate logistic regression analysis to assess the effect of multimorbidity on post-operative in-hospital mortality and morbidity, while adjusting for treatment selection bias.

Results and discussion: Only 456 patients got only carotid surgery, other once had been combined with CABG, valvular, or peripheral vascular surgery. 1567 patients got carotid thrombectomy, 789

with bilateral carotid surgery. 1231 operated patients had carotid artery kinking with a transaction as an applicable surgery.

2100 patients had severe correctable CAD. In patients with cerebrovascular, peripheral and combination with coronary artery disease, bypass surgery was performed after resolving of primary vascular disease. The overall operative mortality for 2798 operated patients with carotid surgery was 3 (0,9%) 5 (0,17%) of operated patients had a stroke as a complication. Postoperative hospital stay was 1,2 days.

Conclusion: Carotid surgery is a safe technique for patients brain life. The incidence of postoperative stroke is substantially reduced with adequate patients evaluation and surgical plan. There is no need for longer anticoagulant therapy.

11

Abstract No. 139

Theme: **Peripheral arterial disease**

Country: **Macedonia**

Doctor Internal medicine

Savetka PJ¹, Magdalena O², Nela K³⁻¹,

Clinic of Cardiology, Skopje, Macedonia¹

Purpose:

Secondary hypertension especially renovascular hypertension (or renal, parenchymal) is a rare condition, women who are resistant to antihypertensive therapy and who gradually additionally reinforces a generalized atherosclerosis.

Methods and results: We present a clinical case of 53 years old female patient who has secondary hypertension and maximum values blood pressure TA 220/120 mmHg and generalized atherosclerosis. The first hospitalization in Clinic of Cardiology Skopje 1997, for renal angiography. In 2010 a second hospitalization in Clinic of Cardiology for chest pain due to propagation with both hands and ECG signs of subacute anterior myocardial infarction. Risk factors- myocardial infarction, arterial hypertension, dyslipidemia, smoking.

Investigations:

EKG: Sinus rhythm with HR ~100/min, axis normal, normal QRS form VI-V6.

Laboratory: SE 9, Hgb 127..135, Er 4.2..5.0; Hct 0.38..0.41, Le 6.2..9.7; Glucose 6.2; urea 4.6, kreatinin 63, Na 140, K 4.8

Doppler of the carotid arteries: 0.9 IMT, plaques of bulbous

Echocardiography: AO 30, LA 39, LVd 53, LVs 39, RV 30, EF 50%

Designated sizes of LV, segmental kinetics outages in the IVS mid-apical segment, apical segment of front wall

Doppler of lower limbs: obstructive signals-a.tibialis left and right and left a.poplitea

Ultrasonography the kidneys: right kidney lower than in the left. Doppler of the renal arteries with stenosis of the right renal artery

Scan the kidneys with Tc-99-mTc-DTPA: strong asymmetry of both kidneys and the extended Tmax in right kidney

Renal angiography: stenosis of the right renal artery 90% stenosis of the left renal artery 50%.

PTRA(POBA) to right renal artery.

Coronary angiography: pRCA plaque, mRCA 85%, pLAD 100%. PTCA balloon and stenting LAD

Keywords: Patient has a resistant hypertension, clear coronary myocardial disease with a history

of heart attacks, stenosis of both renal arteries, crisis hypertension. All these pathologies lead to progression of atherosclerosis. Women with refractory hypertension

12

Abstract No. **173** p

Theme: **Peripheral arterial disease**

Country: **Macedonia**

Pulmonary thrombembolism associated with Bronchopneumonia

Al-Baragoni S, Bosevski M

University Clinic of Cardiology - Skopje

The Purpose of paper is to determine the connection between patients who have Bronchopneumonia and Pulmonary Thrombembolism (PTE) as a complication of the above. A case of patient, who was diagnosed and treated for Pulmonary thrombembolism, condition post Bronchopneumonia was reported.

41 year old male patient with symptoms: shortness of breath, fatigue, cough, fever was admitted to the Clinic of Infectology, diagnosed and treated as Bronchopneumonia. But, although taking necessary precautions and treatment for the above condition, respiratory symptoms continued to progress. A pt who has most likely a high-risk (massive) PTE, even if he does not fulfil all formal criteria of haemodynamic instability. CT angiography was implemented and showed a massive thrombus in projection of the main branch of the right pulmonary artery and in the left lobar artery (findings in favor of bilateral pulmonary thrombembolism). Because of the findings, the pt was referred to the Cardiology Clinic, where he was hospitalized, and immediately treated towards PTE.

Pt was treated with Low molecular Heparin and continued with Rivoraxaban. Clinical symptoms and Lab findings were remarkably improved after the treatment with anticoagulants.

We can conclude that although case fatality rates appear to have dropped over the past two decades, acute PTE continues to pose a serious burden on health and survival. Clinical presentation and risk factors between the two conditions, overlap considerably and therefore leading to confusion. Early recognition and treatment, is fundamental component of management and may ultimately have a good prognosis of this condition.

Keywords: Pulmonary thrombembolism, Bronchopneumonia, treatment, prognosis

13

Abstract No. **174**

Theme: **Peripheral arterial disease**

Country: **Macedonia**

PROMOTION OF EXERCISE AND SPORT IN CARDIOVASCULAR DISEASE PROTECTION. MECHANISMS OF ACTION

Dejanova B.

Institute of Physiology, Medical Faculty, University "Ss Cyril and Methodius" - Skopje, R. Macedonia

It is well known that physical activity has athero-protective property and therefore prevents cardiovascular disease appearance, such as coronary heart disease, heart failure, peripheral artery disease, etc. Many studies have shown that it prevents plaque development, improves coronary

artery stenosis and has beneficial effect on other vascular lesions which may lead to fatal outcome. Regular exercise and daily sport activity promote athero-protection by preventing and/or decreasing both, oxidative stress (OS) and inflammation processes. Thus, OS is decreased by activation of laminar shear stress, down-regulation of endothelial angiotensin II type 1 receptor (AT1R) expression that decrease endothelial NADPH oxidase activity and superoxide anion production. This preserves the bioavailability of the vascular protective agent - nitric oxide (NO), and promotes other vasoactive substances production. Therefore, balanced exercise and sport may up-regulate antioxidant defense, increase repair mechanisms for oxidative damage, and improve resistance to OS. Regarding prevention of inflammation, skeletal muscle contraction, per se, releases anti-inflammatory cytokines such as IL-6 that inhibits tumor necrosis factor- α (TNF- α) and therefore shows athero-protective effect. Its anti-inflammatory effect may be also considered by reduced CRP plasma level. Another benefit of exercise is vascular remodeling which involves 2 forms of vessel growth: angiogenesis and arteriogenesis which may contribute for better tissue perfusion, especially in a case of artery occlusions. Due to many beneficial vasoactive agents released during physical activity, which are obviously involved in anti-oxidant and anti-inflammatory mechanisms of action, well regulated exercise and sport may have beneficial effects on endothelial tissue and therefore have protective role on cardiovascular system integrity.

Keywords: exercise and sport; oxidative stress; inflammation

14

Abstract No. 177

Theme: **Peripheral arterial disease**

Country: **Macedonia**

ENDOTHELIAL DYSFUNCTION IN PATIENTS WITH END STAGE RENAL FAILURE. THE INTERACTION BETWEEN COAGULATION AND INFLAMMATION

Dejanov P.

Clinic of Nephrology, Medical Faculty, University "Ss Cyril and Methodius" - Skopje, R. Macedonia

Coagulation and inflammation processes interaction are related to end stage renal disease (ESRD). Both, inflammation and coagulation may have common markers, such as activated protein C (aPC), protein S, von Willebrand factor (vWf), thrombin, etc. The marker aPC inactivates FVa and FVIIIa, enhances fibrinolysis (via inactivating PAI-1), suppresses inflammatory cytokine elevation in severe sepsis, inhibits leukocyte adhesion, decreases leukocyte chemotaxis and reduces endothelial cell apoptosis. The marker vWf stabilizes FVIII, and is its carrier, mediates among platelets, mediates the contact to sub-endothelium in endothelium injury. Increased vWf levels are observed in acute phase response in inflammatory conditions. The aim of the study was to investigate markers of endothelial dysfunction in ESRD patients concerning coagulation and inflammation processes. A number of 95 ESRD patients were submitted in the study 51% - ESRD (renal failure only), 20% - ESRD with deep venous thrombosis, 16% - ESRD with diabetes mellitus, 13% - ESRD with coronary heart disease. A number of 50 subjects were taken as a control group. Methods that we performed within the study: platelet aggregation was measured on dual channel aggregometer model 440; ATIII reagent assay by Randox 30; for A-1 AT and A-2 MG Elisa kit was used by Behring; protein C

and protein S by Coamatic kit (Chromogenix), coagulation factors II, V, VIII and XII, complement / immune complexes were measured by Behring. All the parameters were examined before and after stasis. The results show significantly increased levels of vWf antigen and antibodies ($p < 0.05$), ATIII ($p < 0.01$), A-1 AT ($p < 0.01$), protein S ($p < 0.01$). Significantly increased activities were found for all coagulation factors. For complement / immune complexes statistical significance was found for C-1 ($p < 0.02$), C-3 ($p < 0.001$), CIK ($p < 0.001$). Platelet aggregation showed 3 times higher value ($p < 0.001$).

Due to obtained results, it can be considered that endothelial may be impaired by compromised processes of coagulation and inflammation which are inter-related, promoting further disease complications in these patients.

Keywords: coagulation; inflammation; endothelial dysfunction

15.

Abstract No. 190

Theme: Other topics

Country: Macedonia

ACUTE INFECTIOUS PERICARDITE AT MALE AT AGE 5 – case report

Breslieva J., Spritova E., Jordanova S.

Introduction: Pericarditis is a medical term for inflammation of heart tunica which intumescens, and sometimes there is flow between the tunica's two layers. It is rare disease, especially in early age, although rarely occurs as primary disease, it very often occurs as result of other disease or complication of primary disease. In child's age those are diseases caused by infectious agents, for Example Mycoplasma Pneumoniae.

Methods: EKG, Rtg pulmo, 2D echocardiography, Pneumoslide

Objective: Male child at age 5 last two weeks has increased temperature, four days breaths hard and the last two days sleeps in sitting position. Until present he has been relatively healthy child. Objectively he is in difficult condition, febrile, pale, tachypnea using additional breathing muscles, tachycardic, lung auscultation weak, almost silent breathing in lower and middle parts on the right and lower parts on the left, heart action is rhythmical - tachycardic (puls: 130/min), systolic hum 2/6 degree precordial. Abdomen is soft on palpation, hepar palp 3 cm under right rib.

Laboratory blood analyses: blood count: Hb:91g/l, Er: $3,84 \times 10^{12}/L$, Le: $16,3 \times 10^9/L$, Tr: $561 \times 10^9/L$, urine:b.o, hepatogram: AST: 62U/L, ALT: 61U/L, tot bil: 5,3 umol/l, Glicemia: 7,2 mmol/l, Urea: 2,82 umol/l, Creatinine: 41,9 umol/l, CRP: weekly positive, CPK:13U/L

Rtg pilmo: Bilateral paracardic basal there are radiological signs of inflammatory changes in pulmonary parenchyma. Vascular hilums, increased heart shadow.

Heart echo: Pericardic flow in the diastole 2,5 cm big, on the level of the papillary muscles in short parasternal axis there is pleural fluid, too.

The child has spent few hours at the Pediatric ward at the Clinical hospital in Shtip and was sent at the Clinical hospital, ward for intensive care in Skopje. After several days at the cardiological ward many examinations have been conducted, Pneumoslide finding was Mycoplasma Pneumoniae, suitable antibiotic therapy ordinated for the above mentioned cause and after short period there was total regrestion of pericardial flow and the child was dismissed on domestic treatment in good health condition.

Conclusion: Acute pericarditis is difficult, in some moments life threatening condition which can result in total healing if it is detected on time and the etiological agent is properly treated.

16.

Abstract No. 191

Theme: Other topics

Country: Macedonia

SECONDARY PULMONARY FIBROSIS DUE TO ATRIAL SEPTAL DEFECT

Jovanovska I., Kedev S., Stojkovic J

We present a case of 48 year old woman with a deterioration of the general state since 2007, when she was treated for asthma but with an incomplete response to the given therapy. Because of a persistent murmur (a whooshing sound) over the tricuspid valve area (LLSA) in 2009 she was sent to the University Clinic of Cardiology where after the echocardiography examination was diagnosed with sinus venosus atrial septal defect in which the defect involved the venous inflow of vena cava inferior. Afterwards with a surgical recommendation from a cardiologist, surgical corrections were made in November 2009 but with an unfavorable outcome in the life quality expectations. Since then with frequent hospitalizations in the University Clinic for Pulmonary Diseases and concomitantly in the University Clinic for

Cardiology for decompensation of the general state presented with (repeated dyspnea, fatigue, non-productive cough and leg swelling) and diagnosed pulmonary vascular remodeling do to the severity of the congenital heart malformation. Presently the spirometry results indicate a severe degree of a pulmonary ventilation insufficiency with a light predominance of the restrictive compound and with the gas analyses attributable to manifest global chronic respiratory insufficiency and the blood analyses indicative to polycythemia.


In summary, untimely surgical correction of a congenital heart malformation as the atrial septal defect can lead to secondary pulmonary fibrosis, which is a result of right heart cavity remodeling as the key point in development of secondary pulmonary artery hypertension and in our case a chronic respiratory failure.

Trust in your ideas and you'll feel free
Create and be proud of your deeds
Treasure your love and you'll be loved
Cherish the spirit and be strong

We in Alkaloid, trust in our creations,
treasure and cherish the force that sets
life in motion and builds perfect
harmony called HEALTH.



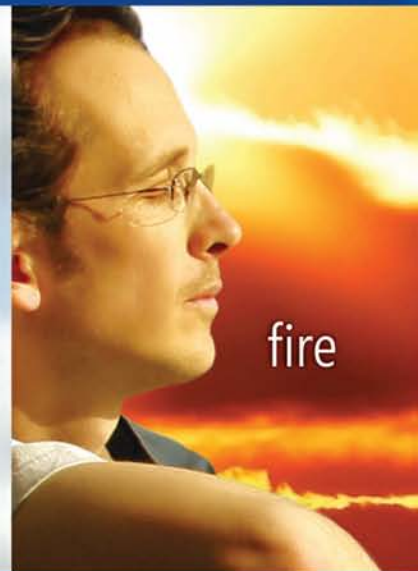earth



water



air



fire

Health above all



ALKALOID
SKOPJE

www.alkaloid.com.mk