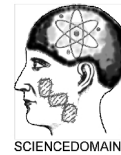

**Cardiology and Angiology: An International Journal**  
2(4): 238-246, 2014, Article no.CA.2014.4.009

SCIECEDOMAIN *international*  
[www.sciencedomain.org](http://www.sciencedomain.org)



## Relationship of Mitral Annular Plane Systolic Excursion (MAPSE) to Left Ventricular Thrombus Formation

Aurora Bakalli<sup>1\*</sup>, Ljubica Georgievska-Ismail<sup>2</sup>, Bedri Zahiti<sup>1</sup>,  
Dardan Kočinaj<sup>1</sup>, Agreta Gecaj-Gashi<sup>3</sup> and Ardiana Murtezani<sup>4</sup>

<sup>1</sup>*Clinic of Cardiology and Angiology, University Clinical Center of Kosova and Medical Faculty, University of Prishtina, Prishtina, Kosovo.*

<sup>2</sup>*University Clinic of Cardiology, Medical School, University of St. Cyril and Methodius, Skopje, Macedonia.*

<sup>3</sup>*Clinic of Anesthesiology and Intensive Care, University Clinical Center of Kosova and Medical Faculty, University of Prishtina, Prishtina, Kosovo.*

<sup>4</sup>*Clinic of Physical and Rehabilitation medicine, University Clinical Center of Kosova and Medical Faculty, University of Prishtina, Prishtina, Kosovo.*

### **Authors' contributions**

*This work was carried out in collaboration between all authors. Author AB designed the study, carried out majority of medical procedures and wrote the first draft of the manuscript.*

*Author LGI wrote the protocol. Authors DK and BZ collected patients for the study and assisted or performed medical procedures. Authors AGG and AM managed the literature searches. All authors read and approved the final manuscript.*

**Original Research Article**

**Received 6<sup>th</sup> April 2014**  
**Accepted 23<sup>rd</sup> May 2014**  
**Published 19<sup>th</sup> June 2014**

### **ABSTRACT**

**Background:** Dilated cardiomyopathy is associated by radial and longitudinal contractile cardiac dysfunction. Left ventricular (LV) thrombus is a frequent finding in patients with dilated cardiomyopathy. The main purpose of our study was to evaluate the role of mitral annular plane systolic excursion (MAPSE) in LV thrombus formation in patients with dilated cardiomyopathy by assessing their correlation. Our additional objective was to compare the relationship of average MAPSE to relations of other LV features [LV size, LV ejection fraction (EF), wall motion score index (WMSI), sphericity index-width to length ratio (w/l) of the LV] and LV thrombus development.

\*Corresponding author: E-mail: [abakalli@hotmail.com](mailto:abakalli@hotmail.com);

**Material and Methods:** This was a prospective cross-sectional study conducted from October 2009 until January 2012 in 100 sinus rhythm patients with dilated cardiomyopathy without anticoagulation therapy. We excluded patients with: swallowing problems, acute myocardial infarction, atrial fibrillation/flutter, severe systolic dysfunction, severe arterial hypertension, valvular disease, and/or mechanical valves.

**Results:** Mean patient age was  $58.1 \pm 12.7$  years and 69% were men. Mean LV EF was  $39.1 \pm 6.4\%$ , while mean value of average MAPSE was  $9.3 \pm 2.2$ mm. LV thrombus was detected in 14% of patients and its presence correlated well with: average MAPSE ( $r = -0.22$ ,  $p = 0.01$ ), MAPSE of septal wall ( $r = -0.23$ ,  $p = 0.01$ ), MAPSE of lateral wall ( $r = -0.2$ ,  $p = 0.02$ ), MAPSE of inferior wall ( $r = -0.22$ ,  $p = 0.01$ ), LV EF ( $r = -0.21$ ,  $p = 0.02$ ), LV end diastolic diameter ( $r = 0.24$ ,  $p = 0.008$ ), LV end systolic diameter ( $r = 0.31$ ,  $p = 0.0008$ ), WMSI ( $r = 0.22$ ,  $p = 0.01$ ) and w/l ( $r = 0.19$ ,  $p = 0.03$ ).

**Conclusions:** Longitudinal LV dysfunction is associated with LV thrombus formation, as average MAPSE demonstrates a negative correlation with LV thrombus, and its role is similar to LV size, LV EF, sphericity index and WMSI.

*Keywords: Left ventricular thrombus; dilated cardiomyopathy; MAPSE.*

## ABBREVIATIONS

*ECG- Electrocardiography; EF- Ejection fraction; LV- Left ventricle/ventricular; LVEDD- Left ventricular end-diastolic diameter; LVESD- Left ventricular end-systolic diameter; TEE- Transesophageal echocardiography; TTE- Transthoracic echocardiography; WMSI- Wall motion score index; w/l - Width to length ratio of left ventricle.*

## 1. INTRODUCTION

Dilated cardiomyopathy is characterized by enlargement of one or both ventricles associated with systolic and diastolic contractile impairment [1], or according to newer definitions dilated cardiomyopathy refers to a large group of heterogeneous myocardial disorders that are characterized by ventricular dilation and depressed myocardial contractility in the absence of abnormal loading conditions such as hypertension or valvular disease [2]. In addition to radial contractile cardiac dysfunction, impairment of longitudinal myocardial function has been reported in the setting of dilated cardiomyopathy [3]. Thromboembolic events are a frequent cause of mortality in patients with congestive heart failure, accounting for about 30% of such patients [4].

The aim of our study was to evaluate the relationship of mitral annular plane systolic excursion (MAPSE), as marker of longitudinal left ventricular (LV) function, to LV thrombus formation in sinus rhythm patients with dilated cardiomyopathy of mild to moderate systolic dysfunction. Our additional objective was to compare the relationship of average MAPSE to relations of other LV features (LV size, LV ejection fraction, wall motion score index, sphericity index) and LV thrombus development.

## 2. PATIENTS AND METHODS

This was a prospective cross-sectional study conducted in University Clinical Center of Kosova from October 2009 until January 2012. The study included 100 patients with dilated cardiomyopathy in sinus rhythm, who were not under oral anticoagulation therapy. Exclusion

criteria included patients with: swallowing problems, acute myocardial infarction, atrial fibrillation/flutter, severe systolic dysfunction, severe arterial hypertension, valvular disease, mechanical valves and/or patients who were taking oral anticoagulation therapy.

The study was approved by our Ethical Board and written informed consent was taken from every patient that entered the study.

Demographic and history data, physical examination, laboratory tests, ECG, chest X-ray, transthoracic echocardiography (TTE) were obtained for every patient that entered the study. Transesophageal echocardiography (TEE) was performed only in those patients with high suggestion of cardiac thrombus in order to obtain better visualization and to confirm the diagnosis. To our best awareness patients that were included in the study did not have prior episodes of atrial fibrillation.

## 2.1 Echocardiography

TTE (Phillips iE 33) examinations and measurements were performed according to the recommendations of the American Society of Echocardiography [5]. Left ventricular end diastolic diameter (LVEDD), left ventricular end systolic diameter (LVESD), septal wall and posterior wall thickness were measured from parasternal M-mode recordings according to standard criteria. LV ejection fraction (EF %) was determined from apical views with modified Simpson's rule. LV EF less than 50% was considered as systolic dysfunction, whereas LV EF under 30% was considered as severe LV dysfunction.

TEE (Phillips iE 33, Agilent Image-Point Hewlett Packard or Toshiba NEMIO XG SSA-580A) was performed in all patients in whom cardiac thrombi was suspected by TTE. Due to the semi-invasive nature of TEE and the unease that causes to the patient, we performed this procedure only in patients in whom thrombus was suspected by TTE.

Thrombus, as observed by TTE and/or TEE, was defined as presence of distinct echogenic intracavity mass, identifiable in at least two different views.

Mitral annular plane systolic excursion (MAPSE), as an indicator of longitudinal LV EF, was measured in millimeters (mm) by M-mode echocardiography from four different points (septal, lateral, inferior and anterior) at four chamber and two chamber apical views. The average MAPSE was derived from the values of the four afore mentioned values and values less than 10mm were considered abnormal [5].

Wall motion score index (WMSI) was calculated according to the 17 segment model [5]. Sum of all scores, corresponding to each segment motion, were divided by the number of total segments.

LV sphericity index during end diastole was defined as ratio of LV length (measured from apex to the middle of mitral annular plane) to LV width (measured at midpoint of LV length) in four chamber projection. Width to length ratio (w/l) >0.76 was considered severe [6].

## 2.2 Statistical Analysis

All data were expressed as mean  $\pm$  standard deviation (SD) and percentages. Correlation of selected variables was estimated using Pearson correlation test. Simple regression analysis

was performed to determine if LV thrombus was associated with longitudinal LV function impairment, as well as other LV features. Variables with a value of  $p < 0.05$  in simple regression were considered significant. All statistical analysis were performed using statistical software SPS, version 2.80, 2005.

### 3. RESULTS

Mean patient age was  $58.1 \pm 12.7$  years and 69% were men. Ischemic origin of dilated cardiomyopathy was found in 57% of patients and only one fourth of the patients were not taking aspirin prior to the study. Among patients with ischemic dilated cardiomyopathy, 9 patients experienced prior myocardial infarction. Baseline patient data are presented in (Table 1).

**Table 1. Baseline patient characteristics\***

	<b>n=100</b>
Age, yr	58.1±12.7
Female (%)	31/100(31)
Current smokers (%)	29/100(29)
Alcohol users (%)	10/100(10)
Mild to moderate hypertension (%)	52/100(52)
Diabetes Mellitus (%)	30/100(30)
Dyslipidemia (%)	25/100(25)
BMI, kg/m <sup>2</sup>	28.4 ±4
Coronary artery disease (%)	57/100(57)
Aspirin therapy usage (%)	75/100(75)
Peripheral vascular disease (%)	5/100(5)

*\*Data are presented as mean±SD or No. (%)*

Haemostasis tests were within normal range in all patients included in the study, with mean prothrombin time (PT) being  $101.4 \pm 12.4\%$ , mean partial thromboplastin time (PTT) was  $24.5 \pm 4.2''$  and mean thrombin time (TT) was  $11.2 \pm 0.9'$ . Average platelet count in our study population was  $219.4 \pm 57.2 \times 10^9$ .

Mean LVEDD of our population was  $66.5 \pm 6\text{mm}$  and mean LV EF was  $39.1 \pm 6.4\%$ . Seven of our patients had normal LV EF, 37 had mild reduction of LV EF and 56 had moderate reduction of LV EF. Basic TTE parameters are shown in (Table 2). Average MAPSE less than 10mm was found in 69 (69%) patients. The mean value of average MAPSE was  $9.3 \pm 2.2\text{mm}$ , whereas the mean for MAPSE of septal wall, lateral wall, inferior wall and anterior wall were:  $8.9 \pm 2.6\text{mm}$ ,  $9.6 \pm 2.7\text{mm}$ ,  $9.4 \pm 2.5\text{mm}$  and  $9.3 \pm 2.5$ , respectively. Mean WMSI in our population was  $1.6 \pm 0.4$ , while mean w/l ratio was  $0.8 \pm 0.1$ . Severe LV sphericity index was encountered in 66% of our patients.

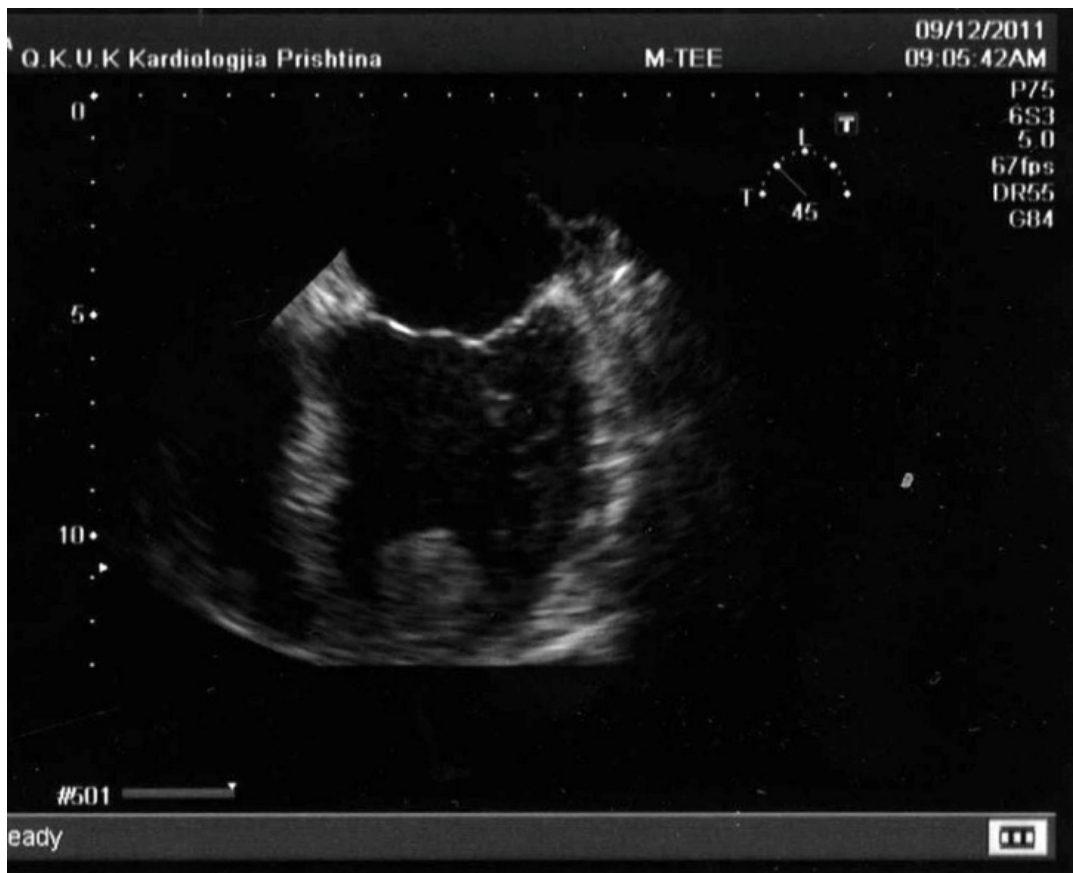LV thrombus was detected in 14 (14%) patients, with 13 thrombi being flat/mural and one protruding, with ball-like shape thrombus (Fig. 1). All thrombi were located in LV apical area. TEE confirmed the presence of LV thrombus in all these patients. Of the 57 patients with coronary artery disease, 11 (19.3%) had LV thrombus. Furthermore, 4 (16%) patients that were not taking aspirin developed LV thrombus.

In simple regression analysis LV thrombus had significant inverse correlation with average MAPSE ( $r=-0.22$ ,  $p=0.01$ ; Fig. 2), MAPSE of septal wall ( $r=-0.23$ ,  $p=0.01$ ), MAPSE of lateral wall ( $r=-0.2$ ,  $p=0.02$ ), MAPSE of inferior wall ( $r=-0.22$ ,  $p=0.01$ ). MAPSE of anterior wall was the only MAPSE site that did not correlate to LV thrombus ( $r=-0.08$ ,  $p=0.2$ ) in our study population.

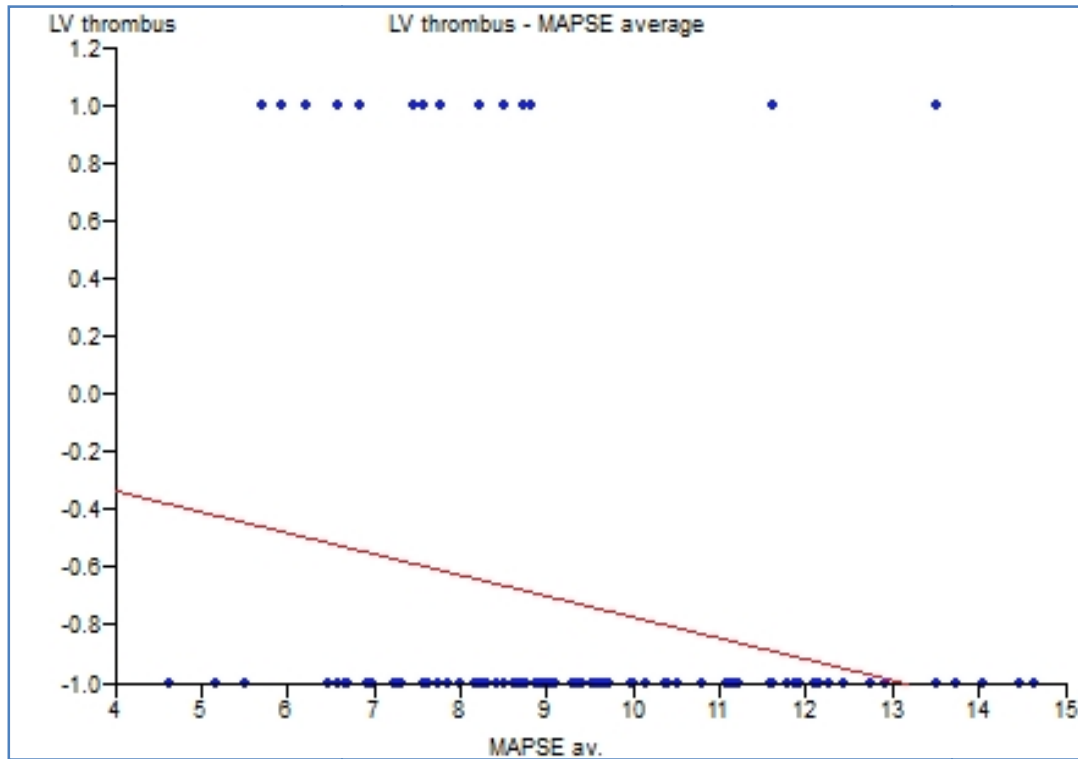
**Table 2. Basic echocardiographic data of the study population\***

	<b>n=100</b>
IVSd, mm	9.9±2
PWd, mm	9.7±1.4
LVEDD, mm	66.5±6
LVESD, mm	53.5±7.4
LVEF, %	39.1±6.4
LA, mm	45.9±4.9
MR area, cm <sup>2</sup>	4.2±3.1

\*Data are presented as mean ± SD. IVSd: diastolic interventricular septum; PWd: diastolic posterior wall; LVEDD: left ventricular end diastolic diameter; LVESD: left ventricular end systolic diameter; LV: left ventricular; EF: ejection fraction; LA: left atrium; MR: mitral regurgitation



**Fig. 1. Transesophageal echocardiography image showing a 6.8cm<sup>2</sup> protruding and ball-like thrombus in LV apex**



**Fig. 2. Diagram presenting correlation of LV thrombus to average MAPSE in our patient population**

Furthermore, LV thrombus also correlated significantly with LV EF ( $r=-0.21$ ,  $p=0.02$ ), LVEDD ( $r=0.24$ ,  $p=0.008$ ), LVESD ( $r=0.31$ ,  $p=0.0008$ ), WMSI ( $r=0.22$ ,  $p=0.01$ ) and w/l ( $r=0.19$ ,  $p=0.03$ ). Correlation of LV thrombus to MAPSE was similar to correlation of LV thrombus to other LV features.

#### 4. DISCUSSION

Our assumption that MAPSE would correlate to presence of LV thrombus proved to be right in sinus rhythm patients with dilated cardiomyopathy of mild to moderate systolic dysfunction. We believe to be the first authors that correlate LV thrombus to longitudinal LV function. We excluded from our study patients with severe LV systolic dysfunction, atrial fibrillation, acute myocardial infarction, mechanical valves, since these features are known to be linked to thrombus formation.

Cardiac disorders can impair longitudinal and radial contraction, although it has been suggested that in certain heart diseases, such as myocardial ischemia and hypertrophy, longitudinal myocardial function is impaired earlier [7]. Base-to-apex displacement of mitral annular ring represents shortening of the left ventricle along its long axis. Simonson and Schiller and Pai et al. reported a strong correlation between systolic annular displacement and LV EF [8,9]. Reduced mitral annular displacement is also observed in patients with coronary artery disease, with more evident reduction in the mitral annular site related to the myocardial infarction zone [10,11].

Dilated cardiomyopathy is a cardiac disorder that is prone to LV thrombus formation. Roberts et al. in their autopsy study, conducted on deceased patients with dilated cardiomyopathy, found that LV thrombus was present in 45% of patients [12]. Gottdiener et al. were able to identify by echocardiography the presence of LV thrombus in 36% of patients with dilated cardiomyopathy [13]. We also found frequently LV thrombus in patients with dilated heart [14-16]. LV thrombus develops in approximately 30% of patients with anterior myocardial infarction and is associated with elevated risk of systemic thromboembolic events [17]. LV aneurysm presents another favorable factor for thrombus formation. The frequency of LV thrombi in aneurysms found *post mortem* range from 14-68%, whereas findings of thrombi from aneurysmectomy vary from 50-95% [18].

Echocardiography has 90% specificity and 75-90% sensitivity for detection of left ventricular thrombus [19,20].

A limitation of this study is that Doppler Tissue Imaging, as a more advanced echocardiographic technique, could not be performed for assessment of long axis ventricular shortening and lengthening.

## 5. CONCLUSION

In conclusion, longitudinal LV dysfunction is associated with LV thrombus formation, as average MAPSE correlates well with LV thrombus. MAPSE is a similar indicator for LV thrombus as are LV size, LV EF, sphericity index, WMSI.

## CONSENT

All authors declare that written informed consent was obtained from all patients included in the study.

## ETHICAL APPROVAL

All authors hereby declare that this study has been approved by our institution's ethics committee and has therefore been performed in accordance with the ethical standards.

## COMPETING INTERESTS

Authors have declared that no competing interests exist.

## REFERENCES

1. WHO/ISFC: Report of the WHO/ISFC task force on the definition and classification of cardiomyopathies. *Br Heart J.* 1980;44:672-3.
2. Yancy CW, Jessup M, Bozkurt B, Butler J, Casey DE Jr, Drazner MH, Fonarow GC, Geraci SA, Horwich T, Januzzi JL, Johnson MR, Kasper EK, Levy WC, Masoudi FA, McBride PE, McMurray JJ, Mitchell JE, Peterson PN, Riegel B, Sam F, Stevenson LW, Tang WH, Tsai EJ, Wilkoff BL. American College of Cardiology Foundation; American Heart Association Task Force on Practice Guidelines. 2013 ACCF/AHA guideline for the management of heart failure: A report of the American College of Cardiology Foundation/American Heart Association Task Force on Practice Guidelines. *J Am Coll Cardiol.* 2013;62(16):e147-239.

3. Nikitin NP, Witte KK, Thackray SD, de Silva R, Clark AL, Cleland JG. Longitudinal ventricular function: Normal values of atrioventricular annular and myocardial velocities measured with quantitative two-dimensional color Doppler tissue imaging. *J Am Soc Echocardiogr.* 2003;16:906-921.
4. Griffith GC, Stragnell R, Levinson DC, et al. Study of beneficial effects of anticoagulation therapy in congestive heart failure. *Ann Intern Med.* 1952;37:867-87.
5. Lang MR, Bierig M, Devereux RB, Flachskampf FA, Foster E, Pellikka PA, Picard MH, Roman MJ, Seward J, Shanewise JS, Solomon SD, Spencer KT, Sutton MS, Stewart WJ. Chamber quantification writing group; American Society of Echocardiography's Guidelines and Standards Committee; European Association of Echocardiography. Recommendations for Chamber Quantification: A report from the American Society of Echocardiography's Guidelines and Standards Committee and the Chamber Quantification Writing Group, Developed in Conjunction with the European Association of Echocardiography, a Branch of the European Society of Cardiology. *J Am Soc Echocardiogr.* 2005;18(12):1440-1463.
6. Galderisi M, Mondillo S. *Chronic Heart Failure: Echocardiographic Evaluation.* 1<sup>st</sup> ed. One Way S.r.l. 2006.
7. Bolognesi R, Tsialtas D, Barilli AL, et al. Detection of early abnormalities of left ventricular function by hemodynamic, echo-tissue Doppler imaging, and mitral Doppler flow techniques in patients with coronary artery disease and normal ejection fraction. *J Am Soc Echocardiogr.* 2001;14:764-772.
8. Simonson J, Schiller NB. Descent of the base of the left ventricle: An echocardiographic index of left ventricular function. *J Am Soc Echo.* 1989;2:25-35.
9. Pai RG, Bodenheimer MM, Pai SM, et al. Usefulness of systolic excursion of the mitral annulus as an index of left ventricular systolic function. *Am J Cardiol.* 1991;67:222-224.
10. Alam M, Høglund C, Thorstrand C, et al. Haemodynamic significance of the atrioventricular plane displacement in patients with coronary artery disease. *Eur Heart J.* 1992;13:194-200.
11. Høglund C, Alam M, Thorstrand C. Effects of acute myocardial infarction on the displacement of the atrioventricular plane: an echocardiographic study. *J Int Med.* 1989;226:251-256.
12. Roberts WC, Ferrans VJ. Pathologic aspects of certain cardiomyopathies. *Circ Res.* 1974; 34:128-44.
13. Gottdiener JS, Gay JA, Van Voorhees L, DiBianco R, Fletcher RD. Frequency and embolic potential of left ventricular thrombus in dilated cardiomyopathy: Assessment by two-dimensional echocardiography. *Am J Cardiol.* 1983;52:1281-5.
14. Bakalli A, Kamberi L, Pllana E, Zahiti B, Dragusha G, Brovina A. The influence of left ventricular diameter on left atrial appendage size and thrombus formation in patients with dilated cardiomyopathy. *Turk Kardiyol Dern Ars.* 2010;38(2):90-94.
15. Bakalli A, Georgievska-Ismail L, Kocinaj D, Musliu N, Krasniqi A, Pllana E. Prevalence of left chamber cardiac thrombi in patients with dilated left ventricle at sinus rhythm: the role of transesophageal echocardiography. *J Clin Ultrasound.* 2013;41(1):38-45.
16. Bakalli A, Georgievska-Ismail L, Koçinaj D, Musliu N, Zahiti B, Krasniqi A, Bekteshi T, Sejdiu B. Left ventricular and left atrial thrombi in sinus rhythm patients with dilated ischemic cardiomyopathy. *Med Arh.* 2012;66(3):155-158.
17. Kontny F, Dale J, Hegrehaes L, et al. Left ventricular thrombosis and arterial embolism after thrombolysis in acute anterior myocardial infarction: Predictors and effects of adjunctive antithrombotic therapy. *Eur Heart J.* 1993;14:1489-92.
18. Nixon JV. Left ventricular mural thrombus. *Arch Intern Med.* 1983;143:1567-71.



19. Israel DH, Fuster V, IP JH, et al. Intracardiac thrombosis and systemic embolization. In: Colman RW, Hirsh J, Marder V, Salzman EW, eds. Hemostasis and Thrombosis: Basic Principles and Clinical Practice, 3<sup>rd</sup> ed. Philadelphia, Pa: JB Lippincott. 1994;1452-68.
20. Stratton JR, Lighty GW, Pearlman AS, Ritchie JL. Detection of left ventricular thrombus by two-dimensional echocardiography: Sensitivity, specificity, and causes of uncertainty. Circulation. 1982;66(1):156-66.

---

© 2014 Bakalli et al.; This is an Open Access article distributed under the terms of the Creative Commons Attribution License (<http://creativecommons.org/licenses/by/3.0>), which permits unrestricted use, distribution, and reproduction in any medium, provided the original work is properly cited.

*Peer-review history:*

*The peer review history for this paper can be accessed here:*  
<http://www.sciencedomain.org/review-history.php?iid=545&id=26&aid=4992>