

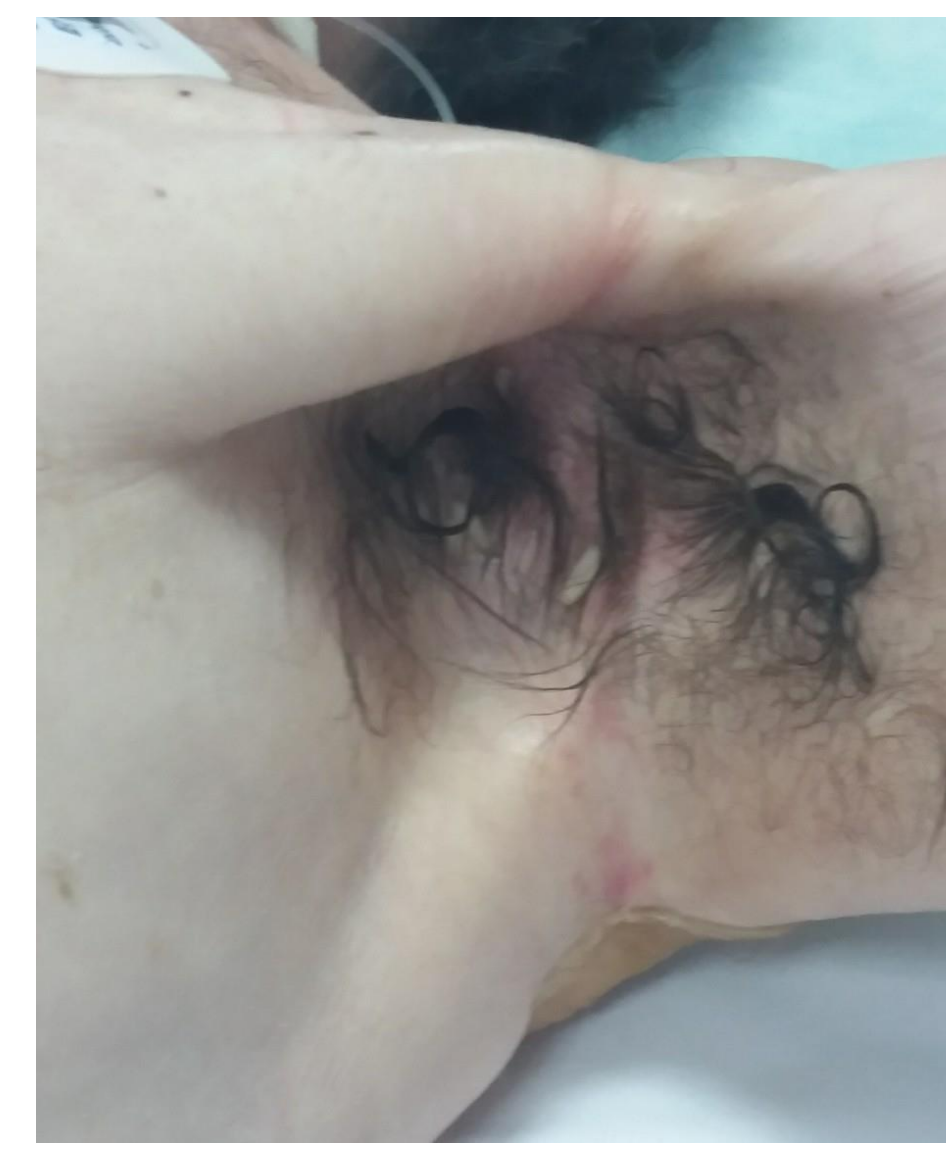
Cutaneous Myiasis: report of nosocomial case

Jurhar Pavlova Maja¹, Milena Petrovska¹, Gordana Mircevska¹, Liljana Labachevska Gjatovska¹, Valentina Slavevska-Stamenkovic² Maja Vasileva Duganovska³, Aleksandar Cvetkovikj⁴

¹Faculty of Medicine, Institute for Microbiology and Parasitology, ²Faculty of Natural Sciences and Mathematics, ⁴ Department of parasitology and parasitic diseases. Veterinary Institute, Faculty of Veterinary Medicine. Ss. Cyril and Methodius University in Skopje, Republic of North Macedonia; ³City General Hospital 8mi Septemvri –Skopje, Republic of North Macedonia

Introduction

Myiasis is an infestation of tissues, organs and body cavities of live vertebrates (humans and/or animals) with larvae of a variety of fly species within the arthropod order Diptera. Dipterous larvae can feed on the host's living or dead tissue, liquid body substance, or ingested food. The distribution of human myiasis is worldwide, however, reports for hospital-acquired myiasis are rare.



Nosocomial myiasis, first reported in 1980 (1), is a term used when the infestation affects subjects in hospital settings. Comatose patients are particularly prone to myiasis.

Here we report a case of nosocomial myiasis, in 44-year old terminally-ill patient. The patient had infratentorial brain neoplasm and underwent surgery intervention. He was unconscious and on mechanical ventilation for four months (March- June). Although isolated in a separate part of the hospital ward, six larvae were found in his left axilla.

Material and methods

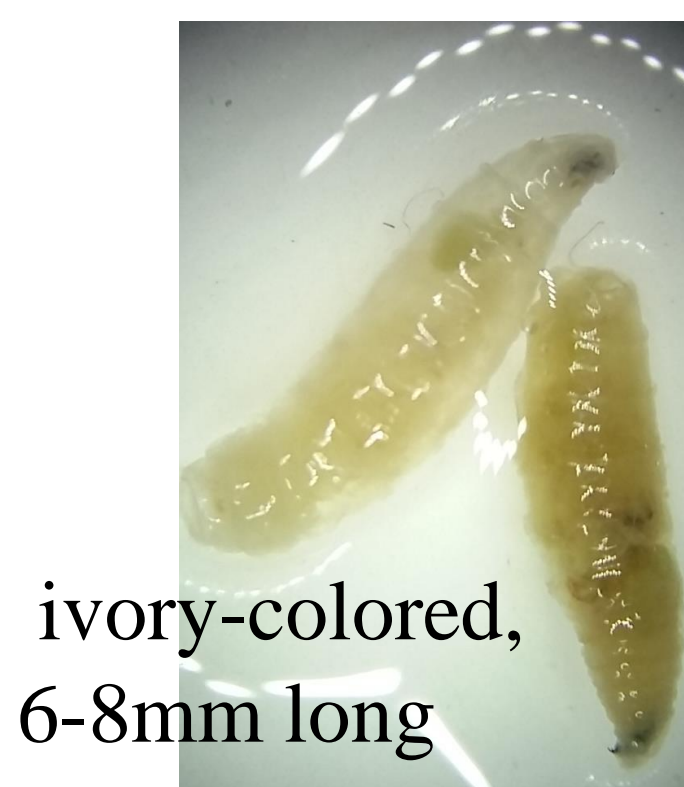Larvae were removed and sent for identification at Institute for Microbiology and Parasitology. Unfortunately, none of the specimens arrived alive.

Final identification was performed by the forensic entomologist in Laboratory for Invertebrates and Animal Ecology, at the Faculty of Natural Sciences and Mathematics, Skopje:

To facilitate the identification of the flesh fly larvae and to visualize the morphological details of the cephalopharyngeal skeleton and the integument, the **clearing technique** proposed by Niederegger *et al.*^[2] was applied.

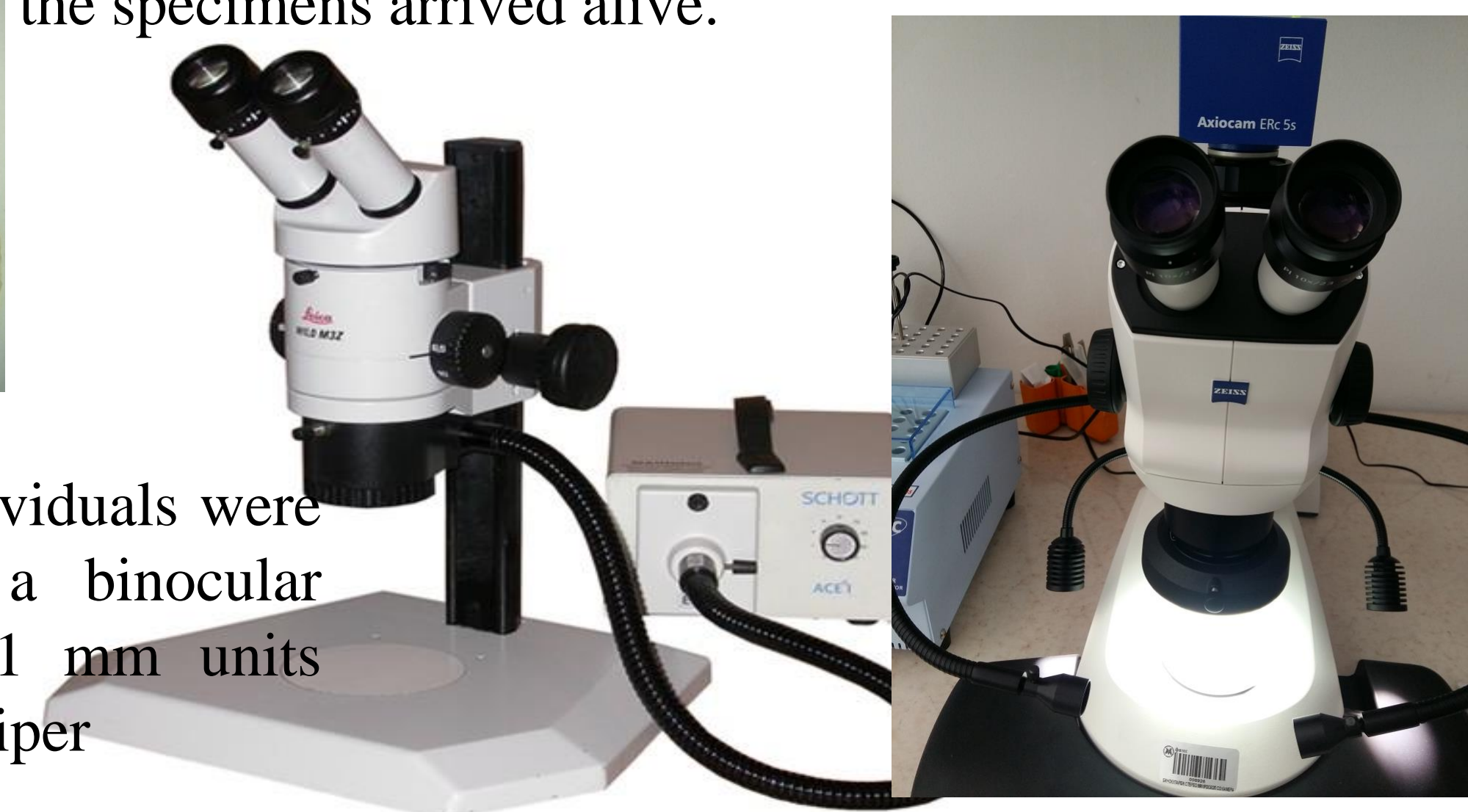
Morphological identification of the immature flesh fly larvae specimens was done using the **identification keys** provided by de Szpila *et al.*^[3]

Photographs were taken using Zeiss Stemi 508 stereomicroscope, Olympus SZX9 and LEICA WILD M3C Stereomicroscope with an integrated high-resolution digital camera .



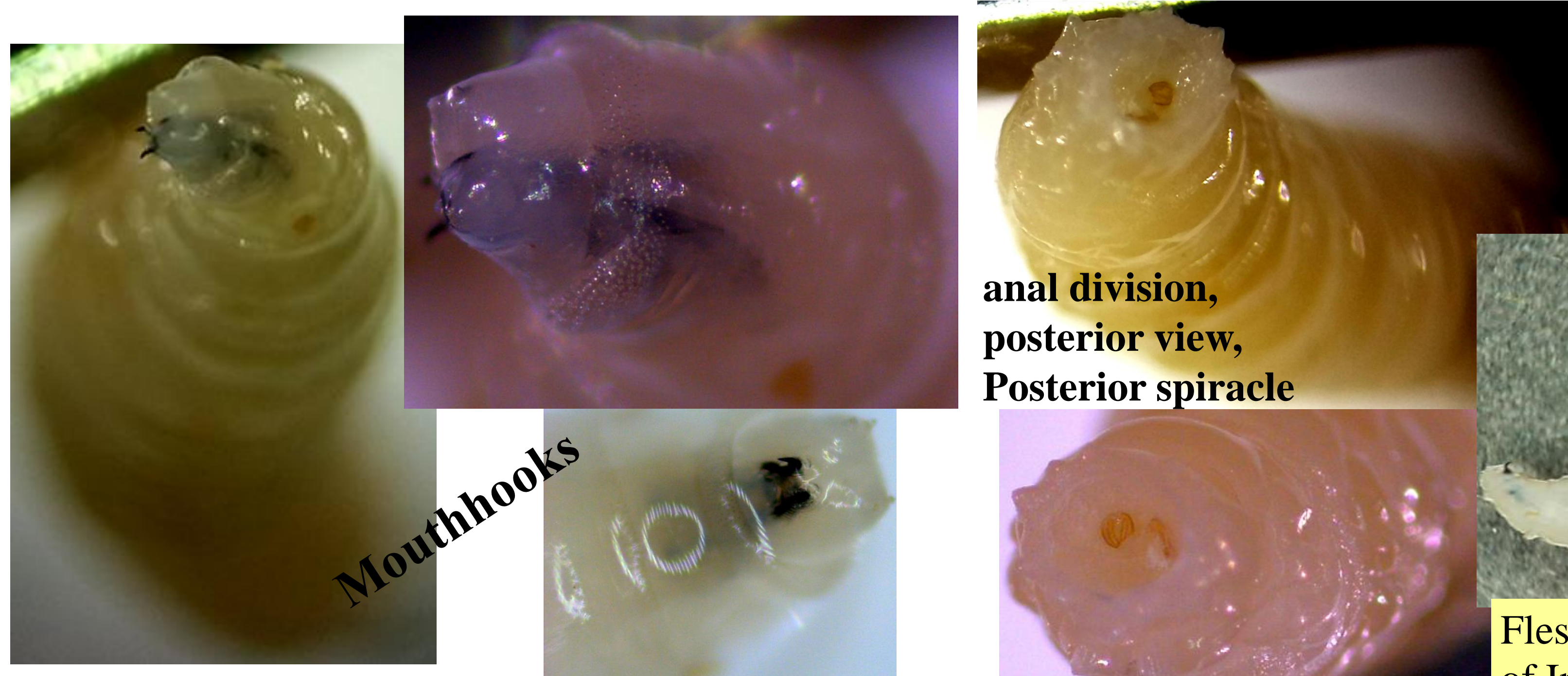
ivory-colored, 6-8mm long

The length of individuals were measured under a binocular microscope in 0.1 mm units using a vernier caliper



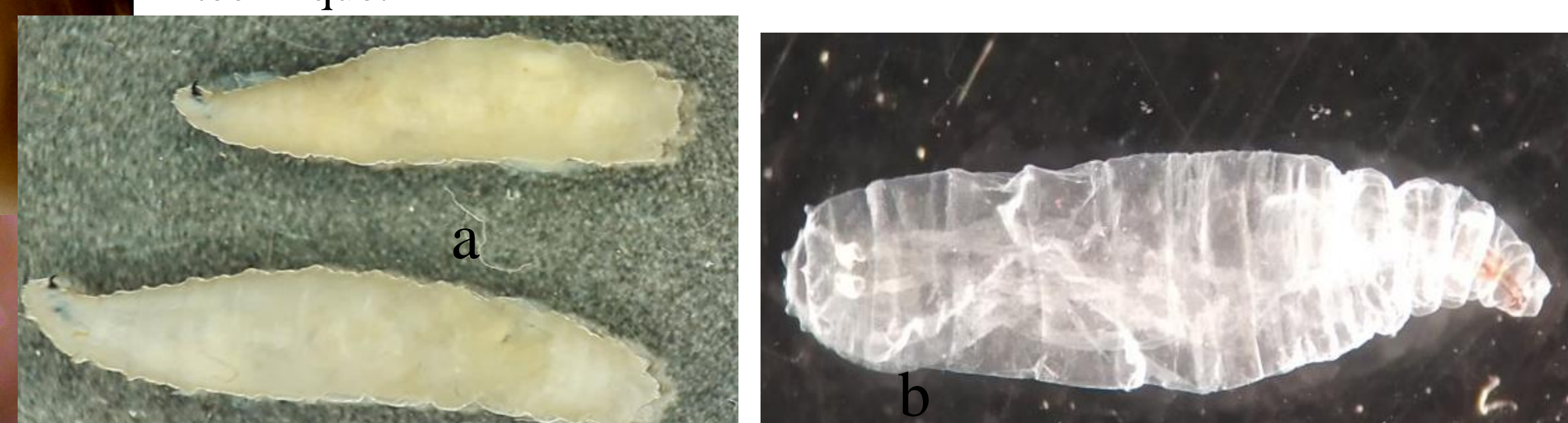
Results

The larvae specimens were identified by the forensic entomologist as individuals of *Sarcophaga argyrostoma* (Sarcophagidae) **second instar larvae** (6-8mm) : a) before and b) after the clearing technique.




anal division, posterior view, Posterior spiracle

Mouthhooks



Flesh fly larvae specimens are deposited in the Macedonian National Collection of Invertebrates at the Faculty of Natural Sciences and Mathematics, Skopje.



Second instar morphology of *Sarcophaga argyrostoma* (Sarcophagidae). A – anal division, posterior view; B – cephaloskeleton, lateral view., C- anterior spiracle. Abbreviations: *sp* posterior spiracle.

Discussion

Sarcophaga (L.) *argyrostoma* belongs in the category of “nosocomial myiasis agents”. Predisposing risk factors include altered consciousness (immobilized patients), blood or odors of decomposition, inattention to proper nursing care and summer season. Comatose and disabled patients such as in our case are very much prone to infestation. Nosocomial myiasis should alert medical personnel about the possible presence of other infestations and a need of urgent preventive measures.

Conclusion

Nosocomial myiasis is underreported although it can occur anywhere in particularly when contributing factors such as unconsciousness and hot summer days are present.

Myiasis is not mandatory reportable and our aim was to raise awareness of this diagnosis.

References

1. Mielke U, Schlote A . 1980. Hospitalerkrankung durch Fliegenmaden. Z. Arztl. Fortbild. (Jena) **74**: 556–558.
2. Niederegger, S., Wartenberg, N., Spieß, R., & Mall, G. (2011). Simple clearing technique as species determination tool in blowfly larvae. Forensic Science International, 206(1-3), 96-98.
3. Szpila, K., Richey, R., & Pape, T. (2015). Third instar larvae of flesh flies (Diptera: Sarcophagidae) of forensic importance—critical review of characters and key for European species. Parasitology research, 114(6), 2279-2289.