

ISSN 2545-4366  
www.e-mja.com

# MJA

## **Macedonian Journal of Anaesthesia**

A Journal on Anaesthesiology, Resuscitation, Analgesia and Critical Care

**Number 4. May 2018**

Journal of the Macedonian Society of Anaesthesiologists  
and Macedonian Society of Critical Care Medicine

---

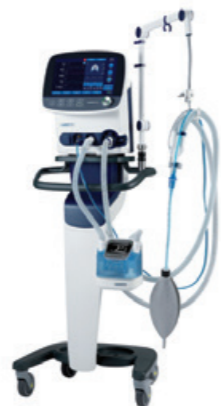**Publisher:**

Department of Anaesthesia and Reanimation, Faculty of Medicine,  
"Ss. Cyril and Methodius" University, Skopje, Macedonia

Опрема за анестезија,  
хирургија и интензивна нега



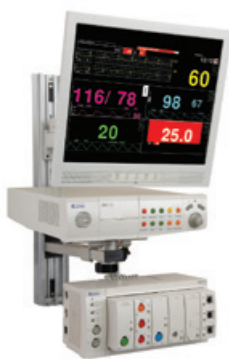Анестезија апарат Leon Plus,  
Heinen + Löwenstein,  
Германија



Вентилатор  
Hamilton, Швајцарија



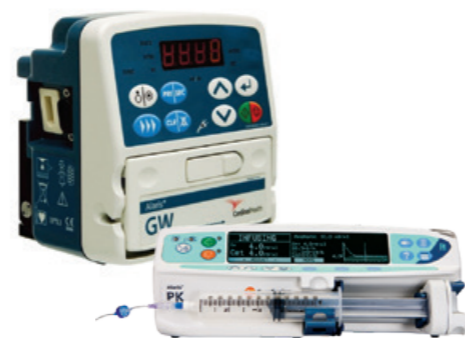Транспортни вентилатори  
Weinmann Emergency,  
Германија



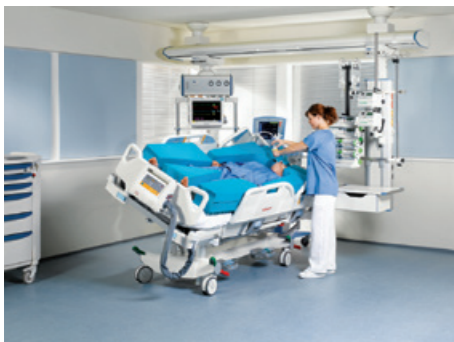Модуларен пациент монитор  
Mennen Medical, Израел



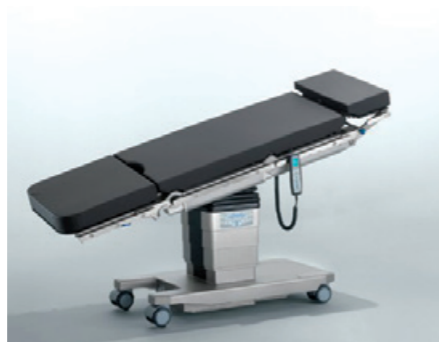Флексибилен ендоскоп за  
тешка интубација  
PENTAX Medical, Јапонија




Инфузиомати, перфузори,  
TIVA и PK пумпи  
Care Fusion, BD, САД



Кревет за интензивна нега  
Multicare, Linet Group, Германија



хируршки операциони столови и светла  
Trumpf Medical, Германија



**Macedonian Journal of Anaesthesia**  
A Journal on Anaesthesiology, Resuscitation, Analgesia and Critical Care

**Editor-in-Chief**

Mirjana Shosholcheva

**Deputy Editors:**

Andrijan Kartalov

Biljana Kuzmanovska

**Associate Editor**

Marija Jovanovski-Srceva

**Editorial Board:**

Marija Sholjakova (Macedonia)

Nikola Jankulovski (Macedonia)

Karin Khuenl-Brady (Austria)

Quirino Piacvoli (Italy)

Zorka Nikolova-Todorova (Macedonia)

Radmilo Jankovic (Serbia)

Olegs Sabelnikovs (Latvia)

Jannicke Mellin-Olsen (Norway)

Meral Kanbak (Turkey)

Nebojsa Ladjevich (Serbia)

Zoran Karadjov (Macedonia)

Hristo Bozov (Bulgaria)

Zuhal Aykaç (Turkey)

Katarina Sakic (Hrvatska)

Jasmina Jakupovich-Smajich (BIH)

Jasminka Nancheva (Macedonia)

Vojislava Neskovic (Serbia)

Daniela Miladinova (Macedonia)

Jordan Nojkov (Macedonia)

Paul Zilberman (Israel)

Antigona Hasani (Kosovo)

Biljana Shirgovska (Macedonia)

Atanas Sivevski (Macedonia)

Hülya Bilgin (Turkey)

**Production Editor**

Vanja Gievski

**Publisher:**

Department of Anaesthesia and Reanimation, Faculty of Medicine, "Ss. Cyril and Methodius"  
University, Skopje, Macedonia

Proofreading Daniela Nacevska Stojcevska

Printed by ASKOLOR

**octaplex®**

Highly Effective  
and Tolerable

## Highly effective

Good haemostatic balance  
of coagulation factors and inhibitors

**octaplex®** is a 2nd generation prothrombin complex concentrate (PCC). It is used in the prophylaxis and treatment of bleeding in hereditary or acquired coagulation defects with isolated or combined deficiency of the prothrombin complex factors.

**octaplex®** contains, in well-balanced proportions, the four coagulation factors II, VII, IX and X as well as the inhibitor protein C and its cofactor protein S

## High tolerability and safety

Low risk of thrombogenic adverse events due to:

- minimal activation of coagulation factors
- therapeutic concentrations of protein C and protein S

## Fast onset of action

Replacing what's required

Bleeding is the most serious adverse event of oral anticoagulants and is a major cause of morbidity and mortality. Rapid and efficacious reversal of anticoagulation is herefore mandatory in bleeding patients or prior to urgent surgery.

PCC is recommended for reversal of oral anticoagulants like Warfarin. Response to **Octaplex®** is rapid with decline of INR within 10 minutes after **Octaplex®** administration.



## CONTENT

### EDITORIAL

**Panta Rhei** – Heraclitus, “Everything flows, everything changes” ..... 7  
Prof. Jordan Nojkov, MD, PhD

### ORIGINAL ARTICLE

**EVALUATION OF REMIFENTANIL TCI PREDICTION** ..... 11  
Piacevoli Q, Del Gaudio A, Wouters G

### ORIGINAL ARTICLE

**ORBITAL METASTASIS AS PRIMARY PRESENTATION OF MISDIAGNOSED BREAST CANCER: A CASE REPORT** ..... 20  
Lazareva E, Smichkoska S, Atanasov Z, Krstevska V, Klisarovska V, Iljovska M

### ORIGINAL ARTICLE

**THE POST-CARDIAC INJURY SYNDROME: REVIEW OF THE LITERATURE** ..... 29  
Kostadinovska B, Nikolic A, Slaveski D, Belostocki V, Srbinovski J, Mustafa E, Mircevska E, Dimishkov A, Paunkoski I

### REVIEW ARTICLE

**EVALUATION OF ANALGESIA, SEDATON AND AGITATION IN INTENSIVE CARE UNIT** ..... 40  
Trojikj T

### CASE REPORT

**EIGHT YEARS OF HEMODIALYSIS WITH TUNNELED DIALYSIS CATHETER PLACED IN RIGHT VENTRICLE: A CASE REPORT** ..... 49  
Mikjunovikj Lj, Sreeva M, Kokareva A, Donev Lj

## REVIEW ARTICLE

- THE INFLUENCE OF ANESTHESIA IN INTRACAVITARY BRACHYTHERAPY IN LOCALLY ADVANCED CERVICAL CANCER - SINGLE INSTITUTIONAL EXPERIENCE** . . . . . 51

Klisarovska V, Smichkoska S, Krstevska V, Lazareva E

## RETROSPECTIVE ANALYSIS

- POSTOPERATIVE COMPLICATIONS IN PATIENTS UNDERGOING THYROID SURGERY** . . . . . 59

Jovanovski-Srceva M, Kokareva A, Kartalov A, Kuzmanovska B, Gavrilovska A, Spirovski Z, Kondov G, Cholanceski R, Crvenkova S, Mojsova M, Peneva M, Stevic M, Nedxati J, Shosholcheva M, Jankulovski N

## CASE REPORT

- PRIMARY HYPERPARATHYROIDISM IN PREGNANCY** . . . . . 65

Kondov B, Pemovska G, Shukarova E, Stavric K, Srceva M, Majstorov V, Stojanovski S, Ilic Miladinova D, Angushev D, Tolevska N, Jovanovska AM, Kondov G

## EDITORIAL

**Panta Rhei** – Heraclitus

*“Everything flows, everything changes”*

One-hundred-seventy-and-two years have passed since the first officially administered anesthesia. Then, in Boston, the American dentist William Morton gave divinyl ether anesthesia to a 20-year-old patient, who at that time was underwent to a neck tumor surgery performed by the famous surgeon Collins Warren. This event was immediately reported in the newspapers at the time, while the news reached Europe quite rapidly thanks to the newly placed cable connection under the Atlantic. Here in the Balkans, only a year after, the Croatian dentist Ivo Bettini in Zadar extracted a tooth from a patient using general etheric anesthesia. However, already in 1848 the first death that had occurred from the use of general anesthesia was also reported.

Almost at the same time, local anesthesia started to be used in medical procedures (“anesthesia without sleep”). The first local anesthesia procedures were administered by surgeons and the first spinal anesthesia was performed by the German surgeon August Bier in 1898.

Since then, these two methods have been developing till this day as two parallel directions. There were times when one or the other was more popular, but in global terms, the dilemma whether general or regional anesthesia should be performed remains, of course in relation to surgeries where this type of choice is possible.

The first used general anesthetics consisted of gases or volatile liquids (ether chloroform, nitrous oxide, cyclopropane), thus, in people’s collective memory the image of anesthesia as something that is inhaled through a mask which causes loss of consciousness has persisted. Today, with the exception of nitrous oxide, the anesthetics that introduced the era of anesthesia have become distant history. The contemporary inhalation anesthesia has reached its peak in 1956 when the use of Halothane was introduced and especially during the 80ties when Enflurane and Isoflurane were applied, while during the next decade Desflurane and Sevoflurane were introduced.

Intravenous anesthesia has bloomed during the World War II when Thiopentone was massively introduced in surgery, as a medication which was advertised that can be administered by the surgeon itself without the necessity of a different kind of a professional. However, due to this unserious approach, which was specially accentuated from the still unperfected techniques related to the maintenance of the airway, frequent incidents occurred that led to severe criticism by the professional public. Intravenous anesthesia had to wait for its next “golden age” for a long time, until the beginning of the 1980ies, when the combination of Fentanyl and Droperdol was massively being used together with the new relaxant at that time Pancuronum bromide, which produced the so-called neuroleptic anesthesia.

Regional anesthesia was also faced with irregular development which was marked by years of stagnation and years of new discoveries. During the first few decades of the 20<sup>th</sup> century several local anesthetics have been synthesized, however the usage of Procaine (Novocaine) and Tetracaine persisted. Later, in 1946 Lidocaine was synthesized and in 1957 – Bupivacaine, anesthetics that are widely used even to this day, amongst other, for neuraxial blocks. But this type of anesthesia has also had its bad days. In 1947, two cases of paraplegia were registered in Great Britain, which occurred during the same day and at the same hospital after the patients were given spinal anesthesia, while a similar case was also registered in the United States. Six years later, this event (the so-called “Woolley and Roe case”) has led to a spectacular trial. Although in the legal procedure the anesthesiologist was acquitted, the entire event has undoubtedly cast suspicion over spinal anesthesia safety which has led to the practice being abandoned in Great Britain and several other countries in the next 25 years.

When considering the anesthesia development we can see that sometimes there were directions that were accepted with amazement at first, but later it was concluded that those practices were “dead-ends”. Many hypnotics and anesthetics were used for a certain period of time only to be later abandoned for their toxic or allergic manifestations. During the 1970ies and 1980ies, the so-called “electroanesthesia” was practiced in the former Soviet Union, in which, after the standard introduction, the level of anesthesia was maintained by emitting electrical current with certain characteristics through the brain. Today this method is abandoned because it does not offer any advantages.

During the 1960ies at the time of Mao Zedong, the Chinese have popularized the so-called “acupuncture anesthesia”. By using electrical stimuli on certain acupuncture points the doctors were able to analgize certain regions of the body. Some notable professors of anesthesiology from the US and Europe who have visited China at that time were amazed by the method. But, after it was concluded that a positive outcome could not be predicted, that the procedure was often incomplete and that it took a long period of time to be performed this method too was practically abandoned, even in China. Also, in terms of the neuroleptic anesthesia, there were attempts to replace the Fentanyl component with a different opiate (buterphenol, tramadol), but as these attempts did not prove that the modification would lead to any kinds of advantages, it too was abandoned, especially after its new analogue drugs appeared on the market such as Alfentanyl, Sufentanyl and Remifentanyl.

On the other hand, we are witnessing the reintroduction of certain almost forgotten anesthetics in their original form or modified. The most visible example is the Ketamine which was synthesized in 1962 while its usage was introduced in the 1970ies. After the first decade of amazement, its usage was significantly decreased due to the many side effects such as agitation, confusion, hallucinations, and the danger of its misuse as a drug, therefore its usage was deducted to the needs of veterinary medicine. However, during these last two decades, the Ketamine is going through a sort of renaissance. After it was made known that it inhibits the effects of many physiological processes that occur through the NMDA receptors its use was spread in order to procure the so-called “preemptive analgesia”, but also in the treatment of depression and other illnesses.

If we would conduct a critical analysis of everything that took place during anesthesia’s short history the question about the attitude the anesthesiologist should adopt in terms of the challenges brought by modern living, in relation to the anesthesia procedures and the new medications, remains. There is an axiom that says that if you want to have a solid and stress-free professional career then do not be the first person who would use a new procedure or new medications, but also, do not be the last person who would use drugs and procedures that others have already abandoned. But if we would all abide to this opportunistic axiom then what would happen with the development of the professional field?

Since forever, progress was due to the efforts of those who were the bravest, of course by respecting the principles of professional ethics, and especially the patients’ safety.

During the years when I was specializing in anesthesiology, some of the old-school anesthesiologists were showing a certain degree of resistance in terms of the regional techniques. There was even the opinion that those who practice regional techniques were in fact afraid of their own profession and that is the reason why they “run away” from the general endotracheal anesthesia procedures. However, time has shown the opposite and today regional anesthesia is accepted even in the environments that have resisted it for a long period of time, for instance in the obstetric anesthesiology. Also, during this time, another axiom was popular. This one said that for the patient, it is best to perform the anesthesia procedure you are most familiar with and the one you trust the most. Later this axiom was replaced with the stance that the anesthesiologist should know all the different types of anesthesia procedures, and the doctor should perform the type that is most convenient for the patient given his or hers medical condition, including the accompanying illnesses, his or her age and of course his or hers own opinion related to the anesthesia procedure that the medical experts propose. Often, in situations like these, a dilemma imposes. What if the doctor deems that for a certain patient the general anesthesia is too risky and he or she categorically refuses the performance of regional anesthesia? It goes without saying that the will of the patient has to be respected, but in practice these decisions do not come easy.

In the beginnings of the introduction of central neuraxial blocks spinal anesthesia was the most frequently used method. But later, with the development of new, technically updated equipment, the epidural anesthesia took up most of the share in the administered blocks. There was even a period when spinal anesthesia was considered as something that was imposed in the developing countries and for those patients who do not have a quality medical insurance, while the epidural anesthesia is the right one that fits the “contemporary” highly developed medical systems. Nevertheless, over time things have found their own course of development. Both in the developed countries and in the developing countries spinal anesthesia is the most common type of central neuraxial block. Why should we use a more complicated, more expensive procedure, if the simpler and the cheaper one is able to satisfy the needs? In this way the sovereign fields for epidural anesthesia have cleared themselves out. It has absolute advantage when it comes to

painless child deliveries, in terms of pain treatment, in combination with a general anesthesia procedure in long-lasting abdominal interventions, but not everywhere.

When we speak about safer anesthesia procedures, we should mention the interesting trend that has appeared in the past several decades. Instead of the dilemma on the application of the type of central neuraxial block, there is a growing perspective for peripheral nerve blocks. The perfection of the peripheral nerves localization through neuro-stimulators, and especially with the use of ultrasound techniques, has led to an increasing percentage of surgical interventions that are performed with precisely this kind of anesthesia procedures. Many blocks that are known for many years, such as TAB, QLB, ED etc, but were rarely used due to the high percentage of failure or partial success, have become common procedure thanks to the new technologies. As in surgery, the axiom “great surgeon – great cut” was replaced with the approach whose priority is placed on less invasive surgery or its complete avoidance and replacement with endoscopic interventions, in the same way, in anesthesiology, the less invasive and the much safer procedures take up a larger space.

In the end, I would like to say a few words on the development of our profession in future. Will the time when anesthesia will be performed by sophisticated machines that would have integrated information gathered through the patient’s monitoring come, while the machine would deliver certain amounts of hypnotic, analgesic or muscle relaxant? If the so-called “robotic surgery” is already being used in surgery, then why anesthesiology would be deprived of similar trends. The anesthesia machine is already dubbed “anesthesia workstation” and it integrates data provided by the monitoring and the patient’s reactions, while the anesthesiologist is already defined as a “doctor-specialist in perioperative medicine”. The computerized machine will deliver the needed amount of medications according to previously defined needs expressed in milligrams or MACs, but would this be enough for each and every patient?

Certainly, the modified Bi Spectral Index and the remaining palette of monitored parameters will enable correction of the delivered doses, but it would be best if the machine could “predict” which amount of the drug is needed for the specific patient depending on the enzymes that he or she has that also participate in the pharmacokinetics of the medication. Today this is possible via the knowledge we are able to gather from pharmacokinetics. In not so distant future every baby would get its own genetic map that would include his or her entire genome that would allow the application of the so-called “personalized medicine” not only in anesthesiology but also in terms of all necessary types of therapy.

During these last few decades we have not witnessed any fundamental discovery in the field of anesthesiology. All the novelties we learn about are mere modifications or improvements of the already existing anesthesia models. Maybe in near future something genuinely new will be discovered. In fact, the history of anesthesia shows that its development was not continuous but took place in the form of “leaps” that followed the application of new discoveries.

*Prof. Jordan Nojkov, MD, PhD*

## EVALUATION OF REMIFENTANIL TCI PREDICTION

*Piacevoli Q<sup>1</sup>, Del Gaudio A<sup>2</sup>, Wouters G<sup>3</sup>*

<sup>1</sup> *Visiting Professor of Anesthesia and Intensive Care, University “St. Cyril and Methodius” Skopje -Macedonia. President of the World Society of Intravenous Society.*

<sup>2</sup> *Division of Anesthesia and Intensive Care II, Department of Head and Neck, Scientific Institute “Casa Sollievo della Sofferenza”, San Giovanni Rotondo , Italy.*

<sup>3</sup> *Eurofin Breda Institute, Breda, The Netherlands.*

### ABSTRACT

**Background:** The aim of the study was to elucidate the difference in concentration among remifentanil blood, cerebral-spinal fluid and cerebral extracellular fluid levels, and to verify the existence of a correlation between arterial and cerebral remifentanil.

**Methods:** The study population was formed by patients scheduled for elective intracranial surgery for cerebral supratentorial neoplasia. We determined the concentration of remifentanil and its main metabolite- remifentanil acid in the blood and in the brain.

**Results:** The mean Performance Error was -45.13% (min -21.80, max -88.75) for the first series of arterial samples, -38.29% (min -6.57, max -79.17) for the second one and 67.73% (min 7, max -93.12) for the ECF fluid sample.

**Conclusions:** We confirmed the presence of wide inter-individual variability with regard both to blood and cerebral remifentanil concentrations. At the end we found a trend in the ratio between the various compartments examined.

**Key words:** Remifentanil TCI, cerebral micro dialysis, cerebral extracellular fluid levels.

**Corresponding Author:** *Prof. Quirino Piacevoli. E-mail address: quirinopiacevoli@gmail.com*

## Introduction

Peter's Never, Never, Neverland

Peter tells Wendy the way to Neverland is "second star to the right and straight on till morning", but it is made clear that "he just said anything that came into his head". In the novel, it is stated they found the island only because it was "out looking for them". Barrie also writes that it is near the "stars of the milky way" and it is reached "always at the time of sunrise" - from Peter Pan or the Boy Who Would Not Grow Up. (J.M Barrie 1904)

The effect site is not necessarily the ECF concentration in the brain. Nor is it the concentration of whatever intra-extracellular fluid in the vicinity of opioid receptors, where ever they are located. The hypothetical effect compartment is a place where there is no delay between concentration and effect: "it has not a real location in the body". (Charles Minto)

What is the effect site? Where is it? And how does it work?

These are the questions at the basis of our study.

Remifentanil is a synthetic opioid, characterized by quick onset and similarly rapid offset, the latter being a result of its large clearance by plasma and tissue esterase. These characteristics make remifentanil ideally suited for target-controlled infusions (TCI). Consequently, Minto developed a pharmacokinetic model which allows its administration via a TCI infusion system. (1,2,3) The first end-point of the study is to validate the brain extra cellular fluid (ECF) as reflecting the effect site in Minto's model, the second one is to verify the presumable existence of a correlation between arterial and cerebral remifentanil concentrations under stable conditions. Brain micro-dialysis has been used to shed light in this aspect of the pharmacokinetic and to correlate these findings with Minto's model.

## Material and Method

### Selection of Patients

The study had been approved by the local ethics committee and the patients had given their informed consent. The study population was formed by patients scheduled for elective intracranial surgery for cerebral neoplasia. We tried to keep the study population as homogeneous as possible, aiming to minimizing inter individual variability in pharmacokinetics. Inclusion criteria were 1) male gender; 2) age between 40 and 50 years; 3) weight between 70 and 85 kg; 4) height between 165 and 180 cm; 5) ASA status I or II; 6) scheduled for surgery for supratentorial neoplasia with a volume not higher than 8cm<sup>3</sup>; 7) GCS 15.

Exclusion criteria were allergic diathesis to the used drugs and the use of any kind of medications. Overall, nine patients were enrolled in the study.

### Operating theatre management

All patients were pre-medicated with clonidine 2 mcg/kg i.m. 12 hrs and 1 hr before being transferred to the operative theatre for removal of the cerebral neoplasia. All patients received

general anesthetic with propofol and remifentanil administered via a Fresenius Base Primea infusion pump.

Firstly, a remifentanil infusion on a dedicated venous access through a 20G angiocath was started. The initial target was 3ng/ml in bio phase to be achieved in 3 minutes. Thereafter, an infusion of clonidine (300 mcg in NaCl 0.9% 50 ml) at the rate of 0.15 mcg/kg/min was started. Anesthetic induction was performed with propofol infused with TCI modality (Schneider algorithm), while the decision about dosage and timing of the other drugs were up to the anesthetist responsible for the case. Radial artery access was obtained for ABP monitoring and sequential blood sampling and BIS monitoring was started as well. Oro-tracheal intubation was then performed after paralysis with cisatracurium. Whenever the 3 ng/ml of remifentanil turned out to be insufficient to blunt the hemodynamic response (namely, if ABP or HR increased more than 25% compared to baseline) the protocol included removal of the laryngoscope, increase of the remifentanil target by 0.5 and reinsertion of the laryngoscope one minute later.

One of the requirements to make the microdialysis samples reliable was the consistency of the remifentanil target concentration throughout the sampling period. Therefore, the study protocol prescribed that the lowest effective remifentanil target was determined at the moment of intubation and kept unvaried up to the end of the sampling period. Instead, the anesthetist was free to vary propofol and clonidine infusion rates and to manage the fluid balance of the patients in order to achieve the hemodynamic parameters and the BIS score (< 40) he deemed clinically indicated.

### Micro Dialysis, Sampling Methods and Analysis

Micro dialysis is an effective technique that allows investigation of the concentration of the substances that are present in the interstitial fluid of a tissue (6). In recent times, it has gained a certain amount of popularity for monitoring of brain chemistry in several clinical and research settings (7).

After dura opening, the neurosurgeon inserted, through the craniotomy a CMA 70, a micro dialysis catheter (CMA Micro dialysis, Sweden) in a healthy area of the brain, not affected by edema, as shown by the preoperative MRI. The catheter was connected to a CMA 107 pump and to a sterile micro vial on its distal end. After priming with an infusion rate of 15 micro liters/min for 5 minutes, the micro vial was replaced with a new one and perfusion was started with a lactated Ringer's solution at a flow rate of 5 micro liters/min for 60 minutes. As a result, at the end of the sampling procedure, 100 micro liters of dialysate were collected. Furthermore, arterial blood samples of 3 ml each were collected, respectively one at the beginning and one at the end of the sampling period. In addition, for the first two patients one venous sample of each was taken as well.

Immediately after collection, blood samples were transferred into heparin-coated vials and subsequently in Nalgene tubes containing 20 micro liters of citric acid, designed to neutralize blood esterases and therefore stop remifentanil metabolism. The content of the micro dialysis vial was also transferred into a Nalgene tube. For two patients it was possible to collect a sample of cerebral spinal fluid. All collected samples were then stored at -20°C and eventually shipped to

Medinet, Breda, Holland where concentration of remifentanil and its main metabolite, remifentanil acid, were determined. In the laboratory blood, cerebrospinal fluid (CSF) and microdialysate samples were thawed, homogenized and centrifuged. When required, samples were diluted to a volume of 1 mL with blank human whole blood. A volume of 1 mL of sample was mixed with 25 µL of the internal standard solution (D4-Remifentanil and D4-GR90291A, 1000 ng/mL) and 1.0 mL phosphate-buffer (pH 7.0, 0.1 mol/L). The mixture was centrifuged at approximately 12.000 rpm at 4°C for 15 minutes, and the bottom layer was discarded.

The C18 SPE column (Bond Elut C18 100 mg 1 ml) was activated using 2 mL methanol, 1 mL ultra pure water and 1 mL phosphate-buffer, pH 7. After transferring the sample mixture into the SPE column, the column was washed with ultra pure water and the analyses were eluted with 1 mL methanol.

The extract was dried under a gentle stream of air with nitrogen at room temperature and reconstituted in 100 µL mobile phase. After mixing for approximately 2 minutes, 10 µL were injected on a Symmetry C18 column (5 µm particle size, 150 mm x 2, 1 mm), with a mobile phase of 50/50 acetonitrile/ultra pure water containing 2 mmol ammonium acetate. Detection was in positive mode on Applied Bio systems Sciex API 3000 LC-MS/MS. The following transitions were monitored for remifentanil, its stable labeled internal standard D4-remifentanil, the metabolite GR90291A and its stable labeled internal standard D4-GR90291A: Remifentanil: m/z 377 -> 113 D4-Remifentanil: m/z 381 -> 113 GR90291A: m/z 363 -> 113 D4-GR90291A: m/z 367 -> 113.

### Correction Factor

During micro dialysis, a complete equilibrium of the concentrations of the molecules on the two sides of the semi permeable membrane has been never actually obtained, and the recovery ratio (the ratio between the concentration outside and inside the catheter) depends on many factors, the most important of which are the perfusion rate (in micro liters/min) and the physical characteristics of the molecule (7). Therefore, in order to determine the recovery ratio of remifentanil at 5 micro liters/min, we performed an in vitro experiment using glucose as a surrogate for remifentanil, being the molecular weight of glucose nearly a half of that of remifentanil (180 vs. 367 g/mol). We immersed a micro dialysis catheter of the same type of the one used in a solution of 5% dextrose in water (equal to a glucose concentration of 5000 mg/dl). The results after 60 minutes of perfusion at 5 micro liters/min showed that the concentration of glucose in the microdialysate was 1018 mg/dl, about one fifth of that in the liquid in which the catheter was placed, so we assumed that it was realistic to estimate the real cerebral interstitial concentration of remifentanil to be five times as large as the one found in the microdialysate. Previous studies had assessed the recovery ratio of micro dialysis using glucose, yielding results somewhat different from ours (8). However, the probe used for such study was the model CMA 60, while the probe involved in our study was a CMA 70. This may have affected the findings of our in vitro study.

### Data Analysis

Data regarding measured concentration values recorded in an Excel spreadsheet; statistical calculations were performed with the statistical package Medcalc. The Student's T-Test for pair samples has been used to compare the two series of arterial samples. The predictive performance of the Minto pharmacokinetic parameter set was evaluated by examining the performance error. For each sample the PE was calculated as  $PE \% = [(C_m - C_p) / C_p] \times 100$ , where  $C_p$  is the predicted concentration in the compartment in question, while  $C_m$  is the measured concentration of remifentanil in that compartment. Median PE for all samples was calculated. Subsequently, Pearson's correlation coefficient was calculated between the predicted value and the measured values, as well as between predicted values.

### Results

Of the nine patients recruited, one has no interstitial fluid value available because of intra operative catheter damage. Mean age of the patients was 44 (40-50, SD 3.53). Mean height was 170 cm (165-178, DS 4.03) and mean weight 74 kg (70-83, DS 4.23). All measured values are shown in Table 1.

Patient	Target	Remiplasma1	Remiplasma2	RemiECF	PE%1	PE%2	PE%ECF
1	4	0,45	2,25	0,567	-88,75	-43,75	-29,13
2	6	4,32	2,46	1,44	-28,00	-59,00	20,00
3	4	2,44	2,9	ND	-39,00	-27,50	NA
4	3	1,27	0,625	0,642	-57,67	-79,17	7,00
5	9,1	4,49	4,94	0,401	-50,66	-45,71	-77,97
6	5	3,91	4,2	0,425	-21,80	-16,00	-57,50
7	7	3,53	4,32	0,0963	-49,57	-38,29	-93,12
8	8	4,39	6,76	0,232	-45,13	-15,50	-85,50
9	7	4,67	6,54	0,14	-33,29	-6,57	-90,00
Median	6	3,91	4,2	0,413	-45,13	-38,29	-67,73

Table 1. Main measured parameters and Performance Error.

All data series resulted to be normally distributed (Kolmogorov-Smirnov test). The concentration of remifentanil does not significantly differ between the two series, whereas remifentanil acid is significantly higher in the second series ( $t=4,276$ ,  $p<0.01$ ). The mean Performance Error was -45.13% (min -21.80 max -88.75) for the first series of the arterial samples, -38.29% (min -6.57 max -79.17) for the second ones and 67.73% (min 7 max -93.12) for the ECF fluid sample. Mean PE of the first series of samples is not significantly different from the ones of the second series (Student's t-test). The concentration of remifentanil set on the pump was statistically correlated with the concentration found in the blood for both series of samples (Pearson's bilinear correlation,  $r=0.8078$ ,  $p<0.01$  e  $r=0.8061$ ,  $p<0.01$  respectively). However, neither the set concentration, nor the arterial samples were correlated with the ECF concentration. Also, the



concentration of remifentanil acid in blood and ECF has no correlation for either of the two series of blood samples. Remifentanil concentration is correlated with the concentration of remifentanil acid in the first series of samples ( $r=0.7459$ ,  $p=0.02$ ), but not in the second. (Fig. 1, 2, 3).

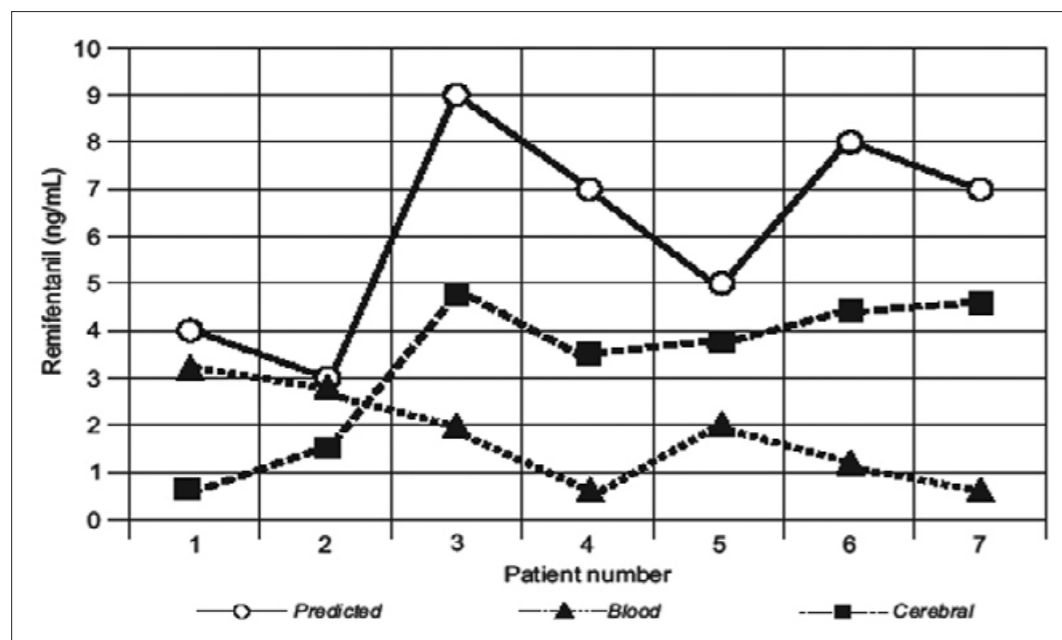


Figure 1. Set target concentrations and measured concentration in the 7 patients.

Our two venous samples showed that venous concentration was in both cases lower than the arterial one, as expected. (Fig. 2)

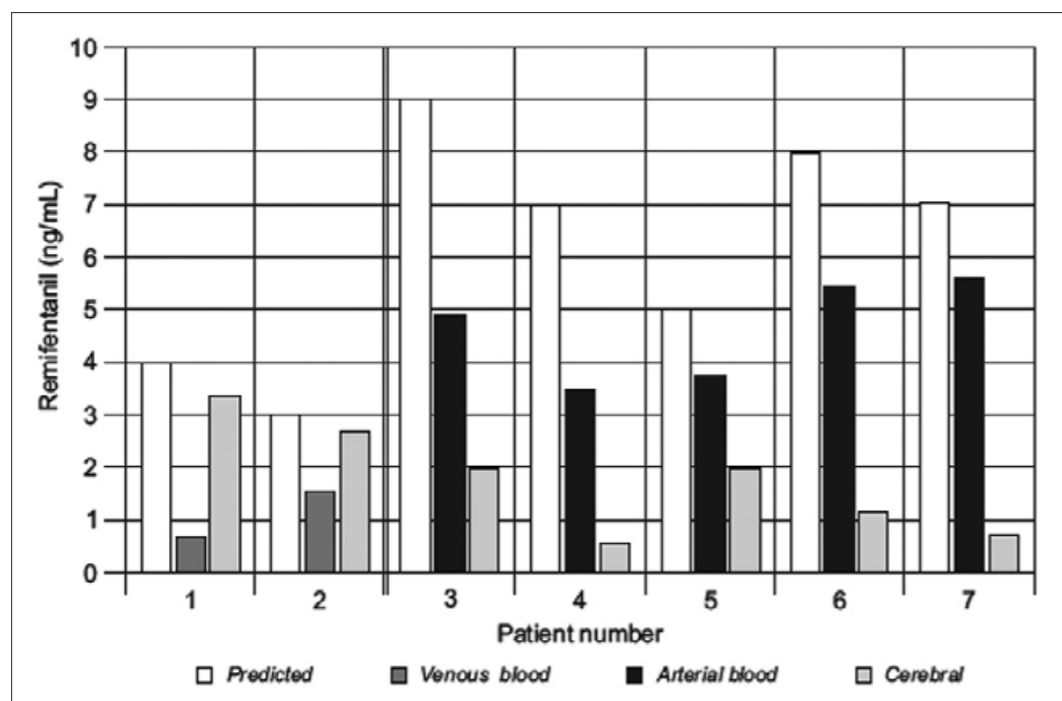


Figure 2. Set target concentration and measured ECF concentration (multiplied by 5).

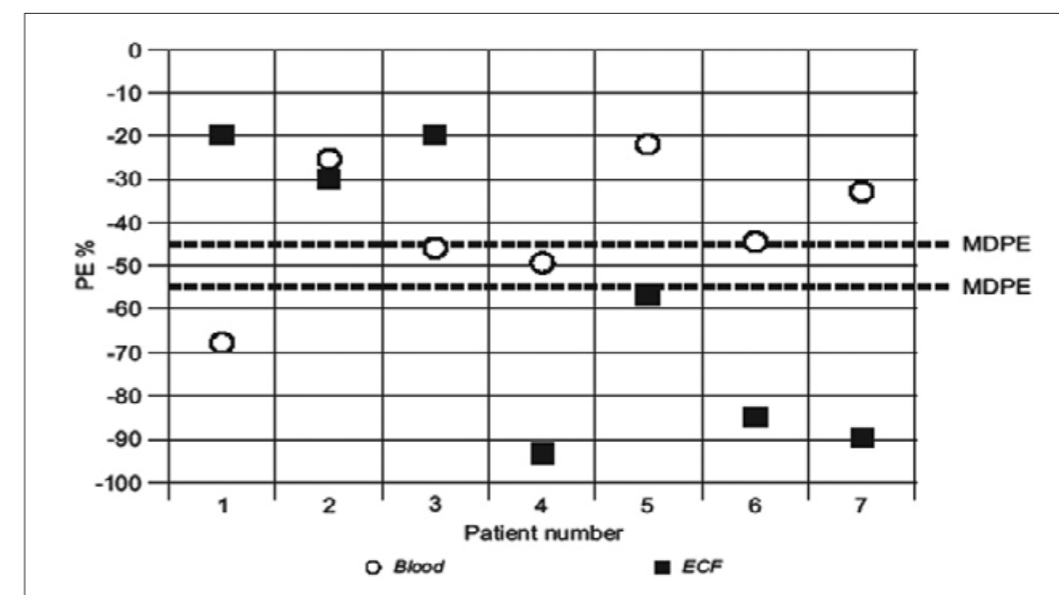


Figure 3. PE% for arterial and ECF samples.

### Discussion

The main problem of TIVA/TCI anesthesia is the relationship between predicted and measured effect site concentration of a drug. All the studies evaluated have shown differences between measured/predicted relationships of plasma concentration. In these studies the MDAPE was 20%, this value is considered a cut-off between an acceptable and unacceptable value. Anyone has measured the effect site concentration, in our opinion, the brain concentration of a drug. Our study has shown a correlation between predicted and measured blood concentration of remifentanil and a MDAPE between 38% and 45%. These data contrasts to previous literature that showed a MDAPE not higher than 15% (4). This poor predictive performance may have been partly caused by the fact that despite being very homogeneous, our population was different from the one from which Minto's model was developed. The latter was in fact rather heterogeneous, in order to gather information on the different covariates that affect remifentanil pharmacokinetics. Furthermore, in the previous studies the number of samples per individual was higher than two, and the patients were more than 9. Therefore, all these factors may have impaired the accuracy of our data. As far as cerebral interstitial concentration measurements are concerned, there are some remarks to make. Firstly, the effect site cannot be properly identified with the brain in pharmacological terms, as it actually is a virtual compartment. The brain is an organ, therefore, it should be better described as an organ belonging to the fast compartment and follow the kinetics predicted by the constant  $K_{12}$ , rather than  $K_{e0}$ . If we take a 40-year-old, 70-kg man as an example,  $K_{e0}$  will be 0.588, while  $K_{12}$  will be 0.39, at about two thirds of the former. As a consequence, it may be expected for the cerebral concentration to take 33% more than the virtual effect site to reach equilibrium with the blood. Nevertheless, this does not explain the high absolute median PE (67%) or the absence of correlation between the set concentration and the measured ECF concentration. The fact that the remifentanil target was kept constant for entire duration of the sampling should have prevented

such a discrepancy. It is important to note that despite the fact that propofol has been reported to be able to alter the kinetics of remifentanil, this seems to occur in a dose-independent fashion (12), and therefore should not account for the variability found in the present study. Another critical point of our work is the correction factor we applied as a consequence of the results of our in vitro experiment with glucose. Glucose and remifentanil have a different molecular weight (180 v 367 d), therefore it cannot be taken for granted that they will behave in the same way with respect to the semi permeable membrane of the micro dialysis catheter. However, Hutchinson et al. (8) showed that glucose and pyruvate share a similar recovery ratio despite the former having a molecular weight twice as large as the latter. In that study, the main factor affecting the recovery ratio was the infusion rate. For these reasons, it is our belief that even in the event of an inaccurate conversion factor being used, this might have explained only partly the inconsistency of our results; especially, it cannot account for the lack of correlation between target and measured concentration.

On the contrary, it is noteworthy to point out that micro dialysis only allows monitoring the events happening in a very limited area, and therefore may be influenced by alterations of the local blood supply. Nevertheless the study showed that the Minto parameter set consistently predicts values that are higher than the measured ones, both in blood and in the ECF. This is shown by the negative value of the calculated PE. In particular, PE of the ECF was higher than that of the blood, indicating an even more significant over prediction of ECF concentrations. The explanation for this phenomenon may be searched in the intra cerebral metabolism of remifentanil, as confirmed by the arterial venous difference in concentration previously reported by other studies. (9) Furthermore, it should be considered that 70% of remifentanil is in the blood in its protein-bound form, but only free remifentanil is able to cross the blood-brain barrier. Lastly, it is possible that the remifentanil that is not bound to opioid receptors is continuously being metabolized by the cerebral tissue esterases, decreasing the unbound fraction in the interstitial fluid. As to remifentanil acid, its half-life is about nine hours (10), much longer than remifentanil's; therefore, its higher value on average in the second series of samples was an expected finding. This also explains the lack of correlation between remifentanil and its metabolite in the second series of arterial samples. The absence of correlation between cerebral and plasmatic concentrations of remifentanil acid deserves the same considerations already discussed for remifentanil. The difference between arterial and venous blood samples witnesses the importance of tissue clearance in the metabolism of remifentanil, confirming previous data reported by Hermann et al. (11).

## Conclusions

Despite our efforts to make the sample population as homogeneous as possible, we confirmed the presence of wide inter individual variability with regard both to blood and cerebral remifentanil concentrations when compared to the predicted values (4). Moreover, the ratio between arterial blood and cerebral remifentanil was not consistent among our patients, in spite of the stable infusion rate of remifentanil. The low samples number does not allow evaluating the meaning in

clinical terms. It will be necessary to perform a larger study to identify the correlation, but is it really possible to give an answer to our question: can a suitable measure/predicted relationship being evaluated considering remifentanil effect site concentration? The answer on the basis of our knowledge is no. TIVA/TCI is the best way to perform anesthesia, but we need to validate our work by EEG and nociceptive monitoring.

## Conflict of interest:

None declared

## References

1. Minto CF, Schnider TW, Egan TD, et al. Influence of age and gender on the pharmacokinetics and pharmacodynamics of remifentanil. I. Model development. *Anesthesiology*. 1997 Jan; 86(1):10-23.
2. Minto CF, Schnider TW, Shafer SL. Pharmacokinetics and pharmacodynamics of remifentanil. II. Model application. *Anesthesiology*. 1997 Jan; 86(1):24-33.
3. Minto CF, Schnider TW, Short TG et al. Response surface model for anesthetic drug interactions. *Anesthesiology*. 2000 Jun; 92(6):1603-16.
4. Mertens MJ, Engbers FH, Burm AG, et al. Predictive performance of computer-controlled infusion of remifentanil during propofol/remifentanil anaesthesia. *Br J Anaesth*. 2003 Feb; 90(2):132-41.
5. Hoymork SC, Raeder J, Grimsmo B, et al. Bispectral index, serum drug concentrations and emergence associated with individually adjusted target-controlled infusions of remifentanil and propofol for laparoscopic surgery. *Br J Anaesth*. 2003 Dec; 91(6):773-80.
6. Lönnroth P, Smith U. Microdialysis--a novel technique for clinical investigations. *J Intern Med*. 1990 May; 227(5):295-300.
7. Lindefors N, Amberg G, Ungerstedt U. Intracerebral microdialysis: I. Experimental studies of diffusion kinetics. *J Pharmacol Methods*. 1989 Nov; 22(3):141-56.
8. Hutchinson PJ, O'Connell MT, Al-Rawi PG, et al. Clinical cerebral microdialysis: a methodological study. *J Neurosurg*. 2000 Jul; 93(1):37-43.
9. Egan TD, Lemmens HJ, Fiset P, et al. The pharmacokinetics of the new short-acting opioid remifentanil (GI87084B) in healthy adult male volunteers. *Anesthesiology*. 1993 Nov; 79(5):881-92.
10. Westmoreland CL, Hoke JF, Sebel PS et al. Pharmacokinetics of remifentanil (GI87084B) and its major metabolite (GI90291) in patients undergoing elective inpatient surgery. *Anesthesiology*. 1993 Nov; 79(5):893-903.
11. Hermann DJ, Egan TD, Muik KT. Influence of arteriovenous sampling on remifentanil pharmacokinetics and pharmacodynamics. *Clin. Pharmacol. Ther*. 1999 May; 65 (5): 511-8.
12. Bouillon T, Bruhn J, Radu-Radulescu L, et al. Non-steady state analysis of the pharmacokinetic interaction between propofol and remifentanil. *Anesthesiology*. 2002 Dec; 97(6):1350-62.

## ORBITAL METASTASIS AS PRIMARY PRESENTATION OF MISDIAGNOSED BREAST CANCER: A CASE REPORT

Lazareva E<sup>1</sup>, Smichkoska S<sup>1</sup>, Atanasov Z<sup>2</sup>, Krstevska V<sup>3</sup>, Klisarovska V<sup>4</sup>, Iljovska M<sup>4</sup>

<sup>1</sup> Department of Breast Cancer, University Clinic of Radiotherapy and Oncology, Skopje, Ss. Cyril and Methodius University in Skopje, Republic of Macedonia, Medical Faculty.

<sup>2</sup> Department of Lung Cancer, University Clinic of Radiotherapy and Oncology, Skopje, Ss. Cyril and Methodius University in Skopje, Republic of Macedonia, Medical Faculty.

<sup>3</sup> Department of Head and Neck Cancer, University Clinic of Radiotherapy and Oncology, Skopje, Ss. Cyril and Methodius University in Skopje, Republic of Macedonia, Medical Faculty.

<sup>4</sup> Department of Gynecologic Oncology, University Clinic of Radiotherapy and Oncology, Skopje, Ss. Cyril and Methodius University in Skopje, Republic of Macedonia, Medical Faculty.

### ABSTRACT

We report the case of orbital metastasis from a hormone-positive infiltrating lobular carcinoma in a previously misdiagnosed metastatic breast cancer in a 61-year old woman presenting with ophthalmic symptoms (diplopia, bulb proptosis). She received external beam radiotherapy, particularly 3D conformal radiotherapy, chemotherapy and hormone therapy. The metastatic involvement of the orbit in malignant tumors is a rarely diagnosed condition. Breast cancer accounts for the majority of these cases. This article highlights the importance of evaluating the one such unique metastatic site (orbital metastasis) as the first indication of advanced malignancy and reinforces the importance of an early correct diagnosis.

**Keywords:** breast cancer, infiltrating lobular carcinoma, orbital metastases.

**\*Corresponding author:** Emilija Lazareva, Department of Breast Cancer, University Clinic of Radiotherapy and Oncology, Majka Tereza 17, 1000 Skopje, Macedonia. Phone: +389 78 44 55 19; E-mail address: [lazarova.emilija@gmail.com](mailto:lazarova.emilija@gmail.com)

**Disclosure:** No potential conflicts of interest were disclosed.

### Introduction

Breast cancer is a histologically heterogeneous disease. Infiltrating ductal carcinoma (IDC) accounts for approximately 90% of breast cancers, whereas infiltrating lobular carcinoma (ILC), the second most common breast carcinoma, comprises approximately 10% of breast cancers (1, 2). The histopathologic appearance of ILC is different from that of IDC. Whereas IDC often metastasizes to the lung, liver, bone, and brain, ILC tends to spread to the gastrointestinal tract, genitourinary tract, peritoneum, retroperitoneum and leptomeninges (2–7). Some investigators have suggested that, compared to IDC, ILC has a higher distant metastasis rate (3,4,8), likely because of its infiltrative nature. It has been postulated that in ILC loss of E-cadherin, the cell-to-cell adhesion molecule, facilitates the metastasis process. Like ILC in the breast, metastatic ILC tends to infiltrate the affected organs in a diffuse process instead of forming a discrete tumor nodule.

The high incidence of breast cancer ocular metastasis, may be related to the longer life expectancy of metastatic breast cancer patients, thus providing a longer time for intraocular metastasis to develop. It is therefore important to recall this diagnosis. The majority of the symptomatic patients note a decreased visual acuity at the time of presentation. Other presenting signs or symptoms include ptosis, eye lid swelling and diplopia. Often, the possibility of an inflammatory process is raised. An excision biopsy often confirms the seemingly improbable diagnosis of an orbital metastasis. Orbital metastases remain an unfavorable prognostic factor, but the diagnosis and treatment are still important in order to prevent loss of vision and improve the patient's quality of life. As previous studies have shown, the overall survival rate is still as limited as nearly half a century ago. Ocular metastases have become less rare since the systemic treatment with chemotherapy prolongs survival in patients with cancer.

Breast cancer is primary cancer the most frequently found in the case of orbital metastases (29-51%) (9). Lobular breast cancer represents the cancer subtype with the highest prevalence among orbital metastases. The high frequency of ILC in orbital metastases illustrates the special metastatic behavior of this tumor entity and may have implications for the understanding of the organotropism of metastatic lobular breast cancer (10).

We report the case of a patient who was discovered with orbital metastasis (OM) from an unknown breast cancer. This is a rare case of an orbital metastatic carcinoma preceding the diagnosis of a nonpalpable primary breast carcinoma.

The importance of emergency treatment for rapidly progressing lesions is stressed, as well as the need for detailed treatment planning to prevent possible damage to sensitive normal structures.

### Case Report

A 61-year-old woman presented with a history of gradually worsening blurred vision, periorbital swelling, pain and proptosis in the right eye. Magnetic resonance imaging (MRI) of the brain and orbits showed a diffuse abnormal enhancement involving the right orbit. (FIGURE 1).

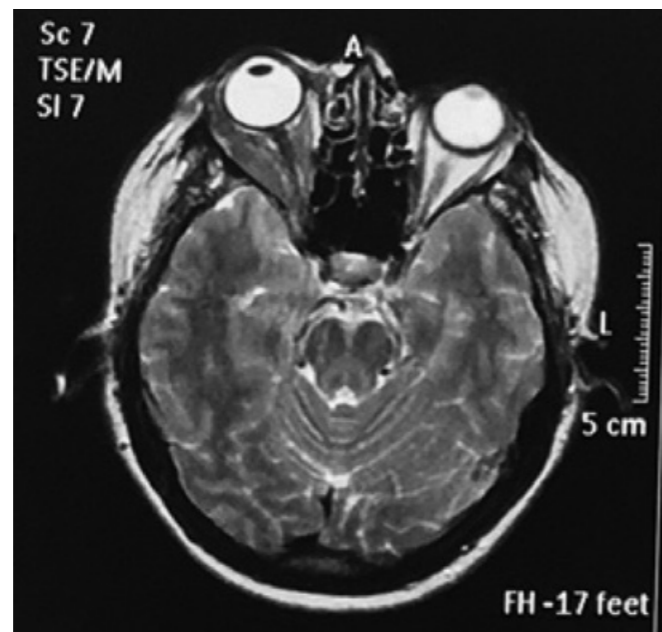


Fig. 1 Pre-operative MRI of the orbit

The initial pre-operative orbit MRI scans show abnormal hypointense thickening of the episcleral tissues and extraocular muscles. The orbital fat also shows diffuse abnormal T2 hypointensity.

The differential diagnosis included severe inflammatory response, pseudotumor, lymphoma, primary or metastatic neoplasia. The patient was referred to Division of Hematology to confirm a suspicion on lymphoma. The biopsy was submitted to the Ophthalmology Division where the possibility of lymphoma was excluded. Histologically, the biopsy demonstrated metastatic carcinoma of possible primary breast cancer estrogen receptor (ER) positive, progesterone receptor (PR) positive. The diagnosis of carcinoma was made; however, the site of origin of carcinoma was not yet determined. Chest and abdominal CT scan and mammography were negative. Since lymphoproliferative lesions are the most common primary orbital tumor in older adults ( $\geq 60$  years of age), representing a spectrum of disorders and radiologic examinations, do not allow reliable differentiation between benign and malignant lymphoproliferative disorders, hematologists indicated right enucleation. The surgical procedure was eventually carried out. The pathology report of the enucleated eyeball identified a microscopic focus of accumulated carcinoma cells (small cell carcinoma) in the sclera. While, the pathology report of the biopsed orbital masses demonstrated hypercellular population of small cells that interdigitate between collagen bundles in a single line, so-called "Indian file". On immunohistochemical stains, the tumor cells from the orbital mass tissue were positive for ER, S100, CKW, CK AE1/AE3 and Lysozim. These cells were negative for Plasma cell, Vimentin, TTF, PR, Melanoma, Melan A, LCA, SYN, Chromogranin, E-cadherin, CK 20, RCC, NSE and Actin. The findings were suggestive of metastatic lobular breast cancer. Post-operative MRI of the orbits demonstrated an expansile extraconal-intraconal mass that involved retrobulbar fat, eyelid, extraocular muscles, right nasolacrimal duct and right optic nerve (FIGURE 2).

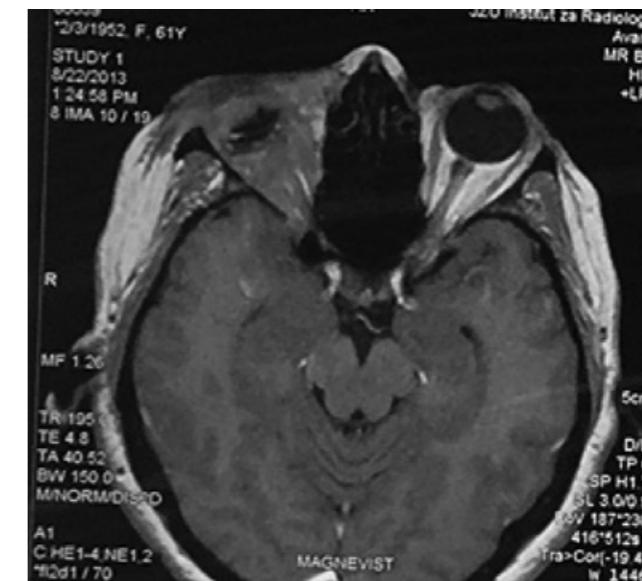


Fig. 2 Post-operative MRI of the orbit

Post-enucleation axial T1-weighted MR image demonstrates abnormal enhancement of the retrobulbar fat and extraocular muscles.

Post-operative chest CT scan revealed inhomogeneous loose tissue in left armpit. Cytological FNAB (fine needle aspiration biopsy) finding was negative for atypical cells. Some **forms of invasive lobular carcinoma (ILC) do not present with a palpable mass**, as ILC is less likely to be associated with a fibrous tissue reaction. No further diagnostic studies were taken to rule out primary breast cancer (MRI, digital tomosynthesis) or primary lung cancer (bronchoscopy).

We believe that variability in the diagnostic report provided by *pathologist* was probably due to the common *morphological features of the lobular carcinoma* and small cell carcinoma. Both tumor cell lines are small, *morphologically*. Tumor cell of lobular carcinoma tends to have a loss of expression of E-cadherin. Small cell cancer tumors usually express chromogranin A and synaptophysin in  $>50\%$  of the cell population. Small cell breast carcinoma is a very rare (the literature describes  $<40$  cases), yet highly aggressive variant of a neuroendocrine carcinoma. The first challenge in the proper diagnosis of small cell carcinoma of the breast is to determine whether it is breast primary, or whether it is in fact a 'secondary' site metastized from another cancer elsewhere in the body, (and the lung would be the first place to look). It is impossible to distinguish metastatic and primary small cell breast carcinomas on the basis of histological evaluation. Treatments by paclitaxel, cisplatin and etoposide have shown to be highly effective against the spread and recurrence of small cell breast carcinoma. Finally, based on the pathologist's examination and diagnostic radiology exams, first-line systemic chemotherapy of metastatic *extrapulmonary small cell carcinoma* was initiated using Cisplatin 75mg/m<sup>2</sup> and Paclitaxel 175mg/m<sup>2</sup> (x 6 cycles) and *sequential external beam radiotherapy*, particularly 3D conformal radiotherapy to the orbit to a cumulative dose of 3000 cGy.

One year after the initial diagnose, she was found a lump in the left breast and in the left underarm area. Based on the mammogram report and FNA cytology, she underwent through left *modified radical mastectomy* (*Histologic type: ILC, pTNM pT2 size of carcinoma 3.5cm pN3 19/19 extranodal extension G3 L1 Stage IIIC, hormone receptor status ER 3+ 95%, PR – 5% Her2/neu 2+, SISH negative, Ki 67 1+ 15%, p53 – 5%*) and was started with hormone therapy with aromatase inhibitor. The post-radiation MRI of the orbits demonstrated almost complete radiologic response (FIGURE 3).

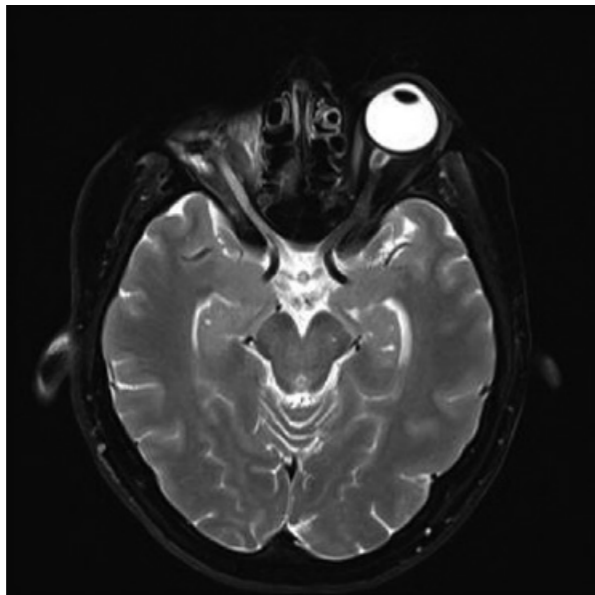


Fig. 3 Post-radiation MRI of the orbit

Axial T2- weighted MR image shows almost complete resolution of the mass on the right.

On a follow-up visit 36 months after her breast surgery, she was disease free. Three months later, computed tomography of the abdomen revealed features of both small and large bowel obstruction with moderate ascites, left *hydronephrosis with ureteral obstruction and gastric wall thickening*. Arrangements for palliation were made. A ileostomy was performed. She passed away 4 years after her initial orbital manifestation.

## Discussion

Orbital metastasis is relatively uncommon. In general, patients with metastatic disease do not develop orbital metastases, being identified clinically in less than 1% of cases. Orbital symptoms occur well before local symptoms from the primary tumour manifestation, and as such are the first indicators of advanced malignancy (11,12). In contrast to IDC metastasis to the CNS, which tends to form metastatic masses in the brain parenchyma, ILC that metastasizes to the CNS has

a strikingly high propensity to spread diffusely along the leptomeninges. Diffuse infiltrative enhancing soft tissue, replacing the postseptal fat or connective tissue, often accompanies the abnormally enhancing extraocular muscles. This diffuse infiltrative expansile process often causes proptosis. The Tenon capsule, sclera, and eyelid soft tissue may also be involved (13-16).

Common tumours that have a predilection to metastasise to the orbit include breast cancer, bronchogenic cancer, prostate cancer, gastrointestinal adenocarcinoma, thyroid carcinoma, renal cell carcinoma, neuroblastoma, Ewing sarcoma and Wilms tumour (9,10,11,12,17,18). Out of all metastatic tumors to the orbit, breast carcinoma is considered to be the most prevalent primary tumor, accounting for 29% to 70% of all metastases (17). It is possible that the actual frequency of breast cancer orbital metastases is much higher than that indicated in the published series. Metastatic involvement of ocular structures in breast cancer seems to be a rare clinical entity. Nevertheless, autopsy histopathological inquiries propose that 10-37% of patients with breast cancer have detectable ocular or orbital metastasis (19). Still, many breast cancer orbital metastases remain subclinical and are never diagnosed (20).

Infiltrating lobular breast cancer is a special breast cancer subtype. It accounts for 10–15% of all mammary carcinomas and for ~1% of all malignancies (21). ILCs display a distinct histomorphology and they are almost always estrogen receptor (ER) positive (22). The absence of the PR in luminal subtypes of breast cancer has a higher risk of relapse and lower disease-free survival (23,24). This is partly due to increase in hormone resistance among PR negative breast cancers (25). PR negative lobular carcinoma confers a particularly poor response to hormonal therapy, and thus, a worse prognosis. ILC growth is strongly dependent on estrogenic stimulation (26). The list of anatomical sites associated with ILC metastasis (ovaries, abdominal cavity, skin, bone) reads like a catalog of tissue compartments with a favorable steroid hormone supply. Estrogen concentrations are up to 1000-fold higher in ovarian tissue and peritoneal cavity fluid as compared with the body circulation (27). Moreover, estrogens are produced by mesenchymal cells of the dermis, adipose tissue and bone (28). Accordingly, ILCs seem to metastasize to sites of estrogen production. The most convincing case supporting this notion has been documented by Arnould et al. They have reported an ILC metastasis within an estrogen-producing granulosa cell tumor of the ovary, which had developed under tamoxifen therapy (29). There is indirect evidence that the orbital fat pad produces steroid hormones to regulate tear film composition (30,31). Alternatively, orbital metastasis from ILBC may simply extend to the orbit from nearby bone metastases or from occult meningeosis carcinomatosa. The mean interval from diagnosis of primary breast carcinoma to detection of orbital metastasis ranges from 4.5 to 6.5 years (32). After the diagnosis, the prognosis is poor: in fact the median survival is 31 months, the median is 19 months with a range of one to 116 months (33). Ocular metastasis can represent the initial manifestation of breast carcinoma, with up to 26% of orbital breast metastases presenting before the discovery of the primary tumor (34). The diagnosis of ocular metastases is based primarily on clinical findings supplemented by imaging studies (CT, MRI).

Orbital metastases originating from breast carcinoma predict widespread metastatic disease in other organs. Systemic treatment of metastatic breast cancer may include some form of hormone therapy and/or chemotherapy depending on the overall disease burden (35). Enucleation offers no advantage concerning disease progression or survival (32). Orbital surgery is primarily used for diagnostic rather than therapeutic purposes given that the disease is usually widespread at time of diagnosis and is not curative. In selected cases, tumor resection, even if incomplete, may be appropriate to improve symptoms of pain, diplopia, and proptosis. Treatment is primarily with radiotherapy, typically with a total dose of 20 - 40Gy (11). It is usually administered to control tumor growth, preserve visual function in the short term, decrease proptosis and exposure keratopathy, or to improve patient comfort (32).

### Conclusion

In summary, although rare, orbital metastasis can be the initial and sole presenting feature of breast cancer. It can occur in the presence of normal breast examination or negative mammogram. It can be misdiagnosed as orbital pseudotumour. Patients with ocular symptoms such as ptosis, proptosis, diplopia, pain, exophthalmus, biopsy and histopathological examination of the orbital lesion should be considered, particularly in elderly. This case demonstrates the importance of the possibility of dual pathology, which may lead to diagnostic confusion. The pattern of ILC metastasis emphasizes its presentation at unusual sites such as the leptomeninges and orbit. This knowledge may aid in accurate imaging interpretation and treatment planning in patients with metastatic ILC of the breast.

**Funding:** None.

**Ethical approval:** Not required.

**Declaration of authorship:** EL and SS drafted the manuscript and performed data collection and interpretation. EL and ZA conceived the study and made critical revision of the manuscript. VK, VK and MI made critical revision of the manuscript. All authors of this paper have read and approved the final version submitted.

**Competing interests:** All authors have completed the Unified Competing Interest Form at [www.icmje.org/coi\\_disclosure.pdf](http://www.icmje.org/coi_disclosure.pdf) (available upon request from the corresponding author) and declare: no support from any organization for the submitted work; no financial relationship with any organizations that might have an interest in the submitted work in the previous 3 years; no other relationship or activities that could appear to have influenced the submitted work.

### References

- Martinez V, Azzopardi JG. Invasive lobular carcinoma of the breast: incidence and variants. *Histopathology*. 1979; 3(6):467-88.
- Borst MJ, Ingold JA. Metastatic patterns of invasive lobular versus invasive ductal carcinoma of the breast. *Surgery*. 1993; 114(4):637-41.
- Harris M, Howell A, Chrissohou M, et al. A comparison of the metastatic pattern of infiltrating lobular carcinoma and infiltrating duct carcinoma of the breast. *Br J Cancer*. 1984; 50(1):23-30.
- Ferlicot S, Vincent-salomon A, Médioni J, et al. Wide metastatic spreading in infiltrating lobular carcinoma of the breast. *Eur J Cancer*. 2004; 40(3):336-41.
- Lamovec J, Bracko M. Metastatic pattern of infiltrating lobular carcinoma of the breast: an autopsy study. *J Surg Oncol*. 1991; 48(1):28-33.
- Winston CB, Hadar O, Teitcher JB, et al. Metastatic lobular carcinoma of the breast: patterns of spread in the chest, abdomen, and pelvis on CT. *AJR Am J Roentgenol*. 2000; 175(3):795-800.
- Arpino G, Bardou VJ, Clark GM, et al. Infiltrating lobular carcinoma of the breast: tumor characteristics and clinical outcome. *Breast Cancer Res*. 2004; 6(3):R149-56.
- Berg JW, Hutter RV. Breast cancer. *Cancer*. 1995; 75(1 Suppl):257-69.
- Cornelis F, Mejdoubi M, Dousset V. [Bilateral orbital extension of breast cancer metastasis]. *J Radiol*. 2007; 88(5 Pt 1):684-6.
- Raap M, Antonopoulos W, Dämmrich M, et al. High frequency of lobular breast cancer in distant metastases to the orbit. *Cancer Med*. 2015; 4(1):104-11.
- Char DH, Miller T, Kroll S. Orbital metastases: diagnosis and course. *Br J Ophthalmol*. 1997; 81(5):386-90.
- Green S, Som PM, Lavagnini PG. Bilateral orbital metastases from prostate carcinoma: case presentation and CT findings. *AJNR Am J Neuroradiol*. 1995; 16(2):417-9.
- Toller KK, Gigantelli JW, Spalding MJ. Bilateral orbital metastases from breast carcinoma. A case of false pseudotumor. *Ophthalmology*. 1998; 105(10):1897-901.
- Gupta S, Bhatt VR, Varma S. Unilateral orbital pain and eyelid swelling in a 46-year-old woman: orbital metastasis of occult invasive lobular carcinoma of breast masquerading orbital pseudotumour. *BMJ Case Rep*. 2011; 2011.
- Tomizawa Y, Ocque R, Ohori NP. Orbital metastasis as the initial presentation of invasive lobular carcinoma of breast. *Intern Med*. 2012; 51(12):1635-8.
- Zhang GJ, Adachi I, Yin DF, et al. Eyelid metastasis from breast cancer showing marked response to chemotherapy. *Jpn J Clin Oncol*. 1995; 25(1):10-5.
- Shields JA, Shields CL, Scartozzi R. Survey of 1264 patients with orbital tumors and simulating lesions: The 2002 Montgomery Lecture, part 1. *Ophthalmology*. 2004; 111(5):997-1008.
- Holland D, Maune S, Kovács G, et al. Metastatic tumors of the orbit: a retrospective study. *Orbit*. 2003; 22(1):15-24.

19. Merrill CF, Kaufman DI, Dimitrov NV. Breast cancer metastatic to the eye is a common entity. *Cancer*. 1991; 68(3):623-7.
20. Dieing A, Schulz CO, Schmid P, et al. Orbital metastases in breast cancer: report of two cases and review of the literature. *J Cancer Res Clin Oncol*. 2004; 130(12):745-8.
21. Weigelt B, Reis-filho JS. Histological and molecular types of breast cancer: is there a unifying taxonomy?. *Nat Rev Clin Oncol*. 2009; 6(12):718-30.
22. Walker RA, Hanby A, Pinder SE, et al. Current issues in diagnostic breast pathology. *J Clin Pathol*. 2012; 65(9):771-85.
23. Cancellato G, Maisonneuve P, Rotmensz N, et al. Progesterone receptor loss identifies Luminal B breast cancer subgroups at higher risk of relapse. *Ann Oncol*. 2013; 24(3):661-8.
24. Feeley LP, Mulligan AM, Pinnaduwege D, et al. Distinguishing luminal breast cancer subtypes by Ki67, progesterone receptor or TP53 status provides prognostic information. *Mod Pathol*. 2014; 27(4):554-61.
25. Linke SP, Bremer TM, Herold CD, et al. A multimarker model to predict outcome in tamoxifen-treated breast cancer patients. *Clin Cancer Res*. 2006; 12(4):1175-83.
26. Rakha EA, El-sayed ME, Powe DG, et al. Invasive lobular carcinoma of the breast: response to hormonal therapy and outcomes. *Eur J Cancer*. 2008; 44(1):73-83.
27. Koninckx PR, Kennedy SH, Barlow DH. Endometriotic disease: the role of peritoneal fluid. *Hum Reprod Update*. 1998; 4(5):741-51.
28. Simpson E, Rubin G, Clyne C, et al. Local estrogen biosynthesis in males and females. *Endocr Relat Cancer*. 1999; 6(2):131-7.
29. Arnould L, Franco N, Soubeyrand MS, et al. Breast carcinoma metastasis within granulosa cell tumor of the ovary: morphologic, immunohistologic, and molecular analyses of the two different tumor cell populations. *Hum Pathol*. 2002; 33(4):445-8.
30. Spelsberg H, Klueppel M, Reinhard T, et al. Detection of oestrogen receptors (ER) alpha and beta in conjunctiva, lacrimal gland, and tarsal plates. *Eye (Lond)*. 2004; 18(7):729-33.
31. Turaka K, Nottage JM, Hammersmith KM, et al. Dry eye syndrome in aromatase inhibitor users. *Clin Experiment Ophthalmol*. 2013; 41(3):239-43.
32. Ahmad SM, Esmali B. Metastatic tumors of the orbit and ocular adnexa. *Curr Opin Ophthalmol*. 2007; 18(5):405-13.
33. Garrity JA, Henderson JW, Cameron JD. Henderson's Orbital Tumors. 4th ed. New York, NY: Raven Press; 2007. Metastatic carcinomas; pp. 313-326.
34. Goldberg RA, Rootman J, Cline RA. Tumors metastatic to the orbit: a changing picture. *Surv Ophthalmol*. 1990; 35(1):1-24.
35. Wickremasinghe S, Dansingani KK, Tranos P, et al. Ocular presentations of breast cancer. *Acta Ophthalmol Scand*. 2007; 85(2):133-42.

## THE POST-CARDIAC INJURY SYNDROME: REVIEW OF THE LITERATURE

*Kostadinovska B<sup>1</sup>, Nikolic A<sup>1</sup>, Slaveski D<sup>1</sup>, Belostocki V<sup>1</sup>, Srbinovski J<sup>1</sup>, Mustafa E<sup>1</sup>, Mircevska E<sup>1</sup>, Dimishkov A<sup>1</sup>, Paunkoski I<sup>1</sup>*

*<sup>1</sup> Acibadem Sistina Hospital, Skopje, R.Macedonia*

### ABSTRACT

Post-cardiac injury syndrome (PCIS) includes the post-myocardial infarction syndrome (PMIS), postpericardiotomy syndrome (PPS), and post-traumatic pericarditis syndrome (either iatrogenic or not). PCIS is characterized by pleural chest pain, fever, leukocytosis, increased red cell sedimentation, abnormal x-rays of the chest and the presence of exudative pericardial and/or pleural effusions.

The exact etiology of the syndromes remains elusive although an immunopathic etiology appears to be the most acceptable triggered by initial damage to pericardial and/or pleural tissues. The immune-mediated pathogenesis is supported by a latent period generally of few weeks until the appearance of the first manifestations and the response to anti-inflammatory drugs (NSAIDs, corticosteroids, colchicine) with the possibility of recurrences. The most common complications associated with PCIS are cardiac tamponade and constrictive pericarditis. Furthermore, PCIS is associated with prolonged hospital stay, more readmissions and higher costs. In order to avoid these potential complications, as well as for the purpose of instituting appropriate therapy, it is important to recognize the syndrome in its early stages. In this review, we have summarized the current evidence on clinical significance, outcomes and management of postcardiac injury syndrome (PCIS) and its complications.

**Keywords:** Dressler's syndrome, postcardiac injury syndrome, postmyocardial infarction syndrome, postcardiotomy syndrome.

**Corresponding author:** *Beti Kostadinovska Jordanoska, Acibadem Sistina Hospital, Skopje, R.Macedonia. E-mail: betikj@yahoo.com.*

## Introduction

Postcardiac injury syndromes (PCIS) is an umbrella term indicating a group of inflammatory pericardial syndromes including post-myocardial infarction syndrome (PMIS), post-pericardiotomy syndrome (PPS) and post-traumatic pericarditis (either iatrogenic or not) (1). The exact etiology of the syndromes remains elusive although an immunopathic etiology appears to be most acceptable triggered by initial damage to pericardial and/or pleural tissues. The immune-mediated pathogenesis is supported by a latent period generally of few weeks until the appearance of the first manifestations and the response to anti-inflammatory drugs (NSAIDs, corticosteroids, colchicine) with the possibility of recurrences. The most common complications associated with PCIS are cardiac tamponade and constrictive pericarditis. Furthermore, PCIS is associated with prolonged hospital stay, more readmissions and higher costs (2). In order to avoid these potential complications, as well as for the purpose of instituting appropriate therapy, it is important to recognize the syndrome in its early stages. In this review, we have summarized current evidence on clinical significance, outcomes and management of postcardiac injury syndrome (PCIS) and its complications.

## Historical Background

Jahnton et al first described the postcardiac injury syndrome in 1952 in patients undergoing mitral valve commissurotomy (3). He referred to it as the post-commissurotomy syndrome and attributed the etiology to the reactivation of rheumatic fever. Later, Itoh in 1958 noted the same syndrome following various types of cardiac surgery and labeled the condition postpericardiotomy syndrome (4). He noted that the pericardium had to be entered in order for the syndrome to occur. Subsequently, others have confirmed Itoh's observations and the incidence of PCS have been variously described to range from 10-50% (10, 22). PMIS was first described by Dressler in 1956 with a lower incidence, less than 5% (5). Dressler syndrome has become rare with early reperfusion therapy of myocardial infarction; however, it may occur especially in cases of even minor bleeding into the pericardium.

## Post-myocardial Infarction Pericarditis

Following an acute myocardial infarction (AMI), three major pericardial complications may occur: pericardial effusion, early infarct-associated pericarditis (often called early post-infarction pericarditis, typically few days after AMI) and late pericarditis or post-cardiac injury (Dressler) syndrome (typically 1–2 weeks after AMI). Early post-infarction pericarditis usually occurs soon after the AMI and is transient. This complication is rare in the primary percutaneous coronary intervention era and it is especially related to late reperfusion or failed coronary reperfusion (6). Diagnostic criteria do not differ from those for acute pericarditis. ECG changes are usually overshadowed by changes due to the myocardial infarction. However, ST segments may remain elevated, with persistence of upright T waves, as T waves may become upright again after having been inverted. Echocardiography should be performed in patients suspected of having post-AMI

to evaluate for the presence of a pericardial effusion. Cardiac magnetic resonance (CMR) can be used to show the presence of concomitant pericardial inflammation. Patients with a post-AMI pericardial effusion >10 mm in thickness should be investigated for a possible sub acute rupture (8). The treatment is generally supportive, as most cases are self-limited. However, a minority of patients may have persistent symptoms that require more than supportive care. For these patients aspirin plus colchicine may be considered.

Late post-AMI pericarditis (Dressler syndrome) is rare (<1%) in the era of primary percutaneous coronary intervention and may reflect a larger size of AMI and/or late reperfusion (6). Diagnosis and treatment are similar to that generally recommended for PCIS.

Although pericarditis is associated with a larger infarct size, in-hospital and 1-year mortality and major adverse cardiac events were similar in patients with and without pericarditis. Timely primary percutaneous coronary intervention may reduce the occurrence of post-AMI pericarditis. Early post-AMI pericarditis remains a marker of larger infarct size, but without independent prognostic significance (6).

## Postpericardiotomy Syndrome

Postpericardiotomy syndrome (PPS) is a common complication that occurs days to months (usually 1–6 weeks) after surgical incision of the pericardium. Rarely, this syndrome has occurred after traumatic hemopericardium, a puncture of the cardiac or pleural structures, after percutaneous coronary intervention, or due to pacemaker or pacemaker wire placement. A consensual diagnostic criterion has been given based on two recent clinical trials (COPPS and COPPS-2), and diagnosis of PPS can be made if patients present with at least two of the following five clinical findings: fever without an obvious cause after the 1st postoperative week, pericardial friction rub, new or worsening pericardial effusion, pleuritic chest pain, and new or worsening pleural effusion (9). This entity has reported incidence that varies from 10% to 40% in various studies (10).

Early post-cardiac surgery pericardial effusion must be interpreted in the clinical context of the patient. They have been reported as asymptomatic in 22% of patients two weeks after cardiac surgery (11). The prognosis is good for mild effusions occurring in two out of three cases, but moderate to large effusions (one out of three) may progress to cardiac tamponade in ~10% of cases one month after cardiac surgery (11,12). Treatment of these asymptomatic effusions by diclofenac was shown to be useless in the Post-Operative Pericardial Effusion (POPE) trial and may be associated with an increased risk of side effects related to NSAID use (13). In contrast, cardiac tamponade occurring in the first hours after cardiac surgery is usually due to hemorrhage in the pericardial space, and surgical reintervention is mandatory in this situation.

## Traumatic Pericardial Effusion and Haemopericardium

Any cardiac intervention (e.g. percutaneous coronary intervention, pacemaker lead insertion, radiofrequency ablation) may be responsible for haemopericardium and cardiac tamponade due



to coronary or cardiac chamber perforation. Pericardial effusion induced by trauma is included in more expanded concept of PCIS (1). However, in the event of overt chest trauma complicated by cardiac tamponade, the magnitude of the trauma is the main cause of the syndrome. Diagnosis includes the presence of a prior history of chest trauma as a trigger for the syndrome plus the signs and symptoms of pericarditis (i.e. chest pain, pericardial rub, dyspnoea, low-grade fever) and markers of inflammatory reaction (i.e. elevated CRP, leucocytosis, ESR). ECG is normally used to rule out AMI as a possible cause of pericarditis. Chest X-ray may help to detect cardiomegaly and pleural effusions. Transthoracic echocardiography is used to detect the presence, size and haemodynamic importance of the pericardial effusion. A recent randomized trial demonstrated that the use of limited transthoracic echocardiography improved the time from the trauma bay to the operating room and reduced the mortality rate (14).

Therefore, the treatment differs according to the severity of the syndrome. For those with post-traumatic pericarditis with no haemodynamic compromise, the treatment is essentially based on empirical anti-inflammatory therapy and adjunctive colchicine, which has been shown to be safe and efficacious for the prevention of pericarditis (15). For those life-threatening cases of penetrating trauma to the heart and chest, the emergency thoracotomy is recommended to improve survival as opposed to the classic strategy of initial pericardiocentesis as a bridge to surgery (16, 17). This is usually done through left anterolateral thoracotomy that makes pericardiotomy possible with effective relief of cardiac tamponade and direct cardiac massage if needed.

In the setting of aortic dissection with haemopericardium and suspicion of cardiac tamponade, the emergency transthoracic echocardiography or a CT scan should be performed to confirm the diagnosis. In such a scenario, the controlled pericardial drainage of very small amounts of the haemopericardium can be attempted to temporarily stabilize the patient in order to maintain blood pressure at ~90 mmHg. (18)

### Pathogenesis

Present evidence supports an immunopathic etiology for PCIS. The clinical course also appears to support this etiology, which is the latent period between myocardial injury and the onset of the syndrome, the disappearance of pericarditis and pulmonary manifestations spontaneously or following therapy with steroids or nonsteroidals and relapse in some cases upon withdrawal of steroids.

Lessof has proposed the following hypothesis: Myocardial injury from infarction, surgery, or trauma leads to the release of cardiac antigens in the circulation (19). This process may be aided by viral infection or reactivation or by the presence of blood in the pericardial space. The subsequent events depend on the amount of antigen levels. If the circulating antigen level is low, no immune complexes are formed. However, if the levels are high, circulating immune complexes are formed. These complexes get deposited in the pleura, lungs, pericardium, joints, etc., provoking inflammatory changes similar to other immune complex diseases. Subsequently, with

antibody excess, circulating immune complexes are cleared by the reticuloendothelial system with regression of the syndrome. Pinckard et al. demonstrated the presence of anti heart antibodies in animals about 10 days after experimental myocardial infarction produced by coronary artery ligation of microsphere injection (20).

In a review on the subject of immunological aspects of cardiac disorders, Roberts and Lessof noted that anti-heart antibody titers were much higher in post infarction and post cardiac surgery patients who developed the syndrome, than in those without the syndrome (21).

Study from Belgium, De Scheerder et al. prospectively studied 162 patients undergoing coronary artery bypass surgery (22). They measured preoperative and serial, 1 to 60 days post-operative titers of actin and myosin antibodies by an enzyme-linked immunoabsorbent assay. They also prospectively evaluated patients clinically for the subsequent development of post-cardiotomy syndrome. The postoperative to preoperative ratio of actin and myosin antibodies was high in 8 (13%) and these patients developed all the preset criteria of PCS which included fever, pericarditis, and laboratory evidence of inflammation (i.e. complete picture); 16 (26%) of the patients develop some, but not all of the features of PCS (i.e. incomplete picture), and the remaining 38 (74%) had low levels of the ratio with no features of PCS. The correlation between the clinical features and the immunologic results was significant ( $p < 0.001$ ). These two carefully done prospective studies clearly indicate that antibodies against cardiac muscle are elevated in patients with PCS, and that there is a good correlation between the clinically detected PCIS and the development of anti-heart antibody titers.

### Predisposing Factors for PCIS

- **Viral Infection**

Epidemiologic studies indicate that there is a seasonal variation in PCS, being the highest at the time of the increased prevalence of viral infection in the community.

Engle et al. have demonstrated elevated viral titers and, as noted above, anti-heart antibodies in patients with PCS suggesting that viruses may have a contributing role in the etiology of PCS (23).

In a prospective study of 150 patients with apparent viral infection of the upper respiratory tract, Spodick demonstrated the occurrence of myopericarditis and Q-wave infarction (24). This association of probable viral infection and myocardial infarction may also hold true for PMIS. However, viruses have not been isolated from the pericardial or pleural effusion in patients with PCIS.

- **Miscellaneous Risk Factors**

In a large prospective epidemiologic study, Miller et al. (25) identified several risk factors that predispose a cardiac surgery patient to the PCS. These include young age, prior history of pericarditis, prior treatment with prednisone, blood type B negative, and halothane anesthesia. Lehnto et al (9) demonstrated that patients with younger age and blood transfusion have an

increased risk, whereas diabetics have a lower risk of developing this entity. Knowledge of these factors should help one to be vigilant for the early detection of PCS in the appropriate clinical setting (e.g. persistent or de novo fever or chest pain in a postcardiac surgery patient).

## Diagnosis

The diagnosis of PCIS is based principally on clinical grounds. Patients with PCIS present with fever without alternative cause, leukocytosis, high erythrocyte sedimentation rate, pleuritic chest pain, friction rub, evidence of new or worsening pleural effusion with elevated CRP, and evidence of new or worsening pericardial effusion.

Sometimes it is difficult to differentiate PCIS from the simple mechanical consequences of surgery (such as pericardial or pleural effusion). The demonstration of inflammatory activity should be essential to establish the diagnosis. Basic diagnostic evaluation of a patient with a suspected PCIS includes physical examination, supporting laboratory, ECG, chest X-ray and echocardiography (1, 26). Echocardiography may provide evidence of pericardial effusion. Analysis of pericardial or pleural fluid is helpful in excluding other potential etiologies. Immunologic studies are currently available only for research purposes.

## Complications

- Cardiac Tamponade

The incidence of tamponade is better documented in PCS and ranges from 0.1 to 6% (26, 27). In a prospective study of 1290 patients undergoing open heart surgery, 10 patients (0.8%) developed tamponade; all were diagnosed to have PCS (27). One patient was receiving sodium warfarin and two were receiving aspirin. Nine were treated with pericardiocentesis and one required pericardial stripping for recurrent tamponade. There were no deaths.

In another study of 150 patients undergoing cardiac surgery, effusion was noted in 115 (77%) patients, but was significant in 43 (29%) (28). In the 33 cases of suspected PCS in this study, effusion did not worsen with sodium warfarin or dipyridamole therapy. Only one patient developed tamponade five days postoperatively and this patient was not on anticoagulant therapy. The authors did not state whether this patient had PCS, but given the fact that tamponade occurred very early in the course, PCS was a most unlikely diagnosis in this patient.

Similarly, tamponade is rare in PMIS and may occur with or without concomitant anticoagulant therapy (29, 30). What advice could one give regarding the use of anticoagulation in the face of PCIS (or, for that matter, pericardial effusion from any cause)? It would appear that anticoagulation may be continued safely in the most cases provided that these patients are observed closely. On the other hand, because of the small but real danger of tamponade, anticoagulation in this setting should be confined to high-risk patients (e.g. prosthetic valve, large myocardial infarction especially anterior, and patients with atrial fibrillation).

- Constrictive Pericarditis

Constrictive pericarditis is characterized by impaired diastolic filling of the ventricles due to pericardial disease. The classic clinical picture is characterized by signs and symptoms of right heart failure with preserved right and left ventricular function in the absence of previous or concomitant myocardial disease or advanced forms. Patients complain about fatigue, peripheral oedema, breathlessness and abdominal swelling. A diagnosis of constrictive pericarditis is based on the association of signs and symptoms of right heart failure and impaired diastolic filling due to pericardial constriction by one or more imaging methods, including echocardiography, CT, CMR and cardiac catheterization. Constrictive pericarditis develops in 2-3% of patients undergoing cardiac surgery (31). It usually develops late after surgery (3-56 months) and has manifestations of dyspnea and right-sided heart failure. It is thought that pooling of blood after surgery in pericardial sac, inflammation and development of fibrosis can cause the thickening and adhesions in pericardium.

One of the earliest series of cases with constrictive pericarditis after cardiac surgery and its treatment was described by Killian et al. (32). Their study included 45 patients with median age of 61 years, majority of them (33 patients) underwent coronary bypass surgery (CABG), among them 4 patients had history of two or more surgeries. Constrictive pericarditis developed during median 23 months (1-204 months) after surgery. Mean pericardial thickening on computed tomography was 0.8 mm. There were signs of inflammation, fibrosis and calcification of pericardium intraoperatively. Pericardial stripping (subtotal pericardiectomy) was performed in 37 patients and 8 patients were treated medically. Overall, 28 patients had symptomatic improvement after surgery, 4 patients underwent extensive pericardiectomy. Mortality rate after surgery was 11% - 4 patients died during 30 days after pericardiectomy.

The most recent series were reported from Cleveland Clinic (33). This prospective cohort study included 239 patients with PPS after cardiac surgery; primary endpoints of the study were development of effusion and constriction during follow-up of 12 months. Overall 75 patients (31%) required intervention: 44 patients with pericardial effusion and tamponade, including 22 patients who underwent pericardiocentesis and 24 – subxiphoid pericardiostomy with drainage, and 31 patients – pericardiectomy. Patients had increased levels of C-reactive protein and sedimentation rate, 14% of them had right heart failure and 31% - signs of constriction. Multivariable analysis demonstrated that constriction physiology as well as younger age and heart failure signs, increased risk of PPS and constriction development during follow-up by almost 6 times, while use of colchicine therapy and NSAIDs reduced risk of tamponade and constriction by 55% (HR – 0.45, 95%CI 0.26-0.79). In younger patients with PPS with signs of heart failure and constrictive physiology, early appropriate management seems to be warranted.

## Treatment

The most patients with PCIS respond to conservative measures which include the use of anti-inflammatory agent that may improve remission rates and reduce the risk of recurrences.

Horneffer PJ et al evaluate the effectiveness of nonsteroidal antiinflammatory drugs (NSAIDs) in the treatment of postpericardiotomy syndrome, in a double-blind, placebo-controlled randomized trial with a 10-day course of ibuprofen or indomethacin. The results of this study demonstrate that both ibuprofen and indomethacin provide safe and effective symptomatic treatment for postpericardiotomy syndrome (34).

NSAIDs are generally not indicated in asymptomatic post-surgical effusions, and this therapy may be associated with an increased risk of side effects related to NSAIDs (13).

Aspirin may be the next agent of choice for, given its established anti-inflammatory and antiplatelet effects for post-myocardial infarction pericarditis and those patients are already on antiplatelet therapies. The supplemental use of a codeine preparation may be necessary in some cases for added analgesic effect. Rare cases of tamponade especially in the setting of PCS are dealt with by pericardial drainage procedure.

Steroids have been employed successfully in the PCS, the PMIS-like syndrome associated with pulmonary infarction and in the PMIS. Several studies reported satisfactory results of treatment of effusive-constrictive pericarditis after cardiac surgery with steroids (35). It should be also noted that the usage of steroids might increase recurrence rate of effusions and complications of PPS (36).

Refractory cases of recurrent effusion or persistent pericardial pain may require pericardiectomy. Also, as noted above, rare cases of unstable angina in the setting of PCS and PMIS may be considered for surgical intervention.

## Prevention

Promising results have been reported for use of colchicine (37). In a COPPS double-blind randomized trial, 360 patients were allocated into 2 arms - 180 patients receiving placebo and 180 patients receiving colchicine - 1mg twice daily 1st day after surgery and then 0.5 mg twice daily 30 days after surgery in patients >70 kg and half dose for patients <70 kg. Follow-up period was 12 months. Primary endpoint was PPS, and secondary composite endpoint included re-hospitalization, constrictive pericarditis, tamponade and relapse of pericardial disease. Patients in colchicine arm developed less PPS (8.9% vs. 21.1%,  $p=0.002$ ) and had significantly fewer secondary composite endpoint (0.6% vs. 5.9%,  $p=0.024$ ). Side effects occurrence did not differ between both arms. Patients on colchicine therapy had significantly better survival free of PPS as compared to placebo group. Colchicine was found to be effective in prevention of PPS and its complications in patients undergoing cardiac surgery.

Recent meta-analysis (38) of 4 randomized controlled trials (894 pts) on prevention of PPS including 2 - colchicine studies, 1- methylprednisolone and 1 - aspirin demonstrated (Fig. 1) that colchicine (2 studies 227 pts) reduced development of PPS by 62% (OR- 0.38, 95% CI 0.22-0.65), while no effect was found for methylprednisolone or aspirin.

## Prognosis

Despite limited published data, the prognosis of PPS is generally good. (38) There are very few available data on other forms of post-pericardial injury syndromes. In the largest published series on PPS patients after cardiac surgery, (2) complication rates were low: <4% for recurrences, <2% for cardiac tamponade and no cases of constriction, although hospital stay may be prolonged in these patients. However, the development of constrictive pericarditis has been reported in ~3% of cases. (31, 39)

## References:

1. Imazio M Hoit BD. Post-cardiac injury syndromes. An emerging cause of pericardial diseases. *Int J Cardiol* 2013; 168:648–652.
2. Imazio M, Brucato A, Rovere ME et al. Contemporary features, risk factors, and prognosis of the postpericardiotomy syndrome. *Am J Cardiol* 2011; 108:1183–7.
3. Janton OH, Glover RP, O'Neill TJ et al. Results of the surgical treatment for mitral stenosis; analysis of one hundred consecutive cases. *Circulation* 1952; 6:321-33.
4. Ito T, Engle MA, Goldberg Hp: Post-pericardiotomy syndrome following surgery for non-rheumatic heart disease. *Circulation* 17,549 (1958).
5. Dressler W Post-myocardial infarction syndrome: Preliminary report of a complication resembling idiopathic, recurrent, benign pericarditis. *JAm MedAssoc* 160,1379 (1956).
6. Imazio M Negro A Belli R et al.. Frequency and prognostic significance of pericarditis following acute myocardial infarction treated by primary percutaneous coronary intervention. *Am J Cardiol* 2009; 103:1525–1529.
7. Doulaptsis C Goetschalckx K Masci PG et al. Assessment of early post-infarction pericardial injury using cardiac magnetic resonance (CMR). *JACC Cardiovasc Imaging* 2013;6:411–413.
8. Figueras J Barrabés JA Serra V et al. Hospital outcome of moderate to severe pericardial effusion complicating ST-elevation acute myocardial infarction. *Circulation* 2010;122:1902–1909.
9. Imazio M Brucato A Ferrazzi P et al. for the COPPS-2 Investigators. Colchicine for Prevention of Postpericardiotomy Syndrome and Postoperative Atrial Fibrillation. The COPPS-2 Randomized Clinical Trial. *JAMA* 2014;312:1016–1023.
10. Lehto J, Gunn J, Karjalainen P et al. Incidence and risk factors of postpericardiotomy syndrome requiring medical attention: The Finland postpericardiotomy syndrome study. *J Thorac Cardiovasc Surg* 2015;149:1324-9.
11. Meurin P Weber H Renaud N et al. Evolution of the postoperative pericardial effusion after day 15: the problem of the late tamponade. *Chest* 2004;125:2182–2187.
12. Tsang TS Enriquez-Sarano M Freeman WK et al. Consecutive 1127 therapeutic echocardiographically guided pericardiocenteses: clinical profile, practice patterns, and outcomes spanning 21 years. *Mayo Clin Proc* 2002;77:429–436.

13. Meurin P, Tabet JY, Thabut G et al. French Society of Cardiology. Nonsteroidal anti-inflammatory drug treatment for postoperative pericardial effusion: a multicenter randomized, double-blind trial. *Ann Intern Med* 2010;152:137–143.
14. Ferrada P, Evans D, Wolfe L et al. Findings of a randomized controlled trial using limited transthoracic echocardiogram (LTTE) as a hemodynamic monitoring tool in the trauma bay. *J Trauma Acute Care Surg* 2014;76:31–37.
15. Imazio M, Brucato A, Trincherio R et al. Colchicine for pericarditis: hype or hope? *Eur Heart J* 2009;30:532–539.
16. Lee TH, Ouellet JF, Cook M et al. Pericardiocentesis in trauma: a systematic review. *J Trauma Acute Care Surg* 2013;75:543–549.
17. ATLS Subcommittee, American College of Surgeons' Committee on Trauma, International ATLS Working Group. Advanced trauma life support (ATLS®): the ninth edition. *J Trauma Acute Care Surg* 2013;74:1363–1366.
18. Hayashi T, Tsukube T, Yamashita T et al. Impact of controlled pericardial drainage on critical cardiac tamponade with acute type A aortic dissection. *Circulation* 2012;126(11 Suppl 1):S97–S101.
19. Lessof MH: Postpericardiotomy syndrome: Pathogenesis and management. *Hosp Prac* 81 (1976).
20. Pinckard RN, Olson MS, O'Rourke RA et al. Development of complement-fixing 19s antiheart mitochondria antibody following myocardial infarction in dogs. *Circ Res* 29,276 (1971).
21. Roberts BM, Lessof MH: Immunological aspects of cardiovascular disorders. In *Progress in Cardiology* (Eds. Yu PN, Goodwin JF). Lea & Febiger, Philadelphia (1973) 31.
22. De Scheerder I, DeBuyzere M, Robbrecht J et al. Postoperative immunologic response against contractile proteins after coronary bypass surgery. *Br Heart J* 56,440 (1986).
23. Engle MA: Postpericardiotomy and allied syndromes. In *Pericardial Disease* (Ed. Reddy PS). Raven Press, New York(1982) 313.
24. Spodick DH: Infection and infarction: Acute viral (and other)infection in the onset, pathogenesis and mimicry of acute myocardial infarction. *Am J Med* 8 1,661 (1986)
25. Miller RH, Horneffer PJ, Gardner TJ et al. The epidemiology of post-pericardiotomy syndrome: A common complication of cardiac surgery. *Am Heart J* 116,1323 (1988).
26. Imazio M . The post-pericardiotomy syndrome. *Curr Opin Pulm Med* 2012;18:366–374.
27. Ofori-Kraykye SK, Tyberg TI, Geha AS et al. Late cardiac tamponade after open heart surgery: Incidence, role of anticoagulants in its pathogenesis and its relation to postcardiotomy syndrome. *Circulation* 63, 1323(1982).
28. Ikaheimo MJ, Huikuri HV, Airaksinen KEJ et al. Pericardial effusion after cardiac surgery: Incidence, relation to the type of surgery, antithrombotic therapy, and early coronary bypass graft patency. *Am Heart J* 116,97 (1988).
29. Lawrence MS, Wright R: Tamponade in Dressler's syndrome with immunological studies. *Br Med J* 1,655 (1972).
30. Prewitt JA: Cardiac tamponade as a late complication of open heart surgery. *Am Heart J* 76,139 (1968).
31. Gaudino M, Anselmi A, Pavone N et al. Constrictive pericarditis after cardiac surgery. *Ann Thorac Surg* 2013; 95: 731–6.
32. Killian DM, Furiassi JG, Scanlon PG, et al. Constrictive pericarditis after cardiac surgery. *Am Heart J* 1989;118: 563-8.
33. Alraies MC, Al Jaroudi W, Shabrang C, et al. Clinical features associated with adverse events in patients with post-pericardiotomy syndrome following cardiac surgery. *Am J Cardiol* 2014; 114: 1426.
34. Horneffer PJ, Miller RH, Pearson et al. The effective treatment of postpericardiotomy syndrome after cardiac operations. A randomized placebo-controlled trial. *J Thorac Cardiovasc Surg* 1990;100:292–296.
35. Kutcher MA, King SB 3rd, Alimurung BN, et al. Constrictive pericarditis as a complication of cardiac surgery: recognition of an entity. *Am J Cardiol* 1992; 50: 742-8.
36. . Van Osch D, Dieleman JM, Nathoe HM, et al. Intraoperative high-dose dexamethasone and the risk of re-thoracotomy. *Ann Thorac Surg* 2015; 100: 2237-42.
37. Imazio M, Trincherio R, Brucato A, et al.; on behalf of the COPPS Investigators. Colchicine for the Prevention of the Post-pericardiotomy Syndrome (COPPS): a multicentre, randomized, double-blind, placebo-controlled trial. *Eur Heart J* 2010; 31: 2749–54.
38. Imazio M, Brucato A, Markel G, et al. Meta-analysis of randomized trials focusing on prevention of the postpericardiotomy syndrome. *Am J Cardiol* 2011; 108: 575–9.
39. Imazio M, Brucato A, Maestroni S et al. Risk of constrictive pericarditis after acute pericarditis. *Circulation* 2011;124:1270–1275.

## EVALUATION OF ANALGESIA, SEDATION AND AGITATION IN INTENSIVE CARE UNIT

Trojikj T<sup>1</sup>

<sup>1</sup> University Clinic for Surgery "St. Naum Ohridski", Skopje, Macedonia

### ABSTRACT

Most of the patients in the intensive care unit need sedation and analgesia in order to avoid pain, anxiety and to be able to have invasive procedures, mechanical ventilation and to reduce stress and oxygen consumption. Untreated patient increases stress response to invasive procedures such as intubation and central venous catheterization. The pain is the most common memory from intensive care unit and that can lead to agitation accidental extubation and removal of intravascular devices. Very often, patients in the intensive care are over sedated and that can prolong time of mechanical ventilation. Maintenance of light sedation, sufficient analgesia, early recognition and treatment of delirium, are imperatives in patients in the intensive care units. The Behavior Pain Scale (BPS), Richmond Agitation –Sedation Scale (RASS), Sedation Agitation Scale (SAS), Ramsey Sedation Scale are valid and reliable sedation assessment tools for measuring quality and depth of sedation in adults in ICU patients. Confusion Assessment Method (CAM) for the ICU as tool for early recognition of delirium is necessity for early and adequate treatment of delirium. Treatments according to these assessments of pain, sedation, agitation and delirium should be usual practice in intensive care unit. Protocols from literature and other hospitals may be initiative for preventing, prolonged sedation, ventilation and length of stay in intensive care unit.

**Key words:** agitation, critically ill patient, sedation.

**Corresponding author:** Tatjana Trojikj, University Clinic of Surgery "St. Naum Ohridski", Skopje, Macedonia. E-mail: tanja.trojik@gmail.com

### Assessment of Pain in the Intensive Care Unit

Intensive care unit patients are not homogenous group of patients. However, all of them have sympathetic stress response due to increased endogenous catecholamine activity. Most of them are in pain during the whole period of intensive treatment. Pain and evaluation of pain is essential in treatment of these patients. In 35% to 55% ICU patients pain was underrate, furthermore 64% of ICU patients have procedures without receiving drugs for pain relief (1,2,3). The pain increases myocardial workload, which can lead to myocardial ischemia, or to splinting, atelectasis, and a cascade of events that in turn can lead to pneumonia (4). Pain and anxiety lead to agitation and delirium. This may also lead to significant physical and psychological stress, and long-term consequences (posttraumatic stress disorder (PTSD) and delirium). Analgesia and sedation, are administered to provide patient's comfort, safety by decreasing the stress response. Sometime patients in the ICU are oversedated. And that leads to prolongation of mechanical ventilation, greater need for radiological evaluations of mental status and developing brain dysfunction (5, 6). In order to avoid prolongation in ICU with all negative effects there must be a balance of analgesic and sedative drug administration. In order to have calm patient with adequate analgesia, we have to try to evaluate the pain. Which scale we should use depends on whether we have communicative or non-communicative patient. Numeric pain scale (NPS) is used to evaluate pain in communicative patient. In this scale 0 indicates that patient has no pain and 10 is the indicator that patient has worst pain that he has ever experienced. Most of the patients in ICU are unable to use this scale because they are on mechanical ventilation, sedated and even paralyzed from neuromuscular relaxants. Many patients are comatose or suffer from cognitive disorder. In these patients we have to focus on observation on behavioral and physiological indicators. In non-communicative patients, scales for evaluation of pain were developed from pediatric patients, newborns, and nonverbal toddlers etc., who were unable verbally to express pain. The first Adult Non-Verbal Pain Scale is modification of FLACC (face, leg, activity, cry, consol ability scale). In these days the most used scale for pain assessment is The Behavior Pain Scale (BPS), based on a sum score of three items: facial expression, movements of upper limbs, and compliance with mechanical ventilation. Each pain indicator is scored from 1 (no response) to 4 (full response) with maximum score of 12. Scores of each three domains are summed, with a total score from 3 to 12.

**Table 1.** Behavior Pain Scale (BPS)

Item	Description	Score
Facial expression	Relaxed	1
	Partially tightened (for example, brow lowering)	2
	Fully tightened (for example, eyelid closing)	3
Upper limbs	Grimacing	4
	No movement	1
	Partially bent	2
	Fully bent with finger flexion	3
	Permanently retracted	4

Compliance with ventilation	Tolerating movement	1
	Coughing but tolerating ventilation for most of the time	2
	Fighting ventilator	3
	Unable to control ventilation	4

Management of the pain in the intensive care unit include regional and systematic analgesic therapy. In the ICU, these regional techniques likely have higher risk of failure, infection, bleeding, neuronal injury, pneumothorax, and hemodynamic compromise due to the patients critical illness and therefore they should only be performed by specially trained clinicians. Systemic therapies include acetaminophen and nonsteroidal anti-inflammatory drugs such as ketorolac, but the most commonly used analgesics in the ICU are opioids secondary to their analgesic and sedative properties. Negative effects of use of systematic pain therapy are: respiratory depression which is commonly seen and often enhanced by co-administration of additional sedative agents; and hypotension results from decreased sympathetic tone or vasodilation from histamine release. Other side effects are: decreased gastrointestinal motility, pruritus, flushing, urinary retention and delirium. Nonopioid analgesics should be considered for treatment of low acuity pain or as adjuncts to decrease opioid and to preserve mental status and pulmonary function. Morphine and hydromorphone are most often utilized as intermittent intravenous (IV) injections. Morphine dose is 2–5 mg IV every 5–15 minutes until the pain is controlled, followed by similar doses every 2–4 hours. Effects can be prolonged in patients with renal or hepatic impairment or obesity.

Fentanyl is a synthetic opioid with a rapid onset (5–15 minutes) and a short duration of action (30–60 minutes). Loading doses of 25–100 µg of fentanyl are given every 5–10 minutes until the pain is controlled, followed by infusion rates of 25–250 µg/h. It has a large volume of distribution, so significant drug accumulation and a prolonged half-life can occur with prolonged infusions. Fentanyl is the preferred opioid analgesic in hemodynamically unstable patients or those with renal insufficiency (1).

Remifentanyl, a derivative of fentanyl, is an opioid that is utilized primarily as an infusion (0.05–2.00 µg/kg/min) and has an elimination half-life of less than 10 minutes regardless of the infusion duration. Dosing for the infusion should be based on ideal body weight or lean body mass, and hypotension and bradycardia are the most common side effects. Due to its ultra-short half-life, supplemental analgesic medications are required. Remifentanyl provides better outcomes than morphine with regards to time at optimal arousal level, necessity of supplemental sedation, duration of mechanical ventilation, and extubation time in one randomized double blind study (7). Meanwhile, remifentanyl and fentanyl have displayed equal efficacy in achieving sedation goals with no difference in extubation times. Patients receiving fentanyl required more breakthrough sedatives, but experienced less pain after extubation compared to the patients receiving remifentanyl.

Sedation is necessary in intensive care patients. It facilitates mechanical ventilation, diminishes anxiety, leads to amnesia, and prevents self-mutilation, insomnia, and dyspnea. The appropriate

use of sedatives can facilitate patient care and contribute to patient's safety. Sometimes, appropriate sedation prevents psychiatric disorders delirium and leads to better cooperation with patient's family who likes to see that patient is peaceful and doesn't suffer.

However, the use of sedation is associated with negative patient outcomes, including prolonged mechanical ventilation and cognitive dysfunction (9,10,11). It is important, therefore, to define the indication for sedation, as this may affect the sedative selection and helps determine the endpoint for sedative utilization. There are many scales which are used to provide goal directed therapy individualized to the patient. When used appropriate, these scales can provide a therapeutic target, which can lead to decreased dosing of sedative medications and decreased time on mechanical ventilation (12). The most common sedative medications used within the ICU are propofol, dexmedetomidine and benzodiazepines, with other agents such as clonidine, ketamine, volatile anesthetics and neuromuscular blockers used as adjunct therapies. Importantly, the duration of sedative medication administration has shown to correlate with the duration of mechanical ventilation and the consistent theme throughout many sedation studies is that efforts should be made to minimize the total dose of sedative by using the minimum effective dose, daily interruption of sedation, and infusions for the shortest time required (13,14). Furthermore, there is increasing literature that favors the avoidance of benzodiazepines for sedation in the ICU in favor of propofol, dexmedetomidine or analgosedation regimens. Propofol is a diisopropylphenol anesthetic and a  $\gamma$ -aminobutyric acid (GABA) agonist. It has rapid onset (1–2 minutes) and short duration of action (2–8 minutes). It is typically given as a bolus injection of 40–100 mg IV, followed by an infusion of 25–75 µg/kg/min. Its volume of distribution is large with a short distribution half-life. Propofol side effects include hypotension due to vasodilation and myocardial depression, respiratory depression and hypertriglyceridemia. The hypertriglyceridemia may either be due to the intralipid carrier or altered hepatic lipid metabolism, which can be seen with the propofol infusion syndrome (PRIS) (15). PRIS is associated with increased dosage of propofol (doses >75 µg/kg/min or >5 mg/kg/h), pediatric sedation, critical illness, and prolonged infusions (>48 hours) and is characterized by severe lactic acidosis and rhabdomyolysis.

**Table 2.** Richmond agitation sedation scale

Score	Term	Description
+4	Combative	Overtly combative or violent, immediate danger to staff
+3	Very agitated	Pulls on or removes tubes or catheters or exhibits aggressive behavior toward staff
+2	Agitated	Frequent nonpurposeful movement or patient-ventilator dyssynchrony
+1	Restless	Anxious or apprehensive but movements not aggressive or vigorous
0	Alert and calm	
-1	Drowsy	Not fully alert, but has sustained (>10 seconds) awakening, with eye contact, to voice
-2	Light sedation	Briefly (<10 seconds) awakens with eye contact to voice
-3	Moderate sedation	Any movement (but no eye contact) to voice
-4	Deep sedation	No response to voice, but movement to physical stimulation
-5	Unarousable	No response to voice or physical stimulation

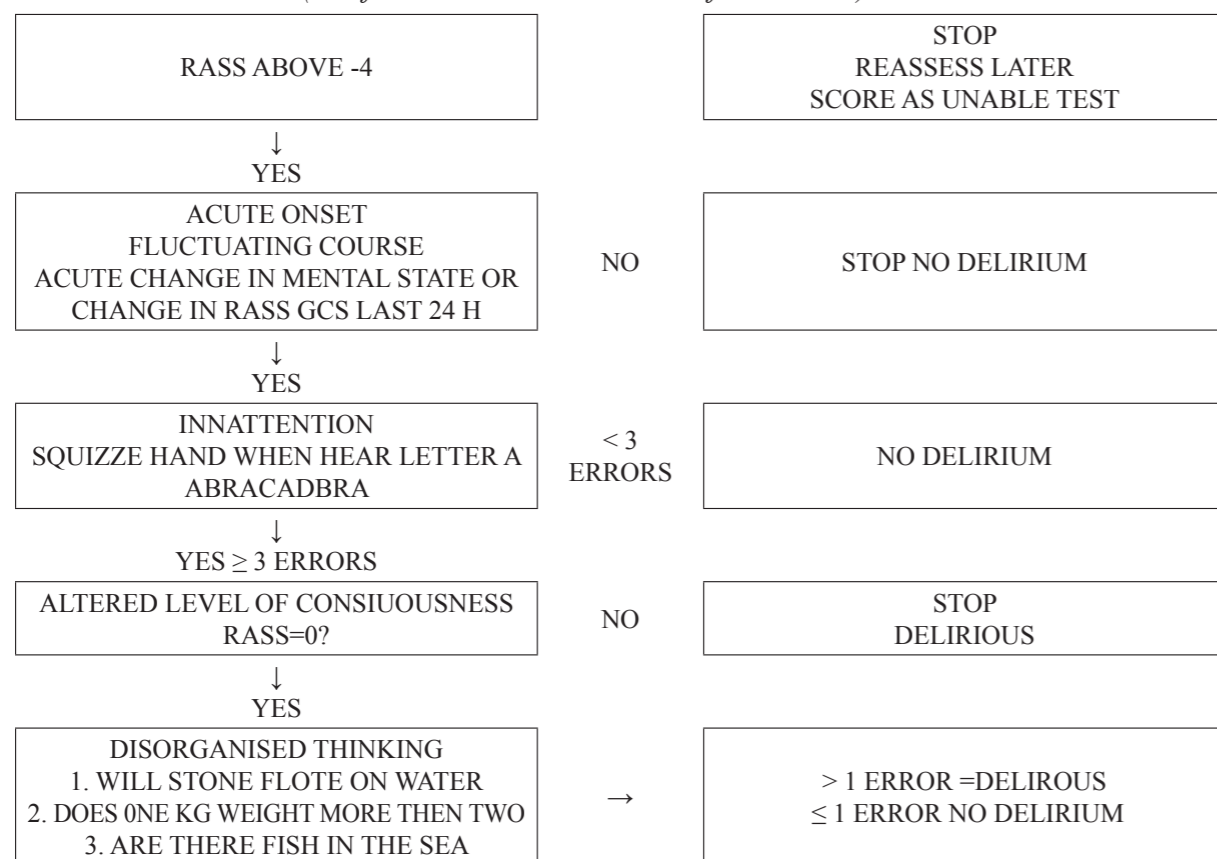
**Table 3. Ramsey scale**

Response	Level
Awake and anxious, agitated, or restless	1
Awake, cooperative, accepting ventilation, oriented, or tranquil	2
Awake, responds only to commands	3
Asleep, brisk response to light, glabella tap or loud noise	4

**Table 4. Sedation agitation scale**

Score	State	Behaviors
7	Dangerous-agitation	Pulling ET tube, climbing over bedrail, striking at staff thrashing side to side
6	Very agitated	Does not calm despite frequent verbal remaining, requires physical restrains
5	Agitated	Anxious or mildly agitated attempting to sit up, calms down to verbal instructions
4	Calm and cooperative	Calm awakens easily, follows commands
3	Sedated	Difficult to arouse, awakens to verbal stimuli or gentle shaking but drifts off
2	Very sedated	Arouse to physical stimuli but does not communicate or follow commands
1	Unarousable	Minimal or no response to noxious stimuli, does not communicate or follow commands

**Table 5. CAM in ICU (Confusion Assessment Method for the ICU)**



**Delirium in Intensive Care Unit**

Delirium is an acute fluctuating change in mental status. It is characterized by inattention and altered levels of consciousness. Delirium now is considered to be a presentation of brain organ dysfunction. Patients in ICU suffer up to 80% from some form of delirium (hyperactive, hypoactive or mixed form) and it can lead to long-term cognitive dysfunction.

The pathogenesis of delirium is not fully appreciated, and there are many proposed hypotheses including inflammatory changes, impaired oxidative metabolism, neurotransmitter disturbances, and alterations in amino acid precursors (16-18).

Delirium occurs when there is impaired pattern of sending and receiving signals from the brain.

Delirium is associated with the use of sedative medications and contributes to increased mortality, morbidity, hospital length of stay.

The presence of delirium is evaluated by Confusion Assessment Method for the ICU. Early recognition and early treatment are essential for patients in delirium. Haloperidol (Haldol) 2-5mg per os or intravenous every 8h. If patients are older than 60 years then the dose is 0,5 -2mg every 8 hours. Maximum dose is 20 mg. Olanzapine can be used in delirium 5 mg per os in 24 hours or in patients older than 60 years 2,5 mg in 24 hours.

**Conclusion:**

Evaluating pain mental status, level of sedation, is imperative for treatment of patients in the intensive care unit (ICU). There are many protocols for sedation and analgesia in the intensive care unit (18-20). Namigar et al. made compression of Richmond and Ramsey scale for sedation in critically ill patients in order to prevent over sedation and complication of sedation (21). Curtis N Sessler and Wolfram Wilhelm were evaluating the long-term effects of analgesic and sedative drug management on neuropsychological function in recovering period (22). Elliott R, McKinley S, Aitken LM, Hendrikz J. evaluated the effect of sedation on prolonged mechanical ventilation (23). Sedation and treatment of delirium is evaluated in pediatric patients as well (24, 25). In all these articles there is necessity for exact protocols for sedation. In Cochran library there is an article by Aitken and coworkers whether protocol directed sedation has better results in diminishing the duration of mechanical ventilation in intensive care patients (26). However, the necessity of evaluating the sedation pain and delirium by numerous scales, is evident (27-29). Everyday implementation of these scales should be routine among doctors residents and nurses in the intensive care units.

## References

1. Hamill-Ruth RJ, Marohn ML. Evaluation of pain in the critically ill patient. *Crit Care Clin.* 1999;15:35–54. doi: 10.1016/S0749-0704(05)70038.
2. Puntillo KA. Pain experiences of intensive care unit patients. *Heart Lung.* 1990;19:526–533.
3. Puntillo K. From Theory to Practice: Preventing Pain After Cardiac Surgery *Am J Crit Care* March 1, 2003 12:136-143 *Am J Crit Care.* 1997;6:259–260.
4. Kapfhammer HP, Rothenhausler HB, Krauseneck T, et al. Posttraumatic stress disorder and health-related quality of life in long-term survivors of acute respiratory distress syndrome. *Am J Psychiatry.* 2004;161(1):45–52.
5. Agarwal V, O'Neill PJ, Cotton BA, et al. Prevalence and risk factors for development of delirium in burn intensive care unit patients. *J Burn Care Res.* 2010;31.
6. Watson PL, Shintani AK, Tyson R, et al. Presence of electroencephalogram burst suppression in sedated, critically ill patients is associated with increased mortality. *Crit Care Med.* 2008;36(12):3171–3177.
7. Dahaba AA, Grabner T, Rehak PH, et al. Remifentanyl versus morphine analgesia and sedation for mechanically ventilated critically ill patients: a randomized double-blind study. *Anesthesiology.* 2004;101(3):640–646.
8. Muellejans B, López A, Cross MH, et al. Remifentanyl versus fentanyl for analgesia based sedation to provide patient comfort in the intensive care unit: a randomized, double-blind controlled trial [ISRCTN43755713].
9. Kollef MH, Levy NT, Ahrens TS, et al. The use of continuous i.v. sedation is associated with prolongation of mechanical ventilation. *Chest.* 1998; 114(2):541–548.
10. Pandharipande P, Shintani A, Peterson J, et al. Lorazepam is an independent risk factor for transitioning to delirium in intensive care unit patients. *Anesthesiology.* 2006;104(1):21–26.
11. Nelson BJ, Weinert CR, Bury CL, et al. Intensive care unit drug use and subsequent quality of life in acute lung injury patients. *Crit Care Med.* 2000; 28(11):3626–3630.
12. Botha JA, Mudholkar P. The effect of a sedation scale on ventilation hours, sedative, analgesic and inotropic use in an intensive care unit. *Crit Care Resusc.* 2004;6(4):253–257.
13. Kollef MH, Levy NT, Ahrens TS, et al. The use of continuous i.v. sedation is associated with prolongation of mechanical ventilation. *Chest.* 1998; 114(2):541–548.
14. Kress JP, Pohlman AS, O'Connor MF, et al. Daily interruption of sedative infusions in critically ill patients undergoing mechanical ventilation. *N Engl J Med.* 2000;342(20):1471–1477.
15. Diedrich DA, Brown DR. Analytic reviews: propofol infusion syndrome in the ICU. *J Intensive Care Med.* 2011;26(2):59–72.
16. Cerejeira J, Firmino H, Vaz-Serra A, et al. The neuroinflammatory hypothesis of delirium. *Acta Neuropathol.* 2010;119(6):737–754.
17. Hsieh TT, Fong TG, Marcantonio ER, et al. Cholinergic deficiency hypothesis in delirium: a synthesis of current evidence. *J Gerontol A Biol Sci Med Sci.* 2008;63(7):764–772.
18. Babamohamadi, Hassan and Tangestani, et al. (2017) Effect of a sedation guideline on the duration of mechanical ventilation and length of stay in intensive care unit. *Koomesh.* pp. 380-390.
19. Kayir S, Ulusoy H, Dogan G. The Effect of Daily Sedation-Weaning Application on Morbidity and Mortality in Intensive Care Unit Patients. Muacevic A, Adler JR, eds. *Cureus.* 2018;10(1):e2062. doi:10.7759/cureus.2062.
20. Sessler CN, Wilhelm W. Analgesia and sedation in the intensive care unit: an overview of the issues. *Critical Care.* 2008;12(Suppl 3):S1. doi:10.1186/cc6147.
21. Namigar, Turgut, et al. “The correlation among the Ramsay sedation scale, Richmond agitation sedation scale and Riker sedation agitation scale during midazolam-remifentanyl sedation.” *Brazilian Journal of Anesthesiology (English Edition)* 67.4 (2017): 347-354.
22. Sessler CN, Wilhelm W. Analgesia and sedation in the intensive care unit: an overview of the issues. *Critical Care.* 2008;12(Suppl 3):S1. doi:10.1186/cc6147.
23. Elliott R, McKinley S, Aitken LM, et al. The effect of an algorithm-based sedation guideline on the duration of mechanical ventilation in an Australian intensive care unit. *Intensive Care Medicine*2006;**32**(10):1506-14.
24. Keogh SJ, Long DA, Horn DV Practice guidelines for sedation and analgesia management of critically ill children: a pilot study evaluating guideline impact and feasibility in the PICU *BMJ Open* 2015.
25. Stephen D. Playfor; Analgesia and sedation in critically ill children, *Continuing Education in Anaesthesia Critical Care & Pain*, Volume 8, Issue 3, 1 June 2008, Pages 90–94.
26. Aitken LM, Bucknall T, Kent B, et al. Protocol-directed sedation versus non-protocol-directed sedation to reduce duration of mechanical ventilation in mechanically ventilated intensive care patients. *Cochrane Database of Systematic Reviews* 2015, Issue 1. Art. No.: CD009771. DOI: 10.1002/14651858.CD009771.pub2.6.
27. Pandharipande PP, Morandi A, Adams JR, et al. Plasma tryptophan and tyrosine levels are independent risk factors for delirium in critically ill patients. *Intensive Care Med.* 2009.
28. Brook AD, Ahrens TS, Schaiff R, et al. Effect of a nursing-implemented sedation protocol on the duration of mechanical ventilation. *Critical Care Medicine*1999.
29. Bucknall TK, Manias E, Presneill JJ. A randomized trial of protocol-directed sedation management for mechanical ventilation in an Australian intensive care unit. *Critical Care Medicine* 2008;36(5):1444-50.



## ПРОЦЕНА НА АНАЛГЕЗИЈА, СЕДАЦИЈА И АГИТАЦИЈА ВО ЕДИНИЦИТЕ ЗА ИНТЕНЗИВНО ЛЕКУВАЊЕ

### АПСТРАКТ

Најголем број на пациенти во одделот на интензивно лекување имаат потреба од седација и аналгезија за да избегне болка, анксиозност и за да можат полесно да ги поднесат инвазивните процедури на кои се секојдневно изложени, како на пример механичка вентилација, поставување на централен венски катетер итн. Пациентите кои не се доволно аналгезирани имаат зголемен стрес одговор, зголемена потрошувачка на кислород и најчесто лекувањето го памтат по постојаната болка на која биле изложени. Кај недоволно аналгезираните и седирани пациенти почеста е инциденцата на екстубација, вадење на централен венски катетер, венски канили. Друга крајност се пациентите кои се премногу седирани, па со тоа им се продолжува периодот на механичка вентилација и самиот престој во единиците за интензивно лекување. Одржувањето на лесна седација, раното познавање на состојбите на агитираност и делириум се императив во современото интензивно лекување. Скалите за проценка на болка, седација агитираност, Behavior Pain Scale (BPS), Richmond Agitation –Sedation scale (RASS), Sedation Agitation Scale(SAS), Ramsey Sedation Scale се корисна алатка за проценка на аналгезијата, седацијата и агитираноста. Делириумот се проценува со Confusion Assessment Method (CAM), кој овозможува рано препознавање на делириумот, негово рано третирање и избегнување на долготрајните последици. Третман на болните соодветно на процената на скалите за болка, седација, агитираност и делириум водат до создавање на протоколи со чијашто помош се превенира прекумерната седација, пролонгираната механичка вентилација и се намалува престојот во единиците на интензивно лекување.

## EIGHT YEARS OF HEMODIALYSIS WITH TUNNELED DIALYSIS CATHETER PLACED IN RIGHT VENTRICLE: A CASE REPORT

Mikjunovikj Lj<sup>1</sup>, Srceva M<sup>1</sup>, Kokareva A<sup>1</sup>, Donev Lj<sup>1</sup>

<sup>1</sup> University Clinic for Anesthesia, Reanimation and Intensive Care, Skopje, R. Macedonia

### Background

Long-term hemodialysis has been provided the best by arteriovenous fistulae and arteriovenous grafts. In recent years, more and more patients have been chronically dialyzed with tunneled dialysis catheters. These catheters, that were originally developed as a short-term bridge to permanent vascular access, have made up an increasing percentage of maintenance vascular access (1). Tunneled dialysis catheters (TDCs) are associated with the highest rate of complications, morbidity, and mortality when compared to arteriovenous fistulas or grafts, and this relates to higher costs in their management. Over time, catheters are prone to higher rates of infection, thrombosis, and central venous stenosis, and, thereby, catheter dysfunction. The central venous catheter (CVC), which is associated with higher morbidity and mortality, could be the only viable option to maintain permanent VA.

### Case Report

We report an unusual complication in a patient, a 63-year-old female, who had been undergoing HD via a TDC for 8 years (since 2009 two Tesio catheters were placed through right subclavian vein). Due to dysfunction of the catheters, a new catheter was installed through the left subclavian vein. Initial chest X-ray after, reported uneventful place of the tunneled right subclavian dialysis lines. The tip of one of the right catheters was located close to the basal segment of the right ventricle, near the interventricular septum. The patient was asymptomatic and there were no significant changes on ECG. Also there was local inflammation of the right breast. The patient was brought to our clinic for surgical removal of the catheters.

### Discussion

The preferred vascular access for hemodialysis is the arteriovenous fistula (AVF), with its high blood flow rate, and the lowest infection and clotting problems. The arteriovenous graft (AVG) is the next preferred access, with blood flow rate comparable to the AVF. Despite the perils associated with dialysis catheters, their use has increased to almost 80% incident dialysis initiation with catheters

(2). Tunneled dialysis catheters (TDCs) are associated with the highest rate of complications, morbidity, and mortality when compared to AVFs or AVGs, and this relates to higher costs in their management (2). Over time, catheters are prone to higher rates of infection, thrombosis, and central venous stenosis. Lower blood flow rates are consequence of the thrombosis and stenosis. The dialysis catheter that is used for long-term dialysis is universally tunneled under the skin for a segment of few inches and is called a TDC. The internal jugular vein is the preferred vein for cannulation, followed by the external jugular and femoral vein (2). The subclavian vein should be absolutely avoided because of its higher rates of stenosis (60–70%). These complications can be immediate or delayed in nature. Immediate complications occur at the time of catheter insertion and include vascular, cardiac, pulmonary, and placement complications. Delayed complications include device dysfunction and infection. Cardiac complications during catheter placement include arrhythmia (premature atrial and ventricular contractions) and cardiac arrest. Probably underreported in the literature, direct valvular (particularly tricuspid) injuries would rarely require intervention as even severe tricuspid regurgitation can be managed medically. Likewise, right ventricular perforations with pulmonary artery catheters can occur and result in life-threatening tamponade. In our case, not only the position of the catheter, but also the duration of its use is rare. There are few prospective studies where TDCs are an alternative for chronic use (86% for 1 year and 79% for 2 years use) (3).

### Learning Points

TDCs are primarily used for temporary access. It is important to understand that the complications of infection and dysfunction are a vicious cycle and are often interrelated. Thrombosis and fibrin sheaths both enhance central CRB by providing an interface for adherence and colonization. If the catheter is used as a bridge until the patient gets a fistula, it should be ensured that the patient gets the AVF or AVG placed as soon as possible and when usable, the catheter should be taken out. But TDC may be a very useful alternative permanent vascular access for hemodialysis patients when other forms of vascular access are not available.

**Corresponding author:** Ljubica Michunovic, Clinic for Anesthesia Reanimation and Intensive Care, Vodnjanska br 17, 1000 Skopje. tel: +38978 208 840, email: bubemicun@yahoo.com

### References

1. Hilleman D, Campbell J. Efficacy, safety, and cost of thrombolytic agents for the management of dysfunctional hemodialysis catheters: a systematic review. *Pharmacotherapy*. 2011 Oct;31(10):1031-40.
2. Vats HS. Complications of catheters: Tunneled and nontunneled. *Adv Chronic Kidney Dis*. 2012;19:188–94.
3. Quarello F, Forneris G, Borca M, et al. Do central venous catheters have advantages over arteriovenous fistulas or grafts? 2006 May-Jun;19(3):265-79.

## THE INFLUENCE OF ANESTHESIA IN INTRACAVITARY BRACHYTHERAPY IN LOCALLY ADVANCED CERVICAL CANCER - SINGLE INSTITUTIONAL EXPERIENCE

Klisarovska V<sup>1</sup>, Smichkoska S<sup>2</sup>, Krstevska V<sup>3</sup>, Lazareva E<sup>2</sup>

<sup>1</sup> Department of Gynecologic Oncology, University Clinic of Radiotherapy and Oncology, Skopje, Republic of Macedonia

<sup>2</sup> Department of Breast Cancer, University Clinic of Radiotherapy and Oncology, Skopje, Republic of Macedonia

<sup>3</sup> Department of Head and Neck Cancer, University Clinic of Radiotherapy and Oncology, Skopje, Republic of Macedonia

### ABSTRACT

Brachytherapy is important and potentially curative treatment for patients with inoperable locally advanced cervical cancer. Depending on the local findings the radioactive source application can cause serious discomfort to the patient, anxiety, followed by pain. Some patients experienced severe uterine pain. In selected patients, anesthesiological assessment and support is of great importance, because this is a way to realize the treatment. Because of that the anesthesiologist is a vital member of the brachytherapy team. Anesthesiologists play a key role in the ongoing challenge to provide safe and pain-free conditions for an optimum brachytherapy treatment effect.

**Disclosure:** No potential conflicts of interest were disclosed.

**Key words:** anesthesia, analgesia, brachytherapy, cervical cancer.

**\*Corresponding author at:** Department of Gynecologic Oncology, University Clinic of Radiotherapy and Oncology, Mother Theresa 17, 1000, Skopje, Republic of Macedonia. Phone: +389 71 331 335. E-mail address: vikiklisarovska@yahoo.com

## Brachytherapy Meaning

Cervical cancer is commonly treated with radiotherapy and brachytherapy which is an essential component of treatment. Brachytherapy (brachy = short, therapy = treatment) is a placement of radioactive sources within the body cavities such as the uterus and vagina [intracavitary brachytherapy (ICBT)]. The Brachytherapy department within the University Clinic of Radiotherapy and Oncology, Skopje is the only center of this type in the country, but it is also considered a regional center, having in mind that patients from nearby neighboring countries are also treated here. Anesthesiological support for low dose rate cervical brachytherapy was obligatory part to all applications, due to the need to dilate the cervical canal and the placement of applicators with a larger diameter than the cervix. Our centre stopped its low dose rate cervical brachytherapy program and developed a new protocol and new processes for high dose rate (HDR) brachytherapy in May 2005. Since then it is important and potentially curative treatment for patients with inoperable locally advanced cervical cancer, who have long survival. It allows an extremely high dose of radiation to be received by the tumor, with relative sparing of the surrounding tissues (normal structures). The standard ICBT application consists of insertion of a central tandem applicator in the uterine cavity (through the cervical canal) and ring applicator in the vagina (along the egzocervix). (Image 1) Anesthesiological support for HDR cervical brachytherapy wasn't obligatory part, because thin 3 mm tandem applicator can often be inserted without anesthesia. HDR ICBT is completed within minutes and applicators are removed within 2 hours after the applicator insertion, but the procedure requires 3 fractions (one weekly). Cervix cancer brachytherapy is a painful invasive procedure for some of the patients that can cause significant discomfort to the patient, anxiety, followed by more or less pain. Some patients experienced severe uterine pain.

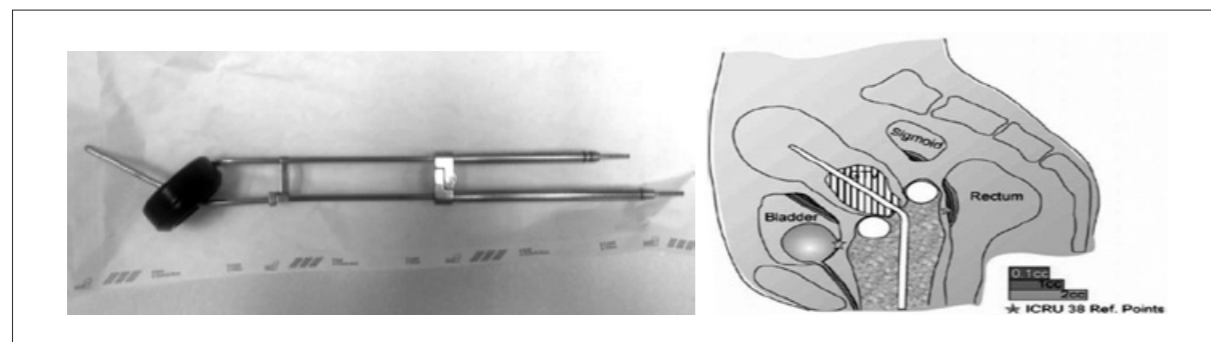


Image 1: Tandem-ring applicators

## Type of Pain

The cause of considerable discomfort is multifactorial. The presence of applicators in the body of the uterus stimulates sympathetic autonomic afferents which enter the spinal cord at the T10-L1 level. This produces poorly localized, central, lower abdominal pain, sometimes associated with nausea and vomiting. Distension of the cervix and upper vagina stimulates parasympathetic autonomic afferents from the pelvic splanchnic nerves of S2-4 to cause lower back pain. Vaginal packing through the labia stimulates somatic afferents via the pudendal nerves of S2-4 (1).

Because of that type of pain different centers choose different methods of anesthesia and analgesia, from general anesthesia, spinal anesthesia, paracervical block and conscious sedation (2,3). The aim is to provide good analgesia (painlessness) and muscle relaxation. More importantly, it allows better placement of the applicators and better vaginal tamponade, which fixes the position of the applicators, and achieved distancing of the bladder and rectum (as organs of risk) from the applicator's active length (4). Because of that the anesthesiologist is a vital member of the brachytherapy team. The optimal anesthetic technique has not been recognized by published data. In practice, general anesthesia and spinal anesthesia are preferred (5,6).

## Anaesthesia Modalities

Anesthesia during HDR brachytherapy for cervical cancer is not well reported in the literature, and the modalities used in practice vary greatly. The literature on analgesia and anesthesia in brachytherapy has increased over the last years but is still limited. There is discussion of the ideal way to provide both analgesia and immobilization (7,8,9). General considerations have been published recently in a review on analgesia for pelvic brachytherapy, where the options of anesthesia techniques in this field are discussed (10,11). According to the American Brachytherapy Society, HDR brachytherapy for carcinoma of the cervix should utilize conscious sedation whenever possible (4). Lower complication rates with conscious sedation as opposed to general anesthetic during HDR brachytherapy of the cervix have also been reported (3,6).

Lim et al (3), showed the complications related to different methods of anesthesia (general anesthesia, topical anesthesia and sedation, paracervical nerve block and conscious sedation) using the Common Toxicity Criteria. General anesthesia has significantly more complications than other methods, spinal or conscious sedation (3).

In most centers, HDR brachytherapy to the cervix uteri is given in 3-6 fractions once or twice weekly (10). Fractionation of the treatment increases the risk of complications from anesthesia (e.g., cardiovascular, respiratory, and neurological complications) and cervical dilatation (e.g., laceration of the cervix, bleeding, and uterine perforation). The cervix needs to be dilated to allow the insertion of the intra-uterine tube (tandem - applicator), which can be a painful procedure, and therefore for patients' comfort, we would recommend that patients receive either regional or general anesthetic. It was long assumed that the use of anesthesia allowed more optimal vaginal packing, which in turn would decrease the dose to organs at risk. However, in the pre-image guided brachytherapy era, one retrospective study showed that dosimetry was not significantly affected whether patients have an anesthetic (spinal or general anesthesia) or not (9). The mean dose to the bladder reference point was not significantly different either, but the mean dose to rectal reference point was significantly higher in the anesthetic group.

A large retrospective review over 5.5 years was carried out in Vienna. It analyzed the different techniques of anesthesia in 1622 brachytherapy procedures, primarily spinal versus general anesthesia. Spinal anesthesia was preferred in patients with pelvic malignancy (5).

A small series of 34 patients in Japan received a sacral epidural anesthesia prior to full insertional brachytherapy and self-reported pain on a numeric scale (range 0-10, with 0 = no pain and 10 = severe pain). This showed, compared to patients treated at the same institution without any analgesia, the pain score that was significantly lower with the epidural anesthesia, without any complications (11).

According to other authors, one of the theoretical concerns of regional anesthesia is that it could lead to cervical tumors becoming more hypoxic, and therefore reduce the efficacy of brachytherapy. However, a study of 10 patients showed that there was no significant difference in intra-tumoral  $pO_2$  levels before and during spinal anesthesia for cervical brachytherapy (12).

The high volume centers of developing countries are the most suitable candidates to use conscious sedation to perform ICRT to treat more cancer cervix patients in same time frame. Application with general anesthesia takes more time per patient, which must be considered due to the waiting lists.

Various techniques of anesthesia have been described for ICBT for cervical cancer. Each technique has its own advantage and some disadvantages also. In general, the indications and risks to patients receiving anesthesia for brachytherapy are similar to other procedures and established pre- and post-procedural instructions should be given and explained to all patients (13).

### Single Institutional Experience

The purpose of this review is to report our small initial clinical experience of performing HDR ICBT for cervix cancer with general anesthesia in an outpatient setting. We want to show the importance of anesthesia for selected patients, for pain control and establishment of application conditions, during using tandem - ring applicators.

### Selecting patients

At the Brachytherapy Department within the University Clinic of Radiotherapy and Oncology, Skopje, brachytherapy under conditions of short-term general anesthesia is not the standard treatment. This is usually an outpatient procedure and usually does not require anesthesia. It is applied to selected patients, in cases where there are difficult conditions due to local active disease, in cases with vaginal stenosis, when the patient cannot tolerate a speculum exam, radiation fibrosis, or in pain hypersensitive patients.

### Anesthesia support

In the selected patients, anesthesiological assessment and support are of great importance, because it is unable to realize the application without anesthesia. This is a way to deliver the treatment. We cooperate with the University *Clinic for Anesthesia, Reanimation and Intensive Care*, Skopje. The decision about the type of anesthesia, the application and the dose of drugs, as well as the overall anesthesiological support is the complete decision and responsibility of the anesthesiologist. Always it is adjusted according to the individual behavior of the patient.

### Treatment protocol

The selected patients day before application have a pre-anesthetic assessment. Anesthesiology assessment includes anamnesis and physical examination, with an evaluation of breathing, blood pressure, heart function, complete laboratory analysis. In terms of the present co-morbidity of the patient additional examinations are made. On the day of the brachytherapy, patients were fasting for six to eight hours prior to anesthesia. No premedications were given.

The radiation oncology team comprised of the radiation oncologist, anesthesiologist and medical nurse. The anesthesiologist administered all intravenous drugs, combination of sedative drugs - midazolam and propofol, and each of them is often coupled with fentanyl and oxycodone to provide analgesia. The medical nurse performed physiologic monitoring on the patient's blood pressure, heart rate, respiratory rate, and pulse oximeter. (Image 2) The radiation oncologist makes an utero-vaginal brachytherapy application.

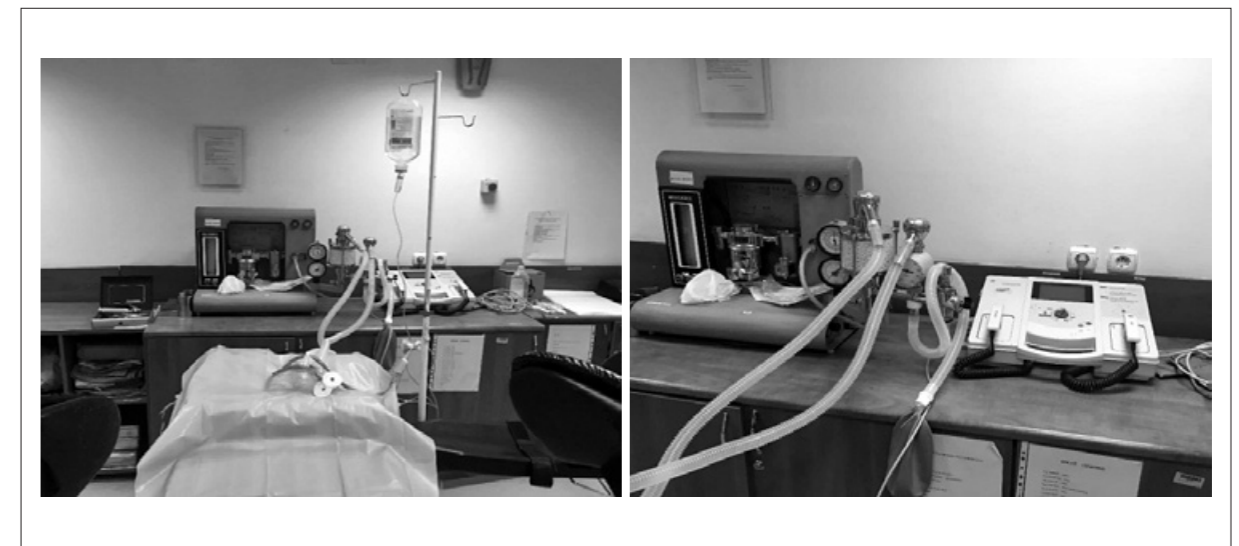

Image 2: Anesthesia technical support

### Utero-vaginal application technique

Foley's catheter was inserted, filled with 7ccm contrast and fixed against the bladder neck. CT compatible tandem-ring applicators were used for HDR ICBT. After the applicators were inserted, they were stabilized, and rectum and bladder were set apart from the applicators with vaginal gauze packing. Only for 2D planning rectal marker was placed deeply in the rectum to visualize it. (Image 3) When the application is finished, the patient wakes up and is fully aware for a short time. After that all patients underwent 2D or 3D - CT simulation and returned to the operating room (brachytherapy bunker - image 4) without fear of applicators displacement, because of special transport tabletop. When dosimetric planning was completed, we delivered brachytherapy using a remote after-loader device (Varian, GammaMedPlus) with Iridium 192. Once the prescribed dose was delivered, we removed the applicators and the Foley catheter.

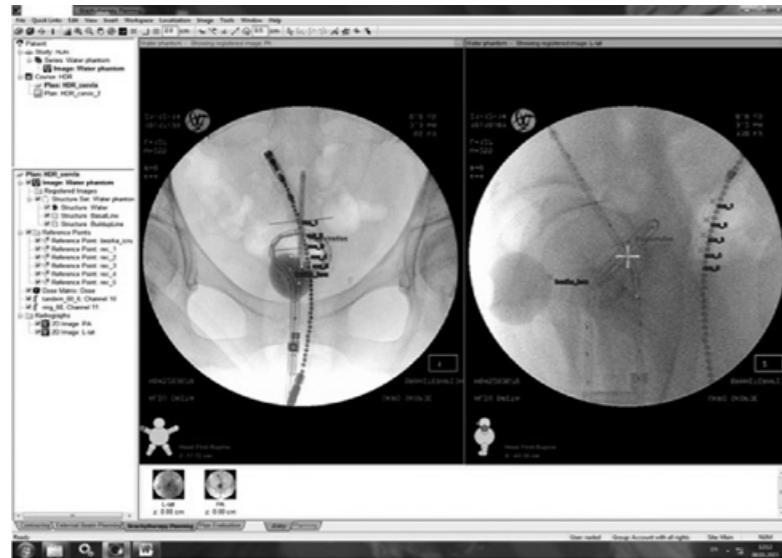


Image 3: Orthographic images with applicators

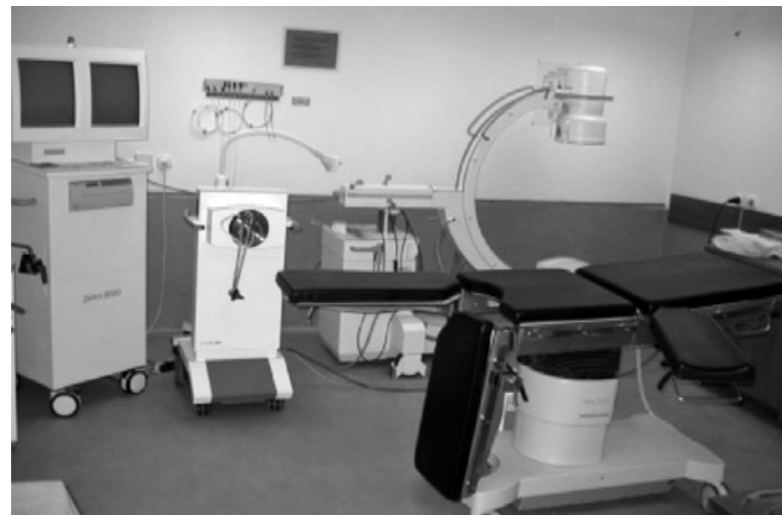

Image 4: Brachytherapy treatment room

The experiences with general anesthesia in intracavitary brachytherapy are satisfying, without any problem or post-anesthesia complications. We observed good analgesic effects for all insertions. During the procedure adequate sedation and good pain relief, without compromised patients' safety was received. There was no adverse effect encountered during the procedure and we did not experience any peri-procedural morbidity or complication.

We must keep in mind the few limitations to this report. It was small number of patients and the fact that we didn't evaluate patients' experience, such as fear and anxiety. We didn't explore women's experiences of pain and distress over a series of three HDR brachytherapy procedures given for cervical cancer. And of course, we have no experience with other anesthetic techniques, which are different from general anesthesia. This is a motive for deepening the further cooperation with anesthesiologists and implementing new anesthetic techniques, which according to literature are less aggressive.

## Conclusion

In selected patients, anesthesia is of great importance as an opportunity for brachytherapy application. The choice of anesthesiology technique remains open, as a decision of each center, primarily from anesthesiologists. For the brachytherapist the most important are the conditions that provide a successful brachytherapy application. Anesthesiologists play a key role in the ongoing challenge to provide safe and pain-free conditions for an optimum brachytherapy treatment effect. Outpatient combined ICBT for cervix cancer with general anesthesia is feasible and safe. But, further investigation of risks and benefits of anesthetic management in brachytherapy is required.

**Funding:** None.

**Ethical approval:** Not required.

**Declaration of authorship:** EL and SS drafted the manuscript and performed data collection and interpretation. EL and ZA conceived the study and made critical revision of the manuscript. VK, VK and MI made critical revision of the manuscript. All authors of this paper have read and approved the final version submitted.

**Competing interests:** All authors have completed the Unified Competing Interest form at [www.icmje.org/coi\\_disclosure.pdf](http://www.icmje.org/coi_disclosure.pdf) (available on request from the corresponding author) and declare: no support from any organization for the submitted work; no financial relationships with any organizations that might have an interest in the submitted work in the previous 3 years; no other relationships or activities that could appear to have influenced the submitted work.

## References

1. Kwekkeboom KL, Dendaas NR, Straub M, et al. Patterns of pain and distress during high-dose-rate intracavitary brachytherapy for cervical cancer. *J Support Oncol*. 2009;7:108–14.
2. Smith MD, Todd JG, Symonds RP. Analgesia for pelvic brachytherapy. *Br J Anaesth* 2002;88: 270-276.
3. Lim KH, Lu JJ, Wynne CJ, et al. A study of complications arising from different methods of anesthesia used in high-dose-rate brachytherapy for cervical cancer. *Am J Clin Oncol* 2004; 27:449–451.
4. Nag S, Erickson B, Thomadsen B, et al. The American brachytherapy society recommendations for high-dose-rate brachytherapy for carcinoma of the cervix. *Int J Radiat Oncol Biol Phys* 2000;48:201–211.
5. Benrath J, Kozek-Langenecker S, Hupfl M, et al. Anaesthesia for brachytherapy - 5 1/2 yr of experience in 1622 procedures. *Br J Anaesth* 2006;96:195-200.
6. Leong YH, Hock Soon Tan K, Chao BA, et al. Novel anesthetic technique for combined intracavitary and interstitial brachytherapy for cervix cancer in an outpatient setting. *J Contemp Brachyther* 2017;3:236-241.
7. Smith MD, Todd JG, Symonds RP. Analgesia for pelvic brachytherapy. *Br J Anaesth* 2002; 88: 270–6.
8. Appadurai IR, Hanna L. Analgesia for pelvic brachytherapy. *Br J Anaesth* 2002; 89:342-342.
9. Sharma DN, Chaudhari P, Sharma S, et al. Comparison of high-dose-rate intracavitary brachytherapy dosimetry with and without anesthesia in patients with cervical carcinoma. *J Appl Clin Med Phys* 2014;15:60-66.
10. Orton CG, Sadr S, Sormay A. Comparison of HDR and LDR remote after loading for cervix cancer and the importance of the fractionation. *Int J Radiat Oncol Biol Phys* 1998;14:54.
11. Isoyama-Shirakawa Y, Nakamura K, Abe M, et al. Caudal epidural anesthesia during intracavitary brachytherapy for cervical cancer. *J Radiat Res* 2015;56:583–587.
12. Weitmann HD, Gustorff B, Vaupel P, et al. Oxygenation status of cervical carcinomas before and during spinal anesthesia for application of brachytherapy. *Strahlenther Onkol* 2003;179:633–640.
13. Dyer B.A., Nielsen A., Kamrava M, et al. Anesthesia and Procedural Care for Brachytherapy. In: Mayadev J., Benedict S., Kamrava M. (eds) *Handbook of Image-Guided Brachytherapy*. Springer, Cham; 2017.p 119-143.

## POSTOPERATIVE COMPLICATIONS IN PATIENTS UNDERGOING THYROID SURGERY

Jovanovski-Srceva M<sup>1</sup>, Kokareva A<sup>1</sup>, Kartalov A<sup>1</sup>, Kuzmanovska B<sup>1</sup>, Gavrilovska A, Spirovski Z<sup>2</sup>, Kondov G<sup>2</sup>, Cholanceski R<sup>2</sup>, Crvenkova S<sup>3</sup>, Mojsova M<sup>1</sup>, Peneva M<sup>4</sup>, Stevic M<sup>5</sup>, Nedxati J<sup>6</sup>, Shosholcheva M<sup>6</sup>, Jankulovski N<sup>7</sup>

<sup>1</sup> University Clinic for Anesthesia, Reanimation and Intensive Care, Skopje, Macedonia

<sup>2</sup> University Clinic for Thoracic Surgery, Skopje, Macedonia

<sup>3</sup> University Clinics of Radiotherapy and Oncology, Skopje, Macedonia

<sup>4</sup> University Clinic for Plastic Surgery, Skopje, Macedonia

<sup>5</sup> Medical Faculty, Belgrade, Serbia

<sup>6</sup> University Clinic for Surgery “St. Naum Ohridski”, Skopje, Macedonia

<sup>7</sup> University Clinic for Abdominal Surgery, Skopje, Macedonia

### ABSTRACT

**Background and objectives:** Postoperative complications from thyroid surgery are numerous and may be shown on different levels. Some of these complications may be detrimental for patients, so minimization of the risks should be always considered. We evaluated the postoperative complications in patients after surgery of the thyroid gland at the Clinic for Thoracic Surgery, Skopje.

**Material and method:** In retrospective manner, all patients undergoing thyroid surgery during the one-year period (1. January- 31. December 2017) were evaluated. Patients were divided into two groups, whereas group ST included patients who underwent goiter removal and subtotal thyroidectomy while group TT included patients in who total thyroidectomy was done. In both groups we analyzed the demographic data and the occurrence of postoperative (in the first 48 hours) complications (stridor, hoarseness, hemorrhage, nerve dysfunction, tracheomalacia, hypocalcemia and the need for reintubation and tracheostomy).

**Results:** Total data from 197 patients was evaluated. 120 patients had subtotal thyroidectomy while total thyroidectomy had 77 patients. Postoperative complications occurred in significantly larger number of patients in the TT group (64.9 vs. 40%). Hoarseness (8.4% vs. 18.5%), stridor (18.3% vs. 9.2%) tracheomalacia (5% vs. 1.2%) and hematoma (2.5% vs. 3.8%) occurred in respect to the groups. Hypocalcaemia occurred in significantly larger number of patients in TT group. Permanent nerve injury was found in one patient in the same group and tracheotomy was done only in one patient.

**Conclusion:** Overall results from our study show that the complications after thyroid surgery occur in all patients who undergo thyroid surgery. However, more severe complications and outnumbered are complications in patients who undergo total thyroidectomy.

**Key words:** complications, occurrence, thyroid surgery, total thyroidectomy.

**Corresponding author:** Marija Jovanovski-Srceva, Clinic for Anesthesia Reanimation and Intensive Care, Vodnjanska br 17, 1000 Skopje. tel:+38972 652 475 , email:marijasrceva2gmail.com

## Introduction

Thyroid gland surgeries are considered to be routine interventions, but many aspects of the nature of the thyroid diseases, as well as the pre and perioperative features might interfere and lead to unwanted complications, higher morbidity and mortality (1).

Literature data show reports where complications after thyroid surgery are reported to be numerous and at different levels. Mainly, studies analyzed patients in whom total thyroidectomy was done, but reports of complications in patients with single or multimodal goiter removal and subtotal thyroidectomy are poorly noted in the literature (2, 3). Even though this is completely logical, because medicine is decisive that total thyroidectomy may lead to more postoperative complications, the fact is that any thyroid surgery increases the risk for postoperative complications like bleeding, recurrent laryngeal nerve (RLN) injuries, hoarseness, hematomas, hypocalcemia, hypoparathyroidism etc. (2). However, not a single postoperative complication has been systematically investigated yet.

Despite the surgery undertaken majority of these complications are directly correlated to the magnitude of the goiter, type of histopathological findings, position of the changes on the gland (retrosternal), experience of the surgeon, difficulties of airway management, intubation trauma and several other factors that may result in higher morbidity (1,3). When these complications are evaluated from anesthesiology aspect, consideration that interfere with difficult airway management, difficult intubation, post-extubating stridor, need for prolonged intubation and need from reintubation, should be discussed (3).

The aim of this study was to analyze and evaluate the occurrence of postoperative complications in all patients who underwent thyroid gland surgery in a retrospective manner.

## Material and method

In a retrospective study, we evaluated the records of all patients who underwent thyroid gland surgery at the Clinic for Thoracic Surgery during one-year period (1 January-31 December 2017). The records of patients were analyzed for demographical and type of the surgery data.

Patients were divided into two groups whereas in Group ST- included patients who had thyroid surgery for goiter (where goiter was removed, and subtotal thyroidectomy was done), while Group TT -included patients who underwent total thyroidectomy for confirmed malignances of the thyroid gland.

In the group ST we analyzed the physical exploration of the goiter/s and the compressive symptoms (Grade I - not visible and palpable, Grade II- visible and palpable, Grade III- compressing the neighborhood structures).

In both groups of patients, we analyzed the preoperative hormonal status and postoperative complications (during the first 48 hours) that included: post-extubating stridor as well as hematomas, hoarseness, tracheomalatia, hypocalcemia whether clinical or by laboratory (<2.1mmol/l) findings, injury of recurrent laryngeal nerve, tracheomalacia as well as the need for reintubation, second intervention, and tracheotomy during the first 48 hours.

Patients who had predicted difficult intubation (Mallampati III, IV), older than 75 years, ASA grade IV, patients with present Pemberton sign (obstruction of Vena cava superior syndrome) and patients with preoperatively paralysis of the vocal cord (assessed by ENT specialist) were excluded from the study.

## Results:

Retrospectively 213 patients had thyroid surgery for the one-year period. Out of them 16 were excluded from the study according to the excluding criteria, leaving total of 197 patients for further analyzes.

Out of 197 patients, group ST (where goiter, multimodal goiters and subtotal thyroidectomy was done) included 60.9% (120 patients), while group TT (where total thyroidectomy was done) included 39.1% (77 patients) of the patients.

Most of the patients in both groups were female, ASA grade II and Mallampati grade I. In both groups most of the patients had hypertension as a co-morbidity. Demographic and clinical data of the patients are shown in Table 1.

Table 1. Demographic and clinical data of the patients.

	Group ST (n=120)	Group TT (n=77)
Age(mean+Sd)	50.05+14.56 Sd	54.3+12.2 Sd
Female/male ratio (%)	82.5%/17.5%	61.1%/38.9%
ASA (%)		
I	20,8%	20.8%
II	75.8%	77.9%
III	3.4%	1.3%
Mallampati (%)		
I/II	65.8%/34.2%	70.1%/29.9%
Duration of surgery(min) (mean+Sd)	107+33.1Sd	103.2+37.5Sd

\*ASA- American society of Anesthesiologists; Sd-Standard deviation

Preoperative hormonal status showed that most of the patients in both groups were euthyreotic. In group ST, 95 patients (79.2%) were euthyreotic, 17 patients (14,2%) were hyperthyreotic and 8 patients (6.6%) were hypothyreotic. In the same group physical exploration of the goiter/s and the compressive symptoms showed that the change was palpable but not visible in 70 patients (58.3%), visible and palpable in 40 patients (33.3%) and compressing the neighborhood structures in 10 patients (8.4%). Intrathoracic component was present in 8 patients from group ST. On the other hand, in group TT, 68 patients (88.3%) were euthyreotic, 6 patients (7.8%) hyperthyroid and 3 patients (3.9%) were hypothyreotic. In both groups most of the patients were intubated on the first attempt.

Nonsystematic evaluation of the complications showed that postoperative complications were found in group TT when compared to group ST (64.9% vs 40%). In other words, only 27 patients who had total thyroidectomy did not have any complications while 72 patients who underwent subtotal thyroidectomy.

Table.2. Occurrence of complications in both groups.

Complication	Group ST (n=120)	Group TT (n=77)
Post-extubating stridor	8.4 % (10 patients)	18.5 % (15 patients)
Post extubating hoarseness	18.3% (22 patients)	9.2% (7 patients)
Hypocalcaemia	2.5% (3 patients)	26% (20 patients)
Transitory RLN injury	0,8% (1 patient)	3.8% (3 patients)
Permanent RLN	/	1.2% (1 patient)
Tracheomalatia	5% (6 patients)	1.2% (1 patients)
Hematoma	2.5% (3 patients)	3.8% (3 patients)

The need for reintubation occurred in 3 patients (2.5%) in group ST and all of these patients had preoperative grade III status of the goiter. In one of them mechanical ventilation for 24 was needed. None of the patients in this group underwent tracheostomy while in group TT one patient had early tracheostomy due to permanent RLN damage. Right-sided transitory RLN injury was found in both groups.

## Discussion

Our evaluation study of the complications after thyroid surgery showed that all patients who undergo thyroid surgery might show postoperative complications. However, more severe complications and outnumbered are complications in patients who undergo total thyroidectomy.

Post extubating hoarseness in our study occurred in 18.3% in patients with subtotal thyroidectomy, while in 9.2% of patients with total thyroidectomy. These findings are not specific because the literature confirms that this complication is considered to be the most often complication in patients after total thyroidectomy (1,4,5). When discussing this complication, we must not forget the etiological factors. Etiologically, hoarseness might occur due to several factors (RLN injury, intubation trauma, extubating manipulations, vocal cord dysfunction or as a result of post thyroidectomy central compartment syndrome, duration of surgery) and etc. (4,5). Differentiating the ethology for this complication include several specific diagnostic tools. Overall for this complication the literature reports incidence is estimated to be up to 50% of all thyroidectomized patients, out of this of patients' hoarseness in 28.5% characterized as transitory in 10.7% as permanent and in 17.9 % of with unknown clinical outcome (4).

Additionally, in our study postoperative stridor was found in 8.4% vs. 18.5% in respect to the groups. Post extubation biphasic stridor mainly may occur as a result of above explained mechanisms, but literature presents that the key role is damaged RLN (5). After extubation, biphasic stridor, respiratory distress and aphonia occur, due to unopposed adduction of vocal cords and closure of glottic aperture necessitating immediate intervention and emergency intubation or tracheostomy (6).

Considering the results for hoarseness and stridor as complications in our study and differences of the global burdens results for complications after thyroid surgery may be due to several factors. Firstly: in our study we only evaluated the percentage of occurrence and not the clinical outcome. Secondly: our study was retrospective, so only the data for the presence of hoarseness and stridor was estimated only through the data from the post anesthesiology recovery unit (which covers information for the 3 hours after the surgery), thirdly: we gathered the information for the first 48 hours post operatively and fourthly: laryngeal complications of tracheal intubation can be seen as these complications during the early postoperative period (which covers our study), so we cannot directly compare our results with the findings from several other studies (5,6,7).

When we discussed the above-mentioned complications (hoarseness and stridor), besides the fact that we explained the results from our study from different angles, we must emphasize that they mainly occur due to RLN injury. RLN injury is estimated to occur in up to 14 % of all thyroidectomized patients (3,4,5,6). Due to retrospective nature of our study and from the postoperative indirect laryngoscopy data (which were performed to identify recurrent laryngeal nerve damage), we can only say that from the gathered data permanent RLN injury was found in 1 patient in the TT group. This is the patient that underwent early tracheostomy.

Tracheomalatia was found in 5% vs. 1.2% of the patients in our study. Tracheal collapse following thyroid surgery is a result from prolonged tracheal compression by large mass (7, 8). From our results and considering the fact that in the ST group, according to the physical examinations of the goiter, the change was palpable, but not visible in 70 patients (58.3%), visible and palpable in 40 patients (33.3%) and compressing the neighborhood structures was in 10 patients (8.4%) higher occurrence rate of tracheomalatia was found in this group. This is life-threatening complication and should be considered before extubating and treatment requires reintubation and/or tracheostomy or some forms of tracheal support such as ceramic rings (6,8). Unfortunately, in our study we did not evaluated the weight of the goiters and the weight of thyroid gland which according to many authors has direct correlation to the tracheomalatia.

Global burdens show data that after thyroidectomy for large multinodular goiter the incidence of temporary hypocalcaemia occurs in 20% of patients about 36 h, postoperative (9). In our study, hypocalcaemia in the patients with total thyroidectomy was registered in 26% of the patients. Our results are in correspondence to the other authors' studies. However, this complication might be reduced by more careful inspection of the thyroid capsule. (6-8)



### Limitations and Suggestions

Our study is limited in several aspects. It is retrospective, it gathers data from the first 48 hours, it does not measure the outcome, it does not analyze the patients from the preoperative therapy and the study does not include large number of patients. Despite the limitations this study is beneficial to the medicine and everyday surgery due to the fact that no study yet has been published that evaluated the complications after the subtotal thyroidectomy. This study opens the door for furthermore systematically, prospective and randomized studies.

### Conclusion

Postoperative complications after thyroid surgery vary and can be on different levels. However, more severe and outnumbered are complications in patients who undergo total thyroidectomy. The most important factor is to have early recognition and prompt reaction for treatment of these complications otherwise they may be **detrimental for the patients.**

### References

1. Fewins J, Simpson C, Miller F. Complications of thyroid and parathyroid surgery. *Otolaryngol Clin North Am.* 2003; 36(1): 189-206.
2. Bouaggad A, Nejmi SE, Bouderkha MA, Abbassi O. Prediction of difficult tracheal intubation in thyroid surgery. *Anesth Analg* 2004;99(2):603–6.
3. Ready AR, Barnes AD. Complications of thyroidectomy. *Br J Surg* 1994;81: 1555–6.
4. Lombardi CP, Raffaelli M, D'Alatri L, et al, 2006 Voice and swallowing changes after thyroidectomy in patients without inferior laryngeal nerve injuries. *Surgery* 140:1026-1032.
5. Harness JK, Fung L, Thompson NW, et al. Total thyroidectomy: complications and technique. *World J Surg.* 1986;10:781–786.
6. Pertl L, Zacherl J, Mancusi G, et al, 2011 High risk of unilateral recurrent laryngeal nerve paralysis after esophagectomy using cervical anastomosis. *Eur Arch Otorhinolaryngol* 268: 1605-1610.
7. Geelhoed GW. Tracheomalacia from compressing goiter: management after thyroidectomy. *Surgery* 1988;104:100–8.
8. Lacoste L, Gineste D, Karayan J, et al. Airway complications in thyroid surgery. *Ann Otol Rhinol Laryngol* 1993;102:441–6.
9. Lee NJ, Blakey JD, Bhuta S, et al. Unintentional parathyroidectomy during thyroidectomy. *Laryngoscope* 1999;109:1238–40.

## PRIMARY HYPERPARATHYROIDISM IN PREGNANCY

Kondov B<sup>1</sup>, Pemovska G<sup>2</sup>, Shukarova E<sup>3</sup>, Stavric K<sup>3</sup>, Srceva M<sup>4</sup>, Majstorov V<sup>5</sup>, Stojanovski S<sup>5</sup>, Ilic Miladinova D<sup>5</sup>, Angushev D<sup>4</sup>, Tolevska N<sup>1</sup>, Jovanovska AM<sup>5</sup>, Kondov G<sup>1</sup>

<sup>1</sup> University Clinic for Thoracic and Vascular Surgery. Clinical Center Mother Theresa, Skopje R. Macedonia.

<sup>2</sup> University Clinic for Endocrinology. Clinical Center Mother Theresa, Skopje R. Macedonia.

<sup>3</sup> University Clinic for Pediatrics. Clinical Center Mother Theresa, Skopje R. Macedonia.

<sup>4</sup> University Clinic for Anesthesia, Reanimation and Intensive care. Clinical Center Mother Theresa, Skopje R. Macedonia.

<sup>5</sup> Institute for Pathophysiology and Nuclear Medicine. Medical Faculty Skopje, R. Macedonia.

### ABSTRACT

In this article, we report a case of a primary hyperparathyroidism in a young woman, as a result of the adenoma of a parathyroid gland, detected few days after delivery. Suspicion for primary hyperparathyroidism was achieved after different clinical features had been seen in the newborn (respiratory insufficiency, neonatal hypocalcaemia and recurrent convulsions).

The aim of this article is to emphasize the importance of the early detection of hyperparathyroidism in pregnancy with adequate control of calcium, phosphates and magnesium, in order to additionally prevent disturbances of the neuromuscular feasibility and other changes in the newborn. Even though, the early treatment of hyperparathyroidism in pregnant woman, needs to be individualized for every case (conservative or surgical treatment), in this article we also present the surgical treatment postpartum and the aspects of how calcium metabolism is changed in pregnancy and why this state may be overviewed by clinicians.

**Key words:** hyperparathyroidism, neonatal hypocalcemia, parathyroidectomy, pregnancy

**Corresponding author:** Borislav Kondov, Clinic for Thoracic Surgery, Vodnjanska br 17, 1000 Skopje, email: b\_kondov@yahoo.com

**Introduction**

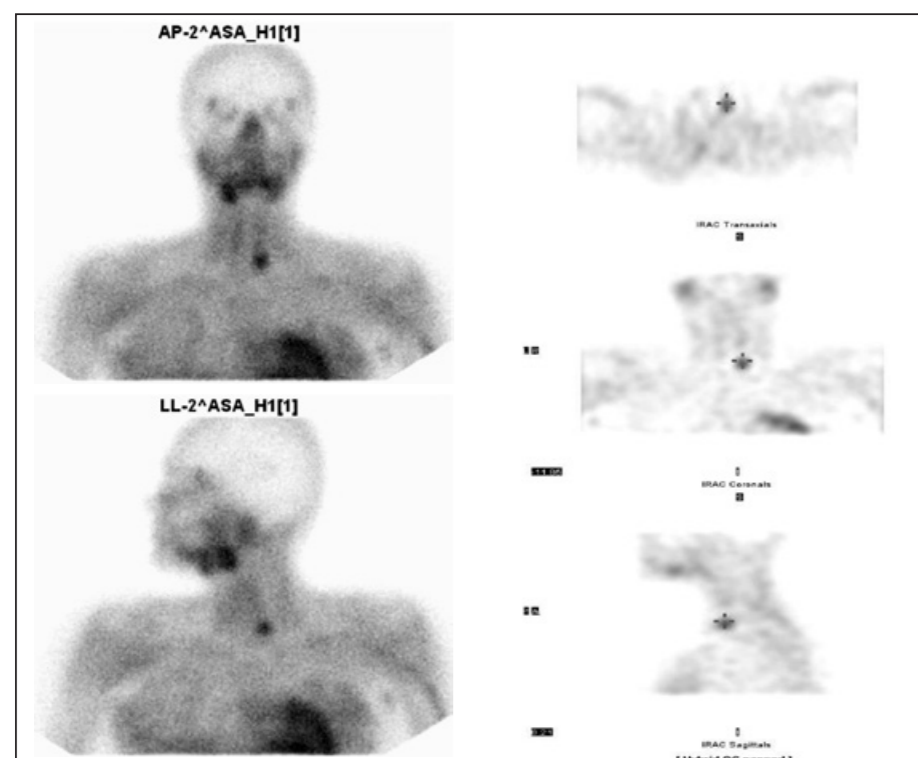
Primary hyperparathyroidism is the most common endocrinological disease, but it rarely occurs during pregnancy (1,2,3,4,5,6). Metabolic changes in the body of the pregnant woman the most often are masking the clinical features of hyperparathyroidism. Even though modern medicine is very investigative, in a small number of cases, hyperparathyroidism might not be detected during pregnancy and the diagnosis in such cases is revealed after the completion of the pregnancy, usually due to some clinical changes seen in the newborn (4).

In this article, we report a case of a primary hyperparathyroidism in a young woman, as a result of the adenoma of a parathyroid gland, detected few days after delivery.

**Case Report**

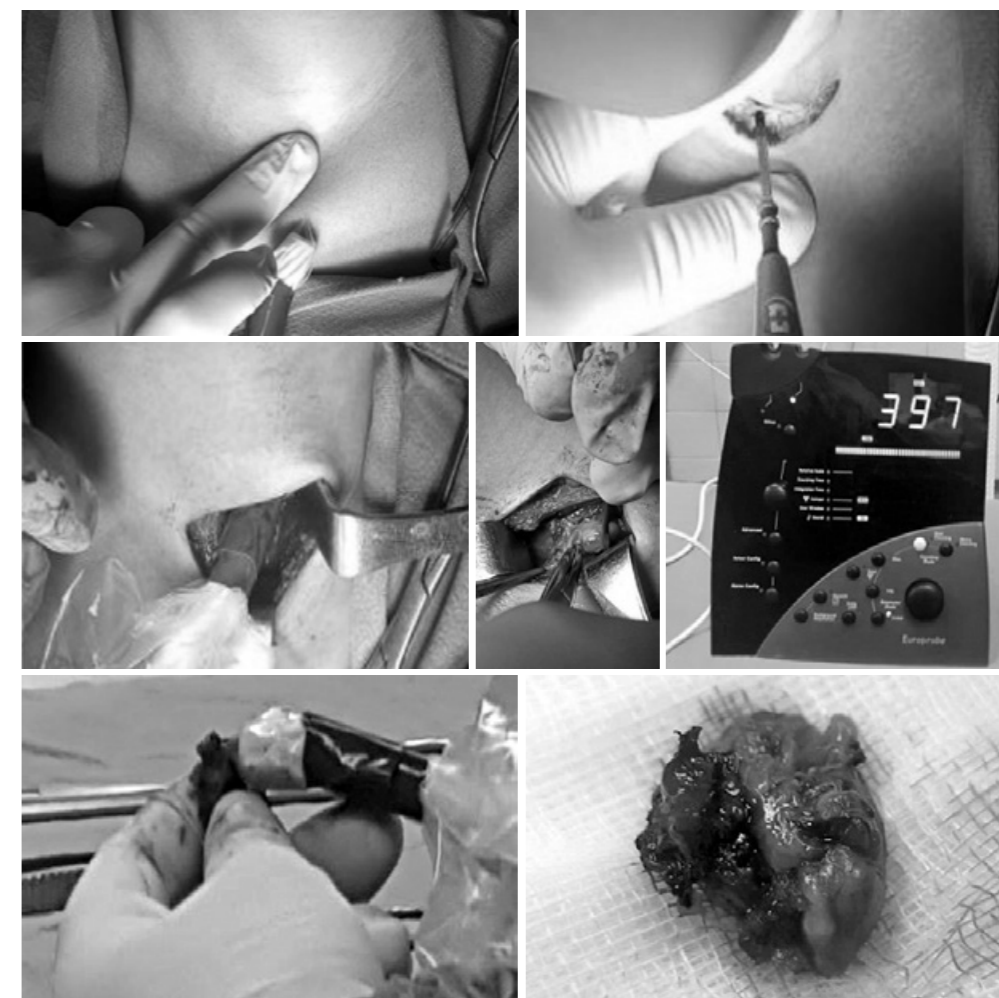At the University Clinic for pediatrics in Skopje, a one-day old male neonate was transferred from the neonatal department at the Clinic for Gynecology due to respiratory insufficiency (maternity asphyxia) and convulsions. Due to the more frequent convulsions that were not responding to standard anticonvulsive therapy and evident respiratory insufficiency, the baby on the 4<sup>th</sup> day was intubated and mechanical ventilatilation was started. At the time in the newborn profound hypercalciuria and hypocalcaemia was found (the blood calcium values were 1.65 mmol/l). Such findings suggested a possible parathyroid hormone and metabolism disorder in the mother.

Therefore, the mother was investigated and hypercalcemia of 2.63 mmol /l and elevated parathyroid hormone (PTH) values of 123.3 pg/ml were found. This was the reason for the planning of a SPECT scan with Tc<sup>99</sup> of the parathyroid gland, which visualized the existence of an adenoma of the lower left parathyroid gland (isotope accumulation under the lobe of the thyroid gland) (Image No. 1).



**Image No.1.**  
SPECT scam of the neck, with fixation of radiotracer in lower left parathyroid gland

These findings were sufficient to set up the indication for the surgery. The surgical intervention was done in general anesthesia, after radioactive tracer Tc<sup>99</sup> was inserted (under ultrasonography) at the Institute of Pathophysiology and Nuclear Medicine. The surgery was performed with minimal base neck incision, led with handheld gamma detector probe, using minimal invasive surgery with ROLL (radioguided occult lesion localization). Adenoma of the lower left parathyroid gland was detected and removed with the ultrasonic knife (Images 2, 3,4,5,6,7,8).



**Images 2-8.** Surgical incision and removal of adenoma of parathyroid gland, using ROLL technique

Postoperatively (in the first 24 hours) decrease in blood calcium levels, to 2.11mmol/l, and normalization of PTH blood levels were found in the mother.

On the other hand, baby was 18 days mechanically ventilated with supplementing therapy of calcium where hypocalcaemia was corrected from 1.65mmol/l to 2.3mmol/l on the day of discharged from the ICU (1.73mmol/l, 2.17mmol/l; 2.3mmol/l) and transferred to the department for endocrinology diseases at Pediatric Clinic. After one week baby was discharged from department of endocrinology in good condition.

## Discussion

During pregnancy, the metabolism of calcium is intense and conditioned by the hormonal changes in the mother and the need for calcium in the fetus. Metabolism of calcium is under the regulation of parathyroid hormone levels of the mother, 1.25 hydroxyvitamin D from the mother, placental parathyroid hormone, calcitriol and etc.

In pregnancy, calcium changes are dependent of the need and delivery for calcium between the mother and the fetus which is especially emphasized in the third semester. These changes are characterized with increased loss of calcium through urine (bounded to proteins), increased transport of calcium through the placenta (around 300 mg/day- which is main source for the need of skeletal formation in the fetus) and an increased amount of calcium absorption in the intestinal tract compensatory for the previously reported losses (4). Under these conditions hypocalcaemia (in means of total calcium) can be detected in laboratory findings, but the values of ionized calcium may be within the normal range.

On the other hand, in such conditions of intense calcium metabolism in the mother, followed by hormonal imbalances, it is very difficult to detect hormonal disorders that are caused specifically by the level of a parathyroid hormone (PTH) due to adenoma of one or more than one parathyroid glands. Primary hyperparathyroidism (due to adenoma) in the mother in reality causes elevated levels of calcium in the blood, but due to the intensive placental transport of this calcium to the fetus, these levels of calcium on laboratory findings are not markedly elevated and usually do not cause clinical manifestation of hypercalcemia in the mother (5). However, hypercalcemia can be rarely detected, followed by muscle weakness, abdominal symptoms, depression, coma and death (5).

Literature reports that the primary hyperparathyroidism (due to adenoma of parathyroid glands) is the most common endocrinological disorder, but still global literature burdens report that during pregnancy it occurs in only 0.08% of the pregnancies (1, 2, 3). This condition in the mother has several implications on the fetus and the pregnancy also. In relation to the fetus of a woman with primary hyperparathyroidism, it may cause lower growth, prematureness and the occurrence of a spontaneous abortion (3).

Hyperparathyroidism in the mother the most often cause suppression of the parathyroid hormone production in the newborn (often transient), which is manifested with hypocalcaemia in the newborn, increased neuromuscular irritability particularly pronounced in the first 3-4 weeks. Baby has small reserves of PTH (from the mother) and according to this, still does not begin to be secreted and have normal PTH hormone and calcium metabolism. Literature reports that the clinical features in the newborn (knowing the fact that calcium is a significant element in the development of the skeleton during the fetal period, 20 -30 grams of calcium/day), may sometimes last longer than 3-4 weeks after birth (6, 7).

Most often, during pregnancy with primary hyperparathyroidism, there are no clinical symptoms.

According to all, it is important to monitor the serum levels of calcium and phosphates in the pregnant women, due to the possible serious consequences for the newborns. When recurrent convulsions, hypocalcemic tetanic cramps are seen in newborn, diagnoses for hormonal disorder (hyperparathyroidism) in the mother should (although mother is asymptomatic) be suspected. Therefore evaluation of calcium, phosphates and parathyroid hormone values (PTH) should be considered.

If laboratory findings suggest hyperparathyroidism, and especially if the values of the parathyroid hormone in the blood are elevated, the ultrasonography of the neck should be done for determining the morphological changes in one or more parathyroid glands. In the case of pregnant women, investigations with radioisotopes are not recommended. For pregnant women application of NMRI to the neck is recommended. If the pregnant woman has already delivered, the function of parathyroid glands is monitored with the application of the MIBI-Tc<sup>99</sup> scan or with the SPECT scan of the neck with the Tc<sup>99</sup>as marker, or the scanning of the neck with computerized tomography (CT).

Treatment should be individualized for each case separately, depending on the values of calcium, phosphates, PTH and stadium on the gravidity. If the PTH levels are not extensively high, a conservative (with medication) treatment can be planed. The conservative medication treatment is consisted in increased water intake, diuretics, orally administered phosphates, bisphosphonates, and in extreme cases, dialysis may be indicated (4).

Unlike the low levels of PTH, the high values of parathyroid hormone with present adenoma (benign tumor) are indication for surgery. During pregnancy, due to the need to plan general anesthesia, surgical intervention may be planned in the second trimester (8, 9).

For our case the woman was delivered and the application of ROLL (radio-guided occult lesion localization) technique that allowed us to use a minimally invasive approach to the parathyroid gland. The technique of preoperative, fixation of the changed in the parathyroid gland with radioisotope (Tc<sup>99</sup>), followed by the hand-held gamma detector probe, allowed removing of the adenoma and possible checking of the bearing field and checking for the residue from the same. However, this technique is not preferable in the pregnant women (8, 9).

For the conclusion of the discussion, it can be stressed that for any suspicion of the calcium regulation in a pregnant woman, it is necessary to determine the blood values of total calcium, ionized calcium and parathyroid hormone (PTH) values in pregnant women. If changes in some of these values occur, ultrasonography of the neck as the least invasive procedure should be done and if morphological changes in one or more parathyroid glands (adenomas) are found out, it is necessary to plan surgical removal of the same, in general anesthesia preferably in the second trimester of pregnancy. This is the only way the occurrence of harmful effects on the fetus and occurrence of clinical manifestations of hypocalcaemia in the newborn child to be prevented.

## References

1. Kort KC, Schiller HJ, Numann PJ. *Hyperparathyroidism and pregnancy*. Am. J. Surg. - January 1, 1999; 177 (1); 66-8.
2. E. Ashlie Darr, Niranjansritharan, Phillip K. et al. Cummings Otolaryngology, 124, Management of Parathyroid Disorders 1929-1956.e8.
3. Chow E, Tsang RW, Brierley JD, et al: Parathyroid carcinoma—the Princess Margaret Hospital experience. Int J RadiatOncolBiol Phys 1998; 41: pp. 569-572
4. Lillemoe KD, and Dudley NE: Parathyroid carcinoma: pointers to successful management. Ann R CollSurgEngl 1985; 67: pp. 222-224.
5. Bukowski RM, Sheeler L, Cunningham J, et al: Successful combination chemotherapy for metastatic parathyroid carcinoma. Arch Intern Med 1984; 144: pp. 339-400.
6. Chahinian AP, Holland JF, Nieburgs HE, et al: Metastatic nonfunctioning parathyroid carcinoma: ultrastructural evidence of secretory granules and response to chemotherapy. Am J Med Sci 1981; 282: pp. 80-84
7. Kort KC, Shiller HJ, and Numann PJ: Hyperparathyroidism and pregnancy. Am J Surg 1999; 177: pp. 66-68.
8. Nader S: Other endocrine disorders. In Creasy RB, and Resnik R (eds): Maternal Fetal Medicine: Principals and Practice, ed 3. Philadelphia: Saunders, 1994. pp. 1004-1026.
9. McMullen TP, Learoyd DL, Williams DC, et al.- *Hyperparathyroidism in pregnancy: options for localization and surgical therapy*/ World J Surg - August 1, 2010; 34 (8); 1811-6.

## Guidelines for Authors

**Macedonian Journal of Anaesthesia (MJA)** is a scientific journal of the Macedonian Society of Anaesthesia (MSA) and Macedonian Society of Critical Care Medicine (MSCCM). The aim of this specialized medical journal is to speed and promote scientific achievements, novelties', clinical experience's, reviews, controversial topics in anesthesia, reanimation and intensive care.

The Journal is published twice a year (April and November), but additional supplements might be published when needed. MJA publishes original (professional and scientific) articles, review articles, case reports, therapeutic and technological innovation, discussions, critics, impressions from meetings, information for international conferences and reviews of new books or variate.

Manuscripts that are published should have not been published previously. Manuscripts that have been previously published only in form of abstracts are eligible for publishing in the journal but should be followed by additional letter send to the Editor, where the abstract details are noted (abstract number, which book of proceeding or doi, date and place).

The authors are responsible for respecting the ethical guidelines for medical researches, as well as for all that is explained, attitudes, analyses and shown results.

The redaction sends the manuscripts to anonymous reviewing process from international or domestic reviewers and the Editors determine the definitive categorization of the manuscript. Once reviewed manuscript together with the reviewers' remarks is send back to the corresponding author, after what the author is omitted to deliver the final form of the manuscript to the Editorial board within one week.

Editorial board has the right to publish the manuscripts according to the reviewer's priority. The order in which the manuscripts are published does not reflect the scientific value of the article. The Editorial board keeps the rights to make changes to the manuscript to fulfil the criteria.

## MANUSCRIPT PREPARATION

Manuscript should be sent together with the accompanying letter from the corresponding authors where declaration that the text has not been published previously is signed. Additional conflict of interests and confirmation by all the authors should be declared in this letter (example: Annex no.1).

The guidelines for authors adhere to the uniform Requirements for Manuscripts submitted to Biomedical Journals: [www.nlm.nih.gov](http://www.nlm.nih.gov).

**Language and style** of the manuscripts should be clear, simple to according the language, anesthesiological and medical taxonomy.

The manuscript has to be written in **English**, followed by an abstract in Macedonia (after the references section).

Manuscripts should be written in **Microsoft Word** (\*.doc format) with **Times New Roman** font and **size 12**. Margins on left, up and bottom should be 3cm and right margin should be 2,5cm.

the inline space should be 2. Do not use Bold or Italic letters for the whole text (only for parts that have to be emphasized). Manuscript should not exceed 10 pages (without the references).

**Abbreviations and correct medical terms** should be used according to the International Committee of Editors of Medical Journals (<http://www.icmje.org>). Use only standard abbreviations; use of nonstandard abbreviations can be confusing to readers. Avoid abbreviations in the title of the manuscript. The spelled-out abbreviation followed by the abbreviation in parenthesis should be used on first mention unless the abbreviation is a standard unit of measurement.

### **MANUSCRIPT SECTIONS**

- Manuscript should be organized in:
- Title page
- Text organized in IMRaD
- Acknowledgments
- Authors Contribution
- References
- Abstract in Macedonian only (For Macedonian Natives)

Review articles, case reports, therapeutic and technological innovation, discussions, critics, impressions from meetings, information for international conferences and reviews of new books or variate may be written in different sequences and manners.

### **TITLE PAGE**

**The title** of the manuscript written in CAPITAL LETTERS.

**Authors Surname and Name initial** ( Jovanov.J), without academic or other titles.

**Name and address of the institution** where the authors come from whit the subscribed digits

**Abstract in English.** Abstract should include up to 250 words and should contain goals of the paper, important elements from the methodology, concisely displayed results and conclusion. Each abstract at the end must have **Key words:** in alphabetical order.

### **TEXT**

- Introduction,
- Matherial and Method,
- Results
- Discussion
- Conclusion

Review articles, case reports, therapeutic and technological innovation, discussions, critics, impressions from meetings, information for international conferences and reviews of new books or variate may be written in different sequences and manners.

**Introduction** section should include a literature overview in relevance to the elaborated problem. In this sections 3-5 key references are cited and this section should not be longer than 2 pages.

**Material and method** sections includes detailed description of the performances in the research as well as the statistical analyses used. This section should include: time during what the research was conducted, type of the study, place of where the research was undertaken, randomization or stratification used (clear description of the examined groups), exclusion and inclusion criteria, method, analysis types, apparatus and instruments used and referent values of the examined features (in SI-International System units).

**Results** are displayed in simple manner with text, images, tables and charts that are submitted in the text where author wants to stand, titled and numbered appropriately. Additionally, on separate document all carts images and tables are send together with the manuscript.

Title and the number of the charts and tables are placed above them while the explanations, abbreviations and comments are placed below. Images title and number is placed below and the image should include proper explanation.

**Discussion** section emphasize the key finding of the actual research and compares these result to other relevant literature data.

**Conclusion** section should not include more than 150 words and shoul be drown from the relevant elaborated results.

**Acknowledgment and Author contributions** sections are displayed after the conclusion and before the reference section.

### **REFERENCES**

This sections include only the cited references. **The references** are listed in order of appearance in the paper and the citation is standard numbers enclosed in small brackets in the same line with the text ( ).

For each reference if more than three authors appear provide the names of the first three authors and followed by **et al**.

#### **Examples:**

Journal references:

Nirmala BC, Kumari G. Foot drop after spinal anaesthesia: a rare complication. Indian J Anaesth. 2011; 55: 78–79.

Lynch EP, Lazor MA, Gellius JE, et al. The Impact of Posoperative Pain on the Development of Postoperative Delirium. Anesth Analg 1998; 86:781-785.

#### **2. Journal supplements:**

AzmanJ, Frkovic V, Bilic L, et al. Korelacija I regresija. Acta Med Croat 2006;60 (suppl I):81-89.

### 3. Books

Brown, D.L. Spinal, epidural, and caudal anesthesia. In R.D. Miller Miller's Anesthesia, 6th edition. Philadelphia: Elsevier Churchill Livingstone; 2005.p 98-198

### 4. Doctoral or master thesis

Jelisavac Cosic S.Urokinazni I tkivni aktivator plazminogena i njihov inhibitor u raku dojke (Master thesis).Zagreb: Farmaceutsko-biohemijski fakultet 2004, p.50

### 5. Electronic reference

Dag Stat. Mackinnon A. Available from :http://www.mhri.cdu.au/biostats.Accessed May 5<sup>th</sup> 2006.  
Webster NR. The anaesthetist as peri-operative physician.Anaesthesia. http://dx.doi.org/10.1046/j.1365- 2044.2000.01722.x

References used from abstracts are marked as **(abstr)**., and from letters with **(letter)**

## АПСТРАКТ НА МАКЕДОНСКИ

Macedonian abstract should include title (in capital letters) and all the needed features as the English abstract only written in Macedonian with Times New Roman, font size 12 with Macedonian support in Microsoft Word.

Prepared manuscript should be submitted electronically to **macedoniananesthesiology@gmail.com**.

**All manuscripts that don't fulfil the above criteria will not be accepted for reviewing**

### Accompany letter ANNEX no.1

I \_\_\_\_\_ . Here by declare that the article \_\_\_\_\_ (NAME OF THE ARTICLE) has not been previously published (fully or partialy) previously.

We autors \_\_\_\_\_ (FULL NAME AND SURNAMES OF THE AUTORS AND SIGNATURES) are responsible for the etic, profesional and scientific content of the study.

I \_\_\_\_\_ ( THE FIRST AUTHOR FULL NAME) declare Conflict of interest or declare non Conflict of interest.

\_\_\_\_\_ (FIRST AND SURNAME OF THE CORESPONDING AUTHOR, ..... (ADRESS), ..... (TELEPHONE NUMBER) ....., E-MAIL

# Apotel<sup>®</sup> 1000mg /6.7ml

## I.V. Paracetamol

### БЕЗБЕДНА АНЕЛГЕЗИЈА

менаџирање на болка кога сте загрижени за безбедноста

I.V. paracetamol за прв пат во Европа е применет во 2001 година, а денес поради неговата докажана безбедност и ефикасност е прв од избор **аналгетик и антипиретик**.

**Предоперативна и Интраоперативна Аналгезија:**  
Предоперативна аналгезија е дефинирана како третман кој што започнува пред оперативниот зафат се со цел да се превенира воспоставувањето на централна сензибилизација на болка.  
i.v. paracetamol е безбеден, добро толериран лек со докажана ефикасност како **предоперативна и интраоперативна аналгезија** за умерена до средна болка при оперативни зафати.  
**Голем број на клинички студии** ја докажуваат ефикасноста на i.v. paracetamol како **предоперативна и интраоперативна аналгезија**.

#### КЛИНИЧКА СТУДИЈА:

Ефект од **предоперативен i.v. paracetamol** за постоперативни аналгетски потреби кај пациенти кои се подложни на оперативни зафати. A Sreenivasulu, RPrabhavathi, 2015

**Цел:** Да се утврди ефикасноста на **предоперативната употреба на 1000mg i.v. paracetamol** кај постоперативните болки и аналгетски потреби кај пациенти подложни на хируршки зафати.

**Метод:** 60 пациенти беа поделени во две рандомизирани групи од по 30 пациенти.

**На I. Група** им беше администрирано **ампула од 1000mg i.v. paracetamol разредена 0,9%NaCl** p-ор 30 минути пред индукција (**ГРУПА П**),

**На II. Група** им беше администрирано **i.v. 0,9% NaCl** p-ор **100мл** 30 минути пред индукција (**ГРУПА НС**)

Сите пациенти беа индуцирани со i.v. thiopentone 5mg/kg, i.v. fentanyl 2µg/kg, i.v. vecuronium 0.1mg/kg

Постоперативниот резултат на болка беше мерен со **Визуелна Аналогна Скала (ВАС)** од "0-10". Исто така беше забележувана и **постоперативната употреба на tramadol** како спасувачки аналгетик. Инциденцата на **постоперативно гадење и повраќање (ПОПП)** и други компликации исто така беа забележувани во пост оперативниот период.

**Резултатот** на постоперативната болка беше забележуван во интервали 15 мин, 30 мин, 1 час, 2 часа, и 6 часа.

**Заклучок:** Предоперативна администрација на **1000mg i.v. paracetamol** кај пациенти подложни на оперативен зафат обезбедува **статистички задоволителна аналгезија**, и ја **намалува постоперативната употреба на tramadol**. Оттука **1000mg i.v. paracetamol** може безбедно да се администрира како превенција при оперативни зафати.

#### Резултат:

**Табела 1:** Споредба на средниот резултат на болка (ВАС) помеѓу двете групи

Интервали	I Група П	II Група НС	P вредност
15 мин	2.06 ± 0.63	2.61 ± 0.56	0.0006
30 мин	2.35 ± 1.17	3.84 ± 1.55	0.0001
1 час	2.42 ± 1.12	2.87 ± 0.99	0.0989
2 часа	2.13 ± 1.06	2.52 ± 0.89	0.1219
6 часа	2 ± 0.52	2.52 ± 0.89	0.0549

**Табела 2:** Споредба за потребите од tramadol помеѓу двете групи

Интервали	I Група П	II Група НС	P вредност
До 1 час	4 (12.90%)	15 (50%)	0.0002
1-2 часа	3 (9.68%)	2 (6.45%)	0.64
2-6 часа	1 (3.23%)	3 (9.68%)	0.301
<b>Вкупно</b>	<b>8 (25.81%)</b>	<b>20 (64.52%)</b>	<b>0.002</b>

**Табела 3:** Споредба на ПОПП помеѓу двете групи

ПОПП	
I Група П	II Група НС
0	4

i.v. Paracetamol + јак опоид	<b>МНОГУ ЈАКА БОЛКА</b>
i.v. Paracetamol + слаб опоид	<b>ЈАКА БОЛКА</b>
i.v. Paracetamol + NSAID i.v. Paracetamol + rescue medicine	<b>УМЕРЕНА БОЛКА</b>
i.v. Paracetamol + rescue medicine	<b>СЛАБА БОЛКА</b>

**Мултимодално менаџирање на постоперативна болка**  
**i.v. Paracetamol** е атрактивна компонента за мултимодално менаџирање на болка.

- Синергистичко делување
- Зголемување на аналгетски ефект
- Значително намалување на болка
- Редукција на дозата на опоидни лекови за - 40% во првите 24 часа
- Намалување на несаканите ефекти поврзани со монотерапија на NSAID и опоидни лекови
- Ублажување на акутна и хронична болка

Здружение на лекарите по  
анестезија, реанимација  
и интензивно лекување



Macedonian Society of Anesthesiologists  
and Intensive Care Medicine



Здружение на лекари за  
критично болни пациенти