

See discussions, stats, and author profiles for this publication at: <https://www.researchgate.net/publication/265421920>

Comparative analysis of clinical and arthroscopic findings in ACL injury of the knee

Article in *Medicus* · January 2014

CITATIONS

0

READS

93

5 authors, including:



Elena Kostova

Saints Cyril and Methodius University of Skopje

35 PUBLICATIONS 256 CITATIONS

SEE PROFILE



Hristijan Kostov

Saints Cyril and Methodius University of Skopje

17 PUBLICATIONS 59 CITATIONS

SEE PROFILE



Slavco Stojmenski

Traumatology clinic, Clinical center Mother t

11 PUBLICATIONS 36 CITATIONS

SEE PROFILE



Ilir Hasani

PHI UK TOARILUC

23 PUBLICATIONS 61 CITATIONS

SEE PROFILE

See discussions, stats, and author profiles for this publication at: <https://www.researchgate.net/publication/322689263>

A comparative study of MRI versus arthroscopic findings in ACL and meniscal injuries of the knee

Article · January 2018

DOI: 10.18203/issn.2455-4510.IntJResOrthop20180123

CITATIONS

2

READS

197

3 authors, including:



Omkar Kulkarni

Dr. Panjabrao Deshmukh Memorial Medical College, Amravati

4 PUBLICATIONS 4 CITATIONS

[SEE PROFILE](#)



Satish B. Sonar

Dr. Panjabrao Deshmukh Memorial Medical College, Amravati

7 PUBLICATIONS 5 CITATIONS

[SEE PROFILE](#)

Original Research Article

A comparative study of MRI versus arthroscopic findings in ACL and meniscal injuries of the knee

Omkar P. Kulkarni*, Ganesh N. Pundkar, Satish B. Sonar

Department of Orthopedics, PDM Medical College, Amravati, Maharashtra, India

Received: 01 January 2018

Accepted: 18 January 2018

Accepted: 19 January 2018

*Correspondence:

Dr. Omkar P. Kulkarni,

E-mail: dr.omkarkulkarni@gmail.com

Copyright: © the author(s), publisher and licensee Medip Academy. This is an open-access article distributed under the terms of the Creative Commons Attribution Non-Commercial License, which permits unrestricted non-commercial use, distribution, and reproduction in any medium, provided the original work is properly cited.

ABSTRACT

Background: This study was conducted to compare accuracy of MRI findings taking arthroscopy as standard in knee injuries.

Methods: All patients attending our hospital with knee injury underwent clinical examination. Out of them 100 patients with knee injury were subjected to clinical examination, MRI and then Arthroscopy. The results were compared and analyzed using various statistical tests. The accuracy, sensitivity and specificity were calculated based on these arthroscopic and MRI findings.

Results: The accuracy of clinical diagnosis in our study was 88% for ACL tears and 85% for meniscal tears. Our study proved high sensitivity and specificity and almost high accuracy for ACL injuries of knee joint in comparison to arthroscopy. MRI is an excellent screening tool for therapeutic arthroscopy. We can avoid diagnostic arthroscopy in patients with knee injuries having equivocal clinical and MRI examination and go on for therapeutic modality.

Conclusions: For the assessment of ligamentous and meniscal injuries magnetic resonance imaging (MRI) is accurate and noninvasive modality. It can be used as a first line investigation but arthroscopy still remains gold standard in diagnosing ACL and meniscal injuries.

Keywords: Arthroscopy, ACL, MRI, meniscus, knee

INTRODUCTION

In today's era, the knee joint is most commonly involved due to road traffic accidents, and sports activities.¹ Injury to ligaments and meniscus affects the stability and normal mechanics of the knee joint resulting in unstable knee which impairs a person to carry out his routine daily activity. Therefore these injuries should be diagnosed accurately and managed (surgically or conservatively) as early as possible. ACL or combined ACL and meniscal injury are most common among these injuries. Orthopedic surgeons relied completely on clinical examination in the late 1960 and early 70's till numerous reports suggested the role of arthroscopy in diagnosis and

treatment of various knee disorders.² The development of magnetic resonance imaging (MRI) helped in the diagnosis of ACL and meniscal tears of knee without arthroscopy. MRI of knee has several advantages over arthroscopy. The purpose of our study was to evaluate the radiological and arthroscopic findings of the anterior cruciate and meniscal injuries and correlate the findings of the above two method. Find out which among the two is better to diagnose ACL and meniscal injury accurately.

METHODS

This is a retrospective and prospective study conducted on a minimum of 100 Individuals admitted in Dr. PDMC

hospital, Amravati with knee injury due to various etiologies and fits into the inclusion criteria. Study conducted in period between August 2015 to August 2017.

Inclusion criteria

Inclusion criteria were patients with knee injury having ACL and meniscal injury, patients with age group 18 to 60 years, patient who have underwent MRI scan, and patients who have underwent arthroscopic surgery

Exclusion criteria

Exclusion criteria were patients with contraindication to MRI like intracerebral aneurysmal clips, cardiac pacemaker, metallic foreign body in eye, implants in middle ear; Patients who had recent knee injury but who on clinical examination had no instability in any plane and negative McMurray test. Patients who were unfit for anesthesia

On clinical examination various tests were performed after taking history. McMurray test and Apley grinding test were done to evaluate meniscal tears. Lachman test and drawer test were done to evaluate acl injury. In case of collateral ligament injury varus or valgus stress test were done to evaluate it. Each MRI was performed using the MR protocol of 1.5 Tesla on General Electric Healthcare company (GE) 1.5 T MRI. T1 and T2 weighed sequences were done on coronal and sagittal planes. MR films were be read by a radiologist.

The status of cruciate ligaments, articular cartilage and menisci were registered. A meniscal tear was classified according to MAYO 2000 classification.

- Grade I tear: Meniscal lesion globular in nature, not communicating with articular surface.
- Grade II tear: Linear in nature and remain within the substance of meniscus, there is no evidence of communication with the articular surface of meniscus.
- Grade III tear: Increased signal intensity within the meniscus that extends to the articular surface.
- Grade IV tear: Distorted tears in addition to findings of grade III tears.

Arthroscopy was done under spinal anesthesia with patient in supine position with lateral support to proximal thigh. Proximal thigh tourniquet was used in each case. The operating surgeon was not told about the MRI findings.

To classify the location of meniscal tear arthroscopically each meniscus was divided into three equal segments:

1. The anterior 1/3 or anterior horn
2. The middle 1/3 or body
3. Posterior 1/3 or posterior horn

The collateral ligaments, ACL and PCL were classified as partial disruption or complete ligament injury. The results were compared and analyzed using various statistical tests.

Method of statistical analysis

The following methods of statistical analysis have been used in this study. The results were presented in number and percentage in tables and figures.

Statistical analysis was used to calculate sensitivity, specificity, positive predictive value (PPV) and negative predictive value (NPV), in order to assess the reliability of the Arthroscopy and MRI results.

To evaluate the sensitivity, specificity and accuracy of MRI, the findings at arthroscopy were taken to be the true diagnosis.

- Sensitivity was calculated from the number of true positive results divided by the sum of the true positive results and the false negative results.
- Specificity was calculated from the number of true negative results divided by the sum of the true negative results and the false positive results.
- Accuracy was calculated from the sum of the true positive and the true negative results divided by the total number of patients who underwent arthroscopy.

The composite data was tabulated and studied for correlation with MRI findings and grouped into four categories:

1. True-positive -if the MRI diagnosis was confirmed by arthroscopy.
2. True-negative -when MRI negative for lesion and confirmed by arthroscopy.
3. False-positive -when MRI shows lesion but the arthroscopy was negative.
4. False-negative-result when arthroscopy was positive but the MRI showed negative finding.

The data was analyzed using SPSS package.

RESULTS

100 cases of traumatic ACL and meniscal injuries were identified and were retrospectively and prospectively reviewed with MRI evaluation followed by arthroscopic surgery. All of the patients had suspected anterior cruciate ligament injury or meniscal injury and those who fulfilled the inclusion criteria were selected. Patients with degenerative changes or evidence of loose bodies in plain radiographs, who were unfit for anesthesia and patients treated non-operatively were excluded from the study.

The data was analyzed to calculate true positive, true negative, false positive and false negatives. Using these specificity and sensitivity, positive and negative

predictive values were calculated with arthroscopic examination as the gold standard for comparison.

Age distribution

This study was conducted on patients with age ranging from 18 to 60 years with a mean age of 35.7 years at the time of admission.

Table 1: Showing age wise distribution of all patients.

Age (in years)	Frequency	Percentage (%)
<20	7	7
20-24	30	30
25-29	30	30
30-34	13	13
35-39	10	10
>40	10	10
Total	100	100

Table 2: Showing mean age and standard deviation.

No.	Mean age	SD
100	35.7	5.85

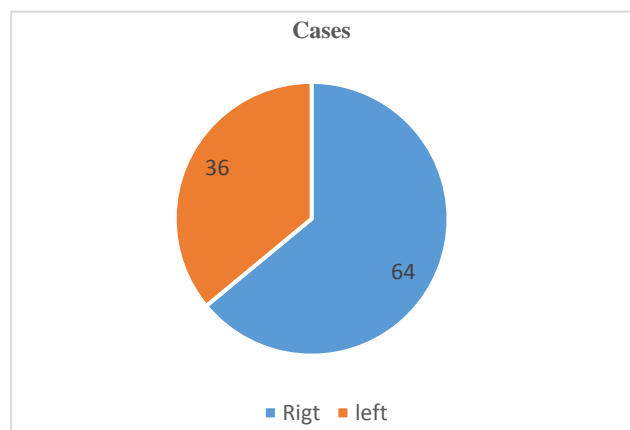


Figure 1: Patient distribution according to side affected.

Right side is commonly affected with 64 cases and left side with 36 cases.

Mode of injury

Road traffic accident was most common mode of injury in our study, accounting for about 60%.

Table 3: Showing mode of Injury study group.

Mode of injury	Cases
RTA	60
Self-fall	21
Sports Injury	19
Total	100

Table 4: Showing MRI and Arthroscopy findings for ACL tear.

	Arthroscopically positive	Arthroscopically negative	Total
MRI positive	70 (TP)	5 (FP)	75
MRI negative	7 (FN)	18 (TN)	25
	77	23	100

Table 5: ACL findings.

Test	ACL (%)
Sensitivity	90.90
Specificity	78.26
Positive predictive value (PPV)	93.33
Negative predictive value (NPV)	72
Accuracy	88

The sensitivity, PPV and accuracy of MRI scan in detecting ACL injury in our study were 90.90%, 93.33% and 88% respectively.

Table 6: Showing MRI and arthroscopy findings for medial meniscus tear.

	Arthroscopically positive	Arthroscopically negative	Total
MRI positive	52 (TP)	6 (FP)	58
MRI negative	8 (FN)	34 (TN)	42
	60	40	100

Table 7: Medial meniscus findings.

Test	Medial meniscus (%)
Sensitivity	86
Specificity	85
Positive predictive value (PPV)	89.65
Negative predictive value (NPV)	80.95
Accuracy	86

The sensitivity, PPV and accuracy of MRI scan in detecting medial meniscus injury in our study were 86%, 89.65% and 86% respectively.

Table 8: Showing MRI and Arthroscopy findings for lateral meniscus tear.

	Arthroscopically positive	Arthroscopically negative	Total
MRI positive	22 (TP)	9 (FP)	31
MRI negative	8 (FN)	61 (TN)	69
	30	70	100

Table 9: Lateral meniscus findings.

Test	Lateral meniscus (%)
Sensitivity	73.33
Specificity	87.14
Positive predictive value (PPV)	70.96
Negative predictive value (NPV)	88.41
Accuracy	83

The sensitivity, PPV and accuracy of MRI scan in detecting lateral meniscus injury in our study were 73.33%, 70.96% and 83% respectively.

DISCUSSION

MRI scanning of the knee joint is considered to be noninvasive and alternative to diagnostic arthroscopy. MRI scan is routinely done to confirm the diagnosis for ACL or meniscal injuries prior to arthroscopic surgery in current clinical practice. Identification of meniscal tears can be difficult to interpret and can be observer dependent as well as dependent upon the sensitivity of the scanner. Our objective was to compare and correlate MRI and arthroscopic findings in the diagnosis of anterior cruciate ligament (ACL) and meniscal injuries

The age group ranging from 18 to 60 years. The youngest male patient was aged 18 years and the oldest female was 60 years. There was a tendency of males being injured and getting operated at the earlier age. Males are mostly to suffer knee injuries since they are active in sports and the right knee was more frequently injured than left shown by study done by Avcu et al.³ Rubin et al reported 93% sensitivity for diagnosing isolated ACL tears.⁴ A sensitivity of 92-100% and specificity of 93-100% for the MR imaging diagnosis of ACL tears shown by similar studies in past.⁵ We obtained 90.90% sensitivity and 78.26% specificity of MRI with respect to fair correlation with arthroscopy in diagnosing ACL tears. Identification of ACL tears in our study was presented with 88% accuracy of MRI, ranged in “very good” (80-90%) interpretation group. The results of this study are in accordance to the literature which suggests an accuracy of 80 to 94% for the crucial ligament tears. PPV of MRI is 93.33% NPV of MRI is 72%.

The validity of MRI with respect to meniscal and crucial ligament disorders of the knee, combined 29 studies within 1991 to 2000 meta-analysis done by Oei and colleagues.⁶ The pooled sensitivity of medial and lateral menisci was 86% and 73.33% while pooled specificities were 85% and 87.14% respectively.

In interpretation of MRI, radiologist's experience and training are very important factors. Regarding knee MRI, in most of the studies and in our study as well, the base of reference is arthroscopy.^{7,8} In current clinical practice

arthroscopy is a technically demanding procedure and the results depend upon surgeon's experience, especially in difficult cases. MRI is the most useful diagnostic technique. The reported accuracy for detecting tears of the ACL has ranged from 70-100%.⁹ Because the ACL crosses the knee joint at a slightly oblique angle, the complete ligament rarely is captured in its entirety by a single MRI scan in the true sagittal plane. Arthroscopy should be considered a diagnostic and used in conjunctions with a good history, complete physical examination and appropriate radiographs. It should serve as an adjuvant to, not as a replacement for, a thorough clinical examination. Surgical alternatives are discussed thoroughly with the patient before the procedure, and the definitive surgical procedure is carried out at the time of an arthroscopic examination.

CONCLUSION

Our study proved high sensitivity and specificity and high accuracy for ACL and meniscal injuries of knee joint. MRI is highly accurate in the diagnosis of ACL and meniscus injuries. MRI is an appropriate screening tool for therapeutic arthroscopy, making diagnostic arthroscopy unnecessary in most patients. Magnetic resonance imaging is accurate and noninvasive modality for the assessment of ligamentous and meniscus injuries. It can be used as a first line investigation in patients with knee injury (ligaments /meniscus tears).

Funding: No funding sources

Conflict of interest: None declared

Ethical approval: The study was approved by the institutional ethics committee

REFERENCES

1. Kaplan PA, Walker CW, Kilcoyne RF, Brown DE, Tusek D, Dussault RG. Occult fractures patterns of the knee associated with ACL tears. Assessment with MR imaging. *Radiology*. 1992;183:835-8.
2. Gillquist J, Hagberg G, Oretorp N. Arthroscopic visualization of the posteromedial compartment of the knee joint. *Orthop Clin North Am*. 1979;10(3):545-7.
3. Avcu S, Altun E, Akpinar I, Bulut MD, Eresov K, Biren T. Knee joint examination by MRI: the correlation of pathology, age and sex. *N Am J Med Sci*. 2010;2(4):202-4.
4. Rubin DA, Kettering JM, Towers JD, Britton CA. MR imaging of the knee having isolated and combined ligament injuries. *AJR*. 1998;170:1207-13.
5. Lee K, Seigel MJ, Lau DM, Hildebolt CF, Matava MJ. ACL tears-MR imaging based diagnosis in pediatric population. *Radiology*. 1999;213(3):697-704.
6. Oei EH, Nikken JJ, Verstijnen AC, Ginai AZ, Myriam Hunink MG. MR Imaging of the Menisci

- and Cruciate Ligaments: A Systematic Review. *Radiology*. 2003;226:837-48.
7. Esmaili Jah AA, Keyhani S, Zarei R, Moghaddam AK. Accuracy of MRI in comparison with clinical and arthroscopic findings in ligamentous and meniscal injuries of the knee. *Acta Orthop Belg*. 2005;71(2):189-96.
8. Navali AM, Bazavar M, Mohseni MA, Safari B, Tabrizi A. Arthroscopic evaluation of the accuracy of clinical examination versus MRI in diagnosing meniscus tears and cruciate ligament ruptures. *Arch Iran Med*. 2013;16(4):229-32.
9. Knee joint examinations by magnetic resonance imaging: The correlation of pathology, age, and sex. In: Patrice Vincken. *MRI of the Knee Cost-Effective Use*. Leiden: University of Leiden, 2010.

Cite this article as: Kulkarni OP, Pundkar GN, Sonar SB. A comparative study of MRI versus arthroscopic findings in ACL and meniscal injuries of the knee. *Int J Res Orthop* 2018;4:198-202.