

Посебен отпечаток
Offprint

Zogovska E., Novevski L., Agai L.j., Mircevski V., Peev I., Dzokic Gj.

OUR EXPERIENCE IN TREATMENT OF PRESSURE ULCERS
BY USING LOCAL CUTANEOUS FLAPS

СКОПЈЕ – SKOPJE
2008

OUR EXPERIENCE IN TREATMENT OF PRESSURE ULCERS BY USING LOCAL CUTANEOUS FLAPS

Zogovska E.,¹ Novevski L.,¹ Agai Lj.,² Mircevski V.,² Peev I.,¹ Dzokic Gj.¹

¹*Plastic and Reconstructive Surgery Clinic, Skopje, R. Macedonia*

²*Neurosurgery Clinic, Medical Faculty, Ss. Cyril and Methodius University,
Skopje, R. Macedonia*

Abstract: Pressure ulcers appear in very ill patients and in states of prolonged immobilization. They are quite frequent in intensive care units and in paraplegic individuals. The expenses for their sanitation are huge, due to the complicity of the long-lasting treatment.

Shallow and superficial pressure ulcers are treated conservatively. Deep ones, with expressive underlying bone prominence in which no regression is on-going, are better to be treated operatively, if possible. Thus the hospitalisation period and the need for frequent dressings are shortened, preventing enormous scars (*sanatio per secundam intentionem* of the wound) and the risk of subsequent infection. What is also important for the treatment of the prime disease is that the patient can rehabilitate earlier.

There are many methods of excision of the ulcer, ablation of the bone prominence and coverage of the defect with different types of flaps afterwards. Although muscle flaps can be utilized, we assume that their use additionally influences the general condition of the patient (malnutrition and anaemia always co-exist). Thus we find our way of treatment less traumatising and better, if pliable, for decubital ulcers.

The objective of the study was to evaluate the clinical results after an operative treatment of deep decubital ulcers (III and IV grade) with local dermal flaps and to promote the method of their closure.

We paid special attention to ablation of the bone prominence. We used local pivotal adipose-cutaneous flaps in order to cover the cleansed tissue defect. The types of flaps employed were unilateral and bilateral rotation flaps, transposition and bipedicular flaps.

whom 16 (69.6%) had a spinal cord injury (paraplegic). Pressure ulcers in the sacral region dominated with 12 cases (52.2%). The operative techniques that we used were as follows: unilateral rotation flaps (in 7 patients), bilateral rotation flap (in 1 patient), transposition flaps (in 10 patients), bipedicular flaps (in 2 patients), free skin Thiersch autotransplant (in 2 patients) and direct closure of the defect (in 1 patient).

The results advocate the justification of these ways of treatment of pressure ulcers, with few early and late complications.

Key words: pressure ulcer, operation, flaps.

Introduction

Pressure ulcer (*Decubitus Ulcer*) is an area of ulceration and skin (tissue) necrosis, which mainly appears over bony prominences being under temporary and prolonged unrelieved excessive pressure. [5] Patients who cannot avoid long-lasting uninterrupted pressure over their bony prominences may develop it. This group of patients typically includes elderly individuals, neurologically impaired, acutely hospitalized, bedridden and wheelchair-ridden individuals, unconscious, burned patients, etc. Regarding their immobility, they cannot protect themselves from long-lasting overpressure, unless medical staff (or other trained persons) perform that for them. [2] Among patients who are neurologically impaired, pressure sores occur with an annual incidence of 5–8%, with a lifetime risk estimated at 25–85%. Moreover, pressure sores are listed as the direct cause of death in 7–8% of all paraplegics. [1, 8]

Many factors are responsible for the development of pressure sores. However, pressure that leads to ischaemia seems to be the final common pathway. Namely, pressure exerted on the skin, soft tissue, muscles and bones by the weight against a surface beneath and other traumatic forces, such as sheer forces and friction, cause microcirculatory occlusion as the pressure rises above capillary filling pressure which is approximately 32 mm Hg. Thus, the result is ischaemia, which leads to inflammation and tissue anoxia. The latter results in cell death, necrosis and ulceration. Irreversible changes may occur after as little as 2 hours of uninterrupted pressure. [8]

Muscles are more susceptible to ischaemia and hypoxia than overlying skin. Thus the necrotic area is usually wider and deeper than it seems on first inspection. When the patient is febrile, probably the wound has become infected and it has collected pus under the skin. By means of a simple incision, it will drain more than we expect, because the tissue destruction in depth is larger. [4]

Rehabilitation procedures in neurologically impaired patients are postponed when pressure ulcers appear. [10] The exhausting and prolonged morbi-

health care organisation that includes a team approach to polytraumatised patients, the number of surviving individuals with head, spinal cord and orthopaedic injuries is greatly enhanced. Sensibility and motility loss of the lower extremity is an important factor that leads to pressure ulcers. The impact of other factors such as malnutrition, anaemia, hypoproteinaemia, hypovitaminosis, uncontrolled motions, frictions, and quality of the bed-sheets cannot be underestimated, implying a multidisciplinary approach to this problem. Despite a variety of anti-decubital measures and devices such as air-filled beds, low air-loss beds (Flexicair, KinAir), air-fluidized beds (Clinitron, FluidAir) etc., it is hard to say that there is a paraplegic patient who has not had a pressure sore at least for a time. [4, 6, 10]

There are many classification systems for staging pressure ulcers. The most widely accepted system is that of Shea (modification of National Pressure Ulcer Advisory Panel). It comprises 4 stages of ulceration, designed to describe the depth of a pressure sore at the time of examination. Stage I represents intact skin with signs of impending ulceration. ((Non-blanchable erythema, warmth and indurations, ischaemic pallor). Stage II represents a partial-thickness loss of skin involving the epidermis and possibly dermis (may be presented as a blister or superficial ulceration). Stage III represents a full-thickness loss of skin and subcutaneous tissue, but intact underlying fascia. Stage IV represents an ulcer that has extended into the muscle, bone, tendon, or joint capsule. Osteomyelitis and bone destruction may be present. Severe undermining as well as sinus tracts usually exist. [13]

Swallow pressure ulcers (stage I and II) are treated conservatively by use of anti-decubital devices and procedures, ointments, dressings, etc. and represent the majority of all decubital ulcers (about 75%). The rest of about 25% comprise deep pressure ulcers (stage III and IV) which can be treated both conservatively and operatively. When the patient's condition does not allow operation, conservative treatment followed by frequent debridements, fibrinolytic ointments and gels, and a variety of dressings are used. [1] Otherwise, operation is recommended in order to close the tissue defect with flaps. Thus we not only shorten the period of hospitalisation and increase the expenses of frequent dressing that can last for months until closure, but also we enhance and accelerate rehabilitation.

Our interest in this article is the operative aspects of pressure ulcers in stage III and IV, which almost always require a surgical approach. Conservative treatment of pressure ulcers regardless of the stadium, is outside our area of interest.

There are four basic principles of pressure ulcer surgery. They include (1) excision of the ulcer with the surrounding scar and (2) ostectomy to remove

struction, that obliterates the dead space and restores the contour by replacement with like, durable and viable tissue.

Davis (1938) was the first to treat the scar of a healed pressure sore with a tissue flap. [3] After World War II, because of an increased number of wounded people (paraplegic patients), the problems became more serious and a lot of effort has gone into their care. [2] In 1947, Kostrubala and Greeley excised the bony prominence and added padding to the exposed bone with local fascia or muscle-fascia flaps. Debridement of a pressure sore that will be reconstructed is different from debridement of a pressure sore that will be treated conservatively. A radical necrectomy is performed by placing a methylene blue and excising the pressure sore circumferentially, removing all granulation tissue, even from the wound base. What has to be avoided during reconstruction, are sutures under tension as well as the position of suture lines where overpressure is expected. Primary closure of the pressure sore is almost always under tension and is doomed to fail. It can be used in rare cases of small, but deep ulcers, thus preoperative assessment is obligatory. [8, 11]

Patients must be meticulously and obligatorily prepared preoperatively, with nutritional deficiency, anaemia, spasms, and coexisting urinary infection corrected. [7] Patients must have adequate social resources, including pressure-release beds, wheelchair mattresses, and a compliant attitude to prevent recurrence. Intraoperatively, technical points of pressure sore reconstruction must be followed stringently to minimize the risk of complications. The postoperative regimen for the transition from flat bed resting to sitting and from weight-shifting into and out of the wheelchair in the return to daily living must be strict and careful. Wound reconstruction can be considered once the bacterial load has been minimized to fewer than 100,000 organisms to reduce the risk of infectious complications. Furthermore, the patient's social situation and nutritional status must be optimized (albumin level > 3.5 g/mL) to reduce the risk of an adverse outcome. Complications include autonomic dysreflexia, osteomyelitis, pyoarthroses, sepsis, amyloidosis, anaemia, recurrence, urethral fistula, and malignant transformation. [1, 2, 8, 11]

When major burn patients develop a decubital wound, operation in two stages is advised. First, a dermo-epidermal skin transplant (Thiersch transplant) is used to cover the granulated surface. Afterwards, when the general condition of the patient is improved, the transplant is replaced by a local flap. [9]

The holistic treatment approach to pressure ulcers includes correction of hypoproteinaemia (serum albumin level > 3.5 g/ml) and anaemia which implies a high caloric diet, rich in proteins, vitamins and minerals. [4, 12]

In the past 10 years, in the Plastic and Reconstructive Surgery Clinic and the Neurosurgery Clinic, 23 patients with decubital ulcers have been operatively treated. Fourteen of them were males. The average age was 35.8 ± 8.4 years. All of them presented ulcers at stages III and IV.

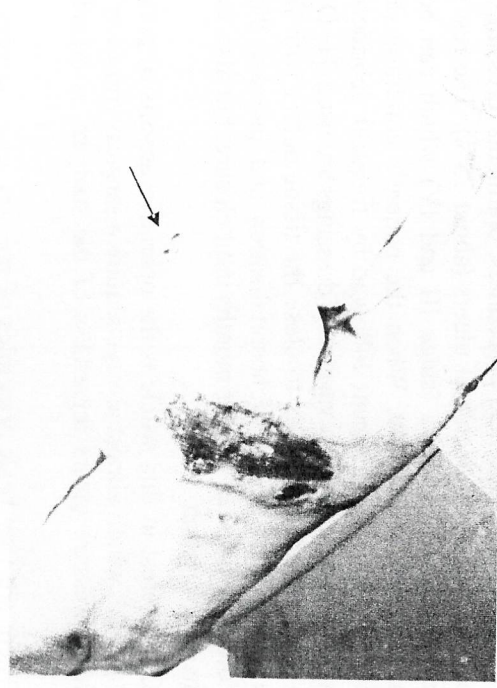

Figure 1 – A forty-six year old female, comatose due to brain injury, developed multiplex back pressure ulcers. The major ulcer in the sacral region is staged as grade IV (sacral bone obvious in the bottom of the wound bed). Evidence

of initial ulcer over the right shoulder blade. Dermal necrosis in right trochanteric protuberance (arrow), staged as grade II ulcer. After the awakening of the patient and a short preparatory period, the excised defect of the sacral pressure ulcer was properly padded with bilateral rotation flaps. Other shallow ulcers were cured conservatively.

Слика 1 – Жена на 46-годишна возраст, во кома заради мозочна повреда, развила повеќе декубитални рани на грбот. Главниот декубитал е во пределот на сакралната регија, е од четвртин стадиум (сакралната коска видлива во дното на раната). Присујна е и почетна декубитална рана во пределот на десниот рамо. Дermal-на некроза во пределот на десниот трохантерично истакнување, градиран како II-стаор улчер на декубитус (стрелка). По враќањето на свесна и краткотрајна подготвителен период, се најпрви дебридман на сакралниот декубитал по што соодветно се обложи и покри со билатерални ротационал резекци

The study was retrospective-prospective.

The inclusive criteria for the operating process were conscious patients, a good general condition, wherein good rehabilitation of patients was expected, efficient social support for patients, expected postoperative prevention of fur-

was optimized, with albumin blood level > 3.5g/ml. Appropriate supplements were administered as well. Local antimicrobial dressings helped to reduce the bacterial load to fewer than 100,000 organisms / g. tissue, justified by frequent microbiologic swabs.

Our operative methods comprised wound excision in healthy tissue, followed by ablation of the bone prominence and defect closure mainly with local cutaneous flaps, but skin transplantation and direct suture of the wound as well.

Mainly, flapping of the ulcer seemed to be the best choice, thus it was used in 20 patients. Operative techniques were unilateral rotation flaps (7 patients), bilateral rotation flaps (1), transposition flaps (10) and bipedicular flaps (used in 2 patients).

After excision of necrotic tissue and ablation of the bone prominence where it was necessary, designing of an appropriate flap followed, depending on the extent of the tissue defect. Evaluating the quality of the surrounding tissue to be used as coverage is of great importance because in the case of these patients, this can be damaged as well. That is why we cannot use only one type of flap in all cases. For that reason, we use a variety of flap patterns. In the case of rotation flaps, we use the neighbouring tissue within the same circle that rotates in order to cover the defect, made from one or both sides of the defect. When a transposition flap is designed, we bring a healthy tissue to cover the defect by raising it from the surroundings with transposition. A bipedicular flap comprises a flap with two radices, large enough to be used as closure. A compressive operative dressing on the flap is used in order to prevent haematoma formation beneath. On the other hand, a loose dressing is applied over the flap base where the blood supply comes from so as not to compromise the circulation. Active drainage follows in each case. The first ward dressing is on the third day after operation. Suction is taken out after 3-6 days depending on the local findings.

When the local environment and the quality of skin and wound assessment do suggest direct suture, it can be used satisfactorily, as we did in one patient. Otherwise, it is not an adequate closure and it is prone to necrosis. Coverage of a clean granulated wound bed with a skin transplant (Thiersch free skin auto transplant) was used in 2 patients, as a temporary defect closure.

A free skin transplant (graft) was taken from flat body areas of undamaged skin such as thigh, arm, buttocks etc., with a special knife called a dermatom. The thickness of the graft was 0.3-0.5 mm and it was placed, sewn and dressed with compression and paraffin gauze to the granulated wound bed. The first postoperative dressing followed after 3-4 days.

All the patients took the operation well. In a one-year follow-up period, in general the local status of the patients was progressing satisfactorily, although there were some early and late complications.

Complications that appeared early were:

- haematoma as a result of suction failure of the drainage system in 3 cases (13.0%);
- infection in 2 cases (8.7%), both in cases with postoperative haematoma;
- suture opening in 3 cases (13.0%), one of which was with postoperative haematoma;
- marginal necrosis in 3 patients (13.0%).

It is obvious that complications issue from one another and they often overlap in the same patients. All in all, 8 patients (about 34%) had complications. Bearing in mind the overall fragility of these patients, it is a reasonable complication rate. With proper intervention, sanitation followed in each case.

Wounds in uncomplicated patients closed properly in 14-18 days.

Recurrence of the ulcer, as a late complication, was manifested in 2 patients (8.7%). It seemed that it had occurred due to inadequate bone prominence ablation. We successfully intervened in both cases.

Discussion

Operative treatment of pressure ulcers is used to achieve fast healing in order to continue the rehabilitation process and prime illness treatment which results in the pressure ulcer. In paraplegic individuals, due to their previous experience of decubital ulcers, the treatment is much easier. Their body is quite atrophic and thinner distally, but shoulders and arms are exercised, thus helping when the lying position is changed, which is important in the prevention of recurrence.

Depending on the wound quality and local skin aspects, all of the mentioned operative methods can be utilized.

We used rotation flaps the most in sacral pressure ulcers. In large wounds we used bilateral rotation flaps.

When transposition flaps are employed, the secondary defect is directly closed, but with its base distally located. Otherwise it can result in locus resistantio minoris for the subsequent evolution of a sciatic pressure ulcer. All the sciatic pressure ulcers were covered with rotation flaps, with ablation and denervation only of the tuber ischia.

g/ml), a wound bacterial load less than 100,000 colony units per gram of wound tissue. The exclusive criteria were coexisting urinary infections, diabetes mellitus, quadriplegia, hyperurexia, sepsis, concomitant injuries and diseases that interfered with the operation. Younger patients have advantages for the operation.

Data received are summarised in the following table:

Table 1 – Табела 1

Distribution of the patients according to the localization, etiology, depth, and dimension of the ulcers

Дистрибуција на пациенти према локализацијата, етиологијата, длабочината и димензијата на декубиталната рана

Localization of the pressure ulcer (with number and percentage)	Etiology for pressure ulcers (with number and percentage)		Stage of the ulcer	Dimension of the ulcer (with number and percentage)	
	Spinal cord injury with paraplegia	Brain injury and comatose patients		III stage - Number: 14 60.9%	> 10 cm ²
Sacral region 12 52.2%	16 69.6%	2 8.7%	IV stage - Number: 9 39.1%	5-10 cm ²	10 43.5%
Trochanteric region 5 21.7%	4 17.4%	1 3.4%		< 5 cm ²	
Ischiadic region 4 17.4%					
Heels 2 8.7%					

According to the etiological factors, patients were divided into the following groups:

- Spinal cord injury with paraplegia – 16 patients;
- Brain injury and comatose patients – 2;
- State after a meningocellae operation – (4);
- Severe burns – 1.

The sacral region as the location of a pressure ulcer predictably dominated in 12 patients, the trochanteric region in 5, the ischiadic region in 4 cases and 2 patients had heel pressure ulcers.

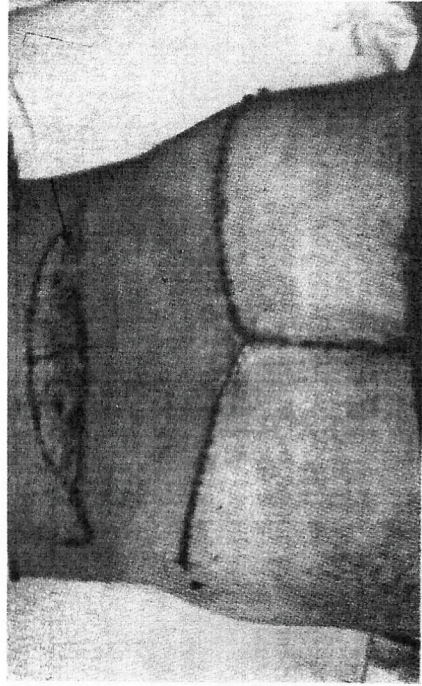


Figure 2 – Bipedicular flaps used to cover round a grade III sacral ulcer 7 × 8 cm gross. Proximal secondary skin defect (arrow) covered with free skin Thiersch transplant, which provides sufficient coverage in this region

Слика 2 – Употреба на бипедикуларни резенки за покривање на кружен сакрален декубитален улкус, со големина 7 × 8 cm, претј степен. Проксималниот секундарен кожен дефект (стрелка) се покри со слободен кожен трансплантат според Thiersch, кој обезбедува доволно квалитетна покривка за овој предел

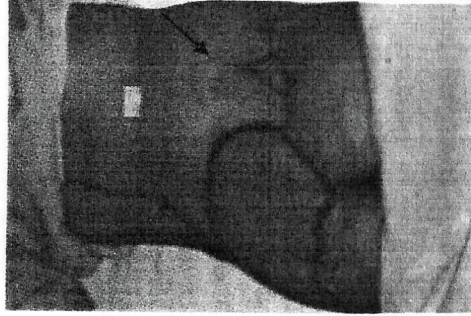


Figure 3 – Unilateral rotation flap used to cover smaller left-lateralized sacral pressure ulcer. Evident scar of conservatively treated shallow ulcer contra laterally (arrow).

Слика 3 – Употреба на унислатерален ротационен резен за покривање на месоцентриран сакрален декубитален улкус. Приклучок лузна на супротивната страна од покривен декубитален улкус конзервативно (стрелка)

combustions. Firstly, a free skin transplant (Thiersch) covers the granulated surface as a temporary coverage until the general condition of the patient improves. It is not a satisfactory long-term coverage due to the vulnerability of the transplant and its other qualities, thus it must be substituted at least with an adiposcutaneous tissue flap.

In cases with operated meningocellae, typical heel pressure ulcers appeared later in the re-socialisation period. When young patients start to play and to put on shoes, due to pressure over the hyposensibilised skin of the feet with misbalanced trophic, a pressure ulcer presents over the bone of the calcaneus. After adequate operation, what we advise are appropriate orthopaedic shoes with concave padding over the ulcer. Thus the pressure is distributed over the larger ulcer-surrounding region, which is sufficient to prevent recurrences.

In all cases, we paid special attention to corrective ablation of the bone prominence where the pressure ulcers appeared, followed by radical excision of the wound bed together with the accompanying sinus tracts, good haemostasis and the use of an active drainage system (1 or 2), which is imperative.

Antibiotics were used only in the presence of concomitant infection.

One of the patients had spastic paraplegia and there was a wound opening.

Conclusion

Pressure ulcers very often become personal, family, health and social problems, particularly in paraplegics, whose number constantly increases. Preventive and conservative anti-decubital and pressure relief measures are not always enough to prevent the appearance or to stop the progress of a pressure ulcer. That is when the operative method can be considered.

There are many different operative methods to treat pressure ulcers (e.g. muscle flaps), but in patients who already suffer malnutrition and anaemia, the use of local cutaneous flaps, if applicable, has far less influence over the general condition of the patients.

We can point out the importance of the ablation of bone prominences which, together with unrelieved overpressure, lead to pressure ulcer in these patients.

REFERENCES

1. Bors E., Commar AE. (1949): Ischial decubitus ulcer surgery; 24: 680.
2. Brunnicardi FC. *et al.* (2005): Schwartz's Principles of Surgery, Eight edition, McGraw-Hill Companies, Inc.; USA, (432-433; 1852-1826).

from www.medscape.com, last updated June 26, 2005.

4. Clark M. (2003): Nutritional Guidelines for Pressure Ulcer Prevention and Treatment. European pressure ulcer advisory panel. Available from www.eupap.org.
5. Converse JM. (1977): *Recons. and Plast. Surg.*; 91: 376.
6. Graf W., Smith J. (1979): *Plast. Surg.*; 50: 818.
7. Gutman L. (1961): The problem of treatment of pressure sores in spinal paraplegies. *Plast. Recons. Surg.*; 24: 237.
8. Revis DR., Jr. (2005): Decubitus Ulcers. Available from www.medscape.com, last updated: October 25, 2005.
9. Tasevski B., Slipac B., Griva B. (1983): Hirusko lecenje dekubitalnih ulceracija; *Zbornik na trudovi VI intersekciski sastanok na Zdruzenieto za plast. i maksilofacijalna hirurgija*, 65-68.
10. Thiyagarian C., Silver JR. (1984): Etiology of pressure sores in patients with spinal cord injury. *Br. Med. J.*; Vol. 289: 1487-88.
11. Wilhelm J. Bradon, Weiner L., Neumeister M. *et al.* (2006): Pressure Ulcers, Surgical Treatment and Principles; Available from www.medscape.com, last updated June 28, 2006.
12. Pressure Ulcer Treatment Guidelines (1998): European Pressure Ulcer Advisory Panel, Available from www.eupap.org.
13. Pressure ulcer staging (2007): National Pressure Ulcer Advisory Panel Available from www.npuap.org.

Резиме

НАШИТЕ ИСКУСТВА ПРИ ЛЕКУВАЊЕТО НА ДЕКУБИТАЛНИ РАНИ СО КОЖНО-ПОТКОЖНИ РЕЗАНКИ ОД ОКОЛИНАТА

Жоговска Е.¹ Новевски Ј.¹ Агаи Љ.² Мирчевски В.² Пеев И.¹ Цокиќ Ѓ.¹

¹Клиника за пластична и реконструктивна хирургија, Скопје, Р. Македонија
²Клиника за неврохирургија, Медицински факултет,
Универзитет „Св. Кирил и Методиј“, Скопје, Р. Македонија

Декубиталните рани се јавуваат кај тешко болни пациенти и состојат на пролонгирана нелекуваност. Чести се во одељенијата за интензивно лекување а кај парализирани. Заради долготрајноста и комплексноста на третманот, превенцијата и нивна свесност се големи.

Понатаму, поручни рани се лекуваат конзервативно. Длабоките декубити кај кои нивна свесност е професионална на коска без регресија на

тивно. Така се скратува и хоспиталниот период како и потребата од чести преврски, а се превенира и санација на раната *per se* *scipiam intentionem* со ризик од консективна инфекција. Воедно, се овозможува брза рехабилитација на болниот што е важно во лекувањето на основната болест.

Има различни методи на ексцизија на декубиталната рана, аблација на коскената проминенција и потоа покривање на дефектот со различни типови на резанки. Иако постојат методи со употреба на мускулни резанки, сметање дека најмалку трауматизирачки за пациентот (кој и така е потхра-нет и анемичен), е начинот на кој ние ја третираме декубиталната рана.

Целта на студијата е евалуација на клиничките резултати по опе-ративен третман на длабоки декубитални рани (степен III и IV) со локални кутани резанки и промоција на овој тип на затворање на декубитусите.

Обративме посебно внимание на аблација на коскената проминен-ција. Користевме локални адипозо-кутани резенки како метод за покри-вање на дебридираниот дефект. Типовите на употребените резанки се рота-циони, од една или двете страни, транспозициони како и бипедикуларните резанки.

Нашата серија вклучува 23 оперирани пациенти во последните 10 години, од кои 16 (69,6%) беа со повреда на р'бетниот мозок (параплеги-чари). Доминираа декубитални рани на сакралната регија (12; 52,2%). Опе-ративните техники кои ги користевме беа ротациони резанки од една [7] и од две страни [1], транспозициони резанки [10], бипедикуларни резанки [2], употреба на слободен трансплантат според Thiertsch [2] и директна сутура на постоечкиот дефект [1].

Резултатите што ги добивме ни говорат за оправданоста на овој начин на лекување на декубитусите, со малку рани и доцни компликации.

Клучни зборови: декубитус, операција, резанки.

Corresponding Author:

Ass. D-r. Peev Igor
Plastic and Reconstructive Surgery Clinic
Medical Faculty
Vodnjanska 17
1000 Skopje, Macedonia
Tel: + 389 2 3111 589
+ 389 75 455 140