



XVII Balkan Congress of Radiology



ESOR Visiting Professorship Programme



October 17th-19th, 2019

Heraklion | Crete | Greece

Aquila Atlantis Hotel

www.bcr2019.gr

UNDER THE AUSPICES



Hellenic College of Radiology



Hellenic Radiological Society



Radiological Society of Crete



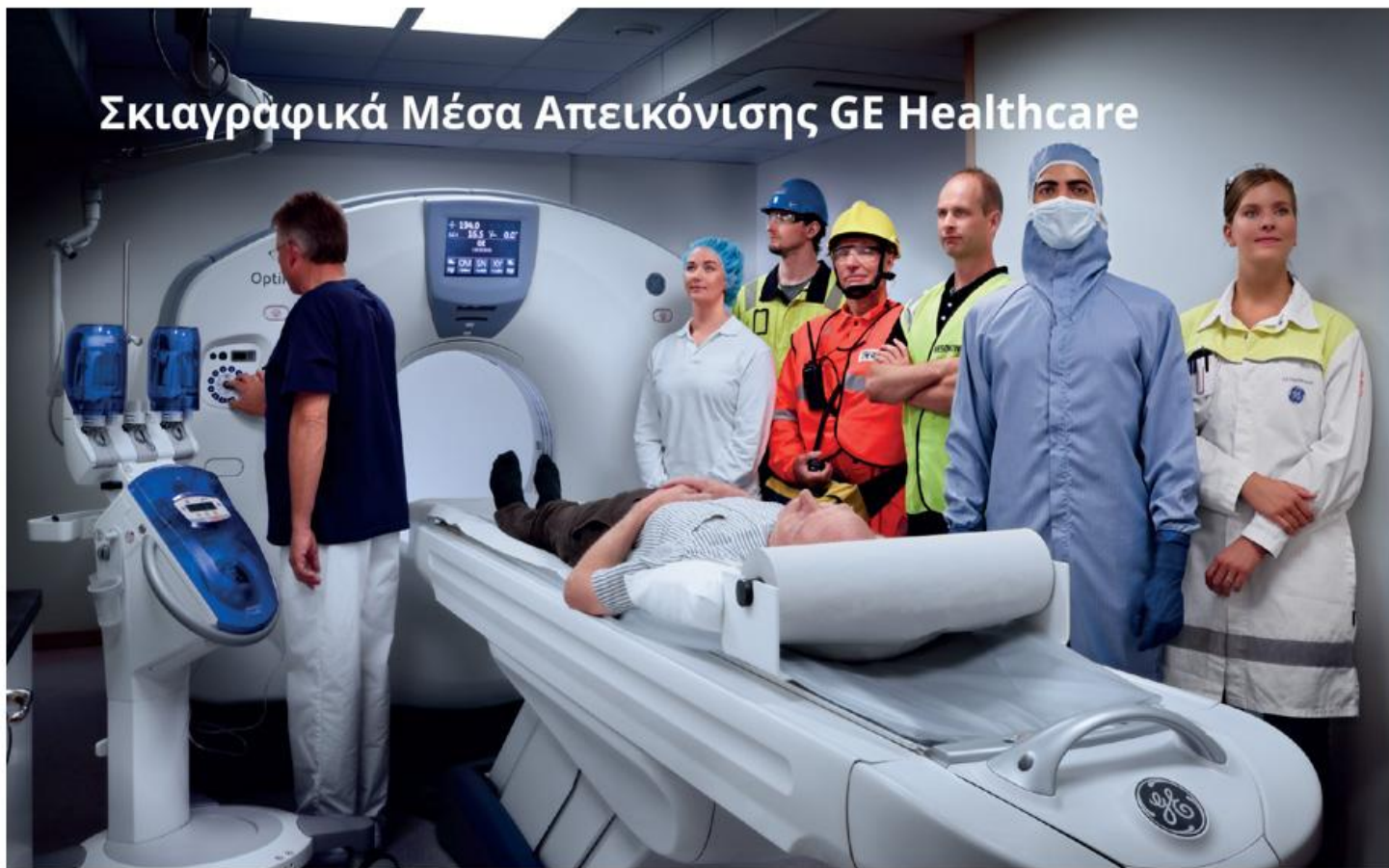University of Crete - Medical School



Medical Association of Heraklion.

• FINAL PROGRAMME • BOOK OF ABSTRACTS

Σκιαγραφικά Μέσα Απεικόνισης GE Healthcare



Η αφοσίωσή μας στην Ιατρική Πράξη

70 εκατομμύρια ιατρικές πράξεις στηρίζονται στα Σκιαγραφικά μας Μέσα Απεικόνισης κάθε χρόνο.

Είναι πολλοί οι άνθρωποι που στηρίζονται σε εμάς ώστε να κάνουν τα πράγματα με τον σωστό τρόπο και αυτή είναι μία ευθύνη την οποία παίρνουμε προσωπικά. Γι' αυτό από την παραγωγή έως την ιατρική πράξη, από τώρα και στο μέλλον, δεσμευόμαστε να σας υποστηρίξουμε να προσδώσετε κλινική αριστεία μέσω της δέσμευσής μας στην επιχειρησιακή υπεροχή.



GE Healthcare AE, Σωρού 8-10, Μαρούσι, Ελλάδα, 15125
www.gehealthcare.com

© 2019 General Electric Company.
GE and the GE Monogram are trademarks of General Electric Company.
07-2019 JB8209/OS


PharmaZac

Αποκλειστικός αντιπρόσωπος
των σκιαγραφικών μέσων
απεικόνισης της GE Healthcare
στην Ελλάδα



WELCOME LETTER

We are very pleased to welcome you to the **17th – XVII Balkan Congress of Radiology** which will take place in **Heraklion, Greece, from October 17th – 19th, 2019**.

The Congress is organized by the Balkan Society of Radiology (BSR) in collaboration with the European School of Radiology (ESOR) and the Hellenic College of Radiology

This event will give a unique opportunity to all participants to update knowledge on important Radiological topics. Radiologists, Medical doctors of different specialties and professionals of other Sciences including Radiologists technologists, and others, can all take part in this Congress and offer their experience and expertise, sharing difficulties and exchanging knowledge. Experts will discuss the key topics in plenary sessions, lectures and workshops. Also, sessions of oral and e-poster presentations will be included. Renowned radiologists not only from the Balkan area, but from the rest of Europe as well, will honor the congress.

We hope that you will enjoy the event and that your interaction with your colleagues from many different countries will stimulate a creative exchange of ideas and will be personally rewarding.

Heraklion is a vibrant city, the hometown and resting place of Nikos Kazantzakis and the largest town of Crete. It distinguishes for its impressive Castle, the Venetian port and the fish taverns along the waterfront. Apart from the town, the entire region is also beautiful and unexplored.

We warmly welcome you to stunning Heraklion !!!!

Prof. Dimitrios Tsetis
 President of BCR 2019
 Professor of Radiology - Medical School of Crete





COMMITTEES

Executive Committee

Ruzica Maksimovic	President
Nicholas Gourtsoyiannis	Honorary President, Chairperson of the Nominations Committee
Dimitrios Tsetis	Past President
Milan Totev	1st Vice President
Nevra Elmas	2nd Vice President
Milos Lucic	Secretary General
Dragos Negru	Treasurer
Charina Triantopoulou	Chairperson of the Program Planning Committee
Cem Calli	Chairperson of the Membership Committee
Nikoleta Traykova	Chairperson of the Bylaws Committee
Nadica Mitreska	Member of Council of National Representatives





Programme Planning Committee

- | | |
|------------------------------|------------------------|
| • Andras Palko | Hungary |
| • Dragos Negru | Romania |
| • Vesna Sarajlic | Bosnia and Herzegovina |
| • Sukru Mehmet Erturk | Turkey |
| • Dragana Djilas | Serbia |
| • Efrosini Papadaki | Greece |
| • Svetlana Antevska Grujoska | Fyrom |
| • Dora Zlatareva | Bulgaria |

Local Organizing Committee

- Aikaterini Adrianaki, Greece
- Evangelos Chartampilas, Greece
- Konstantinos Chlapoutakis, Greece
- Demosthenes Cokkinos, Greece
- Dimitrios Filippiadis, Greece
- Sofia Gourtsoyianni, Greece
- Christina Kalogeropoulou, Greece
- Elias Kehagias, Greece
- Miltiadis Krokidis, UK
- Michalis Mantatzis, Greece
- Efrosini Papadaki, Greece
- Evangelia Pouli, Greece
- Maria Raissaki, Greece
- Konstantinos Spanakis, Greece
- Stavros Spiliopoulos, Greece
- Athina Tsili, Greece





Abstracts Evaluation Committee

- **E. Papadaki Chair**
- A. Andrianaki
- E. Chartampilas
- K. Chlapoutakis
- D. Cokkinos
- D. Filippiadis
- S. Gourtsoyianni
- E. Kehagias
- M. Krokidis
- M. Mantatzis
- A. Tsili

Awards Committee

- C. Calli, Turkey
- M. Lucic, Serbia
- D. Negru, Romania
- P. Prassopoulos, Greece
- V. Sarajlic, Bosnia & Herzegovina
- N. Traykova, Bulgaria

Nomination's Committee

- O. Akhan, Turkey
- V. Hadjidekov, Bulgaria
- A. Palko, Hungary
- P. Prassopoulos, Greece

Council of National Representatives

- N. Bulakbasi, Turkey
- K. Davidovic, Serbia
- A. Chatziioannou, Greece
- M. Nedevska, Bulgaria
- O. Straciuc, Romania
- Z. Mehremic, Bosnia and Herzegovina
- N. Mitreska, Republic of North Macedonia





Membership Committee

- A. Cengic, Bosnia and Herzegovina
- I. Lupescu, Romania
- G. Hadjidekov, Bulgaria
- D. Cokkinos, Greece
- S. Stojanovic, Serbia

Bylaws Committee

- K. Michailidis, Greece
- C. Cevikol, Turkey
- D. Manolova, Bulgaria
- F. Mihai, Romania
- M. Karlovic, Bosnia and Herzegovina

Junior Forum Committee

- **D. Akata, Turkey (Chairperson)**





Faculty

- Akata Deniz (TR)
- Akhan Okan (TR)
- Andrianaki Aikaterini (GR)
- Alexiou Evangelos (GR)
- Antevska - Grujoska Svetlana (MK)
- Arkun Remide (TR)
- Arvaniti Maria (GR)
- Bayraktaroglu Selen (TR)
- Berczi Viktor (HU)
- Beslagic Vanesa (BIH)
- Blazic Ivana (RS)
- Brountzos Elias (GR)
- Bulakbasi Nail (TR)
- Calli Cem (TR)
- Celebi Irfan (TR)
- Cengic Anesa (BIH)
- Cevikol Can (TR)
- Chartampilas Evangelos (GR)
- Chatziioannou Achilleas (GR)
- Chlapoutakis Konstantinos (GR)
- Cokkinos Demosthenes (GR)
- Courcoutsakis Nikolaos (GR)
- Dagdilelis Loukas (GR)
- Daskalogiannaki Maria (GR)
- Detorakis Stathis (GR)
- Dimitropoulos Nickolaos (GR)
- Dineva Svetla (BG)
- Djilas Dragana (RS)
- Efremidis Stavros (GR)
- Elmas Nevra (TR)
- Erturk Mehmet Sukru (TR)
- Filippiadis Dimitrios (GR)
- Georgiev Radoslav (BG)
- Gourtsoyianni Sofia (GR)
- Gourtsoyiannis Nickolas (GR)
- Groudeva Violeta (BG)
- Hadjidekov George (BG)
- Hatakenaka Masamitsu (JP)





- Hayashi Natsuko (JP)
- Hazirolan Tuncay (TR)
- Jefic Svjetlana (BIH)
- Karaali Kamil (TR)
- Karaman Can (TR)
- Karantanas Apostolos (GR)
- Karlović-Vidaković Marijana (BIH)
- Karnabatidis Dimitrios (GR)
- Kehagias Elias (GR)
- Kelekis Alexis (GR)
- Koprivsek Katarina (RS)
- Kozic Dusko (RS)
- Kratimenos Theodoros (GR)
- Krokidis Miltiadis (UK)
- Lazareska Menka (MK)
- Lucic Silvija (RS)
- Lucic Milos (RS)
- Mainta Evgenia (UK)
- Maksimovic Ružica (RS)
- Mantatzis Michail (GR)
- Marias Konstantinos (GR)
- Merhemic Zulejha (BIH)
- Michailidis Konstantinos (GR)
- Mihai Florin (RO)
- Mitreska Nadica (MK)
- Mouloupoulos Lia Antzela (GR)
- Nakajima Yasuo (JP)
- Nass Duce Meltem (TR)
- Nedevska Maria (BG)
- Negru Dragos (RO)
- Njagulj Vesna (RS)
- Obuz Funda (TR)
- Onur Mehmet Ruhi (TR)
- Orguc Sebnem (TR)
- Ozmen Mustafa (TR)
- Palko András (HU)
- Papadaki Efrosini (GR)
- Papaioannou Sofia (GR)
- Papanikolaou Nickolas (PG)
- Peteinarakis Ioannis (GR)
- Prassopoulos Panagiotis (GR)
- Sabir Nuran (TR)





- Sarajlic Vesna (BIH)
- Secil Mustafa (TR)
- Sirakov Stanimir (BG)
- Sotirovic - Senicar Slavica (RS)
- Spanakis Konstantinos (GR)
- Spirovski Milena (RS)
- Stojanovic Sanja (RS)
- Stojovska - Jovanovska Elizabeta (MK)
- Tavernaraki Kyriaki (GR)
- Totev Milan (BG)
- Traykova Nikoleta (BG)
- Triantopoulou Charikleia (GR)
- Tsetis Dimitrios (GR)
- Tsili Athina (GR)
- Tsitouridis Ioannis (GR)
- Tunaci Atadan (TR)
- Uberoi Raman (UK)
- Vasilevska - Nikodinovska Violeta (MK)
- Vjolca Aliji (MK)
- Vlychou Marianna (GR)
- Vucaj - Cirilovic Viktorija (RS)
- Xydis Vasileios (GR)
- Yarmenitis Spyros (GR)
- Zlatareva Dora (BG)

Official Congress Organizer & Travel Agency



105 Michalakopoulou str., GR11527, Athens – Greece

Tel.: +30 210 7711673, Fax: +30 210 7711289

Email: bcr2019@prctravel.gr

Web Site: www.bcr2019.gr





ACKNOWLEDGEMENTS

The Organizing Committee of the 17th Balkan Congress of Radiology (BCR 2019) wishes to acknowledge the contribution of the following companies for their financial support:



M.S. Jacovides Hellas





GENERAL INFORMATION

About Crete!!! The birthplace of El Greco

A vibrant small metropolis, a Port city, the Capital city of Crete, the 5th largest city in Greece.

Heraklion is the largest urban centre in Crete with approximately 200,000 people, the capital of the region and the economic centre of the island. The town enjoys of a dynamic and imaginative combination of natural beauty climate, strategic position, cultural heritage and scientific background what has created an appropriate environment to support a particular mechanism with which to in add value to the broader entrepreneurial activity in the region and stimulate the local economy.

Today Heraklion is the top choice for tourist destinations in the Mediterranean thanks to strategic geopolitical position connecting three continents and many different cultures; furthermore the city is also the commercial and scientific centre of the island.

The sea, the historical sites, the excellent food and the welcoming friendly people make this place a delightful place to visit. Coming to Heraklion for the first time, the visitor nowadays may be somewhat surprised by the changes that are taking place in Crete's capital city; Heraklion is celebrating its rich history and moving onwards to a future full of potential.

If you begin a walk around Heraklion, starting at the fishing harbor close to the Rocca al Mare, but is now known by its Turkish name, Koules. It has a mixed history; for centuries it was used as protection against invaders, as were the great city walls and ditches. These are among the longest city walls in Europe.

With its huge dark hallways and cells, the fortress was also a prison to many Cretan rebels and those who broke the rules imposed by successive occupiers of Crete. Koules is built on two tiers and offers a commanding view of Heraklion from the battlements. Nowadays, the harbor itself is home to brightly colored fishing boats and busy tavernas selling fresh fish.

Looking back towards the city you will see the strong arches which housed boats under repair and were used as an arsenal for storing guns and gunpowder. The greatest threat to the Venetian stronghold of Heraklion, or Candia, as it was named, was thought to come from the seaward side of the city, and indeed, many naval skirmishes were fought off this coast. The view northward takes in the uninhabited island of Dia, where evidence of ancient Minoan settlement (approx 2700-1450 BC) was found by the diver, Jacques Cousteau.

Genuine hospitality that is truly unforgettable

Cretan hospitality shares the characteristics of its famous landscape; grand, generous and infinitely welcoming. Families are only too happy to share the island's many specialties – a dakos salad, free-flowing raki or the experience of the mantinades, poems often accompanied by a Cretan lyre or lute. Wise old men are only too happy to recount memories of the island's rich, and often troubled, past or tales of the vendettas between feuding families. There are also stories of the great loves and friendships that characterise a proud and family-orientated people. You, too, can become part of this unique island: Cretan hospitality will be unforgettable!





Dates

17-19 October, 2019 – Heraklion Crete, Greece

Congress Venue

Aquila Atlantis Hotel

2, Ygias Str.

71 202 – Heraklion, Crete

T. +30 2810 229103

F. +30 2810 226265

Email: info.at@aquilahotels.com

Web Site: <https://theatlantishotel.gr>

BCR 2019 & ESOR Course

Registration categories	Late Registration from July 6 th , 2019 onwards
Specialists	€ 290
Residents-in-training*	€ 225
Technologists Radiologists*	€ 125
Company Representatives	€ 290
Medical Students**	€ 50
Accompanying Persons	€ 75

BCR 2019 (only)

Registration categories	Late Registration from July 6 th , 2019 onwards
Specialists	€ 225
Residents-in-training*	€ 140
Technologists Radiologists*	€ 100
Company Representatives	€ 215
Medical Students**	€ 40





BCR 2019 & ESOR Course

Accompanying Persons	€ 75
----------------------	------

ESOR Course (only)

Registration categories	Late Registration from July 6 th , 2019 onwards
Specialists	€ 150
Residents-in-training*	€ 125
Technologists Radiologists*	€ 115
Company Representatives	€ 150
Medical Students**	€ 40

Registration fees include VAT. 24%

* Residents-in-training and Technologists must submit a certificate of employer, upon registration.

** Medical Students must submit a copy of student identity card, upon registration.

Registration Fee for **BCR 2019 & ESOR Course and BCR 2019 (only)** include:

- Admittance Opening Ceremony & Welcome Cocktail
- Admittance to all Congress Sessions
- Admittance to the Exhibition area
- Coffee during official breaks
- Full Congress related material

Registration Fee for **Accompanying Persons** includes:

- Opening Ceremony & welcome cocktail
- Access to the Exhibition Area

Registration Fee for **ESOR Course (only)** includes:

- Admittance to the Course only, on October 17th, 2019
- Admittance to the Exhibition area, only on October 17th, 2019
- Coffee during official breaks, only on October 17th, 2019
- Light Lunch, only on October 17th, 2019
- Course related material





Social Events

Opening Ceremony

The Opening Ceremony, followed by the Welcome Reception will take place on Thursday, October 17th 2019 at MINOS Hall of Aquila Atlantis Hotel at 18.30h.

Official Language

The official language of the Congress is English. No simultaneous translation will be provided.

Scientific and Commercial Exhibition

A comprehensive Exhibition will run during the Congress. The Exhibition will be at the Congress venue.

Congress Bag

Upon registration, participants will receive a badge with their names written on. Delegates are requested to wear their badge during all sessions. Entrance to the Congress halls, e-posters and exhibition areas will not be permitted to any persons without a congress badge, which will be scanned with a barcode system.

Badges

For identification purposes and admission to session halls, participants are requested to wear their badges, which will be given to them upon registration, at all times. Admission to the Congress areas (meeting halls, e-poster and exhibition areas) will not be allowed without badge identification.

Certificate of Attendance- ESOR Course

The certificate will be handed out to all registered participants on Thursday, October 17th 2019 by the end of the Course at 18.00hs

Certificate of Attendance-BCR 2019

The certificate will be handed out to all registered participants on Saturday, October 19th 2019 from 10:00am until 19.30pm, **after completing the evaluation form** provided by the Congress Secretariat.

Accreditation

The 17th Balkan Congress of Radiology has been granted 15 European CME credits (ECMEC[®]s) by the European Accreditation Council for Continuing Medical Education EACCME[®]





Congress Secretariat Opening Hours

Thursday, October 17 th 2019	08.00 - 18.00
Friday, October 18 th 2019	08.00 - 19.30
Saturday, October 19 th 2019	08.00 - 19.30

Speakers Ready Desk

A Speakers Ready Desk will be available for presenters, every day during Congress. Please note that you need to bring your presentation (PPT or PDF format) on a CD (not a ZIP disk!) or on a USB stick. Personal laptops are not allowed.

We advise you to do this the day before your presentation or, if not possible, early in the morning of the day of your presentation.

Wireless Access

The wireless network will be freely available by all the congress venue public areas.

Smoking

Smoking is not allowed within the Congress Venue. You can smoke though outside the building.

Travelling - Passport and Visas

Visas are required from citizens of some foreign countries. Participants should check with their travel agents, Greek consulate offices or diplomatic missions in their own countries whether or not visas are required.

Liability and Insurance

The organizers cannot be held responsible for accidents which may occur to participants or accompanying persons, or for any damage, loss of personal property or cancellation expenses. Participants are kindly advised to carry out their own insurance arrangements during their stay in Greece.

Useful Information

Time

GMT+2 (GMT +3 between last Sunday in March and last Sunday in October).

Climate

The climate in Greece is typically Mediterranean with warm and dry summers and mild winters. Heraklion has a typically Mediterranean climate. Situated by the sea, the city's climate is directly affected by it.

For more information please visit: www.freemeteo.com or www.bbc.co.uk/weather/.





Electric Current

Electricity in Greece, as in the rest of Europe, comes out of the wall socket at 220volts alternating at a 50cycles per second. The sockets are for plugs with two or three round pins in a row (CEI 23-16/VII and CEE 7/4 German style Schuko). Appliances from North America require a transformer and British ones an adaptor.

Currency

Euro is the official currency in Greece. Money exchange is available in most of banks. There are plenty of cash dispensers in Heraklion. Major international credit cards are widely but not always accepted in Greece (check in advance in small restaurants), and are not commonly used for small amounts. Banks are open from Monday to Thursday 08:00-14:30 and on Friday 08:00 – 14:00.

Credit Cards

All major credit cards are accepted in almost all hotels, shops and restaurants. Stickers in the front windows will advise you as to which cards are accepted.

Banks and ATMs

Banks are open from Monday to Thursday, 8:00-14:30 hrs and on Friday, 8:00-14:00 hrs; on Saturdays and Sundays they are closed. ATMs are widely available all over the country. For further details while in Greece please consult your hotel concierge.

International Calls

Dial 00 + country code + area code + phone number. The international code number from abroad is + 30 followed by the number code of the person you are calling, comprehensive of the '2810' of Heraklion region.

Transfer from Heraklion Airport to the city centre

The airport is situated about 5km east of Heraklion city. You can use the public bus (rate varies upon 1.20€ - 2€ depending on purchase) or take a taxi (20-22€ approximately).

The website of Nikos Kazantzakis International Airport, Heraklion airport is: www.heraklion-airport.info

Public Transportation

Public buses serve the whole island of Crete, even the villages. The buses (called KTEL) are not expensive and the routes are rather frequent. Most of the times you can by a ticket on the bus.





City Buses (blue) serving the city of Heraklion from early morning until late evening. Starting from the port city services operated in the archaeological site of Knossos. Information: 2810-226065 and 220795. Detailed information on ticket options, bus routes and timetables is available at: <http://astiko-irakleiou.gr>.

Intercity Buses (green) connecting Heraklion with all the cities of Crete for easy movement of residents and visitors. Web: <http://www.ktelherlas.gr>.

Standard bus fares:

1.20€ (from/to Heraklion Airport and/or Heraklion Port) – Valid for a single trip (purchased at a point of sale, i.e., Kiosk) or 2,20€ (when issued by ticket vending machines on the bus)

1.70€ (from/to Knossos Palace) (purchased at a point of sale) – Valid for a single trip

TAXI

Taxis from Heraklion can take you at any place on the island, as everything can be accessed within a day's round trip. The cost is reasonable, especially if you share the taxi with one or two other people. You can ask for the price of your journey when getting on the taxi since most routes have a flat rate. Please take into consideration that the route between Heraklion Airport and Aquila Atlantis hotel costs around 16€. Between 00:00 and 05:00 a double fare will be applicable.

Useful Telephone Numbers

Tourist Police: 171

Police Emergency Line: 100

Fire Emergency: 199

Ambulance Service: 166

SOS Doctors: 116

Emergency Hospitals / Pharmacies: 14944

European Emergency Service: 112

Telecommunications info: 11888

Weather: 14944

Time: 14844

Heraklion Airport: +30 2810-397129, 397136 (info 24hrs)

Tourist Police in Heraklion: +30 2810-283190

Service of Lost or Stolen Credit Cards

American Express: (+30) 210 3397250

MasterCard: 00800118870303

Diners: (+30) 210 9290200

Visa: 00800116380304

Eurocard: (+30) 210 9503673



The background of the page is a classical painting. In the center, a large, spotted animal, possibly a lion or a large dog, is depicted in a dynamic, almost dancing pose. To its left, a smaller, pale figure is shown in a similar, graceful movement. The scene is set against a light blue background. The painting is framed by decorative borders at the top and bottom, featuring repeating patterns of stylized figures and motifs in earthy tones.

SCIENTIFIC PROGRAMME

SCIENTIFIC PROGRAMME



THURSDAY, OCTOBER 17TH, 2019

ESOR Visiting Professorship Program within the ESR Support Initiative

HALL PASIPHAE-HI-APOLLON

“Breast Imaging”

08:00-08:45	Registration
08:45-09:00	Welcome and introduction
09:00-09:30	Tomosynthesis and contrast-enhanced spectral mammography <i>E. Fallenberg, Munich (DE)</i>
09:30-10:00	Ultrasound, elastography and more <i>F. Kilburn-Toppin, Cambridge (UK)</i>
10:00-10:30	Ultrafast and non-contrast breast MRI <i>R. Mann, Nijmegen (NL)</i>
10:30-10:50	Coffee Break
10:50-13:00	Workshops <i>E. Fallenberg, F. Kilburn-Toppin, R. Mann</i>
13:00-14:00	Lunch Break
14:00-14:30	Screening: who, when and how? <i>F. Kilburn-Toppin, Cambridge (UK)</i>
14:30-15:00	Preoperative staging and tumour localisation <i>E. Fallenberg, Munich (DE)</i>





THURSDAY, OCTOBER 17TH, 2019

15:00-15:30 Neoadjuvant chemotherapy monitoring
R. Mann, Nijmegen (NL)

15:30-15:50 Coffee Break

15:50-18:00 Workshops
F. Kilburn-Toppin, E. Fallenberg, R. Mann

18:00-18:15 Certificate of attendance





THURSDAY, OCTOBER 17TH, 2019

Hall A | MINOS I-II

18:30 – 20:05	Opening Ceremony
	Addresses:
18.30-18.35	Prof. D. Tsetis (GR) President of BCR 2019
18.35-18.40	Dr. J. Tsitouridis (GR) President of Hellenic Radiological Society
18.40-18.45	Prof. A. Karantanas (GR) On behalf of Hellenic College of Radiology
18.45-18.50	Prof. G. M. Kontakis (GR) Dean of Medical School University of Crete
18.50-18.55	Prof. O.I Zoras (GR) Rector of University of Crete
18.55-19.05	"The Leading Role of ESR" Prof. D. Akata (TR) On behalf of ESR
19.05-19.25	Honorary Lecture Cardiovascular magnetic resonance imaging: at the heart of cardiac function? Prof. R. Maksimovic (RS) President of Balkan Society of Radiology
19.25-19.45	Keynote Lecture Mentorship in Radiology in the era of AI Prof. N. Gourtsoyiannis (GR) Honorary President of Balkan Society of Radiology
19.45-20.05	Cretan Folkloric Group "Aoritis"

Welcome Reception





FRIDAY, OCTOBER 18TH, 2019

Hall A | MINOS II

08:00-09:00
Registration
09:00-10:30
Gastrointestinal Radiology I

 Moderators: **S. Gourtsoyianni (GR), M. Daskalogiannaki (GR)**

Imaging protocols in Dysphagia Management

L. Dagdilelis (GR)

GIST tumors: imaging characteristics

E. Chartampilas (GR)

MR imaging of perianal disease

E. Mainta (UK)

MR Enterography - how I do it

S. Gourtsoyianni (GR)
10:30-11:00
Coffee Break
11:00-12:30
Chest Imaging I

 Moderators: **D. Filippiadis (GR), V. Sarajlic (BIH)**

Imaging of the pulmonary nodules

S. Bayraktaroglu (TR)

Lung biopsy: indications, technique, common and rare complications

V. Sarajlic (BIH)

Percutaneous ablation of lung lesions

D. Filippiadis (GR)

Imaging of interstitial lung disease: Where are we now?

A. Tunaci (TR)
12:30-13:00
Honorary Lecture

 Moderator: **N. Gourtsoyiannis (GR)**

Medical Imaging: from radiography to radiomics an interesting journey

S. Efremidis (GR)




Hall A | MINOS II

13:00-13:45
PHILIPS SATELLITE LECTURE

Interventional Radiology, Vascular studies and cases

 Moderators: **D. Tsetis (GR)** – **E. Brountzos (GR)**

The Image Guided Therapy journey to "Zero" Patient dose

S. Slijderink (NL)
13:45-14:30
Break
14:30-16:00
Oncologic Imaging

 Moderators: **S. Stojanovic (RS)** - **I. Tsitouridis (GR)**

Imaging in pharyngeal cancer: key points

N. Traykova (BG)

Diagnostic-CT and MRI criteria for monitoring biologic therapy response of colorectal metastatic liver lesions

V. Vucaj Cirilovic (RS)

Staging ovarian carcinoma, keys and pitfalls

S. Stojanovic (RS)

Hybrid Imaging in Oncology

S. Lucic (RS)
16:00-16:30
Coffee Break
16:30-18:00
Head And Neck I

 Moderators: **D. Kozic (RS)** - **M. Mantatzis (GR)**

Imaging of laryngeal cancer

I. Celebi (TR)

Imaging of oral cavity and oropharyngeal tumors

M. Nass Duce (TR)

Imaging of orbital pathologies

D. Kozic (RS)

Endovascular treatment of wide neck aneurisms on anterior circulation

M. Lazareska (MK)




Hall A | MINOS II

18:00-19:00

Breast Imaging

Moderators: **V. Beslagic (BIH)** – **N. Dimitropoulos (GR)**

Breast cancer screening in Japan

Y. Nakahima (JP)

Imaging of male breast

S. Antevska Grujoska (MK)

What is new in radiology of breast cancer?

D. Djilas (RS)

19:00

EC Meeting & General Assembly





FRIDAY, OCTOBER 18TH, 2019

Hall B | PASIPHAË I

09:00-10:30
Musculoskeletal Radiology I

 Moderators: **A. Karantanas (GR) - V. Vasilevska - Nikodinovska (MK)**

Spondyloarthropathies-imaging spectrum

R. Georgiev (BG)

Postoperative knee - MRI after ACL reconstruction

V. Njagulj (RS)

MR imaging of the ankle

C. Cevikal (TR)

Imaging of the diabetic foot

N. Sabir (TR)
10:30-11:00
Coffee Break
11:00-12:30
Upogenital Radiology I

 Moderators: **D. Akata (TR) – M. Spirovski (RS)**

Diffusion weighted imaging of female pelvis

D. Akata (TR)

A paradigm shift in prostate MRI

M. Spirovski (RS)

PIRADS v 2 and Gleason score - side by side or miles apart

S. Dineva (BG)

Imaging of testicular tumors

E. Stojovska Jovanovska (MK)
13:00-14:30
Break




FRIDAY, OCTOBER 18TH, 2019

Hall B | PASIPHAE I

14:30-16:00 Junior Forum Session

Moderators: **D. Akata (TR)** – **K. Chlapoutakis (GR)**

Pearls and pitfalls in the imaging of female pelvis: indicators for diagnosis

D. Akata (TR)

How to interpret a mammogram: traps and pitfalls

N. Dimitropoulos (GR)

Characterization of liver lesions: Benign or malignant?

I. Blazic (RS)

Acute Abdomen: decision making in diagnostic imaging step by step

M. R. Onur (TR)

16:00-16:30 Coffee Break

16:30-18:00 Interventional Radiology I

Moderators: **E. Broutzos (GR)** – **D. Karnabatidis (GR)**

Fibroid embolisation

V. Berci (HU)

Endovascular treatment of portal hypertension

E. Broutzos (GR)

Endovascular Treatment of Hemodialysis Fistulas

D. Karnabatidis (GR)

Percutaneous Urological Interventions

E. Kehagias (GR)

18:00-19:00 Image Interpretation session

Moderator: **M. Vlychou (GR)**

Speaker: **D. Cokkinos (GR)**





FRIDAY, OCTOBER 18TH, 2019

Hall C | MINOS I

09:00-10:30

Neuroradiology I

Moderators: **D. Zlatareva (BG) - E. Papadaki (GR)**

Cerebellar imaging - variety of surprises and challenges

D. Zlatareva (BG)

Gadolinium deposition in the brain

E. Papadaki (GR)

Imaging challenges of the Brain Death

S. Jeftic (BIH)

Mechanical thrombectomy in acute stroke-our initial experience

A. Vjolca (MK)

10:30-11:00

Coffee Break

11:00-12:30

Hepatobiliary Radiology I

Moderators: **O. Akhan (TR) – F. Mihai (RO)**

HCC in chronic liver diseases

E. Alexiou (GR)

HCC: the role of local ablation

O. Akhan (TR)

Diffuse liver diseases

S.M. Erturk (TR)

IFN free treatment of the cirrhotic patients

F. Mihai (RO)

13:00-14:30

BREAK





14:30-16:00

Oral Presentations Session I Interventional Radiology

Moderators: *M. Krokidis (UK) -D. Filippiadis (GR)*

OP 022

BILIARY ANASTOMIC LEAKAGE FOLLOWING ELECTIVE LAPAROSCOPIC CHOLECISTECTOMY: NON-INVASIVE DETECTION USING GD-EOB- DTPA ENHANCED MR CHOLANGIOGRAPHY

Kemal Murat Haberal¹, Mehmet Coskun¹1. School of Medicine, Department of Radiology, Baskent University,
Ankara, Turkey

OP 023

PERCUTANEOUS US-GUIDED MWA OF SMALL LIVER HCC: PREDICTORS OF OUTCOME AND RISK FACTORS FOR COMPLICATIONS FROM A SINGLE CENTER EXPERIENCE

Pierpaolo Biondetti¹, Anna Maria Ierardi¹, Enrico Maria Fumarola¹,
Gianpaolo Carrafiello¹¹Diagnostic and Interventional Radiology Department, ASST Santi Paolo
e Carlo, San Paolo Hospital, University of Milan, Italy

OP 024

PERCUTANEOUS MICROWAVE ABLATION OF RENAL ANGIOMYOLIPOMAS IN TUBEROUS SCLEROSIS COMPLEX TO IMPROVE THE QUALITY OF LIFE

Mario Petrillo¹, Pierpaolo Biondetti¹, Anna Maria Ierardi¹, Salvatore
Alessio Angileri¹, Gianpaolo Carrafiello¹¹Diagnostic and Interventional Radiology Department, ASST Santi Paolo
e Carlo, San Paolo Hospital, University of Milan, Milan, Italy

OP 025

PERCUTANEOUS MICROWAVE ABLATION OF UTERINE FIBROIDS: CORRELATION BETWEEN SHRINKAGE OF THE LESION AND SYMPTOMS

Anna Maria Ierardi¹, Pierpaolo Biondetti¹, Mario Petrillo¹, Giuseppe
Granata¹, Gianpaolo Carrafiello¹¹Diagnostic and Interventional Radiology Department, ASST Santi Paolo
e Carlo, San Paolo Hospital, University of Milan, Milan, Italy

OP 026

PERCUTANEOUS COMPUTED TOMOGRAPHY GUIDED RADIOFREQUENCY ABLATION FOR TREATING METASTATIC LYMPH NODES: A SINGLE CENTER'S EXPERIENCE

Efthymiou E. Filippiadis D. Theodosis A. Reppas L. Palialexis K.
Spiliopoulos S. Kelekis A. Brountzos E. Kelekis N.2nd Department of Radiology, University General Hospital "Attikon",
Medical School, National and Kapodistrian University, Athens Greece



- OP 027** **SINGLE CENTER PROSPECTIVE STUDY EVALUATING PAIN TOLERABILITY DURING LIVER MICROWAVE ABLATION WITH CONTINUOUS OR PULSED ENERGY DELIVERY MODE**
 Efthymiou E. Filippiadis D. Mazioti A. Velonakis G. Kelekis A. Brountzos E. Kelekis N.
 2nd Department of Radiology, University General Hospital "Attikon", Medical School, National and Kapodistrian University, Athens Greece
- OP 028** **TRANSCATHETER RENAL INTERVENTIONS : A REVIEW OF EMERGENCY PROCEDURES AND SCHEDULED ONES**
D. Stefanou, E. Antonakou, A. Tsokas, P. Ioannidi, D. Tomais, I. Kalogeropoulos, T. Kratimenos
 Radiology Department Interventional Radiology Department, 'Evangelismos' Hospital
- OP 029** **CROSS-SECTIONAL IMAGING OF IATROGENIC COMPLICATIONS AFTER PERCUTANEOUS NEPHROLITHOTOMY (PCNL) AND URETEROSCOPY (URS)**
 Kaitartzis C., Arvaniti M., Ouroumidou K., Delianidou A., Panagasidou I., Daniil G., Torounidis I.
 Radiology Department of General Hospital of Thessaloniki "G. Gennimatas", Greece
¹Department for diagnostic and interventional radiology, City General Hospital "8th September", Skopje, Republic of North Macedonia
- OP 030** **ENDOVENOUS RADIOFREQUENCY ABLATION OF THE ABOVE-KNEE SAPHENOUS VEIN AND SEQUENTIAL FOAM SCLEROTHERAPY OF THE BELOW-KNEE SAPHENOUS VEIN IN VENOUS REFLUX: A SINGLE CENTER EXPERIENCE**
 Colakoglu Bulent
 Vkv Amerikan Hospital Radiology – Nisantasi, Istanbul Turkey
- OP 031** **SINGLE CENTER EXPERIENCE IN MALIGNANT SVCS STENTING USING DIFFERENT NITINOL STENT TYPES**
 Nikolas Matthaiou¹, Nikolaos Galanakis¹, Elias Kehagias¹, Nelly Kcholcheva¹, Dimitrios Tsetis¹
 1. Department of Medical Imaging, Unit of Angiography and Interventional Radiology, University Hospital of Heraklion, Iraklion, Greece





OP 032

USE OF NEW GENERATION DUAL LAYER MICROMESH STENTS FOR CAROTID ARTERY STENTING – OUR EXPERIENCE”

Aleksandar Gjoreski¹, Filip Risteski¹, Ivona Jovanoska¹, Petar Atanasovski¹, Sanja Zikova Dzambazovska¹

16:00-16:30

Coffee Break

16:30-18:00

Emergency Radiology - Trauma

Moderators: **A. Palko (HU)** - **A. Chatziioannou (GR)**

MDCT technique in the diagnosis of polytrauma

A.Palko (HU)

Pelvic trauma-the role of interventional radiology

A.Chatziioannou (GR)

Imaging of orbital trauma

A. Cengic (BIH)

18:00-19:00

Radiomics/ Deep learning/ Artificial intelligence

Moderators: **N. Papanikolaou (PG)** - **S.M. Erturk (TR)**

Machine learning

N. Papanikolaou (PG)

Deep learning

K. Marias (GR)

Modern applications of DWI in oncologic imaging

M.Hatakenaka (JP)





FRIDAY, OCTOBER 18TH, 2019

Hall | PASIPHAË II

09:00-10:30

Oral Presentations
ULTRASONOGRAPHY

Moderators: *S. Yarmenitis (GR)-D. Cokkinos (GR)*

OP 001

**RADIOLOGICAL-PATHOLOGICAL CORRELATION OF THYROID NODULE
 ULTRASOUND AND CYTOLOGY USING THE TIRADS AND BETHESDA
 CLASSIFICATIONS**

Serdar Aslan¹, Suleyman Ozdemir² ¹ Turhal State Hospital, Radiology
 Clinic, Turhal, Tokat, Turkey ² Turhal State Hospital, Pathology Clinic,
 Turhal, Tokat, Turkey

OP 002

**ACOUSTIC RADIATION FORCE IMPULSE ULTRASOUND IMAGING IN
 DIAGNOSING CERVICAL CARCINOMA**

Kemal Murat Haberal¹

1. Department of Radiology, Ankara Hospital, School of
 Medicine, Baskent University, Ankara, Turkey

OP 003

**ULTRASOUND ELASTOGRAPHY OF BREAST LESIONS: CORRELATION
 OF STRAIN AND SHEAR WAVE ELASTOGRAPHY WITH
 HISTOPATHOLOGICAL FINDINGS**

Valentin Ivanov¹, Gavril Nakov¹, Magdalena Peneva¹

¹ – Department of Radiology, Acibadem City Clinic Tokuda Hospital,
 Sofia, Bulgaria

OP 004

**THE PREDICTION OF INFRAVESICAL OBSTRUCTION WITH
 SONOGRAPHIC ESTIMATION OF BLADDER WEIGHT**

Kulali Fatma, Kulali Safak Firat

Radiology Department, University of Health Sciences Umraniye Training
 and Research Hospital, Itsnabul, Turkey

OP 005

**THE VALUE OF SHEAR WAVE ULTRASONOGRAPHY IN CALCULATING
 ELASTOGRAPHIC VALUES IN LIVER PATHOLOGIES**

Nalbant Mustafa Orhan, Ercan Inci

Dr. Sadi Konuk Research and Training Hospital





- OP 006** **SONOGRAPHIC EVALUATION OF PEDIATRIC LOWER ABDOMINAL PAIN**
 Kaitartzis C., Nalmpantidou C., Arvaniti M., Daniil G., Vekiou R.,
 Panagasidou I., Eleftheriadou M.
 Radiology Department of General Hospital of Thessaloniki "G.
 Gennimatas", Greece
- OP 007** **CONTRAST ENHANCED ULTRASOUND IS USEFUL FOR IMAGING
 EMERGENCY SCROTAL PATHOLOGY**
 Pavlos Ampatzis, Demosthenes Cokkinos, Anastasia Anagnostopoulou,
 Alexandros Letsos, Christina Aslanidi, Sofia Tsolaki, Panagiotis Tserotas,
 Ekaterini Tavernaraki, Ioannis Kalogeropoulos
 Radiology Department, Evangelismos Hospital. Athens, Greece
- OP 008** **ARE WE OVER-PERFORMING FAST ULTRASOUND OF THE ABDOMEN IN
 PATIENTS WITH NO INDICATION?**
 Christina Aslanidi, Demosthenes Cokkinos, Sofia Athanasiou, Pavlos
 Ampatzis, Panagiotis Petaloudis, Sarantis Georgakopoulos, Sofia Tsolaki,
 Eleni G Antypa, Ioannis Kalogeropoulos
 Radiology Department, Evangelismos Hospital. Athens, Greece
- OP 009** **CONTRAST ENHANCED ULTRASOUND IS USEFUL FOR IMAGING
 INFECTION, RUPTURE AND ABSCESES OF THE GALLBLADDER AND
 BILIARY TREE**
 Sofia Athanasiou, Demosthenes Cokkinos, Anastasia Anagnostopoulou,
 Alexandros Letsos, Panagiotis Petaloudis, Sarantis Georgakopoulos, Eleni
 G Antypa, Grigoris Skoufogiannis, Ioannis Kalogeropoulos
 Radiology Department, Evangelismos Hospital. Athens, Greece
- OP 010** **CONTRAST ENHANCED ULTRASOUND MAY GIVE A SOLUTION FOR
 BOSNIAK CLASSIFICATION OF RENAL CYSTS WHEN CT OR MR CANNOT**
 Panagiotis Petaloudis, Demosthenes Cokkinos, Pavlos Ampatzis, Sofia
 Athanasiou, Christina Aslanidi, Eleni G Antypa, Sofia Tsolaki, Stylianos
 Benakis, Ioannis Kalogeropoulos
 Radiology Department, Evangelismos Hospital. Athens, Greece

10:30-11:00
Coffee Break



11:00-12:30
Oral Presentations
ABDOMEN -PELVIS

 Moderators: **A. Tsili (GR) -S.Stojanovic (RS)**
OP 011
POSSIBILITIES OF MR DTI FOR THE PLANNING OF NEURO-SAVING OPERATIONS IN LOCAL PROSTATE CANCER.

 V.I. Kuplevatskiy, D. I. Kuplevatskaya, M. A. Cherkashin, N. A. Berezina
 Diagnostic Treatment Centre of the International Institute Named after
 dr. Sergey Berezin, Russia

OP 012
INVESTIGATION OF PROSTATE CANCER DETECTION RATES OF UPGRADED PIRADS SCORE 4 ON PERIPHERAL ZONE AND COMPARISON OF PIRADSV2 AND PIRADSV2.1 CANCER DETECTION RATE

 Ince Zuhal, Duvek Esin, Kartal Merve, Gulbiz Bakir, Baris Tunaci
 Atadan Istanbul University Istanbul Medical Faculty Department of
 Radiology, Istanbul, Turkey

OP 013
COMPARISON OF MULTIPARAMETRIC PROSTATE MRI AND PSMA GALLIUM PET-CT LYMPH NODE INVOLVEMENT AND EXTRAPROSTATIC EXTENSION RESULTS IN CASES WITH RADICAL PROSTATECTOMY, FUSION PSMA PET-MRI CONTRIBUTION TO DIAGNOSIS RESEARCH

 Guner a. Levent Saglican Yesim ,Tuna Mustafa Bilal,Ozisik Ozan,Kural
 Ali Riza,Karaarslan Ercan
 Acibadem Mehmet Ali Aydinlar University, Istanbul Turkey

OP 014
ROLE OF INTRAVOXEL INCOHORENT MOTION MAGNETIC RESONANCE IMAGING IN DIFFERENTIAL DIAGNOSIS OF CHRONIC PROSTATITIS AND PROSTATE CANCER

 Kulali Fatma, Huseyinkahyaoglu Merve, Kulali Safak Firat, Kucuk Eyup
 Veli, Semiz-Oysu Aslihan , Bukte Yasar
 Radiology Department, University of Health Sciences Umraniye Training
 and Research Hospital, Istanbul Turkey

OP 015
VESICOVAGINAL REFLUX MIMICKING OBSTRUCTIVE HYDROCOLPOS: A FORGOTTEN CAUSE OF DIURNAL INCONTINENCE IN PREPUBERTAL GIRLS

 Daniil G., Arvaniti M., Katsimba D., Ouroumidou K., Delianidou A.,
 Kaitartzis C.

 Radiology Department of General Hospital of Thessaloniki "G.
 Gennimatas", Greece




- OP 016** **PROGNOSTIC SIGNIFICANCE OF CT DETERMINED SARCOPENIA IN PATIENTS WITH METASTATIC PROSTATE CANCER**
Gulpinar Basak
Ankara University School of Medicine, Sina Hospital, Department of Radiology, Ankara ,Turkey
- OP 017** **MAGNETIC RESONANCE PROSTATE TRACTOGRAPHY FOR THE PLANNING NEURO-SAVING SURGERY**
Vladimir Kuplevatsky, Daria Kuplevatskaya, Mikhail Cherkashin, Natalia Berezina
Medical Institute n.a. Berezin Sergey, Russia.
- OP 018** **TWO-STAGE, UTERUS SPARING SURGERY IN THE MANAGEMENT OF FIBROID EXPULSION AFTER UTERINE ARTERY EMBOLIZATION (UAE)**
Ambrus Tóth 1; Zoltán Tömösváry 2, Ildikó Kalina 1, Dóra Kozics 1, Nándor Ács 2, Viktor Bérczi 1
1 Department of Radiology, Semmelweis University, Budapest, Hungary
2 2nd Department of Obstetrics and Gynaecology, Semmelweis University, Budapest, Hungary
- OP 019** **DOES WHOLE-BODY PET / MR IMAGING OF ABDOMINAL CANCERS OFFER ADDITIONAL FINDINGS COMPARED TO CONTRAST-ENHANCED CT**
Gur Seray Gizem(1) MD, Sokmen Bedriye Koyuncu(1) MD
1.Demiroglu Bilim University Florance Nightingale Hospital, Radiology Department, Istanbul/Turkey
- OP 020** **THE APPROPRIATE USE OF CONVENTIONAL ABDOMINAL RADIOGRAPHS AND ITS USEFULNESS IN NON-TRAUMATIC ACUTE ABDOMEN PATIENTS**
Sornsupha Limchareon M.D.1, Alisara Wongsuttilert, M.D.1, Chuenrutai Yeekian, Ph.D.2,Lalitphan Nimmankiatkul, M.D.2
1 Division of Radiology and Nuclear Medicine, Faculty of Medicine, Burapha University, Chonburi, Thailand
2 Somdej Memorial Hospital, Chonburi, Thailand
- OP 021** **COMPARISON OF HETEROGENEITY INDEX AND SUVMAX FOR LIVER METASTASES IN PET-MRI**
Sever İbrahim Halil, Ozkul Bahattin
Sisli Florence Nightingale Hospital Radiology Unit, Demiroglu Bilim University, Istanbul , Turkey

12:30-14:30**BREAK**

**14:30-16:00****Oral Presentations****ABDOMEN-GASTROINTESTINAL**Moderators: **L. Daglileleis (GR) -E. Mainta (UK)****OP 033****MRI-BASED TREATMENT RESPONSE ASSESSMENT FOR LIVER OLIGOMETASTASIS AFTER SBRT**

Kuplevatskaya D.I. 1, Vorobyov N.A.2, Martinova N.I.3, Kuplevatskiy V.I.4, Cherkashin M.A.5, Berezina N.A.6

1.MD, PhD, Chief of Radiology Department, Medical Institute n.a. Dr. Berezin Sergey, Saint- Petersburg, Russia.

2. MD, PhD, Chief of Radiotherapy Department, Medical Institute n.a. Dr. Berezin Sergey, Saint- Petersburg, Russia.

3.MD radiotherapy, Radiotherapy Department, Medical Institute n.a. Dr. Berezin Sergey, Saint- Petersburg, Russia.

4.MD radiology, Medical Institute n.a. Dr. Berezin Sergey, Saint- Petersburg, Russia.

5. MD, Associate Chief Medical Officer, Medical Institute n.a. Dr. Berezin Sergey, Saint- Petersburg, Russia.

6. MD, PhD, Chief Medical Officer, Medical Institute n.a. Dr. Berezin Sergey, Saint- Petersburg, Russia.

OP 034**IMAGING FEATURES OF MULTICENTRIC PANCREATIC TUMORS:A SINGLE CENTRE EXPERIENCE**Mitrovic Milica,Djuric-Stefanovic Aleksandra, Jankovic Aleksandra, Djikic Rom Aleksandra, Lazic Ljubica, Grubor Nikica, Knezevic Djordje, Radenkovic Dejan, Ninic Aleksandar, Ceranic Miljan, Kovac Jelena
First Surgical Clinic , Clinical Centre of Serbia**OP 035****INVESTIGATION OF THE DIAGNOSTIC PERFORMANCE OF LIRADS (THE LIVER IMAGING REPORTING AND DATA SYSTEM) IN LIVER PATHOLOGIES**Guenir Deniz,Tasar Mustafa,Bozlar Ugur,Arda Kemal Niyazi, Sanal Hatice Tuba, Ercin Cemal Nuri, Gunal Armagan
Gulhane Egitim Ve Arastirma Hastanesi. Istanbul ,Turkey**OP 036****HEPATOBIILIARY CONTRAST AGENTS: CHARACTERIZATION OF FOCAL LIVER LESIONS.**Papaioannou S, Sotiriadou A, Rigkas A, Giataganas G.
General Hospital Papageorgiou , Thessaloniki ,Greece



- OP 037** **PARTIAL INTERCOSTAL HERNIATION OF THE LIVER, A CASE REPORT**
 Antonio Gligorievski, Ivan Nevcev
 University Clinic for Surgical Diseases "St. Naum Ohridski" Skopje, North Macedonia
- OP 038** **EVALUATION OF POSSIBLE SUBCLINIC KIDNEY DYSFUNCTION WITH T1 MAPPING MRI SEQUENCE IN CHRONIC VIRAL HEPATITIS**
 Ozkok Sercin
 Istanbul Medeniyet University Goztepe Training and Research Hospital
- OP 039** **COLORECTAL CANCER - MDCT COLONOGRAPHY - VIRTUAL COLONOSCOPY 10 YEARS EXPERIENCES**
Daskalov Blagoja, Daskalov D., C- Radulovska J., Petanovska N.
 Skopje, R. North Macedonia
- OP 040** **COMPARING PLAIN FILMS AND ABDOMINAL CTs IN THE DETERMINATION OF INTESTINAL OBSTRUCTION LEVELS**
 Erturk Sukru Mehmet , Uysal Ibrahim
 Devlet Hastanesi Ultrason 1 Numaralu Oda, Istanbul Turkey
- OP 041** **RADIOLOGICAL MANAGEMENT OF APPENDICITIS TREATMENT**
 Tuney Davut ,Yegen Cumhuri Demirbas Baha Tolga Ilgin Can
 Marmara University Research and Application Hospital, Istanbul Turkey
- OP 042** **CHRONIC DIVERTICULITIS AS AN INCIDENTAL FINDING IN CT COLONOSCOPY**
 Papaioannou Sofia, Rigkas Athanasios, Theodorakopoulos Antonios
 General Hospital Papageorgiou Thessaloniki, Greece
- OP 043** **LOCATION OF COLONIC DIVERTICULAS**
 Papaioannou Sofia, Sotiriadou Amalia, Theodorakopoulos Antonios
 General Hospital Papageorgiou Thessaloniki, Greece
- OP 044** **USE OF DIFFUSION WEIGHTED IMAGING AND APPARENT DIFFUSION COEFFICIENT IN GASTRIC CANCER**
 Soydan Levent, Demir Ali Aslan, Torun Mehmet, Arar Cikrikcioglu
 Makbule Haydarpasa Training and Research Hospital, Department of Radiology

16:00-16:30
Coffee Break



16:30-18:00
**Oral Presentations
THORAX-CARDIAC-BREAST**

 Moderators: **T. Hazirolan (TR)- S. Detorakis (GR)**
OP 045
EFFECTIVENESS OF ADC VALUES IN PREDICTING PATHOLOGIC GRADE IN NON SMALL CELL LUNG CANCER

Fatihoglu Erdem - Aydin Sonay

Sami Uus Training and Research Hospital, Department of Radiology, Ankara Turkey

OP 046
THE ASSOCIATION BETWEEN THE EXTENT OF LGE ON CMR WITH MYOCARDIAL AN INFLAMMATORY BIOMARKERS IN ACUTE MYOCARDITIS

Alis Deniz, Asmakutlu Ozan

Istanbul Mehmet Akif Ersoy Thoracic and Cardiovascular Surgery Training and Research Hospital, Istanbul Turkey

OP 047
FINDINGS OF THE LUNG PERFUSION BLOOD VOLUME WITH DUAL- ENERGY COMPUTED TOMOGRAPHY

Turnaoglu Hale

Baskent University, Faculty of Medicine, Department of Radiology, Ankara Turkey

OP 048
ABERRANT VESSELS IN THE LEFT MEDIASTINUM- UNDERSTANDING THE THORACICVENOUS ANOMALIES

Mihaylova Evgeniya ,Eneva Maria, Groudeva Violeta,

BelyanovaMagdalena, Nedevska Maria

Department of Radiology, St Ekaterina University Hospital Sofia, Medical University Sofia

OP 049
EFFECTS OF PULMONARY END-DIASTOLIC FORWARD FLOW ON RIGHT VENTRICULAR VOLUME AND FUNCTION IN TETRALOGY OF FALLOT

Ozkok Sercin

Istanbul Medeniyet University Goztepe Training and Research Hospital, Istanbul, Turkey

OP 050
COMPARISON OF CORONARY CT ANGIOGRAPHY AND CATHETER ANGIOGRAPHY FINDINGS IN PATIENTS WITH HIGH CALCIUM SCORE

Ali Mahir Gündüz , Yüzüncü Yıl University Faculty of Medicine, Department of Radiology, Van/TURKEY





- OP 051** **ASSOCIATION BETWEEN STRAIN INDEX VALUES AND HISTOPATHOLOGIC GRADE IN EVALUATING NO-SPECIAL TYPE BREAST CARCINOMAS**
 Gulten SEZGIN¹
 1. Izmir Katip Celebi University Atatürk Training and Research Hospital, Department of Radiology
- OP 052** **ENCAPSULATED PAPILLARY CARCINOMA OF THE BREAST-RETROSPECTIVE STUDY**
 Delic Una, Durmic Ajla, Slender Tarik
 KCUS SARAJEVO, Bosnia Hercegovina
- OP 053** **DIAGNOSTIC VALUE OF AXILLARY LYMPH NODE SHORT AXIS-LONG AXIS RATIO AND DETERMINING A CUT-OFF VALUE OBTAINED WITH USG AND MRI IN BREAST CANCER PATIENTS**
 Duran Ozel, Deniz Ozel
 Saglik bilimleri unv. Sisli Etfal Hospital Radiology Department, Istanbul Turkey
- OP 054** **EVALUATING THE CONTRIBUTION OF ADC VALUES AND CONTRAST ENHANCEMENT KINETIC MR DATA TO MORPHOLOGICAL MRI FINDINGS IN THE EVALUATION OF BREAST MASSES**
 Duran Ozel Betul
 Okmeydani Education and Research Hospital, Kaptanp, Saglik bilimleri unv. Sisli Etfal Hospital Radiology, Istanbul Turkey
- OP 055** **OUTCOMES OF PATIENTS WITH COMPLEX CYSTIC BREAST LESIONS**
 Kulali Fatma, Guner Gulbanu, Semiz-Oysu Aslihan, Ezberci Fikret, Bukte Yasar
 Radiology Department, University of Health Sciences Umraniye Training and Research Hospital, Istanbul Turkey
- OP 056** **PATIENT REPORTED COSMETIC OUTCOME AFTER VACUUM ASSISTED EXCISION OF BENIGN BREAST LESIONS: A CROSS-SECTIONAL STUDY**
 van de Voort EMF¹, Klem TMAL², Struik GM², Birnie E^{3,4}, Sinke RHJA⁵, Ghandi A⁶
 1. Department of Surgery, Franciscus Gasthuis & Vlietland, PO Box 10900, 3004 BA, Rotterdam, The Netherlands,
 2. Department of Surgery, Franciscus Gasthuis & Vlietland, PO Box 10900, 3004 BA, Rotterdam, The Netherlands.
 3. Department of Statistics and Education, Franciscus Gasthuis & Vlietland, PO Box 10900 3004, BA, Rotterdam, The Netherlands.
 4. Department of Genetics, UMC Groningen, University of Groningen, PO Box 30001, 970 RB, Groningen, the Netherlands.
 5. Department of Pathology, Franciscus Gasthuis & Vlietland, PO Box 10900, 3004 BA Rotterdam, The Netherlands.
 6. Entrepreneur, RadCo, Rotterdam, The Netherlands




18:00-19:00
Oral Presentations
NEUROIMAGING

 Moderators: **V. Xydis (GR)-K. Karaali (TR)**
OP 057
ADDITIONAL VALUE OF SUSCEPTIBILITY WEIGHTED IMAGING IN THE EVALUATION OF ACUTE ISCHEMIC STROKE PATIENTS

Ahmet Mesrur Halefoglu M.D., Professor, Alper Demirci M.D. ,
Betul Duran Ozel Sisli Hamidiye Etfal training and research Hospital
Radiology Department, Istanbul ,Turkey

OP 058
NORMAL MEASUREMENTS OF OPTIC NEVRE IN PEDIATRIC POPULATION

Fatihoglu Erdem - Aydin Sonay Sami Ulus Training and Research
Hospital, Department of Radiology Ankara Turkey.

OP 059
CORPUS CALLOSUM MORPHOMETRIC MEASUREMENTS AND AGE/GENDER CHARACTERISTICS: A COMPREHENSIVE MR IMAGING STUDY

Arda Kemal Niyazi, Akay Sinan
University of Health Sciences, Gulhane Training and Research Hospital,
Radiology Clinic, Merkez,Turkey

OP 060
MOTOR TRACT EVALUATION ON 3T MAGNETIC RESONANCE IMAGING

N. Fileva, D. Zlatareva, V. Hadjidekov
Department of Diagnostic imaging, UMHAT Aleksandrovska, Mediacal
University Sofia,Bulgaria

OP 061
DETERMINATION OF MAGNETIZATION TRANSFER VALUES IN NORMAL ADULT BRAIN IN 3-TESLA MAGNETIC RESONANCE IMAGING

Kaya Eyup, Hocaoglu Elif
Okmeydani Training and Research Hospital ,ISTANBUL, Turkey

OP 062
AGE-RELATED DEEP WHITE MATTER CHANGES IN MYELIN AND WATER CONTENT: A T2 RELAXOMETRY STUDY

Kavroulakis Eleftherios, Kalaitzakis Georgios, Karageorgou Dimitra,
Makrakis Dimitris, Maris Thomas, Simos Panagiotis, Papadaki Efrosini
Radiology Department and Medical Physics Department University of
Crete, Greece

OP 063
REGIONAL CEREBRAL PERFUSION CORRELATES WITH ANXIETY IN NEUROPSYCHIATRIC SYSTEMIC LUPUS ERYTHEMATOSUS

Kavroulakis Eleftherios, Bertsiias George, Fanouriakis Antonis,
Karagiorgou Dimitra, Papastefanakis Emmanouil, Simos Panagiotis,
Papadaki Efrosini Radiology Department University of Crete Crete
Greece





- OP 064** **ENDOVASCULAR TREATMENT OF INTRACRANIAL ANEURYSM WITH FLOW DIVERTER STENTS**
 Iğus Behlül
 Radiology Department Baskent University Istanbul Hospital Istanbul Turkey
- OP 065** **EPIDURAL VEIN THROMBOSIS – an impossible diagnosis to prove.**
 Roger Smith Neuroradiologist, Assistant Professor University Health Network Uhn Toronto Western Hospital, University of Toronto, Canada
- OP 066** **ENDOVASCULAR TREATMENT OF CAROTID ARTERY DISEASE – EXPERIENCE FROM CLINICAL CENTER OF SERBIA**
 Vladimir Cvetic^{1,2,*}, Borivoje Lukic², Oliver Radmili², Momcilo Colic², Dragan Masulovic^{1,2}
¹School of Medicine, Belgrade University, Belgrade, Serbia
²Center for Radiology and MRI, Clinical Center of Serbia, Belgrade, Serbia
- OP 067** **BILATERAL CATHETERIZATION AND SAMPLING OF THE INFERIOR PETROSAL SINUSES IN PATIENTS WITH CONFIRMED ACTH DEPENDENT CUSHING SYNDROME (BIPSS)**
 Pavlos Ampatzis, Danai Stefanou, Christina Sierrou, Anastasios Tsokas, Panagiotis Petaloudis, Dimitrios Tomais, Ioannis Kalogeropoulos, Theodoros Kratimenos
 Radiology Department Interventional Radiology Unit, Athens General Hospital Evangelismos





SATURDAY, OCTOBER 19TH, 2019

Hall A | MINOS II

09:00-10:30

Gastrointestinal II

Moderators: **P. Prassopoulos (GR)** – **N. Courcoutsakis (GR)**

Abdominal wall hernias

N. Courcoutsakis (GR)

Neoplasms of the peritoneal Cavity

P. Prassopoulos (GR)

CEUS in diagnosis and treatment of inflammatory bowel disease

S. Yarmenitis (GR)

Transcatheter arterial embolization in acute upper gastrointestinal bleeding

T. Kratimenos (GR)

10:30-11:00

Coffee Break

11:00-12:30

Chest Imaging II

Moderators: **M. Nedevska (BG)** – **M. Karlovic Vidakovic (BIH)**

Chest HRCT findings in smokers and ex-smokers

E. Detorakis (GR)

Chronic pulmonary thromboembolic disease - radiology perspective in multidisciplinary team

M. Nedevska (BG)

Imaging of acute dyspnoea

K. Tavernaraki (GR)

MRI of the brachial plexus: Traumatic and nontraumatic causes of brachial plexopathy

M. Karlovic Vidakovic (BIH)




12:30-13:00
Honorary Lecture

 Moderator: **D. Tsetis (GR)**

Embolization Techniques for vascular malformations

N. Hayashi (JP)
13:00-13:30
SIEMENS SATELLITE LECTURE

 Moderators: **A. Chatziioannou (GR) -D. Karnabatidis (GR)**

How Augmented Reality helps making Interventions better

Dr. Christof Sommer, Heidelberg University (DE)
13:30-14:30
BREAK
14:30-16:00
Cardiac Imaging

 Moderators: **R. Maksimovic (RS) – V. Groudeva (BG)**

MRI in myocarditis

R. Maksimovic (RS)

CT imaging in congenital heart disease in adults - expected and unexpected findings

V. Groudeva (BG)

CT coronography: an update

K. Michailidis (GR)

Imaging of non-ischemic cardiac pathologies

T. Hazirolan (TR)
16:00-16:30
Coffee Break



16:30-18:00
Head and Neck II

 Moderators: **N. Traykova (BG) – Z. Merhemic (BIH)**

Advance imaging in vertigo

Z. Merhemic (BIH)

Paranasal sinuses on CT imaging

S. Sotirovic - Senicar (RS)

Parapharyngeal space and its specific pathologies

C. Karaman (TR)

Up-to-date imaging of the cervical trauma

N. Bulakbasi (TR)
18:00-19:00
Closing Ceremony

 Moderators: **D. Tsetis (GR)**
Best Oral and e-Poster Presentation Awards
BCR 2020




SATURDAY, OCTOBER 19TH, 2019

Hall B | PASIPHAEI

09:00-10:30
Musculoskeletal Radiology II

 Moderators: **S. Orguc (TR)** – **D. Filippiadis (GR)**

 Enchondroma versus low-grade chondrosarcoma: MR imaging
R. Arkun (TR)

 Interventional treatment of spine lesions
D. Filippiadis (GR)

 Benign and malignant adipocytic tumors
S. Orguc (TR)

 Postoperative spine
K. Spanakis (GR)
10:30-11:00
Coffee Break
11:00-12:30
Urogenital Radiology II

 Moderators: **M. Ozmen (TR)** – **I. Peteinarakis (GR)**

 Congenital uterine anomalies according to the ESHRE/ESGE classification -
 MRI pictorial review
G. Hadjidekov (BG)

 Imaging of the urothelial tumors
M. Ozmen (TR)

 Renal lesions characterization with MRI
M. Secil (TR)

 Imaging of the adrenals
F. Obuz (TR)
13:00-14:30
BREAK




14:30-16:00

Oral Presentations

INTERVENTIONAL RADIOLOGY-VASCULAR

Moderators: E. Kehagias (GR)-Th. Kratimenos (GR)

OP 068

MR-VENOGRAPHY IN THE DIAGNOSIS OF POST-THROMBOTIC ILIAC VEIN OBSTRUCTION AND EXTRAVASCULAR COMPRESSIONV. Shebryakov^{1,2}, O. Karpov¹, Yu. Stoyko¹, O. Bronov, M. Yashkin¹, D. Lutarevich²¹Pirogov National Medical & Surgical Center, Moscow, Russia ²Ramsay Diagnostics, Moscow, Russia

OP 069

UNDERSTANDING THE EFFECT OF THE NUMBER OF WIRE ON STAGNATION FLOW ZONES INSIDE A GIANT ANEURYSM USING A COMPUTATIONAL FLUID DYNAMICS TECHNIQUEOnur Mutlu¹, Ali Bahadır Olcay^{1,*}, Cem Bilgin², Bahattin Hakyemez²¹Yeditepe University, Faculty of Engineering, Department of Mechanical Engineering, Kayisdagi Cad., 34755, Istanbul, Turkey²Uludag University School of Medicine, Department of Radiology, Gorukle, Bursa 16059, Turkey

OP 070

AORTIC REMODELING AFTER ANTHRACYCLINE THERAPYThiago Ferreira de Souza¹, Thiago Quinaglia A. C. Silva¹, Ravi Shah², Tomas G. Neilan², Fabrício P. Brenelli¹, Lício Velloso¹, Wilson Nadruz¹, José Roberto Mattos¹, Michael Jerosch-Herold³, Otávio R. Coelho-Filho¹¹School of Medical Sciences, State University of Campinas, UNICAMP, Campinas – Brazil ²Massachusetts General Hospital, Harvard Medical School, Boston – USA³Department of Radiology, Harvard Medical School, Boston – USA

OP 071

EVALUATION OF PTA OUTCOME IN PATIENTS WITH CRITICAL LIMB ISCHEMIA USING DYNAMIC CONTRAST-ENHANCED MRI (DCE-MRI)Nikolaos Galanakis¹, Thomas G Maris³, Nikolaos Kontopodis², Nikolas Matthaiou¹, Christos V Ioannou², Apostolos Karantanas¹, Dimitrios Tsetis¹¹Department of Medical Imaging, University Hospital Heraklion, University of Crete Medical School, Heraklion, Greece²Vascular Surgery Unit, Department of Cardiothoracic and Vascular Surgery, University Hospital Heraklion, University of Crete Medical School, Heraklion, Greece³Department of Medical Physics, University Hospital Heraklion, University of Crete Medical School, Heraklion, Greece



- OP 072** **INTIMA MEDIA THICKNESS IN PATIENTS WITH NON-DIPPER HYPERTENSION**
 Altin Cihan, Agildere Muhtesem
 Baskent University, Radiology Department, Izmir, Turkey
- OP 073** **CTA IN THE FOLLOW-UP OF PATIENTS AFTER ENDOVASCULAR ABDOMINAL AORTIC ANEURYSM REPAIR (EVAR): MECHANISMS OF EVAR FAILURE AND SURVEILLANCE STRATEGIES**
 Daniil G., Arvaniti M., Papadimitriou A., Torounidis I., Kotsidi A., Kaitartzis C., Panagasiidou L.
 Radiology Department of General Hospital of Thessaloniki
 "G. Gennimatas", Greece
- OP 074** **DRUG COATED BALLOONS AS A NEW METHOD FOR TREATING PERIPHERAL ARTERIAL DISEASE OF THE LOWER EXTREMITIES**
 Milan Pantelić¹, Miloš Dujović¹, Tamara Vučinić¹, Aleksandra Medan¹
 1Zvezdara Clinical Hospital Center, Department of Radiology, Belgrade, Serbia;
- OP 075** **BRONCHIAL ARTERIES EMBOLIZATION**
 I. Antonakou, D. Stefanou, P. Petaloudis, A. Tsokas, A. Anagnostopoulou, D. Tomais, I. Kalogeropoulos, Th. Kratimenos,
 Radiology Department, Intervention Radiology Unit, Evaggelismos Hospital, Greece
- OP 076** **DIAGNOSTIC AND MANAGEMENT OF VENOUS ACCESS DEVICES THROMBOSIS**
Mikhail Cherkashin, Natalia Berezina, Denis Puchkov, Alexey Nikolaev, Daria Kuplevatskaya
 Medical Institute n.a. Berezin Sergey, Saint Petersburg, Russia
- OP 077** **STENTING OF SUBCLAVIAN ARTERY IN STEAL SYNDROME COMPARED WITH CONVENTIONAL SURGICAL TREATMENT**
 Lukic Borivoje, Cvetic Vladimir, Radmili Oliver, Colic Momcilo, Masulovic Dragan, Maksimovic Ruzica
 Radiology Clinical Center of Serbia
- OP 078** **ANEURYSMS\ TREATMENT EFFICACY BY DIFFERENT ENDOVASCULAR TECHNIQUES: A SINGLE NORTHEASTERN GREEK CENTER EXPERIENCE.**
 Tsaoulia Aikaterini, Birbilis Theodosios, Souftas Vasileios, Tsiknidis Michael, Frigkas Konstantinos, Mantatzis Michalis
 General University Hospital of Alexandroupolis, Alexandroupolis, Greece





OP 079

BILATERAL CATHETERIZATION AND SAMPLING OF ADRENAL VEINS IN PATIENTS WITH DRUG RESISTANT HYPERTENSION (AVS)

Panagiotis Petaloudis, Danai Stefanou, Tsokas, Anastasios Tsokas, Christina Sierrou, Pavlos Ampatzis, Dimitrios Tomais, Ioannis Kalogeropoulos, Theodoros Kratimenos
Radiology Department Interventional Radiology Unit, Athens Greece,
General Hospital 'Evangelismos, Athens Greece

16:00-16:30 Coffee Break

16:30-18:00 Interventional Radiology II

Moderators: **M. Totev (BG)** – **R. Uberoi (UK)**

Embolization of carotid-cavernous fistula-where we stand today?

S.Sirakov (BG)

SFA PTA & stenting

M. Krokidis (UK)

Intraarterial Chemotherapy of brain tumors

M. Mantatzis (GR)

EVAR: an update

R. Uberoi (UK)





SATURDAY, OCTOBER 19TH, 2019

Hall C | MINOS I

09:00-10:30
Neuroradiology II

 Moderators: **M. Lucic (RS) – C. Calli (TR)**

Quantitative Neuroimaging Biomarkers

M. Lucic (RS)

Imaging in neurodegenerative disorders

C. Calli (TR)

Imaging of cranial nerves

K. Karaali (TR)

Brain: Functional and Structural Connectivity

V. Xydis (GR)
10:30-11:00
Coffee Break
11:00-12:30
Hepatobiliary Radiology II

 Moderators: **N. Elmas (TR) – C. Triantopoulou (GR)**

Hepatic Incidentalomas

A. Tsili (GR)

Challenges in Pancreatic Cystic Tumors

N. Elmas (TR)

Focal mass in chronic pancreatitis

S. Papaioannou (GR)

Rare pancreatic neoplasms

C. Triantopoulou (GR)
13:00-14:30
BREAK



14:30-16:00
Oral Presentations
MUSCULOSKELETAL-MISCELLANEOUS

 Moderators: **K. Spanakis (GR)- I. Peteinarakis (GR)**
OP 080
THE USAGE AND EFFICIENCY OF DRUG ELUTING STENTS IN VERTEBRAL OSTIAL STENOSIS

 Geyik Serdar , Yavuz Kivilcim, Saatci Isil, Cekirge Saruhan
 Koc University School of Medicine Department of Radiology, Istanbul
 Turkey

OP 081
SACROPLASTY: A SINGLE CENTRE EXPERIENCE, INCIDENCE AND OUTCOMES

 Roger Smith Neuroradiologist, Assistant Professor University Health
 Network Uhn Toronto Western Hospital, University of Toronto, Canada

OP 082
RADIO-FREQUENCY ABLATION: APPLICATIONS AMONG PAEDIATRIC PATIENTS WITH OSTEIOD OSTEOMA

 Thanou Ioanna, , Hia Botsa Evant, Thanos Loukas
 Imaging and Interventional Radiology Department, Sotiria General
 Hospital, Athens, Greece

OP 083
PERCUTANEOUS TREATMENT OF LOW BACK PAIN USING MIXTURE O2O3: OUR EXPERIENCE

 Kristina Davidović, Ružica Maksimović
 Faculty of Medicine, University of Belgrade, Center for radiology and
 magnetic resonance imaging, Clinical Center of Serbia, Belgrade, Serbia

OP 084
NORMAL ABDOMINAL MUSCLE THICKNESSES IN ADOLESCENTS: A SONOGRAPHIC STUDY

 Fatihoglu Erdem - Aydin Sonay
 Sami Uus Training and Research Hospital, Department of Radiology,
 Ankara Turkey

OP 085
THE IMPORTANCE OF TUMOR CONTACT LENGTH AND ADC PARAMETERS TO PREDICT MUSCLE INVASION OF BLADDER CARCINOMA ON MAGNETIC RESONANCE IMAGING

 Ismet Gulmez,¹ Ismail Caymaz,² Ibrahim Inan,³ Istanbul Turkey




- OP 086** **RADIOLOGY END ART**
Daskalov Blagoja, Daskalov D.
 Skopje, R. North Macedonia
- OP 087** **RADIATION DOSES FROM CT EXAMINATIONS; LOCAL DIAGNOSTIC REFERENCE LEVELS STUDY.**
 Atli Eray, Cevik Cenkeri Halime, Ogunlu Umur, Uyaniksadic Ahmet, Gumus Burcak
 Okan University Hospital Department of Radiology, Istanbul Turkey
- OP 088** **APPLICATION OF ADVANCED MEDICAL IMAGING TECHNOLOGY IN BANGLADESH**
 Mohammad Shamsuddin Joint Secretary
 Bangladesh Association of Radiology and Imaging Technologist.
- OP 089** **RADIOGRAPHERS EDUCATIONAL SYSTEM & PRESENT CONDITION IN BANGLADESH.**
 Mohammad Maruf Khan
 Taleour General Hospital (Pvt) Ltd.

16:00-16:30 **Coffee Break**

16:30-18:00 **Paediatric Radiology**

Moderators: **D. Negru (RO)** – **K. Chlapoutakis (GR)**

MRI of the fetus: an overview
D. Negru (RO)

Pontine morphometry in fetuses with agenesis of the corpus callosum assessed by fetal MRI
K. Koprivsek (RS)

Ultrasonography of Developmental Dysplasia of the Hip (DDH)
K. Chlapoutakis (GR)

Renal pelvic dilatation in fetus
M. Arvaniti (GR)





SATURDAY, OCTOBER 19TH, 2019

Hall | PASIPHAE II

09.00-16.30

Balkan Study Day - Hologic Breast Imaging Sessions

Best Practices in Breast Cancer Detection

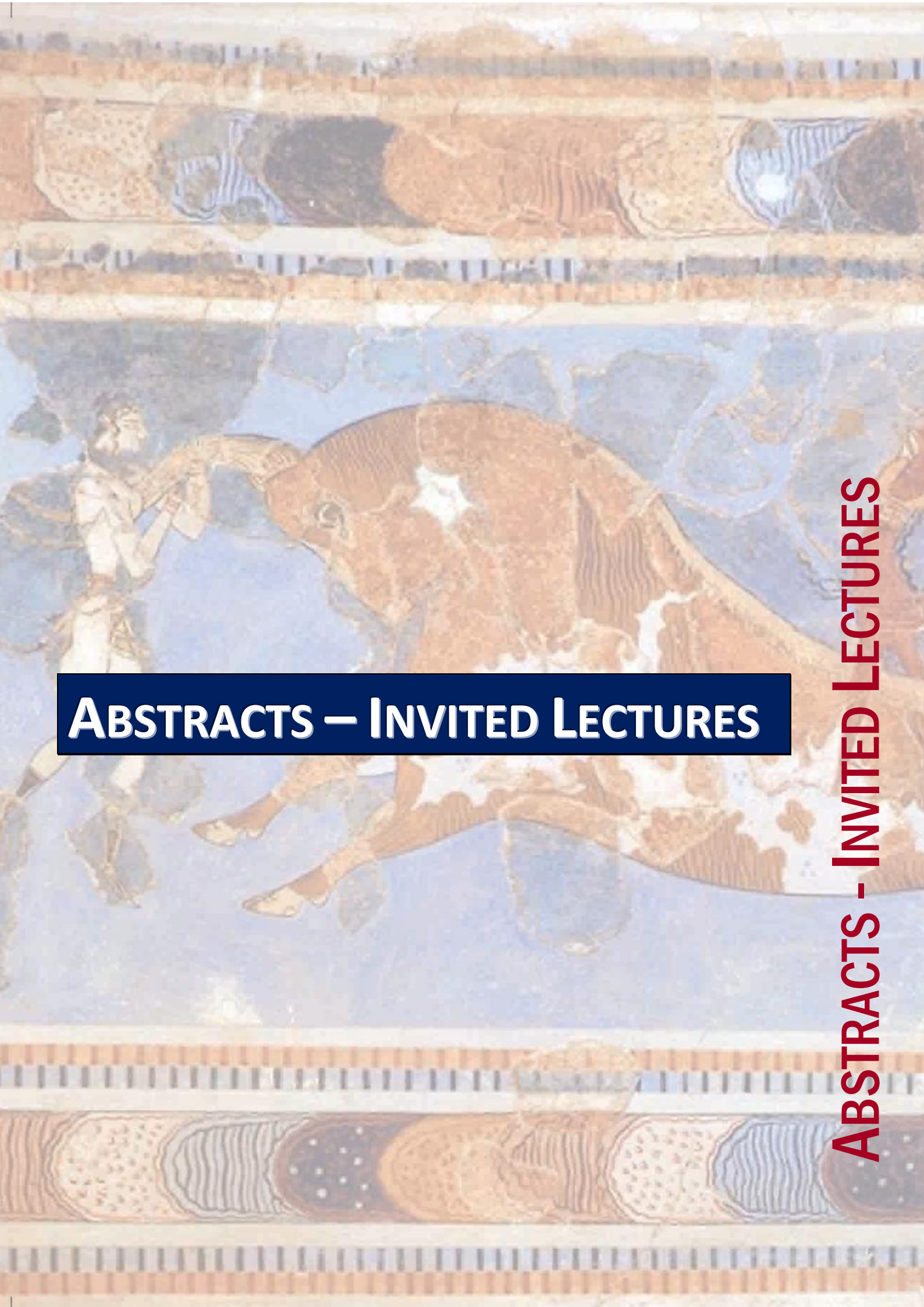
- | | |
|--------------------|--|
| 09.00 | Setting up a National Screening Program
Kadivec, Ljubljana, Slovenia |
| 09.30 | Tomosynthesis in Screening
Giovanna Romanucci, Verona/Italy |
| 10.00 | Contrast Enhanced Digital Mammography: Practical Considerations
Dr Federica Di Naro, Florence/Italy |
| 10.30 | Quality Control in Mammography Screening
Loannis Sechopoulos, Nijmegen/NL |
| 11.00 | Break |
| 11.30 | Breast Density and Personalized Screening
Prof. Dragana Djilas/Serbia |
| 12.00 | Artificial Intelligence: From Hype to Reality
Hologic speaker |
| 12.30-13.30 | Lunch Break |
| | Innovations in Breast Cancer Management |
| 13.30 | Wireless localization of non-palpable lesions |
| 14.00 | Advances of intraoperative imaging and other options for breast conservation surgery
Hologic Speaker |
| 14.30 | Rotating workshops and hands –on sessions (30 min each) |



The image shows a section of an ancient Egyptian wall painting. At the top, there are decorative friezes with alternating blue and brown stripes, and a row of stylized motifs including lotus flowers and circular patterns. Below this, a man in a white kilt stands on the right, holding a bow in his right hand and a staff in his left. On the left, a woman in a reddish-brown dress holds a long staff. In the center, a white cow with brown spots is depicted. The background is a light blue wash with some darker blue patches. The overall style is characteristic of the Late Period of ancient Egypt.

ABSTRACTS

ABSTRACTS



ABSTRACTS – INVITED LECTURES

ABSTRACTS - INVITED LECTURES



FRIDAY, OCTOBER 18TH, 2019

GASTROINTESTINAL RADIOLOGY

Imaging protocols in Dysphagia Management

L. Daglilelis (GR)

Dysphagia by definition is a malfunction of food and saliva transfer from the oral cavity to the stomach. It is characterized by symptoms that reflect a variety of medical conditions, which need clarification and management. Moreover, dysphagia negatively affects lung safety, adequate nutrition and quality of life.

Due to a variety of neurological, oncological, congenital and metabolic diseases that interfere with food transfer, dysphagia management needs the collaboration of many medical and paramedical disciplines. The workout of dysphagia obviates a proper clinical examination and use of instrumental and imaging methods in order to elucidate the anatomical and functional disorders that need to be medically managed.

Radiologists are medical specialists that are called to use their expertise and work together with medical and paramedical disciplines to effectively manage the issue of dysphagia in adult and pediatric population.

The aims of the lecture are:

1. To review basic anatomical and functional parameters of swallowing and esophageal physiology
2. To briefly refer to the common and uncommon aetiology of dysphagia
3. To globally address the use of the investigational methods for the contemporary diagnosis of dysphagia
4. To present the information provided by imaging methods together with their limitations
5. To encourage the state-of-the-art implementation of imaging methods in the field of dysphagia investigation

ABSTRACTS - INVITED LECTURES





GIST tumors: Imaging characteristics **E. Chartampilas (GR)**

Gastrointestinal stromal tumors (GIST) are the most common mesenchymal neoplasms of the GI tract, occurring anywhere along its length. They are most commonly found in the stomach and small intestine. They tend to grow exophytically causing compression and ulceration of the mucosa – leading to hemorrhage – or obstruction of the lumen; frequently they are incidentally discovered during imaging. Typically they present as a well marginated enhancing mass arising from the wall of the gastrointestinal tract and exhibiting exophytic growth. However, when they are large, appearances are more heterogeneous while the organ of origin cannot be clearly determined. Tumor invasion into adjacent structures and intraabdominal metastases, usually to the liver and peritoneum, can also be seen as 10-30% of GISTs have malignant behavior. As 90% of the tumors express KIT, a tyrosine kinase growth factor receptor, treatment with a KIT-inhibitor is employed when surgery is not feasible. Response to therapy may not present with size reduction but with cystic changes or reduced vascularity, or even a transient increase in size due to intratumoral hemorrhage. Therefore, alternative response criteria that incorporate density changes, namely the Choi criteria, are used to assess response or progression after treatment.

In this review, imaging characteristics, typical and atypical presentations of the GISTs, complications and differential diagnosis will be highlighted. Moreover the Choi criteria will be discussed along with examples illustrating their importance in patient follow-up. It will be stressed that radiology plays a crucial role in patient management in the setting of a multidisciplinary team.

MR Imaging of perianal disease **E. Mainta (UK)**

Perianal disease is a leading cause of patient morbidity with serious implications for the patients' quality of life.

MRI is the most accurate imaging modality for the diagnosis, classification and monitoring of perianal fistulas and is the recommended first-line test.

Revolutionary treatment options have emerged that require better communication of findings between the Radiologist and the Surgeon and close collaboration for treatment planning. Standardised MRI protocols with optional use of additional innovations play a pivotal role as they reveal relevant clinical information that alters patient management.

MRI allows accurate depiction of patient-specific pre- and post-surgical sphincter anatomy and fistula mapping. The use of MRI is key to the detection of undiagnosed or underdiagnosed fistula extensions and abscesses which are major causes of recurrent disease in complex cases. Additionally MRI can demonstrate urogenital and anorectal complications and helps monitor treatment response enabling appropriate patient stratification and personalised care.





MR Enterography – How I do it S. Gourtsoyianni, Athens (GR)

The majority of patients being referred for MR Enterography are patients under investigation for or with known inflammatory bowel disease. Main reasons for the examination are: a) to rule out small bowel involvement, b) to image the extent of small bowel disease involvement, c) to depict extraintestinal disease involvement and to identify penetrating disease to aid the surgeons, d) to monitor disease under treatment and e) to identify local recurrence.

In order to be able to answer above questions a dedicated MR examination protocol comprising of ultrafast sequences has to be performed after the patient has drunk a sufficient amount of at least 1 lt of biphasic oral contrast solution that allows optimal luminal distension and opacification of the small bowel during the examination.

Examinations can be performed in a 1.5 or 3T MR scanners using phased array body coils with patient preferably lying prone. In addition reduction of peristalsis has to be achieved during examination by administering antiperistaltic agents, in our case intravenous glucagon. T1 weighted sequences obtained after intravenous administration of paramagnetic contrast agent are considered very important as they allow for better disease characterization.

CHEST IMAGING I

IMAGING PULMONARY NODULES: Bayraktaroglu S. (TR)

Solitary pulmonary nodule (SPN) is a single, rounded radiographic opacity measuring up to 30 mm in diameter within pulmonary parenchyma. The differential diagnosis of the SPN is broad, ranging from benign causes (infectious and granulomatous diseases) to malignant causes such as lung cancer which is the main concern. Important CT imaging features in detection of malignant pulmonary nodules are the nodule size, morphology, attenuation, internal characteristics and growth rate.

Size: The risk of primary malignancy among small solid lung nodules less than 4 mm is low, less than 1%, even among smokers, However the malignancy rate increases as the size of the nodule increases.

Morphology: Lobulation or spiculation in contour are highly predictive of lung cancer. However perifissural solid nodules with smooth margin and lentiform configuration commonly correspond intrapulmonary lymph nodes.





Attenuation: Nodules according to their attenuation can be further classified as solid, part solid and ground glass(GG) nodules. Persistent subsolid and GG nodules have a high likelihood of representing a slow growing tumor such as adenocarcinoma.

Internal Characteristics: Presence of fat in nodule generally indicates hamartoma. Central, diffuse, uniform, popcorn calcification indicates benignancy, however eccentric, punctate calcifications are seen in malignancies. Bubble-like lucencies seen in solid nodules is suggestive of malignancy mostly adenocarcinoma. Nodule located in the wall of a cystic space is also suspicious for malignancy.

Growth Rate: Solid lung nodules are considered benign when stable for more than 2 years, However the doubling time of subsolid nodules are longer so need a longer follow up period. The presence of a new solid component within a previously GGN or increase in size of solid component within a part solid should increase the suspicion of malignancy.

References:

1. Alpert JB, Lowry CM, Ko JP. Imaging the solitary pulmonary nodule. Clin Chest Med. 2015 36(2):161-78
2. Snoeckx A, Reyntiens P, Desbuquoit D et al. Evaluation of the solitary pulmonary nodule: size matters, but do not ignore the power of morphology. *Insights Imaging* 2018 ;9(1):73-86

LUNG BIOPSY: INDICATIONS, TECHNIQUE, COMMON AND RARE COMPLICATIONS

Sarajlic V.(BIH)

Percutaneous lung biopsies are among most frequently and routinely performed nonvascular procedures in many interventional departments around the globe. It is less invasive and less expensive than surgical biopsy, but compared with other percutaneous biopsies it carries a higher risk of complications. Main indications for lung biopsy include differentiation of benign versus malignant lesions, microbiological analysis and tumor staging. Some consider an uncooperative patient the only absolute contraindication for lung biopsy. Other contraindications are uncorrectable coagulopathy, intractable cough and severe underlying pulmonary disease (i.e. emphysema). All patients have to be aware of the risks of the procedure and potential complications, and have to sign informed consent before the procedure. INR, APTT and platelets count findings should be obtained before the procedure.

Lung biopsies are most frequently performed under the CT guidance, less frequently under the guidance of CT- fluoroscopy, and rarely under the ultrasound guidance. Two types of needles are used: aspirating needles for cytology analysis, and cutting needles for core biopsy and histological evaluation.





The most common complication is pneumothorax, with the reported pool rate of 25,3%, and pneumothorax requiring drainage 5,6%. It is followed by pulmonary hemorrhage with the rate of 18%, and hemoptysis 4,1%. Needle tract seeding, air embolism and death are rare complications. According to Society of Interventional Radiology, pneumothorax without need for intervention, parenchymal hemorrhage and transient hemoptysis are considered minor complications, while pneumothorax requiring intervention, hemothorax, air embolism, needle tract seeding and death represent major complications. There is no significant difference in complication rates, especially of major complications, between fine-needle aspiration procedures (FNA) and core biopsies (CB).

PERCUTANEOUS ABLATION OF LUNG LESIONS

Filippiadis D. (GR)

A tumor surrounded by the air-filled lung parenchyma is electrically and thermally insulated by the air resulting for larger ablation volumes at less energy deposition. Advantages of percutaneous ablation of lung lesions include the low invasiveness of the technique, the lack of need for interrupting systemic therapies and the ability to treat several lesions closely located or the ability for secondary re-intervention.

Percutaneous ablation of lung lesions can be proposed as definite or palliative therapy as well as complementary to other therapies. Percutaneous ablation is indicated for bronchogenic carcinoma Stage I or II patients with comorbidities or refusing surgery as well as oligometastatic patients with limited number of lung metastases (ideally less than 3-5 lesions per lung). Absolute contraindications include pulmonary hypertension and/or presence of malignant effusion. In-hospital mortality is 1.3% and most common complications include pneumothorax, pneumonia and effusion.

Currently, tumor size remains the most important selection criterion for success; proper patient and tumor selection enables 89% local control rate. Small sized tumors with a diameter <2 cm can be ablated in 78-96% of cases after a minimum follow-up of 1 year. Apart from the size, another significant factor for complete ablation is the ratio between the area of the ablation induced ground-glass opacity (GGO) and the total tumor volume.

Overall survival of patients with primary and secondary lung tumors can be significantly increased when systemic treatment is combined to percutaneous ablation in a multidisciplinary team setting.





IMAGING OF INTERSTITIAL LUNG DISEASE: WHERE ARE WE NOW?

Tunaci A. (TR)

There are numerous interstitial lung diseases, but in clinical practice only about ten diseases account for approximately 90% of cases.

The definitions and diagnostic criteria for several major forms of ILDs have been revised in recent years. Although well over 100 distinct entities of ILDs are recognized, a limited number of disorders, including idiopathic pulmonary fibrosis, sarcoidosis, and connective tissue disease-related ILDs, account for most ILDs encountered clinically.

Clues from the medical history along with the clinical context and radiologic findings provide the initial basis for prioritizing diagnostic possibilities for a patient with ILD.

In evaluating patients with suspected ILD, the clinician should confirm the presence of the disease and then try to determine its underlying cause or recognized clinicopathologic syndrome. Clues from the medical history along with the clinical context and radiologic findings provide the initial basis for prioritizing diagnostic possibilities for a patient with ILD. High-resolution computed tomography of the chest has become an invaluable tool in the diagnostic process. A confident diagnosis can sometimes be made on the basis of high-resolution computed tomography and clinical context. Serologic testing can be helpful in selected cases. Histopathologic findings procured through bronchoscopic or surgical lung biopsy are often needed in deriving a specific diagnosis. An accurate prognosis and optimal treatment strategy for patients with ILDs depend on an accurate diagnosis, one guided by recent advances in our understanding of the causes and pathogenetic mechanisms of ILDs. Establishing an accurate diagnosis in patients with ILD, ideally within a multidisciplinary team discussion, is critical for ensuring optimal outcomes.

This presentation discusses recent advances imaging of ILD, including updated classification, diagnostic approach and forthcoming new emerging Technologies.





HONORARY LECTURE

MEDICAL IMAGING: FROM RADIOGRAPHY TO RADIOMICS

FROM RADIOGRAPHY TO RADIOMICS AN INTERESTING JOURNEY

Efremidis S. Professor Emeritus (GR)

The title refers to the remarkable story of our discipline. The story of Radiology,

I. It starts with the struggle to establish a professional status right after the clinical application of x-rays at the beginning of past century

II. It continues with a glorious period during the second half of the 20th century, when many new clinical diagnostic applications of many newly developed imaging modalities were implemented and,

III. Ends with the actual involvement of Radiology in most –if not all –advanced diagnostic and research protocols, looking into the heterogeneity of different diseases, mainly malignancies.

The goal of Radiology is of course, to push forward findings indicating imaging heterogeneity. However, it has become apparent in the last 10-15 years that imaging heterogeneity correlates with genetic and histopathologic heterogeneity and that with different biologic behavior clinical course, therapeutic response and prognosis of an apparently “same” disease.

This observation induces the interesting reader directly into the field of precision medicine, Radiomics and Radiogenomics. Summarizing the story of Radiology we can recognize 3 relatively independent periods that I call: I. The period of struggle (1895-1960) II. The glorious years (1960-2010) III. Expanding the limits (2010 and beyond)





ONCOLOGIC IMAGING

IMAGING IN PHARYNGEAL CANCER: KEY POINTS

Traykova N. (BG)

Learning objectives: To learn the normal radiological anatomy of the pharynx, to become familiar with the most common neoplasms affecting pharynx, to recognize key imaging features of pharyngeal cancer and understand the role of CT, MRI and PET in diagnosis, staging and management of pharyngeal malignancies.

Pharyngeal malignancies commonly present in adults over the age of 45th and show a strong male predominance(3-5:1). About 85- 90% are squamous cell carcinomas (SCC) and 10-15% are minor salivary gland tumors, adenocarcinoma, lymphoma and various mesenchymal malignancies. The risk factors are long-term over use of tobacco and alcohol and in the last view years HPVirus type 16, which occurs more often in younger, healthier individuals with little or no tobacco exposure. Knowledge of the normal anatomy and anatomical topography is a fundamental basis for the evaluation of any pathological process. Beside the clinical examination and endoscopy performed by ENT specialists, imaging techniques play a crucial role in the diagnostic process and follow-up of patients with pharyngeal cancer. The contrast-enhanced CT, as well as MRI and PET-CT/ PET-MRI are required to determine the malignancy site, submucosal extension and invasion of adjacent structures. The combined information helps to define the general radiological criteria for tumor involvement and allows the tumor to be classified according to the relevant TNM staging- nodal metastasis, systemic metastasis, presence of synchronous masses and recurrent disease. The clinical and endoscopic outcomes together with the diagnostic imaging evaluation improve the pre-therapeutic staging, post- therapeutic surveillance and follow- up of patients with pharyngeal cancers.

DIAGNOSTIC-CT AND MRI CRITERIA FOR MONITORING BIOLOGIC THERAPY RESPONSE OF COLORECTAL METASTATIC LIVER LESIONS

Viktorija Vucaj Cirilovic (RS)

Quantitative imaging allows robust evaluation of hepatic tumor response. In addition to size changes, various biologic and functional parameters can be quantified by using new imaging technologies. Measurement of these parameters is especially important for the evaluation of tumor response to novel targeted therapies, in which change in functional status sometimes precedes anatomic modification. Familiarization with these different biomarkers is important to facilitate pivotal communication between oncologists and radiologists with regard to patient cancer treatment.

All new therapies have created a new challenge for radiologists, who must assess the response of liver tumors to therapy. Whereas the goal of locoregional therapy is inducing necrosis, molecular-directed therapies interfere with tumor growth. Therefore, tumor shrinkage may not be apparent or may be absent with either method. In addition, hepatic malignancies may appear hyperenhanced or hypoenhanced relative to the normal parenchyma. Specific instructions regarding the best contrast





material-enhanced phase to measure tumors are required to avoid variability in results - hepatic metastases of colorectal cancer must be measured in the portal venous phase.

Anatomic imaging biomarkers that quantify liver tumor response to cytotoxic therapy are based on temporal change in the size of the tumors. Anatomic biomarkers have been incorporated into the World Health Organization criteria and the Response Evaluation Criteria in Solid Tumors (RECIST) versions 1.0 and 1.1. However, the development of novel therapies with different mechanisms of action, such as antiangiogenesis or radioembolization, has required new methods for measuring response to therapy. This need has led to development of tumor- or therapy-specific guidelines such as the Modified CT Response Evaluation (Choi) Criteria for gastrointestinal stromal tumors, the European Association for Study of the Liver (EASL) criteria, and modified RECIST criteria, among many others.

STAGING OVARIAN CARCINOMA, KEYS AND PITFALLS

Stojanovic S. (RS)

Introduction: Echinococcal liver hydatid disease is a parasitic infection brought on by infection with small tapeworms of the genus *Echinococcus*. A person is infected accidentally, by contact with an infected animal. Its treatment can be surgical, medical and percutaneous. Percutaneous treatment provides an adequate alternative to surgical treatment. It is used because it is minimally invasive, to prevent cyst scattering, reduce the risk of anaphylaxis and reduce the number of days in the hospital.

Purpose: The aim of our study was to present the initial results of percutaneous treatment of hydatid disease, which has been conducted in the Clinical Center of Vojvodina for the last ten years in the Center for Radiology, in cooperation with the Hacettepe University Hospital.

Materials and methods: A study was conducted on 29 patients who were treated for hydatid liver disease, in the period from 2009 to 2019 in the Center for Radiology and Clinic for Infectious Diseases. All echinococcal cysts were diagnosed by ultrasound, categorized based on the Gharbi classification, and accordingly to that treated with percutaneous treatment.

Results: 19 out of 29 patients succumbed PAIR method, 9 out of 29 did MoCaT and 1 patient had one cyst done with PAIR method and the other with modified catheterization. All patients had indirect hemagglutination test positive. Size of the cysts was reduced by 39% after the intervention and all cysts except one were nonviable. Relapse occurred in only one patient.

Conclusion: Percutaneous treatment of echinococcal liver disease is a minimally invasive method, with a low percentage of periprocedural and postprocedural complications and a short period of hospitalization.





HYBRID IMAGING IN ONCOLOGY

Silvija Lucic^{1,2} (RS)

1 University of Novi Sad, Faculty of Medicine, Novi Sad, Serbia

2 Oncology Institute of Vojvodina, Sremska Kamenica/Novi Sad, Serbia

For a period of time oncology imaging, consistent with cancer detection, staging, restaging and therapy monitoring, is no longer mainly depending on anatomical/morphological imaging but, in so many oncological entities, is shifting to hybrid imaging, the image acquisition systems that physically combine complementary imaging modalities that provide insights into morphology, function and molecular patients data providing complementary anatomical, biological and quantitative information and opens the door to multiparametric assessment of the disease.

Thus, hybrid imaging plays an important role in the diagnosis and therapy management of a wide range of malignancies and with the introduction of novel radiotracers and development of new PET/CT imaging technologies and increased use of PET/MRI, hybrid imaging is now a part of theragnostic field and becoming one of oncologist main modalities of choice.

With technological development a deeper insight into tumor biology arise and limitations of imaging became more evident. So, we are aware that soft tissue tumor masses are composed of viable tumor, necrosis, fibrosis, inflammation and distinction between them only by morphology is difficult and that the grade of tumor or its biological behavior cannot be predicted only by masses appearance, its size or shape. It is also known that histologically identical tumors may have different genotypes and phenotypes with a significant therapeutic and prognostic implication. For example, it is known that there is a link between hormone receptor expression and FDG uptake in breast cancer, triple negative breast cancers which are known to have poor prognosis, are having significantly higher FDG uptake than estrogen/progesterone receptor positive cancers.

Even though, despite considerable limitations, changes in tumor size are still most frequently used to determine tumor response to therapy and precise anatomical information is very important for planning biopsy, surgery and radiation therapy. The introduction of novel therapeutics such as immunotherapy or gene therapies leads to new defining of criteria of tumor response evaluation, and the introduction of hybrid imaging modalities in this field.

Introduction of positron emission tomography (PET), combined with CT and/or MRI in a hybrid systems enabled us with the possibility not only to scrutinize a meticulous morphometric details, and to characterize various tissue structures, but also to examine the biochemical tissue composition in vivo, to obtain dynamic and functional information and to get the insight into the tissue internal bioarchitecture, by collecting numerous integrated or modality-based metabolic and molecular information.

Therefore, in the light of novel available and technologically performable structural and metabolic "state-of-the-art" applications and techniques, in this brief review we will try to bring more light to some of the possible directions and achievements that may give us an idea in which direction could the advance of technology lead us further to the reliable and accurate implementation of unique structural and metabolic imaging biomarkers in patients with cancer.





HEAD AND NECK I

IMAGING OF LARYNGEAL CANCER

Celebi I. (TR)

Larynx is a challenging organ for radiologists to evaluate especially in cancer patients due to its mobile nature and small important subsections. Radiologists have difficulties evaluating small lesions on computed tomography (CT) images whereas the mobility of the organ causes difficulties in the assessment of magnetic resonance (MR) imaging.

According to embryological development larynx is divided into 3 parts craniocaudally (supraglottis, glottis, infraglottis). The involvement of these parts by cancer shows prognostic importance. It can be deterministic for metastasis, prognosis and surgical approach. Approximately 75% of the glottic tumors present as early stage tumor (T1/T2), whereas supraglottic tumors may stay asymptomatic for a longer period reaching larger sizes thus presenting as late stage tumor (T3/T4). Paraglottic and preepiglottic invasion degree of the supraglottic tumor is correlated with cervical lymph node metastasis. Lymph node metastasis probability increases with advanced degrees of tumor invasion. The lymph drainage of supraglottic and deep glottic tumors are cranially (level 2 and 3). Inferior jugular lymph node (level 4) metastasis is not expected in larynx cancer. This condition appears mostly when tumor extends to infraglottic region.

CT has the advantages of common usage and temporal resolution. In some cases it can't provide sufficient contrast resolution for some anatomical subsegments, where maneuvered imaging can provide additional information. MR imaging provides information about tissue cellularity and perfusion along with its advantage of high soft tissue resolution. MR has more advantages especially in the follow-up of oncologic patients who are operated and/or received chemotherapy treatment.

IMAGING OF ORAL CAVITY AND OROPHARYNGEAL TUMORS

Nass Duce Meltem (TR)

Cancers of the oral cavity and oropharynx are the most common head and neck tumors. More than 90% of the tumors in this region are squamous cell carcinoma (SCC). SCCs of the oral cavity and oropharynx behave differently. The epithelium of the oral cavity which derives from ectoderm tends to give rise to more differentiated and less aggressive tumors. The epithelium of the oropharynx, on the other hand, is of endodermal origin and gives rise to poorly differentiated and more aggressive tumors.

Imaging improves the accuracy of staging and plays a crucial role in the treatment planning and management of these tumors. Physical examination and endoscopy generally underestimate the extent of the tumor while imaging allows the visualization of the pathology beneath the mucosa. The anatomic site at which the primary tumor originates determines the symptoms of the disease, the routes by which it may spread and the prognosis of the patient. Cross-sectional imaging helps to determine the size of the tumor, detects invasion the neighboring structures, bone or perineural





spread, assesses lymph node status and excludes a second tumor. Accurate staging helps to plan the treatment and follow-up during and after the treatment.

In this lecture, imaging features that affect staging and treatment planning will be emphasized and the specific information that needs to be conveyed to the referring physician will be discussed.

IMAGING OF ORBITAL PATHOLOGIES

Kozic D. (RS)

The orbit is an anatomically complex region, containing the eye globe, optic nerve, extraocular muscles, vascular structures, retroorbital fat and connective tissues. The aim of this presentation is to demonstrate magnetic resonance (MR) and computerized tomography (CT) anatomy of the orbital structures, to show main pathology of ocular, intraconal and extraconal regions, to illustrate imaging features of primary and metastatic lesions of the globe and retrobulbar structures, and to present the main imaging characteristics of orbital pseudotumors. Potential pearls and pitfalls are shown in order to increase the sensitivity and specificity in distinguishing neoplastic and non-neoplastic orbital processes. Extension of non-orbital lesions through orbital fissures into orbit is the important part of this lecture. Orbital CT was performed using 3mm slice thickness, reconstructed to 0.75mm, while MR study was performed using 3mm slice thickness, T1W, T2W, STIR sequences and T1W and T2W images with fat saturation. Postcontrast studies were performed with and without fat saturation. Retinoblastoma, melanoma and, metastatic lesions of the globe, pyogenic abscesses, inflammatory, iatrogenic, endocrine and posttraumatic orbital pathologies are illustrated.

ENDOVASCULAR TREATMENT OF WIDE NECK ANEURYSMS

Lazareska M.(MK)

Background: An aneurysm is an abnormal focal dilatation of an artery. Most of the unruptured aneurysms are asymptomatic and discovered incidentally or some of them symptomatic with mass effect or nerve palsy, but rupture of aneurysm results in a potentially life-threatening subarachnoid haemorrhage. Aneurysms with wide necks are defined by neck diameters greater than 4 mm or dome-to-neck ratios less than 2 and are the most difficult to treat with the endovascular method.

Aim: This study aimed to analyse the endovascular treatment of intracranial aneurysms with a wide neck.

Methods: The study population included 46 patients with 55 aneurysms referred to the University Clinic of Radiology in Skopje, the Republic of Macedonia for endovascular treatment during the period from 2015 to 2018. This study included 29 females and 17 males, ranging in age from 25 to 74 years.

Results: From total 55 treated aneurysms 19 were ruptured and 36 unruptured. Six patients were with multiple aneurysms. In these study complex aneurysms were treated with combined technique, 6 with balloon-assisted coiling, 27 with stent-assisted coiling, 6 stents, 3 with flow diverter assisted coiling, 9 FD and 2 with partial coil filling, 2 with coiling and neck remodeling without assistance device.

Conclusion: Aneurysms with wide neck remain a challenge for endovascular treatment. But the development of new techniques and materials in the treatment of aneurysms makes endovascular treatment of intracranial aneurysms safe and feasible.





BREAST IMAGING

BREAST CANCER SCREENING IN JAPAN

Nakajima Y.(JP)

The incidence of breast cancer has been dramatically increasing after 2000 in Japan. The high incidence in relatively younger women and the cancer death is still increasing. Government based Japanese cancer screening started by clinical breast examination (CBE) in 1987 and the mammography added in 2000. In 2017, CBE has no more recommended as a screening tool.

For quality control of mammography screening, central committee of breast cancer screening was organized in 2001 by 6 related scientific societies. The system was followed by ACR BI-RADS, but there are several unique points including category system and the qualification of institutions. Therefore, we call this system J BI-RADS. The category do conjunct with the imaging finding, but does not direct the management. The quality assurance of physicians, technologist and mammography are well qualified, but quality assurance of each institutional system has not yet been well assessed. Now a day Japanese association of breast cancer society try to monitor the surrogated indicators.

In mammography screening, dense breast is the big issue, because of high incidence of younger population and incidence of dense breast about 40 %. Dr. Ohuchi reported usefulness of adjunctive ultrasonography to screen for breast cancer in a randomised controlled trial in 2016. The result is that adding ultrasound to standard mammography tests in breast screening could result in improved rates of detection and decreased rate of interval cancer for breast cancer. The ultrasound screening is promising strategy but the standardization and education of examiners are the biggest issue. Cancer screening has potential risk of harms with false positive and over diagnosis in both mammography and ultrasound screening. To minimize harms, good quality control is key issue, and if ultrasonography screening will start, the integrated interpretation of mammography and ultrasonography is essential.

IMAGING OF MALE BREAST

Grujoska Svetlana Antevska (MK)

What is similar and what is different between male and female breast?

Imaging characteristics of male breast disease

Description of imaging findings

Normal male breast is very simple. SLAJD

The male breast comprises small nipple, a small areola, and subcutaneous fat. Fatty density of breast is interrupted only by supporting stroma and vasculature. There is no retroareolar density, there is no glandular tissue .

Cooper`s ligaments, found in female breasts are absent in male breast

No fibro-glandular tissue is visible under the nipple of the normal breast tissue.





It contains subareolar ducts similar to those found in prepubertal girls, which may elongate and branch when stimulated by hormones or a variety of drugs.

Lobule formation in the male breast is extremely rare which explains absence of the lesions arising from the lobules (fibroadenomas, fibrocystic changes and lobular carcinomas)

Male breast has no physiologic function.

Contrary to female breast where we examine patients with symptoms, as well asymptomatic...

We don't screen (for) male breast cancer

We don't examine asymptomatic male breast

Most men referred for breast imaging have symptoms like breast pain, tenderness, enlargement, swelling and/or palpable "lump"

Breast pain, tenderness

Breast mass, lump, swelling

Breast enlargement

Nipple retraction

Nipple discharge

Axillary mass

Gynecomastia and breast cancer are the two most important diseases of the male breast. The others arise from the skin and subcutaneous tissues

When dealing with male breast pathology and imaging work-up, it is important to have a firm understanding of the benign findings

Almost all breast pathology in women can also be found in men.

The majority of male breast symptoms are typically concerned about the cause of their problem and whether breast problems are benign or not.

Most breast symptoms in male patients are related to benign disease processes.

However, imaging of male breast is often performed on men with breast lumps to exclude breast cancer, which only comprises 1% of male breast masses.

Stage by stage management and outcome of current male breast tumor therapies are similar to those found in female breast cancer patients

Gynecomastia is the most common disease (anomaly) of the male breast, defined as benign proliferation of the male breast glandular tissue, excessive enlargement of the breast. It is most prevalent in the newborn, adolescent and elderly.

It often presents as a soft, mobile and elastic mass, or firm but generally not hard, in the retroareolar region, centred directly under the nipple.

Triangular or flame-shaped area of glandular tissue that points towards the nipple.

The tissue gradually intersperses with the fat and does not appear as a mass.

Pain may be present in gynecomastia of less than 6 months duration

Many causes have been reported, including ingestion of a variety of drugs, such as: reserpine, cardiac glycosides, cimetidine, thiazides, marijuana.

Testicular, adrenal, and pituitary tumors are associated with gynecomastia.

Chronic hepatic disease, by virtue of reduced ability to clear endogenous estrogens, can also cause male breast enlargement

True gynecomastia: Diffuse, non mass shaped, nodular and flame shape (dendritic?)

unilateral and bilateral SLIKI NA SLAJD when bilateral, it is most frequently asymmetric

Gynecomastia could be coexistent with breast cancer and obscuring it.



**METHOD**

Palpation usually demonstrates a soft, mobile and elastic mass in the subareolar region, centered directly under the nipple. Pain may be present in gynecomastia. Over time, gynecomastia can become fibrotic and patients often present with a painless firm mass that is difficult to differentiate from breast carcinoma.

WHAT IS NEW IN BREAST CANCER DIAGNOSIS?**Djilas D.(RS)**

There is a growing battery of features that have been validated to determine a woman's risk of future breast cancer: genetic and genomic information, personal and family history of breast cancer, personal history of benign breast biopsies, especially with atypias, exposure to hormones, breast density on mammography, and background parenchymal enhancement on magnetic resonance imaging (MRI). There are currently no options for primary prevention in women with average risk or intermediate risk. Major drivers of a woman's individual risk are age, genetic predisposition, and breast composition—all factors that are not at all, or hardly modified by one's lifestyle. Invasive measures for primary prevention, such as risk-reducing mastectomy, salpingo-oophorectomy, or chemoprevention, do exist but are justifiable only in the few individuals who are at very high risk. We are left with secondary prevention, namely, early diagnosis by screening. Screening mammography has its limits especially in women with dense breasts, it promotes overdiagnosis of prognostically unimportant disease, as well as underdiagnosis of prognostically relevant cancers. For that reason many new breast cancer screening methods have been developed and validated for screening in the past decade—from hand-held or whole-breast ultrasound, digital breast tomosynthesis, to MRI. In this lecture, the potential place of all of these methods will be discussed, as well as some new perspectives in personalized medicine regarding breast cancer diagnosis,

MUSCULOSKELETAL RADIOLOGY I**SPONDYLOARTHROPATHIES-IMAGING SPECTRUM****Georgiev R. (BG)****a) Introduction**

Spondyloarthropathies present with rheumatoid factor (RF) negative inflammatory arthritis and enthesopathy affecting spine and sacroiliac joints. This group includes familial disposition, increased incidence of HLA-B27, common spectrum of extra-articular features (predominantly muco-cutaneous). Five subgroups are accepted, including ankylosing spondylitis, reactive arthritis (Reiter's syndrome), psoriatic arthritis, arthritis associated with chronic inflammatory bowel disease, and undifferentiated spondyloarthropathies.





b) Purpose,

The clinical, laboratory findings and the imaging spectrum in different spondyloarthropathies are often overlapping but sometimes radiological signs are crucial for the diagnosis. X-ray pictures and CT demonstrate well the chronic inflammation, while MR is suitable for detection of some early and acute changes. That's why MR imaging is included in the modern diagnostic criteria for these diseases.

c) Materials and Methods ,

Typical radiological signs are shown - including Romanus and Andersson lesions in ankylosing spondylitis, ankylosis, syndesmophytes, arthritis of costo-vertebral joints, enthesitis in peripheral tendons and spinal ligaments, erosions and subchondral oedema, sclerosis and periostitis.

d) Results,

Active inflammatory lesions in the sacro-iliac joints include signs of osteitis, enthesitis, synovitis, capsulitis. The osteitis changes with bone marrow oedema is decisive for the diagnosis and must be presented in two consecutive sections. The other musculo-skeletal manifestations could be more specific for the different entities in this group of diseases and include osteoporosis, osteonecrosis, periostitis, hypertrophic osteoarthropathy, dactylitis.

e) Conclusion.

MRI is the threshold diagnostic imaging method for early diagnosis in sacro-illitis, preceding the x-ray positive signs with several years. The presence of subchondral and periarticular bone marrow oedema is obligatory for the diagnosis of sacroiliitis. Spondyloarthropathies are diverse group of immune - mediated inflammatory diseases of spine and joints with broad imaging spectrum but sometimes typical radiological signs and specific muco-cutaneous and other system manifestations.

POSTOPERATIVE KNEE - MRI AFTER ACL RECONSTRUCTION

Njagulj V.(RS)

The most common surgical procedures of the knee include meniscal surgery, partial meniscectomy and meniscal repair, anterior cruciate ligament (ACL) reconstruction and also cartilage repair. It is considered the standard of care for young active patients who wish to return to sport activities after injury. Even there is the of clear evidence of its ability to reduce the onset or progression of knee osteoarthritis, ACL reconstruction is expected to prevent further meniscal and cartilage lesions that could occur in unstable knee.

The purpose of this article is to evaluate the most often postsurgical appearances of the knee after ACL reconstruction. Here will be presented a normal postsurgical MRI appearances of the reconstructed ACL with magnetic resonance imaging (MRI). How to evaluate imaging findings of ACL graft failure and to review the imaging appearance of potential complications associated with ACL reconstruction. Complications are possible at the graft and donor site.

MRI is emerging as an important tool of diagnosis and evaluation of the knee and ACL injuries, and also important tool in follow-up and reinjury. Using MRI radiologist is able to recognize the failure of the procedure, displaced bone fragments, re-tear or other kind of the reinjury.

ACL is one of the most important stabilizers of the knee and its injuries can result in increased knee instability, limitation of activity, pain and even osteoarthritis.





Surgical procedures of the knee allow patients to return to their pre-injury activities. Knowledge of the normal postoperative appearance of the structures, as well as potential complications or appearance of repeated injury is essential for accurate interpretation. It is also important to know the different surgical reconstruction techniques.

MR IMAGING OF THE ANKLE

Cevikol C. (TR)

The most common clinical application of the ankle MRI is soft tissue trauma. In most of the situations; the patient almost always has a complaint at a specific location of the ankle. This may be extremely obvious, such as inversion injury with immediate lateral ankle pain, or sometimes less obvious, such as an inversion injury with late posteromedial or deep ankle pain.

A careful clinical assessment is very important in these cases. Because, after the clinical evaluation, the anatomical structure that is suspected of pathology can usually be identified. In clinically indeterminate cases or in patients with chronic ankle pain, MR imaging is useful for the evaluation.

From the radiologists point of view, the knowledge of normal anatomy and several pathological entities, is helpful to reach the correct diagnosis. The MRI technique is very important to better visualize the anatomical structures and pathologies. The scan plane and selection of pulse sequences are also very important for the standardization and understanding of the images.

In this talk, ankle MR imaging protocol and interpretation and the diagnosis of common ankle pathologies in combination with the related anatomy will be reviewed. Common ligamentous, tendinous and bony problems, anatomic variations, inflammatory lesions and, some uncommon pathologies of the ankle will be discussed briefly.

IMAGING OF THE DIABETIC FOOT

Sabir N.(TR)

Diabetic foot is a significant complication of diabetes. It comprise a broad spectrum of pathology. The range of the spectrum in those presenting can extend from a foot problem secondary to a complication of diabetes such as neuroarthropathy, ulceration, or infection to those with a diagnosis of diabetes who have routine foot pathology such as metatarsalgia or fracture. Diagnostic imaging is a crucial factor determining surgical decision and extent of surgical intervention. Appropriate radiologic investigations may help in determining the diagnosis; however, imaging of the diabetic foot often produces nonspecific findings that require careful interpretation.

In a foot with deformity and resultant pressure ulceration, chronic neuroarthropathy may be complicated by osteomyelitis and/or septic arthritis. The "secondary signs" of osteomyelitis such as ulcers, sinus tracts, and fluid collections combined with typical fragmentation and subluxation suggest an infected neuroarthropathy. On MRI scans of previously scanned neuroarthropathy, evidence of progressing bone erosions, loss of subchondral cysts, extensive marrow abnormality, and enhancement of the articular surface may help with diagnosing superimposed infection. Periarticular marrow edema and joint fluid are nonspecific; however, florid synovial enhancement on postcontrast images would indicate infection. Although bony destruction is typical of both disease processes, extensive fragmentation is classical for neuroarthropathy.





Diagnostic imaging plays a critical role in the diagnosis and management of diabetic foot disorders. The use of imaging modalities in the investigation of diabetic foot problems is a daily occurrence; however, an understanding of the limitations of these tests is vital for accurate diagnosis. Clinical correlation is important, and an appreciation of subtle clues in the history and physical examination can help to guide investigation and management. The use of a systematic approach to diagnosis of diabetic foot problems requires a combination of these clinical findings with appropriate imaging modalities.

UROGENITAL RADIOLOGY

DWI OF THE FEMALE PELVIS

Akata D.(TR)

In the era of “imaging safely”, diffusion weighted imaging acts as an indispensable noninvasive problem solver. In this presentation all the pearls and pitfalls of the DWI in gynecologic oncology will be discussed.

MRI is now considered an accurate method for both detection and staging of cervical cancer. On T2WI, tumours tend to appear hyperintense and are easily recognizable from the hypointense stroma. DWI has been considered very helpful in the detection of cervical cancer. The added value of DWI in the assessment of treatment response in patients undergoing surgery and/or chemo-radiotherapy (CRT) has been recognized. The addition of DWI to T2W sequences considerably improves the diagnostic ability of MRI in the assessment of cervical cancer recurrence. It can be assessed both qualitatively by checking signal intensity on high b-value images and quantitatively with ADC measurements. Both persistence and recurrence tend to appear hyperintense at high b-values and hypointense on the ADC map.

DWI appears to assess early tumour response to CRT even before volumetric changes are seen.

Magnetic Resonance Imaging (MRI) is the modality of choice to preoperatively determine the depth of myometrial invasion where fertility preserving treatment is considered. Recently DWI has been shown to increase accuracy of assessing depth of myometrial invasion. The potential superiority of DWI in assessing myometrial invasion might be explained by its increased accuracy in difficult MRI staging cases, i.e. in the presence of leiomyomas, adenomyosis, poor tumor-to-myometrium contrast, and cornual tumor extension.

In case of early stage, small tumors may not be associated with endometrial thickening. In those cases, diffusion may be particularly helpful to detect small tumor among the normal non-distended endometrial cavity. Studies have demonstrated the ADC values of endometrial cancers are significantly lower than those of endometrial polyps and normal endometrium.

Malignant ovarian lesions tend to be more cellular which demonstrate diffusion restriction by producing high signal on DW-MR imaging. In addition it may also increase the lesion conspicuity, and it is particularly helpful in detecting peritoneal metastases and recurrent disease. The signal intensity tends to increase by increasing the b-value and corresponding low signal intensity on ADC map.

It should be noted that many benign ovarian masses including endometriomas, mature cystic teratomas and fibrothecomas may also demonstrate restricted diffusion. T2 shine through and T2 blackout effects are the major pitfalls in DWI of the adnexa. Because of this overlap, it must be borne in that ADC maps and high b-value images should be interpreted in conjunction with anatomic images and morphological clues derived from other conventional MR sequences.





A PARADIGM SHIFT IN PROSTATE MRI

Spirovski M.(RS)

Magnetic resonance imaging (MRI) provides valuable information on clinically significant prostate cancer detection, tumor localization, biopsy guidance, staging, optimal treatment planning, and the surveillance of the disease. Although the first clinical employment was almost exclusively related to staging histologically proven cancer, the major improvements in other stages of the prostate cancer care have been made, with the most significant in the field of detection.

Introduction of functional techniques - MR spectroscopy, dynamic contrast-enhanced and diffusion-weighted imaging, provided further information on tumor metabolism, vascularization and cellularity, and combination with morphological T2-weighted imaging in multiparametric MRI (mpMRI) improved diagnostic accuracy of clinically significant cancer detection and localization compared to standard systematic TRUS guided biopsy. Systematic biopsy, due to heterogeneity of this type of tumor and the limitation of the technique, does not always provide accurate information on presence, localization, volume and grade of prostate cancer, with certain number of false negative results, overdiagnosis in the means of detection of clinically insignificant cancer, undergrading and underestimation of the tumor volume and extent. Repeated systematic biopsies even showed increase in number of insignificant cancer detection. Several years ago mpMRI has been recommended after negative biopsy, and persistent clinical suspicion of prostate cancer, along with targeted biopsy with MRI guidance. Following the results of a recent multi-center study which showed that mpMRI could reduce unnecessary biopsies by more than quarter if performed prior to the first biopsy, this year for the first time mpMRI is recommended prior to the biopsy in biopsy naïve men, and in the case of negative mpMRI, allows the possibility to omit the biopsy.

Along with paradigm shift from solely staging histologically proven cancer to the possibility of clinically significant cancer detection prior to the biopsy to guide the biopsy, in this review other significant improvements of mpMRI in prostate cancer care will be discussed.

PIRADS V2 AND GLEASON SCORE - SIDE BY SIDE OR MILES APART

Dineva S.(BG)

Learning objectives:

1. To understand the common sources of PIRADS misstaging and how to avoid them.
2. To understand the borderline of PIRADS 3.
3. Outlining current weaknesses of multiparametric MRI and the need for something new.

Multiparametric magnetic resonance imaging of the prostate is considered nowadays as the diagnostic modality of choice for prostate pathology detection. As remains true for the rest of the imaging reporting and data systems, findings are being divided into scores (1 to 5) according to the possibility for clinically significant prostate cancer confirmation (pirads >3). The clinical significance itself is defined by pathology classification system of Gleason, using mainly scores 6-10. A perfect match between the two systems is what radiologist strive for.

A number of studies are performed evaluating different parts of the scientific spectrum of overall diagnostic accuracy of multiparametric MRI and they all use Gleason score as a reference. Different cohorts compare PIRADS and pathology results with respect to PSA, imaging protocols and operator experience. In some groups mp MRI is performed after TRUS biopsy and before surgery and some rely on imaging for TRUS guidance which outlines the emerging role of fusion MRI/US biopsy.





What remains an interesting issue is where do we stop the follow up after PIRADS evaluation and what are the possible risks? Multiparametric MRI and PIRADS itself are still a work in progress. What are the new horizons and challenges among radiologists and are there new methods with higher diagnostic scores?

IMAGING OF TESTICULAR TUMORS

Stojovska Jovanovska E.(MK)

Testicular neoplasms are the most common malignant tumors in the male population aged 18-35 years and account for 11-14% of mortality from malignant disease in men aged 25-34.

Primary testicular neoplasms may originate from any type of testicular cells, but most, about 95% are germ cell tumors, and most of the remaining 5% non-germ cell tumors originate from Leydig and Sertoli cells.

The diagnosis of each palpable fort in the scrotum begins with ultrasound (UC), whereby localization, size, and some of the characteristics of the tumor can be determined, but with respect to tumor extension, in the sense of metastases, the computer tomography (CT) of the abdomen and small pelvis is superior.

Magnetic resonance imaging (MR) is an imaging method that gives the most diagnostic capabilities, with the highest sensitivity compared to the previous one, in determining the type of neoplasm as well as in relation to the tessicular and paratesticular propagation.

The purpose of this lecture is to make a radiological overview of the most common testicular tumors of our practice, with particular reference to the possibilities of MR as a diagnostic procedure. We will, also, present some testicular tumors with low percentage representation, a case of extragonadal, retroperitoneal, mixed germ cell tumor, billateral Leydig cell tumor, and testicular abscess.

JUNIOR FORUM SESSION

HOW TO INTERPRET A MAMMOGRAM: TRAPS AND PITFALLS

N. Dimitropoulos (GR)

Mammography is the standard of reference for the detection of breast cancer, yet 10%–30% of breast cancers may be missed at mammography. Possible causes for missed breast cancers include dense parenchyma obscuring a lesion, poor positioning or technique, perception error, incorrect interpretation of a suspect finding, subtle features of malignancy, and slow growth of a lesion. The radiologist can take a number of steps that will significantly enhance the accuracy of image interpretation at mammography and decrease the false-negative rate. These steps include performing diagnostic as well as screening mammography, reviewing clinical data, strictly adhering to positioning and technical requirements, being alert to subtle features of breast cancers, comparing recent images with earlier mammograms to look for subtle increases in lesion size, looking for additional lesions when one abnormality is seen, and judging a lesion by its most malignant features.





CHARACTERIZATION OF LIVER LESIONS: BENIGN OR MALIGNANT

Blazic I. (RS)

Imaging is an important decision-making tool in the diagnosis of focal liver lesions as it can accurately differentiate benign from malignant lesions in most of the cases. Differentiation between malignant and benign focal liver lesions and establishing the correct diagnosis are of great importance in treatment planning for patients with liver neoplasms and in patients with benign liver lesions for avoiding unnecessary biopsies.

Focal liver lesions are very common in the general population. Most of detected hepatic lesions are benign. Therefore, it is important to avoid unnecessary interventions for benign lesions, while at the same time ensuring accurate diagnosis of hepatic malignancies. Many oncological patients may have incidental benign liver lesions. In planning treatment for cancer patients, it is critical to avoid inappropriate treatment decisions based on misdiagnosis of a benign lesion as a metastasis or primary liver malignancy.

Focal liver lesions could be classified into three clinical categories: benign lesions for which no treatment is needed, benign lesions for which treatment is required and malignant liver lesions for which treatment is always required if feasible. A useful general approach to distinguishing benign from malignant hepatic masses is to identify one or more of the imaging features diagnostic of a common benign lesion or alternatively a feature pathognomonic of a malignant hepatic lesion. These imaging features and the appropriate differential diagnostic considerations will be described.

This lecture will give a comprehensive overview of the major imaging features of the common benign liver masses (cyst, hemangioma, focal nodular hyperplasia and hepatocellular adenoma) and hepatic malignancies (hepatocellular carcinoma, cholangiocarcinoma, liver metastases). Also, a general approach to distinguishing between benign and malignant hepatic lesions will be outline. The lecture will be focused on the use of computed tomography and magnetic resonance imaging.

ACUTE ABDOMEN: DECISION MAKING IN DIAGNOSTIC IMAGING STEP BY STEP

Onur Mehmet Ruhi (TR)

Abdominal emergencies are frequently encountered in emergency departments. Myriad of conditions including inflammatory, infectious, vascular, mechanical (obstructive) and neoplastic diseases may cause acute abdominal pain which range between benign self-limiting disorders and life-threatening conditions. Early and prompt diagnosis of abdominal emergencies prevent unnecessary interventions and lower morbidity and mortality rates. Imaging techniques including radiography, ultrasonography (US), computed tomography (CT) and magnetic resonance imaging (MRI) may play crucial role in the diagnosis and management of abdominal emergencies. US remains as the first imaging tool in the assessment of abdominal emergencies as an ionizing radiation free imaging technique with the ability of real-time imaging. CT is the mainstay imaging technique in most of the abdominal emergencies with the advantages of fast scanning, high spatial resolution and multiplanar imaging capability which make this imaging technique as first imaging option in some emergency departments. Dual-energy CT opens new horizons in abdominal emergencies with the advantages of acquiring virtual unenhanced images, evaluation of tissues with varying attenuation at different X-ray energy levels and detection and measurement of iodine content in tissues. MRI is a problem-solving imaging technique in abdominal emergencies which may be helpful in various conditions with the benefits of high contrast resolution and ionizing radiation free scanning capability. Diagnosis of abdominal emergencies with imaging





techniques necessitates three main steps to be accomplished. First, selection of appropriate imaging technique according to medical history, symptoms and physical examination findings; second, optimizing imaging technique protocol in accordance with patient's conditions and differential diagnosis and third, assessment of imaging findings with the knowledge of typical and atypical imaging features of several conditions that may result in acute abdomen. In this presentation, assessment of acute abdominal emergencies in emergency radiology unit will be summarized with emphasizing the three steps abovementioned and radiation dose reduction strategies.

INTERVENTIONAL RADIOLOGY I

FIBROID EMBOLISATION

Bérczi V1, Valcseva É1, Kozics D1, Kalina I1, Kaposi P1, Sziller P2, Várbíró Sz2, Botos E1, Tóth A1, Ács N2

Department of Radiology¹, 2nd Department of Gynaecology and Obstetrics², Semmelweis University, Budapest, Hungary

Uterine artery embolisation (UAE) is an effective, minimal invasive alternative of hysterectomy for treating symptomatic fibroids or adenomyosis. More than 630 patients have been treated at our clinic since 2008. This is one of the two major UAE centers in Hungary. The conclusions of how to set-up such a clinic will be discussed

Following common femoral artery puncture under local anaesthesia, typically 500-700 μ m PVA particles are injected into both uterine arteries. The patients have MRI before UAE and 6 months after the procedure. Symptom improvement was 80%, partial improvement 15%, no improvement 5% of the cases. The shrinkage of the fibroids at 6 months - based on MRI - is in average 50% in volume. On the 6-month control MRI - in most cases -, fibroid does not enhance contrast medium, showing that the fibroids have no longer any blood flow, whereas the myometrium shows normal enhancement. The internationally accepted indications and contraindications as well as the anatomic variations will be discussed.

Data-analysis concerning large and small fibroids was done on 303 patients in our center; 262 patients had small [largest diameter < 10 cm (Group 1)], whereas 41 patients had large [largest diameter > 10 cm fibroid (Group 2)]. There were 4 myoma expulsions, 1 acute myomectomy, and 2 acute hysterectomies reported from Group 1, meanwhile 1 myoma expulsion, 1 acute myomectomy, and 2 acute hysterectomies were documented from Group 2 (NS differences). These data showed that fibroids larger than 10 cm can also be embolised effectively and safely. Our data on the predictive value of MR parameters on the shrinkage ratio will also be discussed: localisation, T2 SI, contrast enhancement, and < 50 cm³ fibroid volume were associated with better volume reduction; these may help with treatment decisions.





ENDOVASCULAR TREATMENT OF PORTAL HYPERTENSION

Brontzos E. (GR)

Portal hypertension is the main complication of the liver cirrhosis and may lead to serious complications as variceal bleeding and refractory ascites which are associated with poor patient prognosis. Transjugular intrahepatic portosystemic shunt (TIPS) is a percutaneous, minimally invasive method of creating a portosystemic shunt for decompression of portal hypertension. A transjugularly inserted needle through the catheter is used to puncture the liver from a central portion of the hepatic vein and enter the main portal branch. The needle tract is then dilated by a balloon catheter establishing a connection between the portal and systemic circulation directly inside the liver parenchyma. The parenchymal tract is kept open by insertion of a self expandable stent-graft. TIPS offers an effective treatment for patients with complications of portal hypertension, mainly prevention of variceal rebleeding and recurrent or refractory ascites.

ENDOVASCULAR TREATMENT OF HAEMODIALYSIS FISTULAS

Karnabatidis D. (GR)

The number of patients with End Stage Renal Disease (ESRD) is increasing worldwide every year, so do patients on Haemodialysis. Vascular access maintenance is of paramount importance for these patients. Within the last ten years there is increasing interest, technological advancements and evidence to support the endovascular first approach for the treatment of dysfunctional and thrombosed vascular access, together with tunnelled catheter insertion and last option salvage procedures, while lately the ability of endovascular vascular access creation is gaining increasing interest further extending the service endovascular specialists can provide to haemodialysis patients. Dysfunctional access treatment, thrombectomy procedures, central venous catheters, central venous stenosis treatment, no-option patient procedures, immature fistulae treatment, science in the background, trial updates, fundamental knowledge on u/s mapping, and clinical evaluation of dialysis access, are crucial today.

PERCUTANEOUS UROLOGICAL INTERVENTIONS

Kehagias E. (GR)

Percutaneous interventions for obstructive uropathy include percutaneous nephrostomy and percutaneous ureteral stenting. These procedures are valuable in cases where urine diversion is needed, both in acute and chronic cases, such as inflammatory, malignant or iatrogenic causes of obstruction and can offer access for endourologic procedures. Following key technical concepts and using ultrasound and/or fluoroscopy guidance percutaneous urologic procedures are safer, quicker and with a high success rate.





IMAGE INTERPRETATION SESSION

NEURORADIOLOGY I

CEREBELLAR IMAGING - VARIETY OF SURPRISES AND CHALLENGES

Zlatareva D. (BG)

Pathology of the cerebellum is posing many questions that have to be resolved by clinicians and radiologists. His anatomy and complex physiology have to be known by imaging diagnostic specialist as prerequisites to make a proper diagnosis. The cerebellum is involved in maintaining posture, gait and motor tone but also coordination. This infratentorial structure has particular abnormalities and clinical symptoms different from the rest of the brain. However some systemic disease, toxic, metabolic, degenerative, inflammatory and infectious disorders could also affect cerebellum. Technical improvements of the MR imaging have led to increasing frequency of identification and diagnosis of the cerebellar pathology.

However the questions regarding some genetic conditions and their phenotypes still remain. This lecture will present typical and not so common pattern for cerebellar pathology and differential diagnosis along with clinical information. Some pitfalls and their solution will be discussed and some practical aspects of imaging diagnosis will be given that is of utmost importance for patient's management.

GADOLINIUM DEPOSITION IN THE BRAIN

Papadaki E.(GR)

Gadolinium-based contrast agents (GBCAs) are commonly used intravenously in MRI examinations for the diagnosis and follow-up of various diseases. They are known to act by shortening the T1 relaxation time of the abutting hydrogen nuclei, thus, tissues with a high concentration of contrast exhibit enhanced tissue intensity in MR images. Since their introduction in 1987, over 300 million doses of GBCAs have been administered worldwide. Rest aside minimal allergic reactions and adverse effects, GBCAs have long been considered relatively safe.

In 2014 Kanda et al were the first to raise suspicion regarding Central Nervous System (CNS) accumulation of these agents. They reported high MRI signal intensity at the dentate nuclei and the globus pallidi on unenhanced T1-weighted images, in adult patients, after repeated exposures to GBCAs. Subsequently, numerous studies, in both adults and pediatric patients, further confirmed the long-term CNS Gadolinium (Gd) retention that followed multiple GBCA- enhanced MRI scans. Pathological human and animal studies, also, showed similar CNS Gd deposition patterns.

Therefore, concerns have been raised about safety and potential neurotoxicity and the European Medicines Agency (EMA) in 2017 confirmed restrictions on using linear Gd agents. Macrocyclic agents





(gadobutrol, gadoteric acid and gadoteridol) were considered more stable with a lower propensity to release Gd than linear agents. These products were allowed to be used in their current indications but in the lowest possible doses to suffice for diagnostic purposes, although there is no doubt that repeating administration of macrocyclic GBCA could also lead to Gd deposition in brain parenchyma. Of note is the fact that, to-date, there no brain histopathological changes related to Gd deposition and the exact clinical or biological importance of this deposition remains unknown. Further research is needed to elucidate the mechanisms of Gd deposition in the brain, investigate the associated biological effect or clinical impact and determine possible effects in behavior and cognition.

IMAGING CHALLENGES OF BRAIN DEATH

Jefić S. (BIH)

The contemporary international scientific community considers death as a process defined by irreversible cessation of all brain and brainstem functions. Brain death (BD) indicates the point of irreversibility of the process of death. At the same time, vitality of other tissues with different capacities of resistance to the loss of oxygen can be maintained for the purposes of transplantation medicine, but also with a huge economic impact on medical resources. In addition, the conventional concept of death as an event, not as a process, may make diagnosing of BD very challenging. Diagnosis of BD is usually established by using the defined physical examination for confirmation of three cardinal findings: coma, absence of brainstem reflexes and apnoea. However, under the circumstances of uncertainty about reliability of clinical tests or impossibility to perform such tests, certain ancillary tests are recommended: EEG and evoked potentials for assessment of cerebral electrical activity and imaging studies for demonstration of cerebral circulatory arrest. According to most guidelines, imaging techniques - transcranial Doppler sonography, catheter cerebral angiography, CT angiography, CT perfusion, MR angiography and perfusion scintigraphy - have a role to play in the diagnostic algorithm of brain death. Other imaging methods capable of revealing structural changes in the brain around the occurrence of death (non-contrast-enhanced CT, MRI, MR spectroscopy, diffusion-weighted MRI) and functional changes (fMRI) are still being studied as potentially useful in the diagnosis of brain death, but are less frequently applied in clinical settings. A radiologist involved in the process of diagnosing brain death (PDBD) faces various challenges related to:

- physicians - there must be a close collaboration with physicians; a so-called second-line position of imaging in PDBD does not diminish the radiologist's responsibility to make an accurate diagnosis and support his or her colleagues;
- patients – in some cases the demand for urgent action; choice of particular imaging modality may be limited by life-support equipment;
- imaging techniques – familiarity with the entire PDBD is critical, both with relevant neuroimaging possibilities as well as with the phenomena that most commonly mimic BD, such as hypothermia, locked-in syndrome and drug intoxication.

To ensure accuracy of diagnosing death, it is essential to adopt practical guidelines for diagnosing BD.

Key words: Brain death, diagnosis, imaging modalities





MECHANICAL THROMBECTOMY IN ACUTE STROKE- OUR INITIAL EXPERIENCE

Vjolca A. (MK)

We aimed to study the technical and clinical aspects as well as safety and efficacy of mechanical thrombectomy (MT) in patients with large vessel occlusion anterior circulation -related acute ischemic stroke.

Nineteen patients who were treated with MT in our institution between November 2018 and March 2019 were screened for medical records and included in the analysis.

The decision whether or not to treat the patients was made based on time window after symptoms onset, age, clinical status, preexistent vascular disease, location of the vessel occlusion.

All patients suspected of having an acute stroke underwent emergency imaging of the brain including NECT with or without CTA.

Technical success or failure of endovascular revascularization and reperfusion of the targeted artery was assessed with angiography using modified treatment in cerebral ischemia (mTICI score), and clinical success as sustained resolution of symptoms.

We describe the patient emergency pathways, vascular access, sedation regimes, MT technique with stent retrievers alone or combined with aspiration.

Our conclusion is that getting the time-critical treatment after acute ischemic stroke and accumulating additional experience about the strategy of treatment approaches can be the difference between a full recovery and serious disability or even death.

HEPATOBILLIARY RADIOLOGY I

HCC IN CHRONIC LIVER DISEASES

Alexiou E. (GR)

There is a high incidence of hepatocellular carcinoma (HCC) in patients with chronic liver disease, resulting from viral hepatitis infection, primary or transfusional haemochromatosis, PBC and non-alcoholic steatohepatitis. Regular surveillance with liver ultrasonography is mandatory for the early detection of HCC, ideally when the size is up to 2 cm. Every new focal lesion identified with ultrasound which is larger than 1 cm, should trigger further evaluation with cross-sectional imaging, which is CT or ideally MRI. It is mandatory that the exam protocol should be multi-phasic and include pre-contrast scan, contrast administration of iodine or extracellular gadolinium as well as arterial, portal venous and equilibrium phases. On equivocal cases, MRI with hepatospecific contrast agent may be very useful but should never precede. The typical imaging features of HCC include, early contrast uptake on arterial phase, washout on portal or equilibrium phase and delayed ring enhancement on equilibrium phase. In chronic liver disease where cirrhosis has been established, it is a common phenomenon to detect various nodules (regenerative, siderotic, steatotic, low grade and high grade dysplastic) the so-called cirrhotic nodules. Practically is very difficult to differentiate between regenerative from low grade dysplastic nodules (unless iron or fat is predominant) and they tend to be reported as one entity. It is an imaging challenge to differentiate a high grade dysplastic nodule from early or well-differentiated HCC. In such cases, MRI with hepatospecific contrast agent might be extremely useful. The wide variability in the terminology used by radiologists to describe such lesions result in miscommunication between radiologists and referring physicians. To overcome the problem,





structured reporting has been proposed. LI-RADS is a widely used comprehensive system for standardizing the terminology, technique, interpretation, reporting and data collection of liver imaging and has recently been integrated into the AASLD 2018 HCC clinical practice guidelines. The system provides a diagnostic algorithm in order to classify a lesion according to its probability to represent HCC with LR-1 category representing a definitely benign lesion and LR-5 representing definitely HCC. Furthermore, the system serves as a management tool suggesting imaging workup options and time intervals for each category.

HCC: THE ROLE OF LOCAL ABLATION

Akhan O. (TR)

Image-guided tumour ablation in patients with HCC has already become an integral part of the treatment. HCC is a difficult disease for the treatment because of the underlying chronic liver disease in most majorities of the patients and high risk of recurrence. Surgical resection was accepted to be the only treatment with prolonged survival in patients with HCC. However, Hepatic resection (HR) which is the radical treatment option is possible for only 15-20% of patients with HCC because of some reasons such as multifocal diseases, large tumour size and comorbid diseases etc. Therefore image-guided tumour ablation (IGTA) techniques such as RFA, Microwave and/or IRE, have been widely used in the treatment of HCC. Among them Radiofrequency ablation (RFA) has already become very popular with successful results for the treatment of HCC in very early and early stages according BCLC classification. The best treatment of choice in patients with limited tumours is liver transplantation. In patients with early stage HCC, Image-guided tumour ablation is accepted to be the best treatment of choice if liver transplantation or hepatic resection is not possible. In patients with very early stage HCC (one lesion smaller than 2 cm. in diameter) Image-guided tumour ablation is considered to be the first treatment option.

After having the normal bleeding parameters procedure is carried out under either US or CT guidance by percutaneous approach. It is also possible to perform ablation intraoperatively whenever indicated. IGTA is a safe and effective method with successful results. It can also be repeated against tumour recurrence. Long-term results of IGTA in HCC have already indicated that 5-year survival rates are compatible with the results of surgery in the indicated patients.

DIFFUSE LIVER DISEASES

Erturk S. M (TR)

Diffuse parenchymal liver diseases present a serious health problem that affects millions of people worldwide. They can be roughly categorized as vascular diseases, storage disorders, and infectious and inflammatory diseases. In clinically advanced cases liver fibrosis and cirrhosis may develop and the risk of hepatocellular carcinoma increases. Recent advances in imaging technology allow radiologist to detect diffuse parenchymal liver disease in its early stages. In this presentation, I will try to focus on the imaging strategies such as novel MR imaging techniques that can be employed to detect fat and iron accumulation in the liver, on the storage diseases such as NASH and Wilson disease, on infectious diseases such as viral hepatitis and parasitic liver diseases, and on the vascular problems such as Budd-Chiari's syndrome. I will try to discuss the pathophysiology of different clinical settings and their important imaging findings.





IFN FREE TREATMENT OF THE CIRRHOTIC PATIENTS – IMAGING CHALLENGES

Michai F. (RO)

Senior Radiologist, Department of Radiology-Imaging, County Emergency Hospital “St. Spiridon”, Assistant Professor of Radiology, University of Medicine and Pharmacy “Gr. T. Popa”

Cirrhosis is an increasing cause of morbidity and mortality, one of the most common causes being hepatitis C virus (HCV) infection. For a long period of time, cirrhosis was considered an irreversible end stage of liver disease, mostly due to lack of treatment possibilities, with very few exceptions.

Advances in understanding of HCV molecular biology have created the opportunity to develop designed drugs that target specific steps in the infection and replication of HCV. This breakthrough has led to the development of direct acting antivirals (DAAs) and, from this, to the rapid approval of HCV treatment and the possibility for disease elimination. At the present time, chronic hepatitis C is the only chronic viral infection that can be cured with antiviral therapy.

Diagnosis, staging and complications’ assessment are equally important in patients’ management, as well as establishing the right indication for antiviral treatment and further follow-up.

The purpose of the presentation is to review the main morphological transformations of liver as a result of chronic injury and to emphasize the role of imaging in surveillance of treated patients.

EMERGENCY RADIOLOGY -TRAUMA

MDCT TECHNIQUE IN THE DIAGNOSIS OF POLYTRAUMA

Palkó A.(HU)

Penetrating and blunt injuries may be isolated or combined with injuries of other regions. They may affect the parenchymal and/or the hollow organs and be associated with severe bleeding, infection and other complications, including multiorgan failure. Clinical appearance may be dramatic but even severe injuries may be free of symptoms initially. Fast diagnosis is imminent in order to select and start appropriate therapeutic measures. Multidetector CT (MDCT) is the single best of the available imaging methods to achieve this goal with its capacity to visualize simultaneously multiple injuries in most body regions. Its short measurement time allows visualization of more than one region or even the whole body without disturbing motion artifacts of non-cooperating patients. MDCT performs optimally if examination technique is fully adapted to the type and localization of the injury, and to the general condition of the patient. To achieve this performance MDCT examinations of polytrauma patients should be performed under direct control and supervision of the radiologist and immediate reporting of the results is indispensable.





IMAGING OF ORBITAL TRAUMA

Čengić A. (BIH)

Orbital trauma represents important challenge for radiologist. Prompt radiologic assessment in orbital trauma requires basic knowledge of potential injuries of eye and anatomy to determine the gravity and the extent of traumatic injury. Common posttraumatic orbital injuries include fractures of orbital walls, anterior chamber injuries, injuries to the lens, open-globe injuries, ocular detachments, intraorbital foreign bodies, carotid cavernous fistula, and optic nerve injuries.

CT is the primary imaging modality for orbital trauma assessment due to its rapidity and ability to detect bone fractures, soft tissue injury and presence of foreign body. The best protocol is to obtain thin-section axial CT scans, and then to perform multiplanar reformation. Other imaging methods that can be useful are ultrasonography and MRI.

For this reason radiologists should be prepared to rapidly recognize common orbital injuries and should use systematic approach to evaluate the orbit and its content. Comprehensive checklist should include the following: 1) evaluation of potential orbit fractures, and any herniation of orbital contents; 2) evaluation of the anterior chamber; 3) evaluation the position of the lens; 4) evaluation of the posterior segment of the globe, check for bleeds or abnormal fluid collections, and radiopaque or radiolucent foreign bodies; 5) evaluation of the ophthalmic veins and the optic nerve complex, especially the orbital apex.

IMAGING OF CARDIAC TRAUMA

Stojanovska J. (USA)

Blunt trauma is a significant cause of death. In 2016, 1.4 million of the 56.9 million deaths worldwide were due to road injuries. Males accounted for 74% of these trauma-related deaths. Road injuries are the eighth most common cause of death world-wide. In the United States, blunt injuries to the thorax are responsible for one quarter of traumatic deaths caused by high-energy mechanisms. Blunt chest trauma encompasses an array of injuries to the pulmonary and cardiovascular systems. While respiratory tract injuries often have the most dramatic presentations, cardiovascular injuries pose the greatest risk for sudden death. The most devastating fatal injuries to the thorax are acute cardiac injury and aortic injury or transection. The majority of these patients do not survive long enough to receive care at a hospital and expire before definitive diagnoses and treatments can be implemented. Blunt cardiac injuries range from myocardial concussion, to myocardial contusion, cardiac chamber rupture, septal rupture, pericardial rupture, and valvular injuries. Some patients may present with posttraumatic coronary dissection and subsequent myocardial infarction that may mimic myocardial contusion. Imaging plays huge role in diagnosing cardiac trauma. In this presentation we will discuss the role of imaging in cardiovascular trauma.





RADIOMICS/DEEP LEARNING/ARTIFICIAL INTELLIGENCE

MACHINE LEARNING

Papanikolaou N.(PG)

Radiologists are generating their diagnoses based on a combination of their training, experience, and individual judgment. They perceive and recognize imaging patterns and infer a diagnosis consistent with these patterns. Therefore, there is a certain degree of variability in image interpretation. To reduce this variability, alternative avenues like Radiomics and Texture Analysis has been proposed, where someone can access far more information compared to what the naked eye can identify. It is well known that tumors exhibit strong phenotypic differences in patients that can be visualized by imaging. A significant advantage of medical imaging is its ability to noninvasively visualize cancer's appearance, such as intratumoral heterogeneity, on a macroscopic level, at baseline and follow-up, from the primary tumor to potential metastasis. In the current clinical practice, tumors are also monitored by invasive biopsy and molecular profiling, but their spatial and temporal pathologic heterogeneity limits the ability of invasive biopsy techniques to capture their state fully. Furthermore, the necessity of repeated, invasive sampling and the molecular assay may be burdensome to the patient, is expensive, and limits the practical number of opportunities to monitor disease progression and treatment response. Conversely, the imaging phenotype may encompass a wealth of information, including the effects of the genotype, the environment of the tumor, and its potential treatments. At the moment, there is a clear need to improve reproducibility, and diagnostic accuracy of imaging and these are the main driving forces for the development of radiomics, where we are trying to associate imaging features with clinical outcomes. Machine learning methods are used to build, train, and validate models that can aid in the prediction and early stratification of patients, which is at the heart of the precision medicine concept.

DEEP LEARNING: EXPLORING THE NEW HORIZONS IN RADIOLOGY

Marias K. (GR)

Although the idea of the personalization of patient care dates back to the time of Hippocrates, recent advances in diagnostic medical imaging and molecular medicine are gradually transforming healthcare services, by offering information and diagnostic tools enabling individualized patient management. Advanced medical Imaging and image analysis is a *sine qua non* condition towards precision medicine allowing clinicians to screen, diagnose and plan treatments of patients more efficiently. Deep learning (DL) is a specialized machine learning approach based on multiple-layered structures (algorithms) of artificial neurons, which are able to process information and learn by adjusting the weights at each synapse, enabling the performance of an intelligent task with high precision. DL promises to significantly improve medical image analysis and interpretation including automated 3D detections of ROIs, extrapolation of pathology genotype from imaging radiomics features, prediction of clinical outcome as well as assessment of the impact of disease treatment on adjacent organs. This talk will shed light on these aspects focusing on the challenges for the clinical translation of AI techniques to the clinical setting.





Modern application of DWI in oncologic imaging Hatakenaka M. (JP)

Diffusion-weighted-imaging (DWI) has been increasingly applied for oncologic imaging not only for differentiating malignancy from benignancy and evaluating lesion aggressiveness but also for predicting treatment effects and prognosis. However, what the signal intensity of DWI represents is complicated. The word of weighted imaging itself means that signal is composed of several factors, like proton density, T1, T2, and of course, proton diffusion. As you know, diffusion is proportional to absolute temperature (T) and inversely proportional to viscosity (η) (Stokes-Einstein equation). As cancer usually shows high signal intensity on DWI and low apparent diffusion coefficient (ADC), does cancer represent low temperature and/or high viscosity? DWI textbooks explain that cell density of cancer is high that proton diffusion tends to be restricted by cell membranes and as a result, cancer shows high signal intensity on DWI and low ADC. DWI does not represent proton diffusion itself, rather restriction of proton diffusion. The signal intensity and ADC are mainly affected by coarseness and fineness of the structures restricting proton diffusion like cell membrane because it takes some time to obtain DWI. ADC of cancer is usually lower than that of benign lesion or normal tissue probably due to its high cell density. Further, lower ADC represents aggressiveness of the lesion. Indeed, in general, cancer with lower ADC tends to indicate poor prognosis. However, lower ADC is considered to predict favorable prognosis in head and neck cancer treated with chemoradiotherapy. It looks confusing. I would like to propose a hypothesis that might explain why cancer with lower ADC likely to indicate favorable prognosis when treated with chemoradiotherapy.

It is a great pleasure if my lecture helps understand an application of DWI in oncologic imaging more deeply.





SATURDAY, OCTOBER 19TH, 2019

GASTROINTESTINAL II

ABDOMINAL WALL HERNIAS AND THEIR COMPLICATIONS

Courcoutsakis N. (GR)

Learning objectives: To become familiar with the various types of abdominal wall hernias (inguinal, femoral, umbilical, Spigelian, parastomal, post—operative) on CT and on ultrasound.

To learn more about the imaging features of hernial strangulation on CT and on ultrasound.

To understand the imaging features of rectus sheath hematoma on ultrasound, CT and MRI.

TRANSCATHETER ARTERIAL EMBOLIZATION IN ACUTE UPPER GASTROINTESTINAL BLEEDING

Kratimenos Th.(GR)

The incidence of upper gastrointestinal bleeding (UGIB) ranges between 36 and 48 per 100,000 persons annually and despite advances in medical care, the overall mortality remains relatively constant over the past several decades because of the increasing proportion of elderly patients presenting with UGIB and additional comorbidities.

The most common etiologies are: duodenal ulcer, gastric erosions and or ulcers, varices, and other or miscellaneous etiologies

The most important diagnostic techniques in the diagnostic investigation of UGIB are the upper endoscopy as first line option, and if this fails to demonstrate the source of UGIB then several recent studies have documented the high sensitivity, specificity, and predictive value of multiphase multidetector CT (MDCT) in assessing UGIB. Another important advantage is the possibility to localize the source of bleeding sparing a lot of time in the Interventional Radiologist that might be involved in a life-saving embolization procedure.

Regarding the therapeutic options if upper endoscopy is unable to control the source of UGIB, then in high surgical risk or hemodynamically unstable patients transcatheter arterial embolization (TAE) is indicated. TAE is considered a well established method in the current clinical practice as in experienced hands has very high percentage of technical success and low rate of complications. Possible embolic materials can be PVA particles, metallic coils (detachable or not) and many others depending on the location and kind of lesion needed to be treated.

In our center we perform TAE for UGIB in 30 -35 patients per year, with an emergency rate of more than 90%.

TAE in high volume centers with modern infrastructures and experienced interventional radiologists is a safe and valid to surgery alternative.





CHEST IMAGING II

CHEST HRCT IMAGING IN SMOKERS AND EX-SMOKERS

Detorakis E. (GR)

It's been 26 years since Remy-Jardin et al first defined the spectrum of HRCT abnormalities associated with cigarette smoking, in a study where both current smokers and ex-smokers were involved. Nowadays, chest radiologists as well as general radiologists may distinguish and report the different chest HRCT findings related to tobacco smoking, regarding the tracheobronchial tree as well as the lung parenchyma, ranging from COPD-related findings to smoking related interstitial lung diseases, to combined pulmonary fibrosis and emphysema conditions, without neglecting thoracic manifestations of neoplastic origin, related to smoking habits. But what about ex-smokers? Do the upper stated findings fade over time? Depending on many conditions such as the duration of smoking, the pack/years, most of the thoracic HRCT manifestations in smokers seem to persist through time even after quitting smoking, a fact that every radiologist needs to know.

CHRONIC THROMBOEMBOLIC PULMONARY DISEASE- RADIOLOGY PERSPECTIVE IN MULTIDISCIPLINARY TEAM

Nedevska M.(BG)

Chronic thromboembolic pulmonary embolism is a rare but serious complication of acute venous thromboembolism. For reasons not fully understood yet emboli did not resolve and sustain an abnormal path of transformation through organization and recanalization. Typical abnormalities in elastic pulmonary vessels such as intramural webs, bands, wall irregularities, stenosis and occlusions develop. In addition, an associated secondary small vasculopathy influences significantly the progression of the disease.

Patients remain asymptomatic for long period with slow, but progressive development of right heart failure in advanced disease stages. This is the only form of pulmonary hypertension that is potentially curable with surgical or catheter-based intervention, depending on the localization of the thrombosis.

According to the guidelines, multidisciplinary team approach is highly recommended, including members of different medical specialties. Right ventricle catheterization and selective pulmonary angiography are the reference standard to establish the diagnosis and to assess the severity of disease. However, noninvasive and cross-sectional modalities, especially multidetector computed tomography are increasingly important in the initial evaluation and further clinical and therapeutic management.

In this presentation will be discussed the exact role and responsibilities of the radiology team in guiding the proper management of patients with this serious, but potentially curable disease.





IMAGING OF ACUTE DYSPNOEA

Tavernaraki K. (GR)

Acute dyspnoea is one of the most common pulmonary emergencies referred to the radiology department. Apart from PE, imaging diagnosis may be challenging as it covers a wide spectrum of parenchymal lung diseases with overlapping and non-specific imaging findings in many cases. Careful image interpretation on CT and correlation with clinical findings is the key to the diagnosis.

CT findings of the most common parenchymal lung diseases causing acute dyspnoea are demonstrated and analyzed based on the imaging pattern and distribution of changes in the lung parenchyma. These include pulmonary edema, both cardiogenic and ARDS, lung infections, diffuse pulmonary hemorrhage, acute exacerbation of interstitial lung disease and lung cancer-associated conditions. Acute dyspnoea in different clinical settings is also discussed.

Ground glass opacity is by far the most common finding, which is non-specific and may appear in variable distribution and extent. Other findings commonly seen include consolidation, septal thickening, nodules, crazy paving appearance, pleural effusions and cardiomegaly, which are also non-specific.

As CT appearances may be similar and overlapping in different pathologic conditions making imaging diagnosis challenging, careful image interpretation should be achieved. Emphasis on the distribution of lung changes, presence of co-existing findings and clinical correlation is the key to the diagnosis.

MRI OF THE BRACHIAL PLEXUS: TRAUMATIC AND NON-TRAUMATIC CAUSES OF BRACHIAL PLEXOPATHY

Karlovic-Vidakovic M.(BIH)

Brachial plexopathy is a neurological condition that cause pain and/or functional impairment of the ipsilateral upper extremities. Brachial plexus lesion can be classified according to their relation to the clavicle, as supraclavicular, retroclavicular and infraclavicular lesions. Supraclavicular lesions are the most common. The leading cause of brachial plexopathy is trauma, found in more than 50% of cases, in the first row after motor vehicle crashes. It is more common in adolescent and in neonates as an obstetric traumatic plexopathy. Non-traumatic causes of brachial plexopathy are more common in middle age and older individuals, and they include tumors, radiation/inflammatory plexopathy, TOS, cervical spondylosis etc.

To understand the brachial plexus pathology, the basic anatomy of the brachial plexus needs to be known. Pathology of brachial plexus requires clinical assessment, electrophysiologic tests (EMG) and diagnostic imaging techniques.

Different diagnostic modalities can be used to analyse the brachial plexus, including Magnetic resonance imaging (MRI), computer tomography and ultrasound. However, MRI is the imaging modality of choice for the evaluation of the brachial plexus due to its superior soft tissue resolution and multiplanar capabilities. We use 3T MRI system, coronal, axial and sagittal T1 and T2 weighted images, with and without fat suppression and the use of contrast agent.

MR imaging plays an essential role in diagnosis of brachial plexopathy, especially in differentiating preganglionic injuries from postganglionic lesions, which is crucial for the management of brachial plexus injury, predominantly in the setting of trauma. Clinically, lesions of the brachial plexus represent a diagnostic challenge, however imaging assessment of the brachial plexus is especially challenging due to the complexity of its anatomy, distribution in space and due to technical factors, such as long scanning time.

Keywords: magnetic resonance imaging, brachial plexus pathology





HONORARY LECTURE

EMBOLIZATION TECHNIQUES FOR VASCULAR MALFORMATIONS

EMBOLIZATION TECHNIQUES FOR VASCULAR MALFORMATIONS

Hayashi N. (JP)

Vascular malformations can develop in any part of the body. The International Society for the Study of Vascular Anomalies (ISSVA) has categorized vascular malformations into four major types based mainly on the flow characteristics (i.e. slow vs. fast): the slow-flow category consists of venous, lymphatic and capillary malformation, and the fast-flow category consists of arteriovenous malformation. They can lead to cosmetic problems when they develop superficially and other symptoms depending on the locations. There are many different therapeutic approaches for vascular malformation and multidisciplinary treatments are performed though cooperation among departments.

Radiologists play major roles in both diagnosis and intervention. Regarding diagnostic imaging, it is important to make an accurate diagnosis based on the ISSVA classification, as it has therapeutic implications. Regarding interventional radiology, different approaches, such as percutaneous sclerotherapy, transcatheter sclerotherapy and embolization, can be applied. In general, the treatment goal is to improve the cosmetic problems and other related symptoms. Many sclerosing agents are available, including absolute ethanol, oleate monoethanolamine and polidocanol. There are also many embolic materials available such as coils, microspheres and N-butyl cyanoacrylate. It is important for interventional radiologists to understand the properties of the material and the risks associated with the use of these agents.

I would like to take this opportunity to describe the embolization techniques for vascular malformations by presenting previous cases. I would also like to introduce our ongoing research on embolic materials.

CARDIAC IMAGING

MRI IN MYOCARDITIS

Maksimović R. (RS)

Myocarditis is an underdiagnosed cause of acute heart failure, sudden death, and chronic dilated cardiomyopathy. In developed countries, viral infections commonly cause myocarditis; however, some other causes could contribute to development of the disease. The short-term prognosis of acute myocarditis is usually good, but varies widely by cause. Those patients who initially recover might develop recurrent dilated cardiomyopathy and heart failure, sometimes years later. As myocarditis presents with non-specific symptoms including chest pain, dyspnoea, and palpitations, it often mimics more common disorders such as coronary artery disease. In some patients, cardiac MRI and endomyocardial biopsy can help identify myocarditis, predict risk of cardiovascular events, and guide treatment.





The presence of myocardial inflammation is not specific to viral myocarditis or other forms of acute myocardial injury, and the regional distribution within the myocardium helps differentiate acute myocarditis from other diseases. The currently recommended diagnostic criteria (Lake Louise Criteria) include markers for hyperemia/capillary leak, edema, and inflammatory scarring. Their diagnostic accuracy of close to 80% is satisfactory to rule in myocarditis, while the negative predictive value is less than 70%. Novel CMR techniques, especially T1 and T2 mapping, have been shown to further improve the diagnostic utility. T1-weighted images for scar and T2-weighted images for edema visualization are key methods for tissue characterization. Furthermore, T1, T2 mapping and evaluation of the extracellular volume fraction (ECV) allow quantification of diffuse myocardial pathologies and showed great potential in the visualization of fibrosis, edema, amyloid, iron overload and lipid.

In conclusion, CMR has emerged as the prime non-invasive diagnostic tool in patients with acute myocarditis. In the future, novel techniques of mapping might enable the detection of early cardiac involvement, even act as a prognostic factor. Moreover, therapy monitoring and follow-up might be possible due to versatile parameter quantification with these new techniques.

CT IMAGING IN CONGENITAL HEART DISEASE IN ADULTS - EXPECTED AND UNEXPECTED FINDINGS

Groudeva V.(BG)

The number of adults with some type of congenital heart disease (CHD) is nowadays constantly increasing mainly due to the advanced therapeutical options for these conditions. Some of these patients have consequent impairments and possible complications that need assessment and medical care with dedicated multidisciplinary team. Precise follow up with imaging in these patients is needed for appropriate management.

On the other hand with the rapid increase of the number of CT angiography exams performed, detection of structural cardiac anomalies as unexpected finding increases as well. Some of them are minor and do not have consequences. However others might have potential clinical presentation that would require treatment.

The aim of this presentation is to present author's illustrative cases of variety of cardiac structural anomalies in both adults with known and unknown congenital heart defects. Expected and unexpected imaging findings are discussed as well as the approach to their assessment.

The advances in technology in the recent years has brought multiple options for cardiac imaging. Due to the high spatial resolution and rapid acquisition CT is now invaluable tool in the diagnosis and management in selected adults with CHD. CT provides excellent 3D visualization of the cardiovascular anatomy.

Essential part of analysing cardiac anomaly is to identify the morphology and position of cardiac chambers and their connections. Therefore radiologists should be familiar with the broad spectrum of CHD in order to assist the clinicians to diagnose CHD and to clearly describe the anomalies. Knowledge of the specific haemodynamic in these patients is essential.





CT CORONOGRAPHY: AN UPDATE

Michailidis K. (GR)

The presentation will focus on the new technological and clinical achievements of coronary CT angiography.

Coronary CT angiography, from its early beginning, was an outbreak in the anatomic evaluation of the heart and the coronary arteries.

In the recent years, major technological improvements in cardiac CT, have occurred which enabled us to perform high quality images, even on patients with arrhythmia or tachycardia. Also, radiation doses have decreased significantly.

Long term outcomes of the large clinical trials, put new evidence on the clinical applications of coronary cardiac CT. Beyond the assessment of the lumen and stenosis grading, coronary CT angiography can correctly describe the composition the atheromatous plaque and characterize unstable or vulnerable plaques. CT-FFR (fractional flow reserve) is gained evidence on the haemodynamic assessment of the stenosis.

The presentation will focus on the new clinical applications of cardiac Coronography and Coronary Calcium score. Calcium score has recently been included in the hypercholesterolemia Guidelines.

Cardiac spectral imaging is rapidly evolving and along with CT Stress myocardial perfusion offer useful functional evaluation. Cardiac CT is an excellent tool for Cardiac Valve procedure planning.

It is the time to realise that Cardiac CT came to stay and is the only method currently available, which has the potential to significantly decrease Cardiac morbidity and mortality.

IMAGING OF NON-ISCHEMIC CARDIAC PATHOLOGIES

Hazirolan T. (TR)

Cardiac MRI is the imaging method that provides the most specific information in the evaluation of non-ischemic cardiac pathologies. Some treatable non-ischemic cardiac pathologies can be diagnosed according to the contrast enhancement pattern. In recent years, the early diagnosis of non-ischemic cardiac pathologies with MRI has increased due to the development of relaxometry methods and the diagnostic scale of cardiac MRI has significantly expanded. The aim of this presentation is to describe the methods used in the evaluation of non-ischemic cardiac pathologies by MRI and the advantages of cardiac MRI in these.





HEAD AND NECK II

IMAGING IN VERTIGO

Merhemic Z.(BIH)

Vertigo is sensation of movement of self or environment, often rotatory. Results from mismatch of visual, vestibular and sensory system.

Peripheral cause of vertigo can be: benign paroxysmal positional vertigo (BPPV), short-lived episodes of vertigo, vertigo caused by head movement or with neck extension "top shelf" vertigo, vestibular neuritis, Meniere's disease.

Central cause of vertigo: TIA and brainstem infarction, multiple sclerosis, tumor or mass, aneurysm and vascular anomalies, infections, congenital anomalies.

Vertigo and dizziness are, after headache and back pain, the most common symptoms in daily clinical practice. Vertigo, an illusory sense of motion, and imbalance owing to disturbances in gaze and postural stability. In some cases, vestibular dysfunction can culminate catastrophically in a fall, which is associated with serious injury and restricted mobility and ranks among the leading causes of death among older individuals.

Vertigo is a frequent reason for neuroimaging. It is of great importance to diagnose the cause of vertigo, and to treat it.

CT OF THE PARANASAL SINUSES

Slavica Sotirović-Seničar (RS)

Although CT of a paranasal sinuses is technically easy to perform, it often causes dilemma about how to report it, especially in chronic rhinosinusitis, most common indication for the exam. Huge variety of sinonasal morphology poses a problem-what is important for clinician to know? The aim of presentation is to propose systemic approach to evaluation of sinus pathology as well as important and critical variations, so the possible complications during FESS should be avoided. Part of the presentation is optimisation of CT protocol to reduce radiation dose.

PARAPHARYNGEAL SPACE AND ITS SPECIFIC PATHOLOGIES

Karaman Can Zafer (TR)

The parapharyngeal space is one of the potential neck spaces. This paired space is relatively small but critical for acting as a crossroad to associate surrounding spaces. Starting from the skullbase the space may reach down to the thoracic inlet via the carotid sheath. It is generally divided into two compartments by the tensor-vascular-styloid fascia, the prestyloid and the poststyloid compartments, which may also be called as the parapharyngeal space and carotid space, respectively. The prestyloid compartment contains the minor or ectopic salivary glands, branches of the mandibular division of the trigeminal nerve, two arteries, and pharyngeal venous plexus. The internal carotid artery, internal





jugular vein, cranial nerves IX–XII, cervical sympathetic chain, and glomus bodies lies in the poststyloid compartment. The space can easily be detected on cross sectional imaging for its fatty content, where MRI may be slightly superior to CT while evaluating the space and neighboring structures. Congenital or developmental and neoplastic lesions may arise from the above mentioned structures within these compartments. Infectious and inflammatory diseases mostly arising from neighboring spaces and structures may also involve the parapharyngeal space. For that reason neighboring compartments are vital for the space. In the lateral proximity, from anterior to posterior lie the masticator and parotid spaces. The pharyngeal mucosal space is located medially, and the retropharyngeal space posteromedially. Defining the origin of the pathological process in regard to the compartmental anatomy may be the first step in head and neck imaging. Moreover differentiating a prestiloid lesion from a poststyloid lesion located in the parapharyngeal space may be critical for appropriate clinical approaches and surgical planning.

UP-TO-DATE IMAGING OF THE CERVICAL TRAUMA

Bulakbaşı Nail (TR)

Learning objectives:

- Key facts about cervical spinal trauma
- Overview about cervical radiological anatomy
- Update on upper cervical spinal trauma classification
- Update on subaxial cervical spinal trauma classification

Every year, around the world, between 250-500.000 people suffer a spinal injury. Males are most at risk in young adulthood (20-29 years) and older age (70+). People with a spinal injury are two to five times more likely to die prematurely than people without a spinal injury

Radiological diagnosis crucial in the assessment of spinal injury. In the awake, asymptomatic patient who has a normal neurological examination, radiographic evaluation of the cervical spine is not recommended. In awake, symptomatic patients, or in obtunded or unevaluable patients high-quality CT imaging of the cervical spine is recommended. If high-quality CT imaging is not available, a 3-view cervical spine series (anteroposterior, lateral, and odontoid views) is recommended. This should be supplemented with CT (when it becomes available) if necessary, to further define areas that are suspicious or not well visualized on the plain cervical x-rays.

MRI obtained within 48 hours of injury (limited and conflicting Class II and Class III medical evidence) is only recommended to evaluate spinal cord, tension band and ligamentous injuries.

Upper (occipital condyles, cranio-cervical junction, C1 and C2 vertebrae) and subaxial cervical spine (C3-C7 vertebrae) are separately evaluated with different classification systems from the trauma point of view. There is no clear consensus about a significant classification system in neurosurgical society so, it is necessary to reach a consensus with your neurosurgeons. In the assessment of spinal injury, SLICS uses three domains and AOSpine uses five domains. Both systems are valid and reliable tools for the classification of subaxial cervical spine injury. In either way, the experienced neuroradiologist about spinal trauma plays an important role in determining optimal patient management.





MUSCULOSKELETAL RADIOLOGY II

ENCHONDROMA VS LOW-GRADE CHONDROSARCOMA: MR IMAGING

Arkun R. (TR)

Cartilage tumors are chondroid matrix producing tumors and range from completely benign to highly malignant lesions. Among cartilage tumors, enchondroma and low grade chondrosarcoma may be confusing for pathologist as well as radiologist to reach correct diagnosis.

Enchondroma is the secondary most common cartilaginous bone tumor. Hands and feet are the most common locations; it is also seen in long tubular bones. On plain radiography, enchondroma is intramedullary geographic lytic lesion located at metaphysis. Expansile remodeling, endosteal scalloping and matrix calcifications can be seen in the lesion. On MRI, lobulated marked increased signal intensity with low intensity chondroid matrix on T2W images with lobular margins are seen.

Chondrosarcoma is the most common cartilaginous malignant bone tumor which represents cells that produce a cartilaginous matrix. Conventional intramedullary chondrosarcoma shows three different subtypes as grade 1, grade 2 and grade 3 according to histologic features. On plain radiography, there is lytic permeative geographic lesion with deep endosteal scalloping, cortical thickening, periosteal reaction, matrix calcification and soft tissue mass. On MR imaging, the lesion demonstrates low or intermediate signal intensity on T1W images with punctate signal void areas due to matrix mineralization. Non-calcified tumor areas show very high SI on T2W images with lobulated margins and hypointense internal septa. High grade lesions may show cortical destruction and soft tissue mass. After intravenous contrast administration chondrosarcoma shows septal and peripheral enhancement.

Aggressiveness of cartilage tumor may be problematic to differentiate in between enchondroma and grade 1 (low- grade) chondrosarcoma. Diagnosis is based on histologic and growth features, symptoms and radiological findings. However, there are still overlaps in between two entities. It is therefore vital that the differentiation of benign from malignant cartilage tumors is based on a decision made in a multidisciplinary team that takes into account the clinical, imaging and pathology findings.





INTERVENTIONAL TREATMENT OF SPINE LESIONS

Kelekis A.D.(GR)

Interventional procedures of the spine can be separated into treatments for benign and malignant pathology. Additionally the strategic approach should take into account palliative or curative intent. Benign lesions to be treated involve back pain and radiculopathy, a common problem, but quite costly to society. Most cases are successfully treated conservatively (antalgics or physical therapy), but in a small percentage of cases, surgery may also be performed. Percutaneous treatment is a minimal conservative technique, proposed before surgery. By using imaging guidance, one can access cervical, thoracic, lumbar and sacroiliac area with increased accuracy and decreased complication rates. Treatments include nerve block, disc treatment and bone treatment.

Concerning malignant disease, interventional procedures can target accurately the lesions, providing histological information (biopsy), perform ablation and augmentation of the lesion, thus contributing to a curative or palliative treatment. It can be combined with other techniques such as radiotherapy and surgery. The presentation will revise indications, approaches and algorithms for a safe and effective treatment. It will also show potential risk and complications. The intent of the interventional procedures of the spine is not only the localized therapy, but a comprehensive approach to spinal lesions, as well as minimally invasive management with pre-, intra- and post procedure algorithms of care.

References

Kelekis AD, Somon T, Yilmaz H, et al. Interventional spine procedures. Eur J Radiol. 2005 Sep;55(3):362-83

Tsoumakidou G, Too CW, Koch G, et al. CIRSE Guidelines on Percutaneous Vertebral Augmentation, CVIR. 2017 Mar; 40(3):331-342

BENIGN AND MALIGNANT ADIPOCYTIC TUMORS

Orguc S.(TR)

Adipocytic tumors are the most common soft tissue tumor and they are mostly benign. In this lecture our learning objectives are to get familiar with the new WHO classification and overview characteristic and overlapping MRI findings of fat containing soft tissue tumors. Molecular markers have an important role in proper characterization and classification of fat-containing soft tissue masses in the new edition of WHO. We will emphasize on recognizing suspicious findings which may require histologic sampling.

We will review the typical imaging findings of lipomas almost half of all soft tissue tumors.

Lipoblastoma, angiolipoma, spindle cell lipoma/pleomorphic lipoma, myolipoma, chondroid lipoma, lipomatosis of nerve, lipomatosis, hibernoma, and fat necrosis are benign soft-tissue masses. Lipomas show imaging characteristics similar to subcutaneous fat and may contain a few thin septa measuring less than 2 mm in thickness.

Well differentiated liposarcomas and atypical lipomatous tumors are locally aggressive soft-tissue masses that do not metastasize. The malignant adipocytic tumors, or liposarcomas account for 17.1%





of all soft tissue sarcomas and have myxoid, pleomorphic, and dedifferentiated types. Liposarcomas tend to be larger, frequently located deep beneath the muscle fascia, contain nonfatty soft-tissue components and thick, irregular, enhancing septa. However, differentiating benign, atypical and malignant lipomatous lesions may be challenging due to overlapping imaging findings. Biopsy should target the non-fatty component when histologic evaluation is indicated.

POSTOPERATIVE SPINE

Spanakis K. (GR)

Due to the high prevalence of surgical procedures on the spine, radiologists are often tasked to evaluate postoperative spine imaging to assist the surgeon with further clinical management. In order to avoid imaging pitfalls the interpreting radiologist must initially appreciate the clinical presentation of the patient. Secondly it is crucial to recognize the surgical procedure performed and the instrumentation used. Finally one must be familiar with both the expected postoperative changes and the complications that may be encountered following spinal surgery. This presentation provides a review of various imaging techniques, with their advantages and disadvantages and it also gives an overview of normal and abnormal postoperative appearances of the spine as seen via various modalities, with an emphasis on postoperative complications. It is only through a comprehensive clinical, surgical, and radiologic understanding that a proper evaluation of the postoperative spine can be rendered.

UROGENITAL RADIOLOGY II

CONGENITAL UTERINE ANOMALIES ACCORDING TO THE ESHRE/ESGE CLASSIFICATION - MRI

PICTORIAL REVIEW

Hadjidekov G. (BG)

The knowledge of MRI variants of uterine anomalies according to the newest classification system is a useful tool for the radiologist for the solution of different gynecological and obstetrics clinical scenarios. The congenital malformations of the female genital tract, which are anatomy deviations of embryological development present various anatomical and MRI findings. A formation defect at every developmental phase of the Mullerian ducts giving the origin of the uterus could lead to a complexity of different classes and subclasses of uterine maldevelopment.

The aim of this pictorial review is to illustrate the MRI findings in the main anatomical variants of uterine anomalies according to the ESHRE/ESGE classification; to briefly remind the embryology of the female genital tract; to review the origin, clinical outcome, reproductive consequences, therapy, genetic aspects and association with other "non-Mullerian" congenital anomalies. Based on our experience we want to emphasize the practical point of using actual and concrete nomenclature in favor of reproductive medicine and gynecology, to try to clarify the complicated terminology and to make an easy transition to the newest classification system comparing to the oldest ones=

Keywords: congenital uterine anomalies, female genital tract malformations, ESHRE/ESGE classification, MRI, pictorial review





IMAGING OF UROTHELIAL TUMORS

Özmen N. M.(TR)

Urothelial neoplasms are among the most frequent malignant neoplasms encountered in human. The prevalence of urothelial neoplasms is high in elderly patients with history of smoking, analgesic use or occupational exposure to chemical carcinogens. Urothelial cancer has to be considered as a 'systemic' disease, with often multiple, synchronous or metachronous lesions. CTU not only depicts the neoplastic lesion but also enables the examination of entire urothelium during staging or follow-up. Several treatment options are available and imaging plays an important role for tailoring this treatment. Dose reduction techniques have also enabled us to obtain CTU's with very low radiation doses.

In case of hematuria, where CTU is the main diagnostic tool for upper urinary tract evaluation, cystoscopy is the primary diagnostic tool for screening for bladder neoplasms. CTU is indicated for the evaluation of upper urinary tract and staging purposes. MRI might be used for the local staging of bladder carcinoma.

A filling defect seen on CTU usually raises the suspicion of urothelial neoplasm. There are several entities among the differential diagnosis of upper or lower urinary tract neoplasms which can be successfully differentiated with imaging modalities such as CT or MRI.

RENAL LESIONS: CHARACTERIZATION WITH MRI

Secil M. (TR)

Magnetic resonance (MR) imaging, with its supreme contrast resolution capability and with additional imaging biomarkers in use, is a helpful modality in characterization lesions in various body parts. Renal lesions display a spectrum of appearances that may represent a critical clinical decision dilemma of removing the kidney or not. The radiologist plays a critical role in that dilemma and commonly faces the difficulty of making the correct diagnosis in that situation. MR imaging is a very helpful tool for characterization of renal lesions as well and may help the radiologist.

The renal lesions include the cystic disease, inflammations, vascular disease, neoplasm and others. MR is the most helpful method to characterize the cystic lesions, particularly the complex cystic ones. Bosniak classification may safely and accurately be used in characterization. MR can differentiate solid lesions from complex cystic or hemorrhagic lesions with high sensitivity and specificity. Solid lesions may be characterized using the signal intensity, diffusion and contrast enhancement properties of the lesions. MR can also be used to differentiate the solid neoplastic and non-neoplastic lesions. Among the neoplastic ones the diagnosis of subgroups of tumors may be provided in most of the patients. This success of MR in characterization of lesions leads to the suitable clinical decision of surgery, follow-up or ablative treatments, the type of surgery to be used such as total or partial nephrectomy, and even the surgical approach as transperitoneal versus retroperitoneal.

The improvement of knowledge and experience of the radiologists in MR characterization of renal lesions plays an important role in patient care.



**IMAGING OF THE ADRENALS****Obuz F. (TR)**

The anatomy of the adrenal glands and the current imaging modalities that are most useful for the assessment of the various conditions affecting these glands will be discussed. Adrenal lesions are often identified incidentally on cross-sectional imaging performed for other reasons. In the setting of a known malignancy, differentiation between a metastases and adenoma is essential to guide management. Imaging techniques to differentiate benign from malignant lesions will be described and an algorithmic approach of workup of an adrenal mass will be presented.

INTERVENTIONAL RADIOLOGY II**EMBOIALIZATION OF CAROTID-CAVERNOUS FISTULA - WHERE WE STAND TODAY?****Sirakov S.(BG)**

Carotid-cavernous fistulas (CCF) are pathologic arteriovenous shunts into the cavernous sinus (CS) leading to venous congestion. The arterial supply arises from the internal carotid (ICA, type A), meningeal ICA branches (type B), meningeal external carotid branches (type C), or internal and external carotid meningeal branches (type D). Patients usually present with chemosis, proptosis, diplopia, or vision loss. Ophthalmologic examination often reveals an intra-ocular pressure (IOP), greater than 20 mmHg.

Direct carotidocavernous fistula (CCF) has traditionally been treated by detachable balloon placement within the affected cavernous sinus. We describe a case of a direct CCF treated solely with flow-diverting stents. These novel devices may offer a simpler and potentially safer vessel-sparing option in this rare condition.

We present the latest trends in techniques and methods for endovascular treatment of carotid-cavernous fistulas.

SFA PTA & STENTING**Krokidis M.(UK)**

Peripheral arterial disease is the expression of atherosclerosis in the lower limbs leading to intermittent claudication or critical limb ischemia and limb loss. It affects more than 200 million people worldwide and there is a continuous effort to limit its spread with modification of predisposing factors and supervised exercise. The most common area of pathology is the superficial femoral artery (SFA) particularly at the distal third.

Endovascular treatment is an established approach aiming to preserve blood flow towards the lower limb musculature. There are several endovascular treatment options currently available on that purpose and in particular angioplasty alone (with a range of balloon technology), stenting (with a range of stents and vascular mimetics) and lesion debulking (via atherectomy or laser treatment). Drug technology has also been used either via balloons or stents on that purpose.





Purpose of this talk is to describe the current evidence on balloons and stents of the SFA and mainly to offer an overview of the use of drug technology with a focus of paclitaxel-coated devices and of stent technology with a focus of vascular mimetics. Paclitaxel coated devices have been effective in preventing restenosis however there has been recent evidence that there is a link with higher patient mortality. Stents are subject to mechanical challenges and first-generation devices offered limited results due to their rigidity and deformability, due to the constant exposure of the artery to external forces. Laser cut nitinol stents overcame certain challenges due to their superelasticity and thermal shape memory, however with avoiding stent fracture. Interwoven nitinol stents were developed to face these biomechanical challenges offering satisfactory results.

INTRA-ARTERIAL CHEMOTHERAPY FOR BRAIN TUMORS

Mantatzis M. (GR)

For years physicians had to face the blood-brain barrier (BBB) obstacle when it came to the treatment of brain tumors. Intra-arterial administration of chemotherapeutic drugs is a technique that has been studied in the past but was left aside due to major complications (concerning mostly neurotoxicity). The main advantages of the method are the bypass of the BBB and the greater concentration of the administered agent in the area interest. The difficulties that have been met in the past and led to disappointing results can be surpassed nowadays with the refinement of the equipment and the better understanding of the drugs and administration methods. In the future intraarterial chemotherapy will probably play an important role for the treatment of intracranial tumors, especially for recurrence.

EVAR: AN UPDATE

Uberoi R. (UK)

The EVAR trials should conclusively the significant initial benefit of EVAR compared to standard open surgical repair, in particular better 30 day mortality of 1.6 v 4.7%. These results were replicated by several other world trials including the OVER, DREAM and ACE trials. Although the costs of EVAR were show to be higher, this then became established as a viable alternative for the treatment of patients with un ruptured abdominal aortic aneurysms (AAA) and was recognised by NICE in the UK. This was followed by trials looking at rupture aortic aneurysms which demonstrated that although there was no overall survival benefit of EVAR over surgical repair, there was benefits is certain subgroups and should also be considered in these difficult patients.

However since that time the long term follow up from the original EVAR trials have started to show disturbing outcomes. The 3% early survival benefit is lost at 4 years, presumably because of patients dying of co-morbid diseases and then a survival disadvantage out beyond 8 years with surgery coming out on top. In addition, the costs were shown to be significantly higher due to the need for continued follow up and higher re-intervention rates. Despite the arguments for changes in practice and evolution in technologies since the early trials. This has led to the most recent controversial proposed NICE guidelines on EVAR, where it is no longer recommended for un-ruptured aneurysms and only in the context of research areas for juxta-renal or supra-renal aneurysms.





NEURORADIOLOGY II

QUANTITATIVE NEUROIMAGING BIOMARKERS

Milos A. Lucic^{1,2}

1 University School of Medicine Novi Sad, University of Novi Sad, Novi Sad, Serbia

2 Diagnostic Imaging Center, Oncology Institute of Vojvodina, Sremska Kamenica/Novi Sad, Serbia

In the era of radiomics, radiogenomics and radioproteomics data mining, magnetic resonance imaging (MRI) does not cease to surprise us with the novel achievements and possibilities, even after almost forty years of continuous improvements, especially in the field of neuroradiology. Being currently the most applicable and universally versatile diagnostic imaging technique, MRI opens until recently almost unimaginable possibilities of spatial resolution and different contrast, and perhaps even more important, the capability of tissue characterization *in vivo*.

The current status is already impressive, allowing us to scrutinize not only the meticulous morphometric details, and to characterize various tissue structures on different magnetic field strength devices, but also to examine the biochemical tissue composition *in vivo*, to obtain dynamic and functional information and to map the brain activities and pathways, to get the insight into the tissue internal bioarchitecture or into the brain plasticity, and to collect numerous metabolic and molecular information by integration of MRI devices in hybrid systems with positron emission tomography (PET).

In addition, a permanent and continuous introduction of new and reproducible quantitative biomarkers, based on various MRI derived techniques, almost certainly continues to fulfill a large number of gaps in our heretofore understanding of physiological and pathological processes in the brain, opening unique radiomics possibilities in neuroradiology, by understanding that diagnostic images are not only images anymore, but real data bases, containing multi-layered, statistically measurable information.

Moreover, already developed MRI applications and techniques, such as chemical exchange saturation transfer (CEST) imaging, or MRI fingerprinting could lead us into the nowadays still hardly imaginable directions in the imminent future with potentially irreversible impact on our profession - towards imaging without images.





IMAGING OF CRANIAL NERVES

Karaali K. (TR)

The first two cranial nerves (olfactory and optic nerves) are considered to be extensions of brain parenchyma, and remaining ten cranial nerves originate from brain stem structures.

In a patient with symptoms related to cranial nerves, all structures including nucleus of the nerve, cisternal segments, cavernous sinus segments and segments extending to the end organs should be scrutinized. Therefore, knowledge of the normal anatomy is mandatory. The radiologic evaluation is usually performed by MRI (magnetic resonance imaging) and in some selective cases, by CT (computed tomography).

For the MRI evaluation, along with the routine brain MRI sequences, obtaining heavily T2-weighted thin section images, such as CISS (constructive interference in steady state) or DRIVE (Driven equilibrium) is recommended. As well, intravenous contrast material should be given in order to demonstrate neuritic or infiltrative processes, if there is no contraindication. Bony lesions such as fractures in trauma patients or lesions invading the foramina of the cranium base may be shown much better with CT bone window.

In this talk, sectional anatomy of the cranial nerves will be discussed. Examples of pathologies such as tumors, inflammation, traumatic injury and vascular compressions will also be presented.

NEURODEGENERATIVE DISEASES

Calli C.(TR)

Neurodegenerative diseases are age-related diverse group of disorders. They have differences in pathophysiology and consist of many pathologies. Imaging findings usually are non-specific for many of them but may be specific for some of them. In this presentation various imaging findings in neurodegenerative diseases will be discussed. Especially specific imaging findings in some diseases will be noted.

BRAIN: FUNCTIONAL AND STRUCTURAL CONNECTIVITY

Xydis V.(GR)

Functional Magnetic Resonance Imaging (fMRI) and Diffusion Tensor Imaging (DTI) are emerging techniques for studying non-invasively the functional and structural connectivity of the brain. Neuronal activity in a specific brain area leads to increased blood flow in order to meet higher metabolic demands. Increased blood flow overwhelms the local demands for oxygen resulting in increased signal intensity in the activated area. Brain activity may be evaluated during a task (task related fMRI) or at rest (resting state fMRI). Resting state fMRI reveals low frequency synchronous activation of remote brain areas forming resting state networks. Evaluation of resting state networks is increasingly used in different diseases affecting the CNS and in pediatric population. Diffusion Tensor Imaging (DTI) offers information about brain microstructure and quantifies diffusion phenomena and anisotropy with metrics such as apparent diffusion coefficient (ADC), fractional anisotropy (FA), radial diffusivity (RD) and axial diffusivity (AD). By using deterministic or probabilistic Tractography white matter tracts connecting different brain areas can be depicted and offer information about the structural connectivity of the brain.





HEPATIC INCIDENTALOMAS

Tsili C.A (GR)

The widespread use of imaging techniques has led to an increase in the detection of incidental focal liver lesions. Most hepatic incidentalomas are benign lesions which do not require further investigation or intervention; however, few of them may prove malignant. Although, conventional US is usually the first imaging method, it lacks the diagnostic performance of multidetector computed tomography (MDCT) or magnetic resonance imaging (MRI) in the detection and characterization of hepatic incidentalomas. Contrast-enhanced US represents an alternative option, although it is not widely available.

In this presentation, the role of MDCT and MRI in the investigation of hepatic incidentalomas will be addressed. The guidelines of the American College of Radiology regarding the management of focal liver lesions incidentally detected on CT will be discussed. Finally, the typical CT and MRI features of common hepatic incidentalomas, including both benign and malignant will be reviewed.

CHALLENGES IN PANCREATIC CYSTIC TUMORS

Elmas N. (TR)

Detection and characterization of pancreatic cystic tumors have increased with the widespread use of CT, MRI, and EUS. CT is the frequently used imaging modality for characterization. MRI and MRCP are helpful in evaluating the cyst morphology and the relationship between pancreatic duct and cyst. Guidance to biopsy can be performed with EUS. Pancreatic cystic masses are usually asymptomatic. The presence of a history of pancreatitis or trauma can be indicative for pseudocysts. Differentiation of benign and malignant cystic neoplasms is essential. Management depends on type, location and size of the lesion. True cystic lesions include serous cystic neoplasm (SCN), mucinous cystic neoplasm (MCN), intraductal papillary mucinous neoplasm (IPMN) and solid pseudopapillary epithelial neoplasm (SPEN). SCN predominantly occurs in females. It is usually located in the pancreatic head and consists of numerous small cysts. Central scar and calcifications can be seen. MCN is predominantly located at the pancreatic tail or body. It is frequent in perimenopausal women. It presents with large multilocular cysts. Peripheral calcifications can be observed. Thick septa and/or papillary projections may be signs of malignant degeneration. Malignancy potential is higher in MCN than the other cystic tumors. IPMN is frequently identified in elderly patients. It has main duct and branch duct subtypes. Main duct IPMN shows a higher prevalence of malignancy and generally requires resection. High risk stigmata for IPMN include obstructive jaundice, enhancing mural nodule >5mm, and main pancreatic duct diameter >10mm. SPEN is a rare tumor that frequently presents in young females. It is detected as a large, well-defined pancreatic mass, with solid tissue surrounding central hemorrhagic and cystic areas. Morphologic classification can be grouped as unilocular cysts, microcystic lesions, macrocystic lesions, and cysts with a solid component. Imaging findings are important for characterization of pancreatic cystic lesions, assessment of malignant potential, and decision-making for management.





FOCAL LESION IN CHRONIC PANCREATITIS

Papaioannou S. (GR)

Chronic pancreatitis is an inflammatory disease characterised by progressive damage of the pancreatic tissue, with pancreatic fibrosis. The result is irreversible exocrine and endocrine functional impairment.

Inflammatory mass in chronic pancreatitis retain a large degree of fibrosis. The same happens in pancreatic carcinoma. The fibrosis may diffusely affect the entire gland, but occasionally it is unevenly distributed, with preserved normal lobular pattern in some areas.

Differentiating between an inflammatory mass due to chronic pancreatitis and pancreatic carcinoma remain difficult. Due to fibrosis they both show gradual progressive enhancement on contrast enhanced computed tomography. Also, both diseases show decreased T1 signal intensity with delayed enhancement after gadolinium administration.

Pancreatobiliary ducts are dilated and obstructed. The irregularity of the pancreatic duct and the smoothly stenotic pancreatic duct penetrating through the mass are more favourable of chronic pancreatitis.

An abrupt interruption and dilatation of both biliary and pancreatic ducts favour the diagnosis of cancer.

Current MRI protocols routinely include diffusion-weighted (DWI) acquisitions, which have been investigated for differentiating focal lesion in pancreatic carcinoma and chronic pancreatitis. DWI results are questionable. Pancreatic malignancies show restricted diffusion and significantly lower apparent diffusion coefficients (ADC) values than normal parenchyma and focal lesion in chronic pancreatitis but their ADC increases when necrosis is present.

Chronic pancreatitis predisposes to pancreatic cancer development and both diseases share a common etiology and coexist in 1-6% of patients.

The purpose of this study was to clarify helical CT and MR imaging features of pancreatic mass due to chronic pancreatitis.

RARE PANCREATIC NEOPLASMS

Triantopoulou C. (GR)

The list of rare pancreatic tumors is extensive and in most cases there are overlapping imaging features.

Most pancreatic solid hypoenhancing neoplasms are ductal adenocarcinomas. Rare solid hypoenhancing tumors include adenosquamous carcinoma which has more aggressive behavior and poorer prognosis, acinar cell carcinoma, and non-epithelial neoplasms such as lymphoma and hypodense metastases.

Among the rare hyperenhancing neoplasms the most common are pancreatic neuroendocrine tumors that can widely vary in appearance and presentation. Pancreatic metastases may also present as hyperenhancing solid pancreatic masses. Renal cell carcinoma and melanoma are the most common hyperenhancing metastases but breast and thyroid metastases can also present with the same pattern.





All mesenchymal pancreatic tumors are extremely rare. These tumors may be composed of connective tissue with lipomatous, neuronal, vascular, or lymphatic differentiation. There are benign and malignant mesenchymal tumors. Lipomas, liposarcomas, fibrolipomas, and lipoblastomas can be recognize by the presence of fat. Mesenchymal tumors of neural origin include neurofibromas and schwannomas. Neurofibromas are most commonly associated with neurofibromatosis type 1. Schwannomas are more often seen in neurofibromatosis type 2.

Pancreatic desmoid tumors are an extremely rare site for disease occurrence. Pancreatic perivascular epithelioid cell tumors (PEComa) are part of a larger family of PEComas, which include clear cell tumors, angiomyolipoma, and lymphangiomyomatosis. As with the other PEComas, pancreatic tumors are seen in patients with tuberous sclerosis.

Pancreatic sarcoma can be seen as a primary entity or a secondary entity with pancreatic involvement secondary to retroperitoneal sarcoma. Leiomyosarcoma has been described as the most prevalent primary sarcoma. Secondary involvement of the pancreas is more common.

Finally lymphangiomas are benign and characterized by a well-circumscribed mass, with multicystic components containing serous or chylous fluid with rare calcifications.

PAEDIATRIC RADIOLOGY

INTERVE MRI OF THE FETUS - AN OVERVIEW

Negru D.(RO)

Magnetic Resonance Imaging (MRI) is an alternative modality to evaluate the fetus, ultrasound (US) remaining the screening modality of choice.

There are some advantages of the MRI, the method being not limited by fetal lie, overlying maternal or fetal bone, obesity or oligohydramnios.

MRI is able to offer excellent soft tissue contrast and multiplanar images.

The huge technical evolution of MRI, allow faster sequences and studies without sedation in the second and third trimesters. During examinations we are able to distinguish blood, fat, meconium, cartilage increasing the diagnostic accuracy. Multiplanar images improve the understanding of the abnormalities.

In this presentation we will emphasize the fetal MRI technique, indications and will offer plenty of clinical cases.





PONTINE AND VERMIAN MORPHOMETRY IN FETUSES WITH AGENESIS OF THE CORPUS CALLOSUM ASSESSED BY FETAL MRI

K.Koprivsek 1*, S.Stojanoski1, S.Novakov Mikic1

1Faculty of Medicine, University of Novi Sad, Department of Radiology, Serbia

Objective: To describe the appearance and growth of the fetal vermis and pons, from 24 weeks of gestation to term, in fetuses with agenesis of the corpus callosum (ACC) and to test hypothesis whether fetuses with ACC have different pontine and vermian morphometry when compared with fetuses with normal brain findings on fetal magnetic resonance imaging (MRI).

Methods: Retrospectively, we evaluated the fetal brain MRI examinations performed between 2010-2018, on 20 fetuses with ACC and 42 fetuses with normal brain findings. All MRI examinations were performed at 1.5 Tesla system (Magnetom Aera, Siemens) without maternal sedation. Average gestational age in both groups was 30+4 weeks. Pontine height, vermian height and width were manually measured, at mid-sagittal scan and the vermian to pons ratio (VPR) was calculated according to recommendations of Preyer and Griffiths. Corresponding diameters and VPR values were compared between ACC and control group using Student t test ($p < 0,05$).

Results: The pons and vermis in fetuses with ACC grow in a linear fashion throughout pregnancy. Pontine height was significantly smaller in fetuses with ACC ($9.9 \text{ mm} \pm 1.5$) compared to control group ($11.2 \text{ mm} \pm 1.7$); $p < 0.01$. Vermian width and height in ACC group were smaller, VPR greater than in control group, but the difference was not statistically significant.

Discussion and conclusions: Pontine height reduction could be part of associated rhombencephalic abnormalities in fetuses with agenesis of corpus callosum. Further multidisciplinary investigations are warranted to elucidate underlying cytoarchitectural and/or genetic changes and possible impact on postnatal neurodevelopment.

Ultrasonography of Developmental Dysplasia of the Hip (DDH) Chlapoutakis K.(GR)

Developmental Dysplasia of the Hip (DDH) is a term used to describe a wide spectrum of disorders of the growing hip joint, ranging from immaturity to hip dysplasia and dislocation.

True incidence of DDH is approximately 1% (published prevalence of the disorder ranges from 0,25 to 2,5%).

Risk factors have been well documented and include, among others, female sex, family history, true breech presentation and mechanical restriction after birth (swaddling).

It is now well established that early diagnosis facilitates earlier and more successful treatment. Low sensitivity of clinical examination promoted the development of several sonographic techniques for the diagnosis of the disorder. Graf's technique, supported by robust clinical and epidemiological literature, offers a valuable examination tool, both for the correct diagnosis and the monitoring of treatment of DDH.

Universal sonographic screening is mandatory for the identification of all neonates with DDH.





If diagnosed early, hip pathology is then conservatively treated with an abduction device, to achieve reduction, retention and maturation of the hip joint.

Consensus on the various issues regarding DDH, in particular policies for early detection and treatment, standardization, promotion and improvement of teaching and training the sonographers performing Graf's technique, and also research, audit and quality improvement in the field of detection and early treatment, are the main interests / work topics of an international group of specialists that was formed in 2018, now formalized as the International Interdisciplinary Consensus Committee on DDH Evaluation (ICODE).

ONA RENAL PELVIC DILATATION IN THE FETUS

Arvaniti M.(GR)

Prenatally discovered urinary tract dilatation (UTD) is common. Although many classification systems exist, there is a lack of uniformity in defining and classifying UTD, both prenatally and postnatally. Efforts continue worldwide for a unified grading system of UTD, so that prenatal US findings correlate well to postnatal US findings, in the quest for appropriate and internationally accepted evaluation and postnatal management guidelines.

In general, the prenatal grade of dilatation determines and correlates well with the severity of postnatal dilatation. Several parameters must be sonographically evaluated, both prenatally and postnatally, including: the anterior – posterior renal pelvic diameter, possible calyceal dilatation, the parenchymal thickness and echogenicity, possible ureteric dilatation, the bladder wall, the presence of oligohydramnios, etc.

In the postnatal workout, other imaging modalities should also be individually considered, including VCUG, ce-VUS, dynamic renography and MRU. Therapeutic and prophylactic management (e.g. surgery, antibiotics) should also be put in their right perspective. As more experience and data are accumulated, controversy and research for a unified optimal approach, with internationally agreed imaging and therapeutic management guidelines concerning UTD in fetuses and neonates continue.





FRIDAY , OCTOBER 18TH , 2019

ABSTRACTS – ORAL PRESENTATIONS

ABSTRACTS ORAL PRESENTATIONS



INTERVENTIONAL RADIOLOGY

OP 022

BILIARY ANASTOMIC LEAKAGE FOLLOWING ELECTIVE LAPAROSCOPIC CHOLECISTECTOMY: NON-INVASIVE DETECTION USING GD-EOB-DTPA ENHANCED MR CHOLANGIOGRAPHY

Kemal Murat Haberal¹, Mehmet Coskun¹

1. School of Medicine, Department of Radiology, Baskent University, Ankara, Turkey

Increasing hepatobiliary laparoscopic surgeries have led to a rise in injury to the biliary tree and other complications like bile leak. Significant postoperative bile leak may occur in up to 1% of patients undergoing laparoscopic cholecystectomy (1). Definite preoperative localisation of bile leaks is important in determining the surgical approach and reducing the extent of exploration and anaesthesia time. Thus, morbidity and mortality rates can be reduced significantly (2). Ultrasonography (US) and computed tomography (CT) cannot reliably distinguish bile from other postoperative fluid collections. Magnetic resonance (MR) imaging with hepatobiliary agents and MR cholangiopancreatography provide anatomic and functional information that allows for prompt diagnosis and excludes any other concomitant complications.

We want to present a case of post-cholecystectomy bile leak in a 61-year-old female who presented with persistent dull abdominal pain after the intervention, postoperative biliary anastomotic leakage demonstrated on intravenous contrast-enhanced MRI performed with Gd-EOB-DTPA (gadolinium ethoxybenzyl diethylenetriamine penta-acetic acid/Primovist). Primovist has been widely used for its combined extracellular and hepatocyte-specific properties in the characterization of liver lesions. Another recognized, but less widely utilized property of Primovist is its ability to provide morphologic and functional assessment of the biliary system. Primovist is incorporated into the hepatocytes by an anionic transport system after the vascular phase. Approximately 50% of Primovist is excreted in the human biliary system. Therefore, Primovist may provide adequate biliary imaging after 10-20 minutes (3). In our case, Primovist-enhanced MR imaging demonstrated the presence and location of an active biliary leakage which was associated with free spillage into the peritoneum.

References

1. Deziel DJ, Millikan KW, Economou SG, et al: Complications of laparoscopic cholecystectomy: a national survey of 4,292 hospitals and an analysis of 77,604 cases. *Am J Surg.* 1993;165:9-14.
2. Kantarcı M, Pirimoglu B, Karabulut N, et al: Non-invasive detection of biliary leaks using Gd-EOB-DTPA-enhanced MR cholangiography: comparison with T2-weighted MR cholangiography. *Eur Radiol.* 2013; 23(10): 2713-2722.
3. Seale MK, Catalano OA, Saini S, Hahn PF, Sahani DV. Hepatobiliary-specific MR contrast agents: role in imaging the liver and biliary tree. *Radiographics.* 2009;29:1725-1748.





OP 023

PERCUTANEOUS US-GUIDED MWA OF SMALL LIVER HCC: PREDICTORS OF OUTCOME AND RISK FACTORS FOR COMPLICATIONS FROM A SINGLE CENTER EXPERIENCE

Pierpaolo Biondetti¹, Anna Maria Ierardi¹, Enrico Maria Fumarola¹, Gianpaolo Carrafiello¹

¹ Diagnostic and Interventional Radiology Department, ASST Santi Paolo e Carlo, San Paolo Hospital, University of Milan, Via A di Rudini 8, 20142, Milan, Italy

INTRODUCTION Microwave ablation (MWA) is today used by many institutions for treatment of various neoplasms, including hepatocellular carcinoma (HCC).

PURPOSE: to identify risk factors for complications or predictors of outcome in patients with small HCC (< 3cm) treated by percutaneous MWA.

MATERIAL AND METHODS: Forty-six patients with non-previously treated small HCC, mean diameter of 17,22 mm, underwent ultrasound-guided percutaneous MWA. Nodules were classified as central in 28.3%, pericholecystic in 32.6%, and peripheral in 39.1% of cases. Patient factors (albumin, platelets, International Normalized Ratio/Prothrombin Time, Partial Thromboplastin Time ratio, bilirubin, Child-Pugh classification, etiology of liver disease) and tumor factors (diameter, border type, hepatic segment, contact with portal vein or arterial vessels, hepatic hilum, capsule and presence of 5 mm ablative margin) were assessed. Outcome and complications rates were registered during follow-up. Patient and tumor factors were then analyzed in relation to outcome and complications

RESULTS: Incomplete response was detected in 13,0% of cases at one-month follow up. Local tumor progression was recorded in 21.7% of cases at 3-12 months after intervention. New HCC nodules were recorded in 19.6% at 3-24 months post-procedure. Complications occurred in 17,4 % patients, with 2.2 % of them being major. Ablation site was significantly related to incomplete response, local tumor progression, appearance of a new nodule and complication onset; insufficient ablation margin was related with local tumor progression and complication onset. Time from ablation was related with new nodule onset. Child-score was related with complication onset.

CONCLUSION: Despite the small series analyzed, significant factors related with outcomes may be kept in mind.

Conflict of interest: None

Funding: None





OP 024

PERCUTANEOUS MICROWAVE ABLATION OF RENAL ANGIOMYOLIPOMAS IN TUBEROUS SCLEROSIS COMPLEX TO IMPROVE THE QUALITY OF LIFE

Mario Petrillo¹, Pierpaolo Biondetti¹, Anna Maria Ierardi¹, Salvatore Alessio Angileri¹, Gianpaolo Carrafiello¹

¹ Diagnostic and Interventional Radiology Department, ASST Santi Paolo e Carlo, San Paolo Hospital, University of Milan, Via A di Rudini 8, 20142, Milan, Italy

Introduction Tuberous sclerosis complex (TSC) patients develop at least one renal angiomyolipoma (AML) in 80% of cases, and sometimes multiple bilateral tumors. Renal AMLs are associated with renal dysfunction and, when larger than 4cm, hemorrhage. Preservation of renal parenchima is crucial in these patients, with multiple mini-invasive treatment options reported, including microwave ablation (MWA).

Purpose To evaluate efficacy and safety of percutaneous MWA for treatment of renal AMLs in patients affected by TSC, and to assess the effects on their quality of life.

Materials and methods Nine patients (7 females and 2 males; mean age 27.6 years, range 23–34), with 10 renal AMLs with a mean size of 6.3 cm (range 4.5–8.5) were treated with image-guided percutaneous MWA. Indications for treatment were risk of hemorrhage (>4cm), symptomatology, or previous hemorrhage. The volume of ablated AMLs was assessed at follow-up by MRI, and its relationship with symptoms was investigated. Technical and clinical success, safety, and quality of life (QOL) were assessed during follow-up (mean 9 months, range 3–12).

Results Technical and clinical success were achieved in all cases. No significant association was found between the volume of ablated AMLs and symptoms, but all patients experienced an improvement in QOL. There were no major procedural complications. A small self-limited subcapsular hematoma occurred in one patient. Post-ablation syndrome was registered in 5 cases and was self-limited. No bleeding occurred during follow-up.

Conclusions Percutaneous image-guided MWA of AMLs in TSC patients is a safe procedure that can reduce the risk of hemorrhage, achieve symptomatic relief and improvement of QOL.

Conflict of interest: None

Funding: None





OP 025

PERCUTANEOUS MICROWAVE ABLATION OF UTERINE FIBROIDS: CORRELATION BETWEEN SHRINKAGE OF THE LESION AND SYMPTOMS

Anna Maria Ierardi¹, Pierpaolo Biondetti¹, Mario Petrillo¹, Giuseppe Granata¹, Gianpaolo Carrafiello¹
¹ Diagnostic and Interventional Radiology Department, ASST Santi Paolo e Carlo, San Paolo Hospital, University of Milan, Via A di Rudini 8, 20142, Milan, Italy

Introduction: Uterine fibroids are the most common benign neoplasm in women and are often associated with symptoms that affect patients' quality of life. To date, different treatment options are available for fibroids including surgery and mini-invasive treatments, like percutaneous microwave ablation.

Purpose: To assess a correlation between shrinkage of tumor and symptoms after treatment with ultrasound-guided percutaneous microwave ablation.

Methods: Fourteen patients with symptomatic subserosal uterine leiomyomas measuring >4cm maximum diameter (mean fibroid volume: 111,45 cm³) were treated. Contrast enhanced MRI was performed before and after treatment to assess the tumor volume. Two scores derived from the Uterine Fibroids Symptom and Quality of Life questionnaire, representing a measure of symptoms and quality of life, were assessed at baseline and at 3, 6 and 12 months after treatment.

Results: Technical success was achieved in all patients with no complications. Throughout a mean MR follow-up of 8,1 months we observed a shrinkage of the fibroids in all patients (mean 70,3 cm³). During a 12 month clinical follow up, we observed a significative improvement of symptoms and an excellent improving of Quality of Life (p < 0,001).

Conclusion: Uterine fibroid percutaneous microwave ablation can achieve a volume shrinkage of tumor in time which is associated with a significant improvement in Quality of Life of treated patients.

Conflict of interest: None

Funding: None

OP 026

PERCUTANEUS COMPUTED TOMOGRAPHY GUIDED RADIOFREQUENCY ABLATION FOR TREATING METASTATIC LYMPH NODES: A SINGLE CENTER'S EXPERIENCE

Efthymiou E. Filippiadis D. Theodosis A. Reppas L. Palialexis K. Spiliopoulos S. Kelekis A. Brountzos E., Kelekis N.

2nd Department of Radiology, University General Hospital "Attikon", Medical School, National and Kapodistrian University, Athens Greece

Introduction: Treating oligometastatic patients with pathologic lymph nodes has been shown to increase survival rate. Due to the nodal capsule and the resultant "oven effect" radiofrequency ablation seems to be a very effective and safe technique.

Purpose: To assess the effectiveness and safety of computed tomography guided percutaneous radiofrequency ablation (RFA) of metastatic lymph nodes (LN).

Materials and methods: Twelve patients with metastatic solitary lymph nodes underwent percutaneous computed tomography guided radiofrequency ablation. All patients were evaluated prior to ablation either with MRI (including diffusion weighted imaging) or PET-CT and underwent biopsy on the same session with ablation using an 18 G semi-automatic soft tissue biopsy





needle. Contrast-enhanced computed tomography or magnetic resonance imaging was used for post-ablation follow-up. Patient and tumor characteristics, radiofrequency ablation technique and complications were evaluated.

Results: Mean patient age was 67.66 years (male-female: 8-4). Average lesion size was 2 cm (range 1.2-3 cm). Malignant substrate included renal cell carcinoma (RCC) (n=3), hepatocellular carcinoma (HCC) (n=3), sarcoma (n=2), gastric carcinoma (n=2) and colorectal carcinoma (n=2). Technical success was feasible in all 12 lymph nodes (100%); there were no complications reported. Mean follow-up was 9.3 months (range 1-19 months) and there was evidence of recurrence at ablated sites in 2/12 patients with lymph nodes measuring 3 cm in diameter. Both patients were retreated with no signs of local recurrence thereafter. After RFA, 5/12 metastatic LN completely disappeared and 7/12 remained as small scar-like lesions at the last follow-up visit.

Conclusion: Computed tomography guided percutaneous RFA for metastatic LNs is a feasible, safe and effective therapy. With this nonsurgical percutaneous therapeutic option metastatic lymph nodes can be eradicated with a very low complication rate.

OP 027

SINGLE CENTER PROSPECTIVE STUDY EVALUATING PAIN TOLERABILITY DURING LIVER MICROWAVE ABLATION WITH CONTINUOUS OR PULSED ENERGY DELIVERY MODE

Efthymiou E. Filippiadis D. Mazioti A. Velonakis G. Kelekis A. Brountzos E. Kelekis N.

2nd Department of Radiology, University General Hospital "Attikon", Medical School, National and Kapodistrian University, Athens Greece

INTRODUCTION: Pulsed delivery of microwave energy has been used for the production of a more spherical ablation zone. When compared to continuous delivery mode, there is an additional assumption of lower intra-operative level due to the more homogeneous energy deposition.

PURPOSE: To evaluate pain tolerability during liver microwave ablation with continuous or pulsed energy delivery mode by comparing the self-reported pain scores of patients

MATERIAL – METHODS: During the last 6 months 24 patients underwent liver ablation; patients were prospectively evaluated and randomized into continuous mode (CM – 12 patients) and pulsed mode (PM – 12 patients) groups. All ablation sessions were performed under Computed Tomography-guidance and IV analgesia (paracetamol 1g + tramadol 100ml – same anaesthesia protocol in all 24 patients). Group CM included 6 HCC and 14 metastatic [colon(9), pancreatic (1), breast (2), bronchogenic (2) carcinoma] treated lesions; depending on location CM group included 6 sub-capsular and 14 lesions at least 2 cm away from liver capsule. Group PM included 6 HCC and 12 metastatic [colon(8), pancreatic (1), breast (2), bronchogenic (1) carcinoma] treated lesions; depending on location PM group included 8 sub-capsular and 10 lesions at least 2 cm away from liver capsule. Immediately upon completion of the ablation session all patients were asked to complete a pain score questionnaire with a 0-10 numeric pain scale.

RESULTS: The mean pain score was 8.17 ± 1.850 in CM group and 4.50 ± 1.567 pain units in PM group. There was a statistically significant difference of 3.667 ± 2.807 pain units ($p = 0.001$). No complications were noted in CM group; there were two grade I complications according to the CIRSE classification system (small peri-hepatic haemorrhagic fluid collections).

CONCLUSION: Pulsed mode of microwave ablation seems to be less painful for patients undergoing liver ablation under IV analgesia, rendering this mode an attractive alternative whenever anesthesiologist is not present.





OP 028

TRANSCATHETER RENAL INTERVENTIONS : A REVIEW OF EMERGENCY PROCEDURES AND SCHEDULED ONES

D. Stefanou, E.Antonakou, A.Tsokas, P.Ioannidi, D.Tomais, I.Kalogeropoulos, T.Kratimenos
 Radiology Department , Interventional Radiology Department , 'Evangelismos' Hospital

INTRODUCTION

Transcatheter interventions play a significant role in the treatment of renal pathology, whether this includes an emergency or a scheduled procedure. Angioplasty, stenting, Ch- EVAR (chimney) technique, embolization of renal neoplasm or trauma are included in the array of procedures available for the interventional radiologist.

PURPOSE

To review the established transcatheter renal interventions, the indications for endovascular treatment, the efficacy and safety of the methods.

MATERIAL AND METHODS

From January of 2016 until June of 2019, a cohort of 47 patient referred to our department for endovascular intervention of renal pathology. All underwent scanning with ultrasound as well as with a 16-slice CT after injection of iodine contrast agent intravenously. Post-processing procedures such as Multiplanar *Reconstruction* and Maximum Intensity Projection reconstructions aided in identifying the aforementioned pathology. DSA for precise mapping and accurate material selection was performed.

RESULTS

Endovascular intervention had a 100% successful rate and was well tolerated, while none complication emerged. 10/12 angiomyolipomas were treated successfully with selective renal artery embolization sparing the normal renal parenchyma, while the remaining 2 cases needed a reapproach for total treatment. 14/14 vascular embolization including iatrogenic injuries, postoperative pseudoaneurysms and vascular malformations of Bourneville syndrome were 100% successful. 11/11 patients with renal stenosis were treatment with stent placement including a case of transplanted kidney with stenosis at the level of anastomosis. Finally, 10/10 cases were technically and clinically successful after placing an aortic stent graft performing the Ch-EVAR technique.

CONCLUSION

Early and accurate diagnosis of renal pathology with CT, US, CEUS-US and MRI is the key to avoid unnecessary nephrectomy, providing a wide spectrum of pathology for endovascular treatment. The efficacy of percutaneous transcatheter endovascular interventions depends on the accurate detection of renal pathology, the appropriate choice of materials and the experience of interventional radiologist





performing the procedure. Complications related to endovascular interventions are rare and follow up of the patient requires short time of hospitalization and daily activities may be resumed immediately.

OP 029

CROSS-SECTIONAL IMAGING OF IATROGENIC COMPLICATIONS AFTER PERCUTANEOUS NEPHROLITHOTOMY (PCNL) AND URETEROSCOPY (URS)

Kaitartzis C., Arvaniti M., Ouroumidou K., Delianidou A., Panagasidou I., Daniil G., Torounidis I.
 Radiology Department of General Hospital of Thessaloniki "G. Gennimatas", Greece

Introduction: Percutaneous nephrolithotomy (PCNL) and ureteroscopy (URS) are the current gold standard methods for the treatment of large and complex renal stone disease. They are complex procedures that require skill and experience.

Purpose: To present our experience in the stratification with cross-sectional imaging, of the complications of PCNL and URS, with the use of the modified Clavien system.

Materials and Methods: 920 patients were treated by PCNL and URS from March 2015 to May 2019 in our Hospital. We review the clinical features and cross-sectional imaging appearances of common and unusual complications, with case examples. Postoperative complications were classified by the modified Clavien grading system.

Results: A total of 108 severe iatrogenic complications were documented, including steinstrasse, subcapsular, perirenal and suburothelial haemorrhage, severe urinary tract infections (such as pyeloureteritis, pyelonephritis, renal abscesses and pyonephrosis), ureteral injuries, delayed strictures, lower renal pole rupture, urinary bladder rupture, pleural injury, segmental renal artery pseudoaneurysm with hemorrhage. All postprocedural complications that obviated CT scanning ranked between grades IIa and V.

Conclusion: The most challenging step and key requisite of iatrogenic complications is establishing optimal access to the renal collecting system with the help of imaging modalities. Due to the increasing prevalence of urolithiasis and the large number of therapeutic procedures performed, in hospitals with active urologic practices radiologists are increasingly requested to investigate suspected post-procedural complications following PCNL or ureteroscopic stone removal. Image guidance is a critical factor for the performance of urologic interventions.





OP 030

ENDOVENOUS RADIOFREQUENCY ABLATION OF THE ABOVE-KNEE SAPHENOUS VEIN AND SEQUENTIAL FOAM SCLEROTHERAPY OF THE BELOW-KNEE SAPHENOUS VEIN IN VENOUS REFLUX: A SINGLE CENTER EXPERIENCE

Colakoglu Bulent

Vkv Amerikan Hospital Radiology – Nisantasi, Istanbul Turkey

Introduction: Surgical treatment of the great saphenous vein (GSV) reflux with high ligation and stripping was the mainstay treatment option in the last century. However, in the previous decade, invasive nature, high recurrence and complication rates of the conventional surgical techniques have led to a shift to minimally invasive endovenous treatment modalities.

Aim: To demonstrate our results with above knee-great saphenous vein (AK-GSV) radiofrequency ablation (RFA) with or without ambulatory phlebectomy and sequential below knee-great saphenous vein (BK-GSV) ultrasound-guided foam sclerotherapy (USGFS) in GSV insufficiency.

Methods: The presence of venous disease was determined according to Doppler findings. GSV was cannulated under US guidance at the level of the knee. RFA was performed through cranial to the caudal direction, and every 7-cm segment of the vein was treated in a 20-second treatment cycle at 1200

C temperature. Sequential USGFS was performed one week after the RFA ablation procedure; GSV was cannulated with a 27 Gauge needle, just below the lowest incompetent BK-GSV segment, sclerosant foam delivered along the GSV. Patients were followed by Doppler US examinations at two weeks and one year after the treatment, and patients' experiences during the treatment process were questioned at one-year.

Results: A total of 210 patients, 158 women, and 52 men, with 348 lower extremities (164 right limb and 184 left limb) were treated with AK-GSV RFA and sequential BK-GSV. Doppler US control was performed one year after the treatment, and the AK-GSV and BK-GSV were totally occluded in 95,7% and 44,3% of the patients, respectively. The patients satisfaction rate was 96,19% at one year.

Conclusion: AK-GSV RFA with concomitant BK-GSV UGFS is a suitable treatment option for patients with AK and BK GSV reflux, which achieves excellent patient satisfaction, despite relatively low BK segment occlusion rate at one year.





OP 031

SINGLE CENTER EXPERIENCE IN MALIGNANT SVCS STENTING USING DIFFERENT NITINOL STENT TYPESNikolas Matthaiou¹, Nikolaos Galanakis¹, Elias Kehagias¹, Nelly Kcholcheva¹, Dimitrios Tsetis¹¹ Department of Medical Imaging, Unit of Angiography and Interventional Radiology, University Hospital of Heraklion, Iraklion, Greece

Introduction

Superior vena cava syndrome (SVCS) is the result of blood flow impairment through the superior vena cava. It is a very common complication in patients suffering from lung and mediastinal malignancies because of outer compression or direct invasion on the vein. It is a medical emergency which requires immediate diagnostic evaluation and treatment.

Purpose

The aim of this study is to evaluate the technical success and clinical outcome of SVC stenting in malignant SVCS and to correlate the efficacy of different types of nitinol stents used.

Methods

Between July 2006 and July 2018, 156 patients (132 male) with a median age of 62 (range 33-81) were treated with self-expanding nitinol stents. The main causes of malignant SVCS were bronchogenic carcinoma, metastases and lymphoma. The diagnosis of SVCS was based on clinical symptoms/signs and imaging studies. Patients were followed-up for a mean duration of 8 months.

Results

Technical success achieved in 98% of cases. There were 2 cases of migration to the right atrium and pulmonary artery and 1 case of death due to SVC rupture. Upper limb vein puncture was performed successfully without complications in all cases. The follow-up showed an overall survival of 92%, 56% and 22.8% and an overall primary patency of 93.4%, 83.6% and 79.9% at 1 month, 6 months and 1 year respectively. There were no statistically significant differences in primary patency between venous dedicated and peripheral use stents ($p>0.05$).

Conclusions

Stent placement in SVCS seems to be a safe and effective treatment option for patients suffering from malignant SVCS, with no significant difference between venous dedicated and peripheral use nitinol stents.





OP 032

USE OF NEW GENERATION DUAL LAYER MICROMESH STENTS FOR CAROTID ARTERY STENTING – OUR EXPERIENCE

Aleksandar Gjoreski¹, Filip Risteski¹, Ivona Jovanoska¹, Petar Atanasovski¹, Sanja Zikova Dzambazovska¹

¹Department for diagnostic and interventional radiology, City General Hospital "8th September", Skopje, Republic of North Macedonia

Introduction:

Carotid artery stenting (CAS) represents an alternative treatment option to endarterectomy (CEA) for the treatment of extracranial carotid artery disease. Both closed and open cell design stents have been used for this purpose routinely with satisfactory results. Recently, new generation dual layer micromesh stents like the Roadsaver stent, Terumo are available options for this purpose.

Purpose:

The purpose of this abstract is to show our experience with the use of this new generation dual layer carotid stent device, Roadsaver, Terumo. Furthermore, we evaluated it's safety and efficacy in patients who are eligible candidates for elective stenting procedure.

Materials and methods:

Thirty four patients with symptomatic carotid artery stenosis were treated with CAS with the use of Roadsaver stent form the period of November 2017 to May 2019 at the Department for diagnostic and interventional radiology at City General Hospital "8th September". All patients had previously diagnosed significant carotid stenosis (> 70%) confirmed by Duplex ultrasound and CT angiography. Roadsaver stent was used in all cases with distal embolic protection in 31 and with proximal cerebral protection in 3 cases. Technical success of the procedure as well as rates of any major adverse events (MAEs) defined as the cumulative incidence of any death or stroke within 30 days after procedure were evaluated. Neurological assessment of patients with NIHSS score was performed pre and post procedure and at 1 month follow up period.

Results:

Technical and procedural success was achieved in all thirty four cases (100%). The rate of any TIAs, stroke or death within 30 days from the initial procedure was 0%. No major vascular and bleeding complications occurred.

Conclusion:

Our initial experience with the use of Roadsaver micromesh stent for CAS showed promising and effective results. According to this primary investigation results we can conclude that the use of dual layer stents for CAS is safe and effective. Further studies with larger patient series are needed in future to confirm this statement.





ULTRASONOGRAPHY

OP 001

RADIOLOGICAL-PATHOLOGICAL CORRELATION OF THYROID NODUL ULTRASOUND AND CYTOLOGY USING THE TIRADS AND BETHESDA CLASSIFICATIONS

Serdar Aslan¹, Suleyman Ozdemir²

¹Turhal State Hospital, Radiology Clinic, Turhal, Tokat, Turkey

²Turhal State Hospital, Pathology Clinic, Turhal, Tokat, Turkey

Introduction: Thyroid Imaging Reporting and Data System (TIRADS) is a risk stratification system for classifying thyroid nodules on ultrasound. It allows clinicians involved in the management of thyroid nodules to have an objective system of clinicopathological correlation.

Purpose: To compare the TIRADS of classifying thyroid nodules with the findings on fine-needle aspiration cytology (FNAC) reported using the Bethesda System.

Methods and Materials: A prospective analysis of 150 patients was performed comparing thyroid nodule ultrasound findings based on the TIRADS classification to the FNAC report based on the Bethesda Classification. TIRADS 1 and previously biopsy-proven malignancy were excluded. Benign-appearing nodules were reported as TIRADS 2 and 3. Indeterminate or suspected follicular lesions were reported as TIRADS 4, and malignant-appearing nodules were reported as TIRADS 5. All the nodules were performed to FNAC, and TIRADS findings were compared to Bethesda Classification.

Results: Of 150 patients, 77 were TIRADS 2, 28 were TIRADS 3, 18 were TIRADS 4 and 27 were TIRADS 5. The probability of a malignant FNAC (Bethesda V-VI) in TIRADS 2, 3, 4 and 5 classes were 0%, 7.1%, 16.6% and 81.4%, respectively. The benign FNAC (Bethesda II) in TIRADS 2 was 100%, while for TIRADS 3, 4 and 5 were 75%, 27.7% and 4.6%, respectively. Of 18 patients that were classified as TIRADS 4, 5 were benign (Bethesda II), 8 were indeterminate (Bethesda III), 2 were follicular neoplasms (Bethesda IV), and 3 were malign (Bethesda V-VI). Of 27 patients that were TIRADS 5, 20 patients had a biopsy-proven cancer (74% concordance), but 7 were benign. Overall concordance rate with FNAC was 92%, and sensitivity, specificity and negative predictive value were 88%, 90.4% and 95% respectively.

Conclusion: Our study shows a fairly good correlation of thyroid ultrasound reporting using the TIRADS classification with the Bethesda Classification of FNAC.

DISCLOSURE: Authors should disclose any relationship that may bias their presentation.





OP 002

ACOUSTIC RADIATION FORCE IMPULSE ULTRASOUND IMAGING IN DIAGNOSING CERVICAL CARCINOMAKemal Murat Haberal¹

1. Department of Radiology, Ankara Hospital, School of Medicine, Baskent University, Ankara, Turkey.

Introduction

Cervical cancer is the fourth most common female malignancy worldwide(1). MRI with high contrast resolution of soft tissue, is the ideal modality for visualization of the cervix(2). Ultrasound is gaining clinical interest since it is less time consuming, cheaper, noninvasive and safe. Acoustic radiation force impulse (ARFI), a new technique of ultrasonic elastography, is able to obtain qualitative and quantitative information of the elasticity distribution within tissues(3).

Purpose

The aim of this study was to evaluate the application of acoustic radiation force impulse (ARFI) ultrasound imaging and its potential value in the characterization of cervical cancer.

Materials and Methods

Sixty six patients between March 2017 and April 2019 were selected then two groups were created, as group I for control and II for cancer. A total of 30 women in group I (mean age 34.5 ± 8.35 years, range 22-46) and a total of 36 women in group II (mean age 47.04 ± 11.42 years, range 31-70) were enrolled in the study.

Real-time ARFI ultrasound imaging was performed using an Acuson S2000 diagnostic ultrasound system (Siemens Healthcare, Germany) equipped with a 3.5 MHz abdominal probe. All measured data were presented as the mean \pm standard deviation. The ARFI analysis used the non-parametric Mann-Whitney U test.

Results

All the lesions were assessed at least three times by the observer based on various static images and the average value was recorded as the final result. From the 36 malignant lesions, 24 (%66.7) were squamous, 3(%8.3) were adenosquamous and 9 (%25) were adenocarcinoma. The lesion sizes ranged from 24mm to 89mm, with an average of 32,2mm. There were no significant difference between the ARFI values for subtypes of cervical carcinoma.

Normal tissue had ARFI values with a mean of 1.86 ± 0.62 m/sec, while the ARFI values in malignant lesions were 2.79 ± 1.03 m/sec, $P < 0.001$.





Conclusion

ARFI ultrasound imaging of the uterine cervix may be an objective method for the assessment of cervical cancer.

References

1. Bray F, Ferlay J, Soerjomataram I, et al: Global cancer statistics 2018: GLOBOCAN estimates of incidence and mortality worldwide for 36 cancers in 185 countries. *CA Cancer J Clin* 68: 394–424, 2018.
2. Fischerova D, Cibula D, Stenhova H, et al: Transrectal ultrasound and magnetic resonance imaging in staging of early cervical cancer. *Int J Gynecol Cancer* 18: 766-772, 2008.
3. Shuang-Ming T, Ping Z, Ying Q, Li-Rong C, Ping Z and Rui-Zhen L: Usefulness of acoustic radiation force impulse imaging in the differential diagnosis of benign and malignant liver lesions. *Acad Radiol* 18: 810-815, 2011.

OP 003

ULTRASOUND ELASTOGRAPHY OF BREAST LESIONS: CORRELATION OF STRAIN AND SHEAR WAVE ELASTOGRAPHY WITH HISTOPATHOLOGICAL FINDINGS

Valentin Ivanov¹, Gavril Nakov¹, Magdalena Peneva¹

¹Department of Radiology, Acibadem City Clinic Tokuda Hospital, Sofia, Bulgaria

Introduction: elastography is an ultrasound technique that provides useful information about tissue stiffness. There are two types of elastography – strain (SE) and shear wave (SWE). The former determines the relative elasticity of a tissue and the latter determines its quantitative stiffness.

Purpose: to evaluate the elastographic findings in strain and shear wave examination of suspicious lesions of the breast. Subsequently the results from the elastography were correlated with the histopathological findings from the core biopsy.

Materials and methods: a retrospective study with a total of 72 suspicious breast lesions of 72 consecutive patients were evaluated using strain and shear wave elastography. In each case the distance ratio (E/B ratio) in strain elastography and the maximum speed and the ratio of the maximum speed and the speed of the breast fat tissue were obtained. Every lesion is also classified according to the Tsukuba Elasticity Score (TES, Itoh-Score). Correlation of elastographic measurements with histopathological findings were studied.

Results: fifty-nine malignant and thirteen benign lesions were histopathologically diagnosed. The distance ratio (E/B ratio), maximum speed and the ratio of the maximum speed and the speed of the breast fat tissue were obtained. The mean distance ratio of malignant lesions was 0.99 and of benign lesions was 0.89. The mean maximum speed was accordingly 6,26 m/s (117,5 kPa) and 5,4 m/s (87,5 kPa) and the mean mass/fat ratio was accordingly 0,7 and 0,91.

Conclusion: the elastographic technique increases the diagnostic value of the ultrasound examination in the assessment of breast lesions. Both elastographic methods lead to an increased diagnostic value of the ultrasound examination when confirming or renouncing malignant changes.





OP 004

THE PREDICTION OF INFRAVESICAL OBSTRUCTION WITH SONOGRAPHIC ESTIMATION OF BLADDER WEIGHT

Kulali Fatma, Kulali Safak Firat

Radiology Department, University of Health Sciences Umraniye Training and Research Hospital, Itsnabul ,Turkey

Introduction:

Pressure-flow urodynamic test which is gold standard for diagnosis of infravesical obstruction due to benign prostate hyperplasia (BPH) is an invasive and difficult method.

Purpose:

Our aim was to predict infravesical obstruction due to BPH with sonographic estimation of bladder weight.

Materials and Methods:

A total of 70 men (35 men with infravesical obstruction due to BPH in study group with a mean age of 69 and 35 men in control group with a mean age of 68) were enrolled in this retrospective study. Bladder wall thickness and volume of bladder on ultrasound was used for estimation of bladder weight. Two groups were compared. Relationships between estimated bladder weight and international prostate symptom score, maximum flow rate and severity of obstruction were investigated.

Results:

Our study consisted of two groups; study group (35 men with infravesical obstruction) and control group (35 men without urinary symptoms). In study group (n=35), 19 men had severe and 16 men had mild-moderate obstruction according to pressure-flow urodynamic tests. There was significant difference in the estimated bladder weight between patients with severe obstruction (63 ± 6 gr) and mild-moderate obstruction (46 ± 3 gr). Study group (53 ± 24 gr) had higher estimated bladder weight than control group's (36 ± 18 gr). In study group, there was intermediate correlation between estimated bladder weight and prostate symptom score ($r=0.323$) and negative correlation between estimated bladder weight and maximum flow rate ($r=-0.369$).

Conclusion:

Sonographic estimation of bladder weight is noninvasive, reliable and easily applicable method for prediction of infravesical obstruction due to BPH.

Keywords: benign prostate hyperplasia, infravesical obstruction, ultrasound, urodynamic test





OP 005

THE VALUE OF SHEAR WAVE ULTRASONOGRAPHY IN CALCULATING ELASTOGRAPHIC VALUES IN LIVER PATHOLOGIES

Nalbant Mustafa Orhan, Ercan Inci

Dr. Sadi Konuk Research and Training Hospital

Background: Liver pathologies consist of multiple benign and malignant diseases; shear-wave elastography values vary according to the lesions. We aimed to determine the mean shear-wave elastography values quantitatively in different lesions of the liver in our study.

Materials and methods: 17 focal nodular hyperplasia, 41 hemangiomas, 25 cysts and 45 malignant lesions were evaluated in 112 patients who had liver pathology. 20 patients had hepatosteatosi and fibrosis was present in 26 patients. B-mode and shear wave ultrasonography examinations were performed on defined pathologies. Malignant lesions were histopathologically diagnosed and benign lesions were evaluated according to cross-sectional examination (Computerized Tomography, Magnetic Resonance Imaging) methods.

Results: In our study, the average elastography values were determined as 50.38 kilopascals (kPa) and 3.69 meters/second (m / s) in FNH lesions; 12.54 kPa and 1.97 m / s in hemangiomas; 116,47 kPa and 6,34 m / s in malignant lesions; 8.97 kPa and 1.57 m / s in the cysts; 16.54 kPa and 2.30 m / s in cases with hepatosteatosi and 90,98 kPa and 5.44 m / s in cases with liver fibrosis. Mean values in cysts, hepatosteatosi and hemangiomas were close to normal; In liver fibrosis, in malignant lesions and in FNH lesions they were higher than normal.

Conclusion: We think that shear wave elastography is a promising method in distinguishing benign-malign liver lesions by calculating quantitative values where biopsy-free diagnosis preferred in the present day.

Key words: Diffuse liver diseases, FNH, hemangioma, shear wave ultrasound





OP 006

SONOGRAPHIC EVALUATION OF PEDIATRIC LOWER ABDOMINAL PAIN

Kaitartzis C., Nalmpantidou C., Arvaniti M., Daniil G., Vekiou R., Panagasidou I., Eleftheriadou M.
 Radiology Department of General Hospital of Thessaloniki "G. Gennimatas", Greece

Introduction: Lower abdominal pain is a common presentation cause in the pediatric population, representing a diagnostic challenge for pediatric radiologists. Lacking ionizing radiation, sonography is an excellent, non-invasive imaging modality for the evaluation of pediatric lower abdominal pain. Common causes include GI tract inflammatory conditions, mesenteric lymphadenopathy and coprostasis. Pathology of the inner female genitalia and tumors are less common causes.

Purpose: To present our experience in the sonographic evaluation of pediatric lower abdominal pain, demonstrating the important role of sonography in the correct diagnosis of the underlying pathologic spectrum.

Materials and Methods : During a 2-year period (2017-2019), 2915 pediatric ultrasound scans were performed in our Department. Patients' age ranged between 1 day and 17 years. In 757 cases, lower abdominal pain was the presenting cause. Sonography was performed in supine position, with the use of convex and linear transducers. Full bladder and post-void scans were obtained, whenever needed.

Results: Pathology was found in 575 cases, including: mesenteric lymphadenitis (372), acute appendicitis (122), ileitis (60), ovarian mass (4), abscess (3), corpus luteum rupture (2), Crohn's disease (2), secondary intussusception (2), hydro-hematocolpos (2), ovarian torsion (1), inguinal ovarian torsion (1), undescended testis (1), cystic lymphangioma (1), omental infarction (1) **and duplication cyst (1).**

Conclusion: Sonography is an excellent, non-invasive, highly accurate, lacking ionizing radiation imaging modality for the evaluation of pediatric lower abdominal pain, enabling early and correct diagnosis and treatment of the various underlying pathologic conditions.





OP 007

CONTRAST ENHANCED ULTRASOUND IS USEFUL FOR IMAGING EMERGENCY SCROTAL PATHOLOGY

Pavlos Ampatzis, Demosthenes Cokkinos, Anastasia Anagnostopoulou, Alexandros Letsos, Christina Aslanidi, Sofia Tsolaki, Panagiotis Tserotas, Ekaterini Tavernaraki, Ioannis Kalogeropoulos
 Radiology Department, Evangelismos Hospital. Athens, Greece

Introduction

Emergency conditions affecting the scrotum are seen very often. Usually baseline unenhanced ultrasound is sufficient to answer the clinical question. In equivocal cases, Contrast Enhanced Ultrasound (CEUS) is used for setting a diagnosis when baseline unenhanced US cannot or for confirming its findings and increasing the examiner's confidence.

Purpose

To study the value of CEUS for imaging emergency conditions of the scrotum.

Materials and Methods

Retrospective review of 31 male patients aged 18-72 years scanned with emergency CEUS for emergency situations of the scrotum (acute pain or trauma). All patients were examined with CEUS after baseline non-enhanced US was performed for possible torsion (12 patients), scrotal trauma (9), infection (7) or infarct (3). The additional time for performing CEUS was recorded.

Results

CEUS confirmed baseline US findings in all 31 patients. Torsion was confirmed in 8 patients and ruled out in 4. Traumatic lesions in the testicles were confirmed in 6 patients and ruled out in 3. Infection or abscess in the testicles were confirmed in 5 patients and ruled out in 2. Infarct was confirmed in 2 patients and ruled out in 1. The additional time for performing CEUS was 7-12 min (median 9,5 min).

Conclusion

Emergency CEUS ultrasound for imaging scrotal pathology is easy and fast to perform. It can be used to confirm baseline US diagnosis and increase the examiner's confidence.





OP 008

ARE WE OVER-PERFORMING FAST ULTRASOUND OF THE ABDOMEN IN PATIENTS WITH NO INDICATION?

Christina Aslanidi, Demosthenes Cokkinos, Sofia Athanasiou, Pavlos Ampatzis, Panagiotis Petaloudis, Sarantis Georgakopoulos, Sofia Tsolaki, Eleni G Antypa, Ioannis Kalogeropoulos
 Radiology Department, Evangelismos Hospital. Athens, Greece

Introduction

Focused Assessment with Sonography in Trauma (FAST) ultrasound is the first imaging modality to be performed in patients with blunt abdominal trauma. It is aimed for the detection of free fluid suggestive of injury in the peritoneal, pericardial, and pleural cavities. However, its advantages (easy, fast, without radiation) often lead to possible over-performance.

Purpose

To study if patients referred for FAST abdominal ultrasound have an indication for this examination. To assess how often in these patients abdominal trauma is actually found and how often an intravenous catheter had been placed in the Emergency Department (ED), according to guidelines for traumatic cases. To measure the waiting time of these patients before the performance of FAST US.

Materials and Methods

Retrospective review of 612 patients scanned with emergency FAST abdominal ultrasound from January 1 to March 31, 2019. 458/612 patients (74.8%) had suffered trauma in the torso (chest, abdomen). 154/612 (25.2%) only complained of injuries in the extremities or the skull.

Results

In only 8 patients (1.3%) injuries of the solid abdominal organs were found. In another 6 patients (1%) other incidental findings of no traumatic nature were observed. Furthermore, in 182 patients (29.7%) no intravenous catheter had been placed in the ED. The waiting time of these patients was 0-58 min (median 36 min).

Conclusion

Emergency FAST abdominal ultrasound is being over-performed, due to referrals from clinicians that, in most cases, have no clinical indication. This is also proved by the fact that many of these patients do not have an intravenous catheter place in the ED, while often they have to wait for a long time for an examination that was actually not warranted. This over-performance results in waste of time and money for the patients and the hospital.





OP 009

CONTRAST ENHANCED ULTRASOUND IS USEFUL FOR IMAGING INFECTION, RUPTURE AND ABSCESES OF THE GALLBLADDER AND BILIARY TREE

Sofia Athanasiou, Demosthenes Cokkinos, Anastasia Anagnostopoulou, Alexandros Letsos, Panagiotis Petaloudis, Sarantis Georgakopoulos, Eleni G Antypa, Grigoris Skoufogiannis, Ioannis Kalogeropoulos
 Radiology Department, Evangelismos Hospital. Athens, Greece

Introduction

Contrast Enhanced Ultrasound (CEUS) is used for many indications in everyday practice, including imaging emergency pathology of the gallbladder and biliary tree. It is used for setting a diagnosis when baseline unenhanced US cannot or for confirming its findings and increasing the examiner's confidence.

Purpose

To study the value of CEUS for imaging emergency conditions of the gallbladder and biliary tree.

Materials and Methods

Retrospective review of 26 patients (15 men, 11 women, aged 21-89 years) scanned with emergency CEUS for signs and symptoms related to the gallbladder and/or biliary tree (right upper quadrant pain, jaundice, fever, elevated enzymes etc). All patients were examined with CEUS after baseline non-enhanced US suggested the presence of gallbladder intraluminal material for differentiation between sludge and neoplastic material (9 patients), gallbladder wall rupture for determining loss of wall integrity (8 patients), hepatic parenchyma infection/abscess for outline of their borders (5), echogenic material inside the biliary tree for differentiation between sludge and neoplastic material (3), gallbladder wall abscess for studying the lesion's borders (1). The additional time for performing CEUS was also estimated.

Results

CEUS confirmed baseline US findings in 17 patients and set a definitive diagnosis that was not possible on baseline scanning in 8 patients. The additional time for performing CEUS was 8-19 min (median 11.5 min).

Conclusion

Emergency CEUS ultrasound for imaging the gallbladder and the biliary tree is easy and fast to perform. It elucidates clinical questions, confirming baseline US diagnosis and increasing the examiner's confidence or setting a diagnosis which was not possible before the injection of the US contrast agent.





OP 010

CONTRAST ENHANCED ULTRASOUND MAY GIVE A SOLUTION FOR BOSNIAK CLASSIFICATION OF RENAL CYSTS WHEN CT OR MR CANNOT

Panagiotis Petaloudis, Demosthenes Cokkinos, Pavlos Ampatzis, Sofia Athanasiou, Christina Aslanidi, Eleni G Antypa, Sofia Tsolaki, Stylianos Benakis, Ioannis Kalogeropoulos
 Radiology Department, Evangelismos Hospital. Athens, Greece

Introduction

CT is the method of choice for Bosniak classification of renal cysts. Often MRI is also used for this task. In some cases cysts are not adequately characterised by either method and patients are referred for Contrast Enhanced Ultrasound (CEUS).

Purpose

To assess the value of CEUS for characterising renal cysts according to the Bosniak classification system. To study the number of cases where CT-MRI could not give a definitive answer and CEUS could.

Materials and Methods

Retrospective review of 36 cystic renal lesions seen in 34 patients (19 men-15 women, aged 18-85 years). In 21 cases, the patients also underwent CT and/or MRI. All lesions were characterised according to the Bosniak classification system as I, II, IIF, III or IV.

Results

The 36 lesions were classified according to the Bosniak system as follows: Bosniak I: 9 lesions, II: 7, IIF: 13, III: 4, IV: 3. In 17 of the 21 lesions where CT/MRI were also performed, there was agreement with CEUS. Four lesions were classified by CEUS in a higher category compared to CT/MRI, without however any clinical significance (IIF on CEUS vs II on CT/MRI). In 5 cases CT/MRI did not conclude in a definitive classification, but CEUS did: Bosniak I (2 cases), II (1), IIF (2).

Conclusion

CEUS is very useful for characterising cystic renal lesions according to the Bosniak classification system. It can be an alternative to CT, since it is not related with ionising radiation, while the US contrast agents can also be given in patients with renal insufficiency. CEUS can also be used in cases where CT/MRI may fail to answer the clinical question.





ABDOMEN PELVIS

OP 011

POSSIBILITIES OF MR DTI FOR THE PLANNING OF NEURO-SAVING OPERATIONS IN LOCAL PROSTATE CANCER

V.I. Kuplevatskiy, D. I. Kuplevatskaya, M. A. Cherkashin, N. A. Berezina

Diagnostic Treatment Centre of the International Institute Named after dr. Sergey Berezin, Russia

Introduction: MRI for detecting adenocarcinoma and assessing changes makes possible evaluation of focal tumors and correlation with the capsule thus shifting the percentage of cancer to minimal forms. MRI helps verification using MR-target or fusion biopsy. Accurate diagnosis makes possible to use SRT and neuro-sparing surgery. In order to choose a treatment method, it is vital to evaluate the ratio of the tumor node to the capsule and to evaluate nerve bundle locations.

Objective: Developing MRI studies for patients with verified cancer with DTI evaluation to assess neuro-sparing surgery options.

Materials and Methods: 63 patients with verified adenocarcinoma were examined within the capsule according to the MRI study. According to histology, carcinomas of the 3 + 4 Gleason (65%) prevailed. 21% corresponded to Gleason 4 + 3. 14% showed 4 + 4 Gleason tumor.

Results: At the first stage, the spatial prevalence of the tumor was estimated by PI-RADSv2: 11% of cases the tumor was located in the AZ segments; 14% in PZpm segments, 85% in PZpl segments. None of the foci exceeded 1.5 cm³. At the second stage, DTI was performed with an analysis of the relationship of the nerve bundles to the gland's tumor areas.

In all cases, MR DTI made it possible to estimate the ratio of the tumor to the adjacent nerve tracts. With the intimate arrangement of the node to the capsule and the proximity of the neural bundles, SRT was the method of choice (81%). In 19% of patients, the tumor site to nerve bundles ratio allowed a neuro-sparing prostatectomy to be performed.

Conclusion: MRI with DTI allows not only tumor site visualization in the gland structure and evaluation of the involvement of the capsule in the process, but also evaluation of the correlation of the tumor and nerve tracts, providing all the necessary information to select the optimal treatment strategy.





OP 012

INVESTIGATION OF PROSTATE CANCER DETECTION RATES OF UPGRADED PIRADS SCORE 4 ON PERIPHERAL ZONE AND COMPARISON OF PIRADSV2 AND PIRADSV2.1 CANCER DETECTION RATE

Ince Zuhail, Duvek Esin, Kartal Merve, Gulbiz Bakir, Baris Tunaci Atadan

Istanbul University Istanbul Medical Faculty Department of Radiology, Istanbul, Turkey

Introduction; To the PIRADS, dominant sequence for the peripheral zone (pz) is diffusion-weighted images (DWI). Lesions located on the pz receiving score 3 on DWI are upgraded to 4 by contrast enhancement.

Purpose; To compare the cancer detection rates of the score 3 and 4 with upgraded 4 on pz regarding v2 and v2.1.

Material and Methods: Between December 2015 and December 2018 104 patients with score 3, upgraded 4, 4 and 5 were re-evaluated retrospectively according to the PIRADSV2 and v2.1. Clinically significant prostate cancer detection rates of score 3, upgraded 4, 4 and 5 were revealed and compared among each sub-groups.

Results; The median age, PSA value, PSA density, volume of the patients were 64 (range = 53-74), 11ng / ml (0.2-200), 0.2 ng / ml / cc (0.005-2), 47 cc (13-196). 104 patients had 142 lesions. The mean diameter of 142 lesions was 10 mm (2-52). To PIRADSV2 there were 28 lesions with score 3, 30 lesions with upgraded score 4, 68 lesions with score 4 and 16 lesions with score 5. Clinically significant prostate cancer detection rates of PIRADSV2 score 3, upgraded 4, 4 and 5 were 10% (3/28), 16.6% (5/30), 42.6% (29/68), 68.7% (11/16), respectively. To PIRADSV2.1, there were 33 lesions with score 3, 34 lesions with score upgraded 4, 59 lesions with score 4, and 16 lesions with score 5. Clinically significant prostate cancer detection rates of PIRADSV2.1 score 3, upgraded 4, 4 and 5 were 0% (0/33), 14.7% (5/34), 54.2% (32/59), 68.7% (11/16), respectively.

Conclusion; Clinically significant prostate cancer detection rates were closer between the lesions with score 3 and upgraded 4, whereas the clinically significant prostate cancer detection rates of lesions with score 4 were significantly higher. Furthermore, cancer detection rates of PIRADSV2.1 score 4 were significantly higher than PIRADSV2 score 4.





OP 013

COMPARISON OF MULTIPARAMETRIC PROSTATE MRI AND PSMA GALLIUM PET-CT LYMPH NODE INVOLVEMENT AND EXTRAPROSTATIC EXTENSION RESULTS IN CASES WITH RADICAL PROSTATECTOMY, FUSION PSMA PET-MRI CONTRIBUTION TO DIAGNOSIS RESEARCH

Guner a. Levent Saglican Yesim ,Tuna Mustafa Bilal,Ozisik Ozan,Kural Ali Riza,Karaarslan Ercan Acibadem Mehmet Ali Aydinlar University, Istanbul Turkey

Introduction

Prostate cancer is a major health problem in the male population. Magnetic resonance imaging (MRI) and ga68Ga-PSMA (prostate-specific membrane antigen) PET CT are noninvasive modalities used for the diagnosis and treatment planning of prostate cancer.

Purpose

The aim of our study was to compare the efficacy of PET and MRI in detecting lymph node involvement and extraprostatic extension in patients with clinically significant prostate cancer who underwent radical prostatectomy; also to investigate the contribution of PSMA PET-MR fusion images to the diagnosis.

Materials and Methods

Thirty patients who underwent radical prostatectomy between June 2015 and April 2018 were included in the study. Data were analyzed with two proportion z test. P value < 0.05 was considered for statistical significance.

Results

PET had high sensitivity and low specificity compared with MRI in detecting extracapsular invasion. The specificity of MRI and PET in demonstrating metastatic lymph nodes was the same but MRI sensitivity was higher.

Conclusion

Fusion PSMA PET MRI increased the sensitivity of the lymph node identification according to PSMA PET CT.

Key words: ⁶⁸Ga-PSMA PET/BT, PSMA PET MRI, Multiparametric Prostate MRI, Prostate Cancer



**OP 014****ROLE OF INTRAVOXEL INCOHERENT MOTION MAGNETIC RESONANCE IMAGING IN DIFFERENTIAL DIAGNOSIS OF CHRONIC PROSTATITIS AND PROSTATE CANCER**

Kulali Fatma, Huseyinkahyaoglu Merve, Kulali Safak Firat, Kucuk Eyup Veli, Semiz-Oysu Aslihan, Bukte Yasar

Radiology Department, University of Health Sciences Umraniye Training and Research Hospital, Istanbul Turkey

Purpose:

Our purpose was to evaluate the role of intravoxel incoherent motion (IVIM) magnetic resonance imaging (MRI) parameters in differential diagnosis of chronic prostatitis and prostate cancer.

Materials and Methods:

A total of 36 lesions in 22 patients who had suspicion of prostate cancer and prostate IVIM-MRI examinations with a mean age of 62 ± 6 (SD) were enrolled in this retrospective study. Pre-interventional IVIM-MRI examinations were reviewed by two radiologists. Quantitative IVIM-MRI findings were statistically analyzed according to histopathological results.

Results:

Of 36 prostatic lesions, 13 were prostate cancers, four were atypical small acinus proliferations and 19 were lesions due to chronic prostatitis. The mean size of lesion was 13.7 ± 4.8 (SD) mm. Among 13 prostate cancers, nine were in peripheral zone and four located in transitional zone. Most of false positive lesions (14/19, 73.6%) were seen in transitional zone. The sensitivity, specificity, and accuracy of IVIM-MRI findings in the diagnosis of prostate cancer was 100%, 50%, and 62.7%, respectively. The diagnostic accuracy (73.7%) was higher in peripheral zone lesions. There was no significant difference about mean apparent diffusion coefficient (ADC), true diffusion coefficient (DC), pseudo-diffusion coefficient (D^*) and perfusion fraction (f) parameters between prostate cancer and chronic prostatitis (all $p > 0.05$).

Conclusion:

IVIM MRI can be helpful for depiction of lesion and guiding for biopsy. The awareness of possibility of overlapping findings in chronic prostatitis and prostate cancer especially in transitional zone is important. Clinical evaluation combined with radiological findings is necessary to make accurate diagnosis.

Keywords: chronic prostatitis, intravoxel incoherent motion, magnetic resonance imaging, prostate cancer





OP 015

VESICOVAGINAL REFLUX MIMICKING OBSTRUCTIVE HYDROCOLPOS: A FORGOTTEN CAUSE OF DIURNAL INCONTINENCE IN PREPUBERTAL GIRLS

Daniil G., Arvaniti M., Katsimba D., Ouroumidou K., Delianidou A., Kaitartzis C.

Radiology Department of General Hospital of Thessaloniki "G. Gennimatas", Greece

Introduction: Vesicovaginal reflux (VVR) may be the cause of incontinence in 12–15% of prepubertal girls with urine leakage. The diagnosis may be difficult if this possibility is not taken into account, requiring a multitude of diagnostic tests and some paediatric radiologists are not familiar enough with VVR.

Purpose: To describe two cases of hydrocolpos that proved to be due to VVR.

Materials and methods: An overweight 9-year-old girl, presented with symptoms of diurnal incontinence consisting of post void dribbling without enuresis. She also reported occasional urgency and 3–4 yearly episodes of afebrile urinary tract infection. Imaging evaluation included US and VCUg. A 7-year-old girl presented with RLQ pain. Lower abdominal US was performed, to evaluate the genitals and the appendix.

Results: In the 1st case, vaginal distension sonographically identical to obstructive hydrocolpos was observed. Fluoroscopic studies showed VVR. No anatomic abnormalities were identified. In the 2nd case, an inflamed appendix was found. Vaginal distension sonographically identical to obstructive hydrocolpos was also noted. Postvoid sonography allowed proper diagnosis.

Conclusion: Vesicovaginal reflux can produce vaginal collection that is sonographically identical to obstructive hydrocolpos. It is important to differentiate this functional disorder presenting as hydrocolpos from other obstructive causes of hydrocolpos which require surgical management. Sonographic examination with a distended bladder followed by a postvoid evaluation easily provides the correct diagnosis of VVR by demonstrating disappearance of the vaginal collection. Management includes behavioral modifications, toilet training and parental education.





OP 016

PROGNOSTIC SIGNIFICANCE OF CT DETERMINED SARCOPENIA IN PATIENTS WITH METASTATIC PROSTATE CANCER

Gulpinar Basak

Ankara University School of Medicine, Sina Hospital, Department of Radiology, Ankara Turkey

Introduction: The prevalence of prostate cancer is increasing worldwide. Main treatments for metastatic prostate cancer are androgen-deprivation therapy and taxane-based chemotherapy. Due to the indolent nature of prostate cancer, these treatments tend to be long-lasting and long-term chemotherapy is closely associated with muscle loss. Sarcopenia, defined as decreased skeletal muscle mass is associated with poor prognosis in various solid tumors. The purpose of this study was to determine prognostic role of sarcopenia in patients with metastatic prostate disease.

Materials-Methods: Between January 2015 and February 2019 patients with metastatic prostate cancer were extracted from our database. 60 patients with castration-resistant prostate cancer who underwent docetaxel chemotherapy were enrolled in the study. The cross sectional area at the level of third lumbar vertebra (L3) level was measured using abdominal computed tomography (CT) scans. Sarcopenia was assessed using L3 skeletal muscle index (SMI, cm^2/m^2). The impact of sarcopenia on patients prognosis and overall survival was statistically evaluated. ROC analysis was performed to determine AUC, cut-off, sensitivity and specificity values for discrimination of poor and good prognosis group.

Results: Statistical analysis showed that L3 skeletal muscle index was significantly lower in the poor prognostic group ($p < 0.001$). The cut-off value of L3 muscle index for differentiating poor prognostic group was 55.1 with a specificity of %89. Sarcopenia is associated with poor prognosis and shorter survival time.

Conclusion: Sarcopenia, as determined by abdomen CT, can be used to predict poor prognosis and high mortality risk in patients with metastatic prostate disease.





OP 017

MAGNETIC RESONANCE PROSTATE TRACTOGRAPHY FOR THE PLANNING NEURO-SAVING SURGERY

Vladimir Kuplevatsky, Daria Kuplevatskaya, Mikhail Cherkashin, Natalia Berezina

Medical Institute n.a. Berezin Sergey, Russia.

Introduction: Detailed prostate visualization allows to accurately take material for histological verification using MR-target biopsy or fusion biopsy. Accurate diagnostics allows the use of more benign treatments for non-disabling patients, such as stereotactic radiation therapy, proton therapy, and neuro-sparing surgery.

Objective: To develop an algorithm for MRI studies for patients with verified prostate cancer. To assess the possibility of using MR prostate tractography for neuro-sparing surgery decision.

Materials and Methods: 63 patients with verified adenocarcinoma were examined within the capsule according to the MRI study. According to histology, carcinomas of the 3 + 4 Glisson (65%) prevailed. In 21% the tumor corresponded to Glisson 4 + 3. In 14% there was a 4 + 4 Glisson tumor.

Results: At the first stage, the spatial prevalence of the tumor was estimated by PI-RADSv2: 11% of cases the tumor was located in the AZ segments; 14% in PZpm segments, 85% in PZpl segments. The size of the foci in all cases did not exceed 1.5 cm³. At the second stage, MR tractography was performed with an analysis of the relationship of the nerve bundles to the tumor areas of the gland. In all cases, MR tractography made it possible to estimate the ratio of the tumor to the adjacent nerve tracts. With the intimate arrangement of the node to the capsule and the proximity of the neural bundles, stereotactic radiation therapy was the method of choice (81%). In 19% of patients, the ratio of the tumor site to the nerve bundles allowed a neuro-sparing prostatectomy to be performed.

Conclusion: The prostate gland in combination with tractography allows not only to visualize the tumor site in the gland structure and to evaluate the involvement of the capsule in the process, but also to evaluate the correlation of the tumor and nerve tracts, which gives the full necessary information to the attending physician to select the optimal treatment strategy.

DISCLOSURE Authors disclose absence of any conflicts of interest





OP 018

TWO-STAGE, UTERUS SPARING SURGERY IN THE MANAGEMENT OF FIBROID EXPULSION AFTER UTERINE ARTERY EMBOLIZATION (UAE)

Ambrus Tóth 1; Zoltán Tömösváry 2, Ildikó Kalina 1, Dóra Kozics 1, Nándor Ács 2, Viktor Bérczi 1

1 Department of Radiology, Semmelweis University, Budapest, Hungary

2 2nd Department of Obstetrics and Gynaecology, Semmelweis University, Budapest, Hungary

Introduction: Uterine artery embolization (UAE) is an effective treatment method for uterine fibroids with a low rate of complications, fibroid expulsion being one of them. Obstruction of the cervical canal can lead to infectious/septic complications, possibly leading to acute hysterectomy.

Purpose: To report a case of fibroid expulsion with uterine sparing approach with successful preservation of the uterus.

Materials and methods: A 45-year-old female patient with a known uterine fibroid underwent UAE in our institution because of one symptomatic large intramural uterine fibroid. The procedure was technically successful and without any complications. Two months after UAE, the patient presented with odorous discharge. Gynecological examination showed a necrotizing mass protruding through the cervix.

Results: The mass has been removed and antibiotics were given to the patient who showed clinical recovery. A small fraction of the fibroid was deliberately left in place to avoid hysterectomy. Histology confirmed that it was a fibroid. Ten months after UAE the patient was admitted for the elective removal of the remaining fibroid tissue, the operation was successful, the uterus has been saved. The histological examination after the second operation, however, showed endometrial polyp. The patient had no symptoms at the last follow-up. The literature on fibroid expulsion and possible treatments will be discussed.

Conclusion: Fibroid expulsion can be managed effectively with two-staged surgery in selected cases often leading to the preservation of the uterus.



**OP 019****DOES WHOLE-BODY PET / MR IMAGING OF ABDOMINAL CANCERS OFFER ADDITIONAL FINDINGS COMPARED TO CONTRAST-ENHANCED CT**

Gur Seray Gizem(1), MD, Sokmen Bedriye Koyuncu(1), MD

1.Demiroglu Bilim University Florence Nightingale Hospital, Radiology Department, Istanbul/Turkey

Introduction and purpose:

In Positron Emission Tomography / Magnetic Resonance Imaging (PET / MRI), the radiation dose received by the patient is less than computed tomography (CT) or PET / CT. This is not only related to the use of MRI instead of CT, but also the introduction of solid-state PET detectors associated with the ability to generate sufficient images with lower Fluoro Deoxy Glucose (FDG) activity(1,2). As a result, both CT and FDG induced radiation dose will be decreased. Therefore, PET/MRI usage is increasing in oncology patients. In this study, we aimed to compare the diagnostic value of Contrast enhanced CT and PET/MRI in patients with abdominal malignancy.

Materials and Methods:

Between January 2016 and May 2019, 77 patients with intraabdominal primary tumors with PET/MRI and contrast enhanced CT examination were screened with retrospectively. PET/MRI and contrast-enhanced CT images of the patients were evaluated by two independent radiologist and common consensus was obtained. Histopathological findings were taken as reference. Diagnostic value of two different modalities for primary tumor, metastatic focus and lymphadenopathy were compared.

Results:

PET /MRI and CT , respectively, regardless of the histology of the primary tumor, 100% of primary tumors(77 patients) and 98,7 % of primary tumors (76 patients); 100% of lymph node involvement(24 patients) and 91,6% of lymph node involvement(22 patients), 100% of distant metastases (36 patients) 97,2 % of distant metastases (35 patients) has detected. In addition, it provided additional information in %6,6 (1/15 patients)of patients in detecting multiple foci in hepatocellular carcinoma, regardless of our aim. In addition, PET/MRI detected undetectable brain and extremity metastases in 19.4 % (7/36 patients)of patients compared with CT.

Conclusion:

The biggest advantage of PET/MRI is the low ionizing radiation. PET/MRI is superior to CT in lymph node and distant metastasis detection.





OP 020

THE APPROPRIATE USE OF CONVENTIONAL ABDOMINAL RADIOGRAPHS AND ITS USEFULNESS IN NON-TRAUMATIC ACUTE ABDOMEN PATIENTS

Sornsupha Limchareon M.D.¹, Alisara Wongsuttillert, M.D.¹, Chuenrutai Yeekian, Ph.D.², Lalitphan Nimmankiatkul, M.D.²

¹Division of Radiology and Nuclear Medicine, Faculty of Medicine, Burapha University, Chonburi, Thailand ²Somdej Memorial Hospital, Chonburi, Thailand

Abstract:

Introduction: Conventional abdominal radiographs (CAR) are often ordered in patients presented with acute abdominal pain.

Purpose: The purpose of this study was to investigate the appropriate use of CAR and its usefulness.

Materials and Methods: Adult patients who had CAR ordered from Emergency Department between 1st September and 31st October 2018 were retrospectively reviewed. Patients' demographics, indications for CAR, CAR results, further imaging, and its results, and final diagnoses were assessed. The appropriate or inappropriate use of CAR was stratified. Comparison between the appropriate group and inappropriate group was made.

Results: There were 154 CAR studies, M:F = 57:97, mean age 48.3 years (ranged 15-88 years). 33.8% of CAR was considered appropriate. Of the 154 examinations, 17 (11%), 73(47%) and 64(42%) were reported positive, negative and non-diagnostic results by CAR respectively. Comparison between appropriate and inappropriate groups, number of cases (χ^2 goodness of fits; $\chi^2_{1} = 16.234$, $P < 0.001$), CAR negative results (χ^2 goodness of fits; $\chi^2_{1} = 11.521$, $P = 0.001$), CAR non-diagnostic result (χ^2 goodness of fits; $\chi^2_{1} = 10.563$, $P = 0.002$) and negative further imaging results (χ^2 goodness of fits; $\chi^2_{1} = 6.400$, $P = 0.021$) were significantly different. There was no statistical difference in a number of further imaging between both groups ($p = 0.291$). The common findings of positive results which had no further imaging were bowel obstruction ($n=6$), followed by bowel perforation ($n=3$). 12 out of 73 (16.4%) negative CAR results and 11 out of 64 (17%) of non-diagnostic results had positive findings from further imaging.

Conclusion: CAR yields limited value in acute abdominal patients. More precise imaging is often required. The use of CAR causes delayed management, added cost and radiation dose. Strict to the protocols, staff education and internal audit should be performed in the hospital.





OP 021

COMPARISON OF HETEROGENEITY INDEX AND SUVMAX FOR LIVER METASTASES IN PET-MRI

Sever Ibrahim Halil, Ozkul Bahattin

Sisli Florence Nightingale Hospital Radiology Unit, Demiroglu Bilim University, Istanbul , Turkey

Introduction

The liver is highly susceptible to the development of metastases. Discerning malignant from normal liver tissue is essential for patient management.

Purpose

We aimed to compare the apparent diffusion coefficient (ADC) heterogeneity index and standard uptake value (SUVmax) values measured on PET-MRI in differentiating liver metastases (LM) from normal liver parenchyma (NLP).

Materials and Methods

25 liver metastases of 17 oncology patients who underwent PET-MRI between January 2018 and March 2019 were retrospectively analyzed. ADC and SUV measurements were measured by transferring them to the workstation (Syngo Via; Siemens Healthcare, Erlangen, Germany). PET-MRI protocol on 3T device (Biograph mMR. Siemens Healthcare GmbH, Erlangen, Germany) was composed of; diffusion-weighted imaging for upper abdomen ($b = 0 \text{ s} / \text{mm}^2$ and $800 \text{ s} / \text{mm}^2$), axial plan T1-weighted Turbo Flash and coronal T2-weighted HASTE sequence , axial contrast 3D fat printed VIBE and whole body axial late contrast series. Tissue heterogeneity was calculated using the variance coefficient (ADC_{cv}) of ADC. ADC_{mean}, ADC_{min} and SUVmax were measured quantitatively. The difference between NLP and LM values was analyzed by Mann-Whitney U test. The correlation between the values was analyzed by Spearman correlation test. ROC analysis was performed to evaluate the diagnostic performance of the parameters.

Results

There was a positive and high significant correlation between ADC_{cv} and SUVmax in liver metastases ($r = 0.803$). There was a moderate negative correlation between ADC_{mean} and ADC_{min} and SUVmax ($r = -0.545$, $r = -0.570$, respectively). When the ADC_{cv} cut off value was determined as 0.15, the sensitivity was 86%, the specificity was 100%; and when the SUVmax was determined as 3.75, the sensitivity was 95% and the specificity was 100%.

Conclusion

ADC_{cv} heterogeneity index is a potential quantitative biomarker that correlates well with SUVmax measured on PET-MRI in differentiating LM and NLP.





ABDOMEN- GASTROINTESTINAL

OP 033

MRI-BASED TREATMENT RESPONSE ASSESSMENT FOR LIVER OLIGOMETASTASIS AFTER SBR

Kuplevatskaya D.I., 1, Vorobyov N.A.2, Martinova N.I.3, Kuplevatskiy V.I.4, Cherkashin M.A.5, Berezina N.A.6

1. MD, PhD, Chief of Radiology Department, Medical Institute n.a. Dr. Berezin Sergey, Saint-Petersburg, Russia.
2. MD, PhD, Chief of Radiotherapy Department, Medical Institute n.a. Dr. Berezin Sergey, Saint-Petersburg, Russia.
3. MD radiotherapy, Radiotherapy Department, Medical Institute n.a. Dr. Berezin Sergey, Saint-Petersburg, Russia.
4. MD radiology, Medical Institute n.a. Dr. Berezin Sergey, Saint-Petersburg, Russia.
5. MD, Associate Chief Medical Officer, Medical Institute n.a. Dr. Berezin Sergey, Saint-Petersburg, Russia.
6. MD, PhD, Chief Medical Officer, Medical Institute n.a. Dr. Berezin Sergey, Saint-Petersburg, Russia.

Introduction: the stereotactic body radiation therapy (SBRT) for unresectable liver tumors is effective method of treatment, but the criteria of the tumor response assessment for SBRT are not enough developed yet.

Purpose of the study:

To develop mpMRI criteria for SBRT treatment response assessment in patients with liver oligometastases.

Materials and methods:

In our study 39 patients with liver metastasis, treated by SBRT were included. Abdominal MRI (1.5T scanner) were performed before radiation and after 1, 4, 6, 12 months. Analysis included target measurement by RECIST 1.1 criteria, necrotic area volume measurement by "Segmentation volume" (OleaSphere V2.3 SP1), DWI, dynamic contrast enhancement and parenchymal postradiation changes assessment.

Results: partial tumor response after SBRT was revealed in 62% in month 1th and in 49% in months 4th. Size decreasing by 30% or more was maximal in 76.9% patients (month 1st) and maximal tumor necrosis (25 to 50% lesions) was detected in month 4.

In 6 and 12 months local control was observed in 93% and 87% of cases. Necrotic changes (more than 75% of target volume) were revealed in 61.2% of patients. Complete tumor response after 12 months of SBRT was detected in 48% of patients.

Conclusion: Multiparametric MRI allows to assess morphological characteristics and functional status of radiated metastases and liver parenchyma after SBRT. Complex imaging support radiation oncologist with clear treatment response assessment, and is a helpful tool for timely treatment strategy changing.





OP 034

IMAGING FEATURES OF MULTICENTRIC PANCREATIC TUMORS:A SINGLE CENTRE EXPERIENCE

Mitrovic Milica, Djuric-Stefanovic Aleksandra, Jankovic Aleksandra, Djikic Rom Aleksandra, Lazic Ljubica, Grubor Nikica, Knezevic Djordje, Radenkovic Dejan, Ninic Aleksandar, Ceranic Miljan, Kovac Jelena
First Surgical Clinic , Clinical Centre of Serbia

Introduction: Multicentric pancreatic neoplasms are not frequent finding and require precise diagnostic approach followed by radical surgery. Since multiple pancreatic masses are located in different parts of the pancreas, a total pancreatectomy (TP) is the only surgical treatment for these patients.

Purpose: To describe CT and MRI imaging features of multicentric pancreatic tumors, including multifocal intraductal papillary mucinous neoplasm, multifocal neuroendocrine tumors and pancreatic adenocarcinoma, and metastases of renal cell carcinoma.

Materials and Methods: Fifteen patients with multifocal pancreatic tumors who underwent total pancreatectomy in the period from January 2015 until April 2019 were included in the study. All patients underwent CT and/or MRI examination, followed by radical surgery.

Results: The most common indication for total pancreatectomy was intraductal papillary mucinous neoplasm (8 patients, 53,3%). Two of them had malignant form of mixed type of IPMN, while mixed type with high grade displasia was found in 5 patients. Intestinal type of adenocarcinoma was found in one case of main duct IPMN. In three patients (20%), reason for TP was multicentric neuroendocrine tumor, while bicentric pancreatic adenocarcinoma was diagnosed and histopathologically confirmed in 3 cases (20%). One patient (6,7%) had multiple metastases of renal cell carcinoma, ten years after right radical nephrectomy. There was no perioperative mortality.

Conclusion: Pancreatic neoplasms usually arise as a single mass. Since multicentricity of pancreatic tumors is exceptionally rare it is of great clinical importance to correctly identify these lesions on preoperative imaging which is necessary for appropriate planning of surgical treatment.





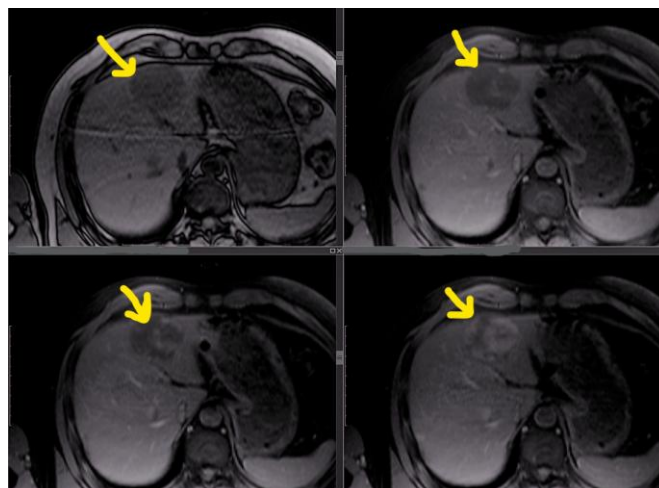
OP 035

INVESTIGATION OF THE DIAGNOSTIC PERFORMANCE OF LIRADS (THE LIVER IMAGING REPORTING AND DATA SYSTEM) IN LIVER PATHOLOGIES

Guenir Deniz, Tasar Mustafa, Bozlar Ugur, Arda Kemal Niyazi, Sanal Hatice Tuba, Ercin Cemal Nuri, Gunal Armagan

Gulhane Egitim Ve Arastirma Hastanesi. Istanbul, Turkey

Introduction: Hepatocellular carcinoma (HCC) is the most common primary malignant tumor of the liver. Screening methods have been developed to reduce mortality in patients at risk for HCC, and early detection allows for curative treatment options. The aim of LIRADS was to provide standardization of reports and to better manage lesion follow-up. **Purpose:** In this study, our aim is to determine the interobserver compatibility of LIRADS reporting system and to determine the validity criteria. **Materials and Methods:** Our study was single-center and retrospectively. 94 CT and 41 MR examinations of 135 cases were evaluated by two observers according to the LIRADS reporting system. The interobserver agreement and correlation of the LIRADS reporting system and its major features were assessed by Kendall's sequential correlation analysis and Cohen's analysis. Sensitivity, specificity, positive and negative predictive values and accuracy values were calculated for 16 cases with pathologic diagnosis. **Results:** Correlation between all LIRADS categories was found to be Kendall Tau b and Cohen Kappa coefficients were 0.898 and 0.791, respectively. In the LR-1 and LR-5 categories, while compliance was higher, the compliance for the LR-2 category was lower. The LIRADS reporting system of the major characteristics of the arterial enhancement, washout, pseudocapsul and tumor within lumen of vein, the coefficients of Kendall tau-b were determined tau-b 0.785, tau-b 0.755, tau-b 0.542 and tau-b 0.820, respectively. Sensitivity, specificity, positive predictive value, negative predictive value, accuracy rates were calculated for observer one were %100, %33.3, 86.6%, %100 and %87.5, and observer two %100, %66.6, %92.8, %100 and %93.75, respectively. **Conclusion:** Interobserver compliance and sensitivity of the LIRADS reporting system is high. We believe that it will increase accuracy and consistency after evaluation of LR-1 / LR-2 and LR-4 / LR-5 groups by merging.





OP 036

HEPATOBIILIARY CONTRAST AGENTS: CHARACTERIZATION OF FOCAL LIVER LESIONS

Papaioannou S, Sotiriadou A, Rigkas A, Giataganas G.
 General Hospital Papageorgiou, Thessaloniki, Greece

Introduction:

There are two types of contrast media used in MRI that are useful when imaging the liver. The first is composed of purely extracellular agents and the other of hepatobiliary agents. The latest have properties of extracellular agents, but also have affinity for hepatocytes.

Purpose:

The purpose of this study is to demonstrate the role of hepatobiliary specific contrast agents in characterization of focal liver lesions.

Material and methods

We present 26 patients examined the last year. All of them had a noncharacterized liver lesion, appeared in MRI after intravenous administration of extracellular agent. They underwent contrast enhanced hepatic MRI after injection of 10 mL hepatobiliary agent at 3 TESLA MRI. We evaluated arterial phase (25 sec after administration), portal venous (65sec), venous phase (120sec) and hepatobiliary phase (10 minutes and 20 minutes after administration) at axial fat-suppressed T1-weighted GRE.

Results

At 11 of them focal nodular hyperplasia was diagnosed, in 5 hemangioma, in 3 adenoma, in 1 simple cyst and in 4 hepatocellular carcinoma was the final diagnosis. In two of our patients we were not able to distinguish among hemangioma and adenoma.

Conclusion:

Hepatobiliary offers advantages for the imaging of liver lesions including HCC, fibromedullar HCC, FNH and adenoma and the management of those entities.





OP 037

PARTIAL INTERCOSTAL HERNIATION OF THE LIVER, A CASE REPORT

Antonio Gligorievski, Ivan Nevcev

University Clinic for Surgical Diseases "St. Naum Ohridski" Skopje, North Macedonia

Introduction: An intercostal hernia, defined as an acquired herniation of abdominal contents through disrupted intercostal muscles, is a rarely reported entity, but extremely rare is liver herniation. Liver herniation through the intercostal defect or through the lateral abdominal wall usually is incisional. Incisional herniation of the liver usually occurs 2 to 3 years after the previous operation of the abdomen which consequently leads to weakness of the abdominal wall.

Case report: We present an extremely rare case of an intercostal incisional hernia of the right lobe of the liver, segment V between 11th and 12th rib due to preceding lumbar incision for tumor nephrectomy. Therefore there is a weakness in the intercostal space between 11th and 12th rib at the right midaxillary line through which the herniation of the right lobe of the liver. A CT of the abdomen after an intravenous contrast application, arterial and venous phase was performed to exclude the incarceration of the herniated portion of the liver.

Discussion: The intercostal incisional hernia is a delayed complication of abdominal surgery. They can occur anywhere on the abdominal wall and frequently encountered in the vertical than in transverse incisions. Typically, incisional hernia manifest during the first months after surgery but it can occur later. Herniation of the liver through the intercostal defect is a rare condition and usually related to previous major surgery of the abdomen. Due to its rarity, it is, and diagnostic and therapeutic challenge. Abdominal incisional hernia in the intercostal region is rare and therefore easily overlooked.

Conclusion: We can conclude that there is a connection between liver herniation in the intercostal space with a previously performed surgery on the abdomen. CT is the method of choice for diagnosis of liver herniation through the intercostal defect.





OP 038

EVALUATION OF POSSIBLE SUBCLINIC KIDNEY DYSFUNCTION WITH T1 MAPPING MRI SEQUENCE IN CHRONIC VIRAL HEPATITIS

Ozkok Sercin

Istanbul Medeniyet University Goztepe Training and Research Hospital

INTRODUCTION: Functional impairment of kidneys can be observed in chronic liver disease without structural changes.

PURPOSE: The aim of this study was to evaluate the efficiency of MRI- T1 mapping method of detecting renal dysfunction in early stage without clinical findings in patients with chronic viral hepatitis.

MATERIALS AND METHODS: The patients diagnosed chronic viral hepatitis by liver tissue sampling performed Native MOLLI T1 sequence in axial and coronal planes. The T1 mapping value was calculated for each kidney in upper, middle and lower pole of cortex and medulla automatically. Liver and kidney function tests revealed from hospital data.

RESULTS : A total of 45 patients were included in the study evaluated between april 2016 and january 2017. 23 patients (45 ± 13 years old) had viral hepatitis B, 11 patients (48 ± 18 years old) had viral hepatitis. There were 11 patients (40 ± 8 years old) in the control group. There was no significant difference between the ages ($p = 0.40$). When the mean T1 mapping value of cortex evaluated there was no statistically significant difference between the chronic hepatitis group and the control group (1204 ± 199 msec vs. 1169 ± 132 ms, $p = 0.59$). The mean medullary T1 value of the right kidney was significantly higher in the chronic hepatitis group than control group (1612 ± 161 msec, 1473 ± 103 msec, $p = 0.002$). When the renal and medullary T1 mapping values of hepatitis B and hepatitis C patients were compared, no significant difference was found between them. And there was no correlation between creatinine levels and renal-cortical T1 values in chronic hepatitis patients.

CONCLUSION: In patients with chronic viral hepatitis, T1 mapping may not be sufficient to demonstrate subclinical renal dysfunction. These results should be confirmed by further studies in larger study groups.





OP 039

COLORECTAL CANCER - MDCT COLONOGRAPHY - VIRTUAL COLONOSCOPY 10 YEARS EXPERIENCES

Daskalov Blagoja, Daskalov D., C- Radulovska J., Petanovska N.

Skopje, R. North Macedonia

Introduction

Colorectal cancer is the third. the most common diagnosed malignancy in people and the second leading cause of death from malignancy.

The incidence of colorectal cancer increases sharply with age, 25per 100,000 to 45-50g. 300per 100 000 - 75g.

Colorectal cancer is equally common in men and women, and rectal more in men.

Early diagnosis and TNM staging are the basis for effective therapy and increases the chance of survival.

MDCT colonography- Virtual colonoscopy represents a diagnostic procedure review and analysis of the inside of the colon with so-called "travel through it."

All patients with symptoms suspected of colorectal malignancy should undergo scrutiny on MDCT on the abdomen and bowel.

1 of every 200 patients in the routine MDCT of abdomen, MDKT colonography or "virtual colonoscopy" as routine, are with diagnosis of malignant changes, intra or extracolonal. *

Materials and Methods

This diagnostic procedure is possible by applying the latest MDCT-MSCT systems and software solutions

Medical technology leadership, represent, recent generations of multidetektors - multislice computer systems, MDKT - MSCT.in our case 16 and 128sl

MDCT colonografijata, axial sections of 1mm., are the basis for reconstructive analysis of colon in many dimensions.

The complete analysis is carried out on PS-Work station.

Risks

Perforation - 1/2000 p.

Effective radiation dose

MDCT colonografija - 8 mSv (ranging from 1.8 - 15 mSv) *)

Possible allergic reactions to medications used.

Conclusion

In our 10-year experience, a series of 2000 patients received values of detection of colorectal cancer with sensitivity and specificity > 94%, with histopathological verification. - Colonoscopic and postoperatively.





OP 040

COMPARING PLAIN FILMS AND ABDOMINAL CTs IN THE DETERMINATION OF INTESTINAL OBSTRUCTION LEVELS

Erturk Sukru Mehmet , Uysal Ibrahim

Devlet Hastanesi Ultrason 1 Numaralu Oda, Istanbul Turkey

Objective

Intestinal obstructions are common surgical emergencies that demand early diagnosis. Obstruction levels and causes are important for surgical treatment of intestinal obstructions. Abdominal CTs and plain films are utilized for diagnostic work-up of intestinal obstructions. In our study, we retrospectively analyzed the agreement of plain films and abdominal CTs in the determination of obstruction levels.

Materials And Methods

In this study, we included 315 patients who get a diagnosis of intestinal obstruction at Sisli Hamidiye Etfal Research and Training Hospital between November 2015- October 2018. We retrospectively compared intestinal obstruction levels at plain films which were interpreted independently by two readers with intestinal obstruction levels at abdominal CTs that were interpreted by our study coordinator. The agreement between abdominal CTs and plain films were analyzed using kappa statistics.

Results

The mean age of the patients in this study was 56 and standard deviation is 18,27. This study group has included 315 patients and 182 (%58) of them is men and 133 (%42) of them is women. The agreement between reader 1 and reader 2 in interpreting plain films was almost perfect and statistically significant ($\kappa=0,813$; $p < 0,0001$). The agreement of reader 1 with abdominal CT was substantial and statistically significant ($\kappa=0,667$; $p < 0,0001$). The agreement of reader 2 with abdominal CT was substantial and statistically significant ($\kappa=0,655$; $p < 0,0001$).

Conclusion

In this present study, we found substantial and statistically significant agreement in determining the level of intestinal obstruction between plain films and abdominal CTs for both readers. Plain films have advantages such as cost-effectivity and low radiation doses. They can be fairly utilized in the diagnostic work-up of intestinal obstructions. who has a pre-diagnosis of bowel obstruction and why plain films are so important at following the patients have intestinal obstruction.





OP 041

RADIOLOGICAL MANAGEMENT OF APPENDICITIS TREATMENT

Tuney Davut ,Yegen Cumhuri Demirbas Baha Tolga Ilgin Can
 Marmara University Research and Application Hospital, Istanbul Turkey

Background and purpose: Acute appendicitis is the most common cause of acute abdomen requiring surgical treatment. Although standard treatment is surgery there is also a treatment option with antibiotics emerged in recent years. In this study, our aim was to determine whether CT findings in patients diagnosed with acute appendicitis should be used for selection of the treatment.

Materials and Methods: A total of 138 patients who underwent to abdominal CT and were diagnosed with acute appendicitis, were evaluated retrospectively. Of these patients, 60 received medical treatment and 78 received surgical treatment. CT findings of medical and surgical treatment groups were compared with chi-square and Mann Whitney U tests. Backwards binary logistic regression was applied, in which the outcome of surgical or medical treatment was dependent variable and variables obtained from CT were independent variables. Appendiceal diameter and appendicitis index values were evaluated with nonparametric ROC curves to determine the way type of treatment.

Results: Appendix diameter($p=0.0001$), diameter index($p<0.0001$), adjacent organ findings($p=0.041$), periappendiceal fat stranding severity($p=0.002$), the appendicitis index($p<0.0001$), presence of appendicolith($p=0.001$) and intraabdominal free fluid($p<0.001$) showed statistically significant differences among treatment groups.

The diagnostic value of appendix diameter on surgical treatment was found to be good in the ROC analysis (AUC=0.6994, 95%CI 0.61317-0.78555).

The diagnostic value of appendicitis index on surgical treatment was found to be good in the ROC analysis (AUC=0.7417, 95%CI 0,65907-0,82427).

According to the logistic regression test, when the diameter index is ≥ 13 mm(compared to the diameter index ≤ 9 mm OR=6.54, 95%CI 1.83-23.35, $p=0.004$), appendicolith(OR=4.07, 95%CI 1.19-13.99, $p=0.026$) and intraabdominal free fluid present(OR=2.91, 95% CI 1.22-6.93, $p=0.016$), physicians should be directed to surgical treatment.

Conclusion: Besides clinical and physical examination findings; appendix diameter, appendicitis index, intraabdominal free fluid and the presence of appendicolith in CT may be used for helping physicians for their decision on surgical or medical treatment.



**OP 042****CHRONIC DIVERTICULITIS AS AN INCIDENTAL FINDING IN CT COLONOSCOPY**

Papaioannou Sofia, Rigkas Athanasios, Theodorakopoulos Antonios

General Hospital Papageorgiou Thessaloniki, Greece

Purpose

The purpose of this study is to present 28 cases with findings of chronic diverticulitis.

Material and methods

In this retrospective study, a group of 316 patients who underwent CTC from 26/6/2015 to 11/5/2019 was evaluated. Each patient was on a low fiber diet and was also administered with laxatives the day before the examination. 200ml of gastrographin and buscopan were administered to them before the examination. Every examination was made with Philips Briliance iCT 256 multislice CT scanner.

Results

28 out of 316 patients were found with nonspecific wall thickening with homogenous enhancement. All of them had also diverticulas at the sigmoid. The indication for CTC in all of them was lack of completing a colonoscopy.

Conclusion

Chronic diverticulitis is a distinct pathological entity characterized by frequent development of chronic obstructive symptoms. Although CTC is not the first-line examination for the diagnosis of chronic diverticulitis, when found even as an incidental finding, should be differentiated from cancer and the radiologist should be aware of the exact point to make the differential diagnosis easier.





OP 043

LOCATION OF COLONIC DIVERTICULAS

Papaioannou Sofia, Sotiriadou Amalia, Theodorakopoulos Antonios
 General Hospital Papageorgiou Thessaloniki, Greece

Purpose

The purpose of this study is to review the various locations of colonic diverticulas.

Material and methods

In this retrospective study, a group of 216 patients that underwent CT colonoscopy from 26/6/15 to 14/1/2019 was evaluated, from which 132 female and 68 males. All of them were on a low fiber diet for three days, before the day of the examination and they were also administrated with laxatives the day before. 200ml of gastrographin and buscopan were administrated to them before the examination.

Results

From the 68 males, 41 (60%) had diverticulas, from whom 16 only at the sigmoid (39%), 10 at the descending colon (24%), 1 at the transverse colon and 2 at the ascending colon. From the 41 males 11 had diverticulas at the whole colon (26%).

Only one patient had diverticulas only at the cecum.

From the 130 females 72 (54%) were found with diverticulas, from which 18 at the sigmoid (25%), 16 at the descending colon (22%), 3 at the transverse colon and 4 at the ascending colon. From the 72 males 30 had diverticulas at the whole colon (41%).

Conclusion

The presence of multiple diverticulas in the whole colon shows that the high pressures at the colon are not the main cause for the formation of diverticulas and that enteral nervous system disorder should also be considered at the pathogenesis.

From the 95 males, 73 (76%) had diverticulas, from whom 37 only at the sigmoid (50,6%), 16 at the descending colon (22%), 0 at the transverse colon and 3 at the ascending colon. From the 73 males 15 had diverticulas at the whole colon (20%).

Only two patients had diverticulas only at the cecum.

From the 169 females 104 (61%) were found with diverticulas, from which 42 at the sigmoid (40%), 19 at the descending colon (18%), 3 at the transverse colon and 4 at the ascending colon. From the 104 males 35 had diverticulas at the whole colon (33%).



**OP 044****USE OF DIFFUSION WEIGHTED IMAGING AND APPARENT DIFFUSION COEFFICIENT IN GASTRIC CANCER**

Soydan Levent, Demir Ali Aslan, Torun Mehmet, Arar Cikrikcioglu Makbule
Haydarpasa Training and Research Hospital, Department of Radiology

Introduction: Presurgical clinical staging in gastric cancer (GC) is important for planning the extent of surgery.

Purpose: To investigate the diagnostic role of DWI and its quantitative parameter. Apperent Diffusion Coefficient (ADC) in staging of GC against histopathologic TNM staging.

Methods: Forty six patients with non-metastatic biopsy proven GC who underwent abdominal Magnetic Resonance Imaging (MRI) with DWI before surgery were included in this retrospective study. Tumor invasion depth (T stage) and nodal involvement (N stage) was evaluated using signal increase on DWI and tumor ADC was measured. Diagnostic performance of these results were assesed bycomparindg with post surgical hystopathology based on 8th TNM classification.

Results: Sensitivity, specifity and accuracy of DWI in T-staging were 92.1%, 75%, 89.1% for T2 vs T3 and 75%, 88.5%, 82.6% for T3 vs T4, whereas in N –staging 89.3%, 88.9%, 89.1% for N1 vs N2 and 73.7%, 96.3%, 86.9%for N2 vs N3 respectively. Relative preoperative ADC values correleated with pathologic T-staging ($r=-0,397$, $p=0.006$). There was also statistically significant difference of relative ADC values between T3 and T4 stages with an odds ratio of 7.714 (95 CI:1.479-40.243). The area under the receiver operating characteristic (ROC) curve for differentiating T3 and T4 stages was 0.725.

Conclusion: Our study findings suggest that DWI may be used in clinical staging of non-metastatic GC. In particular, relative ADC of DWI can distinguish T4 GC from less advanced stages.





THORAX - CARDIAC-BREAST

OP 045

EFFECTIVENESS OF ADC VALUES IN PREDICTING PATHOLOGIC GRADE IN NON SMALL CELL LUNG CANCER

Fatihoglu Erdem - Aydin Sonay

Sami Uus Training and Research Hospital, Department of Radiology, Ankara Turkey

Introduction: Lung cancer is the most common malignant tumor and causes mortality. It is crucial to predict tumor pathological characteristics to select the proper treatment strategy. It is stated in the literature that ADC values can be used to demonstrate the histological characteristics of lung cancers.

Purpose: In the current study, we aim to define the diagnostic efficacy of ADC values for discriminating the tumor grade in non-small cell lung cancer (NSCLC).

Materials and methods: 48 surgically diagnosed NSCLC cases were included into the study. MRI examinations are performed with 1.5 Tesla MRI systems Diffusion-weighted imaging (DWI) was performed in the axial plane with a single-shot, echo-planar imaging sequence. The ADC maps were generated, and a region-of-interest (ROI) was placed on the tumor to obtain ADC values. Values were measured three times from different places of the lesion, and mean value of these measurements were recorded.

Results: There were 11 grades 1, 27 grade 2, and 10 grade 3 NSCLC cases. 15 cases were squamous cell cancer, 32 cases were adenocancer, and 2 cases were large cell carcinoma. Mean ADC value was 2041.1 ± 143.5 in grade 1 tumors, $1855.4.8 \pm 102.5$ in grade 2, and 1571.5 ± 185.3 in grade 3 tumors. We found a significant negative correlation between grade and ADC values. The cut-off value to discriminate grade 2 from 1 was 1881 ± 198 (85% sensitivity, 75% specificity). The cut-off value to discriminate grade 3 from 2 was 1603 ± 210 (87% sensitivity, 69% specificity).

Conclusions: ADC values can be used to predict NSCLC grade effectively.





Figure 1: 53 year old woman, nonsmoker, grade 1, adenocancer. Axial fat saturated T2WI (a), DWI (b), and ADC images (c); showing the mass (arrows). The ADC value of the mass was measured as $2109 \times 10^{-6} \text{ mm}^2/\text{sec}$.

Figure 2: 57 year old man, smoker, grade 2, squamous cell cancer. Axial fat saturated T2WI (a), DWI (b), and ADC images (c); showing the mass (arrows). The ADC value of the mass was measured as $1891 \times 10^{-6} \text{ mm}^2/\text{sec}$.

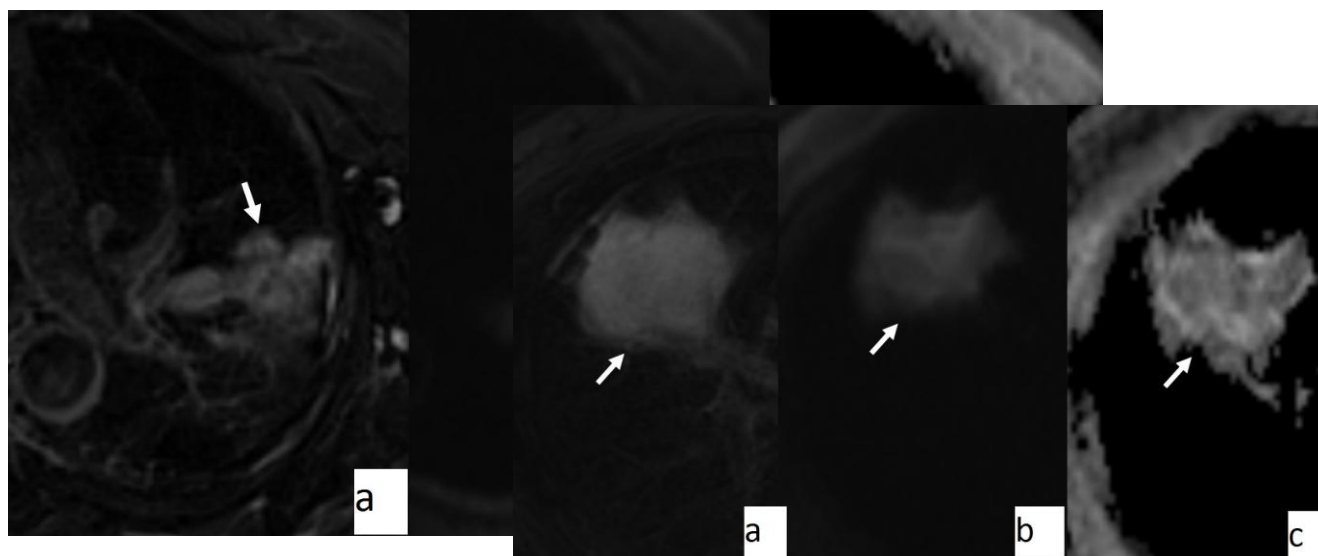
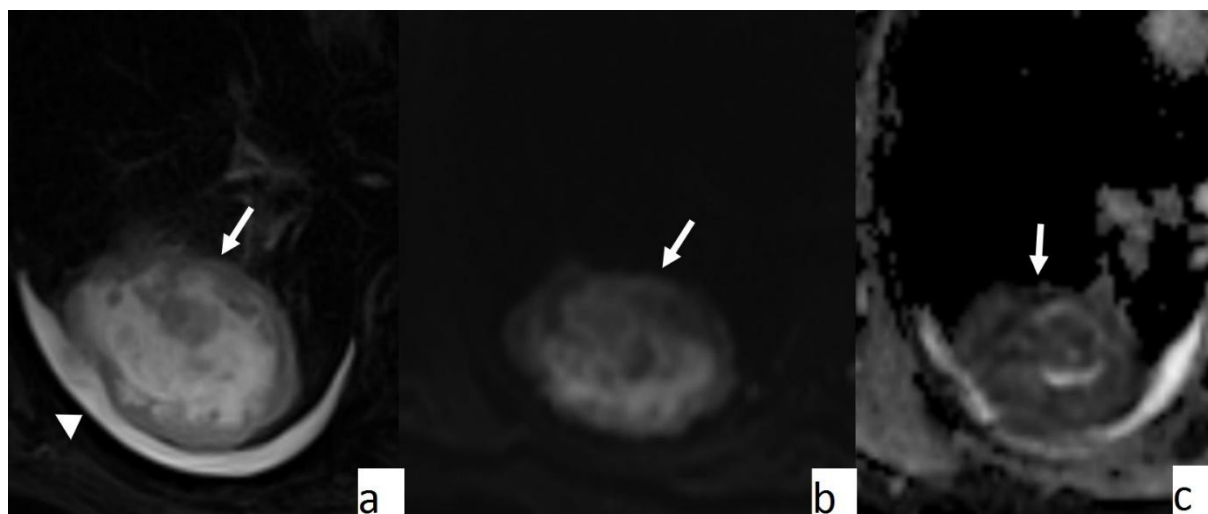


Figure 3: 68 year old man, smoker, grade 3, squamous cell cancer. Axial fat saturated T2WI (a), DWI (b), and ADC images (c); showing the mass (arrows). The ADC value of the mass was measured as $1540 \times 10^{-6} \text{ mm}^2/\text{sec}$.





Characteristics (n =...)	Value
Age (yr)	
Mean (\pm SD)	75.7 (7.0)
Range	56–88
Tumor size (mm)	
Mean (\pm SD)	34.9 (14.4)
Range	12–57
Histologic type	
Squamous cell carcinoma	21
Adenocarcinoma	38
Large cell carcinoma	1
Pathological grade	
Grade 1	15
Grade 2	30
Grade 3	15





OP 046

THE ASSOCIATION BETWEEN THE EXTENT OF LGE ON CMR WITH MYOCARDIAL AND INFLAMMATORY BIOMARKERS IN ACUTE MYOCARDITIS

Alis Deniz, Asmakutlu Ozan

Istanbul Mehmet Akif Ersoy Thoracic and Cardiovascular Surgery Training and Research Hospital, Istanbul Turkey

Introduction: Late gadolinium enhancement (LGE) on cardiac magnetic resonance (CMR) imaging in acute myocarditis represents myocardial necrosis and irreversible myocyte damage. However, to date, the relationship between LGE and biomarkers reflecting myocyte damage such as troponin I and MB isoform of creatinin-kinase (CK-MB) and serum markers reflecting the presence of inflammation such as c-reactive protein (CRP), platelet to lymphocyte ratio (PLR), and neutrophil to lymphocyte (NLR) ratio have mostly been overlooked.

Aim: To evaluate the association of LGE extent on CMR with troponin I, CK-MB, CRP, PLR, and NLR in patients with acute myocarditis.

Materials and methods: We retrospectively investigated 29 consecutive patients, 24 male (82.8%) and 5 female (17.2%), who were diagnosed as having acute myocarditis according to "International Consensus Group on Cardiovascular Magnetic Resonance in Myocarditis". All patients had troponin I and CK-MB examinations and routine hemogram within two days before or after CMR acquisition. The extent of LGE, as expressed as LGE-% and was calculated by proportioning the LGE positive areas to total left ventricular mass on short-axis CMR images using planimetry method. The association of LGE-% and laboratory markers were investigated using Spearman test.

Results: The mean age of the study cohort was xx years of age. We identified positive moderate correlations between CRP and LGE-%, troponin and LGE-%, and CK-MB and LGE-% ($p=0.003$, $r=0.54$; $p=0.003$, $r=0.53$; and $p=0.006$, $r=0.49$, respectively). No correlations were identified between LGE-% and PLR, and LGE-% and NLR ($p>0.05$)

Conclusion: The present study pointed out that LGE-% and myocardial biomarkers were positively correlated in patients with acute myocarditis. On the other hand, despite there was a positive correlation with CRP, no association was observed between LGE-% and other well-known inflammatory serum markers.





OP 047

FINDINGS OF THE LUNG PERFUSION BLOOD VOLUME WITH DUAL-ENERGY COMPUTED TOMOGRAPHY

Turnaoglu Hale

Baskent University, Faculty of Medicine, Department of Radiology, Ankara Turkey

INTRODUCTION: Dual-energy CT can generate maps that provide perfusion weighted information for patients with pulmonary thromboembolism. Lung perfusion blood volume (LPBV) maps can be used to identify the segmental or subsegmental areas of lung affected by a pulmonary embolus. However, false-positive perfusion defects may be seen in various lung diseases.

PURPOSE: To present the findings of LPBV images generated by dual-energy CT, in patients with the suspicion for acute pulmonary thromboembolism.

MATERIALS AND METHODS: Between April 2018 and March 2019, we retrospectively analyzed the images of total 589 consecutively registered patients who underwent dual-energy CT and had LPBV images, because of clinically suspected acute pulmonary thromboembolism. Pulmonary perfusion defects were evaluated in images obtained by LPBV. Then, findings suggestive of perfusion defects in LPBV images were evaluated with CT pulmonary angiography and standard CT images. False positive perfusion defects were analyzed.

RESULTS: 9.9% (n=58) of the patients had various degree of perfusion defects in LPBV images, and thromboembolism were detected in the CT pulmonary angiography images. 32.2% (n=190) of the patients had perfusion defects in the LPBV images, although pulmonary arteries were patent in the CT pulmonary angiography. In these patients, with the evaluation of standard CT images the reason of the perfusion defects were detected as emphysema (25.3%, n=48), atelectasis and/or pleural effusion (23.2%, n=44), consolidation (24.2%, n=46), congestion (15.8%, n=30), mass (5.3%, n=10), interstitial fibrosis (3.7%, n=7), secondary to surgery (1%, n=2), bronchiectasis (1%, n=2), and pneumothorax (0.5%, n=1). 21.6% (n=41) of these 190 patients had more than one finding was observed which caused to perfusion defects.

CONCLUSION: LPBV maps are useful for assessment of the clinical severity of PTE. In the analysis of LPBV images, sources of false-positive perfusion defects should be kept in mind to avoid misdiagnoses, and the standard CT images should be evaluated for other pulmonary pathologies.





OP 048

ABERRANT VESSELS IN THE LEFT MEDIASTINUM- UNDERSTANDING THE THORACIC VENOUS ANOMALIES

Mihaylova Evgeniya ,Eneva Maria, Groudeva Violeta, Belyanova Magdalena, Nedevska Maria
Department of Radiology, St Ekaterina University Hospital Sofia, Medical University Sofia

Introduction: Congenital anomalies of the superior vena cava are rare and often asymptomatic. The superior vena cava may more often be affected by intra- or extraluminal factors leading to strictures and consequently to the development of venous collaterals. On the other hand pulmonary venous anomalies are rarely asymptomatic and are often associated with [congenital cardiac diseases](#). These abnormalities may sometimes show imaging similarities and may present diagnostic and therapeutic challenges.

Purpose: to discuss the differential diagnosis of an aberrant vessel, coursing in the left mediastinum on contrast-enhanced computed tomography imaging and its clinical significance.

Materials and methods: We present three cases in which patients underwent contrast-enhanced computed tomography of the thorax due to different clinical indications.

Results: In all three patients an aberrant vessel in the left middle mediastinum, lateral to the pulmonary trunk was discovered. In case 1 superior vena cava duplication due to a persistent left superior vena cava, draining in a dilated coronary sinus was discovered as an incidental finding. In Case 2 a patient was diagnosed with partial anomalous pulmonary venous return together with another congenital anomaly- cor tratriatum. In Case 3 the study showed significant stenosis of the superior vena cava due to previously inserted pacemaker electrode which led to the development of venous collaterals. Additionally the images demonstrated dilated accessory hemiazygos vein draining directly into the brachiocephalic vein, which is a rare anatomical variant.

Conclusion: Knowledge of the anatomical variants and possible collateral pathways of the upper body venous return is important for the planning of surgical or interventional procedures. The thoracic venous anomalies may be very variable and exhibit some imaging similarities thus making the correct diagnosis often difficult.





OP 049

EFFECTS OF PULMONARY END-DIASTOLIC FORWARD FLOW ON RIGHT VENTRICULAR VOLUME AND FUNCTION IN TETRALOGY OF FALLOT

Ozkok Sercin

Istanbul Medeniyet University Goztepe Training and Research Hospital, Istanbul, Turkey

Introduction:

After initial surgical repair, resulting in severe pulmonary regurgitation (PR) or morphologic changes of main (MPA) and branch pulmonary artery (BPA), discrepancy between pulmonary vascularity, and perfusion, each of which may independently modify the amount of pulmonary regurgitation.

Purpose:

We aimed to search whether pulmonary artery flow dynamics such as regurgitation fraction (RF) and end-diastolic forward flow (EDFF) of MPA correlates with right ventricular end-diastolic volume index (RV-EDVI), right ventricular ejection fraction (RV-EF), right (RPA) and left (LPA) pulmonary artery size.

Materials and Methods:

We retrospectively reviewed 80 consecutive cardiac magnetic resonance (CMR) studies. Short axis SSSP images for functional and CE-MRA angiography for vascular anatomical, and phase-contrast imaging for RF evaluation were used. Acquired MRI data were postprocessed in a workstation.

Results: RF of the MPA was $45 \pm 14\%$. RF of the LPA ($56 \pm 20\%$) was greater than that of the RPA ($34 \pm 15\%$; $P=0.002$). R/L size ratio varied from 0.25 to 2.66, while the R/L flow ratio varied from 0.37 to 19. Patients with BPA stenosis or size discrepancy showed no significant difference between right and left BPA RF (34% vs. 56%, $p = 0.357$). However, there was a significant difference between RF and RV-EF ($P=0.002$) but not with RV-EDVI ($P=0.49$). Beside that, there was a significant difference between EDFF and RV-EDVI ($P=0.0004$) and RV-EF ($P=0.0002$) but not with RF ($P=0.49$).

Discussion: EDFF of MPA seen in echocardiography is widely accepted a marker of restrictive RV physiology. EDFF is associated with increased RV-EDVI and impaired RV-EF.

Conclusion: PR after repair of TOF is commonly associated with physiological and morphologic changes. End-diastolic reverse flow should be evaluated during the reporting when considering the need for further surgical or interventional procedures.





OP 050

COMPARISON OF CORONARY CT ANGIOGRAPHY AND CATHETER ANGIOGRAPHY FINDINGS IN PATIENTS WITH HIGH CALCIUM SCORE

Ali Mahir Gündüz

Yüzüncü Yıl University Faculty of Medicine, Department of Radiology, Van/TURKEY

Abstract

a) Introduction: There are various complications of catheter angiography which is the reference method in the diagnosis of coronary artery disease. Today, coronary angiography performed with multidetector computed tomography (c-CTA) is widely used in diagnosis.

b) Purpose: We aimed to investigate the effect of high calcium score on diagnosis by comparing CT and catheter angiography (cCA) findings in patients with a calcium score of 200 ↑.

c) Materials and Methods: The c-CTA and cCA findings of 29 patients with a calcium score above 200 were compared. We examined whether the calcific plaques exaggerated stenosis rates.

d) Results: A total of 29 patients, 12 females and 17 males, aged 44-86 years (mean age 63.5 years) were included in the study. Calcium score was between 200-400 in 12 patients, between 400-600 in 8 patients, between 600-800 in 2 patients, between 800-1.000 in 1 patient and over 1.000 in 6 patients. We observed intensive artifact in patients with a calcium score above 1000. In 3 patients, stenosis between 60-80% in cCA was seen as 90% and above in c-CTA.

e) Conclusion: Coronary artery calcification (CAC) is a pathognomonic finding of atherosclerosis. Increased CAC levels are indicative of a high total plaque burden and the presence of common disease, but do not necessarily mean obstructive CAD. However, the absence of calcium in the coronary arteries ≥ 50% stenosis has a very high negative predictive value of 98-100% in terms of exclusion. In patients with a calcium score above 1000, evaluability due to artifacts was reduced. We found an increase in stenosis rates in 3 patients compared to catheter angiography. In addition, we found that the coarse calcifications showed exaggerated stenosis.

Keywords: Coronary artery disease, angiography, calcium score





OP 051

ASSOCIATION BETWEEN STRAIN INDEX VALUES AND HISTOPATHOLOGIC GRADE IN EVALUATING NO-SPECIAL TYPE BREAST CARCINOMAS

Gulten SEZGIN¹

1. Izmir Katip Celebi University Ataturk Training and Research Hospital, Department of Radiology

Introduction:

No-special type breast carcinoma (NSTBC) forms the majority of breast cancers (1). Due to favorable prognosis, early detection is important. The histopathologic classification has a direct impact on the five-year survival rate of patients with NSTBC (2).

Purpose:

We aimed to investigate the association between histopathologic grade and strain index (SI) in evaluation of invasive NSTBC.

Material and Methods:

A total of 82 patients (age range, 27-80 years) were retrospectively evaluated. Ultrasound (US), strain elastography and US-guided core biopsy was performed for all patients. T test was used for statistical analysis. P value < 0.05 was considered statistically significant.

Results:

Five of the breast lesions (6.1 %) were classified as grade I, while 44 (53.65 %) were grade II and 33 (40.24 %) were grade III. Grade I lesions were excluded from the study because of their few number. When SI values for grade II and III lesions were compared, the SI values of grade II tumors were found to be significantly higher than those of grade III tumors ($p = 0.024$).

Conclusion:

In our study, we found that grade III invasive NSTBCs have lower SI values than grade II. Although the results are controversial in the literature. The results of our study are similar to the results of Durhan et al (3). They said that this result was because of high necrosis and fibrosis in grade III tumors. But Zhu et al. (4) have shown that there was a high correlation between histological grade and SI.





OP 052

ENCAPSULATED PAPILLARY CARCINOMA OF THE BREAST- RETROSPECTIVE STUDY

Delic Una, Durmic Ajla, Slender Tarik
KCUS SARAJEVO, Bosnia Hercegovina

Introduction:

Encapsulated papillary carcinoma (EPC) (*intracystic* or *encysted* papillary carcinoma) is traditionally considered a variant of ductal carcinoma in situ (DCIS).

Recent studies show EPC's lack myoepithelial cells at their periphery, leading to conclusion that EPCs can also present as invasive tumors with occasional lymph node involvement and distant metastasis.

Purpose:

The objective of this paper is to evaluate diagnostic challenge of these types of tumors, radiological, histological, immunohistological and pathological features of tumors, to determine how many are DCIS and how many have invasive component.

Materials and Methods:

Data base of patients was sourced from University Clinical center of Sarajevo from the years 2004 through 2016.

Results:

The mean patient age at diagnosis was 63 years, and the mean tumor size was 2,3 cm.

Female patients accounted for 94,44 % , male accounted for 5,5%.

16,66 % cases were pure EPC, 16,66 % cases were EPC with only DCIS , and 66,66% cases were EPC with invasive carcinoma (EPC+IC),

Invasive component was smaller than 1 cm in 100 % invasive tumors.

All tumors were HER2 negative , 88,8 % were highly positive for estrogen receptor, 11,11 % were negative , 66,66 % were highly positive for progesterone receptor and 33,33 % tumors were negative.

Conclusion :

IPC is a rare breast cancer, usually manifesting in postmenopausal women.

Long-term outcome is good, whether the tumor is classified as invasive or DCIS.

EPC on ultrasonography is usually seen as complex cystic with solid masses that have mild to moderate posterior acoustic shadowing or posterior acoustic enhancement.

EPC is usually a oval or round , lobulated, high-density mass, on mammography,.

The majority of EPCs in our study were ER+ , PR + and all tumors were HER2 negative.

Invasive component was smaller than 1 cm.





OP 053

DIAGNOSTIC VALUE OF AXILLARY LYMPH NODE SHORT AXIS-LONG AXIS RATIO AND DETERMINING A CUT-OFF VALUE OBTAINED WITH USG AND MRI IN BREAST CANCER PATIENTS

Duran Ozel, Deniz Ozel

Saglik bilimleri unv. Sisli Etfal Hospital Radiology Department , Istanbul ,Turkey

Introduction: In previous studies, the criteria for determining malignancy risk and biopsy indication in lymph nodes were defined by radiological methods. These criteria include the size of the long axis of the lymph node, the thickness of the cortex, the presence of fatty hilum, the short - long axis ratio, and the assessment of vascularity. However, there is no definite cut-off value for the short - long axis ratio.

Purpose: To define cut-off values for this parameter and to investigate the diagnostic efficacy of magnetic resonance imaging (MRI) and ultrasonography (USG), which are frequently used in the evaluation of lymph nodes.

Materials and methods: Axillary lymph node short - long axis ratio was determined on USG and MRI of each case diagnosed with breast cancer.

Results: The number of cases included in our study was 44, (43 females and 1 male). The mean age was 51.4 years. Primary mass pathologic diagnosis and sentinel lymph node biopsy results of the subjects included in the study are shown in Table a.

The cut-off value for USG was 0.59 and the cut-off value for MRI was 0.6. The corresponding diagnostic values are shown in table b.

Conclusion: In our study, close cut values were obtained for both modalities and this value was approximately 0.6. In similar studies, malignancy rate was found to be higher in spherical lymphadenopathies. The specificity and sensitivity and therefore the diagnostic accuracy of USG is higher but seems not satisfactory. The USG is a real-time modality and the operators have opportunity to perform optimal short - long axis evaluation with transducer maneuvers. In addition, the results should not be surprising given that axillary lymph nodes are generally superficially located and that high-quality images can be obtained with high frequency transducers. Finally, one criterion cannot give adequate information.

Table a. Mass and lymph node biopsy results of the subjects included in the study

Primary	Number of cases	%
Invasive ductal carcinoma	29	66
Invasive lobular carcinoma	5	11,4
Mixt carcinoma	4	9,1
Ductal carcinoma in situ	3	6,8
Invasive micropapillary carcinoma	2	4,5
Apocrine carcinoma	1	2,2
Lymph node biopsy		
Reactive	15	34,1
Granulomatous lymphadenitis	1	2,2



Metastatic involvement	28	63,6
------------------------	----	------

Table b. Short - long axis ratio cut-off value and diagnostic parameters for USG and MRI

Modality	Cut-off value	Sensitivity	Specificity	Diagnostic accuracy
USG	0,59	51,7	73,3	59,1
MRI	0,6	47	50	54,8

Figure 1. A 62 years old female spherical but reactive lymph node on MRI.

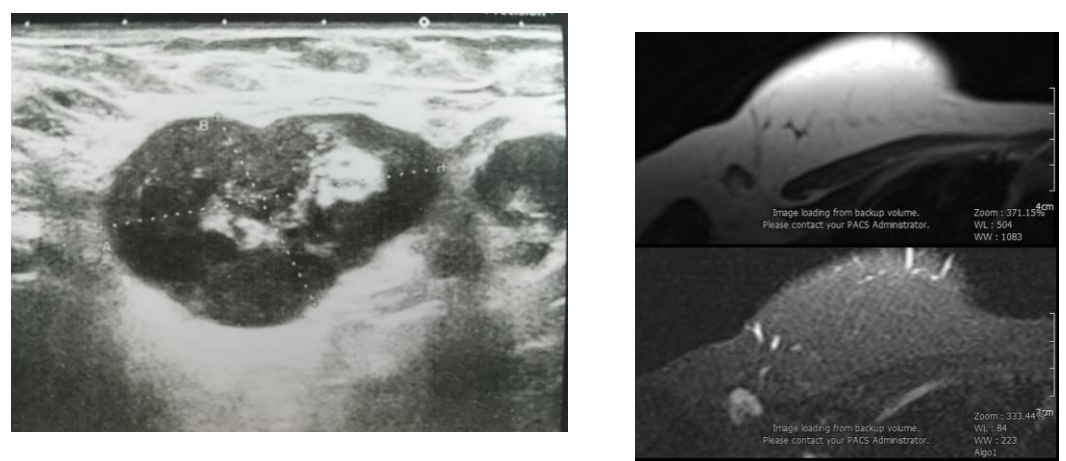


Figure 2. A 63 years old female axillary lymph node (invasive ductal carcinoma metastasis) on USG

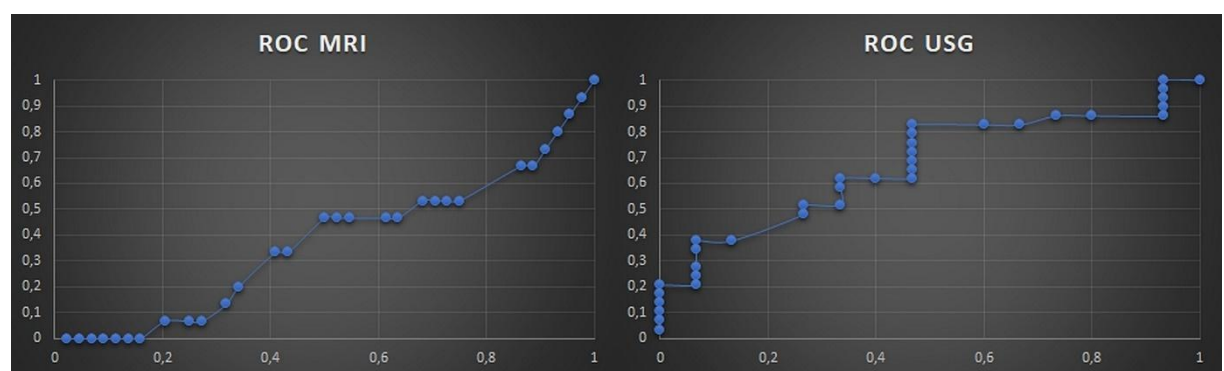


Figure 3. The ROC curves of MRI and USG





OP 054

EVALUATING THE CONTRIBUTION OF ADC VALUES AND CONTRAST ENHANCEMENT KINETIC MR DATA TO MORPHOLOGICAL MRI FINDINGS IN THE EVALUATION OF BREAST MASSES

Duran Ozel Betul

Okmeydani Education and Research Hospital, Kaptanp, Saglik bilimleri unv. Sisli Etfal hosp. Radiology, Istanbul Turkey

Introduction: BI-RADS is the most common guide for identifying and classifying breast lesions. BI-RADS 4 group is defined as gray zone and has three subgroups of different benign-malignant distribution. BI-RADS 3 lesions, considered almost completely benign, and BI-RADS 5 lesions, considered almost completely malignant.

Purpose: To evaluate the contribution of ADC values and dynamic analysis to conventional MRI data.

Materials and methods: BIRADS score classified according to morphological characteristics on MRI. The mean ADC values was then calculated. The region of interest was taken from the region with the T2 signal increase. The cut-off value of the benign-malignant lesions was calculated based on the mean ADC. Finally, the kinetic curve was classified into the three categories.

BI-RADS 4 lesions were excluded from determining the contribution of additional methods.

Results: The number of participants was 49 and all were women. The mean age was 48.3 years. The histopathological results of the cases are shown in table a.

The difference between the mean ADC values of benign and malignant lesions was statistically significant. The cut-off value was $1.12 \times 10^{-3} \text{ mm}^2 / \text{sec}$. Sensitivity and specificity were 90.6% and 83.2%, respectively. ADC, BI-RADS score and kinetic curve distribution of benign and malignant lesions are shown in table b. The contribution of ADC values and kinetic curves to the BI-RADS score is shown in table c.

Conclusion: In our study, it was observed that, ADC values were compatible with histopathological results substantially and contributed positively in one and misleading in the other case. However, dynamic MRI showed a good correlation with the histopathological result, but discordance was found in 10 cases. 8 of malignant lesions showed type 1 and 2 of benign lesions showed type 3 curve. Consequently, contrary to ADC values, difficult to declare, dynamic examination contributes the diagnosis.

Table a. Demographic and histopathological data of the subjects who participated in our study

Histopathology	Number of cases	Percent
Fibroadenoma	12	24.5
Benign adenomatoid changes	5	10.2
Mastitis	2	4.1
Benign fat based	3	6.1
Invasive ductal carcinoma	15	30.6
Invasive lobular carcinoma	5	10.2
Carcinoma in situ	4	8.2
Invasive papillary carcinoma	1	2
Metastases	2	4.1
Total	49	



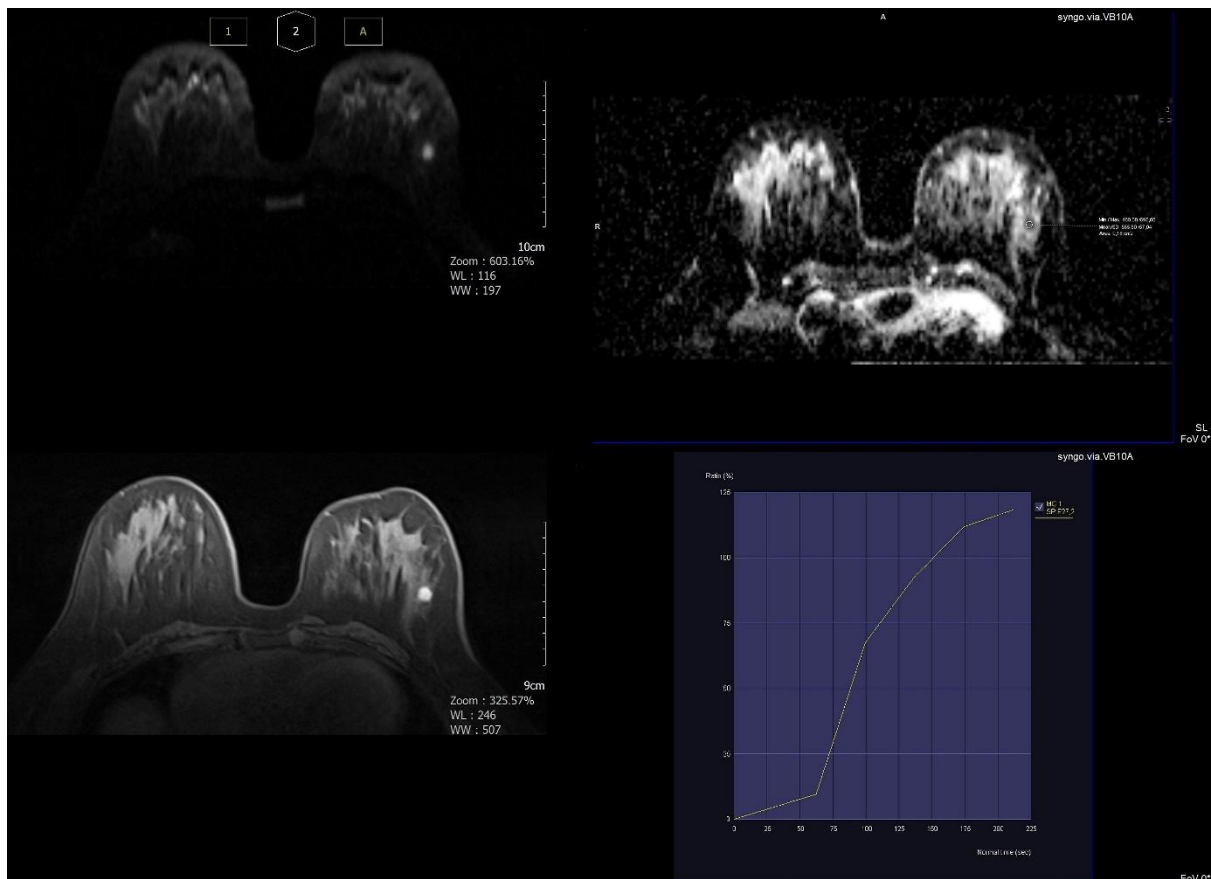


Table b. ADC (mean \pm standard deviation), BI-RADS score and kinetic curve distribution of benign and malignant lesions

	ADC (10^{-3} mm ² / sec)	BI-RADS 3	BI-RADS 4	BI-RADS 5	Type 1	Type 2	Type 3
Benign (n=22)	1.32 \pm 0.25	14	8	0	12	7	3
Malignant (n=27)	0.9 \pm 0.17	1	9	17	11	5	11
<i>p</i>	< 0.01						

Table c. Contribution of ADC values and kinetic curves to BI-RADS score

	Compatible	Positive contribution	Misleading
ADC	30	1	1
Contrast curve	22	0	10



Figures:

Figure 1: A 53 years old female. BI-RADS score:3 and the mean ADC value is less than cut-off value. Type 1 kinetic curve. Histopathology: Metastatic involvement



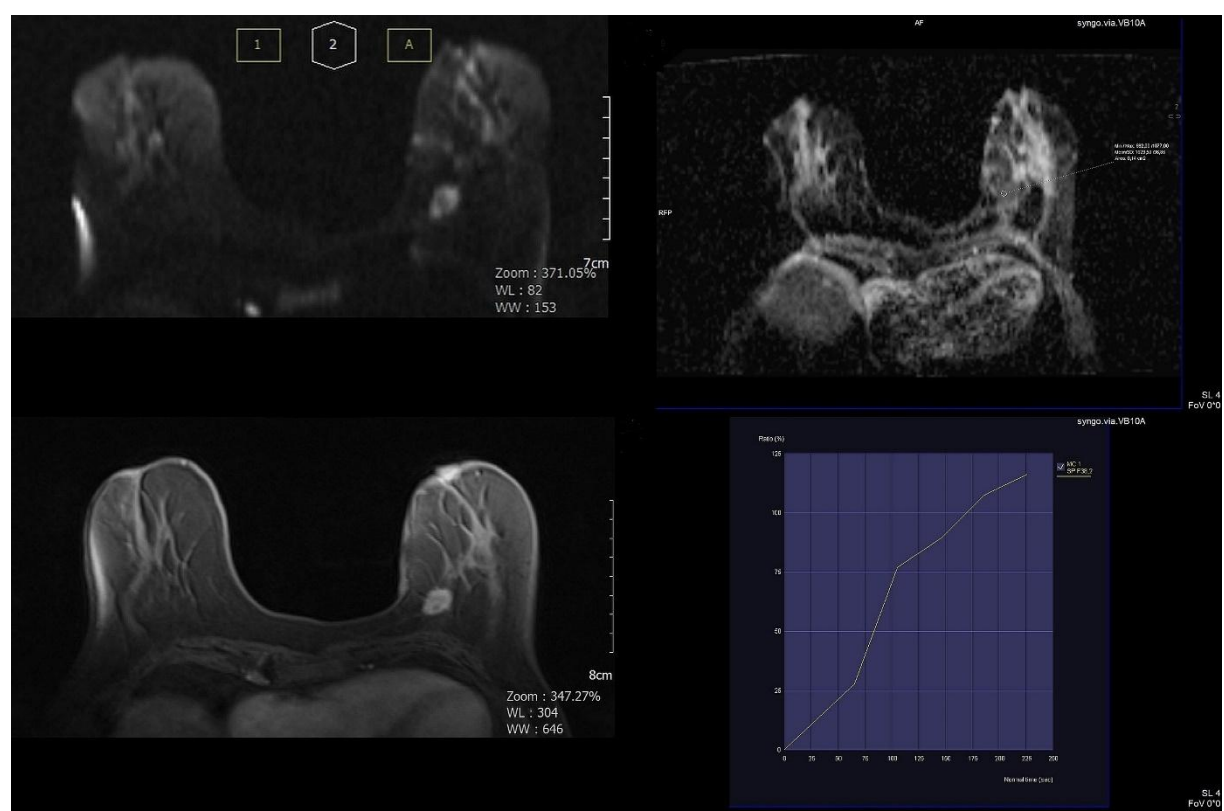


Figure 2. A 49 years old female. BI-RADS score:5 and type 1 kinetic curve. Invasive ductal carcinoma





OP 055

OUTCOMES OF PATIENTS WITH COMPLEX CYSTIC BREAST LESIONS

Kulali Fatma, Guner Gulbanu, Semiz-Oysu Aslihan, Ezberci Fikret, Bukte Yasar

Radiology Department, University of Health Sciences Umraniye Training and Research Hospital, Istanbul Turkey

Introduction:

The early diagnosis of complex cystic breast lesion is important because of malignancy risk. Previous studies reported various malignancy rates ranging from 0.3% to 23-31%.

Purpose:

We aimed to present our results in patients with complex cystic breast lesions and to estimate malignancy rate.

Materials and Methods:

A total of 74 women with complex cystic breast lesions with a mean age of 44 were enrolled in this retrospective study. Sonographic findings of patients (n=74) were reviewed by two radiologists. Complex cysts were classified into four categories due to sonographic findings (thick septa/wall, intramural nodule, solid/cystic ratio). Sonographic findings were compared with histopathological and follow-up results.

Results:

Of 74 complex cystic breast lesions, six were malignant and 68 were benign. Of 74, there were 19 with thick septa/wall (category 1), nine with intramural nodule (category 2), 37 with solid/cystic ratio < 1 (category 3) and nine with solid/cystic ratio > 1 (category 4). Most of benign lesions (42/68, 62%) were fibroadenomatoid and fibrocystic changes. Among six malignant tumors, four intraductal papillary carcinomas and one of invasive ductal carcinomas were in category 3 whereas one of invasive ductal carcinoma was in category 1. Most of malignant complex cystic lesions (5/6, 83%) were in category 3. The malignancy rate was estimated as 8%.

Conclusions:

The malignancy rate of complex cystic breast lesions in our study was 8%. Most of malignant complex cystic lesions were in category 3. Awareness of specific sonographic findings is important, because fibroadenomatoid and fibrocystic changes are common.

Keywords: breast cyst, intraductal papilloma, malignancy, ultrasound





OP 056

PATIENT REPORTED COSMETIC OUTCOME AFTER VACUUM ASSISTED EXCISION OF BENIGN BREAST LESIONS: A CROSS-SECTIONAL STUDY

van de Voort EMF¹, Klem TMAL², Struik GM², Birnie E^{3,4}, Sinke RHJA⁵, Ghandi A⁶

1. Department of Surgery, Franciscus Gasthuis & Vlietland, PO Box 10900, 3004 BA, Rotterdam, The Netherlands,
2. Department of Surgery, Franciscus Gasthuis & Vlietland, PO Box 10900, 3004 BA, Rotterdam, The Netherlands.
3. Department of Statistics and Education, Franciscus Gasthuis & Vlietland, PO Box 10900, 3004 BA, Rotterdam, The Netherlands.
4. Department of Genetics, UMC Groningen, University of Groningen, PO Box 30001, 9700 RB, Groningen, the Netherlands.
5. Department of Pathology, Franciscus Gasthuis & Vlietland, PO Box 10900, 3004 BA, Rotterdam, The Netherlands.
6. Entrepreneur, RadCo, Rotterdam, The Netherlands

Conflicts of interest and source of funding: Nothing to declare. No funding or sources of support are received.

Abstract

Introduction About 80% of all breast tumors are benign and can be excised through a vacuum assisted excision (VAE) under local anesthetics. Although most studies imply that cosmetic outcome after VAE is superior to cosmetic outcome after surgical excision (SE), hardly no studies on this subject are conducted. **Objective** In this study we aimed to evaluate cosmetic outcome and the possible influencing factors after VAE for benign lesions.

Methodology In this cross-sectional study all eligible patients were contacted to complete the Dutch BCTOS-13 questionnaire on cosmetic outcome (no difference (1) to a big difference (4)). Socio-demographic and procedure-related characteristics were retrospectively collected from the electronic patient record. All possibly associated variables with cosmetic outcome were included in a WLS multivariate linear and a binary multiple logistic regression analysis.

Results A total of 47/65 (72%) patients completed the questionnaire on cosmetic outcome. Cronbach's alpha for internal consistency of the questionnaire was good (0.73). Overall cosmetic outcome was good in 74% of patients (mean 1.5). The presence of follow-up complications was significantly associated with cosmetic outcome after WLS multivariate linear regression and binary multiple regression analysis.

Conclusions VAE has several advantages over SE, such as lower costs and less invasiveness. Overall cosmetic outcome after VAE was good and the presence of follow-up complications seem to have a negative effect on cosmetic outcome. Compared to literature VAE seems to have a better cosmetic outcome than surgical excision. A comparative study for results after VAE and SE is necessary to confirm findings.





NEUROIMAGING

OP 057

ADDITIONAL VALUE OF SUSCEPTIBILITY WEIGHTED IMAGING IN THE EVALUATION OF ACUTE ISCHEMIC STROKE PATIENTS

Ahmet Mesrur Halefoglou M.D., Professor, Alper Demirci M.D., Betul Duran Ozel M.D.
 Sisli Hamidiye Etfal training and research Hospital Radiology Department, Istanbul Turkey

Introduction

SWI (susceptibility weighted imaging) is a relatively new technique provides to enhance contrast in MRI (magnetic resonance imaging) and adds clinically useful complementary information to conventional spin-echo MRI sequences.

Purpose

The aim of our study was to prove SWI as useful adjunct to routine MRI in the evaluation of acute ischemic stroke patients.

Materials and Methods

We performed a prospective study of 65 patients presenting with acute ischemic stroke in whom the diagnoses were based on clinical findings and DWI (diffusion weighted imaging). All patients were referred to computed tomography (CT) and complete brain MRI examinations which also included SWI within 24 hours of stroke onset. These patients were evaluated for the presence of macrohemorrhage or microhemorrhage, prominent vessel sign, hyperdense artery sign, hyperintense artery sign and susceptibility vessel sign (SVS).

Results

SWI was able to detect hemorrhage in 12 out of 65 patients (18%) as either macrohemorrhages or petechial microhemorrhagic forms which were later not seen on CT or routine MRI sequences. Out of these 12 patients, 6 (50%) showed macrohemorrhages and the remaining 6 (50%) had petechial microhemorrhages. SWI was able to detect all microhemorrhages (100%) which otherwise would not be picked up by other imaging modalities. A prominent vessel sign was detected in 53 out of 65 (82%) patients in the vicinity of the acute ischemic brain territory. Hyperdense artery sign on CT in 31 (48%) patients and hyperintense artery sign on fluid attenuated inversion recovery (FLAIR) sequence in 21 (32%) patients were present. However, on SWI sequences, SVS was present in 55 out of 65 (85%) patients with different major intracranial artery locations.

Conclusion

SWI has been proven to provide invaluable additive information which otherwise would not be able to be picked up by other imaging sequences, in the evaluation of acute ischemic stroke patients.



**OP 058****NORMAL MEASUREMENTS OF OPTIC NEVRE IN PEDIATRIC POPULATION**

Fatihoglu Erdem - Aydin Sonay

Sami Ulus Training and Research Hospital, Department of Radiology, Ankara Turkey

Introduction: Fifteen percent of the blindness cases is due to congenital optic nerve defects. Also optic nerve hypoplasia counts for 12% of blindness cases. Visual impairments can be associated with brain, endocrine, and other systemic defects and syndromes. Hence, measurements of optic nerve can be a good diagnostic tool for many neuro and endocrine pathologies.

Purpose: We aim to define the normal measurements of the optic nevre in different segments according to age groups in pediatric population by using MRI.

Materials and methods: Optic nerves were retrospectively measured by two radiologists in 426 children (213 males, 213 females). MRI examinatioes were performed by 1.5 T MRI systems. T2 images were used to perform the measurements. Measurements were performed at orbital part of the optic nerves (OP), prechiasmatic part (PP), and optic tracts (OT). Patients were classified into five subgroups according to their age: a)infants: up to 1 year of age, b)toddler: 1-3 years, c)preschooler: 3-5 years, d)school age: 6-12 years, e)adolescent: 12-18 years

Results: Mean age of the population is 8.3 ± 1.5 years. Mean diameter of OP in whole population is 3.58 ± 0.53 , PP 4.74 ± 0.48 , OT 3.61 ± 0.48 . Age and OP, PP, OT values are positively correlated. Mean diameters of OP, PP and OT is significantly different between all age groups. Interobserver reliability of the measurements was good for all three diameters (OP kapa value 0.62, PP kapa value 0.58, OT kapa value 0.67).

Conclusion: Normal diameters of the optic nevre can be measured by MRI at above mentioned sections with a good interobserver reliability. These normal values can be used to detect obscure thickness changes/abnormalities in optic nerves of the children.





Figure 1: 5 year old male, axial T2WI image showing measurement of optic nerve at intraorbital portion (OP).

Figure 2: 3 year old female, axial T2WI image showing measurement of optic nerve at prechiasmatic portion (PP).

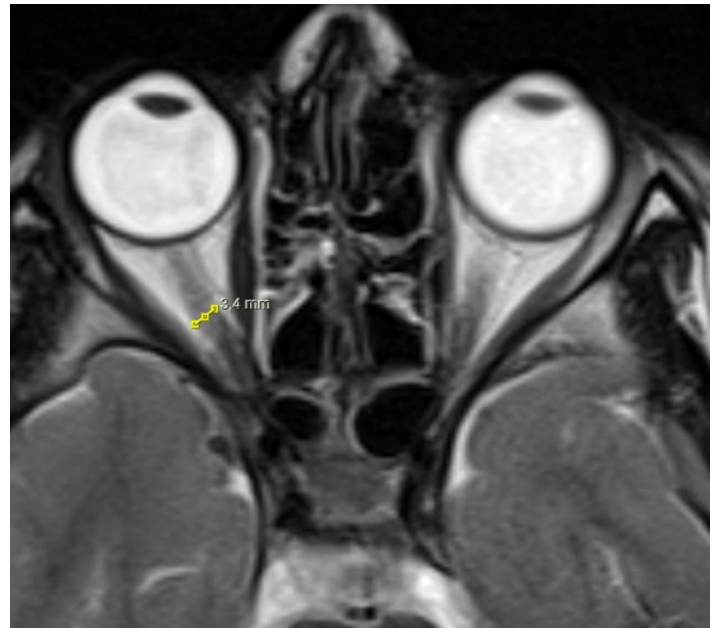
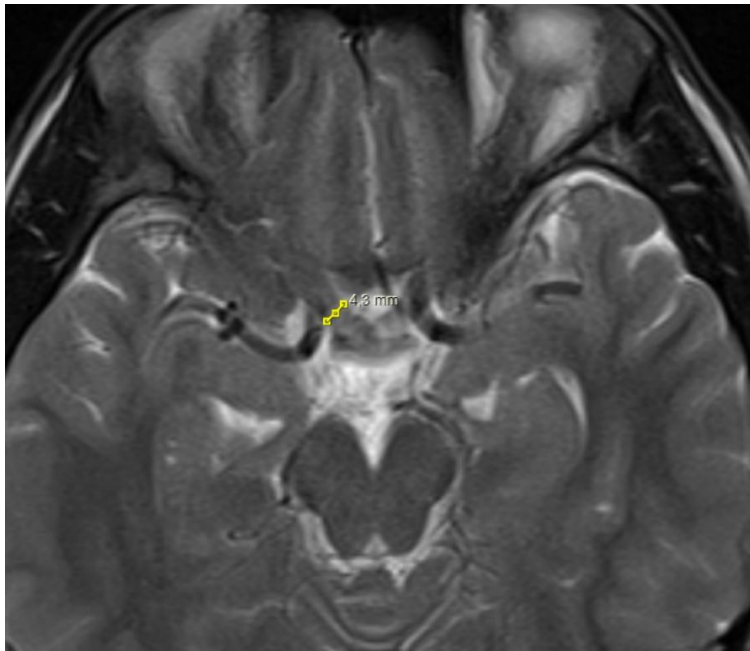
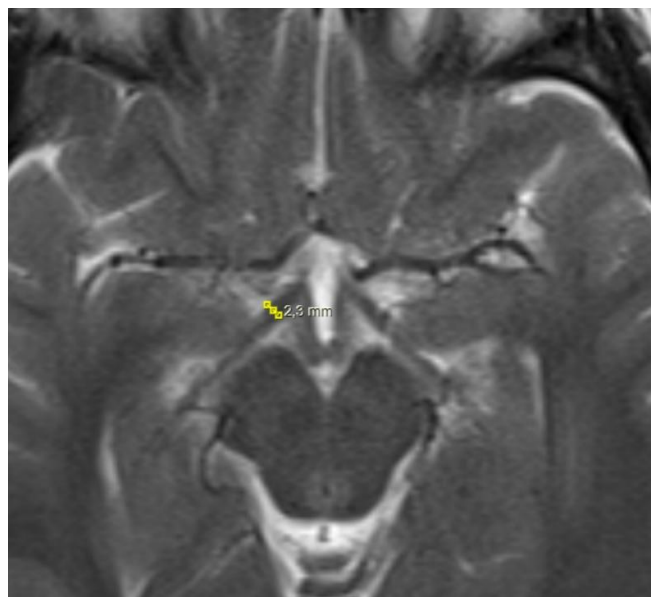


Figure 3: 10 months old, male, axial T2WI image showing measurement of optic nerve at optic tract (OT).





OP 059

CORPUS CALLOSUM MORPHOMETRIC MEASUREMENTS AND AGE/GENDER CHARACTERISTICS: A COMPREHENSIVE MR IMAGING STUDY

Arda Kemal Niyazi, Akay Sinan

University of Health Sciences, Gulhane Training and Research Hospital, Radiology Clinic, Merkez Turkey

Introduction: The corpus callosum (CC) is the main interhemispheric commissure of the brain. Numerous studies have been published regarding changes in CC macro-anatomy throughout childhood and adolescence to old age. In medical literature, there is no consensus on how and from where CC measurements should be done, and there are also no comprehensive imaging studies regarding this subject.

Purpose: To examine a possible relationship between morphometric CC measurements, age and gender characteristics using MR images.

Materials and Methods: The medical data and MR examinations of 436 consecutive subjects were retrospectively reviewed. The CC thickness from five different sites, splenium length, height and total length of the CC, and the splenium index (SI) were measured with a mid-sagittal T1-weighted sequence. Those measurements were compared with age and gender characteristics.

Results: A weak but statistically significant negative correlation was found between age and thicknesses of genu and all body portions of CC ($p = \leq 0.001$ for all). There was a weak but statistically significant positive correlation between age and the lengths of CC and splenium ($p \leq 0.022$ for both). The second part of the body (B2) was thicker in females ($p = 0.014$). On the other hand, the CC and splenium lengths were greater in males compared to females ($p = 0.029$ for both).

Conclusion: We designed a comprehensive MR study to investigate a possible relationship between normal morphometric CC measurements in 436 subjects. We preferred splenium length and SI as the main splenium measurements instead of direct splenium thickness, due to discrepancies regarding splenium measurement methods in medical literature. There was a wide spectrum of results, and we compared those results with existing medical literature.



**OP 060****MOTOR TRACT EVALUATION ON 3T MAGNETIC RESONANCE IMAGING**

N. Fileva, D. Zlatareva, V. Hadjidekov

Department of Diagnostic imaging, UMHAT Aleksandrovska, Medical university Sofia, Bulgaria

Introduction

Corticospinal tract is a white matter structure beginning from the primary motor area in the precentral gyrus, passing through the internal capsule, cerebral peduncles, reaching the pyramids in the medulla oblongata.

Purpose

The purpose is to demonstrate the possibility of visualization of the motor tracts using Magnetic resonance imaging (MRI) and standard sequences.

Materials and Methods

We present two patients examined in our radiology department, using 3 Tesla MRI Unit and a standard head protocol without contrast enhancement. The included sequences are T1W, T2 TIRM DARK FLUID (FLAIR), SWI, T2 TSE and DWI in different planes.

Results

In both cases T2/FLAIR hyperintense changes in the white matter were appreciated. The first patient is a 59-year-old male with right-side hemiparesis, 4 months after a left middle cerebral artery ischemic stroke. The MRI showed an unilateral visualization of the left motor tract as a result of post-stroke Wallerian degeneration. This is a process of myelin destruction, followed by total axonal degeneration that occurs in distal axons after injury to the proximal parts of a neuron. The second patient is a 27-year-old male with painless, progressive muscle weakness and EMG findings of motor neuron disease, suggestive of amyotrophic lateral sclerosis (ALS). In this case the corticospinal tracts can be found bilaterally, because of the symmetric affliction characteristic of the disease.

Conclusion

The presented cases are showing that in some conditions the standard MRI sequences can be enough to visualization of the corticospinal tracts.





OP 061

DETERMINATION OF MAGNETIZATION TRANSFER VALUES IN NORMAL ADULT BRAIN IN 3-TESLA MAGNETIC RESONANCE IMAGING

Kaya Eyup, Hocaoglu Elif

Okmeydani Training and Research Hospital, Istanbul, Turkey

Background: As magnetization transfer has shown to be a useful technique which helps to differentiate the composition of tissues and widely used for general diagnostic purposes it becomes more important to have a normal baseline values for image interpretation.

Aims: To serve a model for further pathological studies, we aimed to map regional MTR values in the normal white/grey matters in a group of adults using 3-Tesla MRI.

Methods: Axial T1 weighted images with and without magnetization transfer were performed on a 3T MR on 50 healthy subjects (aged 20 to 40 years). The areas of interest in the MTR maps in all subjects were analyzed. Both hemispheres were measured individually, and midline structures were measured alone. The MTR values were measured in the right/left hemispheres, whitematter/grey matters (cortical-deep), all localizations in the white matter and supra and infratentorial compartments of the grey matter. The regional differences and mean MTR values with standard deviation (SD) and standard error of mean (SEM) of measured areas were statistically analyzed. A total of 80 measurements were obtained from each subject; nine areas from the grey matter and 29 areas from the white matter were taken bilaterally and three midline WM were taken unilaterally. The measurements of one CSF and total 79 parenchymal areas were evaluated with circular regions of interest (ROIs). The ROIs were between 0.5 mm² and 25 mm² depending on the region.

Results: The mean MTR value in the white matter was higher, compared to the grey matter. In the grey matter, the lowest MTR values were obtained from the cerebellum and frontal lobe, while the highest values were obtained from the thalamus and globus pallidus. In the white matter, the lowest MTR values were obtained from the tectum, optic tracts, fornix, and anterior commissure, while the highest values were obtained from the corpus callosum, posterior crus, and centrum semiovale. In the comparison of the lobes, the highest mean MTR value was detected in the occipital and temporal lobes for the grey matter, whereas the white matter MTR value of the temporal lobe was higher than the other lobes.

Conclusion: MTR measurement has the potential to evaluate pathological and physiological structural alterations in CNS *in vivo*, and the method is an invaluable tool which can provide enhanced sensitivity and specificity in the evaluation of the pathological processes.





OP 062

AGE-RELATED DEEP WHITE MATTER CHANGES IN MYELIN AND WATER CONTENT: A T2 RELAXOMETRY STUDY

Kavroulakis Eleftherios, Kalaitzakis Georgios, Karageorgou Dimitra, Makrakis Dimitris, Maris Thomas, Simos Panagiotis, Papadaki Efrosini
 Radiology Department and Medical Physics Department University of Crete, Greece

Introduction

Systemic Lupus Erythematosus (SLE) affects the Central Nervous System in about 30-70% of cases. Depression and clinically significant manifestations of anxiety are found in up to 50% and 22% of patients with SLE, respectively.

Purpose

The aim of this study is to examine the hypothesis that there is a primary pathophysiological process causing emotional difficulties in SLE patients and that these are not secondary to the physical and social burden incurred by the disease, by exploring associations between hemodynamic changes and the emotional status.

Material and methods

19 patients without overt neuropsychiatric manifestations (non-NPSLE), 31 neuropsychiatric SLE (NPSLE) patients, and 23 healthy controls (HC) were examined. Self-reported symptoms of anxiety and depression were recorded using the Greek version of the Hospital Anxiety and Depression Scale (HADS). Cerebral blood flow (CBF) and cerebral blood volume (CBV) values were estimated using Dynamic Susceptibility Contrast Magnetic Resonance Imaging in dorsolateral prefrontal, ventromedial prefrontal and anterior cingulate white matter, hippocampi, caudate nuclei and putamen.

Results

NPSLE patients reported high rates of anxiety and depression symptomatology. Significantly reduced CBF values were detected in the NPSLE group, compared to HC, in dorsolateral prefrontal (left: $p=.004$; right: $p=.001$) and ventromedial prefrontal areas (left: $p=.003$; right: $p=.0012$). Reduced CBV values, as compared to the HC group, were found in dorsolateral prefrontal, ventromedial prefrontal, caudate, and putamen ($p<.004$). In NPSLE patients anxiety symptomatology was significantly associated with lower perfusion in fronto-striatal regions ($p<.004$) and in the right anterior cingulate white matter ($p<.003$). Importantly, the latter associations appeared to be specific to anxiety symptoms, as they persisted after controlling for depression symptomatology and independent of the presence of visible lesions on conventional MRI.

Conclusion

A primary mechanism for anxiety—distinct from that of depression—linked to hypoperfusion in specific limbic and fronto-striatal regions is indicated in NPSLE patients.





OP 063

REGIONAL CEREBRAL PERFUSION CORRELATES WITH ANXIETY IN NEUROPSYCHIATRIC SYSTEMIC LUPUS ERYTHEMATOSUS

Kavroulakis Eleftherios, Bertias George, Fanouriakis Antonis, Karagiorgou Dimitra, Papastefanakis Emmanouil, Simos Panagiotis, Papadaki Efrosini
 Radiology Department University of Crete, Crete Greece

Introduction

Systemic Lupus Erythematosus (SLE) affects the Central Nervous System in about 30-70% of cases. Depression and clinically significant manifestations of anxiety are found in up to 50% and 22% of patients with SLE, respectively.

Purpose

The aim of this study is to examine the hypothesis that there is a primary pathophysiological process causing emotional difficulties in SLE patients and that these are not secondary to the physical and social burden incurred by the disease, by exploring associations between hemodynamic changes and the emotional status.

Material and methods

19 patients without overt neuropsychiatric manifestations (non-NPSLE), 31 neuropsychiatric SLE (NPSLE) patients, and 23 healthy controls (HC) were examined. Self-reported symptoms of anxiety and depression were recorded using the Greek version of the Hospital Anxiety and Depression Scale (HADS). Cerebral blood flow (CBF) and cerebral blood volume (CBV) values were estimated using Dynamic Susceptibility Contrast Magnetic Resonance Imaging in dorsolateral prefrontal, ventromedial prefrontal and anterior cingulate white matter, hippocampi, caudate nuclei and putamen.

Results

NPSLE patients reported high rates of anxiety and depression symptomatology. Significantly reduced CBF values were detected in the NPSLE group, compared to HC, in dorsolateral prefrontal (left: $p=.004$; right: $p=.001$) and ventromedial prefrontal areas (left: $p=.003$; right: $p=.0012$). Reduced CBV values, as compared to the HC group, were found in dorsolateral prefrontal, ventromedial prefrontal, caudate, and putamen ($p<.004$). In NPSLE patients anxiety symptomatology was significantly associated with lower perfusion in fronto-striatal regions ($p<.004$) and in the right anterior cingulate white matter ($p<.003$). Importantly, the latter associations appeared to be specific to anxiety symptoms, as they persisted after controlling for depression symptomatology and independent of the presence of visible lesions on conventional MRI.

Conclusion

A primary mechanism for anxiety—distinct from that of depression—linked to hypoperfusion in specific limbic and fronto-striatal regions is indicated in NPSLE patients.



**OP 064****ENDOVASCULAR TREATMENT OF INTRACRANIAL ANEURYSM WITH FLOW DIVERTER STENTS**

Igus Behlul

Radiology Department Baskent University Istanbul Hospital Istanbul Turkey

Introduction

Endovascular treatment of intracranial aneurysm with coil embolization is the most commonly used method but also has some limitations. Recently, Flow-diverter stents have been developed and it is increasingly used to treat wide neck, blister and fusiform aneurysms which are technically challenging to treat by the endovascular approach.

Purpose

We aimed to present the treatment and follow-up results of 41 patients who were treated for intracranial aneurysm with flow diverter stents.

Materials and Methods

Forty-one patients (Age range 27-68 years) were treated with the flow-diverting devices during January 2010 and January 2014. Aneurysms ranged in size from small to giant (1-30mm) and include wide-necked, saccular, blister, dissection, fusiform and recurrent intracranial aneurysms. Control skull X-Ray Graphy was typically performed at 1, 3 and 6 months after the treatment. A follow-up digital subtraction angiography (DSA) was performed at first day, 6 and 12 months after the treatment.

Results

Complete angiographic occlusion was achieved in 36 patients (%88) at follow-up DSA. Two transient morbidities and one permanent morbidity occurred due to stent thrombosis. There was no mortality observed.

Conclusion

Flow diverter stents are an effective tool in the treatment of complex intracranial aneurysms. The treatment-related complication rate was relatively low. However, larger studies are needed to confirm these results.

OP 065**EPIDURAL VEIN THROMBOSIS – an impossible diagnosis to prove.**

Roger Smith Neuroradiologist, Assistant Professor University Health Network

Uhn Toronto Western Hospital, University of Toronto, Canada

Acute lumbar back pain and radiculopathy is a common presentation to the emergency department necessitating acute pain management and imaging. MRI as the modality of choice is used to define any etiology.

Epidural vein thrombosis is an imaging diagnosis often seen in association with an acute annular tear. It has specific MR imaging characteristics and is often misinterpreted as an acute disc protrusion. Surgery is usually deferred however at follow up 'presurgical' planning imaging the acute disc has disappeared and surgery is no longer indicated. As a result there is no 'specimen' to solidify the diagnosis.

With the opioid crisis patient management options need to be considered and alternative therapies may be indicated.

The talk will present the diagnosis through images and case histories defining criteria for the diagnosis.

Key points: Imaging diagnosis, strong clinical associations, complete absence of pathological data, common incorrect diagnosis of acute disc extrusion, treatment implications.





OP 066

ENDOVASCULAR TREATMENT OF CAROTID ARTERY DISEASE – EXPERIENCE FROM CLINICAL CENTER OF SERBIA

Vladimir Cvetic^{1,2,*}, Borivoje Lukic², Oliver Radmili², Momcilo Colic², Dragan Masulovic^{1,2}

¹School of Medicine, Belgrade University, Belgrade, Serbia

²Center for Radiology and MRI, Clinical Center of Serbia, Belgrade, Serbia

Introduction: Carotid artery stenting (CAS) has become a standard alternative to surgical treatment of patients with hemodynamically significant carotid stenosis.

Purpose: The aim of this study was to evaluate the results of endovascular therapy on the treatment of carotid artery stenosis.

Materials and Methods: According to literature recommendations respecting the indications for CAS, starting from June 2006 to June 2019 at Clinical Center of Serbia more than 800 patients with carotid artery stenosis underwent CAS (31% had restenosis after carotid endarterectomy, 7% patients had surgically unapproachable lesions, 2% were treated after radiation therapy, and more than 50% of the patients were with severe coronary or pulmonary disease). There were more asymptomatic, than symptomatic patients. Because of anatomical reasons we didn't finish the procedure in 20 patients.

Results: The overall rate of in-hospital adverse events (transient ischemic attack, minor stroke, major stroke, myocardial infarction, and death) was around 5%. Implanted carotid stents open and closed design, and dual layer stents depending on the type of the lesions, with mandatory use of cerebral protection devices.

Conclusion: CAS seemed feasible and relatively safe in our experience. CAS is the method of choice in the treatment of carotid disease in appropriately selected patients with a selection of the optimal material. Identifying complications during endovascular treatment of carotid stenosis, and the possibility of their solution is conditional upon the learning curve, experienced operator and the number of procedures performed in specialized centers.





OP 067

BILATERAL CATHETERIZATION AND SAMPLING OF THE INFERIOR PETROSAL SINUSES IN PATIENTS WITH CONFIRMED ACTH DEPENDENT CUSHING SYNDROME (BIPSS)

Pavlos Ampatzis, Danai Stefanou, Christina Sierrou, Anastasios Tsokas, Panagiotis Petaloudis, Dimitrios Tomais, Ioannis Kalogeropoulos, Theodoros Kratimenos
 Radiology Department Interventional Radiology Unit, Athens General Hospital 'EVAGGELISMOS'

Purpose

To highlight in detail the method of bilateral catheterization and sampling of the inferior petrosal sinuses and underline the value of this procedure at ACTH dependent Cushing Syndrome cases, after a negative pituitary gland MRI result

Materials and Method

The differential diagnosis of ACTH-dependent Cushing's syndrome (CS) is crucial in order to proceed to the appropriate management. Differentiating, however, between a pituitary (Cushing's disease-CD) and a nonpituitary (ectopic ACTH syndrome -EAS) remains a challenge. The non-invasive dynamic tests (CRH test and High Dose Dexamethasone Suppression Test) have a considerable rate of false positive and false negative results, whereas the diagnostic accuracy of pituitary MRI is even worse.

BIPSS with CRH stimulation represents the most accurate diagnostic test and is recommended by the Endocrine Society for all patients with ACTH-dependent CS and no obvious causal neoplasm (>6 mm). A basal central-to-periphery ACTH ratio ≥ 2 and/or ≥ 3 after hCRH is diagnostic of CD.

Herein, we report our recent experience with 20 BIPSS procedures, performed during the period 2016-2019, all carried out by the same interventional Radiologist (T.K.). Briefly, samples for measurement of ACTH are drawn simultaneously from the inferior petrosal sinuses and the periphery before and at 3-5, 8-10 and 13-15 minutes after the administration of 100mcg hCRH. In patients who are poor responders to CRH we use a combined stimulation with CRH plus desmopressin to increase the sensitivity of the test, by overcoming the risk of false-negative results.

Results. The procedure was successful in all patients. No complications occurred and all patients tolerated the procedure well. In all patients the central/periphery ACTH ratio established the diagnosis of CD; in 11 patients was confirmed by positive histology and/or postoperative remission, 8 patients have not been operated yet and one patient underwent the procedure after unsuccessful TSS.

Conclusion

BIPSS is safe and reliable method with low complication rate. It is useful for the differential diagnosis between Cushing Syndrome and ectopic ACTH syndrome. Anatomy knowledge conduction of the examination by expert interventional radiology team is the key for a successful result.



SATURDAY, OCTOBER 19TH, 2019





INTERVENTIONAL RADIOLOGY -VASCULAR

OP 068

MR-VENOGRAPHY IN THE DIAGNOSIS OF POST-THROMBOTIC ILIAC VEIN OBSTRUCTION AND EXTRAVASCULAR COMPRESSION

V. Shebryakov^{1,2}, O. Karpov¹, Yu. Stoyko¹, O. Bronov, M. Yashkin¹, D. Lutarevich²

¹Pirogov National Medical & Surgical Center, Moscow, Russia

²Ramsay Diagnostics, Moscow, Russia

Introduction Social and economic importance of the problem is determined by the lack of standards for diagnosis of iliac and cava vein obstruction, significant individual variability of adaptation processes and venous outflow disturbance compensation as well as lack of widely accepted diagnostic criteria.

Purpose: Evaluate the information value of MRI in the diagnosis of post-thrombotic iliac vein obstruction and extravascular compression.

Methods and Materials: The study included 118 patients with CVD (clinical class C3-C6 according to the CEAP classification), including 47 men and 71 women. The average age of the patients was 43.6±11.6 years. Clinical classes of patients are as follows: C3 – 17, C4a – 8, C5 – 2, C6 – 1. All patients underwent ultrasound angioscanning veins of the lower extremities and MRI of the iliac veins and IVC. Studies were performed on MRI using a special protocol contrast free sequences: 1. BH TROOFI/FIESTA ISO using Valsalva maneuver; 2. INHANCE 3D using free breathing technique, with subsequent 3D reconstruction.

Results: 87 patients have been diagnosed with stenosis of the left common iliac vein due to compression of the right common iliac artery (May-Turner syndrome). 21 patients underwent stenting of left common iliac vein with the May-Turner syndrome. 2 patients underwent stenting of the left external and common iliac veins with post-thrombotic obstruction. 10 post-thrombotic deep vein changes have been revealed: post-thrombotic obliteration of the left common iliac vein (CIV) in 4 cases, right CIV, IVC in 3 cases, right external iliac vein (EIV)- 1, left EIV - 1, 1 with stenosis of both EIV, 2 stenosis of the left CFV and 1 has demonstrated complete recanalization of the left EIV after thrombosis of a previously deferred.

Conclusion: MRV is the most optimal method in the diagnosis of the causes of extra and intravenous pathology of the IVC and its basin. There is no radiation exposure, non contrast agent and short time relation. 3D-reconstruction of the IVC and iliac veins can be used for planning corrective and reconstructive operations.





OP 069

UNDERSTANDING THE EFFECT OF THE NUMBER OF WIRE ON STAGNATION FLOW ZONES INSIDE A GIANT ANEURYSM USING A COMPUTATIONAL FLUID DYNAMICS TECHNIQUE

Onur Mutlu¹, Ali Bahadır Olcay^{1,*}, Cem Bilgin², Bahattin Hakyemez²

¹Yeditepe University, Faculty of Engineering, Department of Mechanical Engineering, Kayisdagi Cad., 34755, Istanbul, Turkey

²Uludag University School of Medicine, Department of Radiology, Gorukle, Bursa 16059, Turkey

Introduction: Flow diverter stents provide a great solution in the treatment of giant aneurysms. However, when an interventional radiologist faces a giant aneurysm, s/he needs to make a choice of brand and model of a flow diverter stent to be placed into the neck of an aneurysm.

Purpose: In this study, the effectiveness of one of the most common flow diverter stent used in clinics, namely Surpass (Stryker Neurovascular), is assessed based on stagnation flow zones in the aneurysm sac for 48, 72 and 96 wires stent models.

Materials and Methods: A saccular aneurysm in an internal carotid artery of a forty-six years old female patient was simulated using a time-dependent computational fluid dynamics (CFD) model. A flow diverter (FD) stent is defined as a porous medium to the aneurysm neck. Massless fluid particles were introduced from the vessel inlet into the domain to identify how many particles would have actually passed thru the stent yielding inflow characteristics of the FD once CFD simulations were obtained.

Results: Particle analysis shows that although 83422 massless fluid particles sent thru the vessel inlet, nearly 40% of the seeded particles ended up inside the aneurysm region for 48, 72 and 96 wires stents while only 0.025% of the seeded particles stayed inside the aneurysm region for no stent case

Conclusion: Stagnated fluid flow zone formation of 48 and 72 wires Surpass FD showed a similar behavior while 96 wires Surpass FD demonstrated a brief squeezing formation of stagnated fluid flow zones in the sac. Stagnated fluid flow zone formations and growth of this zone can actually be associated with early stage of blood clotting process yielding quantification of FD stents' effectiveness.

Acknowledgements: This work was supported by The Scientific and Technological Research Council of Turkey (TUBITAK) under the 1001 Program, (Project no. 117M491).





OP 070

AORTIC REMODELING AFTER ANTHRACYCLINE THERAPY

Thiago Ferreira de Souza¹, Thiago Quinaglia A. C. Silva¹, Ravi Shah², Tomas G. Neilan², Fabrício P. Brenelli¹, Lício Velloso¹, Wilson Nadruz¹, José Roberto Mattos¹, Michael Jerosch-Herold³, Otávio R. Coelho-Filho¹

¹School of Medical Sciences, State University of Campinas, UNICAMP, Campinas – Brazil

²Massachusetts General Hospital, Harvard Medical School, Boston – USA

³Department of Radiology, Harvard Medical School, Boston – USA

Introduction

Anthracycline therapy is associated with adverse effects including irreversible cardiomyopathy and vascular remodeling. The nature of vascular remodeling remains controversial, with reports demonstrating an increase of pulse wave velocity (PWV), and others a decrease.

Purpose

This study investigates the vascular remodeling using PWV by cardiac magnetic resonance (CMR) imaging in breast cancer patients treated with anthracycline (240 mg/m²).

Materials and Methods

Twenty-seven women with breast cancer (mean-age 51.8±8.9 years, BMI 26.9±3.6 kg/m²), underwent CMR prior, and up to 3-times after anthracycline. CMR protocol included left ventricular ejection fraction (LVEF), mass, volumes, maximal left atrial (LA) volume and PWV measured in the aortic arch, using a phase-contrast technique.

Results

At baseline, all subjects had normal LVEF (69.4±3.6%), LV mass-index (51.4±8.0g/m²), PWV (6.26±2.354) and aortic wall thickness (2.55±0.494). At 351-700 days after anthracycline, LVEF and LV mass-index declined to 586% (P<0.001) and 366 g/m² (P<0.001), respectively. PWV decreased after anthracyclines (P<0.001), reaching a minimum of 4.93 ± 1.621m/s in the follow-up period of (368,700] days post-anthracycline (P=0.01). PWV and LA volume index were positively associated at baseline (P=0.029), but after anthracyclines this association becomes significantly weaker (P=0.009), suggesting that the change of PWV post-anthracyclines is unrelated to LA indices of diastolic dysfunction. A VLDL above its median at baseline was associated with a significant decline of PWV after anthracyclines (P<0.01).

Conclusion

The decrease of PWV after anthracycline therapy may be associated with lipid disturbances associated with anthracycline therapy. This may be due to a previously reported interaction of anthracyclines with the TG-rich VLDL fraction of lipoproteins. VLDL plays a prominent role in negative vascular remodeling, and our findings suggest that particularly patients with high VLDL before therapy may undergo a decrease of PWV after anthracyclines, independent of the degree of any pre-existing diastolic dysfunction and age.





OP 071

EVALUATION OF PTA OUTCOME IN PATIENTS WITH CRITICAL LIMB ISCHEMIA USING DYNAMIC CONTRAST-ENHANCED MRI (DCE-MRI)

Nikolaos Galanakis¹, Thomas G Maris³, Nikolaos Kontopodis², Nikolas Matthaïou¹, Christos V Ioannou², Apostolos Karantanas¹, Dimitrios Tsetis¹

¹Department of Medical Imaging, University Hospital Heraklion, University of Crete Medical School, Heraklion, Greece

²Vascular Surgery Unit, Department of Cardiothoracic and Vascular Surgery, University Hospital Heraklion, University of Crete Medical School, Heraklion, Greece

³Department of Medical Physics, University Hospital Heraklion, University of Crete Medical School, Heraklion, Greece

Introduction: Imaging modalities such as CDUS, CTA and MRA provide significant information about the distribution of macrovascular lesions of the limbs (stenoses, occlusions) in patients with peripheral arterial disease but not for the local microvascular perfusion of the feet.

Purpose: The purpose of this study is to evaluate foot perfusion in patients with critical limb ischemia (CLI) and estimate percutaneous transluminal angioplasty (PTA) results using dynamic contrast-enhanced magnetic resonance imaging (DCE-MRI).

Materials and Methods: Eight patients (5 male, median age 68 years) with CLI were examined. All patients underwent DCE-MRI of the lower limb before and within 1st month after PTA. Perfusion parameters such as blood flow (BF), K_{trans}, K_{ep} were analyzed and applied for statistical comparisons. The studies were also examined by a second observer to determine inter-observer reproducibility.

Results: Revascularization was technically successful in all patients and mean ankle brachial index (ABI) increased from 0.35 ± 0.2 to 0.76 ± 0.25 , $p < 0.05$. After PTA, mean BF increased from 6.18 ± 3.221 to 9.788 ± 3.346 , K_{trans} increased from 0.063 ± 0.024 to 0.106 ± 0.045 and K_{ep} increased from 0.102 ± 0.026 to 0.145 ± 0.026 , $p < 0.05$. All measurements demonstrated very good inter-observer reproducibility with an ICC > 0.9 for all perfusion parameters.

Conclusion: DCE-MRI may be a useful means for the diagnosis of foot hypo-perfusion. It seems also to be a promising tool for evaluation of PTA outcome, as significant restitution of perfusion parameters was observed after successful revascularization.





OP 072

INTIMA MEDIA THICKNESS IN PATIENTS WITH NON-DIPPER HYPERTENSION

Altin Cihan, Agildere Muhtesem

Baskent University, Radiology Department, Izmir, Turkey

Introduction: Ambulatory blood pressure-monitoring (ABPM) helps us to understand the diurnal variations of the blood pressure. It is well known that blood pressure reaches its highest levels in the morning, decreases slowly during the day and maintains lowest levels during the night. According to ABPM dependent classification, if nocturnal blood pressure decreases more than 10% of the day-time levels, it is called dipper hypertension and if the drop is less than 10%, it is considered as “non-dipper” hypertension which is associated with target-organ damage such as left ventricular hypertrophy, congestive heart failure, myocardial infarction, stroke and renal failure.

Purpose: The aim of this study was to investigate carotid, femoral and aortic intima media thickness (IMT) in otherwise healthy volunteers with non-dipper hypertension.

Materials and Methods: The study included 165 middle-aged, healthy volunteers (mean age: 62.05 ± 10.13; range: 28–83 years: 56 men and 109 women). According to ABPM data and participants were divided into two groups; non-dipper (n=88) and dipper pattern (n=77). On B-mode duplex ultrasound the mean IMT at the far wall of both left and right common carotid/femoral arteries and abdominal aorta were measured manually.

Results: Groups were similar regarding age and sex distributions. Both left and right carotid IMT were significantly higher in patients with non-dipper hypertension compared to controls (0.87 ± 0.18 mm vs. 0.72 ± 0.11 mm and 0.85 ± 0.17 mm vs. 0.73 ± 0.11 mm; p < 0.001 for both). However there were no significant differences between the groups in terms of femoral and aortic IMT (0.67 ± 0.18 mm vs. 0.65 ± 0.18 mm and 0.20 ± 0.21 mm vs. 0.21 ± 0.22 mm; p > 0.05 for both).

Conclusion: Patients with non-dipper hypertension seem to have increased carotid IMT which is a predictor of atherosclerotic process. However differences in femoral and aortic IMT are not significant. Non-dipper hypertension may affect IMT in carotid arteries earlier than femoral and aortic IMT. Further studies are needed to confirm these results.





OP 073

CTA IN THE FOLLOW-UP OF PATIENTS AFTER ENDOVASCULAR ABDOMINAL AORTIC ANEURYSM REPAIR (EVAR): MECHANISMS OF EVAR FAILURE AND SURVEILLANCE STRATEGIES

Daniil G., Arvaniti M., Papadimitriou A., Torounidis I., Kotsidi A., Kaitartzis C., Panagasidou L.
 Radiology Department of General Hospital of Thessaloniki "G. Gennimatas", Greece

Introduction: Endovascular aneurysm repair (EVAR) is the most common treatment for abdominal aortic aneurysms (>70%). Lifelong surveillance after EVAR has been well-accepted. Guidelines suggest CTA performed at 1, 6, and 12 months post EVAR and annually, thereafter, for at least 5 years.

Purpose: To review normal CTA findings of different types of stent-grafts, describe imaging findings of early and late EVAR complications and add our experience-based estimation upon the existing CTA follow-up imaging protocols.

Materials and methods: Within a 9-year-period, 312 patients underwent post EVAR CTA in our institution, in accordance with the international post EVAR surveillance guidelines, with CTA being effective in the detection of the full spectrum of possible complications.

Results: Primary endoleaks (1st CTA, 1 month post EVAR) were present in 35 patients (18%). The majority was type II (> 80%), which are independent of device selection and carry a relatively benign course. 3 patients had type I endoleak (3%). Presence of endoleak on initial CTA significantly increased the need for a secondary procedure within 5 years. Type I and III endoleaks were associated with higher rates of reintervention (48% for type I, 20% for type III, and 6% for type II). Persistence of a type II endoleak on follow-up imaging correlated with sac enlargement, and reintervention. 4 patients had stent-graft migration, 9 iliac had limb stenosis and 7 iliac limb occlusions.

Conclusion: Absence of endoleak on CTA at 30 days was associated with a 90% freedom from aneurysm-related morbidity rate at 5 years, compared to patients with endoleak. Our results suggest that, if CTA findings 1 month after EVAR are negative for abnormalities, additional CTA imaging can be delayed for up to 2-3 years.





OP 074

DRUG COATED BALLOONS AS A NEW METHOD FOR TREATING PERIPHERAL ARTERIAL DISEASE OF THE LOWER EXTREMITIES

Milan Pantelić¹, Miloš Dujović¹, Tamara Vučinić¹, Aleksandra Medan¹

¹Zvezdara Clinical Hospital Center, Department of Radiology, Belgrade, Serbia

Introduction Peripheral arterial disease (PAD) includes extracranial carotid and vertebral artery disease, upper and lower extremity arterial disease, mesenteric arterial disease, renal artery disease and diffuse artery disease. The prevalence of PAD in general population is up to 10%, while in population aged 70 and over it's even up to 20%. PAD of the lower extremities is most commonly localized in the femoral-popliteal region (FPR) with different clinical presentation from asymptomatic to symptomatic. . The therapeutic approach in PAD is based on conservative, surgical and/or endovascular therapy.

Purpose The aim of this research is to consider the possibilities, advantages and disadvantages of the new therapeutic approach in PAD FPR through percutaneous transluminal angioplasty (PTA) with drug-coated balloons.

Materials and Methods The study included 45 patients with the symptoms of PAD in the lower extremities. The stage of the disease was estimated according to the Fontaine classification. The diagnostic suspicion of the PAD was based on the anamnesis and on the calculation of Ankle-Brachial Index. The diagnosis of PAD was confirmed by Doppler ultrasound examination and multidetector computed tomographic angiography or by the conventional invasive arteriography of the lower extremities. The inclusion criteria included: type A, B and C lesions according to TASC II classification. The exclusion criteria included: type D lesion according to TASC II classification, allergy to iodinated contrast media, Paclitaxel, Clopidogrel or Acetylsalicylic acid, renal insufficiency and coagulation disorder. All patients were treated with drug-coated balloon angioplasty . The follow up period was three months. Clinical success, technical success and clinical failure were defined.

Results The intervention was technically successful in 39 patients (86.7%), and unsuccessful in 6 patients (13.3%). Clinical success was reached in 36 patients (92.3%), while that was not the case with three patients (7.7%).

Conclusion PTA with drug-coated balloons is an efficient and successful method for the treatment of PAD FPR.





OP 075

BRONCHIAL ARTERIES EMBOLIZATION

I.Antonakou, D.Stefanou, P.Petaloudis, A.Tsokas, A.Anagnostopoulou, D.Tomais, I.Kalogeropoulos, Th.Kratimenos,
 Radiology Department, Intervention Radiology Unit ,Evangelismos Hospital

Introduction: Massive hemoptysis is a frightening and potentially life-threatening clinical event. Bronchial artery angiography with embolization has become a mainstay in the treatment of hemoptysis.

Purpose:

Massive hemoptysis is a life threatening emergency condition, the treatment of which has been established in the modern clinical practice of embolization of the bronchial arteries. Our goal is to communicate our department's experience with bronchial artery embolism as well as to evaluate the safety and the adequacy of the method.

Material & Method:

30 patients with acute mass hemoptysis were treated in our department during 2016-2018. All patients before being brought to the Interventional Radiology Unit were submitted to a CT scan with intravenous contrast imaging. Femoral access was performed using a Simmons or Cobra 5F catheter and selective bronchial artery angiography, while polyvinyl alcohol (PVA) particles of 300-500, 500-700 μm in diameter, as well as detachable metal coils of small diameter and length (2X2, 2X3 etc) were used for embolization. Selective catheterization of intercostal arteries, subclavian and mammary arteries was performed, as appropriate.

Results:

Of all our patients, the 27 were successfully treated. One patient was admitted to the Intensive Care Unit due to continued hemoptysis while 4 patients had recurrence of hemoptysis and a new embolization session was required. No paraparesis was observed in any of the patients who received embolism.

Conclusion:

Transdermal embolization of the bronchial arteries is a lifesaving and safe invasive method to treat mass hemoptysis with good results. It also recommends a first line therapy in order for the patient to undergo causative-surgical treatment at a second time and not in the ultra-acute phase.





OP 076

DIAGNOSTIC AND MANAGEMENT OF VENOUS ACCESS DEVICES THROMBOSIS

Mikhail Cherkashin, Natalia Berezina, Denis Puchkov, Alexey Nikolaev, Daria Kuplevatskaya

Medical Institute n.a. Berezin Sergey, Saint Petersburg, Russia

Introduction

Venous access devices are widely used in cancer patients. In 6 - 15% of patients devices thrombosis revealed during chemotherapy. Venous ports malfunction challenging patient management and timely diagnostic is very important.

Purpose

To implement diagnostic and management algorithm for venous ports malfunction.

Materials and Methods

In our analysis 325 patients with implanted central venous port were included. Mean patients' age was 45 y.o. Access distribution: subclavian n=298, jugular n=22, femoral n=5. After intervention every patients were included in observational program: visits to surgeon (1, 3, 6 and 12 months), subclavian and superior caval vein ultrasound examination and echocardiography. In case of pulmonary embolism suspicion - chest CT and pulmonary CT angiography were performed. In case of device occlusion - X-Ray scopy by C-arm with contrast enhance.

Results

In 39 patients (13.5%) venous thrombosis or device occlusions were revealed. All these patients received low- molecular weight heparin (LMWH). In 11 cases anticoagulation was ineffective and local thrombolysis with active thrombotic masses aspiration was performed. On the first step by C-arm X-ray investigation devices occlusions were confirmed, then thrombolytic agent was injected into the system with mean 20 min exposition and after good blood aspiration patency was confirmed by venography. Initial success was achieved in 9 patients (81.8%). In 2 patients we have performed device explantation due to absence of recanalization and risk of thrombosis progression.

Conclusion

Active VTE monitoring in oncologic patients with implanted central venous access systems for long-term chemotherapy is the important part of disease management. Aggressive tactic with device recanalization allows to continue life-saving chemotherapy.

DISCLOSURE Authors disclose absence of any conflicts of interest





OP 077

STENTING OF SUBCLAVIAN ARTERY IN STEAL SYNDROME COMPARED WITH CONVENTIONAL SURGICAL TREATMENT

Lukic Borivoje, Cvetec Vladimir, Radmili Oliver, Colic Momcilo, Masulovic Dragan, Maksimovic Ruzica
Radiology Clinical Center of Serbia

a) Introduction

A phenomenon of subclavian steal is caused by occlusion or stenosis of the proximal subclavian artery with subsequent retrograde filling of the subclavian artery via the ipsilateral vertebral artery.

b) Purpose

The aim of this research was to compare surgical method [carotid-subclavian bypass grafts (CSBG)] and endovascular methods PTA and stenting of subclavian artery from the aspect of immediate and long-term results.

c) Materials and Methods

Thirty patients [16 (53.33%) males], of average age between 60.1 ± 8.25 years were treated with CSBG and compared with a group of forty patients [18 (45%) males], of the average age between 57.75 ± 6.15 years treated by PTA and stenting of subclavian artery. All patients were followed-up after 1, 6 and 12 months post-procedure, and annually thereafter.

d) Results

The average follow-up for both groups was 22.37 ± 11.95 months. There were 2 (6.67%) procedural complications in the CSBG group (transient ischemic attack in 2 patients) and 3 (7.5%) ones in the PTA/stent group (dissection and distal embolization in one patient and puncture site hematoma in one patient). Systolic blood pressure difference between the two brachial arteries in CSBG group was: 42.6 ± 14.5 mmHg vs 4.75 ± 12.94 mmHg. In the PTA/stent group it was: 41.2 ± 15.35 mmHg vs 3.58 ± 5.83 mmHg. Long-term success was 93.33% in the CSBG group and 92.5% in the PTA/stent group.

e) Conclusions

Both, the CSBG and PTA/stenting of subclavian artery are safe, efficacious and durable procedures. They have similar immediate and long-term results. PTA and stenting are the methods of choice for high grade stenosis, near total occlusions and segment occlusions of subclavian artery. CSBG is indicated in case of diffuse occlusive lesions and when the PTA and stenting do not succeed or cause complications.





OP 078

ANEURYSMS' TREATMENT EFFICACY BY DIFFERENT ENDOVASCULAR TECHNIQUES: A SINGLE NORTHEASTERN GREEK CENTER EXPERIENCE

Tsaoulia Aikaterini, Birbilis Theodosios, Souftas Vasileios, Tsiknidis Michael, Frigkas Konstantinos, Mantatzis Michalis

General University Hospital of Alexandroupolis, Alexandroupolis, Greece

Introduction: After the first detachable coil system was used in the 1990s, endovascular treatment of cerebral aneurysms evolved dramatically, from balloon and stent assisted coiling to the latest innovation of flow diverters.

Purpose: This review aims to compare the efficacy of different neurovascular techniques in cerebral aneurysm treatment.

Materials and Methods: All consecutive patients treated in our department between January 1st, 2015 and May 31st, 2019 were included in this study. We retrospectively checked the department's database for all treated aneurysms. Traumatic, pseudoaneurysms, infectious, and tumorous aneurysms were excluded from this review. Aneurysms that had a 6-month follow up were taken into account.

Results: 97 aneurysms were treated in 92 patients (56F, 60,9% - 36 M, 39.1%). 65 (67%) were treated by simple coiling, 18 (18,6%) treated using a flow diverter and 14 (14,4%) by stent assisted coiling. Coiling resulted in total occlusion in 59% of the aneurysms, flow diversion in 85% and stent assisted coiling in 89%.

Conclusion: Aneurysm embolization with coiling whether it is assisted by stenting or not, proved to be a safe procedure in our department. Usage of stents improves vastly long-term permanent occlusion.





OP 079

BILATERAL CATHETERIZATION AND SAMPLING OF ADRENAL VEINS IN PATIENTS WITH DRUG RESISTANT HYPERTENSION (AVS)

Panagiotis Petaloudis, Danai Stefanou, Tsokas, Anastasios Tsokas, Christina Sierrou, Pavlos Ampatzis, Dimitrios Tomais, Ioannis Kalogeropoulos, Theodoros Kratimenos
 Radiology Department Interventional Radiology Unit, Athens Greece, General Hospital 'EVAGGELISMOS, Athens Greece

Purpose

To highlight in detail the method of bilateral catheterization and sampling of adrenal veins and underline the value of this procedure at cases of drug resistant hypertension caused by primary aldosteronism.

Materials and Method

Primary aldosteronism (PA) causes almost 1/3 of cases of drug resistant hypertension. Adrenal vein sampling (AVS) is a procedure entailing the measurement of aldosterone from both adrenal veins, to diagnose an adrenal source of excess aldosterone secretion. Primary Aldosteronism may be caused by unilateral or bilateral adrenal pathology. This distinction is critical, as unilateral etiologies are surgically curable, whereas bilateral causes are often medically managed. Identifying these sources by venous sampling is critical.

In recent studies comparing the diagnostic value of CT with AVS, CT has unclear results at a rate of 68%. There is also the inherent weakness of CT to diagnose adenomas of adrenal glands with a diameter of <1cm, which are 50% of the functional ones.

Adrenal vein sampling (AVS) is the gold standard test to localize sources of excess aldosterone. AVS can be technically challenging, although performed by experienced interventional radiologist technical success exceeds 90% and can reliably diagnose the etiology of PA.

Technical aspects of the procedure are reviewed.

We report our recent experience with 7 AVS, performed in the period Jan. 2018 - May 2019.

Results

Adrenal veins catheterization was successful in all patients. No complications occurred and all patients tolerated the procedure well. In all patients the AVS established the diagnosis of either having bilateral idiopathic hyperplasia, or unilateral aldosterone – producing adenoma.

Conclusion

In conclusion, AVS is a safe procedure with a high technical success rate among experienced operators. It is the gold standard test in diagnosing unilateral sources of aldosterone in patients with primary aldosteronism and is indicated in all patients who are surgical candidates for potentially curative adrenalectomy.





MUSCULOSKELETAL-MISCELLANEOUS

OP 080

THE USAGE AND EFFICIENCY OF DRUG ELUTING STENTS IN VERTEBRAL OSTIAL STENOSIS

Geyik Serdar ,Yavuz Kivilcim, Saatci Isil, Cekirge Saruhan

Koc University School of Medicine Department of Radiology, Istanbul Turkey

Introduction: Extracranial vertebral artery atherosclerosis is an insidious and hazardous disease. Previous trials with balloon expandible bare metal coronary stents have shown that the primary stenting of vertebral artery origin stenosis can be carried out safely with high technical success despite relatively high in-stent restenosis-rates. With technological development and accumulating experience, antiproliferative drug eluting stents became a viable option for reducing the in-stent restenosis of the origin of the vertebral artery. Here, we evaluated the technical success rates, efficiency, clinical and angiographic results of the usage of drug eluting stents in vertebral ostial stenosis.

Material and Methods: 28 stents were implanted in 24 patients with vertebral artery origin stenosis. Digital subtraction angiographic or CT angiographic follow up was made at 6, 12 and 24 months.

Results: Paclitaxel eluting stents were placed with high technical success for the treatment of vertebral artery origin stenosis. There was no procedure related mortality. However one patient succumbed to death due to aspiration pneumonia for a basilar artery stroke with successful stenting and thrombolysis procedure. There was only one limited subclavian artery dissection in a patient (3.7%) during the procedure which was managed conservatively. One patient (3.7%) had in-stent restenosis on early period (6th month) and one patient (3.7%) had recurrent neurological symptoms on follow up (9th months). In a median follow up of 13 months (6-25 months) none of the patients had late stent thrombosis.

Conclusion: Vertebral artery ostial stenosis can be treated effectively and safely with high technical success- and low in-stent restenosis rates with paclitaxel drug eluting stents. With low restenosis rates the antiproliferative drug eluting stents are an option for reducing the vertebral artery in-stent restenosis.





OP 081

SACROPLASTY: A SINGLE CENTRE EXPERIENCE, INCIDENCE AND OUTCOMES

Roger Smith Neuroradiologist, Assistant Professor University Health Network
Uhn Toronto Western Hospital, University of Toronto, Canada

Sacral insufficiency fractures (SIF) cause severe pain and debilitation. Delays in the diagnosis and ignorance of treatment options, frequently result in loss of mobility, loss of independence, chronic pain, opioid dependency and chronic neurologic symptoms and deficits.

Literature to date has been lacking for SIF however as with other major osteoporotic fractures causing immobility and deconditioning they have an increased risk of mortality with a 6-month mortality rate of 9.8%, a 1-year mortality rate of 17.5%, and 3-year mortality rate of 25.5%. This is clinically and socially significant.

Traditionally considered a condition of the elderly, osteoporotic SIFs were managed conservatively. Today cancer care patients have increasing expectations of long term survival and improved quality of life. As a result secondary osteoporosis post pelvic radiation (cervix, uterus, ovary, prostate) and steroid use in chemotherapy for myeloma and metastatic disease are now common and frequent causes of SIFs.

This is reflected in the increasing referral pattern to a single centre performing vertebral augmentation associated with a major Cancer Care Centre.

Fig 1

Sacroplasty has been increasingly acknowledged as an excellent procedure for relieving the pain of sacral insufficiency fractures (SIF) and more recently metastatic fractures.

Outcomes and technique in 130 patients (2009-2018) will be presented with the development of a new lateral sacroplasty technique (1), rationale and preliminary results.

1. Single-Needle Lateral Sacroplasty Technique, P.J. Nicholson, C.A. Hilditch, W. Brinjikji, A.C.O. Tsang and R. Smith. American Journal of Neuroradiology November 2018, DOI: <https://doi.org/10.3174/ajnr.A5884>

Fig 2

Figure 1: Increasing sacroplasty frequency in a single centre with a large Cancer Centre

Figure 2: Lateral single needle sacroplasty technique.





OP 082

RADIO-FREQUENCY ABLATION: APPLICATIONS AMONG PAEDIATRIC PATIENTS WITH OSTEIOD OSTEOMA

Thanou Ioanna, , Hia Botsa Evant, Thanos Loukas

Imaging and Interventional Radiology Department, Sotiria General Hospital, Athens, Greece

Introduction: Osteoid osteoma represents 10% of all benign bone tumors. They are located most frequently in the cortex of the diaphysis of the femur or tibia but may occur also in nearly any part of the body. The most important clinical symptom is pain that is more severe at night and responds to non steroidal anti-inflammatory drugs .

Purpose: Evaluation of safety and efficacy of computed tomography guided radiofrequency ablation as a minimal invasive treatment technique of osteoid osteoma in pediatric patients .

Materials and Methods: We performed a retrospective study with 34 children with osteoid osteoma (M:20,F:14,MEAN AGE:13,4 years,RANGE :9-18 years). The diagnosis is based on severe pain, relief of pain after administration of NSAID, and computed tomography radiological features. Duration of pain before application to the outpatients department varied ref:1. All patients had received medical therapy with NSAID (?) before procedure. All radio frequency procedures were performed under sedation. All procedures were done under CT guidance with minimum radiation dose (80 KV, 33mAs, Slice Width =5 mm, Feed/Rotation = 16, Kernel B40, CTDI = 0,9. Duration of thermal ablation was 8 to 10 minutes (mean time 9,7min) accordingly the lesion and the temperature used was about 80-110 °C.

Results: All ablations were technical successful. Clinical efficacy was 94,1% (33/34) and was estimated with Brief Pain Inventory (BPI) before the ablation and one week, one month and one year after the treatment. Two patients underwent a second ablation. None major complication occurred. Post ablation syndrome was reported to 4 patients. All pediatric patients were dismissed after 24h hospitalization.

Conclusion: Radiofrequency ablation is an effective, minimal invasive treatment with low rate of complications and referred relapses ideal for pediatric patients.





OP 083

PERCUTANEOUS TREATMENT OF LOW BACK PAIN USING MIXTURE O2O3: OUR EXPERIENCE

Kristina Davidović, Ružica Maksimović

Faculty of Medicine, University of Belgrade, Center for radiology and magnetic resonance imaging, Clinical Center of Serbia, Belgrade, Serbia

Introduction: Oxygen-ozone therapy is a minimally invasive treatment for lumbar disc herniation that uses the biochemical properties of the gas mixture of oxygen and ozone. We evaluated the therapeutic outcome of this therapy by monitoring and testing the patient immediately after the procedure, a month and three months after the procedure

Methods. In the period from February to June 2019, the procedure of oxygen-ozone therapy was performed in 45 patients with a diagnosis of lumbar disc herniation. All of them showed clinical signs of compression of the nerve root of the lumbar disc, with MR evidence containing the lumbar disc herniation. Patients were administered a mixture of oxygen-ozone at a concentration of 33 microgr-ml in an amount of 5-25 ml. Depending on the symptoms and MR findings, patients received a peridural injection of corticosteroids and anesthetics. The therapeutic outcome was evaluated immediately after the procedure, between one day later and three months after the procedure using the modified MacNab method, Global Pan Scale and Pain Scale.

The results. At all patients, immediate relief was achieved immediately after the procedure.

Postpartum lesions in postural headaches as a result of peridural anesthesia or after transdual manipulation were observed in 5 patients. After a month, in 38 patients, an excellent or good result was achieved. After three months, 42 patients observed an excellent or good result.

Conclusion: Oxygen-ozonotherapy of the lumbar disc herniation produces positive results and a low morbidity rate when administered percutaneously for the treatment of chronic pain in the lower back.

Key words: Oxygen-ozone disc herniation, minimal invasive.





OP 084

NORMAL ABDOMINAL MUSCLE THICKNESSES IN ADOLESCENTS: A SONOGRAPHIC STUDY

Fatihoglu Erdem - Aydin Sonay

Sami Uus Training and Research Hospital, Department of Radiology, Ankara Turkey

Introduction: The lateral abdominal muscles, transversus abdominis (TA), internal oblique (IO), and external oblique (EO) contribute to the stability of the trunk. So that, abdominal muscles are important for the management and prevention of low back pain (LBP). In the literature, it is easier to find normal ranges of abdominal muscle thickness for adult population.

Purpose: In the current study, we aim to determine normal values of TA, IO, and EO thickness in adolescents.

Materials and methods: 200 healthy children between the ages of 12-18 are included into the current study. US exams are performed with a 7.5-MHz linear array transducer. Abdominal muscle thicknesses were measured at rest. The transducer was placed transversely, in the anterior axillary line, between the 12th rib and the iliac crest.

Results: Mean muscle thickness of all three muscles is higher in boys than girls. Mean thickness of IO is the biggest and the order of muscle thickness is the same between boys and girls (IO>EO>TA). There is a negative correlation between age and IO and EO muscle thicknesses. We cannot detect such a correlation between age and TA muscle thickness

Conclusion: Knowing the normal thickness value of abdominal muscles can help diagnosis of pathologies like LBP and follow up of athletic training. Thickness of muscles lines up as IO>EO>TA. BMI, weight is positively correlated with muscle thickness. Age is negatively correlated with IO and EO muscle thicknesses.

Keywords: Abdominal muscle thickness, normal, ultrasound, adolescent

Table 1: Mean muscle thickness values in girls:

Girls		Mean (mm)
Right	TA	2.53±0.21
	IO	4.30±0.80
	EO	2.97±0.47
	SF	3.05±0.27
Left	TA	2.55±0.27
	IO	4.23±0.76
	EO	2.95±0.45
	SFT	3.03±0.29

TA: Transversus abdominis, **IO:** Internal oblique,
EO: External oblique, **SFT:** Subcutaneous fat thickness,
BMI: Body Mass Index





Table 2: Mean muscle thickness values in boys:

Boys		Mean (mm)
Right	TA	2.71±0.13
	IO	5.31±0.87
	EO	3.22±0.56
	SF	3.01±0.21
Left	TA	2.68±0.17
	IO	5.19±0.72
	EO	3.18±0.47
	SFT	3.07±0.30

TA: Transversus abdominis, **IO:** Internal oblique,
EO: External oblique, **SFT:** Subcutaneous fat thickness,
BMI: Body Mass Index

Table 3: Correlations between variables

	Age		Weight		Height		BMI	
	R	p-value	R	p-value	R	p-value	R	p-value
Mean TA	-0.067	0.542	0.479	0.001	0.249	0.003	0.414	0.001
Mean IO	-0.237	0.004	0.574	0.001	0.422	0.001	0.422	0.001
Mean EO	-0.224	0.005	0.400	0.001	0.785	0.681	0.323	0.001
Mean SFT	-0.257	0.675	0.422	0.001	0.347	0.482	0.368	0.001

TA: Transversus abdominis, **IO:** Internal oblique,
EO: External oblique, **SFT:** Subcutaneous fat thickness,
BMI: Body Mass Index





OP 085

THE IMPORTANCE OF TUMOR CONTACT LENGTH AND ADC PARAMETERS TO PREDICT MUSCLE INVASION OF BLADDER CARCINOMA ON MAGNETIC RESONANCE IMAGING

İsmet Gulmez,¹ Ismail Caymaz,² Ibrahim Inan,³
İstanbul Turkey

Introduction

Tumor contact length(TCL) with the bladder wall and ADC(Apparent diffusion coefficient) parameters have been considered useful to predict muscle invasion of bladder carcinoma(BC) on 1.5 Tesla magnetic resonance imaging(MRI).

Purpose

To investigate the importance of values of TCL and ADC parameters for prediction of invasion of BC on MRI.

Materials and Methods

This study were included 28 patients with 36 pathologically confirmed tumor lesions. Invasion was performed according to TNM classification system. The aggressiveness of bladder cancer pathologically was classified as low and high-aggressiveness. The largest TCL and the largest depth(D) of the tumor was measured on the axial and sagittal T2 weighted MRI. Additionally on the ADC, ROI values from the normal wall of the bladder, intratumoral and the tumor invaded wall were measured.

Results

The TCL and D of lesion were found to be statistically significant between the patients invasion and non-invasion groups ($p = 0.001$, $p = 0.016$, respectively). The rate of the intratumoral ADC value to the the normal bladder wall ADC value and the rate of the invaded bladder wall ADC value to the normal bladder wall ADC value was statistically significant in the determination of invasion ($p = 0.0001$ and 0.019 respectively).

Conclusions

MRI measurements of adc parameters and TCL have good potential to assess invasion but should be confirmed these findings in larger groups of patients.





OP 086

RADIOLOGY END ART

Daskalov Blagoja, Daskalov D.
Skopje, R. North Macedonia

Introduction

Thanks to some doctors of our life, who raised Radiology to the level of art, I began to feel the radiology and try to use it in several parts of the art.

Civilization, from the very beginning of its existence, ilife, it is related to art - painting, sculpture, music, architecture ...

Continuity on this is the numerous evidence, founds arte facts, from the beginning until presents days.

Radiology, physics, from the beginning (1895), became a fundamental driver in the development of medicine, involved in art, with the analyzes made in all of its parts.

Material and methods

MDCT is a workstation, as a basic instrument for the annexation of more artefacts. These are some examples of our work with artifacts from our region.

Vase- Veles, NM, 2005,

Hunter wise, 6000bs, Neolith,

Antic Pot- (Demetra) VI-V bc,

Okarina, 6000bs,, 6000bs Neolith, Musical Instrument locality Mramor, Veles, Chashka, 1989 4,7 centimeters and hollow interior.

Goddess / Vardar rid-IIbc Cybele, (Demetra, Aphrodite)

Greater Mothers Goddess / patroness of fertility- 5000bc, neolith, Tumba Madzari, Sk NM

Kaval- Pipe Cavalry is a Macedonian folk wind instrument open on both sides, carved out of an assed piece and ornamented throughout its length

Zurla-Zurla is a Macedonian folk wind instrument made of walnut or plum tree.

Wine-Sorrow for the south- Brandy-yellow/ Ouzo 2010

Coclusion Do not try to divide the art from science, the Radiology from art,

It's impossible, science and art are life, you try to be part of that universal wisdom,

Science, art and frendship, you will be the best.





OP 087

RADIATION DOSES FROM CT EXAMINATIONS; LOCAL DIAGNOSTIC REFERENCE LEVELS STUDY

Atli Eray, Cevik Cenkeri Halime, Oguşlu Umut, Uyanıksadık Ahmet, Gumus Burcak
Okan University Hospital Department of Radiology, Istanbul Turkey

Introduction: Day by day increased usage of CT raises the concern of cancer risk attributed to increased X-ray exposure, which is a main limitation of CT scans. Although number of CT examinations among all X-ray used procedures are low, it contributes the largest portion of radiation exposure from medical sources, such as 66 % in the United States (USA), and 47 % in the United Kingdom (UK). Thus, needless usage should be avoided and patients should be protected from detrimental effects of X-rays from CT examinations. First step for optimization, it is recommended to compare CT scan parameters and patient radiation doses with diagnostic reference levels (DRLs). Radiologists use DRLs as reference point to evaluate their radiation dose parameters and identify whether if their radiation parameters are within the specified reference ranges.

Purpose: To obtain local DRLs for head, neck, chest, and abdominal CT examinations from routine patients.

Materials and Methods: Single-phase head, neck, chest and abdominal CT scans of adults performed in 2018 were included in this study from one institution. Radiation dose parameters of CT scans were obtained retrospectively from PACS. Mean CTDI_{vol} and DLP values were recorded. Effective dose (ED) and scan length (SL) was calculated. Mean, SD, and first, second, and third quartiles values of CTDI_{vol}, DLP, and ED were calculated.

Results: Third quartile CTDI_{vol} (mGy), DLP (mGy.cm) and ED (mSv) values was 59, 1129 and 2.3 for the head; 14.8, 378 and 2.2 for the neck; 10.8, 416 and 5.8 for the chest, and 12.5, 656 and 9.8 for the abdomen. Compared to DRLs of national, European and USA, overall there is need for optimization in head and abdomen CT examinations obtained in our institution.

Conclusion: A new data set of local DRLs for adult head, neck, chest, and abdominal CT examinations were reported from one year CT scan experiences from one institution.





OP 088

APPLICATION OF ADVANCED MEDICAL IMAGING TECHNOLOGY IN BANGLADESH

Mohammad Shamsuddin

Joint Secretary ,Bangladesh Association of Radiology and Imaging Technologist

OBJECTIVES:

Like other part of the world Bangladesh healthcare industry is currently undergoing major changes in an effort to control costs and increase efficiency without compromising patient care. In the past, this care was delivered through only few healthcare specialists but as the number of specialists is increased the scenario is changing. For last 5 years Bangladesh underwent tremendous advancement in the field of Radiology & Imaging in terms of introduction of cutting edge technologies along with -parallel up gradation of the technologist's demands assessment for optimum utilization of these facilities.

METHODS:

Advanced medical facilities (Govt&Non-govt) having latest equipments of the different modalities throughout the country were studied by onsite visits. Data were collected from the patients, institutions and supplier of the equipment in these facilities.

RESULTS:

In Bangladesh the use of advanced diagnostic imaging in the Medicare population has increased significantly over the last 5 years, particularly using expensive new technologies such as computed tomography (CT), magnetic resonance imaging (MRI), Interventional radiology, positron emission tomography-CT (PETCT), PACS and Teleradiology. The development and improvement in these advanced technologies is widely credited leading to earlier and more accurate diagnosis & treatment of disease using noninvasive or less invasive techniques. However, new methods for improved image reconstruction, image segmentation, modelling of organs, as well as methodical improvements of non-linear image registration algorithms are presented together with applications of image analysis methods in different medical disciplines are also progressing in Bangladesh but needs more effort & assistance from advanced sources.

CONCLUSION:

Advanced Medical Imaging is committed to help our patients. Advanced diagnostic imaging can benefit patients when used appropriately as it detects diseases at early stage and it allows health care practitioners to guide patients to take proper health care services they need. But, when used inappropriately, advanced diagnostic imaging provides practitioners and patients with minimal clinical benefits, wastage of scarce health care resources and can even jeopardize patient's safety.





OP 089

RADIOGRAPHERS EDUCATIONAL SYSTEM & PRESENT CONDITION IN BANGLADESH.

Mohammad Maruf Khan

Taleour General Hospital (Pvt) Ltd.

Objective

After 200 years of British Colonial rule. We Bangladeshi People became the ruthless victim of Barbarous Pakistani for 24 years. For the sake of independence, Bangladeshi People started the Liberation War on March 26, 1971. After the nine month bloody war, Independence is attained in exchange for three millions lives.

METHOD

A) Course details -1) Diploma in Medical Technology (Radiology & Imaging), State Medical faculty is affiliation body. 2) Conditions for entrance -a) Qualifications & Pre-requisite 1) SSC Science equivalent with Science with Physics & Chemistry, Candidate has to Secure with 2nd Division or equivalent GPA-2.5, candidate passed SSC examination in current year & previous 3 years is illegible for admission. Course Structure & duration is First year, Second year & Third year.

RESULT

B) BSC in Radiology & Imaging Technology in (Honours)-1) Admission requirements :A candidate with SSC (Science Group) & HSC (Science Group) or their equivalents is eligible to apply with a minimum CGPA of 2.5 in either one & a combined CGPA of 6.2) Course to be Covered :Radiological Anatomy Part-1, Basic Biology, Basics of information & communication Technology, Radiology imaging & Physics, Radiological Anatomy -part 2, Radiological Physiology, Communication & Signal processing, Conventional Radiography, Radiological Pathology, Radiological Photography & Quality Assurance, Interventional Radiography part 1, Radiological Findings part-1, 2. Residential field practice, Special Radiological Procedure, Hospital Management. 3) Credit & Duration -This program will be conducted on a course & Credit based structure with 37 number of course to be dispensed in 160 credits in total, completed in a minimum time span of 4 years.





ABSTRACTS — EPOSTERS



PP 001

MR FINDINGS OF POST-OPERATIVE COMPLICATIONS RELATED TO ANTERIOR CRUCIATE LIGAMENT GRAFT RECONSTRUCTION

Evangelia Papadaki¹, Eleni Soulounia¹, Nikolaos Glentis¹, Aris Mpampis¹, Marios Georganas¹, Eleni Tsiompanou¹

¹General Hospital of Rhodes, Greece

Introduction

As untreated post-trauma ACL deficiency due to ACL tear, can lead to damage of articular cartilage and menisci, the graft reconstruction of the anterior cruciate ligament (ACL) has become a popular and well accepted treatment during the last decades.

Purpose

To provide an overview of the imaging findings of post-operative complications in individuals who had undergone Anterior Cruciate Ligament Graft Reconstruction.

Materials and Methods

We reviewed MRI knee examinations during the last 3 years. Examinations with ACL reconstruction have been evaluated for normal and abnormal findings. MR was performed with 1.5 Tesla Philips imager. Imaging sequences included proton density (PD) turbo spin echo (TSE) fat saturation (FS) images in three planes, T1 in coronal plane, T2 FFE in sagittal plain.

Results

We categorized patients with graft reconstruction of the anterior cruciate ligament (ACL) in three groups. Patients with normal findings of graft caliber, signal intensity, and bone tunnel position, patients with signs of roof impingement and of partial or complete ACL graft tears and patients with complications of ACL graft reconstruction such as hardware failure, infection, tunnel cysts and iliotibial band friction syndrome.

Conclusion

MRI is the method of choice in defining pathology of knee's ligaments involving post-operative complications related to anterior cruciate ligament graft reconstruction. It's important for radiologists to be familiar with the spectrum of imaging findings, as early diagnosis is critical to prevent graft failure and rupture.





PP 002

ABNORMAL SPINAL CORD MAGNETIC RESONANCE SIGNAL: IMAGING FINDINGS AND DIFFERENTIAL DIAGNOSIS OF NON NEOPLASTIC ETIOLOGIES

Evangelia Papadaki¹, Marios Georganas¹, Nikolaos Glentis¹, Aris Mpampis¹, Eleni Tsiompanou¹, Eleni Soulounia¹

¹ General Hospital of Rhodes, Greece

Introduction

Abnormal spinal cord magnetic resonance (MR) signal can be found in broad range of pathologies. Among the compressive myelopathies the most common etiology represents the group of Degenerative Diseases, while between the non compressive myelopathies, multiple sclerosis represents the vast majority on MRI studies.

Purpose

To provide an overview of the imaging findings of compressive and non compressive spinal cord lesions, the differential diagnosis among them and the differentiation of imaging findings from spinal neoplasms.

Materials and Methods

We reviewed MR spinal examinations during the last 3 years. Examinations have been evaluated for normal and abnormal findings of spinal cord. The exams were performed with 1.5 Tesla Philips imager. Imaging sequences included Short-TI Inversion Recovery (STIR), T2, T1 in three planes.

Results

We categorized patients with abnormal spinal cord lesions in three groups. Patients with compressive myelopathy, non compressive myelopathy and spinal cord neoplasms. Compressive myelopathy is usually in the setting of degenerative spine diseases and secondary due to compression from metastatic disease or trauma. Non compressive myelopathy includes a broad spectrum of causes including, Multiple Sclerosis, Neuromyelitis Optica, Acute Disseminated Encephalomyelitis, Nutritional causes such as B12 Deficiency, Infection (e.g enterovirus), Infraction and Vasculitis, Syringomyelia, Neurogenerative diseases (e.g Primary Lateral Sclerosis) and Arteriovenous Malformations.

Conclusion

MR is the method of choice in defining pathology of spinal cord. It's important for radiologists to be familiar with the spectrum of imaging findings, as the craniocaudal length of abnormal signal, which quadrant is involved on the transverse plane, findings indicative of cord swelling, and the contrast enhancement patterns.





PP 004

LUNATE DISLOCATION CASE REPORT

Bekir Karčić, Emina Karčić

1. Department of radiology, General hospital "prim dr Abdulah Nakaš", Sarajevo B&H.
1. Department of pediatrics, Cantonal hospital Zenica, B&H.

Introduction

Lunate dislocations are an uncommon traumatic wrist injury, typically occur in young adults with high energy trauma resulting in loading of a dorsiflexed wrist, that require prompt management and surgical repair. Although early diagnosis enabling early surgical treatment is crucial for preventing long-term sequelae, these dislocations are frequently missed in the initial assessment. Imaging tools, such as plain radiography, magnetic resonance imaging, ultrasonography, and electrodiagnostic studies, have been used for diagnosis. Despite treatment there remains a high risk of future wrist instability, median neuropathy, avascular necrosis of the lunate and degenerative arthritis.

Case report

A case of the 35-year-old patient who suffered severe polytrauma with hemorrhagic shock, fractures of the right femur (suracondylar part) and distal part of the right humerus with dislocation, after severe motorcycle accident, was presented. Six to seven days after admission to hospital the patient started to complain of the significant swelling, pain and the limited mobility of the left wrist. The X-ray of the left wrist showed signs of the palmar- lunate dislocation. Despite surgical treatment, changes of consecutive left wrist contracture have been noted.

Conclusion

The main goal of this case report is to emphasize the importance of proper choice of initial clinical and radiological evaluation tools for making an accurate early diagnosis as soon as possible. The above implies an impeccable and meticulous clinical and radiological approach to earlier diagnosis and adequate treatment of the lunate dislocation to prevent possible devastating outcomes.

Key words: polytrauma , X-ray of the wrist , lunate dislocation, contracture





PP 005

MR DIFFUSION-WEIGHTED IMAGING (DWI) BIOMARKERS OF THE HEALTHY LIVER PARENCHYMA. A REPEATABILITY STUDY

Veliou K., Priovolos D., Ghiatas A., Christou A.
 Ioannina Greece

Introduction:

In the last few years there is an interest on revealing imaging biomarkers. The ability of an imaging biomarker to act as an indicator of a biological process can be influenced by the lack of reproducibility and repeatability. Repeatability tests, refer to the variation in repeat measurements of the same imaging biomarker under identical conditions. In this study we determined the repeatability of diffusion imaging biomarkers (different diffusion models) in healthy liver parenchyma.

Purpose:

This study assessed test–retest repeatability of diffusion imaging biomarkers of the healthy liver parenchyma .

Methods and materials:

Twenty healthy volunteers (age range, 22–47 years), were imaged with a multi-b value diffusion sequence, optimized for the quantification of diffusion imaging biomarkers was acquired twice (test-retest scheme) in the same imaging session using a 1.5T MR Scanner (Siemens ,Avanto).The diffusion sequence comprised 9 b values (0, 50, 100,150, 250, 400, 600, 800, and 1000 s/mm²) and 4 different models including Gaussian mono-exponential (gm),Gaussian bi-exponential (gb), non-Gaussian mono-exponential (kurtosis model) and stretched exponential model (sem) were applied to quantify the following diffusion biomarkers: ADC(for gm model) Fp, Dt, Dp, DpxFp(for gb model) Dapp, Kapp (kurtosis) and DDC, a (sem). Variation coefficients (CV) were calculated for all diffusion biomarkers.

Results:

All CVs were lower than 10%, except Dp that was 23.5%,Fp 12% and DpxFp with 24%. More specifically, Dapp and Kapp provided with the lowest CV values (4.22% and 4.61%, respectively), followed by a (7.51%), Dt (8.38%), ADC (9.21%), DDC (10%).

Conclusion:

Both Gaussian and non-Gaussian diffusion models offer imaging biomarkers like ADC, Dapp, Dt, a, DDC and Kapp (with the exception of perfusion related biomarkers from gb model) with very high repeatability therefore longitudinal assessment of these biomarkers is feasible .





PP 006

AN UNUSUAL CAUSE OF GLOSSOPHARYNGEAL NEURALGIA: EAGLE'S SYNDROME

Kosar Tunc, Harmanci Kemal, Onder Hakan

Acubadem Mah Betul Sok Cesan Sitesi Daire No : 11 , Istanbul ,Turkey

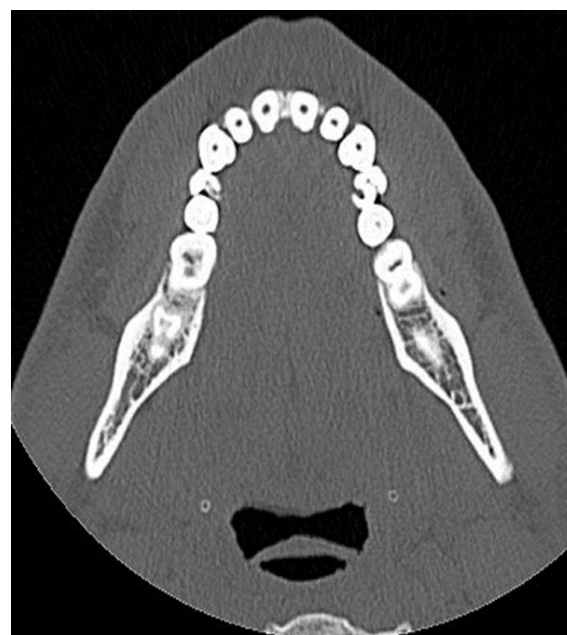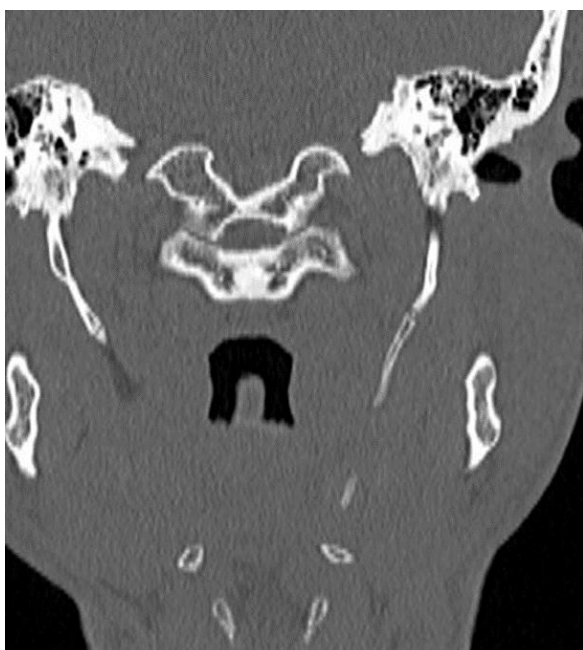Introduction: Eagle's syndrome (ES) described by Eagle in 1937, is characterized by symptomatic elongation of styloid process or calcification of stylohyoid ligament. Clinically ES causes recurrent throat and neck pain radiating into the ear, foreign body sensation and dysphagia.

Purpose: In this case our purpose is demonstrate and learn the Computered imaging(CT) findings of the Eagle's syndrome.

Case report: A 26-year-old male presented with a pain ,lasting more than a year ,beginning at the back of the tongue and throat and spreading to the ear. He also complained of difficulty speaking and swallowing. The patient underwent a CT scan of the head and neck. CT showed elongated bilateral styloid processes, of which the right side measured about 4.5 cm and the left side measured 4.7 cm.

Discussion: The average length of the styloid in an adult is approximately 2.5-3 cm whereas an elongated styloid is generally longer than 3 cm. Elongation of the styloid process is seen 4% of the general population but of these, only 4% are symptomatic. It thought that the reason of the pain is the compression of the glossopharyngeal nerve by elongated styloid process as it passes over the superior constrictor muscle.

Conclusion: Eagle syndrome is a rare cause of glossopharyngeal neuralgia. But in patients with undiagnosed throat and neck pain, an elongated styloid process should be suspected . Radiologically CT is one of the most valuable methods in the diagnosis. It can describe the length and location of styloid process.





PP 007

THE ADVANTAGE OF IMAGING MAMMOGRAMS ON FILM DURING COMPARATIVE STUDIES

Kosta G. Kappes, G. Krontira, S. Panagoy, G. Bogosian, A. Papadatou, K. Agorgianitis, L. Panaritis V.
 Radiology Department General Hospital Amfissa, Greece

PURPOSE: The purpose of our work is to show the advantage of imaging mammography on film in comparative mammography using a new method.

MATERIAL AND METHOD

We performed 20 annual comparative mammography studies using a new method of screen control. We noticed that it is a disadvantage to perform the mammograms in different laboratories due to the different imaging parameters.

To address this disadvantage of different technical parameters, we thought of introducing the term repeatability into mammography.

First we set fixed breast pressure parameters in the mammogram and secondly the constant technical values for each mammogram examination.

We also introduced to a pioneering, arbitrary model of imaging estimation.

This estimation model is based on the classification of the breast image in three equal diameters zones,

The zone A refers to the anterior part of the breast the zone B of the median, and the zone C to the posterior part of the breast.

RESULTS

Despite the few cases and the short time that we applied the method, we have seen encouraging results in improving the time required for our diagnosis in the comparative mammography examination.

CONCLUSION

We believe with our little experience that with this method of identifying the icons we are able to diagnose even the most premature changes in the comparative mammogram control.



**PP 008****PERCUTANEOUS TREATMENT OF HEPATIC ABSCESS COMPLICATED BY HEPATOPULMONARY FISTULA**

Totev Milan, Cilkov Done , Garvanska Galia, Antonova Daniela
Sofia, Bulgaria

Female, 62 y. old, operated before 10 months from hydatid cyst of the liver. 2 months after the surgical treatment she receives periodic coughing attacks and bitter and iron taste in the mouth, pain and heaviness in the right upper quadrant, and she was treated as a recurrent pneumonia. On the Ultrasound and CT examinations we established well defined, rounded cavitory lesion in the right lobe of the liver (segment 7).

Having considered that there was a high operational risk, the patient was referred to a percutaneous procedure and the cavity was drained percutaneously whereby pus had leaked. After the application of contrast media in the cavity under fluoroscopy guidance a communication with peripheral bronch from right pulmonary segment 10 was found. The contrast media filled right pulmonary bronch, carina and left pulmonary bronch in a row witch provoked cough in the patient. After 2 weeks of drainage and flush with NaCl the patient's cough disappeared. Before drainage catheter removal we injected (as with PAIR) 20 cc 95 % alcohol.

On the 25th day after the procedure, with control US examination, we established hyperdense zone without liquid equivalence component and the patient was clinically health without any complains.

The percutaneous drainage of liver abscess is an approved and well established procedure, but there are few cases with treatment of their complications, among which hepatobronchial fistula is somewhere between 1-1.8 %.

The percutaneous drainage of this complication –the hepatobronchial fistula is easy, well paced, and painless treatment with minimal complications.

PP 009**CONTRIBUTION OF COLOR US EXAMINATION IN ARTHRITIS OF THE KNEE**

Burgianos N. Kappes G. Giosi D. Dritsoulas L..Katsaounis D. Koyvli M..D.Panaritis V.
General Hospital Amfissa, Greece

Contribution of color us examination in arthritis of the knee

PURPOSE: The purpose of our work is to show the contribution of color us study of the superior lateral and medial arteries in knee arthritis

MATERIAL AND METHOD

We performed in 12 patients with acute arthritis of the knee color Doppler examination of the lateral superior genicular and medial superior genicular arteries.

We performed also color Doppler studies of the same arteries in 12 totally healthy volunteers

We did measurements of the PEAK VELOCITY ~PI ~ RI in each of the arteries

RESULTS

Despite the few cases we noticed the significant high PV PI and RI in arthritis compare to the healthy volunteers

CONCLUSION

We believe with our little experience that with this method we are able to contribute in the diagnosis of the arthritis.





PP 010

RADOMNISED US STUDY IN POPULATION WITH NO SERIOUS MEDICAL HISTORY

Spanos M.Papahristou An. Dousopoulos V. Papadopoulou A.NitsaAl. Panaritis V.
 General Hospital Amfissa, Greece

INTRODUCTION

The aim of our study is the random screening ultrasound control in order to highlight the ultrasound as a necessary test in an annual checkup

MATERIAL AND METHOD

We performed 128 ultrasound examinations 58 men and 62 women with no previous serious medical history.

All were residents of Fokida prefecture.

In a 3 month period time and at a predetermined morning appointment we performed all kind of ultrasound exams included color Doppler examinations of carotid arteries and low extremity vessels.

In 65 persons we performed abdominal ultrasound in 42 of them thyroid ultrasound in 13 of them color Doppler of carotid and vertebral arteries and in the rest 8 persons color doer of low extremities vessels

RESULTS:

In five persons we found gall bladder gallstones.

In 4 of them we found abdominal Aortic dilatation

In twelve persons we found thyroid nodules .

In 3 persons we found carotid atheromatosis with no serious stenoses and in one person stenoses up to 70% in the right internal carotid artery.

CONCLUSION

Despite the small number of cases , our randomized findings are encouraging us to consider that the ultrasound examination should be included in the annual checkup.





PP 011

NON-TRAUMATIC ACUTE ASCENDING AORTA ANEURYSM RUPTURE. EMERGENCY CT IMAGE FINDINGS. A CASE REPORT.

B Bouchra Konstantina¹, Barbagianni Eleni², Baroutsi Kyriaki¹, Stamouli Evaggelia³, Ispanopoulou Sofia¹, Fakou Anastasia¹, Kazakidis Panagiotis¹.

¹ Computed-Tomography Department, G. Hospital of Nikea, Piraeus, Greece

² Health-Center Piraeus, Greece

³ Radiology-Department, General Hospital "Hippocrates", Athens, Greece

⁴

a) Introduction: Acute rupture of the aorta is the most severe complication of aortic aneurysm and highly related to the diameter of the aneurysm. In the literature, there is a remarkable percentage of thoracic aortic aneurysms especially involve the ascending aorta and quite great risk of rupture, yearly, of those with maximal diameter larger than 60mm. Thoracic aneurysms are even more life threatening than the abdominal due to the acute heart failure that may cause after their rupture into the mediastinum, pleural space or pericardium as a result of compression effects.

b) Purpose: To report a patient's sudden death due to acute rupture of a 48mm ascending aortic aneurysm and highlight measurement thresholds for surgical intervention.

c) Materials and Methods: A 62-year-old male with known hypertension and atherosclerosis was admitted with heavy dyspnea and shortly after, severe hypotension. He never underwent any specific examination of body great vessels and no family related disease was known.

Unenhanced CT scan revealed a large, moderately hyperdense (30HU) pericardial effusion and mild cardiomegaly. The ascending aorta was measured 48mm in diameter. After contrast administration detected massive extravasation, as a result of acute rupture of the aneurysm and active hemorrhage. The patient developed hemorrhagic cardiac-tamponade and he died due to sudden shock.

d) Results: Aortic rupture is a serious condition which may worsen quickly and be life threatening. Three-dimensional reconstructions mostly with data from CT scanning images may be useful tools for preoperative visualization and communication with surgeons for the treatment.

e) Conclusion: Computed tomography is the modality of choice for evaluation of acute aortic aneurysm syndrome. Radiologists should be aware of the image limitations and clinical implications of reported measurements.





PP 012

INTRAABDOMINAL ECTOPIC SPLENIC TISSUE AS A GREAT MIMICKER; INTRAPANCREATIC SPLEEN (IPAS) AND SPLENOSIS

Yusuf Gibran Timothy ,Kumar Sumantra ,Leung Rebecca

King's College Hospital Nhs Foundation Trust- Princess Royal University Hospital Farnborough
 Common/Orpington/Kent

Introduction

Intrapancreatic spleen (IPAS) is a form of accessory spleen which is a congenital entity. Conversely, splenosis is an acquired condition of heterotopic autotransplantation of splenic tissue after splenic rupture either iatrogenic or traumatic.

Both conditions are structurally identical, usually asymptomatic, and found incidentally. Radiologic appearances may cause diagnostic challenges due to confusion with other entities particularly neoplastic conditions such as neuroendocrine tumour (NET), solid pseudopapillary tumour (SPT), ovarian malignancy or hepatocellular carcinoma (HCC). Recognition of IPAS and splenosis in terms of noninvasive approach is important as treatment is not warranted unless secondary lesions arise such as torsion, spontaneous rupture, cyst formation or haematologic disorders when splenectomy may be necessitated.

Contrast-enhanced computed tomography (CT) and magnetic resonance imaging (MRI) may aid diagnosis with characteristic splenic enhancement pattern in all phases. In equivocal cases imaging modalities such as MRI with superparamagnetic iron oxide (SPIO) agents and nuclear medicine studies with Tc99m-labeled sulphur colloid and Tc99m-labeled heat-damaged red blood cell (HDRBC) scintigraphy may be used as confirmatory modalities. Contrast-enhanced Ultrasound (CEUS) has also been postulated as a further diagnostic tool for IPAS. Accurate diagnosis will not only prevent unnecessary intervention and related potential morbidity but also obviate the need for follow-up imaging and alleviate patient anxiety.

Herein we describe six cases, three with IPAS, three with intrabdominal splenosis with contrast enhanced CT, MRI and HDRBC SPECT findings.

Keywords

Splenosis, intrapancreatic accessory spleen (IPAS), contrast-enhanced computed tomography (CT), contrast-enhanced magnetic resonance imaging (MRI), Tc99m sulfur colloid scintigraphy, Tc99m heat-damaged red blood cell (HDRBC) scintigraphy, single-photon emission computed tomography (SPECT)





PP 013

ENDOVASCULAR TREATMENT OF STEAL SYNDROME

Arterial Intervention / Peripheral vascular disease intervention

P. Popeski¹, B. Bogdanova¹, G. Aleksov², M. Totev

1 Radiology, National Heart Hospital, Sofia, BG,

2 Imagine diagnostic, SBAL Oncology, Sofia, BG

3 Pirogov Emergency Hospital, Sofia, BG

1. Clinical History/Pre-treatment Imaging:

Steal syndrome is defined as steno-occlusive disease in 1st segment of subclavian artery with retrograde blood flow in ipsilateral vertebral artery. As a result, the blood flow to the corresponding arm is reduced and apart from collaterals, is performed primarily by retrograde blood flow from the ipsilateral vertebral artery. Blood is 'stolen' from the circular vertebrobasilar system to supply the distal territory of the occluded or stenosed artery.

2. Treatment Options/Results:

According to world statistics, technical success in endovascular treatment varies from 86% to 100%. Clinical symptoms improved in 83% to 100%. Complications were reported in 3% to 45% of the patients. After subclavian artery stenting, the rate of restenosis is from 0 to 16% after 24 months.

3. Discussion:

Endovascular treatment with its safety, efficacy and relatively low cost has been proven to be an alternative to the treatment of stenocclusive disease in subclavian arteries.

4. Take-home points:

Clinical appearances vary in severity and include:

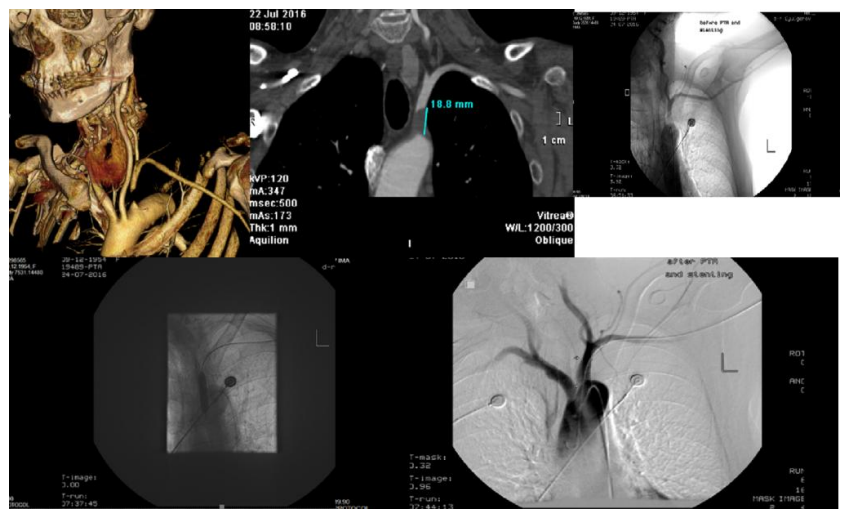
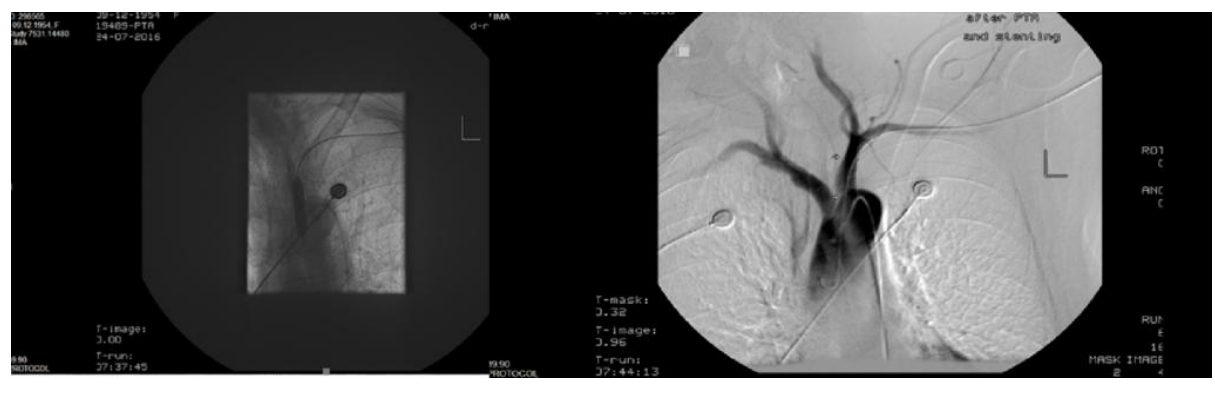
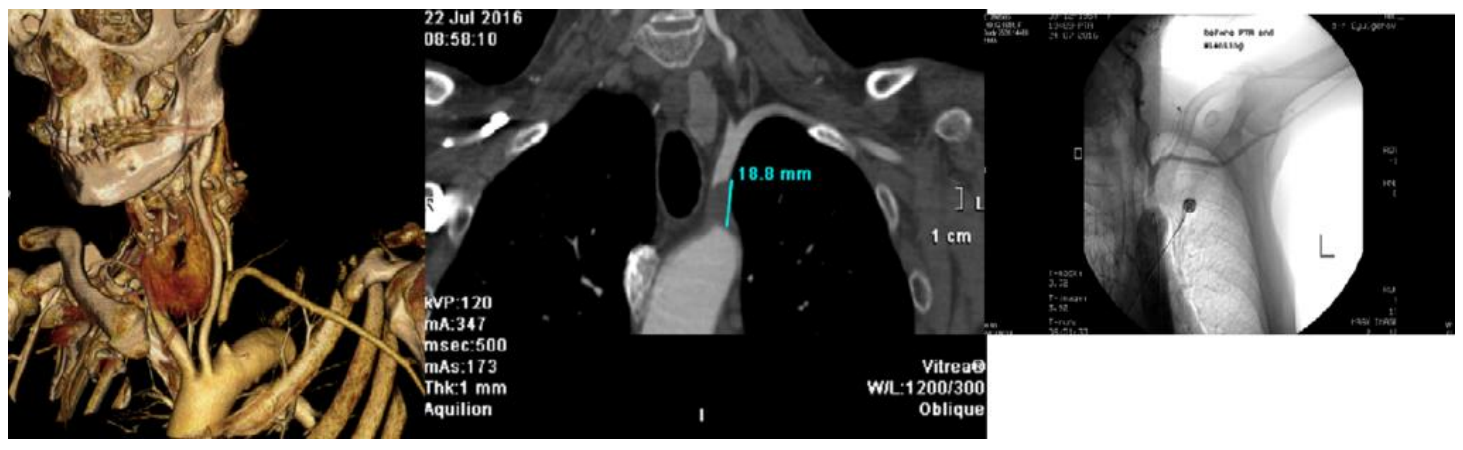
From upper limb side - weakness, thirst, cold, decreased blood pressure of the respective arm, pain. Neurological - Increasing in the physical load of the respective hand: dizziness, syncope, ataxia.

5. Images:





6.





PP 015

REMOTE CEREBELLAR HEMORRHAGE AFTER SUPRATENTORIAL LOBECTOMY: CASE REPORT

Ahmet Kursat Karaman, Ömer Bağcılar, Yeseren Deniz Senli,

Department of Radiology, Cerrahpasa Medical Faculty, Istanbul University-Cerrahpasa, Istanbul, Turkey

Introduction

Remote cerebellar hemorrhage (RCH), is a rare but benign and self-limiting complication that occurs after supratentorial and spinal procedures.^{1,2} It typically develops distant to the site of surgery.^{2,3} RCH, may be seen as an incidental finding detected in postoperative computed tomography or magnetic resonance imaging or together with neurological symptoms.^{1,4,5}

Purpose

In this case report, we aimed to present this rare complication and radiological features in a patient with supratentorial lobectomy.

Materials and Methods

A 44 year old man was admitted to our hospital who had recurrent seizure for twenty five years. MR imaging performed that revealing left hippocampal volume loss and increased signal on T2 weighted images consistent with mesial temporal sclerosis. Surgical treatment (anterior temporal lobectomy) performed for patient's drug resistant epilepsy.

Patient had not any postoperative neurological symptoms. Postoperative control MRI demonstrated left temporal surgical site and postoperative changes of uncomplicated craniotomy. There was no supratentorial hemorrhage (subarachnoid, epidural, subdural). MRI also showed that bilateral cerebellar hemorrhages with mild mass effect and minimal adjacent edema.

Results

Remote cerebellar hemorrhage must be considered after supratentorial surgery in patients with both asymptomatic and with unexplained neurological deterioration.^{1,4,6} Although it does not seem to be related to any specific type of surgery, more frequently reported for IA clipping, tumors' resection, and lobectomies for focal epilepsy in literature.^{2,5}

The most common radiologic finding in RCH is layering of blood over superior folia, called the zebra sign.^{2,7} Despite the pathomechanisms leading to RCH are not definitely understood, it is believed that loss of larger volumes of CSF related to this complication.^{1,2}



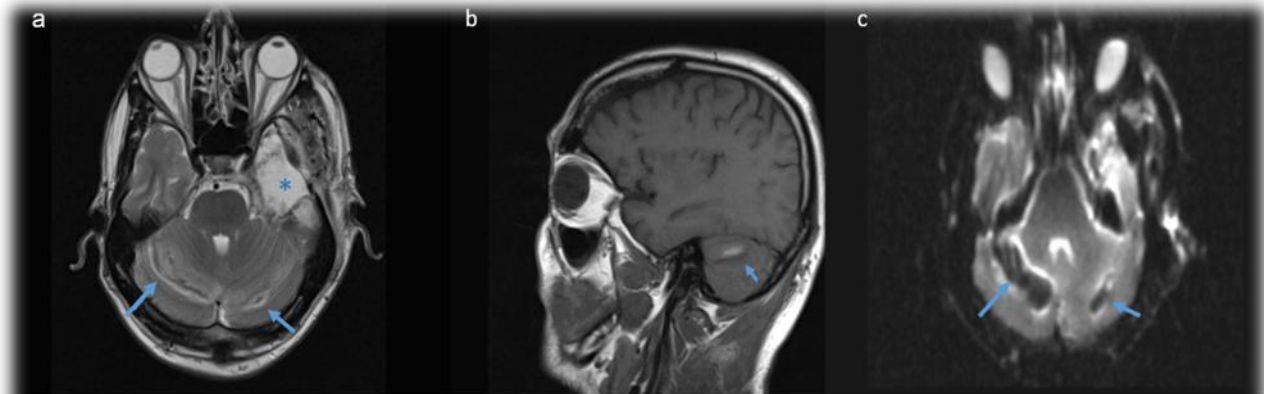


Figure: Postoperative MRI shows bilateral cerebellar hemisphere hemorrhage with mild mass effect and minimal adjacent edema. The pattern of blood products' distribution among the cerebellar folia is called "zebra sign". Asteriks(*) indicates that left temporal lobectomy site. (a: T2W, b: T1W Sagittal, c: DWI (b0))

References

1. Amini A, Osborn AG, McCall TD et-al. Remote cerebellar hemorrhage. *AJNR Am J Neuroradiol.* 2006;27 (2): 387-90.
2. Brockmann MA, Nowak G, Reusche E et-al. Zebra sign: cerebellar bleeding pattern characteristic of cerebrospinal fluid loss. Case report. *J. Neurosurg.* 2005;102 (6): 1159-62.
3. Friedman JA, Piegras DG, Duke DA, et al. Remote cerebellar hemorrhage after supratentorial surgery. *Neurosurgery* 2001;49:1327-40
4. A. Dincer, Ü. Özcan, D. Kaya, M. I. Usseli, C. Erzen, and M. N. Pamir, "Asymptomatic remote cerebellar hemorrhage: CT and MRI findings," *Cerebellum*, vol. 11, no. 4, pp. 880-886, 2012.
5. Sturiale CL, Rossetto M, Ermani M, et al. Remote cerebellar hemorrhage after supratentorial procedures (part 1): a systemic review. *Neurosurg Rev* 2016;39:565-
6. Honegger J, Zentner J, Spreer J et-al. Cerebellar hemorrhage arising postoperatively as a complication of supratentorial surgery: a retrospective study. *J. Neurosurg.* 2002;96 (2): 248-54.





PP 016

IMPROVING MEDICAL STUDENTS' CONFIDENCE WITH REQUESTING AND INTERPRETING RADIOGRAPHS PRIOR TO FOUNDATION TRAINING USING A PILOT 'FUNDAMENTAL RADIOLOGY' COURSE

Shreena Patel

Barnet General Hospital UK

Introduction

Evidence suggests medical students do not receive sufficient teaching in radiology, often expressing apprehension prior to training (1), nevertheless it forms a vital part of clinical decisions.

Purpose

A quality improvement project aiming to improve confidence with interpreting common pathology on radiographs in preparation for foundation training.

Materials and Methods

Using Plan Do Study Act methodology, Final Year Medical Students at Barnet General Hospital were surveyed to provide data assessing 8 key areas (1= not confident; 5= confident) surrounding radiology knowledge and interpretation. A 'Fundamental Radiology for Foundation Year 1' course was organized to address clinical encounters during on-calls. Students completed the post course questionnaire to analyze results.

Results

13 participants contributed to the project. The mean confidence score was 2.76 pre-teaching and 3.67 post teaching. An unpaired t-test produced a statistically significant increase of 0.92 or 18.40% ($p=0.0008$ 95% CI 0.41 to 1.42). Additionally, paired t-tests showed an increase in confidence for: CXR interpretation by 0.62 or 12.40% ($p=0.0068$ 95% CI 0.15 to 1.08); Musculoskeletal X-ray interpretation by 0.85 or 17% ($p<0.0001$ 95% CI 0.51 to 1.18); and AXR interpretation by 0.69 or 13.80% ($p=0.0002$ 95% CI 0.40 to 0.98).

Conclusion

The results showed an intensive course in radiology increased confidence for clinical scenarios faced as a doctor. Students stated they felt better prepared to discuss scans with an on-call radiologist. Despite a small sample size, this pilot course justifies dedicated radiology teaching in the MBBS curriculum. Further development of the project involves using a series of lectures over a set period of time.

Disclosure: No conflict of interest to disclose. Fundamental Radiology Course was organized by Shreena Patel.





PP 017

PANCREATIC CANCER AS A SECOND PRIMARY TUMOR

Charikleia Triantopoulou, Dimitris Fagkrezos, Paraskevi Vlachou, Labrini Adamopoulou, Maria Staikou, Areti Kavvatha, Ioannis Christofilis, Petros Maniatis
 Radiology Department, Konstantopouleio General Hospital, Athens, Greece

Introduction

There is an increasing interest on risk estimation of a pancreatic ductal adenocarcinoma development in cancer survivors.

Purpose

The purpose of this study was to present our experience on pancreatic tumors as a second cancer in patients with prior neoplasms in other organs.

Materials and Methods

We reviewed our database from January 2016 until December 2018, concerning new pancreatic cancer cases. Twelve patients were identified presenting a history of a previously treated cancer in other organs. Patient population consisted of 3 women and 9 men aged from 47 to 71 years.

Results

Three patients had renal adenocarcinoma and underwent nephrectomy 2, 4 and 24 years before. One had Hodgkin lymphoma treated with chemotherapy since 2012. Another patient had small cell lung cancer treated by surgery on 2011. Adenocarcinoma of gastroesophageal junction and stomach was treated by surgery and chemotherapy on 2008 and 2012 in other two cases. The other five patients had colonic cancer five years before, prostate cancer two years before, urothelial carcinoma of the bladder one year before, thyroid cancer two years before and the last one multiple myeloma since 2000. Pancreatic cancer was revealed due to patient symptoms in 7 cases, while in 5 it was an incidental finding on the follow-up examination for the first cancer. In five cases where pancreatic ductal dilatation was not so prominent, EUS-FNA was performed to confirm the diagnosis and exclude metastases from the prior neoplasm.

Conclusion

Pancreas can be the site of a second primary tumor development in a variety of different cancers survivors.





PP 018

EARLY DETECTION OF SMALL BREAST CANCERS BY SCREENING MAMMOGRAPHY AND SUPPLEMENTAL ULTRASOUND (IN SPECIFIC CASES): REVIEW OF 18 MONTHS EXPERIENCE IN A LOCAL COMMUNITY HOSPITAL

Markou Andreas¹, Papatolios Georgios², Dinas Sotirios², Noniasvili Liana¹, Mauroeidi Vasiliki¹, Liemarkopoulos Emmanouil², Kofinas Athanasios², Dimakis Konstantinos², Gkountelas Georgios¹

¹Department of Radiology, General Hospital of Florina, Greece

²Department of Surgery, General Hospital of Florina, Greece

Introduction: Breast cancer is the most common cancer and the second most common cause of death from cancer in women. It is a heterogeneous disease with many identified environmental, reproductive, and genetic risk factors. Early detection of small breast cancers by screening mammography (SM) greatly improves a woman's chances for successful treatment.

Purpose: To show the role of screening mammography and supplemental ultrasound (in specific cases) in early detection of breast cancer in a Local Community Hospital (LCH).

Materials and Methods: 1500 women aged between 34 and 79 underwent SM between 01/03/2018 and 31/05/2019. The presence of suspected malignant findings in the SM and in specific cases heterogeneously dense and extremely dense breast were the main causes of further ultrasound investigation. The presence of suspicious calcifications and the unsatisfactory imaging of the retroareolar space were the main causes for additional mammographic imaging.

Results: Among all 1500 women who underwent SM, 240 women were called for ultrasound and 73 women for additional mammogram images. Among 240 women who were called for ultrasound, 91 women were recalled for ultrasound examination due to BI-RADS 3 classification. Eventually 10 women were referred for core biopsy, that confirms the diagnosis of cancer in 9 patients. Among 73 women who were called for additional mammogram images, 2 women underwent bracketing wire placement and the histopathological examination revealed ductal carcinoma in situ in both of them.

Conclusion: Our experience suggests that SM in a LCH is an important tool for reducing the burden of breast cancer and provides a cancer incidence rate comparable with that of organized breast cancer screening programs (OBSP) in Europe. However, future work is needed to create OBSP with new imaging technologies and personalized care.





PP 019

PULMONARY AND ABDOMINAL LYMPHANGIOLEIOMYOMATOSIS (LAM) IN A 41-YEAR-OLD FEMALE WITH DOWN SYNDROME

Markou Andreas¹, Tsoukas David², Ioakeimidis Nikolaos³, Kollari Erieta³, Kalogiannis Emmanouil³, Douitsis Petros³, Gkountelas Georgios¹

¹Department of Radiology, General Hospital of Florina, Greece

²Subdepartment of Pulmonary Medicine, Department of Internal Medicine, General Hospital of Florina, Greece

³Department of Internal Medicine, General Hospital of Florina, Greece

Introduction: Lymphangioliomyomatosis is a rare disease characterized by abnormal proliferation of lymphatic vessels. It can be single organ involvement or multiple organ involvement. The lung is a relatively common involved organ, which is commonly involved alone. Abdominal LAM is extremely rare in adult patients, and the clinical symptoms of this condition are complicated and atypical.

Purpose: To demonstrate the role of Multidetector Computed Tomography (MDCT) in the diagnosis of LAM and reveal rare extra-pulmonary manifestations of LAM.

Materials and Methods: A 41-year-old female with pulmonary LAM and Down syndrome complained of dyspnea and cough for two months. The patient has noticed a marked worsening in the last few days and underwent MDCT of the chest and abdomen.

Results: The chest MDCT demonstrated thin walled cysts of variable sizes surrounded by normal lung parenchyma, interlobular septal thickening, pleural effusion (chylothorax) and aberrant right subclavian artery. The abdomen MDCT revealed multiple low-attenuation cystic masses without internal enhancement in the abdominal cavity. The biggest mass reached 13cm and the most of them distributed in the retroperitoneal space. In LAM patients, cystic masses are assumed to be lymphangioliomyomas unless there are clinical indications of abscess or tumor.

Conclusion: MDCT is a fast and efficient tool to evaluate pulmonary and abdominal findings of LAM. The abdominal manifestations are infrequent and mainly include renal angiomyolipomas, lymphangioliomyomas, chylous ascites and abdominal lymphadenopathy.





PP 020

SOLITARY METACHRONOUS SPLENIC METASTASIS FROM CUTANEOUS MELANOMA

Markou Andreas¹, Kontakli Theodosia², Noniasvili Liana¹, Grigoriadis Lazaros¹, Gkountelas Georgios¹

¹Department of Radiology, General Hospital of Florina, Greece

²Department of Radiology, General Hospital of Kozani, Greece

Introduction: Although the spleen is the most vascular organ in the body, it is an infrequent site of tumor metastases. Metastases to the spleen are rare and are generally part of a multi-visceral metastatic disease.

Purpose: The aim of this study is to reveal that contrast-enhanced Multidetector Computer Tomography (MDCT) has a high diagnostic accuracy for detection and characterization of splenic metastases, which are often asymptomatic and incidentally found.

Materials and Methods: A 48-year-old man was operated for neck cutaneous melanoma. MDCT scan of the whole body was negative. He was scheduled for follow-up visits every 3 months.

Results: After 9 months and on a programmed follow-up visit, MDCT scan of the whole body revealed a solitary tumor of the spleen and highly suspected for malignancy. The patient refused to perform any other exam, like magnetic resonance imaging (MRI) and positron emission tomography (PET/CT). After 3 months the tumor has increased in size. Splenectomy was performed and the histopathological report confirmed solitary intraparenchymal melanoma metastasis in the spleen. He recovered uneventfully and was discharged on the sixth postoperative day.

Conclusion: Isolated metastases from melanoma are rare and could be found several months after primary diagnosis of melanoma. An isolated solid splenic lesion in a patient with a past history of malignancy is highly suspicious for metastatic disease. Surgery remains the most effective treatment, especially for metachronous disease.





PP 021

SEVERE UNCOMMON INCIDENTAL FINDINGS ON CT PULMONARY ANGIOGRAPHY (CTPA)

Markou Andreas¹, Sapouridis Georgios², Ioakeimidis Nikolaos¹, Kontaki Theodosia³, Anastasiou Aikaterini¹, Noniasvili Liana¹, Gkountelas Georgios¹

¹Department of Radiology, General Hospital of Florina, Greece

²Department of Radiology, General Hospital of Thessaloniki, Greece

³Department of Radiology, General Hospital of Kozani, Greece

Introduction: Computer Tomography [pulmonary angiography](#) (CTPA) is being used increasingly as a diagnostic modality for patients with suspected [pulmonary embolism](#) (PE). CTPA has many benefits, including being fast and accurate, high interobserver agreement and the ability to detect alternative abnormalities that may explain the patient's symptoms or need further investigation.

Purpose: The aim of this study is to evaluate the frequency of severe non-embolic and non-pulmonary findings that have been detected by CTPA and to describe the importance of reporting these CT findings.

Materials and Methods: A retrospective review was done on 112 CTPAs of adults with suspicion of PE in the Radiology Department between April of 2018 and April of 2019. Median age of the patients was 59 years (range, 21-92 years). We studied severe (need further evaluation and can be life-threatening) non-pulmonary and extra osseous findings, divided into noncardiovascular and cardiovascular, excluding usual findings like aortic aneurysm, coronary calcification and cardiomegaly.

Results: Among the 112 patients who underwent CTPA, the severe (need further evaluation and can be life-threatening) incidental findings include:

- subclavian artery stenosis (2 cases),
- contralateral axillary and bilateral internal mammary lymph node metastasis in woman, who underwent mastectomy 15 months ago because of second primary cancer at the same breast (1 case)
- breast cancer with ipsilateral axillary lymph node metastasis (1 case)

Conclusion: An additional benefit of CTPA is CTPAs ability to provide simultaneous information on other pathologies affecting the thorax. It is recommended that radiologists report the non-embolic findings, especially those that require further investigations (earlier diagnosis and better management) or explain the clinical symptoms of the patients.





PP 022

ROLE OF COMPUTED TOMOGRAPHY (CT) SCAN IN TUMOR RESPONSE ASSESSMENT OF LUNG CANCER IN ALBANIA

Enkela Xhori¹, Adrian Hoti¹ Ortensia Gjyli¹, Fatjona Kraja²

¹Radiology and Nuclear Medicine Department

²University Clinic of Oncology

University Hospital Center "Mother Teresa", Tirana Albania

Purpose: To evaluate the role of CT scan in tumour response assessment in lung cancer (LC).

Methods: The data of 48 consecutive patients with stage II- IV LC treated at the University Hospital Center Mother Teresa, during 2018 were analyzed retrospectively. Tumor response was evaluated using the Response Evaluation Criteria in Solid Tumors (RECIST 1.1). CT scan was performed before the treatment and 3 months after the treatment. The statistical analysis was made through SPSS version 20.0 (SPSS, Chicago, IL).

Results: The mean age of patients was 61.8 ± 6.1 years (range 46-74 years). The male to female ratio was 3:1. Four patients (8.3%) were stage II LC, 15 (31.3%) stage III and 29 (60.4%) stage IV.

Adenocarcinoma was found in 22 patients (45.8%), squamous cell carcinoma in 18 (37.5%), small cell carcinoma in 7 (14.6%) and neuroendocrine LC in 1 (2%). Patients were treated with chemotherapy 54.1% of patients, concomitant chemo-radiotherapy 35.4%, adjuvant chemo-radiotherapy in 10.4%. According to RECIST tumour response assessment, 4 patients demonstrated complete response, 7 partial response, 15 stable disease and 22 progress disease.

Significant correlation was observed between the histology and tumor response ($p=0.03$).

Conclusion: CT scan still plays an important role in tumour response assessment. Use of RECIST to classify response in lung cancer patients should be considered, regardless of histological subtype and stage of disease, to standardize monitoring and evaluate all lesions present for optimal treatment control. Providing information about the patient, disease type, and treatments received is necessary.

Keyword: Lung cancer, CT-scan, tumor response.

Disclosure: The authors declares that they have no relevant or material financial interests that relate to the research described in this paper.





PP 023

MRI IMPORTANCE IN DIAGNOSIS OF CADASIL

Biljana Prgova, MD, PhD, Dimitar Veljanovski, MD, Masha Kostova, MD, Gordana Bozinovska, MD, PhD
 City General Hospital 8th September, Radiology Unit, Skopje, R. of N. Macedonia

Introduction: CADASIL is the most common form of hereditary cerebral angiopathy which clinically presented with migraine headaches, recurrent cerebral infarctions, cognitive damage, psychiatric impairments, and later with pseudobulbar paralysis and urinary incontinence. The disease develops due to a mutation of the NOTCH3 gene on the 19q12 chromosome. The changes occur as a result of thickening of the wall of the cerebral arteries and non amyloid substance accumulation in the media.

Purpose: The aim of this study is to present the MRI characteristics and the genetic involvement in the etiopathogenesis of this disease by presenting two blood related patients.

Material and methods: Two blood related patients are examined with the same diagnostic method, MRI magnetom essenca, with magnetic field strength of 1,5Tesla. Standard protocol for examination of the endocranium with contrast was performed as well as MRI angiography.

Results: Using MRI imaging method the diagnostic changes were identical in both patients: bilaterally periventricular in centrum semiovale, insula, basal ganglia, capsula externa, temporal lobes, as well as in the pons extensive confluent hypersignals in T2W/FLAIR changes are noted, which appear hyposignal in T1 Pulse sequence. The changes in the temporal lobus are significant in the differential diagnosis of this disease despite the microvascular ischemic lesions. The extension and the number of lesions correlate with the neurological deficit. When there is a radiological suspicion of cerebral autosomal dominant arteriopathy, it is necessary to conduct genetic testing for detection of NOTCH3 gene mutation. Skin biopsy is also recommended which can display skin blood vessel changes, similar to the brain arteries.

Conclusion: MRI is an important diagnostic method for diagnosis of the disease of interest.

PP 024

COMPUTED TOMOGRAPHY ANGIOGRAPHY EVALUATION OF COMBINED TYPES OF ENDOLEAKS AFTER ENDOVASCULAR ABDOMINAL AORTIC ANEURYSM REPAIR: OUR DEPARTMENT'S EXPERIENCE

Magdalini Smarda, Georgios Masouris, Dimitrios Argiropoulos, Dimitrios Fagkrezos, Eleni Koumpoulidou, Petros Maniatis

Computed Tomography Department, Konstantopouleion General Hospital, Athens, Greece

Introduction: Endovascular aneurysm repair (EVAR) has become an established technique for treatment of the majority of infrarenal abdominal aortic aneurysms (AAA). Among EVAR-related complications, endoleaks are the most common ones requiring accurate detection and classification, as well as periodic follow up usually conducted with Computed Tomography Angiography (CTA).

Purpose: To evaluate the role of CTA for accurate diagnosis and appropriate management planning in complicated cases where different types of post-EVAR endoleaks coexist.

Materials and Methods: CTAs of patients with a history of abdominal aortic endovascular stent-graft placement were retrospectively reviewed in our Department during the last year. All the





aforementioned examinations were performed using the same 64-detector row CT scanner and the same examination protocol, including a non-contrast, an arterial and a delayed phase 2 minutes after intravenous contrast media injection.

Results: A total number of 30 such examinations were found, with the vast majority (17 patients) presenting no signs of endoleak. Among the rest, type I endoleak was diagnosed in 2 cases, type III in one case and type II in 5 cases (3 from lumbar arteries and 2 from inferior mesenteric artery). The last 5 exams included combined types of endoleaks (3 cases of type I and II combination, 1 case of type II and III combination, and finally, a quite unusual case of simultaneous type I, II and III endoleak existence). All the above patients with combined types of endoleaks underwent another endovascular repair surgery and following CTAs showed no signs of endoleak this time.

Conclusions: CT angiography can accurately detect and classify complicated cases of post-EVAR combined endoleak types and determine the line of treatment.

PP 025

COMPUTED TOMOGRAPHY ANGIOGRAPHY ANALYSIS OF VISCERAL VESSELS VARIANTS WITH OUR DEPARTMENT'S 64-DETECTOR ROW CT SCANNER

Magdalini Smarda, Dimitrios Argiropoulos, Georgios Masouris, Dimitrios Fagkrezos, Theodoros Panagopoulos, Petros Maniatis

Computed Tomography Department, Konstantopouleion General Hospital, Athens, Greece

Introduction: Computed Tomography Angiography (CTA) constitutes the modality of choice for the depiction of abnormal anatomy of visceral vessels. Evaluation of hepatic arterial anatomy before liver transplantation or tumor resection, visceral arterial anatomy in pancreaticoduodenectomy, superior mesenteric artery variants in intestinal ischemia, or vascular encasement in pancreatic neoplasms are some of CTA's applications in everyday clinical practice.

Purpose: To present anatomic variants of visceral vessels incidentally found in patients undergoing CTA of the abdominal aorta in our Department during the last year.

Materials and Methods: A total number of 249 CTAs were retrospectively reviewed. They were all performed using the same 64-detector row CT scanner and the same examination protocol.

Results: Normal celiac trunk anatomy was observed in 189 patients (75.9%), whereas anatomical variations were found in 60 patients (24.1%). Among them, there were 25 patients with a common trunk trifurcation into the common hepatic artery (CHA), splenic artery (SA) and left gastric artery (LGA), 9 cases of right hepatic artery (CHA) originating from superior mesenteric artery (SMA) and 6 cases of CHA origin from SMA as well (3.6% and 2% respectively), 3 cases of left hepatic artery (LHA) originating directly from the abdominal artery at the level of celiac artery (CA) origin (1.2%), 3 cases of direct origin of the LGA from the abdominal artery (1.2%) and 2 cases of abnormal gastroduodenal artery (GDA) origin from the celiac artery itself (0.8%). Finally, there were 12 combined anatomical variations (4.8%).

Conclusion: CTA is a valuable tool for accurate detection of anatomic variants of visceral vessels. Three-dimensional presentation of vessel anatomy with Volume Rendering (VR) and Maximum Intensity Projection (MIP) techniques, renders anatomical variations more understandable for clinicians. Existence of these variants always has to be pointed out in the written radiology report, as it may affect impending surgical procedures.





PP 027

ULTRASOUND EVALUATION OF AXILLARY LYMPH NODES AND COMPARISON OF THE RESULTS WITH THE SENTINEL LYMPH NODE BIOPSY IN WOMEN WITH BREAST CANCER

Liovarou E.(1), Michalopoulos N.(2), Voros D.(3), Zografos G. (4)

Radiologist, Ultrasound Department General Hospital of Nikea, Pireaus, Greece (1), Assistant Professor of Surgery 'A Propaedeutic Surgery Clinic University of Athens (2), Emeritus Professor of Surgery University of Athens (3), Associate Professor of Surgery 'A Propaedeutic Surgery Clinic University of Athens (4), Greece.

INTRODUCTION: The pre-surgical staging of the axilla in breast cancer patients is a vital part of modern surgical oncology. The sentinel lymph node dissection has become the "gold standard" for the axillary evaluation in patients with early breast cancer, albeit not without complications or false negative results.

PURPOSE: To compare specific ultrasound characteristics of axillary lymph nodes with the result of their histopathology examination and to test the diagnostic value of ultrasonography in identifying malignant infiltration.

MATERIALS AND METHODS: In the Breast Unit Department of the Hippokration hospital in Athens, 12 women with histologically proven breast cancer were subjected to ultrasound evaluation of the axillary nodes, regarding their morphologic features, vascularization pattern and stiffness. Suspicious lymph nodes were hook-wired and removed during sentinel lymph node dissection. The ultrasound characteristics for each node were compared to its histopathology report.

RESULTS: Cortical thickness >3mm showed the highest sensitivity as an indication of malignancy (100%) but presented low specificity (<50%). The "lack of fatty hilum" and "irregular peripheral vascularity" showed equivalent results. Sonographic evaluation presented high sensitivity (100%) but low specificity (<50%) if a lymph node was considered malignant with one positive sonographic criterion and low sensitivity (50%) with increased specificity (79%) when two criteria were a prerequisite to reach the same conclusion. (71)

CONCLUSIONS: The ultrasound examination cannot replace the sentinel lymph node biopsy with the contemporary data. When the ultrasound is negative we should proceed to the sentinel node biopsy to minimize the false negative findings. If the ultrasound is positive (and this is proven to be so by percutaneous biopsy) we can skip the SLNB and proceed to axillary node dissection.





PP 029

RADIOLOGY APPROACH IN ACUTE ABDOMINAL TRAUMA – CASE REPORT

Dejanova Panev Sandra, Jakimovska Maja, Nancheva Bogoevska Andrea, Prgova Veljanova Biljana
 City General Hospital 8th September Radiology Unit, Skopje, R. of N. Macedonia

Introduction: Abdominal trauma can be difficult to diagnose and manage and may be a major cause of post trauma death. Good radiology approach of both, blunt and penetrating trauma contributes to exact diagnosis and appropriate treatment of patients.

Purpose: The purpose of the case study was to present our experience in diagnosis of patients with acute abdominal trauma.

Material and Methods: In this case study a number of 3 patients, which sustained abdominal trauma from traffic accident, are presented.

1. Case 1, S. I. (27 years old, male), abdominal pain, bloody urine
2. Case 2, Sh. I (40 years old, male), general pain, hematuria
3. Case 3, S. J. (20 years old, female), general pain

The patients were analyzed through conventional radiography (x-ray), Computer Tomography (CT, G16) and Ultrasonography (US, Saote, My Lab25Gold).

Results:

Case 1, The first day on US was found free fluid in Morrison space. The same day on CT was visualized laceration of lower part of right kidney – classification stage 4 and haematoma in retroperitoneal space. The following day on US in the perirenal space hypoechogenic change was found, with appearance of haematoma or exudates liquid. The same changes were detected on CT from the previous examination

Case 2, On CT several hypodense zones in the liver were found, which go for intraparenchymal laceration of liver – stage 3.

Case 3, On CT inhomogenous post-contrast accumulation around the spleen hilus was found, leading to diagnosing spleen rupture. Ascites around the liver, perisplenic and in Douglas.

Conclusion: The combination of radiological findings is of a great importance in the early evaluation and decision making algorithm for hemodynamically stable patients who sustained abdominal trauma.





PP 030

BILATERAL SYNCHRONOUS RENAL CELL CARCINOMA (RCC) WITH BILATERAL SYNCHRONOUS ADRENAL GLAND METASTASES: MULTIDETECTOR COMPUTED TOMOGRAPHY FINDINGS.

Markou Andreas¹, Kontaki Theodosia², Noniasvili Liana¹, Minou Aikaterini¹, Manousi Zoi¹, Gkountelas Georgios¹

¹Department of Radiology, General Hospital of Florina, Greece

²Department of Radiology, General Hospital of Kozani, Greece

Introduction: Bilateral renal tumors remain relatively uncommon, accounting for 1%- to 5% of patients with renal cell carcinoma (RCC). Several factors determine the risk of developing metastases: stage (the most important), nuclear grading and histologic subtype of the primary tumor. RCC metastasizes in two basic ways: hematogenous and lymphatic dissemination. RCC typically metastasizes to the lung, bone, lymph nodes, liver, adrenal glands, and brain, although practically any organ may be affected. Adrenal function is usually maintained even though bilateral adrenal glands are affected by malignancy.

Purpose: To demonstrate the role of *Multidetector Computed Tomography* (MDCT) in the diagnosis of renal tumors and metastases from renal cell carcinoma.

Materials and Methods: A 84-year-old woman presented with cough and dull abdominal pain. A *chest X-ray*, posterior-anterior view, *revealed* multiple pulmonary nodules, which were highly suggestive of metastases and the patient underwent MDCT scan of the whole body.

Results: The chest MDCT demonstrated multiple metastases of variable sizes. The abdomen MDCT revealed large bilateral synchronous renal tumors with bilateral synchronous adrenal gland metastases and tumor *thrombus* of the *inferior vena cava*.

Conclusion: Patients with adrenal metastases and *intracaval tumor thrombus* tend to have large primary renal tumors that nearly encompass the entire kidney. MDCT is a fast and efficient tool to evaluate *metastatic renal cell carcinoma*.





PP 031

THE IMPACT OF LIVER HYPERTROPHY OF THE FUTURE LIVER REMNANT VOLUME (FLR) INDUCED BY PREOPERATIVE PORTAL VEIN EMBOLIZATION (PVE) AND THE ACCURACY OF METHOD OF LIVER VOLUMETRY IN THE PREOPERATIVE MANAGEMENT OF LIVER TUMORS

Smarda Magdalini, Massouris Georgios, Tsipra Evangelia, Delis Spyros, Triantopoulou Charikleia, Maniatis Petros

Konstantopouleio General Hospital Neas Ionias, Athens Greece

Introduction

Despite the decrease in postoperative complications after liver resection, there is theoretical evidence that an insufficient hepatic functional reserve estimated by a small future liver remnant volume (FLR) after major liver resection is still considered a risky situation. Therefore, it could be assumed that by hypertrophying the FLR, the safety and tolerance of major liver resections could be improved.

Purpose

To assess the impact of liver hypertrophy of the future liver remnant volume (FLR) induced by preoperative portal vein embolization (PVE) and the contribution of CT volumetry in the planning of major liver resection.

Materials and Methods

We studied 65 patients (51 men and 14 women) within 3 years. Among 65 patients (40 liver metastases, 3 cholangiocarcinomas, and 22 hepatocellular carcinomas), 25 underwent hepatectomy after PVE and 40 underwent immediate surgery. 18 patients had chronic liver disease. FLR was assessed with volumetric helical computed tomography. All patients with resectable tumors underwent postoperative volumetry.

Results

The mean increase of FLR (Future Liver Remnant) 4 to 8 weeks after PVE were respectively $54 \pm 14\%$ for patients with normal liver and $30 \pm 18\%$ for those with chronic liver disease. Volumetry revealed that all patients with non-cirrhotic liver and 85% with cirrhotic liver experienced hypertrophy after PVE. The postoperative course of patients with normal liver who underwent PVE before hepatectomy was similar to those with immediate surgery. In contrast, PVE in patients with chronic liver disease significantly decreased the incidence of postoperative complications and hospital stay.

Conclusion

The process of volumetry with the aid of the MDCT is a reliable method in the planning of surgical treatment of liver tumors, evaluating also the effectiveness of preoperative portal vein embolization (PVE) and its impact in liver hypertrophy of the future liver remnant volume (FLR).





PP 032

VALUE OF THE REVISED GENEVA CRITERIA, AND THE D-DIMER LEVELS, IN THE DIAGNOSIS OF PULMONARY THROMBOEMBOLISM, FOR REDUCE TO OVERUSE OF PULMONARY CT ANGIOGRAPHY.

Turnaoglu Hale, Keskin Sefa, Aybatova Leila, Ozcetin Ayse, Becer Berkay, Durukan Elif, Baskent University, Faculty Of Medicine, Department Of Radiology, Ankara Turkey

Introduction: Pulmonary CT angiography has become the main method of diagnosis in patients with the suspicion of pulmonary thromboembolism. Classification of patients according to their symptoms, signs and risk factors, with the d-dimer results provides advantage in diagnostic and clinical approaches.

Purpose: To investigate the applicability of modified Geneva score which is used to evaluate the clinical probability, with the d-dimer results, to reduce the overuse of CT angiography, on patients with suspicion of pulmonary thromboembolism, who were admitted to the emergency department.

Materials and Methods: A total of 400 patients who had performed pulmonary CT angiography, with the suspicion of pulmonary thromboembolism, in the emergency department, were included in this retrospective study. The clinic and demographic datas of the patients were classified according to the modified Geneva score, and d-dimer values were recorded. Presence of pulmonary thromboembolism was investigated on the pulmonary CT angiography images accessed from Picture Archiving Communication Systems.

Results: In a 33 (8.25%) of 400 patients, thromboembolism was detected in the pulmonary CT angiography. 20% (n=1), 8.8% (n=25), and 6.4% (n=7) of the patients, have been diagnosed pulmonary thromboembolism by CT, with the high, intermediate, and low clinical probability, respectively. 197 (49.25%) out of 400 patients had d-dimer results. 1 (2.9%) out of 34 patients with a low d-dimer value had thromboembolism in CT. The sensitivity, specificity, positive predictive value, and negative predictive value were calculated, as 78.8%, 28.1%, 9%, 93.6% of the modified Geneva score, and as 94.7%, 18.5%, 11%, 97.1% of the d-dimer, respectively.

Conclusion: In the diagnosis of pulmonary thromboembolism, modified Geneva score, and d-dimer test have high negative predictive values. Other clinic diagnoses can be considered primarily, in patients with low d-dimer values and low modified Geneva scores. This may contribute to the reduction of the overuse of CT.





PP 033

COMPLETE ATLAS OCCIPITALISATION WITH BASILAR INVAGINATION AND ANTERIOR ATLANTOAXIAL SUBLUXATION. A CASE REPORT

Argyropoulos Dimitrios, Smarda Magdalini, Massouris Georgios, Fagrezos Dimitrios, Konstantinidis Maniatis, Maniatis Petros
 Konstantopouleio General Hospital Neas Ionias, Athens Greece

Introduction

Atlas assimilation or occipitalisation is a partial or complete congenital fusion between the atlas and the occipital bone. Though rare -reported incidence ranges between 0.08% to 3% in general population- it represents the most common anomaly involving the craniovertebral junction. Possible complications include basilar invagination and atlantoaxial subluxation.

Purpose

The aim of this presentation is to discuss the CT findings that should be checked in case of atlanto-occipital assimilation.

Method

A 40-year-old lady was referred to our CT department by her physician for a dull pain in her posterior neck radiating to both shoulders. The pain was associated with episodic neck stiffness but the sensory and motor examinations were normal in both upper and lower extremities.

Results

CT revealed complete fusion of the lateral masses of the atlas with the occipital condyles (complete atlantooccipital assimilation). The odontoid process of the axis and the anterior arch of the atlas were located above the Chamberlain line suggesting basilar invagination. Clivuscanal angle was reduced. The increased distance between dens and anterior arch of atlas indicated atlantoaxial subluxation.

Conclusion

Atlas occipitalisation ranges from a complete bony fusion of the atlas into the occiput to a partial connection, with a small bony bridge or a fibrous band of the atlas uniting to the occiput base. Occipitalisation affects males and females equally. Symptoms usually appear in the third and fourth decades of life. These include neck pain, headache, numbness and pain in the upper extremities, weakness and symptoms connected to the anterior or posterior spinal cord impingement or vertebral artery compression. Occipitalisation can also lead to chronic atlantoaxial instability and basilar invagination. Since this anomaly ranges from complete assimilation to a partial connection of the atlas into the occiput, routine radiographs are usually difficult to interpret. CT scans or MRI scans may be needed to show the occipitocervical fusion and determine the line of management and treatment.





PP 034

TUMOR IN A HORSESHOE KIDNEY

Kirova Ani

University Hospital Virgin Mary, Burgas, Bulgaria

INTRODUCTION:

Horseshoe kidney (HSK) is a benign malformation and it is the most common congenital renal fusion anomaly with an incidence of 1 in 400–600 individuals, /2:1 ratio in men/. Fusion at the lower poles is seen in 90% of the cases. There is an increased risk of malignant tumors in a HSK, including renal cell carcinoma (RCC), transitional cell carcinoma, Wilm's tumor, etc.

AIM OF THE STUDY:

Purpose of this study was to present the possibilities of using CT to detect, stage and give a preoperative evaluation of the tumor, incidentally found on a routine abdominal ultrasound. The patient is a 48-year-old woman with HSK without any symptoms of urological complications.

MATERIALS AND METHODS:

Multidetector CT currently represents the gold standard for staging, including multiplanar image reformations. We used GE Optima CT540, 16-slice and administered 100 mL of intravenous contrast material at a rate of 3 mL/s.

RESULTS:

Contrast-enhanced (CT) with three-dimensional (3D) and MIP reconstruction, identified a mass (100mm), located in the lower pole in the right moiety of the HSK. On non-contrast CT the lesion is soft tissue attenuation between 20-50 HU with heterogeneous enhancement. During the early arterial phase the lesion shows heterogeneous enhancement due to necrosis. During the nephrographic phase the lesion is hypoattenuating to the renal parenchyma. The tumor was limited to the kidney, without any evidence of metastasis or lymph node lesions. There was no vascular or collecting system involvement. The preoperative staging of the tumor in TNM classification is T2N0M0 (larger than 7cm, but not involving Gerota's fascia)

CONCLUSION:

The present study describes a case about a patient with a large tumor in a HSK. Our observations confirm that CT examination is appropriate for determining the tumor size, location and staging it in TNM classification. Detailed evaluation is essential for the assessment of tumor extension and surgical planning.





PP 035

AIR WITHIN THE GASTRIC WALL: A CASE OF EMPHYSEMATOUS GASTRITIS

Kalpaxi Aggeliki, Farazi-Chongouki Christos, Triantafyllou Evangelia, Pachi Anna, Kalokairinou Mariana, Vagdatlis Theodoros, Ioannidi Parthena, Flokatoula Maria, Papaevangelou Angeliki
 Department of Radiology, Thrasio General Hospital, Athens Greece

a. Introduction

Emphysematous gastritis is an uncommon cause of air within the gastric wall, with only 41 cases described in the English literature from 1883 till 2003. It is caused by invasion of the gastric wall by a gas producing organism. It is a life-threatening condition, with high mortality rate (60%–80%) even with aggressive medical or surgical management.

Gastric emphysema refers to other noninfectious and often benign conditions that may also lead to air within the gastric wall.

CT is the imaging modality of choice for diagnosis of gastric intramural gas. Although wall thickening is not typical in gastric emphysema, often the imaging appearance of the two conditions is indistinguishable. It is primarily the clinical presentation that differentiates the two entities, as patients with benign gastric emphysema are usually asymptomatic and nontoxic appearing.

b. Purpose

To present the CT findings of a case of emphysematous gastritis, that was successfully treated with broad-spectrum antibiotics.

c. Materials and Methods

A 77-year-old male with a history of operated colon cancer and poorly regulated diabetes presented to the emergency department complaining of epigastric pain, fever and vomiting. The patient was hemodynamically unstable, without signs of peritoneal irritation. Laboratory tests indicated severe sepsis complicated by diabetic ketoacidosis.

The patient was further evaluated with a computed tomography (CT) examination of the abdomen and pelvis.

d. Results

CT scan showed a dilated stomach, with thickening of the posterior gastric wall and intramural air. No portal gas or pneumoperitoneum was present.

The diagnosis was confirmed by gastroscopy, that showed ischemia of the posterior wall of the stomach. Cultures revealed *Candida*.

e. Conclusion

Early recognition and treatment of emphysematous gastritis is key to survival from this potentially fatal condition. The radiologist plays a vital role in the diagnosis.





PP 036

COIL EMBOLISATION OF RENAL ARTERY PSEUDOANEURYSM AFTER PERCUTANEOUS NEPHROLITHOTOMY- CASE REPORT

Hadji Nikolova N1., Lazareska M.2., Ilievski M.3, Jakimovska Dimitrovska M.4, Stojkovska Jovanovska E.4, Panchevska I. 5

1Cardiovascular and Interventional department, University Clinic of Radiology Skopje, Skopje, 2Neuroradiology and Neurointerventional department, University Clinic of Radiology, Skopje, 3Gastrointestinal radiology, University Clinic of Radiology, Skopje, 4Genitourinary radiology, University Clinic of Radiology, Skopje, 5Musculoskeletal radiology, University Clinic of Radiology, Skopje

Introduction:

A 66 year old male patient with right renal calculus underwent percutaneous nephrolithotomy and following the procedure was discharged from hospital. After two days the patient develops fever with complainings of dysuria and anuria prior hospitalization and ongoing haematuria with haemoglobin 88g/L.

Materials and Methods

CT angiography was indicated which showed intracaliceal coagulums with present hydronephrosis and contrast extravasation and accumulation at the lower pole of the right kidney. There was an early hilar division of the renal artery in which the dominant one has inferior branch for the lower pole where current pseudoaneurysm on the distal branch protruding into the right lower calyces was detected. Purpose Endovascular treatment was chosen. Selective catheterization of the right renal artery was performed with Sim catheter, followed by a Headway micro catheter for access to the lower pole division and super selective catheterization of the branch was used. Coil embolisation was performed at the most distal part of the efferent branch and all full flow to the pseudoaneurysm was excluded.

The control angiography showed preserved flow to the rest of the kidney.

Results

During embolisation of great importance for us was excluding the most distal part of the branch not the pseudoaneurysm itself preventing future refilings because of the lack of wall structures and also preserving the renal parenchyma.

Conclusion The recognition of renal pseudoaneurysm especially after kidney procedures is of great significance due to the risk of blood loss if undetected on time. Coil embolisation is a treatment of choice in iatrogenic pseudoaneurysms.





PP 037

AORTIC INTRAMURAL HEMATOMA STANFORD TYPE B IMH , CT EVALUATION

Eirini Kasti, Eugenia A. Zbogo, Electra Patsia-Zalavra, Chrisoula Kalamara, Penelope. Lampropoulou, Charalampos Drosos
Rhodes General Hospital, Athens General Hospital Genimmatas , Greece

Introduction:

Intramural hematoma (IMH) is included in the spectrum of acute aortic syndrome and is associated with significant morbidity and mortality. Is caused by spontaneous hemorrhage within the medial layer of the aortic wall without intimal rupture or dissection flap. Spontaneous hemorrhage can be attributed to pathological neovascularization, spontaneous rupture of vasa vasorum and penetrating aortic ulcers. Clinically IMH is indistinguishable from aortic dissection characterized by acute intense chest pain and hypertension. Natural course of IMH can be variable, it may resolve or progress to aneurysm, dissection or rupture.

Purpose:

We aim to present a case of aortic intramural hematoma revealed at CT scan and the diagnostical characteristics on unenhanced and enhanced CT scan.

Material and Method:

Patient 70 years -old male, presented to the emergency room with chest pain. Medical history on hypertension and diabetes. A CT scan was performed.

Results:

Non – enhanced CT scan revealed an area of hyperattenuating smooth crescentic thickening in the thoracic aorta wall. After the i.v contrast administration the intramural fluid collection appears as non-enhancing, crescentic wall thickening that extends almost entirely the opacified aortic lumen. No intimal flap is evident. The above findings are considered diagnostic of acute Intramural Hematoma arise distal to the left subclavian artery and involves the descending thoracic aorta (Stanford type B IMH).

Conclusions:

CT has a significant role in prompt diagnosis, classification and management in the spectrum of acute aortic syndrome. Radiologists should be aware of the characteristics, the presentation and the potential complications of IMH for the correct management where is surgical (Stanford A) or close clinical and imaging follow up (Stanford B).





PP 038

DERMOID CYST OF THE FLOOR OF THE MOUTH ,IMAGING FINDINGS

Eirini Kasti, Eugenia A Zbogo, Eleni Foti, Chrisoula Kalamara, Penelope Lampropoulou, Charalampos Drosos
 Rhodes General Hospital, Athens general Hospital Gennimatas, Athens Greece

Introduction:

Cystic masses on the floor of the mouth are classified into three types: epidermoid cysts, dermoid cysts and teratomatous cysts. Dermoid cysts of the head and neck are relatively rare (7%) derived from ectodermal layer, lined by the epithelium and formed by several mechanisms such as the occlusion of a sebaceous duct or entrapment (congenital and post-traumatic) of epidermal cells. Complex dermoid cysts contain mesodermal elements like cartilage, bone, and fat.

Nearly 34% of dermoid cysts are found in the head and neck, of which 6.5% are located at the floor of the mouth. They usually manifest during the second and third decades of life as slow-growing benign mass, when large enough, they can cause dysphagia, dysphonia and dyspnea.

Purpose:

We aim to present the imaging characteristics of dermoid cyst of the floor of the mouth by ultrasound and CT scan.

Materials and Methods:

Caucasian male of 25years old with a painless slow growing mass for the past 1 year localized at the floor of the mouth. An ultrasound of the area and a CT scan of the neck with i.v contrast has been performed.

Results:

Ultrasonography showed an inhomogeneous hyperechoic mass, localized medially above the mylohyoid muscle. Intra-cystic round hyperechoic corpuscles with shadowing were noted, giving a "sac-of-marbles" sign appearance. CT scan shows a midline, well-defined, unilocular, thin-walled, low-attenuating mass lesion containing multiple hypo-attenuating nodules and no sign of enhancement. The US and CT findings are pathognomonic for dermoid cyst of the floor of the mouth.

Conclusion:

Diagnostic imaging plays a pivoting role in the anatomic localization of the mass in the floor of the mouth and, therefore, helps in guiding surgical planning.





PP 039

PSEUDOANEURYSM OF AORTIC ISTHMUS -CT CHARACTERISTICS

Eirini Kasti, Eugenia A. Zbogo, Eleni Zafiriou, Chrisoula Kalamara, Penelope Lampropoulou, Charalampos Drosos
 Rhodes General Hospital, Athens general Hospital Gennimatas, Athens Greece

Introduction:

False aneurysm is a focal dilatation of an artery that does not contain all three of the normal arterial wall layers. Pseudoaneurysms are contained by an outer adventitial layer or thrombus and fibrous tissue. Causes are trauma, iatrogenicities, atherosclerosis, vasculitis or infectious etiology. Complications include progressive enlargement and rupture, fistula formation and superinfection.

Purpose:

We aim to present a case of aortic isthmus-descending thoracic aorta pseudoaneurysm after catheterization.

Material and Method:

A 64-year-old Caucasian male with medical history of hypertension and hyperlipidemia, presented with a 2-month history of worsening pressure-like chest pain, was admitted for a non-ST-segment elevation myocardial infarction (NSTEMI). The patient was referred for cardiac catheterization and possible coronary intervention. After the procedure the patient was complained about worsening chest pain. A CT Angiography scan with i.v contrast was performed.

Results:

CT scan revealed a focal dilatation arising from the aortic isthmus and projecting inferiorly, suggesting a pseudoaneurysm of aortic isthmus. Also, is evident mild mural local hematoma.

Conclusion:

An important differential diagnosis of these false aneurysms is a ductus diverticulum. Differentiation is critical since aortic pseudoaneurysm is a surgical emergency whereas ductus diverticulum is a normal anatomic variant.





PP 040

PSOAS MUSCLE HEMATOMA CAUSED BY RUPTURED ILIAC ARTERY ANEURYSM ,CT FEATURES

Eirini Kasti, Eugenia A. Zbogo, Eleni Zafiriou, Chrisoula Kalamara, Penelope Lampropoulou, Charalampos Drosos
Rhodes General Hospital, Athens general Hospital Gennimatas, Athens Greece

Introduction:

Aortic aneurysm rupture is part of the acute aortic syndrome spectrum. Is a surgical emergency. The classic clinical presentation of hypotension, abdominal or back pain, and a pulsating abdominal mass. Abdominal aortic aneurysm is defined as a focal dilation of the aorta of more than 50 % of its expected diameter, found in 1 % of the population over the age of 50 years old. Aneurysms may progress in size and result gradual wall weakening. The aneurysmal rupture occurs when the mechanical stress is in excess of the wall strength. The commonest sites of rupture are intraperitoneal (80%), luminal (aortoenteric fistula 1%-aortocaval fistula 3-4%) and retroperitoneal (20%).

Purpose:

We present a case of retroperitoneal aortic rupture with extension enlargement and hematoma of psoas muscle.

Material and Method:

Patient 68 years old admitted for evaluation of back and right leg pain. The pain was constant for the last 4 weeks. General physical examination showed a palpable mass in the right iliac fossa. CT Angiography scan was performed.

Result:

CT demonstrate a retroperitoneal hematoma caused by ruptured right iliac artery aneurysm with involvement of psoas muscle. Non-enhanced and contrast enhanced CT scan shows patchy areas of hyper attenuation (fresh hemorrhage) extended in the right psoas muscle. Signs of intraperitoneal extension of blood leakage is also evident along right paracolic gutter.

Conclusions:

Aortic aneurysm rupture presents an emergency that requires prompt diagnosis and surgical intervention. CT-Angiography is the standard imaging method for the accurate diagnosis.

PP 041

RETROPERITONEAL ABSCESS AND PERFORATED SIGMOID DIVERTICULITIS CT FINDINGS

Eirini Kasti, Eugenia A. Zbogo, Electra. Patsia – Zalavra, Chrisoula Kalamara, Penelope Lampropoulou, Charalampos Drosos
Rhodes General Hospital, Athens general Hospital Gennimatas, Athens Greece

Introduction:

Colonic diverticula are caused by herniating mucosa through defect on muscularis layer usually on the mesenteric side of the colon. The sigmoid and descending colon are the most common locations.

Colonic diverticulitis is considered a western civilization disease, with highest prevalence in USA, Europe and Australia. Fundamental pathogenesis factor is the diet regimen low in fibers. Prevalence of diverticula disease increase with age ,50-80% by the age of 80 and its rather uncommon under 40 years of age.

Usually colonic diverticula are asymptomatic. The obstruction of the diverticulum neck can cause diverticulitis with inflammation signs. Complications include local abscess formation, bowel occlusion, rupture, colovesical fistula and generalized peritonitis.





Purpose:

Our aim is to present the CT findings in a case on retroperitoneal abscess formation caused by perforation of inflamed diverticula of the sigmoid colon.

Material and Methods:

Patient male 70years old presented to the emergency room with pain in the left lower quadrant of the abdomen for 25 days. Medical history of diabetes and hypertension and laboratory tests showed increased white cell count, neutrophilia and mild elevation of CRP. A CT scan with i.v contrast media is currently the modality of choice for diagnosing and staging acute diverticulitis

Results:

The CT scan revealed a fluid collection containing air, delineated by an enhancement rim, localized retroperitoneally on the pelvis with diameter ~6cm. Also, wall thickening of sigmoid colon and numerous diverticula.

Conclusion:

Colon diverticulitis is complicated by perforation in approximately 8% of patients. Because diverticula are confined almost exclusively to the area between the mesenteric and the antimesenteric taenia, perforation to the retroperitoneal space or the subperitoneal space (sigmoid mesocolon) is seen less often than free or paracolic rupture. CT scan in acute diverticulitis is the modality of choice with a sensitivity and specificity almost 100%.

PP 042

ACUTE DURAL VENOUS THROMBOSIS – NON-ENHANCED CT AND DIAGNOSIS

Eirini Kasti, Eugenia A. Zbogo, Elektra Patsia-Zalavra, Chrisoula Kalamara, Penelope Lampropoulou, Dimitrios Karakiklas, Charalampos Drosos
 Rhodes General Hospital, Athens General Hospital Gennimatas, Athens Greece

Introduction:

Cerebral venous sinus thrombosis is an uncommon cerebrovascular event, accounting for 0.5–1% of cases of stroke. Is a disease of young adults (<50), accounting for 1-2% cases of stroke, diagnosis is based on clinical suspicion with confirmatory neuroimaging. Patients exhibit a wide range of nonspecific signs and symptoms creating a diagnostic challenge for the clinician and radiologist. Headache is the commonest symptom present in 90% of cases and also nausea and vomiting.

Risk factors include idiopathic conditions, hormonal (pregnancy, oral contraceptives, steroids), systemic illness (malignancy, sepsis, dehydration) and prothrombotic hematological conditions. Any of the dural sinuses can be affected in isolation or combined with others.

Non-enhanced head computed tomography is usually the first imaging investigation performed however if not associated with hemorrhage or infarction may be normal in up to two-thirds of patients with venous sinus thrombosis.

Purpose:

We aim to present a case of dural sinuses thrombosis (superior sagittal, straight and transverse sinus) and imaging characteristics with non-enhanced CT and further confirmation with CT Venography.

Material and Method:

Female patient 35 years old presented at the Emergency with headache, dizziness and nausea from 2 days, history of oral contraceptive pills uptake. A CT scan was performed.

Results:

Hyperdense appearance of venous sinuses on unenhanced CT, CT Venography confirmed the thrombus- lack of venous flow at superior sagittal, straight and transverse sinus.





Conclusion:

In acute stages of thrombosis, the sensitivity on unenhanced CT is higher as the sinuses are hyperdense. The increase in attenuation occurs due to clot retraction, elimination of water, and increased concentration of red blood cells and hemoglobin. Early detection of dural venous thrombosis with CT is important for initiation of anticoagulation therapy to prevent the propagation of thrombus and subsequent venous infarcts and hemorrhage.

PP 043

PERFORATED APPENDICITIS CT FINDINGS

Eugenia A. Zbogo, Eirini Kasti, Eleni Zafiriou, Penelope Lampropoulou, Chrisoula Kalamara, Charalampos Drosos
 Rhodes General Hospital, Athens General Hospital Gennimatas, Athens Greece

Introduction:

Acute appendicitis is the most common surgical emergency and the most common cause of abdominal pain in the Western population (7-12%). Is typically a disease of children and young adults. Is caused by the obstruction of the vermiform appendix lumen with infection, venous congestion, ischemia, necrosis and if untreated rupture and peritonitis. Due to high sensitivity (94-98%) and specificity (97%) CT is the imaging modality of preference for the diagnosis of acute appendicitis in addition to clinical and laboratory examinations.

Purpose:

We aim to present the CT findings of perforated appendicitis and the important role of CT in the prompt and correct diagnosis.

Material and Method:

Patient female 28-year-old presented in the Emergency, complain on increasing pain in the lower abdominal quadrants for the last 2 days. Laboratory tests demonstrate leukocytosis an increased C-reactive protein. A CT scan of the abdomen with i.v contrast was performed.

Results:

CT scan revealed specific findings of appendiceal rupture such as free intraperitoneal gas in the expected anatomical position, increased haziness of fat, fluid collections and a part of the retrocecal appendix with intense wall enhancement and diameter >1cm. CT scan indicates appendiceal rupture with distal dissemination on inflammatory changes

Conclusion:

CT scan can contribute in prompt and accurate diagnosis of appendicitis and its complications. With increased sensitivity and specificity is considered the initial diagnostic tool of choice regarding appendix pathologies.





PP 044

HYPERDENSE BASILAR ARTERY ON UNENHANCED CT – SIGN OF ACUTE THROMBOSIS OF POSTERIOR CIRCULATION

Eugenia A. Zbogo, Eirini Kasti, Sofia Gretou, Penelope Lampropoulou, Chrisoula Kalamara, Dimitrios Karakiklas, Charalampos Drosos
 Rhodes General Hospital, Athens general Hospital Gennimatas, Athens Greece

Introduction:

Basilar artery occlusion partial or complete result from a variety of causes such as embolism, primary atheromatous disease and vessel dissection. As result acute occlusion of posterior brain circulation can cause ischemia or infarction in the brainstem, cerebellum, thalami or occipital cortex.

Is a rare neuro-interventional emergency characterized by rapid neurological deterioration and high morbidity and mortality. Only 1% of posterior circulation strokes is caused by occlusion of basilar artery.

Purpose:

The hyperdense basilar artery sign on unenhanced CT scan is an indicator of acute (<24h) occlusion of the vessel. CT angiography for verification, is highly accurate in detecting absence of flow at basilar artery and can be of great utility in critical patients and also in dubious cases.

Suspicion and early detection on basilar artery occlusion is of great value for the treatment approach either is intravenous thrombolysis or intra-arterial thrombolysis-mechanical clot disruption.

Materials and Methods:

We performed at Emergency Department, unenhanced brain CT scan and CT Angiography at five patients with acute (24h) onset of posterior circulation symptoms and suspected occlusion of basilar artery. An hyperdense basilar artery sign can be depicted at unenhanced CT and CTA scan confirms the filling defect at the vessel.

Results:

Hyperdense basilar artery sign is a concrete and valid sign for early recognition of posterior circulation stroke. CT Angiography for verification can be of great value especially for dubious cases.

Conclusion:

Acute occlusion of basilar artery is a life threatening event, rare but with high mortality and morbidity among the few survivors. Is an easy missed uncommon but devastating true neurological emergency. Early recognition behalf of the radiologist is of extreme importance for the immediate patient treatment.





PP 045

CONE BEAM COMPUTED TOMOGRAPHY STUDY OF THE PREVALENCE OF PERIAPICAL RADIOLUCENCIES

Teodora Karteva¹, Neshka Manchorova-Veleva¹, Ekaterina Karteva¹, Donka Keskinova², Petya. Kanazirska³, Goergi Jordanov³, Stoyan Vladimirov¹

1 - Department of Operative Dentistry and Endodontics, Medical University - Plovdiv, Faculty of Dental Medicine, Plovdiv, Plovdiv, Bulgaria

2 - Department of Applied and Institutional Sociology, University of Plovdiv Paisii Hilendarski, Plovdiv, Bulgaria

3 - Department of Imaging Diagnostics, Dental Allergology and Physiotherapy, Medical University - Plovdiv, Faculty of Dental Medicine, Plovdiv, Bulgaria

Introduction

In the field of Endodontics, the three-dimensional reconstruction of anatomical structures provided by Cone Beam Computed Tomography (CBCT) enhances the diagnosis of periapical radiolucencies and the assessment of previous endodontic treatment.

Purpose

The purpose of this study was to investigate the prevalence of periapical radiolucencies in a Bulgarian subpopulation using CBCT scans.

Materials and Methods

160 Large FOV CBCT images were selected from the database of a dental radiology laboratory in Plovdiv, Bulgaria. 2795 roots were evaluated by two independent and calibrated examiners. The periapical status of each root was scored with the CBCT-PAI and PESS indices.

Results

The interexaminer agreement for the measurements varied between 0.892 and 0.983, a range of values spanning between strong and almost perfect agreement. According to the CBCTPAI and PESS indices, the prevalence of periapical lesions was 23.1% and 12.9 %, respectively. 34.1% of all roots were endodontically treated. 65% of all endodontically treated roots presented with signs of periapical radiolucencies, while only 1.4% of all non-treated roots had a periapical lesion. A significant association between periapical disease, poor quality of the root canal filling and inadequate coronal seal was established ($p < 0.001$).

Conclusion

This study underlined the high prevalence of periapical disease in endodontically teeth in the Bulgarian subpopulation. Poor root canal filling and inadequate coronal seal were assessed as prognostic determinants of treatment failure. The implementation of CBCT in the field of Endodontics can augment conventional diagnostic techniques. The support of Grant №07/2018 from Medical University – Plovdiv is acknowledged.

DISCLOSURE : Financial Interest Disclosure: NONE





PP 046

A REVIEW ON THE ADHERENCE TO GUIDELINES IN THE PREVENTION OF CONTRAST-INDUCED NEPHROPATHY IN YORK HOSPITAL AMONG FY1 DOCTORS

Dr Z Y Tan^a

^aYork Teaching Hospital NHS Foundation Trust, United Kingdom

Introduction

The management of acute kidney injury (AKI) is currently costing the NHS £1.2 billion a year, with the administration of intravenous iodinated contrast being one of the most common causes of AKI.¹ Contrast-induced acute kidney injury (CI-AKI) usually occurs within 2-3 days of exposure to contrast, with serum creatinine peaking at 72-96 hours and then falling spontaneously.²

The Royal College of Radiology (RCR) and National Institute for Health and Care Excellence (NICE) have published guidelines to reduce the incidence of CI-AKI.² This can be done by prescribing appropriate intravenous (IV) fluids for pre- and post-contrast administration. A local guideline has also been developed in York Hospital to minimise the incidence of CI-AKI.

Doctors, especially Foundation Year 1 (FY1) doctors play a crucial role in the detection of AKI and prescribing IV fluids.

Aim:

Hence, this project was performed to review the adherence to the guidelines among FY1 doctors in preventing CI-AKI.

Methods

A questionnaire was used and handed out to FY1 doctors working in York Hospital.

Results

21 FY1 doctors responded to the initial questionnaire. Only 16 doctors (76%) were aware of the guideline; and 11 doctors (52%) prescribed the correct fluid with correct rate.

Intervention included formal teaching sessions, putting up posters and circulation of emails.

Following the intervention, a re-audit was performed. 20 FY1 doctors responded. All 20 doctors (100%) were aware of the guideline with 19 of 20 doctors (95%) prescribed the correct fluids with correct rate.

Conclusion

Doctors play a crucial role in preventing CI-AKI, and this is best done by vigilant prescription of intravenous fluids.

Reference:

1. Estimating the financial cost of chronic kidney disease to the NHS in England. Kerr M1, Bray B, Medcalf J, O'Donoghue DJ, Matthews B. Nephrol Dial Transplant. 2012 Oct;27 Suppl 3:iii73-80. doi: 10.1093/ndt/gfs269. Epub 2012 Aug 5
2. Acute kidney injury: Prevention, detection and management of acute kidney injury up to the point of renal replacement therapy Clinical guidelines, CG169 - Issued: August 2013 <http://guidance.nice.org.uk/cg169>



**PP 047****A CASE OF MULTIPLE PARAGANGLIOMAS OF THE NECK CT DIAGNOSIS**

Eugenia A Zbogo, Eirini Kasti, Eleni Zafiriou, Penelope Lampropoulou, Chrisoula Kalamara, Dimitrios Karakiklas, Charalampos Drosos
Athens General Hospital G. Gennimatas , Athens, Greece

Introduction:

Paragangliomas are neuroendocrine tumors slowly growing, usually benign that represent 0.012% of all tumors. Paragangliomas can occur in individuals at any age, although most arise in the fourth or fifth decades of life with equal sex predilection. Most paragangliomas are solitary and arise sporadically although they can be multicentric (10%) with familial occurrence.

Paragangliomas arise from extra-adrenal paraganglia, derived embryonically from the neural crest cells of the autonomic nervous system and they may occur anywhere from the skull base to the pelvic floor along with the distribution of paraganglia. In the head and neck region paragangliomas are located in four primary sites: the carotid bifurcation, the jugular bulb, the tympanic plexus and the vagal ganglia. Less common sites are the nose, larynx, parotid gland, orbit and thoracic inlet.

Most of the tumors in the head and neck belong to the group of nonchromaffin paraganglioma as the don't secrete catecholamines.

Purpose:

The present case report presents a case of multiple paragangliomas involving the carotid body and vagal region.

Material and Method:

Patient male 45years old, presented on otolaryngology department complaint for painless swelling of the upper right region of the neck, present from last four years and with insidious onset and progressed gradually. A CT scan of the neck with i.v contrast was performed.

Result:

Contrast enhanced CT scan revealed 3 lesions with intense enhancement. The at the level of right carotid bifurcation is evident large (~9cm) inhomogeneous tumor causing splaying of ICA-ECA, above and underneath this level are localized two more smaller paragangliomas also with areas of necrosis.

Conclusions:

Accurate diagnosis of paraganglioma is thought to be difficult, and therefore both clinical findings and radiographic studies are essential to determine the diagnosis.





PP 048

PULMONARY ARTERY DISSECTION AS COMPLICATION OF AORTIC DISSECTION CT EVALUATION

Eugenia A. Zbogo, Eirini Kasti, Sofia Gretou, Penelope Lampropoulou, Chrisoula Kalamara, Charalampos Drosos
 Athens General Hospital G. Gennimatas , Athens, Greece

Introduction:

Aortic dissection occurs when blood enters the medial layer of aortic wall through a tear or penetrating ulcer in the intima layer, forming a second blood filled channel -the false lumen. Is the most common form of acute aortic syndrome with devastating results and high mortality. Risk factors include hypertension, connective tissues disorders (Marfan sdr, Ehlers-Danlos sdr.), structural aortic abnormalities (bicuspid aortic valve, aortic coarctation), atherosclerosis, vasculitis, pregnancy, iatrogenic causes etc.

Purpose:

We present a case of Stanford type A -De Backey 1 aortic dissection with extension through the pulmonary artery and the presence of intramural hematoma to the main and especially the left pulmonary artery.

Material and Method:

A 64 years-old male presented at the Emergency room with chest pain and shortness of breath. Medical history of hypertension. A CT angiography of aorta was performed.

Results:

CT angiography showed a Stanford type A -De Backey 1 aortic dissection with extension through the pulmonary artery and the presence of intramural hematoma to the main and especially the left pulmonary artery. The intramural hemorrhage extended along the lower lobes pulmonary arteries with resultant peribronchovascular ground glass opacity, consistent with pulmonary hemorrhage.

Conclusion:

The extension of the aortic dissection Stanford type A, through the pulmonary artery is a result of rupture through the posterior aspect of the aortic root into the common adventitia of aorta and pulmonary artery. Is a life threatening condition requires prompt diagnosis and treatment.



**PP 049****SYNOVIAL HEMANGIOMA – MRI PRESENTATION**

Milenkovic Radovan

Institute of Rheumatology, Belgrade, Serbia

Introduction: Synovial hemangiomas are rare, benign vascular malformations that occur in relation to the joint and are often quite difficult to diagnose.

Case report: We are presenting a case of male patient at the age of 23 years, who presented for MR examination with intense pain and limited movements in his left knee, without significant medical history, but after detailed questioning information about the sport's injury that occurred a more than a year before the examination was given.

MR examination demonstrated a lobulated popliteal mass with unusual MR signal characteristics, that together with enhancement pattern of the lesion suggested the diagnosis of hemangioma.

Lesion was surgically excised two weeks later and histologic findings were confirmatory.

Conclusion: It is important to consider synovial hemangioma in cases of non-specific symptoms and pain, especially at the knee joint. Magnetic resonance imaging presents the main diagnostic tool for this rare lesion.





PP 050

THE VALUE OF PRONE MYOCARDIAL PERFUSION IMAGING IN BREAST ATTENUATION ARTEFACT AND HOW OFTEN IT CAN OBTAIN THE NEED FOR A REST STUDY

Fragkaki Christina, Archontaki Aikaterini

Nuclear Medicine Physician, Md, Phd, Nuclear Medicine Department, Chania General Hospital, Greece

INTRODUCTION: In myocardial perfusion SPECT studies, inferior wall artefact caused by diaphragmatic attenuation and anterior wall artefact due usually to breast attenuation, is a common finding.[1,2] The value of prone imaging has been well established in the former but needs further investigation in the latter.[3]

PURPOSE: To assess the role of prone imaging in attenuation artefacts with emphasis to breast attenuation artefact and to demonstrate how often a subsequent rest study was avoided.[4,5]

MATERIALS AND METHODS: In an eight month period that our department started to work, a total of 381 patients underwent myocardial perfusion imaging with an Infinia-II GE Dual-detector γ -camera with either ^{99m}Tc -MIBI or ^{99m}Tc -tetrofosmin. From those, 248 studies with both supine and prone acquisitions were retrospectively assessed. Prone imaging acquisition was performed when there was what seemed to be reduced perfusion in the anterior wall (40), in the inferior wall (137) or both (71). The images were evaluated by two independent specialists. Rest imaging acquisition was not performed when stress prone images showed normal perfusion in the wall in question.

RESULTS: From 248 prone studies, improvement was shown in 45/111 anterior wall defects (40.5%) and in 120/208 inferior wall defects (57.7%) proving attenuation artefacts. From those 9/71 patients showed improvement in both defects (12.7%) simultaneously. Rest imaging acquisition was safely omitted in 45/248 patients (18.2%) with normal prone stress studies, avoiding unnecessary radiation exposure.

CONCLUSION: Prone imaging helps diagnose soft tissue attenuation artefacts not only to inferior wall defects but to anterior wall defects known as "breast attenuation artefact" as well. With prone imaging, patients can often avoid unnecessary radiation exposure since rest myocardial perfusion studies with ^{99m}Tc agents, need a second radiopharmaceutical injection.





PP 051

EXTRAVENTRICULAR NEUROCYTOMA MRI FINDINGS: A CASE REPORT

Turnaoglou Hale, Kahraman Gokhan, Haberal Kemal Murat, Kural Rahatli Feride, Agildere Ahmet Muhtesem

Baskent University, Faculty of Medicine, Department of Radiology, Ankara, Turkey

INTRODUCTION AND PURPOSE: Extraventricular neurocytoma is a very rare parenchymal tumor with neurocytoma features in the cerebral hemispheres. Although it is frequently reported in adults, it is very rare in the pediatric population. In this report, we aimed to present the MRI findings of a pediatric patient diagnosed with extraventricular neurocytoma.

CASE PRESENTATION: A 14-year-old male patient was referred for cranial MRI to our department, who had headache and double vision. Contrast-enhanced MRI showed a heterogeneous cystic necrotic and solid mass, extending from the right parietal lobe to the frontal lobe, causing minimal shift in midline structures. Contrast enhancement was observed in the solid components of the mass. There were vasogenic edema around the mass (figure 1, 2). Diffusion restriction was present in the solid components of the mass on DWI (figure 3). The patient was operated and the pathological diagnosis was reported as extraventricular neurocytoma. In the pathology report, an increase in mitotic activity, necrosis, microvascular proliferation, and a high Ki-67 proliferation index were reported and close follow-up was recommended because of increased risk of recurrence.

DISCUSSION AND CONCLUSION: Extraventricular neurocytomas are called central neurocytoma-like tumors. In terms of imaging properties, extraventricular neurocytomas are generally well-defined, heterogeneous masses, which have cystic and solid components. Calcification and peritumoral edema are frequently present. They usually show more malignant biological behaviors associated with atypia, high recurrence rate, and shorter duration for recurrence, than central neurocytomas. Total surgical resection is a treatment that provides significantly good results. Since our knowledge of extraventricular neurocytoma is limited, series with long follow-up data are required to guide management protocols. Extraventricular neurocytomas should be considered in the differential diagnosis of brain parenchymal masses with cystic necrosis, calcification, bleeding foci and contrast-enhancing solid components in young patients. Patients should be follow-up closely because of the possibility of recurrence.





PP 052

ILEAL NEUROENDOCRINE TUMOR DIAGNOSED WITH SUBMANDIBULAR GLAND METASTASIS: A CASE REPORT

Turnaoglou Hale, Kahraman Gokhan, Haberal Kemal Murat, Kural Rahatli Feride, Agildere Ahmet Muhtesem

Baskent University, Faculty of Medicine, Department of Radiology, Ankara, Turkey

INTRODUCTION AND PURPOSE: Neuroendocrine tumors of the small intestine are usually slow-growing tumors that tend to metastasize to organs and lymphatic tissues in their immediate neighborhood. In this report, we aimed to present neck MRI and abdominal CT findings of ileal neuroendocrine tumor diagnosed with submandibular gland metastasis.

CASE PRESENTATION: A 75-year-old male patient who had swelling under the jaw was referred to our department. Ultrasonography revealed a solid mass in the left submandibular gland. Neck MRI showed a heterogeneous mass in the left submandibular gland (figure 1). Mild diffusion restriction was present in the mass on DWI (figure 2). Submandibular gland excision was performed. Pathological diagnosis was reported as neuroendocrine carcinoma. Abdominal CT examination for detection primary tumor focus revealed diffuse wall thickening at the level of the distal ileal segments and a spiculated mass in the mesentery (figure 3), consistent with neuroendocrine tumor. Mass resection was performed and pathologic diagnosis was reported as neuroendocrine tumor.

DISCUSSION AND CONCLUSION: Although neuroendocrine tumors can be seen in extra-gastrointestinal regions, both primary and metastatic presentation in the head and neck regions are very rare. Approximately 20% of the patients have metastasis at the time of diagnosis, while seen in 35-40% in the follow-up. Metastatic involvement is most commonly seen in liver, mesentery and peritoneum. Metastasis to salivary glands is very rare in gastrointestinal neuroendocrine tumors. It is important to increase awareness of neuroendocrine tumors, due to their increased incidence and often delayed diagnosis due to non-specific symptoms. The possibility of metastasis should also be considered in the initial presentation of neck masses. Furthermore, as recurrences have been reported even years later, the possibility of metastasis should be kept in mind in the head and neck region masses, detected in patients with neuroendocrine tumor.





PP 053

REMOTE CEREBELLAR HEMORRHAGE CT FINDINGS: A CASE REPORT

Turnaoglou Hale, Kahraman Gokhan, Haberal Kemal Murat, Kural Rahatli Feride, Agildere Ahmet Muhtesem

Baskent University, Faculty of Medicine, Department of Radiology, Ankara, Turkey

INTRODUCTION AND PURPOSE: Remote cerebellar hemorrhage is a very rare benign complication seen after supratentorial craniotomy or spinal surgery. In this report, we aimed to present the CT findings of a patient with remote cerebellar hemorrhage who was operated for subdural hematoma.

CASE PRESENTATION: A 81-year-old male patient who admitted to the emergency department with head trauma, was referred to our department for cranial CT. CT examination revealed subdural hematoma in the bilateral cerebral hemisphere (figure 1). The patient was operated. The patient's postoperative control cranial CT showed acute hematoma in the right cerebellar hemisphere, consistent with remote cerebellar hemorrhage (figure 2). No additional intervention was considered. During follow-up, both subdural and cerebellar hematomas were resorbed (figure 3).

DISCUSSION AND CONCLUSION: Although remote cerebellar hemorrhage occurs most commonly after frontotemporal or frontal craniotomy, it has not been associated with any specific surgery. The most common symptom is altered level of consciousness. Other symptoms include motor deficits and ataxia. Some cases are asymptomatic and incidentally detected on postoperative CT or MRI. Although postoperative cerebrospinal fluid hypovolemia is thought to cause cerebellar sagging and occlusion of superior penetrating veins, and thus hemorrhagic infarction, the exact cause of remote cerebellar hemorrhage is unknown. It is considered a self-limiting complication. Most patients do not require intervention. The location and size of bleeding is an important prognostic factor. If bleeding is large enough to cause a mass effect resulting in obstructive hydrocephalus, surgical intervention may be necessary. Smaller hemorrhages with little or no mass effect are self-limiting. CT follow-up helps in assessing the natural evolution of bleeding.

PP 054

METHODOLOGY OF SEMI-AUTOMATIC EPICARDIUM FAT QUANTIFICATION WITH SLICER 3D USING ECG-GATED CARDIAC CT

Samar El Shemeri^{1,2}, Georgi Valchev^{1,2}, Sofia Chausheva¹, Svetomir Chakarov¹, Ralitsa Popova³, Boyan Balev^{1,2}

1 UMHAT "Saint Marina" Varna, Bulgaria

2 Medical University of Varna "Prof. D-r Paraskev Stoyanov", Bulgaria

3 UMHAT "Heart and Brain Center of Excellence" Pleven, Bulgaria

Abstract:

Introduction: In the recent decade epicardial fat has been found to be a factor of significance for a variety of diseases (sources). In light of this our research team has developed a method of quantifying epicardial fat using an open-source software package (Slicer 3D 4.10) to process data from ECG-gated computed tomography of the heart.

Purpose: This work describes the specific steps that are taken to facilitate the measurement - from image acquisition guidelines to post processing in Slicer 3D.





Materials and Methods: The scans used are obtained using an adapted low-dose prospective ECG-gated helical scanning protocol on a 64-slice Siemens Somatom Verio device, without contrast enhancement. Patients with arrhythmia are scanned with a retrospective protocol by exception. The images are then anonymized and exported to independent workstations equipped with Slicer 3D, on which the measurements take place. The semiautomatic nature of the measurement lies in the application of a Hounsfield unit (HU) threshold, which selects all voxels within the range of -200 and -30HU. Following that, the selection is manually edited by the operator to correspond to the epicardial fat deposits. This step can be expedited by use of a graphics stylus. The final selection volume can then be automatically quantified by the software. The total time needed for full postprocessing of a single patient performed by a trained radiologist is under 20 minutes, with the potential for further shortening. This process does not require dedicated expensive workstations or proprietary complex software, making it very accessible.

Results and Conclusion: We have created an affordable, easily reproducible, and relatively expedient method of measuring epicardial fat from CT images. These measurements can benefit future medical research in various fields.

Keywords: computed tomography, cardiac applications, epicardial fat, semi-automatic quantification, postprocessing

PP 055

SECONDARY COMPUTED TOMOGRAPHY FINDINGS IN URETERAL STONES

Mehtap ILGAR, Mehmet AKCICEK, Suzan TUNC

From the Department of Radiology, Malatya Training and Research Hospital, Malatya, Turkey

Introduction: Unenhanced computed tomography (CT) as an initial imaging modality for patients with acute flank pain referred for urinary stone disease management. In addition to direct stone visualization secondary CT signs of ureteral obstruction have been previously described. These secondary signs include : asymmetric perinephric fat stranding, hydronephrosis, hydroureter, tissue rim sign, unilateral renal enlargement and unilateral absence of white renal pyramids. This has been reported to be useful in differentiating ureteral calculi from extraurinary calcifications.

Objective: The purpose of this study was to determine the incidence of secondary signs associated with [ureteral stones](#) on unenhanced CT scans.

Material and Methods: All CT examinations were performed according to the departmental protocol using a 16-slice MDCT scanner. We included the CT scans performed on adult patients (18 years and older) presenting to our urology departments with signs or symptoms suggesting renal colic/an obstructing ureteral calculus. A total of 324 non-contrast MDCT examinations performed have been met our inclusion criteria.

Results: A urinary calculus was identified in 60.5% including males 68.4% and females 49.6%. Positive results were significantly higher in men with P values < 0.001. There were hydronephrosis in 61.7%, hydroureter in 62.7% , perinephric fat stranding in 36.2% , tissue rim sign in 38.3%, renal enlargement in 14.9%, absence of white renal pyramids in 15.9% with ureteral stones. Of the patients with ureteral stones, only 7.4% had no secondary findings and 92.6% had at least one secondary finding.

Conclusion:

Secondary findings may be useful in cases of difficulty in distinguishing ureteral stones from extrauretic calcifications.





PP 056

RARE CASE OF GIANT LYMPHOEPITHELIAL CYST LOCALISED ON THE GROOVE AREA.

Rigkas A., Sotiriadou A., Papaioannou S., Giataganas G.

Radiology Department/"Papageorgiou" General Hospital of Thessaloniki/ Thessaloniki/ Greece

Introduction

Lymphoepithelial cyst (LEC) of the pancreas is an extremely rare benign cystic lesion, that is characterised by keratinised mature squamous epithelium surrounded by lymphoid tissue.

Purpose

Our purpose was to present a case of a large cystic lesion in the groove area between the duodenum and the pancreatic head that histologically turned to be a LEC.

Material and Methods

The patient visited our hospital due to chronic right upper abdominal pain. After an inconclusive clinical examination, an abdominal computed tomography (CT) and magnetic resonance imaging (MRI) were performed demonstrating a cystic lesion between the pancreas and duodenum. A CT-guided core biopsy of the lesion followed, and its progress was monitored with follow-up abdominal MRIs every 6 months for the next 3 years.

Results

Abdominal CT and MRI demonstrated an exophytic, multilocular, mainly cystic lesion, measuring 8x9,3x7,5cm, in contact with head and uncinete process of pancreas extending till the caudate lobe of liver. The lesion exerted pressure on the common bile duct causing mild duct stenosis. The histopathological evaluation of the biopsy specimen demonstrated keratinised stratified squamous epithelial lining with increased lymphocytic reaction, and no signs of malignancy. The findings were diagnostic for lymphoepithelial cyst of the pancreas and no further steps were made.

Conclusion

LEC is a rare entity with very few cases reported so far. In contrast with its most common localisation in the body and tail of pancreas, we described a case of a LEC extending on the pancreatoduodenal groove.





PP 057

SIGNIFICANCE OF ULTRASOUND IN DETECTION OF THYROID GLAND LESIONS

Juković Mirela^{1,2}, Hadnađev Darka¹, Mrdjanin Tijana¹, Donat Daniela¹, Nićiforović Dijana^{1,2}

¹Clinical Centre of Vojvodina, Centre for Radiology

²Medical Faculty of Novi Sad, University of Novi Sad

Introduction: Thyroid gland is very important in human because of its role in metabolism, growth and tissue differentiation. Ultrasound of thyroid gland is the primary method in evaluation of gland morphology, detection and recognition of diffuse or focal thyroid lesions. Classification of the thyroid nodes also could help in decision-making for fine-needle aspiration cytology. Together with the evaluation of thyroid gland, ultrasound could show and describe lymph nodes in the neck that could be indirect markers of the pathological process in the neck, especially in malignant nodes of the thyroid gland.

Purpose: The purpose of this study is to give overview of thyroid gland lesions and significance of the ultrasonography examination.

Material and methods: In our study, in Clinical Centre of Vojvodina, Centre for Radiology, from October 2018 until May 2019 (8 months) 309 patients with clinically suspect thyroid lesions and changes in the level of thyroid hormone were examined by ultrasound.

Results: About 15% of patients thyroid gland had normal sonographic appearance. Diffuse thyroid lesions (autoimmune thyroiditis) were present in about 20.5% of patients. Benign lesions such colloid cysts and microcysts in the parenchyma were present in about 13.5% and macrocalcifications were present in about 3.5% of patients. Predominantly patients had solid thyroid nodules (about 42%) with hypo- or hyperechogenicity or mixed sonographic appearance. About four percent (4%) of patients had unilateral lobe thyroidectomy. Adenoma of the parathyroid glands were present in about 2.5% of ultrasound examined patients.

Conclusion: Ultrasound is the safe and sensitive method for examination of the thyroid lesions.





PP 058

ANTERIOR IMPAGEMENT SYNDROME IN FORMER BASKETBALL PLAYER-CASE REPORT

Tanja Petrovska

PHI University Clinic for Surgical Diseases "St. Naum Ohridski-Skopje" N.Macedonia

Introduction- The Anterior impagement syndrome is an assembly of pathology of the joint that involves soft changes as well as bone changes.

There is a compression of the front margin of the tibial-joint joint in the performance of hyperdorsoflexion.

Purpose-to emphasize the use of mr-artrography in AIS and the significance of detecting cartilage defects.

Material and methods-case report of x- ray of the ankle, mri and mri arthrography of the ankle.

Conclusion-The MR-artrography as a method is useful in anterior impagement syndrome because it does not provide an image of the hinged proctor, the tendons of the tendons, the defects of the problem that if they are combined with changes seen only on the MRI, give the complete picture of the changes.

Key words- ankle x- ray,mri mri-artrography .

Literature

1. Imaging of ankle impingement - an update ESSR 2016 E. Sellon, P. Robinson; Leeds/UK
2. MRI imaging of impingement syndromes of the ankle. ECR 2015 M. E. Banegas Illescas¹ , M. L. Rozas Rodríguez¹ , L. Caminero Pardo¹ , A. Pinar Ruiz¹ , M. Y. Torres Sousa² , C. López Menéndez¹ ; 1Ciudad Real/ES, 2Ciudad Real, Spain/ES ECR 2015
3. Ankle impingement syndromes Masciocchi, Carlo et al. European Journal of Radiology , Volume 27 , S70 - S73
4. Ankle Ligaments on MRI: Appearance of Normal and Injured Ligaments Kiley D. Perrich, Douglas W. Goodwin, Paul J. Hecht, and Yvonne Cheung American Journal of Roentgenology 2009 193:3, 687-695
5. MRI and MR arthrography in evaluation of chronic ankle pain and correlation with clinical outcome in ligament injury and impingement syndromes ECR 2017





PP 060

CHARACTERISTIC APPEARANCES OF PULMONARY FAT EMBOLISM ON CT PULMONARY ANGIOGRAM

Sonja Jovanoska, MD¹, Ivona Jovanoska, MD², Marija Bunda Kalpak, MD³, Anita Lazarevska MD¹; Slavica Jakimovska MD⁴

West Suffolk Hospital, Bury St Edmunds, UK¹; City General Hospital "8th September" Skopje, MKD²; PHI Dijagnosticki Centar Skopje, MKD³; General Hospital Kumanovo, MKD⁴;

Introduction

Pulmonary fat embolism is a specific subtype of pulmonary embolism where the embolic particles in the pulmonary circulation are composed of fat. This usually occurs in the context of a long bone fractures and during orthopedic prosthetic procedures. May occur in 1-3% of patients with simple tibial or femoral fractures and in up to 20-33% of patients with more severe trauma. Patients usually develop symptoms of pulmonary dysfunction around 24-48 hours after the traumatic insult, which has characteristic appearances on a CT pulmonary angiogram.

Purpose

The consequences of pulmonary fat embolism are especially well depicted on contrast enhanced CT studies, therefore imaging may aid to exclude competing differential diagnosis or be suggestive of fat embolism.

Materials and Methods

Retrospective analysis of CT findings in 4 patients diagnosed with pulmonary fat embolism was done. Pulmonary angiogram was performed on 64 slices CT scanner with 4ml/sec injection of 60-100ml of CM (300mg/ml) via 18G cannula.

Results

All the patients presented with short of breath with increasing oxygen requirements and pyrexia 24h after operatively treated fractures of hip or other long bones. The most common abnormalities in all 4 CT studies were bilateral lung changes with regional ground glass densities associated with septa thickening in 3 patients. In 2 patients nodular/patchy densities were also seen more in the upper lobes and tiny pleural effusions. Although in 2 patients there was suboptimal, below 200 HU density, opacification of the pulmonary trunk, in non of the patients filling defect was seen in the pulmonary vessels. All patients recovered on subsequent imaging. Treatment remains supportive.

Conclusion:

Diagnosis of pulmonary fat embolism is based mainly on clinical findings beginning 24-48h after trauma, surgery or long bone fracture. However, appearances on CT pulmonary angiogram are characteristic therefore, this is modality of choice to exclude competing differential diagnosis and establish the diagnosis diagnosing about 90% of cases.





PP 062

PNEUMATOSIS AND PSEUDOPNEUMATOSIS

Terzic Nevena, Begenisic Biljana, Arsenovic Srdjan
 Kbc Dr Dragisa Misovic Belgrade ,Serbia

a) Introduction

Pneumatosis intestinalis, defined as gas in the bowel wall, is a radiographic finding and not a diagnosis, as the etiology varies from benign conditions to fulminant gastrointestinal disease. It is one of the most concerning radiologic pattern because it can be seen in life-threatening situations in patients with ischemia and impending bowel perforation, who need immediate therapy. On the other hand, pneumatosis can also be found as an incidental finding in patients without abdominal complaints. Very often gas adjacent to the bowel wall can mimic pneumatosis. This is called pseudopneumatosis. And the most important task of a radiologist is to separate these two entities.

b) Purpose

Discuss and specify CT findings of pneumatosis intestinalis and pseudopneumatosis, with an emphasis on their differences.

c) Materials and Methods

Computed tomography (CT) is widely used to assess patients with nonspecific abdominal pain or obstruction. We will demonstrate the most representative CT findings in our daily praxis.

d) Results

Primary pneumatosis intestinalis occurs most frequently in the colon of adults and is usually cystic. This condition is relatively benign, and frequently resolves spontaneously. Small intestinal involvement, in the adult, is associated with a variety of conditions, many of them serious. The distribution of the gas is usually linear. Air in the portal system is a grave prognostic sign and generally indicates intestinal necrosis.

Pseudopneumatosis is especially seen in the cecum and ascending colon where gas bubbles can be trapped between fecal debris and the mucosa. It can also be mistaken with the „string of pearls sign“, which is typical for small bowel obstruction (SBO).

e) Conclusion

From a clinical perspective, it is essential not to confuse the incidental imaging finding of asymptomatic pneumatosis with symptomatic pneumatosis because the treatment is significantly different.





PP 063

PRIMARY MALIGNANT LYMPHOMA OF THE VAULT : THE ROLE OF COMPUTED TOMOGRAPHY AND MAGNETIC RESONANCE IMAGING IN THE DIAGNOSIS AND THE TREATMENT PLAN. A CASE REPORT.

Baroutsi Kyriaki¹, Barbagianni Eleni², Bouchra Kontstantina¹, Stamouli Euaggelia³, Ispanopoulou Sofia¹, Fakou Anastasia¹, Kazakidis Panagiotis¹.

⁵ Department of Computed Tomography, General Hospital of Nikea "Agios Panteleimon", Piraeus, Greece

⁶ Health Center Piraeus, Greece

⁷ Department of Radiology, General Hospital of Athens "Hippocrates", Athens, Greece

⁸

a)Introduction: The primary malignant lymphoma of the vault is a very rare condition with intracranial and extracranial involvement and accounting for <5% of bone tumors and <1% of non-Hodgkin lymphoma with male predominance in about fifth decade of life.

b)Purpose: To present a case of rare vault malignant lymphoma as a cause of palpable mass of the scalp extended to the epidural space with no significant osteolytic lesions.

c)Materials and methods: A 55 years old male with two mass lesions over the left frontal and temporal region of the skull and at the right parietal bone at the level of postcentral gyrus. The expanding lesions enlarged slowly in the past six months and caused mild headache without any traumatic brain injury.

No signs of inflammation or tenderness were detected, no neurological defects and no lymphadenopathy or organomegaly was maintained.

Plain X-ray showed soft tissue density and ct scan- MRI images detected hyperdense masses extending intra- and extra-cranially over the above bone regions, with only a minimal hyperostosis and without significant bone erosion.

d)Results: Imaging characteristics of cranial lymphoma are nonspecific. The differential diagnosis of calvarian bone tumors include intraosseous meningioma or metastases

e)Conclusion: Presence of the tumor on the sculp and dura sides, without bone invasion between might be one of the characteristic of primary lymphoma. CT and MRI images play an important role in the non-invasive diagnosis.





PP 064

PERCUTANEOUS TREATMENT OF THE HEPATIC ECHINOCOCCOSIS IN THE CLINICAL CENTER OF VOJVODINA

Stojic Ivana , Stojanovic Sanja, Drazetin Ljiljana , Radic Maja, Akhan Okan

Faculty of Medicine, University of Novi Sad; Clinical Center of Vojvodina, Center for Radiology, Novi Sad, Serbia

Introduction: Echinococcal liver hydatid disease is a parasitic infection brought on by infection with small tapeworms of the genus *Echinococcus*. A person is infected accidentally, by contact with an infected animal. Its treatment can be surgical, medical and percutaneous. Percutaneous treatment provides an adequate alternative to surgical treatment. It is used because it is minimally invasive, to prevent cyst scattering, reduce the risk of anaphylaxis and decrease the number of days in the hospital.

Purpose: The aim of our study was to present the initial results of percutaneous treatment of hydatid disease, which has been conducted in the Clinical Center of Vojvodina for the last five years in the Center for Radiology, in cooperation with the Hacettepe University Hospital.

Materials and methods: A study was conducted on 29 patients who were treated for hydatid liver disease, in the period from 2014 to 2019 in the Center for Radiology and Clinic for Infectious Diseases, with a control of one to five years after the treatment. All echinococcal cysts were diagnosed by ultrasound, categorized based on the Gharbi classification, and accordingly to that treated with percutaneous treatment.

Results: 19 out of 29 patients succumbed PAIR method, 9 out of 29 did MoCaT and 1 patient had one cyst done with PAIR method and the other with modified catheterization. All patients had indirect hemagglutination test positive. Size of the cysts was reduced by 39% after the intervention and all cysts except one were nonviable. Relapse occurred in only one patient and accordingly to that, the cyst was treated twice.

Conclusion: Percutaneous treatment of echinococcal liver disease is a minimally invasive method, with a low percentage of periprocedural and postprocedural complications and a short period of hospitalization.





PP 065

TU IS NOT ALWAYS A TU

Sofka Malenko, General Hospital, Department of Radiology, Ohrid

Aleksandra Markoska Dameska, General Hospital, Department of Radiology, Ohrid

Asim Mussa, Ministry of health, R. North Macedonia

Introduction:

Case report - Tu vesicae urinariae

Material and methods:

Patient 64 old man with hematuria, often urinating and burning urination.

Occasional lumbal and pelvic pain, nausea.

We used:

Ultrasound - we found the left kidney with hidronephrosis II-III degree. Vesica urinaria with irregular contours, thickened walls and Tu mass inside. The mass is heteroeogenic irregular and swimming like a foreign body.

Plain radiography of UT, we found an increased shadow of the left kidney and shadow of little pelvis.

Laborathory - hematuria

CT investigation with **iv** contrast, we found the left kidney with hidronephrosis II - III degree. Left ureter dilated.

Vesica urinaria with thickened heterodenzitet and trabeculized walls with divertikulum. Inside we are watching the oval mass heterodenzited with free air in the same. The mass is moving free in the vesica urinaria (swimming like a foreign body).

After **iv** contrast the mass accumulated the contrast.

Results:

Ddg Tu Vesicae urinariae

The patiten was operated.

Patohistologycal analisys we verified:

The mass is not Tu. The mass contain neutrofili and calcificats, but not tumor cages.

Conclusion:

The mass inside the vesica urinaia with hematuria is not always a Tu!





PP 066

ACUTE SINUSITIS COMPLICATED BY ORBITAL SUBPERIOSTEAL ABSCESS

Markou Andreas¹, Rizou Aikaterini², Mauroeidi Vasiliki¹, Noniasvili Liana¹, Anastasiou Aikaterini¹, Grigoriadis Lazaros¹, Vakalopoulos Athansios¹, Gkountelas Georgios¹

¹Department of Radiology, General Hospital of Florina, Greece

²Otorhinolaryngologist (ENT), Florina, Greece

Introduction: Orbital infection is an uncommon devastating infection and is usually a complication of paranasal sinus infection. It occurs when pathogens pass from an infected maxillary, ethmoidal, frontal, or sphenoid sinus into the orbit, either directly through neurovascular foramina or a congenital or acquired bony dehiscence, or indirectly through valveless veins of the sinuses and orbit.

Purpose: The aim of this study is to show that the head multidetector computed tomography (HMDCT) is efficient and sufficient method in the rapid diagnosis of orbital infection and should be immediately referred method if MRI is not available.

Materials and Methods: A 15-year-old patient presented with left painful proptosis and ophthalmoplegia after an attack of acute sinusitis. Her past medical history was unremarkable, and no previous visual compromise was reported. The pediatrician ordered an urgent HMDCT.

Results: HMDCT demonstrated left ethmoid sinusitis and partial obliteration of ipsilateral sphenoid, frontal and maxillary sinuses. There was elliptical fluid collection at the medial aspect of the left orbit, extra conal in location and displaces the medial rectus laterally (subperiosteal abscess). In addition, there was increased thickness of skin and soft tissue overlying the mediolateral area of the left orbit. The cavernous sinus was not thrombosed. The patient was referred to an otolaryngologist and underwent functional endoscopic sinus surgery (FESS) under general anaesthesia. The postoperative course was uneventful and the patient was discharged on the fourth postoperative day with an antibiotic therapy

Conclusion: MDCT is a fast, non-invasive and efficient tool to evaluate the complications of paranasal sinus infections. Without appropriate treatment, orbital infection may lead to serious complications, even death. Early diagnosis and prompt treatment is mandatory to avoid visual loss or intracranial complications.





PP 067

RENAL INJURY GRADE IV -CT FINDINGS

Eugenia A. Zbogo, Eirini Kasti, Sofia Gretou, Penelope Lampropoulou, Chrisoula Kalamara, Charalampos Drosos
Rhodes General Hospital, Athens general Hospital Gennimatas, Athens Greece

Introduction:

Renal injury is seen in approximately 8%–10% of patients with blunt or penetrating abdominal injuries. The majority (80%–90%) of cases involve blunt rather than penetrating injury. Computed tomography can provide essential anatomic information required to determine management of intraabdominal and retroperitoneal injuries sustained by abdominal trauma. It can help in evaluation of the type and severity of parenchymal injury, the extent of perirenal hemorrhage and parenchymal devascularization and the presence of urinary extravasation. Indications for the use of CT for the evaluation of renal trauma are: macroscopic or microscopic hematuria and shock (systolic blood pressure < 90 mmHg). Renal injuries are classified into five grades of severity according to AAST. This surgical-pathologic classification system recognizes the progressive nature of parenchymal and vascular damage associated with increasingly severe mechanisms of trauma.

Purpose:

We aim to evidence the characteristic CT findings in a blunt renal trauma, grade IV (AAST classification)

Material and Method:

Patient male 45 years old after car accident submitted to the Emergency room with gross hematuria and intense pain in left abdominal quadrant irradiated to the back. CT Urography scan with the use of i.v. contrast was performed.

Results:

CT Urography findings include lacerations of left renal parenchyma, retroperitoneal and intraperitoneal hematoma. Delayed scanning during the excretory phase demonstrates a laceration involving the collection system with urinary extravasation but not injuries regarding the renal artery or vein. Findings suggestive of renal injury grade IV.

Conclusion:

CT is the modality of choice in the evaluation of blunt renal injury. Intravenous urography is used primarily for gross assessment of renal function in hemodynamically unstable patients.





PP 068

ACUTE LIMP ISCHEMIA THE ROLE OF DUPLEX ULTRASOUND IN EARLY DIAGNOSIS

A. Tzefferakos¹, I. Vlahou¹, G. Kyprianos¹, D. Stergiou¹, L. Livieratos¹, K. Kokkinis¹

Radiology Department, Kat General Hospital, Athens, Greece

INTRODUCTION

Acute limb ischemia (A.L.I) is characterized by rapidly developing perfusion deficiency - up to two weeks after the initial symptom - with potential necrosis of the involved extremity. The sudden loss of limb perfusion can occur in any peripheral artery of the upper and lower extremities and is considered a vascular emergency associated with significant morbidity and mortality. In the US, the incidence of lower extremity ALI is 16 cases per 100.000 persons per year and about four times lower for the upper extremity. ALI is the result of either thrombotic or embolic phenomena that partially or completely occlude a vessel such that adequate perfusion is no longer achieved. Typically, symptoms of ALI are pain, pallor, paresthesia, paralysis, pulselessness and poikilothermia. Several studies have shown that duplex ultrasonography is a safe alternative diagnostic method to contrast arteriography in chronic ischemia, but its role in the setting of acute ischemia remains open for discussion.

PURPOSE OF THE STUDY

The goal of the study was to review the role, the effectiveness and limitations of Duplex Ultrasound in Acute Limb Ischemia.

METHODS

Relevant studies were reviewed from the following electronic databases: PubMed, Cochrane Library, Medscape and UpToDate. Research papers and reviews from 2001-2018 were included.

RESULTS

The Doppler Ultrasonography (DUS) can be employed in cases of acute ischemia to define the level of arterial occlusion and the patency of the vessels. Additionally, it provides important information regarding the collateral circulation, which determines the available time to conduct a more thorough evaluation of the case. DUS is sensitive for proximal extremity occlusions, but its sensitivity falls off distally and is operator dependant.

CONCLUSION

The initial clinical examination is the crucial stage for early diagnosis and optimal management. It is the crossroad leading to an immediate surgical intervention or to a more conservative approach which requires immediate imaging in order to determine the subsequent therapeutic procedure. Contrast arteriography is the gold standard preoperative imaging modality for limb ischemia. However, DUS can also provide a reliable assessment of the arteries and identify the cause of the arterial occlusion, thereby making it a valuable alternative as the sole preoperative imaging technique.





PP 069

THE EFFICIENCY OF RF ABLATION IN RENAL CANCER < 3 CM

P. Papaspyridakos¹, S. Stouki¹, E. Karras¹, V. Zaharopoulos¹, D. Tzortzis¹, K. Kokkinis¹.

Radiology Department, Kat General Hospital, Athens, Greece

INTRODUCTION

Renal cell carcinoma (RCC) is the most lethal of all urologic cancers and considered a heterogeneous group of neoplasms with varying histological findings. The determination of the size of a renal tumor is important for staging, prognosis and selection of the appropriate surgical treatment. The increased use of modern imaging techniques such as computed tomography (CT) has led to an increase in the incidental discovery of smaller renal masses. It is necessary to define the consistency between pathologic and radiographic sizes. Smaller renal tumours (< 4 cm), should be treated with minimally invasive techniques to preserve renal function and avoid unnecessary surgical removal of the entire kidney. Image-guided percutaneous radiofrequency (RF) ablation is a viable treatment option for the focal destruction of solid tumors because it provides many potential advantages.

PURPOSE OF THE STUDY

The aim of the study is to report the efficacy of radiofrequency ablation on small renal tumours.

METHODS

To identify relevant studies for inclusion, the following electronic databases were searched: MEDLINE; Google Scholar and the Cochrane Library.

RESULTS

In radiofrequency thermal ablation, the size and sinus extension of the tumour can increase the risk of technical failure. In a series of 104 patients and 125 tumours, Zagoria was able to treat all tumours measuring < 3.7 cm completely. The survival rate without recurrence fell to only 47% for tumours over 3.7 cm in size. Gervais, in a series of 85 patients and 100 tumors, identified tumour size <3 cm and a non-central location as independent factors of primary efficacy. Only the non-central site of lesions is an independent factor of secondary efficacy. Gervais emphasized that the choice of a size limit for treatment is not unequivocal.

CONCLUSION

Given the low morbidity of these techniques and the excellent oncological efficacy reported in the management of kidney tumors of < 4 cm, enlarging the indications to a wider population can be envisaged.





PP 070

PERIPHERAL LIMB VASCULAR MALFORMATIONS; CLASSIFICATION AND ULTRASONOGRAPHY APPROACH

S. Stouki¹, I. Vlahou¹, P. Papaspyridakos¹, A. Tzeferakos¹, G. Kyprianos¹, K. Kokkinis¹.
 Radiology Department, Kat General Hospital, Athens, Greece

INTRODUCTION

Peripheral vascular malformations (PVM's) are a heterogeneous group of abnormalities that constitute some of the most difficult diagnostic and therapeutic challenges. They are the result of arrested development of the venous system during various stages of embryogenesis. They can present as incidental finding or produce potentially life- or limb- threatening complications. Correct classification and terminology is paramount for proper clinical management. Ultrasonography is typically the first line imaging study for the evaluation of vascular anomalies.

PURPOSE

To provide the necessary information about the current classification and terminology of vascular anomalies, as well as to address the role of ultrasonography as the basic first imaging examination modality in the diagnosis, therapy and follow up of patients with PVM's.

MATERIALS AND METHODS

The International Society of Vascular Anomalies (ISSVA) broadly categorizes vascular anomalies into vascular tumors and vascular malformations. Vascular malformations are further divided based on their flow properties into slow- flow venous, capillary and lymphatic malformations, high- flow malformations (arteriovenous malformations and arteriovenous fistulas) and congenital mixed syndromes, which can include combinations.

Duplex ultrasonography can be an adequate initial screening modality for non- invasive evaluation of patients with PVM's; B-mode is used to differentiate tumors vs. malformations and colour Doppler mode to assess flow and velocity characteristics.

RESULTS

Developments in classification and imaging techniques have helped to improve management and outcome. Duplex ultrasound is recommended as the first diagnostic test for all patients with PVM's. It is safe, non-invasive, cost effective and reliable to determine flow characteristics. DUS is essential part of real-time evaluation during ultrasound-guided intervention procedures and post therapy monitoring.

CONCLUSION

Peripheral vascular anomalies are rare but an important spectrum of abnormalities. The symptomatology and imaging appearances of these lesions can be complex. Imaging methods are the cornerstone of an adequate diagnosis and the basis of an appropriate management of these conditions.





PP 071

MARKING LUNG NODULE WITH METHYLENE BLUE UNDER CT GUIDANCE

D.Stergiou¹, V. Zaharopoulos¹, E. Karras¹, K. Kalokairinoy¹, A. Petinelli¹, K. Kokkinis¹.

Radiology Department, Kat General Hospital, Athens, Greece

Introduction.

It is fact that the widespread use of multi-section CT has increased the incidental detection of small pulmonary nodules that would not have been identified previously.

A biopsy or an excision may be necessary when imaging tests cannot confirm that a nodule is benign, or a nodule cannot be reached by bronchoscopy or other methods.

CT guided marking is a safe, simple and reproducible technique that helps in VATS dissection of the nodule.

Purpose.

The main purpose of this article is to demonstrate and review the success of our technique in marking lung nodules with methylene blue, under CT guidance and associate it with the results after VATS.

Materials and methods.

In our study were included patients with a peripheral pulmonary nodule smaller than 1 cm, not in contact with the visceral pleura.

Results.

4 nodules were marked with a mean size of 10 mm (8–12 mm) located at a mean depth of 25 mm. An 25G needle with methylene blue solution introduced close to the nodule. Dye was detected at the pleural surface and at the nodule in 100% of the patients. There were no major complications except a small pneumothorax in one case with no need for thoracic tube placement. Thoroscopic resection was possible in 75%. In one case the dye was diffused in the visceral pleura.

Conclusion.

Methylene blue labeling is a simple and safe method of lung nodule marking to facilitate thoroscopic resection in cases where this may not be technically possible due to nodule location.





PP 072

THE CONTRIBUTION OF DSA IN LERICHE SYNDROME

P. Paspaspyridakos¹, S. Stouki¹, I. Vlahou¹, L. Livieratos¹, N. Makris¹, K. Kokkinis¹.

Radiology Department, Kat General Hospital, Athens, Greece

INTRODUCTION

Leriche syndrome is known as aortoiliac occlusive disease, (AIOD) with characteristics of a triad of claudication, impotence and decreased femoral pulses. It's a product of atherosclerosis affecting the distal abdominal aorta, iliac arteries and femoropopliteal vessels. Typical symptoms of Leriche syndrome are intermittent claudication related to arterial insufficiency of the lower extremities, an aggravation of hypertension, erectile dysfunction, and weight loss. AIOD is more prevalent among males and the non-Hispanic black race. A serum lipid profile should be obtained followed by an ankle-brachial index (ABI) performed to evaluate the perfusion of the lower extremities. An ABI < 0.9 indicates the syndrome significant enough to cause claudication. Duplex ultrasonography and CTA are performed to determine the location and degree of stenosis while planning an intervention. Digital subtraction angiography (DSA) has been considered the reference standard technique in the assessment of aortoiliac occlusive disease.

PURPOSE OF THE STUDY

The aim of the study was to report the effectiveness of Digital subtraction angiography on Leriche Syndrome.

METHODS

To identify relevant studies for the purpose of the study, the following electronic databases were searched: PubMed and the Cochrane Library. Research papers and reviews from 2002-2018 were included.

RESULTS

Digital subtraction angiography (DSA) is the main technique for imaging of AIOD. It is relatively invasive, has a low morbidity, requires highly trained personnel and it can be quite difficult to interpret when evaluating on infrarenal aortic occlusion with complex collateral vessels. In cases of distal aortic occlusion, transfemoral catheterization is contraindicated, and the transbranchial approach is then the most commonly used technique

CONCLUSION

DSA allows to diagnose patients with early stages of Leriche syndrome and also evaluates the nature and severity of pathologic lesions within the abdominal aorta and arteries of the lower extremities. DSA has the highest specificity and sensitivity in detecting particular vascular pathologies in patients with Leriche syndrome and is considered the gold standard.





PP 073

INTRALOBAR PULMONARY SEQUESTRATION IN A MALE PATIENT PRESENTED WITH SUDDEN COUGH

İbrahim Altuntaş, Mustafa Koplay

Selcuk University, Medical Faculty, Department of Radiology, Turkey

INTRODUCTION: Pulmonary sequestration (PS) is a rare congenital pulmonary disorder characterized by a mass of dysplastic and nonfunctional tissue that is separate from bronchopulmonary tree and is fed by a branch from the systemic circulation and depending on having an independent pleural structure can be described as intra-lobar (IPS) or extra-lobar pulmonary sequestration (EPS) (1-2).

PURPOSE: Study aims were to show how emergent the presentation of a pulmonary sequestration (PS) patient can be and to describe main differences between intralobar pulmonary sequestration (IPS) and extrapulmonary pulmonary sequestration (EPS).

MATERIALS AND METHODS: This case reports investigated an IPS patient. Literature was scanned from pubmed for the review of main features of PS.

RESULTS: Patient presented to department of chest surgery with complaint of sudden cough. Computed tomography (CT) angiography was performed to exclude pulmonary thromboembolism. CT angiography showed no embolus but abnormal vascular structure branching from descending thoracic aorta extends into the lesion that contains multiloculated cystic and consolidated areas at medial portion of the right lower lobe. Venous drainage was to pulmonary vein. There was no independent pleural structure surrounding the lesion. The patient was diagnosed as IPS.

CONCLUSION: IPS which hasn't independent pleura, seen three times more than EPS. PS almost always locates at lower lobes (%97) and especially at the left lung (%50-75). Feeding artery is mostly single that mainly comes from the thoracic aorta (46.1-86.1%) IPS mostly diagnosed at childhood but nearly half of them diagnosed after the age of 20 (1). EPS is usually linked with other congenital abnormalities so can be recognized on the prenatal ultrasound or magnetic resonance imaging (MRI), while IPS mostly don't cause any symptom, diagnosed incidentally and lately. IPS may also present with pneumonia symptoms (recurrent cough, fever, chest pain) or even with hemoptysis in few studies (1-2).





PP 074

PATIENT-SPECIFIC DOSIMETRY FOR PEDIATRIC PATIENTS UNDERGOING INTERVENTIONAL PROCEDURES

Agapi Ploussi¹, Ellas Spyratou¹, Maria Souli², Ioannis Seimenis³

¹2nd Department of Radiology, Medical Physics Unit, National and Kapodistrian University of Athens, Attikon University Hospital, 12462, Athens, Greece

²Physics Department, School of Applied Mathematical and Physical Sciences, National Technical University of Athens, Zografou Campus, 15780, Athens, Greece

³Medical Physics Laboratory, School of Medicine, Democritus University of Thrace, Alexandroupolis, Greece

Introduction: The increased frequency of pediatric interventional radiology and cardiology procedures, the radiogenic cancer risk and the relatively high radiosensitivity of children warrant patient-specific dosimetry.

Purpose: This study aims at i) performing patient-specific dosimetry in pediatric patients undergoing interventional procedures by combining physical dosimetry for the estimation of absorbed dose and biological dosimetry for the detection of DNA breaks, and ii) probing potential radiation-induced changes in the mechanical properties of peripheral blood lymphocytes.

Materials and methods: A cohort of 20 pediatric patients who underwent interventional cardiology procedures in a biplane angiography system was studied. Clinical indication, somatometric characteristics, acquisition parameters, and Dose Area Product (DAP) values were recorded for all patients. Physical dosimetry was conducted by employing suitable pediatric anthropomorphic phantoms and thermoluminescent dosimeters (TLD). Biodosimetry was based on quantifying the radiation-responsive protein biomarker gamma-H2AX. Morphological and biomechanical properties of cells were studied by using Atomic Force Microscope (AFM). To serve protein expression and cell mechanics measurements, peripheral blood samples were collected pre- and post-procedure. Following lymphocyte isolation, immunofluorescence microscopy and AFM analysis were carried out.

Results: Acquired immunofluorescence results suggest gamma-H2AX foci formation in response to irradiation, which seems to be associated with absorbed dose. Current findings also indicate that x-ray irradiation affects the biomechanical properties of lymphocytes. Specifically, the elastic modulus of lymphocytes seems to constitute a sensitive biomarker for ionizing radiation exposure. No considerable radiogenic changes were found in relation to the lymphocyte shape and morphology.

Conclusions: The combination of physical dosimetry and protein expression based biodosimetry, along with the quantification of radiogenic changes in cell mechanics, could provide a hybrid, comprehensive tool capable of paving the way towards the much-needed personalized dosimetry.

Acknowledgements: This research is co-financed by Greece and the European Union (European Social Fund- ESF) through the Operational Programme "Human Resources Development, Education and Lifelong Learning 2014-2020" under the call for proposals "Supporting researchers with emphasis on new researchers" (EDULLL 34), in the context of the project "Patient-specific dosimetry for pediatric patients undergoing interventional cardiology procedures" (82089-MIS 5006356).





PP 075

CEREBELLO-PONTINE ANGLE EPIDERMOID CYST IN PATIENT WITH TRIGEMINAL NEURALGIA: A RARE CASE REPORT

Stosic Srdjan, Zigic Vedran, Golubovic Jagos

Center for Radiology, Clinical centre of Vojvodina, Novi Sad Serbia

Introduction:

Intracranial epidermoid cysts account for about 1% of intracranial tumors. They result from inclusion of ectodermal elements and usually present in middle age due to their compressive effect on local neural structures.

Case report:

A 40 year old male patient presented with facial pain characteristic of trigeminal neuralgia and mild hearing loss. MRI revealed an expansive cystic mass in the left cerebello-pontine angle, bearing a T2W hyperintense signal similar to CSF and a prominent DWI hypersignal with no signs of signal alteration after paramagnetic contrast administration. The pons was mildly shifted to the right by the tumor, while the cisternal component of the trigeminal nerve as well as the VII/VIII neural complex were compromised. On the basis of typical MRI findings, a diagnosis of an epidermoid cyst was established.

Conclusion:

Epidermoid cysts account for approximately 5-10% of masses in the cerebello-pontine region, while the clinical signs are usually due their gradual mass effect. Their MRI characteristics usually reflect CSF with the exception of increased signal on DWI.

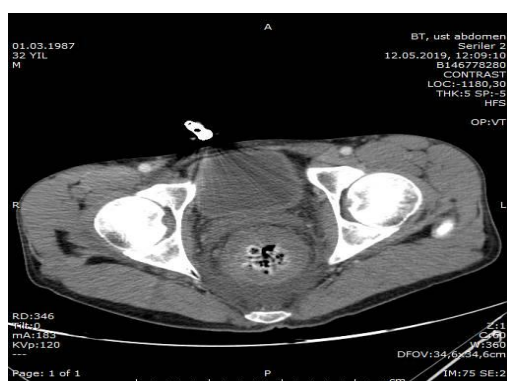PP 076

FOREIGN BODY SWALLOWING AND PROCTITIS

Polat Admis Tugba, Simsek Samet, Sarikaya Ebru, Bilgi Esra, Oncu Mehmet, Karagulle Mehmet, Oncu Suleyman, Kolca Cilem

Bagcilar Egitim Ve Arastirma Hastanesi, Istanbul Turkey

A 32-year-old male patient was admitted to the emergency department after pressing 100 buttons. CT examination revealed bright opacities consistent with foreign bodies in all colon loops. All segments of the rectum showed significant diffuse wall thickness increase and heterogeneous density increase in perirectal fatty tissue supporting proctitis. It was evaluated in favor of proctitis due to ingested foreign bodies.



**PP 077****CT PRESENTATION OF NON RUPTURED GIGANTIC INTRACRANIAL ANEURYSM**

1 Daniela Donat, 2 Dalibor Ilic, 3 Mirela Jukovic, 4 Viktor Till

Klinicki centar Vojvodine

Introduction

This case report present the patient with unspecific neurological disorder and CT diagnostic of unruptured gigantic intracranial aneurysm.

Purpose

Present the case in purpose to not misdiagnose gigantic aneurysm as intracranial tumor lesion

Materials and Methods

Patient has been examined in Emergency centre, on CT Siemens Somatom Definition Flash, native and contrast studies has been done.

Results

65 years old patient comes to the emergency center due to progressive weakness of the right half of the body in the last few weeks and with occasional severe headaches and mental disorder in the past few days. After the initial neurological examination was made CT examination of the head. In the native axial sections on the left side supratentorial is evident large heterodense, partially calcified, lesion, 65mm in maximal diameter, with pronounced perifocal edema. On the postcontrast axial studies with MPR coronal and sagittal sections gigantic partially calcified and thrombosed intracranial aneurysm M1 segment of the left MCA was made with currently no signs of acute bleeding. The patient was admitted to the neurosurgical clinic.

Conclusion

Rare case of gigantic intra aneurysm propouse the importance of postcontrast studies in patients with expansive intracranial lesions even in emergency setting.

PP 078**ROLE OF GADOLINIUM ENHANCED MRI AND DWI IN DIAGNOSIS OF RENAL ABSCESS IN CHILDREN**

Elizabeta Stojovska-Jovanovska¹; Maja Jakimovska-Dimitrovska¹; Milkica Pasoska¹; Mitko Ilievski¹; Ace Dodevski²

1. PHI University clinic of Radiology – Skopje
2. Insitute of Anatomy – Skopje

INTRODUCTION: Renal abscess is a localized collection of infected fluid in kidneys. It develops as a complication of focal pyelonephritis or hematogenous infection, when inflammation may occasionally result in liquefactive necrosis and abscess formation. MRI is increasingly important pediatric imaging modality because of great spatial resolution and sparing patients from potential risks of ionizing radiation exposure, especially children and adolescents

PURPOSE: The purpose of this article is to present a case report of 10 years old child with renal abscess, diagnosed by MRI.





MATERIALS AND METHODS: We present a 10 years old female with symptoms of fever, left flank pain, dysuria, vomiting and fatigue 5 days before examination. Blood tests shows leukocytosis and bacteria and leukocytes were present in urine. CT and US was performed previously, but were inconclusive. MR was used to confirm the diagnosis. 1.5 Siemens Avanto scanner was used with whole body MRI coil exploited. Standard MRI abdominal examination involved T1 and T2 weighted pulse sequences, Fat Sat technique, DWI and SPC 3D sequence and post Gadolinium T1 sequences.

RESULTS: MRI confirmed a renal abscess formation in upper pole of left kidney, especially DWI and postcontrast T1 sequence. DW and corresponding ADC map show that the lesion has restricted diffusion with thin walled post Ga enhancement. Lesion has drained in perirenal space and collecting system.

CONCLUSION: MRI is increasingly important pediatric imaging modality because of great spatial resolution and sparing patients from potential risks of ionizing radiation exposure, especially children and adolescents.

PP 079

PSEUDOMEMBRANOUS COLITIS IN MRI (ACCORDION SIGN) – CASE REPORT

M. Ilievski¹; Elizabeta Stojovska-Jovanovska¹; Maja Jakimovska-Dimitrovska¹; Natasha Hadzi-Nikolova¹; Ivana Panchevska¹;

1. PHI University clinic of Radiology – Skopje

Introduction: Pseudomembranous colitis, also known as Clostridium difficile colitis is an acute infectious disease characterized by the presence of pseudomembranes on colonic mucosa. This membranes are elevated yellowish plaques on colonic mucosa. Most common cause of this colitis is a toxin from C. difficile bacteria, as a result of an unopposed proliferation in patients who underwent a treatment with broad spectrum antibiotics for other disease. It is important for radiologists to know its imaging characteristics, because in many cases they may be the first to suggest the diagnosis. It can be assessed on plain radiography, US, CT, scintigraphy and MRI.

Purpose: The purpose of this case report is to illustrate a classical appearance and “accordion sign” of pseudomembranous colitis in MR Enterography.

Materials and methods: We present a 21 year old male with symptoms of abdominal pain, fever, leukocytosis, diarrhea, anorexia, that started 2 weeks after antibiotic treatment with broad spectrum antibiotics for his primary disease cystic fibrosis. CT and US were performed previously but were inconclusive. MR Enterography was performed to exclude small bowel affection and other unknown conditions. 1,5 T Siemens Avanto scanner was used with whole body MRI coil exploited. Lactulose was given as a positive oral contrast 1 hour prior examination. Spasmolytic agens and i.v. contrast material was applied during examination.

Results: MRI confirmed a thickened colonic wall and oral contrast trapped between markedly thickened haustral folds, classical, highly suggestive “accordion sign”, pericolic stranding, involving almost entire colon.

Conclusion: Because imaging is being used increasingly in the evaluation of patients with abdominal pain, it is important to recognize the imaging features of PMC that may suggest the diagnosis.





PP 080

CORONARY ARTERY DISSECTION AS PART OF ACUTE CORONARY SYNDROME: NONINVASIVE DIAGNOSIS WITH MULTIDETECTOR CT ANGIOGRAPHY- CASE REPORT

Hadji Nikolova Natasha¹, Ilievski Mitko¹, Panchevska Ivana¹, Lazareska Menka¹, Jakimovska Dimitrovska Maja¹

1.UC of Radiology Skopje

Introduction:

Coronary Artery Dissection (CAD) is a rare disease that may lead to acute coronary syndrome, or acute ischemic coronary events. We evaluated two events that could lead to coronary artery dissection and that are iatrogenic catheter induced coronary artery dissections and the other events are as part of intimal flap extension in Stanford A Aortic Dissections.

Materials and Methods

In our institution, we reported two cases evaluated under CT coronary angiogram with Acute Coronary Syndrome, shortly after previous endovascular interventions of coronary angioplasty and stent placement. In the first case, aortic dissection was shown from Sinus Valsalva to descending part of aortic arch and the dissection involved the root of the right coronary artery (RCA) in which there were several stent placement after myocardial infarction. The second case was also evaluated under CT coronary angiogram after coronary stent placement, at the proximal part of RCA in which was shown dissection at the ostium of the artery and also thrombosed dissection of ascending aorta. As part of the Stanford A Aortic Dissection we reported three cases that involved the coronary artery ostia and their segments in which two cases have shown involvement of left main coronary artery and also left anterior descending artery and the third case involvement of right coronary artery.

Purpose

Of great importance for us was the recognition and the ability of fast diagnostic evaluation that could be evaluated by the help of CT coronary angiography as a diagnostic value for Coronary Artery Dissection.

Results

The two cases after endovascular interventions were conservative treated with resolution changes of the blood pool flow. The first two cases of the Stanford A Aortic Dissection were surgically treated.

Conclusion

With the help of the diagnostic modality and that is ECG gated CT coronary angiography we are capable of fast and noninvasive diagnostic evaluation of the coronary arteries as part of Acute Coronary Syndrome





PP 081

CEREBRAL AIR EMBOLISM

Uludag Mustafa Enes Mısır ,Aydan Arslan , Ali Uludag
 Acibadem Mehmet Ali Aydinlar University, Istanbul Turkey

PURPOSE / INTRODUCTION

Cerebral air embolism is a rare condition that can cause fatal consequences. It may be of arterial and venous origin. When the literature research was done ; iatrogenic, secondary to surgical and biopsy procedures, catheter insertion and removal, endoscopy, hysteroscopy and defibrillator were seen as etiological factors. Complications include stroke and cerebral edema. Treatment is supportive. Hyperbaric O2 treatment option has been published by researchers.

CASE

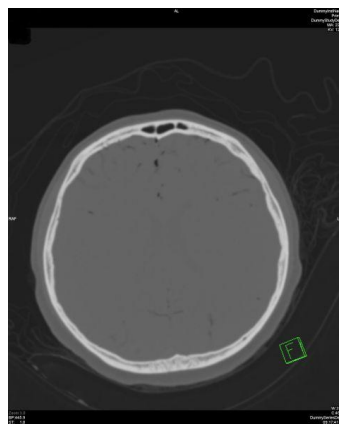
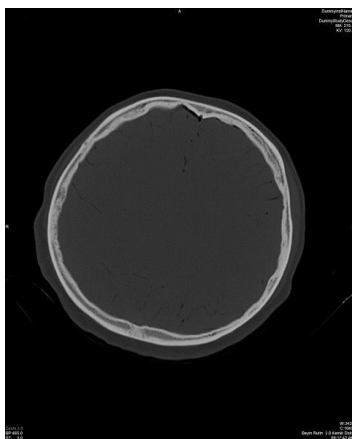
A 31-year-old male patient was diagnosed with end-stage renal disease secondary to membranous glomerulonephritis and he underwent renal transplantation from live donor three days ago. The significant early post-op complications did not observed in first three days. On the other hand, sudden fainting and followed respiratory arrest were observed as a result of the patient's removal of her own central venous catheter. CPR was applied. Unfortunately, there was no response to resuscitation and the patient died.

FINDINGS

In post-mortem non-contrast CT examination; free air images were observed in cerebral and cerebellar hemisphere's sulcal areas, arterial and venous structure traces. Millimeter-sized air images were seen in the right ICA cavernous segment, at the level of the transverse and superior sagittal sinuses. Significant herniation, hemorrhage or mass were not detected

RESULTS

Cerebral air embolism is a sudden general condition deterioration that effects arterial and venous system. It causes fatal results. CT examination is helpful in the diagnosis





PP 082

ATRESIA OF THE RIGHT PULMONARY ARTERY AND ONE OF THE RIGHT PULMONARY VEINS IN YOUNG ADULT - CASE REPORT

Pathena Ioannidi², Dimitrios Tomais¹, Angeliki Kalpaxi², Christina Sierrou¹, Panagiotis Petaloudis¹, Vasilis Panou*, Anna Skoula¹, F. Rontogianni¹, Dimitrios Chondros¹

¹CT/MRI Department of Evaggelismos Hospital

²Radiology Department of Thrasio Hospital

*Medical student of National and Kapodistrian University of Athens

Introduction

Absence of one pulmonary artery combined with partial obliteration of one of pulmonary veins is rare condition which concerns on the one hand developmental failure of 6th brachial arc during the period of 6th -16th week of gestation and on the other hand failed connection of the common pulmonary vein to the left atrium.

Purpose

Presentation of interesting computed tomography and scintigraphy findings.

Materials and Method

A 21-year-old man was presented at the ER department with 2 episodes of haemoptysis in the last 24h. From the history it is known, that at the age of 5 months surgical resection of right lung cyst had been made and since the age of 3-4 years there were sporadic episodes of haemoptysis, without further diagnostic examination. Patient denied smoking, drug or alcohol abuse. Patients' vitals were within normal limits. No cough, chest pain or dyspnoea mentioned. Decreased breathing sounds were observed during auscultation on the right. Taking in concern the age of the patient and the symptoms, CT angiography, heart ultrasound and lung perfusion scintigraphy were performed.

Results

CTA revealed multiple vascular anomalies: absence of right pulmonary artery and one of right pulmonary veins. Tortuous bronchial, intercostals and inferior phrenic arteries composed rich collateral net connected to descending thoracic aorta. Additionally findings: hyperventilated left lung, reduced volume of right lung with mediastinal shifting to the right. Alveolar opacities were found at the middle lobe and bronchiectasis at the upper right lobe.

Heart ultrasound: without congenital abnormalities.

Perfusion scanning highlighted no participation of right lung in gas exchange, which confirmed CT findings.

Conclusion

20% of young patients with haemoptysis may present vascular abnormalities; one of the most significant is atresia of the pulmonary artery. There is no general agreement about the therapeutic methods. Asymptomatic population must be followed up to prevent pulmonary hypertension. Medical and/or surgical treatment preferred to be adjusted.





PP 084

GASTRIC DIVERTICULUM INCIDENTAL FINDING - CASE REPORT

Pathena Ioannidi, Angeliki Kalpaxi, Theodoros Vagdatlis, Maria Flokatoula, Dimitrios Papaioannou, Marianna Kalokairinou, Eustathia Kapnisi, Evangelia Triantafyllou, Vasilis Panou¹, Angeliki Papaevangelou

Radiology Department of Thriasio Hospital

¹Medical student of National and Kapodistrian University of Athens

Introduction

Gastric diverticula are uncommon incidental findings, discovered while searching for other pathology in the endoperitoneal space or routine diagnostic testing. They usually found at posterior wall of fundus, near gastroesophagel junction in the range of 2-3 cm from the minor curve and they are usually congenital (true diverticula). Acquired (pseudodiverticula) are typically located close to the atrium and can be traction or pulsion diverticula, caused by inflammatory process of the stomach or the perigastric region, malignancies and surgical procedures, such as gastric by-pass Roux-en-Y.

Purpose

Case report presentation of computed tomography findings.

Materials and Method

A 68-year-old man was presented at the ER department with acute abdominal pain, diarrhea and 3 episodes of vomiting. Patient's vitals were almost normal except body temperature 38°C. Blood tests showed small elevation of WBC and CRP. Ultrasound, x-ray and CT of the abdominal area were performed.

Results

Ultrasound and X-ray of abdomen showed chololithiasis, without wall thickness and no significant pathological findings from the parenchimal organs. Abdomen CT revealed multiple diverticuli of the sigmoid without any sign of inflammation and solid large gastric diverticulum at the dorsal wall of the fundus.

Conclusion

Gastric diverticula are rare condition, which can cause very serious complications: ulceration, upper gastrointestinal bleeding, perforation, malignancy and bleeding. Some of these situations can be life-threatening and clinicians have to keep it in mind, when symptoms such as epigastric pain, discomfort, nausea, dyspepsia and halitosis are presented. Therapeutic management mostly depends from the severity of clinical condition and the presence of complication; it can be medical or surgical.

Asymptomatic patients may be treated with PPI and sometimes it is alleviating, although many authors support that it has only temporary effect. When the symptoms persist or there are severe complications, open surgical or laparoscopic management combined with intraoperative endoscopy are preferred with good results.





PP 086

POSTTRAUMATIC INTERNAL CAROTID ARTERY PSEUDOANEURYSM DUE TO CHRONIC INTIMAL TRANSECTION

Kokovic Tijana

Centar za radiologiju, Klinicki centar Vojvodine, Novi Sad, Srbija

1. Introduction:

Posttraumatic internal carotid artery aneurysm dilatation due to intimal transection is extremely rare entity. These usually present with either “hard signs” of vascular injury or by identification of a pseudoaneurysm on imaging.

2. Purpose: The purpose of this paper is to define this rare entity and diagnostic algorithm and findings.

3. Materials and Methods: We present a case of delayed presentation of carotid pseudoaneurysm due to transection of arterial intima. The patient is a 30-year-old previously healthy female brought to cardiologist due to intermittent tachycardia. DUS was performed, and internal carotid artery aneurysm was found. There was no acute neck trauma. Patient had severe neck trauma due to bicycle accident in childhood. Further CT angiography and MRI/MRA was performed.

4. Results: DUS findings showed turbulent blood flow in dilated internal carotid artery, with blood vessel thinning and intimal transection, and no locoregional haematoma. CT angiography showed fusiform internal carotid artery aneurysmatic dilatation, without contrast extravasation and without locoregional haematoma. MRI/MRA was performed with additional T1W fat/sat MRI sequence, in order to evaluate presence of intimal haematoma – crescent sign seen in acute arterial wall dissection. All imaging findings were in favor of chronic arterial wall aneurysmatic dilatation, with intimal transection, without signs of acute trauma.

5. Conclusion: Pseudoaneurysm formation, due to intimal transection is rare entity, and requires multiple imaging findings in order to evaluate if the trauma of vessel is acute or chronic. In case of chronic pseudoaneurysm findings, surgical intervention is not required in most cases. Conservative medical treatment and diagnostic follow-up is required.





PP 087

TRANSIENT HEPATIC ENHANCEMENT DIFFERENCES - CHALLENGING THE RADIOLOGIST

Panayotova Polina, Dineva Svetla

MD / University Hospital "Alexandrovska" / Sofia / Bulgaria

Introduction

The liver has a unique dual blood supply. Approximately 70% of its vascular inflow is comprised by the portal vein and the remaining 30% via the systemic circulation through hepatic artery.

It is essential for the radiologist to understand the physics of portal venous blood flow, causes for its alterations and consequent pressure changes because "every alteration must have a cause" and can lead to variable and often confusing radiological picture.

Purpose

Our purpose is to illustrate perfusion disorders of the liver such as transient difference in hepatic enhancement. It could be challenging to avoid misinterpretation and to accurately evaluate the hepatic parenchymal and vascular image.

Materials and Methods

Cross-sectional imaging like multiphase CT is the most frequently used imaging modality for assessment of the portal venous system. The radiological report must include anatomy, pathological changes and functional information consistent with subtle imaging features.

Transient Hepatic Attenuation Difference (THAD) is a change of the hepatic perfusion which can be seen through contrast enhanced CT.

THAD is often referred to portal venous occlusion. The decreased venous inflow lowers the arterial resistance pressure leading to increased hepatic arterial inflow. Its symptoms are best seen during arterial phase imaging - the affected area has a marked hyperenhancement compared to the adjacent intact parenchyma. These changes are usually segmental or marginal. During the portal venous phase they turn into isoattenuating zones.

Results

This perfusion abnormality is associated with a variety of intra- or extrahepatic pathological conditions that may involve the liver vasculature. These include portal hypertension, thrombosis (tumorous or bland), compression, anomalous blood supply, inflammation of the biliary tree or adjacent abdominal structures.

Conclusion

Hepatic arterial phenomena are visualized often in daily practice obviating the need for correct radiological report (and should be known). They could be signs of liver disease or underlying condition affecting the normal hepatic function.





PP 088

MR ENTEROGRAPHY IN ASSESSING CROHN'S DISEASE ACTIVITY. CORRELATION WITH ENDOSCOPIC FINDINGS

Ntoumpara Maria, Sotiriadou Amalia, Fotoulaki Maria, Morichovitou Anthi
 Radiology Department of "Papageorgiou" General Hospital, Thessaloniki, Greece

Introduction

Crohn's disease (CD) affects a large number of paediatric population. Active form should be differentiated from inactive stenotic or infiltrative form due to their different therapeutic options.

Purpose

The aim of the study was to detect active CD using MR Enterography (MRE) findings. To compare it with endoscopic and histopathological findings. To present MRE usefulness in guiding treatment management.

Material and methods

We present a retrospective analysis of MRE findings in 56 patients aged 1-18 yo, referred to us from the department of Paediatric Gastroenterology of our Hospital. In the study were included 32 patients with clinically suspected CD, 9 patients with low possibility of CD and 15 patients with known CD but suspected relapse of the disease. Patients with known stenotic or infiltrative disease without suspicion of activity were excluded. The examination was performed on Philips Insignia 3T system, with standardized MRE protocol. The reference standard was endoscopic and histopathologic findings.

Results

In the group of validation with suspected CD: 17 of 32 patients were correctly diagnosed with active disease; in 7 patients was correctly excluded active CD; 4 patients were misdiagnosed with probable Crohn while endoscopy and histopathology revealed ileitis from other causes; in 3 patients MRE results of active disease were not comparable due to interrupted endoscopy for technical reasons. Between MRE and endoscopic findings it was found 1. An absolute correlation in excluding CD in all patients with low possibility of CD. 2. A perfect coincidence in detection or exclusion of relapse in patients with known CD.

Conclusion

MRE is an excellent tool in detecting activity in CD and guiding treatment options. Advantages of MRE such as good tolerability, non-invasiveness and lack of radiation increase method's diagnostic value in everyday disease's management in paediatric patients.





PP 090

A CASE OF UPPER THORACIC ARTERIOVENOUS MALFORMATION PRESENTING WITH SPONTANEOUS SUBARACHNOID HEMORRHAGE AND ITS ENDOVASCULAR TREATMENT

Densel Araç, Mehmet Kenan, Mahmut Sertdemir, Fatih Keskin, Mehmet Fatih Erdi, Osman Koç
Necmettin Erbakan University Meram Medical Faculty Department of Neurosurgery 2019, Konya, Turkey

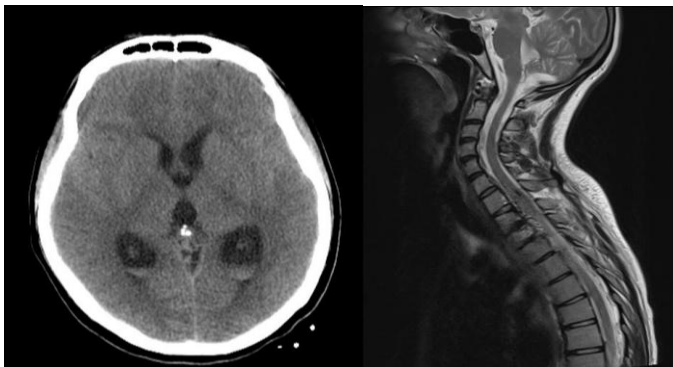
Introduction

Spinal dural arteriovenous fistula (SDAVF) is an abnormal connection between a radiculomeningeal artery and a radiculomedullary vein (RMV) characteristically draining into the perimedullary venous system. Clinical symptoms are non-specific including loss of sensory or motor function, gait difficulties, radicular pain or disturbances of sphincter control and this often results in delayed diagnosis. Due to nonspecific symptoms, the neuroradiologist is often the first clinician to make the initial diagnosis based on MR imaging, with differential diagnoses causing confusion. In addition, spinal angiography is the gold standard and should be taken into consideration where SDAVF is highly suspected

Materials and Methods

A 21-year-old female patient presented to our clinic with a 1-month history of head and neck pain and numbness in both arms. Neurological examination of the patient showed left sixth nerve paralysis, left hofmann +, babinski + / + and bilateral deep tendon reflexes were increased, and did not describe urinary and stool incontinence.

Brain computerized tomography (CT) of the patient showed subarachnoid hemorrhage, cervical and thoracic MRI of the patient revealed C7-T4 vascular structures extending into the vertebral bone structures and spinal canal posteriorly, also into the spinal cord at the level of C7-T1.



Brain CT showed spontan subaraknoid hemorrhage in ventricles
Spinal MR showed thoracal 1-2 dural AVM

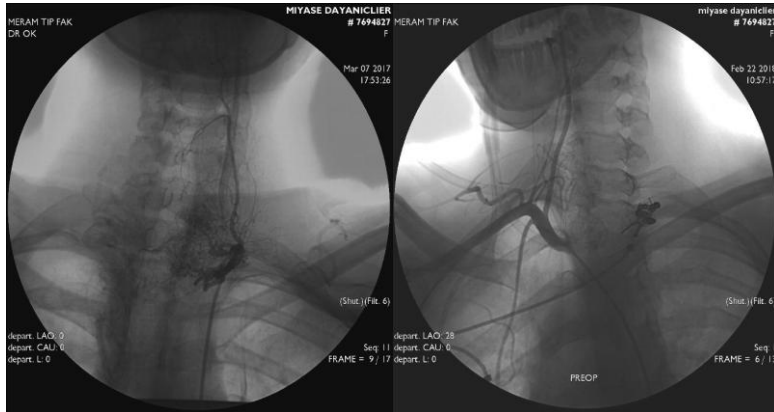
The patient underwent angiography for further examination. SDAVF and aneurysm, also cranial aneurysm were detected. As a treatment, cranial aneurysm was embolized and 70% glu injection was applied to the fistulose nourishing vein of SDAVF. Three weeks later ventriculo-peritoneal shunt was applied to the patient because of hidrocephaly.

Result

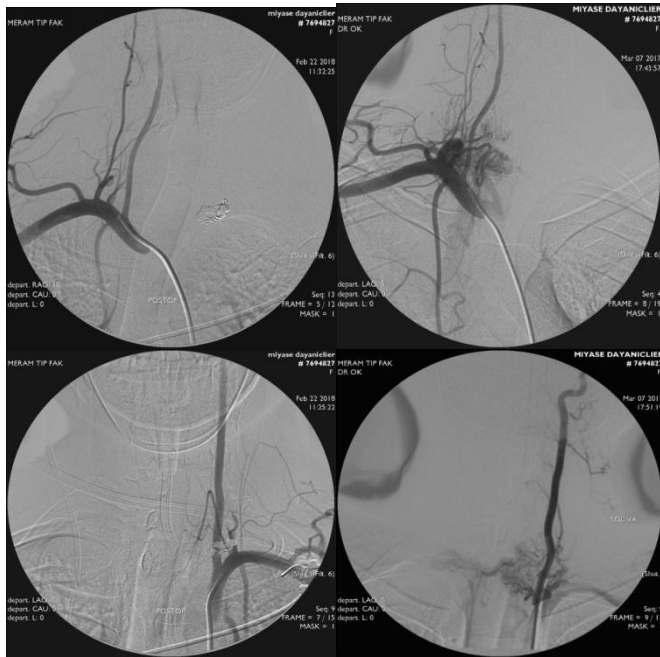




Surgical excision-ligation and selective endovascular embolization are two effective methods of treatment. Surgical treatment has a high morbidity and nowadays endovascular treatment is the first choice because it is less invasive.



Spinal avm is showed in digital substaractional angiographi in first image and threated with onix embolization in second image



**PP 091****THORACAL MENENGIOMA WITH AORTIC COARCTATION: A CASE REPORT**

Densel Araç, Mehmet Kenan, Lokman Ayhan, Fatih Keskin, Mehmet Fatih Erdi, Yalçın Kocaoğullar, Osman Koç
Necmettin Erbakan University Meram Medical Faculty Department of Neurosurgery 2019, Konya, Turkey

Introduction:

Spinal tumors are less common than brain tumors and constitute approximately 10-25% of central nervous system tumors. They account for 40% of spinal tumors and approximately 70% are caused by meningioma and schwannoma; It is stated that 90% of them are benign and can be removed completely and 0-10% worsening of neurological status is seen.

Most cases of aortic coarctation occur sporadically and extracardiac vascular anomalies can be seen frequently with coarctation. Variations in truncus brachiocephalicus anatomy, collateral artery circulation and Berry aneurysm of Willis polygon are some of the most common major vessel anomalies.

Purpose :

In this study, we present a case with multiple collaterals in the thoracic paravertebral area with aortic coarctation and thoracal meningioma at the same level.

Material and Methods:

A 65-year-old female patient was admitted to our outpatient clinic with the complaint of low back pain, left hip pain, numbness and in both legs, and walking difficulties. Neurological examination of the patient was paraparesis, increased deep tendon reflex in the lower extremities, bilateral babinski positivity and hypoesthesia below T4 level.

A mass compatible with intradural extramedullary meningioma at T4-5 level on contrast-enhanced thoracic magnetic resonance imaging (MRI). In addition, vascular collaterals were detected in the paravertebral area from anteriorly and posteriorly secondary to aortic coarctation at this level.

Anjiography of the patient revealed coarctation of aorta.

Tumor excision was performed with thoracic laminoplasty. During subcutaneous and paravertebral surgical incision, collateral vascular structures were closed with clips. The patient was discharged on the 5th postoperative day with corrected neurological deficit.

Result:

Coexistence of spinal tumor and aortic coarctation is one of the rare cases. Preoperative radiological examinations are extremely important in order to minimize complications during the operation.



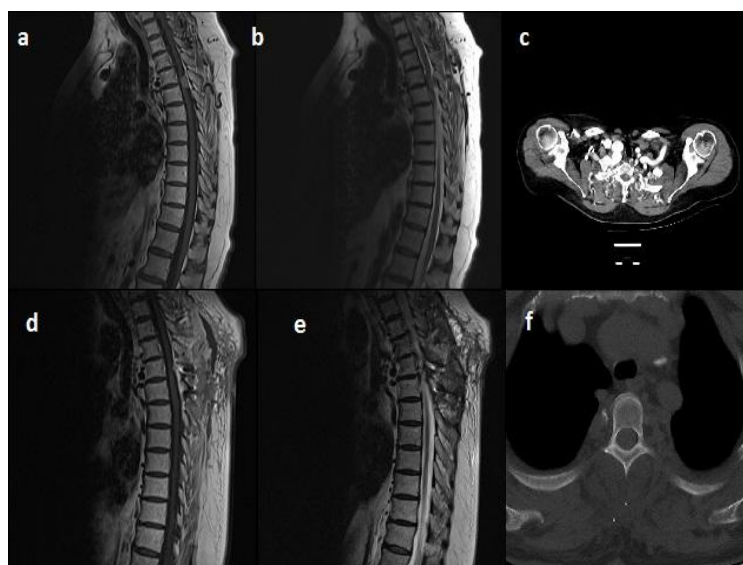


Figure 1: pre-op toracal MRI showed vasculer colleterals and intradural-extrameduller menengioma (a,b) and toracal CT showed aort coarctation (c). Pos-op torakal MRI showed laminoplasty and excision of mass lesion (d,e) and post-op toracal CT showed clipped colleteral vessels (f).

PP 092

POTENTIAL HARMFUL EFFECTS OF IONIZING RADIATION IN PEDIATRIC POPULATION

Ljiljana Drazetin, Ivana Stojic, Vedran Zigic

Clinical Center of Vojvodina, Center for Radiology, Novi Sad, Serbia

Introduction: Radiobiology is a science discipline about ionizing radiation mechanisms and effects on human cells. Radiological examinations are the most important source of artificial radiation, created by humans.

Purpose: The aim of our study was to point out potential health problems in pediatric population, who were exposed to X-rays during medical examinations.

Material and methods: Child organism continually grows, its tissues are immature and it is more vulnerable on X-rays. Children have plenty of time for developing more cell destroys, because their lifetime is longer than the adults.

Results: The radiation effects are cumulative and cell destroys are irreversible. The most sensitive organs in children are brain and bone marrow, while liver and breast are relatively radiosensitive. The longlasting unwished effects are leukemia and anaemia, many types of cancers, skin diseases, fertility problems and cataract.

Conclusion: Radiologists and pediatricians should be educated about risks and how to prevent unwanted effects on children. ALARA concept- As Low As Reasonably Achievable- is devoted to X-ray dose reduction and their risks in pediatric group of patients. "Image gently" campaign has a purpose to promote protection against radiation.





PP 093

INVESTIGATION OF SMALL BOWEL COMPLICATIONS IN PATIENTS WITH MULTIPLE POLYPOSIS SYNDROMES WITH MAGNETIC RESONANCE ENTEROGRAPHY (MRE). A CASE SERIES OF SIX PATIENTS.

Melpomeni Kosmidou, Maria Lelegianni, Athanasios Rigkas, Filippos Sarafis, Anthi Morichovitou
 Radiology Department of "Papageorgiou" General Hospital, Thessaloniki, Greece

Introduction

Patients with multiple polyposis syndromes may often experience complications regarding the small intestine, such as obstruction or pseudo-obstruction. Evaluation of these entities is extremely difficult with invasive methods such as capsule endoscopy. Moreover, other imaging modalities, like contrast enhanced computed tomography had shown limited capacity in accurate manifestation of these conditions.

Purpose

To describe and analyse the complications caused by multiple polyposis syndromes in patients with clinical signs of obstruction, with Magnetic Resonance Enterography (MRE).

Materials and Methods

The MRE database of our department (3.0T MR, Philips Ingenia) in a two-year time period was retrospectively reviewed. Four patients with familial adenomatous polyposis (FAP) and two patients with Peutz-Jeghers syndrome with clinical indications of incomplete obstruction were referred to our department for investigation.

Results

Three cases with pseudo-intussusception were present, two of them located in the jejunum and one of them in the ileum. In addition, enlarged lymph nodes, edema of bowel wall and stenosis of certain bowel segments in two of the cases were present. Furthermore, there was one particular case presented with ulceration in anastomosis from previous surgery.

Conclusion

MRE is a non invasive imaging modality which can detect and locate the suspected complications of small intestine in patients with multiple polyposis syndromes and describe in detail their characteristics. Additionally, various co-existing extra-colonic manifestations can be identified. This important information could be crucial for therapeutic decisions and patient management and consequently, we should consider MRE as a valuable diagnostic tool in these cases.





PP 094

THE SIGNIFICANCE OF MRI IN DETECTION OF BRAIN SARCOIDOSIS – CASE REPORT

Dimitar Veljanovski, Masha Jovcevska, Sandra Dejanova Panev, Miranda Ramani Izairi, Ivona Jovanoska, Gjorgji Dungevski
 City General Hospital 8-th September, Radiology Unit, Skopje, N. Macedonia

Introduction: Sarcoidosis is a multi systematic idiopathic granulomatosis disease. In most of the cases it affects the lungs, primarily as bilateral lymphadenopathy, but also it may affect other organs such as lymph nodes, eyes, skin, heart, muscles, liver and brain. Neurosarcoidosis occurs in the range between 5-15 % of the patients with sarcoidosis, and brain neurosarcoidosis occurs in app. 5%.

Purpose: The purpose of the case study was to present the importance of MRI in detection of neurosarcoidosis.

Material & Methods: In this case study a female patient, 37 years old was presented. The symptoms of the patient were sudden loss of vision in both eyes and occasional occurrence of dizziness and languor. MRI examination was used to present parenchymal, leptomeningeal and cranial nerve involvement. The disease began with skin changes in left cheek, arms and both hands. Definitive diagnosis was made by biopsy.

Results: Using MRI modality several typical changes of neurosarcoidosis were found such as leptomeningeal involvement, intraparenchymal mass lesion and cranial nerve involvement. The intraparenchymal mass lesions, which are highly associated with leptomeningeal involvement, are shown with post-contrast enhancement.

Conclusion: MRI is a high sensitive diagnostic tool and follow up procedure in patients with neurosarcoidosis, including brain inflammation, however sometimes there is a lack of specificity, which makes the neurosarcoidosis a clinical challenge.





PP 095

DIFFUSION RESTRICTION MAINLY IN POSTERIOR LIMB AND GENU OF INTERNAL CAPSULE IN A CASE WITH HYPERNATREMIC DEHYDRATION

Bülent Aslan^{1a}, Burak Ütük^{1b}, Gazanfer Ekinci^{1a}

1a. Department of Radiology, Marmara University Pendik Training and Research Hospital, Turkey / Istanbul

1b. Department of Pediatrics, Marmara University Pendik Training and Research Hospital, Turkey / Istanbul

We report peculiar neuroimaging findings of hypernatremic dehydration in an 15-month-old boy. Hypernatremic dehydration classically causes subdural, subarachnoid or intraparenchymal hemorrhage and cerebral venous sinus thrombosis in brain. Diffusion restriction in mainly posterior limb and genu of internal capsule has been rarely reported in literature.

Introduction:

Hypernatremia is a condition that serum sodium concentration is above 150 mEq / L. This is relatively more common in infants, young children and the elderly. When serum sodium rises above 160 mEq / L, clinical results are more severe. The most common intracranial complications of hypernatremic dehydration are brain edema; intraventricular, subarachnoid and subdural hemorrhages; multifocal intraparenchymal bleeding; hemorrhagic infarction and sinus thrombosis. (4) In imaging, restriction in diffusion weighted imaging in mainly posterior limb and genu of internal capsule without hemorrhage and sinus thrombosis has been rarely identified (1)

Case Report:

A 15-month-old boy was admitted to our pediatric emergency department with diarrhea and vomiting for two days. The patient was born with breech presentation and was followed up fourteen days for respiratory distress in neonatal intensive care unit. When the patient's neuromotor development was questioned, it was learned that he could not keep his head upright, could not sit without support and was fed with nasogastric catheter.

On physical examination, his pulse was pale, his lips and tongue were dry, his under eyes were collapsed, his skin was dry, and his skin turgor was decreased, and the findings suggested severe dehydration. In the patient's neurological examination, he responded to the painful stimulus by pulling his extremities and had an intermediate-severe level of encephalopathic appearance. There was widespread spasticity on the extremities. Laboratory values were serum sodium 168 mmol / L, potassium 2.7 mmol / L, chlorine 132 mmol / L, urea 133 mg / dl, creatinine 0.87 mg / dl. Blood gas analysis revealed pH: 7.24, HCO₃⁻: 12.8 mmol / L, and the patient was on metabolic acidosis with increased anion gap.

Due to encephalopathic appearance and other neurological findings, diffusion MRI and cranial CT were requested in emergency conditions.

In diffusion weighted MR imaging; there was restriction in corona radiata level, bilateral internal capsule posterior limbs and genu, splenium of corpus callosum and bilateral lentiform nucleus. (Figure 1a) Cranial CT examination showed hypodense appearance at these levels. There was no evidence of bleeding and sinus thrombosis on CT. (Figure 1b) When the findings were evaluated





together with clinical and laboratory data, they were interpreted in favor of extra pontine myelinolysis due to hypernatremic dehydration. Other changes in CT and MRI (cerebral and cerebellar atrophy, etc.) were considered as sequelae of hypoxia in the newborn period.

The patient's clinical situation improved with IV and oral hydration and supportive therapy, and serum sodium was normalized. Because patient's encephalopathic appearance decreased after seven days of hospitalization and diarrhea/vomiting complaints completely regressed, the patient was discharged from hospital.

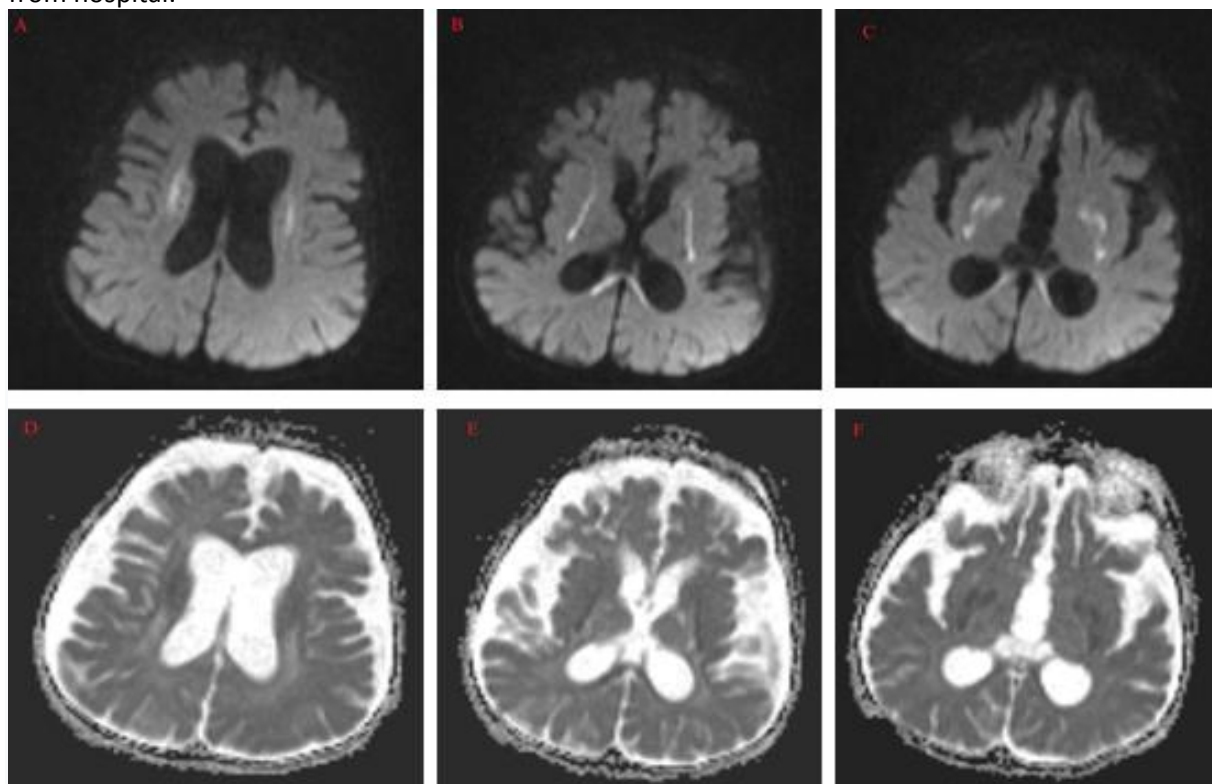


Figure 1A: (A-F) Axial diffusion-weighted images (A-C) on the 2nd day of disease, corresponding to ADC maps (D-F), respectively. Images show restriction at corona radiata level, bilateral internal capsule posterior limbs and genu, splenium of corpus callosum and bilateral lentiform nuclei.

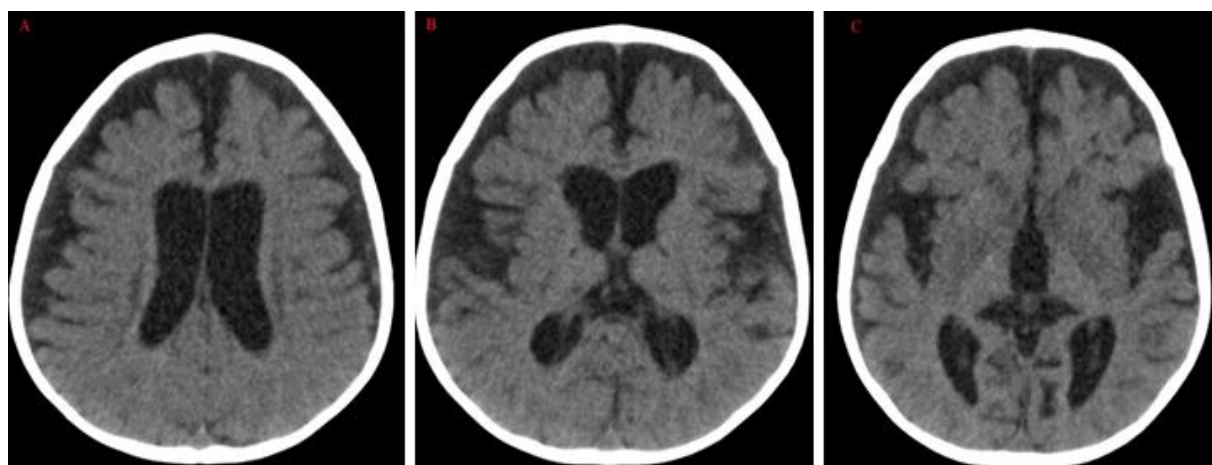




Figure 1B: (A-C) Axial IV non-contrast cranial CT images on day 2 of the disease. Images show hypodense appearance at corona radiata level, bilateral internal capsule posterior limbs and genu, splenium of corpus callosum and bilateral lentiform nuclei. No signs of bleeding or sinus thrombosis are observed.

Discussion:

In hypernatremic dehydration classically, subdural, subarachnoid or intraparenchymal hemorrhages and cerebral venous sinus thrombosis are seen. These are associated with intracellular water-loss and severe contraction of neuronal and glial cells. (1,2) Smaller hemorrhages on the brain surface or in the parenchyma occur due to direct endothelial damage, whereas large subdural hemorrhages occur when the bridging veins over the brain in subdural space torn. Severe hypernatremia increases blood osmolality and causes water to pass from the brain into the bloodstream. Neurons form intracellular osmolites as a mechanism against this osmotic attack. These are the structures known as "idiogenic osmoles" that create hyperosmolarity within the cells and provide water retention within the cells. The very slow dispersion of these idiogenic osmoles leads to persistent water retention, swelling of neuronal and glial cells, and consequently brain edema. (3) These osmotic changes cause edema in myelin and myelinated fibers to split into myelin lamellae, leading to restriction in brain structures such as internal capsule and corpus callosum in diffusion-weighted magnetic resonance imaging. (1,3) In contrast, diffusion restriction in myelin-free fibers in the brain was thought to be due to glial and axonal swelling. (1,3) Our patient had peculiar neuroimaging findings due to hypernatremic dehydration because diffusion restriction in the posterior limb and genu of the internal capsule has been rarely reported. (1)

Result:

Myelin edema and damage due to hypernatremic dehydration and radiological findings due to these are less known conditions. Although it is well known that hypernatremic dehydration classically causes subdural, subarachnoid or intraparenchymal hemorrhage and cerebral venous sinus thrombosis, it should be known that although rarely, it may lead to extrapontine myelinolysis imaging findings.

References:

- (1) Patil S, Bhagwat C, Saini AG, et al. BMJ Case Rep. doi: 10.1136/bcr-2018-225101
- (2) Finberg L, Lutrell C, Redd H. Pathogenesis of lesions in the nervous system in hypernatremic states. II. Experimental studies of gross anatomic changes and alterations of chemical composition of the tissues Pediatrics 1959;23:46-53.
- (3) Righini A, Ramenghi L, Zirpoli S, et al. Brain apparent diffusion coefficient decrease during correction of severe hypernatremic dehydration. AJNR Am J Neuroradiol 2005;26:1690-4.
- (4) Musapasaoglu H, Agildere Muhtesem A, Teksam M, Tarcan A, Gurakan B et al. The British Journal of Radiology, 81 (2008), e57-e60. doi: 10.1259/bjr/28766369





PP 096

THE SIGNIFICANCE OF MRI IN DETECTION OF UTERINE ANOMALIES - A CASE REPORT

Masha Kostova, Slavica Chalchevska, Filip Risteski, Aleksandar Gjorevski, Miranda Ramani, Sandra Dejanova Panev, Violeta Tolevska
 City General Hospital 8th September, Radiology Unit, Skopje, N. Macedonia

Introduction: Infertility is a common problem for 8-12% of the couples and both gender are equally affected. The most common reasons for infertility in women are uterine anomalies, complications after pelvic surgery, submucosal fibroids, endometriosis and previous sterilization treatment. The risk factors may be older age, smoking, alcohol intake, obesity, malnutrition, STDs, mental stress, etc. Good radiology approach in uterine anomaly and other medical condition in female reproductive organ is important for accurate diagnosis and appropriate treatment.

Purpose: The purpose of the study was to present the importance of MRI modality in uterine anomalies.

Materials and methods: Retrospective review of the medical records of two female patients with uterine anomalies. Both patients presented with dyspareunia and were examined with the same diagnostic method, MRI Siemens magnetom essence, 1.5 Tesla. Standard protocol of pelvis was performed.

Results: The first patient was presented with bicornate uterus. Uterus and cervix were divided by fibrous septum which continues in proximal third of vagina with significant lumen reduction. In the left ovary was detected multilocular cystic formation field with serous liquid, without visible proliferative masses. Ascites was found in Douglas space. The second patient was presented with incomplete bicornate uterus with two vagina with separate layers.

Conclusion: MRI modality is of a high importance for uterine anomalies detection which is a superior method due to the advantages: less invasive, appropriate for female reproductive system detection and surrounding tissue.

PP 097

CHIARI MALFORMATION TYPE II

Dzidrova Elizabeta ,Dzidrova Blagica,Trajkova Vesna
 PHI Clinical Hospital Stip, Bulgaria

Introduction

Chiari malformations are structural defects in the base of the skull and cerebellum, the part of the brain that controls balance. This causes pressure on the cerebellum and brain stem that may affect functions controlled by these areas and block the flow of cerebrospinal fluid. Most of the hindbrain findings in Chiari II malformation derive from a diminutive posterior fossa, with brain structures squeezed superiorly, inferiorly, and anteriorly. The fourth ventricle is squeezed into a small vertical slit. Syringomyelia is a disorder in which a CSF-filled tubular cyst, or syrinx, forms within the spinal cord's central canal. The growing syrinx destroys the center of the spinal cord, resulting in pain, weakness, and stiffness in the back, shoulders, arms, or legs.



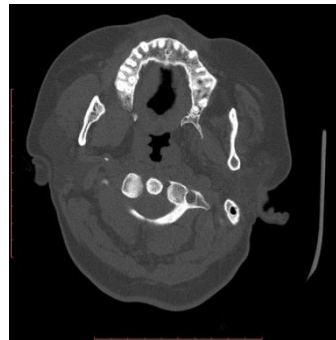
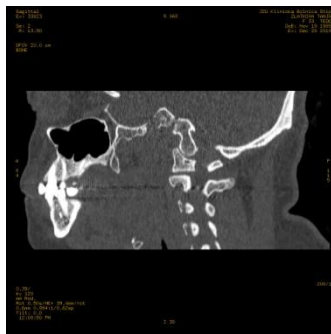

Purpose

Since Chiari malformations are associated with certain birth defects like spina bifida, children born with those defects are often tested for malformations and to use that knowledge to reduce the burden of neurological disease.

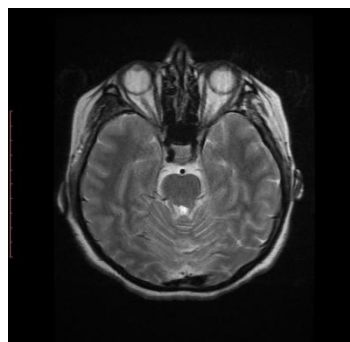
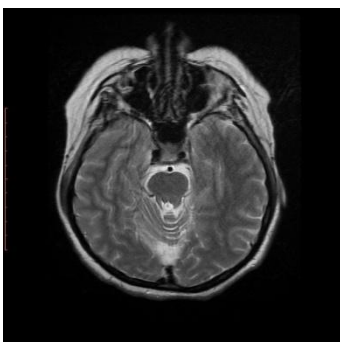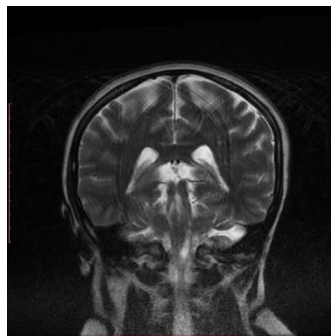
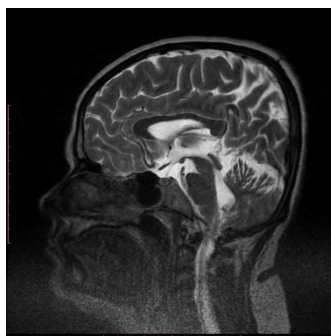Materials and methods

33 years old woman with apnea, weakness in the both arms and trouble using them to pick up and use small objects, arm and neck pain, balance problems, difficulty swallowing or speaking and etc.



Results

Computed tomography. stenosis of spinal kanal at the level C1, 13mm and distal of this 16 mm. Magnetic resonance imaging (MRI) is the imaging procedure most often used to diagnose a Chiari malformation.





Sagittal Coronal and Axial T2 WI with syrinx formation in the cervical cord and syringobulbia. The cisterna magna is obliterated and the fourth ventricle is effaced, atrophy of the cerebellar tonsils.

Conclusion

Many people with Chiari malformations have no symptoms and their malformations are discovered only during the course of diagnosis or treatment for another disorder.

PP 098

TRANSVENOUS, TRANSJUGULAR EMBOLIZATION OF A HUGE RUPTURED VENOUS ECTASIA OF A COGNARD IV TENTORIAL DURAL ARTERIOVENOUS FISTULA AS A LIFE-SAVING PROCEDURE: REPORT OF TWO CASES AND REVIEW OF THE LITERATURE

Maria Karachaliou¹, Sofia Dimoulia¹, Fotis Anagnostopoulos¹, Petros Zampakis¹, Vasileios Panagiotopoulos²

¹Department of Radiology, University Hospital of Patras, Greece

²Department of Neurosurgery, University Hospital of Patras, Greece

Introduction

Tentorium is a rare location of brain DAVFs, representing less than 4% of cases. Hemorrhagic clinical presentation is common, as cortical venous reflux consists a usual characteristic of tentorial DAVF's angioarchitecture.

Materials and Methods

We present two cases of transvenous, transjugular embolization of a huge ruptured venous ectasia of a Cognard IV tentorial DAVF, as a first step life-saving procedure. In both cases, a transarterial antegrade embolization attempt was performed but failed due to the tortuous course of arterial feeders. Subsequently, the internal jugular vein was directly catheterized under U/S guidance and a 6F guiding catheter was placed at the ipsilateral transverse sinus. A microcatheter was navigated inside the venous ectasia and eventually coils were deployed inside causing complete occlusion of the huge venous ectatic aneurysm. In this way, initial occlusion of the venous ectatic ruptured point has been achieved as a first-stage lifesaving treatment. After 4 months, one of the patients underwent stereotactic radiosurgery for the DAVF. Angiographic control with DSA 2 years after embolization revealed complete occlusion of the tentorial DAVF. Stereotactic radiosurgery for the second patient is pending. Both patients experienced complete neurological recovery.

Conclusion

Transvenous, transjugular embolization technique may be considered as an alternative, first step life-saving procedure, concerning the endovascular management of complex tentorial DAVFs with ruptured venous ectasia.





PP 099

CONTRAST ENHANCED ULTRASOUND (CEUS) IN EVAR FOLLOW UP

Soultana Foutzitz¹, Savas P. Deftereos¹, Efstratios Georgakarakos², Vasileios D Souftas¹.

¹Department of Radiology, Faculty of Medicine, Alexandroupolis University Hospital, Democritus University of Thrace, Alexandroupoli, Greece.

²Department of Vascular Surgery, University Hospital of Alexandroupolis, Medical School, Democritus University of Thrace, Alexandroupolis, Greece.

Introduction: Endovascular repair of abdominal aortic aneurysm (EVAR) considered as treatment of choice for Abdominal Aortic Aneurysms due to its minimal perioperative morbidity and mortality. A thorough pro- and post-operative imaging estimation are necessary and crucial in the long run allows visualization and documentation of adequate sealing and detects complications at an early stage, enabling early reintervention and preventing detrimental consequences.

Purpose: To evaluate the potential usefulness of CEUS, in the intravascular restoration of the abdominal aortic aneurysm (AAA).

Materials and Methods: 24 patients after AAA repair were included. All patients underwent thorough preoperative assessment of the AAA geometry for assessment of its eligibility for successful EVAR. Furthermore, postoperative Color Doppler Sonography (CDS), CEUS, CTA and MRA were performed. DSA was performed in three of these patients.

Results: CDS was a reliable non-invasive method with excellent sensitivity and specificity in the identification and classification of endoleaks after EVAR (in DDx Ia from Ib endoleaks, dissociation of the endograft's parts, endoleaks from the inferior mesenteric or the lumbar arteries to the AAA sac). CDS also can differentiate between IIa and IIb endoleak type.

CEUS is a modified technique using intravenous contrast agents (microbubbles) It yields high sensitivity and accuracy in detecting endoleaks and their types and seems to have similar accuracy compared to CTA and MRA. CEUS can characterize and better classify endoleaks with real time approach and with advantages [protection from adverse reactions to iodinated contrast agents (nephrotoxicity), burden of radiation and high cost of repeated CTA].

Conclusion: In conclusion, CEUS is considered a safe and effective imaging method which could be incorporated in institutional monitoring protocols of patients after EVAR, while the CDU display coupled with ABD-XR can be proposed as an alternative method of CEUS for detecting endoleaks and documenting the stent integrity.

References:

1. Partovi S., et al. "Contrast-enhanced ultrasound after endovascular aortic repair-current status and future perspectives". *Cardiovasc Diagn Ther.* 2015 Dec;5(6):454-63.
2. Cantisani V., et al. "EVAR: Benefits of CEUS for monitoring stent-graft status". *Eur J Radiol.* 2015 Sep;84(9):1658-65.
3. David E et al. What is the role of contrast-enhanced ultrasound in the evaluation of the endoleak of aortic endoprostheses? A comparison between CEUS and CT on a widespread scale. *J Ultrasound.* (2016).
4. Scaife M., et al. "Contemporary Applications of Ultrasound in Abdominal Aortic Aneurysm Management". *Front Surg.* 2016 May 27;3:29.
5. Rübenthaler J et al. Contrast-Enhanced Ultrasound in the Follow-Up of Endoleaks after Endovascular Aortic Repair (EVAR). *Ultraschall Med.* (2017)
6. Chisci E et al. Endovascular Aortic Repair Follow up Protocol Based on Contrast Enhanced Ultrasound Is Safe and Effective. *Eur J Vasc Endovasc Surg.* (2018).





PP 100

IDENTIFICATION OF A RARE INTRACRANIAL VASCULAR ANOMALY IN ADULTS

Sofia Dimouli¹, Maria Karachaliou¹, Nefeli Chaniotaki², Fotis Anagnostopoulos¹, Vasileios Panagiotopoulos³, Christina Kalogeropoulou¹, Petros Zampakis¹

¹Department of Radiology, University Hospital of Patras, Greece

²Medical School, University of Patras, Greece

³Department of Neurosurgery, University Hospital of Patras, Greece

Introduction

The primitive carotid-basilar anastomoses are embryonic cerebral vessels that temporarily provide arterial supply from the internal carotid artery to the longitudinal neural artery, the future vertebro-basilar artery in the hindbrain. Failure of these vessels to regress results in various persistent carotid-vertebrobasilar anastomoses which might cause clinical symptoms.

Materials and Methods

We report a case of a 59-year-old woman presented with acute, non-traumatic headache whose CT scan showed a perimesencephalic subarachnoid haemorrhage. The CT angiography later performed did not reveal any aneurysm, tumor or arteriovenous malformation in the area, whereas DSA was planned to exclude possible other causes. During the selective catheterisation of the right carotid artery there was immediate opacification of the right anterior circulation as well as the posterior circulation. These findings are related to persistent carotid-basilar communications which were indeed confirmed in the next CTA performed for detailed anatomic mapping.

Results

CT angiography was performed to figure out which of these arterial communications existed and to evaluate their exact anatomic configuration. A primitive hypoglossal artery was found since it was passing through the hypoglossal canal of the right side and joined the basilar artery inferiorly. The persistent hypoglossal artery (PHA) is the second most common persistent carotid-basilar anastomosis (incidence of 0.03–0.09%) after the trigeminal artery and it arises from the distal cervical ICA, usually between C1 and C3. The extremely rare presence of a PHA can be recognised as an incidental finding in a cerebral angiography without any clinical implications like in this patient or as a source of other severe clinical complications.

Conclusion

Since CT angiography has become a first line tool for the evaluation of intracranial vasculature mapping, it is evident that it is essential for the diagnosis of these rarely persistent anastomoses by providing precise and detailed information of their intracranial route.





PP 101

THORACIC SPLENOSIS AFTER SPLENIC INJURY. AN UNCOMMON SIDE EFFECT OF THORACOABDOMINAL TRAUMA. INCIDENTAL FINDING AFTER YEARS

Soultana Foutzitz¹, Savas P. Deftereos¹, Afroditi Strataki², Eleftheriadou Eftychia³, Zissimopoulos Athanasios², Vasileios D Souftas¹.

¹Department of Radiology, Faculty of Medicine, Alexandroupolis University Hospital, Democritus University of Thrace, Alexandroupoli, Greece

²Nuclear Medicine Department, Medical School University of Alexandroupolis, Thrace, Greece.

³ Vascular Surgeon; Private medical.

Introduction: Thoracic splenosis is a rare consequence in the more complex traumatic cases for the diagnosis it may be necessary to resort to invasive procedures, for which we wish to underline the importance of a detailed anamnesis.

Purpose: To indicate the value of good and detailed medical history in general and especially in cases with not obvious explanation of imaging findings.

Materials and Methods: A 46-year-old woman accesses the emergency room for acute thoracic pain. Laboratory tests revealed elevated D-dimmers. Pulmonary artery embolism (PE) was suspected and a thoracic CT was followed. CT was positive for PE

Results: The CT examination shows acute PE and multiple nodular formations, with the maximum size of a few centimeters, solid density, distributed in the pleural surface visceral parietal and in the recess of the ipsilateral diaphragmatic cost. After intravenous administration of contrast these lesions show marbled aspect in the arterial phase and homogeneous strengthening in the venous phase of study. These formations, in the first hypothesis, are interpreted as pleural in Technetium-99m sulphur colloid (99mTc-SC), for the diagnosis of diseases with high glucose asses/repetitive lesions.

Investigating the pathological history, a previous road accident is referred, with rib fractures, and accompanying deformation of the thoracic hull, Pneumothorax, diaphragmatic and splenic rupture with subsequent splenectomy. The CT characteristics, in agreement with the anamnestic data, appear compatible with nodules of thoracic splenosis.

Conclusion: Thoracic splenosis is an uncommon side effect of thoracoabdominal trauma involving injury to the diaphragm and spleen. Splenosis is a benign condition and is usually found incidentally on imaging studies. It is rarely diagnosed without invasive biopsy including surgical methods. However, radionuclide scanning can provide an alternative to these invasive procedures.

References:

1. Kim K., Choi H.J., Kim Y.M., Kwon W.J., Lee W.C., Suh J.H. Thoracic splenosis: a case report and the importance of clinical history. J Korean Med Sci. 2010;25:299–303
2. Yuwei Tian, et al. Diagnosis of multiple splenosis in right thorax and retroperitoneum: a case report and literature review. Int J Clin Exp Pathol 2016;9(7):7498-7502.



**PP 102****ANATOMICAL VARIATIONS OF THE VERTEBROBASILAR CIRCULATION AND THEIR SIGNIFICANCE: AN ANALYSIS WITH 64-DETECTOR ROW CT ANGIOGRAPHIES**

Jelena Kostić, Irena Kostić, Ana Stanković, Dragan Mašulović

Centar za radiologiju i magnetnu rezonancu, Klinički centar Srbije.

Purpose. To determine the normal anatomical features and variations of the vertebrobasilar circulation and its branches in patients who underwent multidetector computed tomography (CT) or magnetic resonance (MR) angiographies of the brain.

Material and methods. 135 traumatized patients (male, 83 and female, 52; mean age, 50.1 years) who underwent CT or MR angiographies of the vertebrobasilar vasculature for various reasons were analyzed retrospectively at Emergency center Clinical centre of Serbia. The right and left distal vertebral arteries (VAs), posterior inferior cerebellar arteries (PICAs), anterior inferior cerebellar arteries (AICAs), superior cerebellar arteries (SCAs), posterior cerebral arteries (PCAs), and posterior communicating arteries (PCoAs) were analyzed individually.

Results. In 24.4% of the cases (33/135) right PICA, in 19.3% of the cases (26/135) left PICA, in 17.8% of the cases (24/135) right AICA, and in 18.5% of the cases (25/135) left AICA were absent. In cases without PICA or AICA, there was a statistically significant, moderately or well-developed AICA or PICA on the same side, respectively. The most common variation was isolated absence of right PICA and was seen in 17.8% of the cases.

Conclusions. The anatomic features of the branches of the vertebrobasilar circulation may be different from well-known normal anatomy. CT and MR angiographies allow a precise and detailed evaluation of vertebrobasilar circulation.

Keywords: arterial variants, vertebrobasilar circulation, CT angiography, MR angiography.

PP 103**THE DIAGNOSTIC DIFFICULTIES OF OLFACTORY NEUROBLASTOMA-CASE REPORT**

Grdinic Marija, Sotirovic-Senicar Slavica

Centre for radiology, Clinical Centre of Vojvodina, Novi Sad, Serbia

1. Introduction:

Olfactory neuroblastoma is an uncommon malignant tumor that arise from the sensory neuroectodermal olfactory cells. The tumor tends to be locally aggressive, involving adjacent structures and it can mimic many tumors within the sinonasal tract, but one of the most important radiological characteristic is hyperattenuating mass extending across the cribriform plate with intracranial and sinonasal propagation.

2. Purpose: Our aim was to present radiological characteristics of olfactory neuroblastoma.

3. Materials and Methods: Young female (30 yrs) with chronic rhinohhrea, right nasal congestion, and sometimes with bleeding during past three years had PNS CT scan, MRI of the paranasal sinuses and brain, and cereblar DSA.

4. Results: PNS CT and MRI shows expansive, irregular, fairly well-circumscribed soft-tissue mass involving nasal cavity, vestibulum and the nasopharynx, as well as right sphenoid and maxillar sinus





with bone destruction of nasal conchas, anterior wall of sphenoid sinus, and anterior etmoid cells. Cribriform plate was infiltrated with endocranial tumour propagation, but without sign of parenchymal infiltration. After IV contrast administration a strong enhancement was seen. Conventional digital angiography revealed a vascular network of the mass, supplied by the terminal branches of both maxillary arteries, both ophthalmic arteries and right facial artery. Before the operation, as the radiologic findings showed the high vascularisation of the tumour, terminal branch of maxillary artery was selectively embolised by interventional radiologist.

5. Conclusion: Olfactory neuroblastoma is a rare tumora with difficulties in diagnosis where the most important role have pathohistological examination after surgery. Radiologist has major role in providing information about lesion size, vascular pattern, extent of lesion, and anatomical information of the surrounding vital structures such as underlying bony structures, as well as cerebral parenchym. Also because of its hypervascularity selective preoperative embolisation of main vascular feeder is life saving procedure regarding potential fatal bleeding during surgery.

PP 104

A RARE CASE: A CASE OF METACHROMATIC LEUKODYSTROPHY

Ersen Mehmet, Arda Kemal Niyazi, Akay Sinan, Tasar Mustafa
Gulhane Research Hospital/SBU, Ankara, Turkey

Introduction

39-year-old female patient was admitted with complaints of introversion and forgetfulness that started after of her child trauma which happened a year ago. After administrating neurology department, she was referred to our clinic for further evaluation.

Material and Method

Case evaluated with 3T MRI device. Patient was evaluated by conventional MRI sequences, diffusion-weighted imaging and MRI spectroscopy imaging.

Result

MR imaging showed T1 hypointens, T2 and FLAIR hyperintense areas with volume loss in the periventricular deep white matter, anterior parts of the bilateral frontal lobe and corpus callosum genu. Lesions did not restrict diffusion (Figure 1). Multivoxel MR spectroscopy showed significant increase in Choline/NAA ratios, significant decrease in NAA, and occasional myoinositol peaks (Figure 2). Defined findings suggested neurodegenerative processes. When the appearance was evaluated with the involvement pattern, it suggested metachromatic leukodystrophy. Histopathological sampling was interpreted as compatible with leukodystrophies.

Discussion and Conclusion

Leukodystrophies are diseases with a genetic background that primarily affect white matter components in the central nervous system. Metachromatic leukodystrophy is the most common hereditary leukodystrophy. It is transmitted in an autosomal recessive pattern and is one of the lysosomal storage diseases. It is seen in 1/100000 in the general population. Usually it is diagnosed in 12-18th months. Three forms of metachromatic leukodystrophy (adult, juvenile and late infantile) were identified according to the time of finding. Pathological findings are related to the deficiency of aryl sulfatase A enzyme. Sulphide accumulation in white matter seems in this process. In addition, because sulphate accumulates in the gallbladder wall, cholecystitis is also frequently observed in these cases. Leukodystrophies should be considered in MR evaluation especially in cases where white matter is symmetrical involved. A preliminary diagnosis can then be obtained by assessing the localization of





involvement. Metachromatic leukodystrophy is characterized by symmetrical areas that confluences in the periventricular deep white matter. Involvement becomes apparent, especially in the neighborhood of frontal horns. Involvement becomes more pronounced especially in the neighborhood of frontal horns. These findings with non affected U fibers results in a characteristic butterfly pattern. Involved areas are observed as hypointense in T1A and hyperintense in T2A, and these areas characteristically do not shows enhancement. Spectroscopic examination of the affected areas shows decrease in NAA peak and increase in lactate and myoinositol peaks.

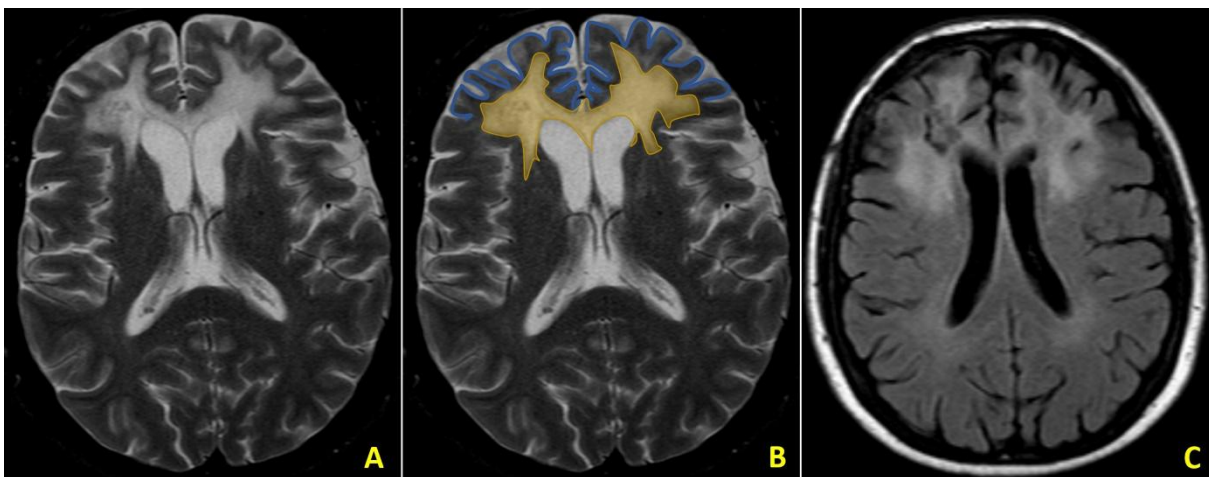


Image 1. (A) and (B) T2A and (C) FLAIR slices show butterfly-like pattern in the periventricular white matter adjacent to the frontal horns (yellow shaded area). atrophic changes characterized by deepening of the gyri also seems in frontal region (blue lines).

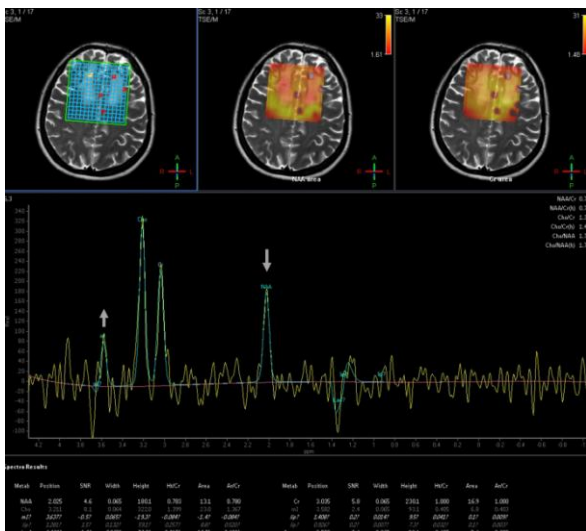


Figure 2. Multivoxel MR spectroscopy of the lesion shows a decrease in NAA peak and increase myoinositol peak in a voxel.





PP 105

IGG4 SYNDROME-CT FINDINGS

Dimoula Sofia, Zampakis Petros, Karachaliou Maria, Tsintoni Aggeliki,
 Petsas Theodoros, Kalogeropoulou Christina
 Department of Radiology, University Hospital of Patras, Greece

Introduction

IgG4 syndrome is a multi-systemic disease that is associated with elevated serum IgG4 levels and T-cell organ infiltration. Organs that are affected are pancreas, bile ducts, kidneys, lymph nodes, retroperitoneal fat, thyroid, salivary glands, vessels and lungs. Autoimmune pancreatitis is the most common manifestation of the syndrome. Patients show a dramatic response to corticosteroid therapy, making rapid diagnosis important.

Purpose

The presentation of CT findings in patients (study) where the diagnosis of IgG4 syndrome was confirmed.

Materials and Methods

We present the CT findings of IgG4 syndrome in patients of our radiology department's database in which the diagnosis was confirmed based on the serological-histological findings.

Results

Imaging findings of IgG4 syndrome include focal and diffuse infiltration of organs from inflammatory and fibrous tissue. The pancreas infiltration is common with CT findings compatible with autoimmune pancreatitis. As a result of affection of other organs, CT findings of sclerosing cholangitis, cholecystitis, nephritis, retroperitoneal fibrosis, sclerosing mesenteritis, lymphadenopathy, pericardial infiltration, sialadenitis or interstitial lung disease are identified. The combination of imaging findings with serological-histological findings (increased IgG4 levels and positive biopsy) and eventually response to corticosteroid therapy confirm the diagnosis of the syndrome. CT scan provides the necessary information about the location of the disease and the underlying pathology, thus directing treatment. Imaging with CT, MRI and / or PET-CT is essential for assessing both the extent of the disease and the response to treatment

Conclusion

The sclerosing disease associated with the IgG4 syndrome may be multi-systemic. CT imaging is important for early diagnosis, early treatment initiation, and prevention of possible complications.





PP 106

MULTIDETECTOR COMPUTER TOMOGRAPHY FOLLOW-UP AFTER CARDIOVASCULAR SURGERY AND ENDOVASCULAR INTERVENTIONS

Cobzeanu Maria Luiza, Chistol Raluca Ozana, Negru Dragos
"Sf. Spiridon" Emergency Hospital Iasi, Romania

Introduction: Development of electrocardiographically (ECG) gated multidetector computed tomography (MDCT) had a significant impact in cardiovascular imaging both in preoperative planning and postoperative evaluation of surgery.

Purpose: The aim of this paper is to illustrate normal and pathologic postoperative aspects identified by MDCT in case of open or endovascular cardiovascular procedures with emphasis on its utility for the cardiovascular surgeon.

Materials and Methods: Due to its improved spatial and temporal resolution and its ability to produce three-dimensional, dynamic and multiplanar images, MDCT assumes an integral role in characterization of graft patency, congenital heart diseases interventions, aortic procedures, aortic valve prostheses, and endovascular devices as used at the Cardiovascular Diseases Institute.

Results: Except these specific indications, MDCT allows investigation of alternative postoperative complications due to its excellent tissue discrimination. In addition, the expanded capabilities of volumetric imaging may provide valuable anatomical information in preoperative planning for redo cardiac surgery in order to avoid potential life-threatening intraoperative incidents.

Conclusion: In conclusion, a thorough knowledge of possible findings will allow an appropriate identification and differentiation of normal MDCT findings from postoperative complications.

PP 107

ENDOMYOCARDITIS IN PEDIATRIC AGE HEMOPHAGOCYTIC LYMPHOHISTIOCYTOSIS AFTER EBSTEIN BARR-VIRUS INFECTION: CARDIAC MRI FINDINGS

Ozkok Sercin
Istanbul Medeniyet University Goztepe Training And Research Hospital

Introduction:

Hemophagocytic lymphohistiocytosis (HLH) syndrome is a life-threatening hematological disease associated with severe systemic inflammation caused by uncontrolled and ineffective immune response. In this article, we aimed to report the cardiac magnetic resonance imaging (CMRI) findings of endocarditis after Epstein-Barr virus (EBV) infection in a child with HLH syndrome who has not previously reported.

Case Presentation:

A 9-year-old male patient who had bone marrow transplantation with the diagnosis of HLH and history of EBV endocarditis on his history admitted to pediatric cardiology clinic for the cardiac evaluation before methotrexate treatment. Thickening of the left ventricular mitral valve papillary muscle and echogenic nodularity on the endocardial surface were detected on echocardiography and referred to





our clinic for CMRI examination. Cardiac MRI revealed normal biventricular volume and function with myocardial late enhancement in papillary muscles of mitral valve on myocardial delayed enhancement sequence 10 minutes later intravenous contrast agent injection (**Figure 1**). And also there was a milimetric nodular contrast enhancement at the endocardial surface of lateral wall of the left ventricle (**Figure 2**) indicative for endomyocarditis. The patient was given medical treatment for EBV endomyocarditis.

Discussion:

HLH may be primary familial, secondary to infection, lymphoproliferative disease or connective tissue diseases. Liver, lung, kidney, heart and skin involvement can occur in various degrees and may lead to multiple organ failure. In a few cases that is reported that papillary muscle involvement and subendocardial infiltration imagined by MRI in the hypereosinophilic syndrome in the literature. Our case is the only pediatric case with papillary muscle involvement and subendocardial infiltrations showed by CMRI in HLH syndrome and EBV endocarditis.

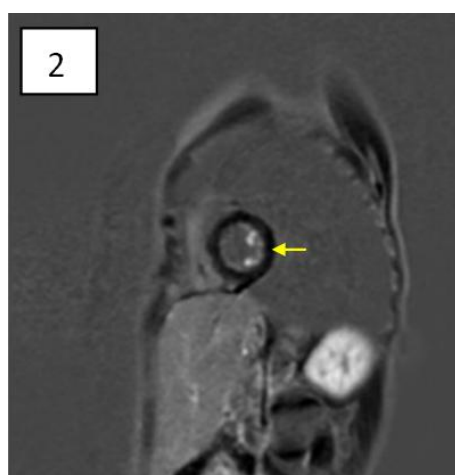
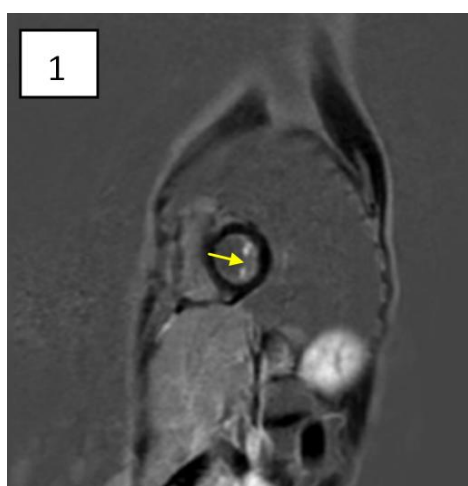Results:

Cardiac involvement can be seen in both primarily or secondarily in hematological diseases. CMRI is one of the non-invasive imaging modality used to imagine endocardial and papillary muscle involvement in this patient group. In addition, CMRI is an appropriate imaging modality for follow-up and response to treatment when combined with echocardiography.

KEYWORDS: Cardiac Magnetic Resonance Imaging (MRI), Hemophagocytic lymphohistiocytosis (HLH), endomyocarditis, papillary muscle, Ebstein-Barr virus (EBV)

Figure 1. Myocardial enhancement in papillary muscles of mitral valve on myocardial delayed enhancement sequence 10 minutes later intravenous contrast agent injection

Figure 2. Milimetric nodular contrast enhancement at the endocardial surface of lateral wall of the left ventricle on myocardial delayed enhancement sequence 10 minutes later intravenous contrast agent injection





PP 108

PSEUDOMYXOMA PERITONEI – CASE REPORT

Violeta Tolevska, Masha Kostova, Dimitar Veljanovski, Magdalena Bogucevska, Bozidar Blazeovski, Sandra Dejanova Panev
City General Hospital 8th September, Radiology Unit, Skopje, N. Macedonia

Introduction: Pseudomyxoma peritonei is a syndrome of intraperitoneal accumulation of mucinous ascites caused by mucinous neoplasm, most common in appendix. It can be also caused by mucinous tumors of colon, rectum, gaster, pancreas and urachus.

Purpose: The purpose of the study is to show our diagnostic experience in patients with pseudomyxoma peritonei.

Material and methods: In this case study a male patient (61year) old with pseudomyxoma peritonei is presented. The patient was analyzed through Computer Tomography (CT, G16) and Ultrasonography (US, Saote, My Lab25Gold).

Results: On CT abdomen perihepatal and perisplenic ascites were found. The right hepatic lobus was light increased, left hepatic lobus was compressively changed with thick content which is suspected to be mucine. Intrahepatal biliary tract was slightly dilated and biliary cyst showed compressive effect due to surrounding thick liquid. Thick free liquid – mucine was found perihepatal, perilienal, perigastric, paracolic with slight compression of the intestine with not significant augmentation of lumphs nodes was found. By US method, thick free liquid was found in perihepatal space, intrainestinal space and in the pelvic cavity.

Conclusion: The combination of radiological findings is important in diagnosis and decision making algorithm for treatment of the patient with pseudomyxoma peritonei.

PP 109

ADULT ONSET SCIMITAR SYNDROME: ANATOMIC AND PHYSIOLOGIC EVALUATION BY CARDIAC MRI

Ozkok Sercin

Istanbul Medeniyet University Goztepe Training And Research Hospital

Introduction:

Scimitar syndrome is a rare congenital heart disease (CHD) characterized by an partial anomalous of pulmonary vein connection, often associated with hypoplastic right lung. Abnormal pulmonary vein can be drained to the supra or infradiaphragmatic part of the inferior vena cava and the name is derived from its similarity to a Turkish palate called 'Scimitar'. Here we present an adult patient with Scimitar syndrome diagnosed by cardiac magnetic resonance imaging (CMRI).

Case report:

A 37-year-old female patient presented with chest pain and exertion dyspnea. Physical examination and laboratory findings were normal. Transesophageal echocardiography showed enlargement of the right heart cavities, and systolic pulmonary artery pressure was 55 mmHg and pulmonary-to-systemic flow ratio (Qp:Qs) was approximately 2.4. Magnetic resonance-angiography revealed that the right inferior pulmonary vein drained to the subdiaphragmatic part of inferior vena cava consistent with Scimitar syndrome (**Figure 1a,b**). CMRI revealed increased a right ventricul end-diastolic volume of 136 ml/m² and ejection fraction of 59 %. Calculated Qp:Qs was 1.78 (Figure 2). revealed by phase contrast sequences of aorta and pulmonary artery (Figure 3a,b). Any associated congenital heart disease (CHD)





detected. The patient was referred to cardiovascular surgery with the surgical indications without any additional invasive procedure.

Discussion:



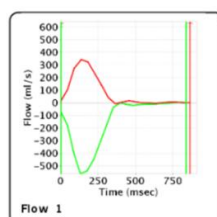
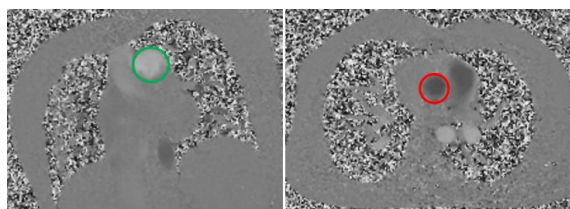
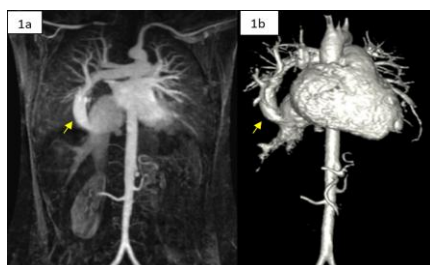
Right lung hypoplasia, dextroposition of the heart, right pulmonary artery hypoplasia, pulmonary artery sequestration, and abnormal arterial feeding of the right lung lower lobe from the infra-diaphragmatic aorta are other important components of the syndrome. Severity of the disease is associated with accompanying cardiac and pulmonary anomalies. It can be complicated by congestive heart failure and pulmonary hypertension at later ages in mild cases. Other congenital heart disease can be seen such as atrial septal defect, ventricular septal defect, patent ductus arteriosus, aortic arch anomalies. Although the diagnosis of the disease is made by catheter angiography, non-invasive computed tomographic and magnetic resonance angiography have been recently used in the diagnosis. Surgical indication of Scimitar syndrome are Qp:Qs ratio higher than 1.5 and presence of pulmonary hypertension. As a result, CMRI reduces the need for conventional angiography which is accepted as the gold standard because of the ability to evaluate both anatomical and hemodynamic changes.

Keywords: Cardiac magnetic resonance imaging (CMRI), Scimitar syndrome, Magnetic resonance-angiography

Figure 1a,b : Magnetic resonance-angiography shows that the right inferior pulmonary vein drained to the subdiaphragmatic part of inferior vena cava by MIP (1a) and 3D (1b) reconstructed image.

Figure 2: Imaging planes of main pulmonary artery (green circle) and aorta (red circle) on phase contrast CMRI sequence.

Figure 3a,b: Calculated flow parameters and diagram of main pulmonary artery (green curve) and aorta (red curve).





PP 110

ASSOCIATION OF LEFT MAIN CORONARY ARTERY ANEURYSM AND RIGHT VENTRICULAR CAMARAL FISTULA: TIME RESOLVED MR ANGIOGRAPHY FINDINGS

Sercin Ozkok¹, Oyku Tosun²

1 Istanbul Medeniyet University, Goztepe Training and Research Hospital, Radiology Department, Istanbul, Turkey

2 Istanbul Medeniyet University, Goztepe Training and Research Hospital, Pediatric Cardiology Department, Istanbul, Turkey

Introduction:

Coronary artery fistulas are defined as abnormal direct connection of coronary arteries to any cardiac cavity (coronary-camaral) or large vessels. Coronary artery fistulas are rarely seen (1 in 50000 live births). Although most of them seen congenitally they can also be seen after coronary angiography, thoracic trauma, endo-myocardial biopsy. Usually they drains into the right heart cavities. Although patients are usually asymptomatic, coronary artery fistula may be complicated with myocardial ischemia, dilatation of right heart cavities, heart failure, infective endocarditis. Here we report the time-resolved MR angiography images of the association of left main coronary artery (LMCA) aneurysm and left anterior descending artery (LAD) to right ventricular camaral fistula.

Case presentation:

A 9-year-old male patient admitted to our clinic for cardiac magnetic resonance imaging (CMRI). The patient had a history of hypoplastic right heart, intact ventricular septum, 1.5 ventricular repair due to pulmonary atresia, Glenn operation, and transcatheter pulmonary valve replacement at the age of 8 months. In cardiac MRI, the patient had normal left ventricular ejection fraction (LV-EF = 45%) with impaired right ventricular ejection fraction (RV-EF = 26%). After contrast agent administration it's observed that contrast agent passed through left heart via superior vena cava, pulmonary veins and pulmonary arteries and pulmonary veins due to Glenn operation (**Figure 1a,b**). While the contrast media were present in the left heart chambers, it was absent right heart chambers in first phase of MRA. Increased contrast media filling in right ventricular apex retrogradely was observed in followed phases due to the presence of a fistula between LAD and right ventricular apex (**Figure 2a,b,c**). In following phases, millimetric nodular contrast filling along the LAD through anterior interventricular sulcus significant for LAD aneurysm. It was also diagnosed that digitiform aneurysm in proximal part of LAD (**Figure 3**).



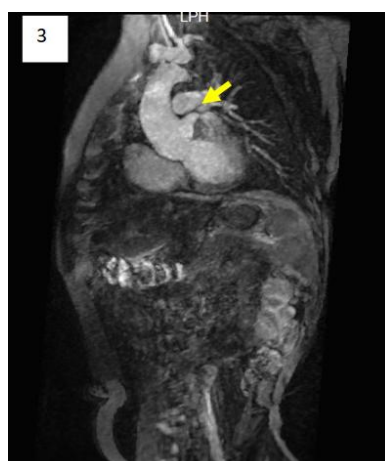
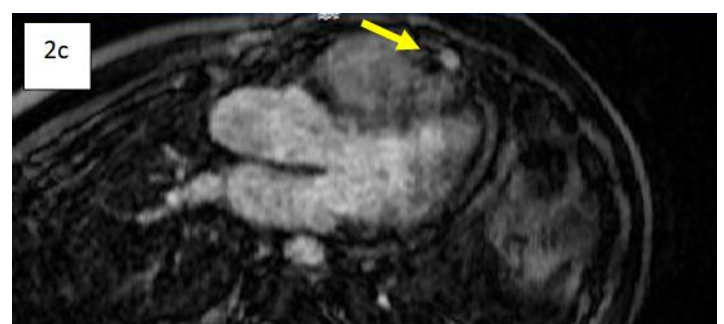
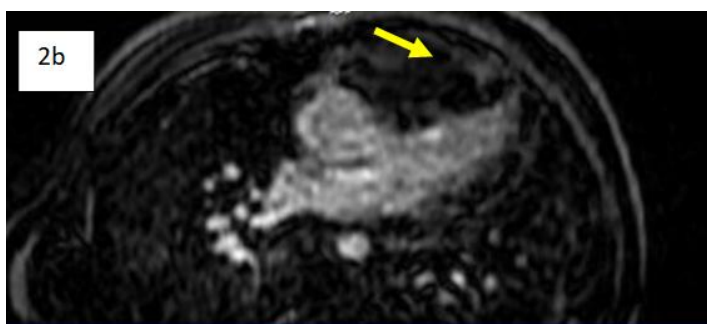
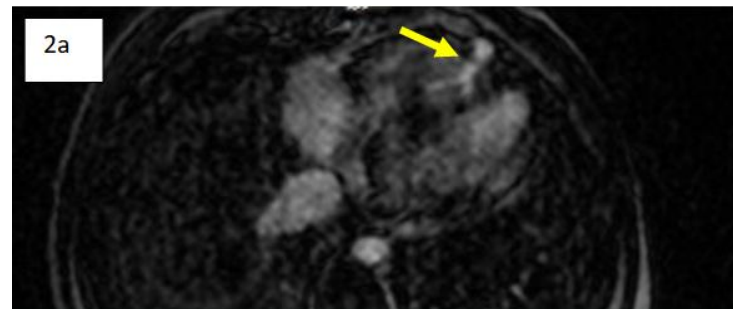
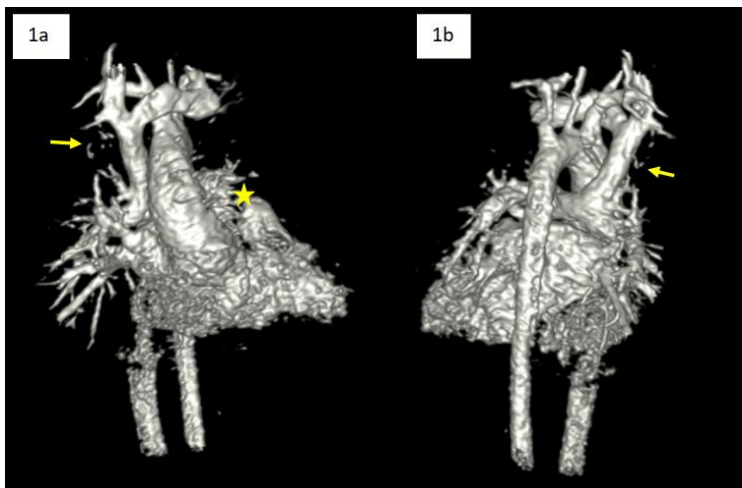
**Discussion:**

Although arterial catheterisation is a gold standard in imaging of coronary artery fistulas, MRA is an appropriate non-invasive imaging option in selected cases. Vascular anatomy, cardiac function can also be evaluated by cardiac MRA.

Figure1: 3D reconstructed MRA images of Glenn shunt between superior vena cava and right pulmonary artery with pulmonary valvere placement area (asteriks) from anterior aspect (1a) and posterior aspect (1b).

Figure2: Increased contrast media filling in right ventricular apex retrogradely in following phases due to the presence of a fistula between LAD and rightventricular apex.

Figure3: MIP reconructed MRA images of digitiformaneurysm in proximalpart of LAD.





PP 111

RENAL TUMORS WITH CAVOATRIAL EXTENSION

Begenisic Biljana

KBC"Dr.Dragisa Misovic Dedinje" Belgrade Servia

INTRODUCTION

Renal cancer accounts for approximately 3 % of all cancers. The most common type (80–90% of cases) is renal cell carcinoma. Renal tumors, especially RCC, but sometimes TCC, sarcoma, Wilms' tumor, or even benign neoplasms like angiomyolipoma have a tendency to extend into the lumen of the renal vein, inferior vena cava, or even into the right atrium. About 20-30 % of patients with RCC have tumor thrombosis of the renal vein, and in 4-10 % the thrombus extends into the IVC.

a) PURPOSE

To describe CT findings used for diagnosing and staging of cavoatrial tumor thrombosis.

b) MATERIJALS AND METODS

Contrast-enhanced CT is considered the standard method for diagnosing cavoatrial tumor thrombosis, with sensitivity and specificity between 80% and 98%.

c) RESULTS

Since renal tumors are often asymptomatic, symptoms resulting from cavoatrial thrombosis may be the first to appear. They include bilateral lower extremity edema, Budd-Chiari syndrome, dilated superficial abdominal veins, venous collateral formation, varicocele, concomitant pulmonary emboli. Also, cavoatrial thrombosis may be mistaken for bland thrombi or heart tumors.

Cavoatrial tumor thrombosis is best visualized in the portal venous phase. After administration of the contrast material, the tumor thrombus is visualized as a low-density filling defect in the brightly enhanced blood, contiguous with the adjacent tumor. CT signs of wall invasion are focal enhancement of the vena cava wall, or infiltration of the adjacent soft tissue.

d) CONCLUSION

Preoperative radiological evaluation of cavoatrial tumor thrombosis is mandatory. It allows detection of metastases and precise determination of cephalic extension of the tumor thrombus, both of which determine the right surgical approach. In the vast majority of cases, cavoatrial tumor thrombosis occurs in patients with RCC. However, one should always have in mind the possibility of other tumors (renal or from other organs) extending into the IVC.





PP 112

INGVINO-SCROTAL URINARY BLADDER HERNIAS

Antonio Gligorievski, Ivan Nevcev

University Clinic for Surgical Diseases "St. Naum Ohridski" Skopje, Republic of North Macedonia

Abstract Herniation of urinary bladder through the inguinal canal is a rare disease that requires surgery. The resulting combination of failure of the abdominal wall and an increase in intra-abdominal pressure occurs prolapse of the urinary bladder in the inguinal canal and the occurrence of ingvino-scrotal hernia. This phenomenon is very rare and often misdiagnosed. It occurs more often in older men with increased body weight and symptoms of distal urinary obstruction and urinary infections. The symptoms usually are mild to moderate, associated with hindered urination and urinary infections, and if this condition promptly left untreated can lead to serious health problems, to renal failure. CT reconstruction in three planes is the method of choice in the diagnosis of ingvino-scrotal hernia of the bladder. This method provides a clear display of herniated part of the urinary bladder, and allows detection of the contents of the hernial sac.

PP 113

ECTOPIC SPLEEN PRESENTING AS PELVIC MASS

Antonio Gligorievski

University Clinic for Surgical Diseases "St. Naum Ohridski" Skopje North Macedonia Introduction:

Ectopic spleen is a very rare clinical entity, characterized by the absence of one or more of the ligaments, in which the spleen is located outside of its normal position. The spleen can be found anywhere in the abdomen or pelvis owing to its long, vascular pedicle. Ectopic spleens are found more commonly in women. Patients are often asymptomatic and the diagnosis can be accidental.

Presentation of case: A female patient at the age of 67 years was undergone on CT investigation after a clinical finding of a suspicious hernia on the anterior abdominal wall. The patient complains of pain in the lower abdomen. A post contrast CT scans clearly reveal of an ectopic spleen in the pelvis with normal enhancement and no signs of infarction or torsion. There was a long splenic pedicle containing tortuous vessels.

Discussion: Clinical manifestations of ectopic spleen vary from asymptomatic to complications related to torsion. Imaging findings of the ectopic spleen are the absence of the spleen in its normal position and a mass located anywhere in the abdomen or pelvis with enhancement pattern of a normal splenic tissue. The treatment choice of an ectopic spleen is splenopexy. Splenectomy is required only in case of infarction, which can be diagnosed radiologically.

Conclusion: This diagnosis should be considered whenever there are mobile abdominal or pelvic mass, signs, and symptoms of an abdominal discomfort, or an acute abdomen or during investigations of chronic intermittent abdominal pain. CT is the most used methods for diagnosis which revealed the absence of the spleen in its normal position, and a homogeneous mass with contrast enhancement located in the pelvis.





PP 114

ROLE OF MR MAMMOGRAPHY IN DETECTION OF BREAST IMPLANTS ABNORMALITIES

Maja Jakimovska¹, Maja Jakimovska-Dimitrovska², Tanja Petrovska³, Sandra Dejanova Penev⁴

¹General City Hospital 8th of September Skopje, MKD

²University Clinic of Radiology, University St. Ciril and Methodius Skopje, MKD

³Clinical Hospital St. Naum Ohridski Skopje, MKD

The indication for breast implants may be: breast outlook improvement due to small breast, breast asymmetry, reduction of breast tissue, breast outlook after pregnancy and lactation, after mastectomy. There are 2 types of breast implantation: submuscular (below m. pectoralis), and subglandular (between m. pectoralis and breast tissue).

Breast reconstruction after mastectomy is more complicated due to the additional skin extirpation.

The advantages of implants versus flap: shorter and easier surgery; the certain incision site for mastectomy is used with less scar formation; it can be done in one act; the weight changes has no influence on breast size; qualified surgeons available.

Disadvantages of implant versus flap: occasionally the procedure may last longer; the breast outlook shows much difference than the natural one; complications such as rupture, deflation and capsular contracture may occur; the other healthy breast often needs to be reconstructed for same outlook of both breasts; it is not good option for irradiated skin; the implant has expiration date.

Imaging methods are used for the breast implant evaluation such as the implant integrity; implant irregularities; or to diagnose breast changes, such as cancer. The imaging modalities are: Mammography; Ultrasound; and Magnetic resonance.

Breast implants complications may be early and late. Early complications are: haematoma and local infection, while late are: capsular contracture, implant rupture.

Results In CGH 8th of September have been made during 2017 and 2018 252 MR mammography and on University Clinic of Radiology 56 MR mammography or total 308. 29 patients or 9,4% have had breast implants and were made with silicons protocol, but on all of them have made dynamic puls sequences after contrast application too. 6 patients or 20,6% have made implants because of cosmetic reasons and rest 23 or 79,3% post mastectomy. In 6,9% of patients with implants we found abnormalities 1 case with siliconom in breast tissue outside implants capsule and another case with intracapsular rupture. On MRI mammography normal implants are with smooth contours, surrounded with hypointensive ring in all puls sequences which corresponds with fibrous capsule. Radial spaces can be normal finding, and they shouldn't be misinterpreted for intracapsular rupture signs.

Conclusion. The golden standard for detection of implant rupture is Magnetic resonance.

The method of choice in detection of breast malignant diseases with implants is MR mammography after contrast application.





PP 115

UNILATERAL VENTRICULOMEGALY ASSOCIATED WITH ISOLATED INFERIOR VERMIAN HYPOPLASIA

Koyun Mustafa, Arda Kemal Niyazi, Akay Sinan, Tasar Mustafa

Department of Radiology, University of Health Sciences, Gulhane Training and Research Hospital, Ankara, Turkey

Purpose

Isolated vermian hypoplasia refers to the partial absence of the inferior part of the cerebellar vermis. In the literature, some authors describe this anomaly as Dandy-Walker variant (1). Unilateral ventriculomegaly describes the asymmetric extension of the lateral ventricle secondary to the non-functioning of foramen Monro. In this paper, we aimed to present the MR findings of a unilateral ventriculomegaly case that is associated with isolated inferior vermian hypoplasia which was not previously described in the literature.

Case report

T1-weighted, T2-weighted, FLAIR (Fluid attenuation inversion recovery) and contrast-enhanced T1-weighted MR images of a 6-year-old male with a history of cerebral palsy and epilepsy were referred to our department for follow-up imaging. The frontal horn and body of the right lateral ventricle were dilated (figure 1). The white matter volume adjacent to dilated ventricle was decreased. The right thalamus was not seen. Corpus callosum was considered to be thin. The same images showed that the cisterna magna was enlarged and the inferior part of the cerebellar vermis was hypoplastic (figure 2).

Discussion

Isolated inferior vermian hypoplasia, also called Dandy-Walker variant, is frequently used for cases that do not include all the criteria of Dandy-Walker malformation. Some writers avoid using this naming as it causes confusion. In addition, it is not known exactly what the disease-related effects are in these patients. Recent studies show that these patients may have normal cognitive, language, social and behavioral functions. Approximately 25% of patients have mild functional impairment in fine motor activities and grip (2). Many CNS anomalies or findings may accompany this entity.

Conclusion

Unilateral ventriculomegaly in our case is a very rare association of inferior vermian hypoplasia. The radiologists should be familiar with the radiological features for guiding the clinicians in managing those patients, correctly.

References

1. Estroff JA, Scott MR, Benacerraf BR. Dandy-Walker variant: prenatal sonographic features and clinical outcome. *Radiology* 1992;185(3):755–758.
2. <https://radiopaedia.org/articles/isolated-inferior-vermian-hypoplasia>.





PP 116

TRAUMATIC PSEUDOANEURYSM OF THE SUPERFICIAL TEMPORAL ARTERY

Koyun Mustafa , Arda Kemal Niyazi, Akay Sinan, Tasar Mustafa

Department of Radiology, University of Health Sciences, Gulhane Training and Research Hospital, Ankara, Turkey

PURPOSE

Pseudoaneurysm occurs after arterial wall defect and refers to condition in which blood and extravascular structures are associated. Superficial temporal artery pseudoaneurysm (STAP) is less than 1% of reported true aneurysms and pseudoaneurysms (1). In the etiology of superficial temporal artery pseudoaneurysm, 90% of blunt traumas and 5-10% of penetrating trauma and iatrogenic causes are reported (2). In this paper, we aimed to present the clinical and ultrasonographic (US) findings of a superficial temporal artery pseudoaneurysm case.

CASE REPORT

A 23-year-old female patient was admitted to our hospital with right frontotemporal swelling (figure 1). It was learned that the patient was dealing with martial arts and he was hit to swelling area two months ago. A painless pulsatile mass was palpated in the swelled area. Gray scale US images revealed that oval-shaped, thick-walled, well-circumscribed, anechoic cystic lesion with dimensions of 9.3x3.7 mm (figure 2). Color doppler ultrasonography showed “yin-yang” arterial flow signal in the cystic lesion (figure 3). An arterial flow signal was detected in the related tubular structures (figure 4). In the light of those findings, the lesion was diagnosed as superficial temporal artery pseudoaneurysm.

DISCUSSION

STAPs are pulsatile lesions located in subcutaneous tissue and are mostly occurred secondary to blunt trauma. On US, STAP is seen as round or oval shaped, thick-walled, hypo-anechoic cystic lesions (2). Partial or total thrombosis may be seen in pseudoaneurysm sac. The appearance of pseudoaneurysm may vary according to the age of the thrombus. On color doppler ultrasonography, showing “yin-yang” sign within the pseudoaneurysm sac and the arterial connection of the aneurysm is important in the diagnosis. Furthermore, the presence of “To and fro” flow pattern on the aneurysm neck is specific finding for aneurysm and pseudoaneurysm.

CONCLUSION

Knowing the clinical findings, gray scale and color doppler ultrasonography characteristics of STAP may prevent this rare entity from being overlooked and guide the clinician to correctly manage the patients.

REFERENCES

- 1) Faisal A. Quereshey, Sunwoong Choi, Brad Buma. Traumatic Pseudoaneurysm of the Superficial Temporal Artery in a Pediatric Patient: A Case Report. Oral and maxillofacial surgery. doi.org/10.1016/j.joms.2006.05.071.
- 2) A. Corvino, O. Catalano, F. Corvino, F. Sandomenico, S. V. Setola, and A. Petrillo. Superficial temporal artery pseudoaneurysm: what is the role of ultrasound?. J Ultrasound. 2016 Sep; 19(3): 197–201. doi: 10.1007/s40477-016-0211-8.





PP 117

PREOPERATIVE RENAL ARTERY EMBOLIZATION IN THE TREATMENT OF RENAL CELL CARCINOMAZorbas D.¹, Georgiadou M.¹, Karaterakis N.², Boulalas I.², Koutelas N.¹, Nikolaou V.¹¹ Radiology Department, Nikaia General Hospital, Greece² Urology Department, Nikaia General Hospital, Greece**Introduction**

Renal cell carcinoma (RCC) is the most common malignant neoplasm of the kidney and is usually very vascular. Operative treatment of RCC can be associated with a high rate of perioperative morbidity related to hemorrhage and injury to adjacent anatomical structures. Renal artery embolization is a technique by which arterial blood flow can either be decreased or completely terminated to prepare a patient with a renal neoplasm more safely for surgical resection.

Purpose

The authors evaluated the outcome of 11 hospitalized patients with single large RCC in whom Preoperative Renal Artery Embolization was performed.

Materials and Methods

All Preoperative Renal Artery Embolization procedures were performed 6-24hrs prior to planned surgery. Embolization technique consisted, in all cases, of a right common femoral artery approach using ultrasound guidance, a 0.032" hydrophilic guide wire, a 5Fr short sheath and a 4Fr Cobra 2 catheter, providing selective access of the renal artery. No aortogram was performed, since all patients had extensive CTA imaging. Embolic agents used were primarily Coils ranging in size from 3mm to 8 mm. In 2 cases of very large RCC's (with diameter >10cm) large PVA particles (700-900µm) were also used, after careful exclusion of arteriovenous communication.

Results

All Preoperative Renal Artery Embolization procedures were technically successful, with completely terminated arterial blood flow to the kidney. All patients underwent planned Nephrectomy, with none of them requiring blood transfusion. There were no access point and no non target embolization complications. Only one patient with large (est. Volume >500 ml) RCC presented with postinfraction syndrome that required extensive analgesia, which completely remised after surgery.

Conclusion

Preoperative Renal Artery Embolization is a safe procedure that decreases blood loss, requires minimal or no transfusions, facilitates larger and more advanced tumor resection, is tolerable by patients and has good surgical outcomes.

PP 118

CAROTID WEB

Oruc Meltem, Garipoglu Cemile, Koc Osman

Department of Radiology, Meram Faculty of Medicine, Necmettin Erbakan University, Konya, Turkey

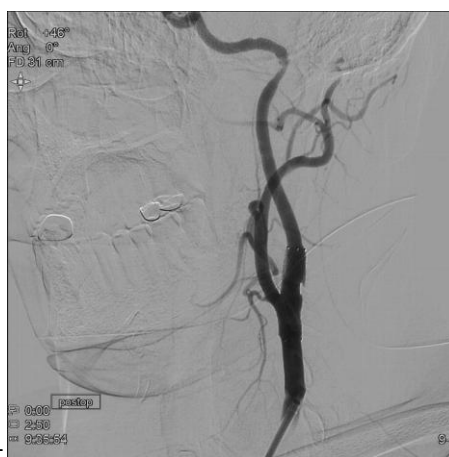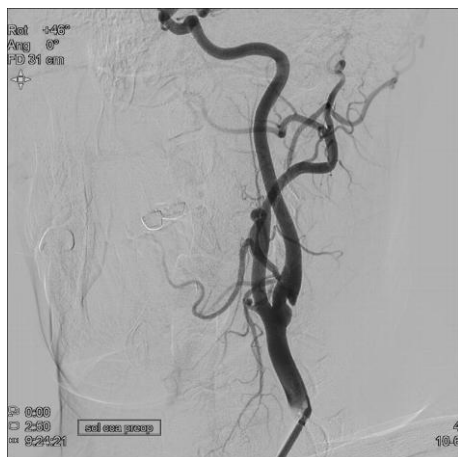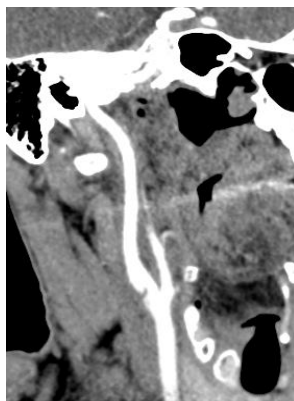
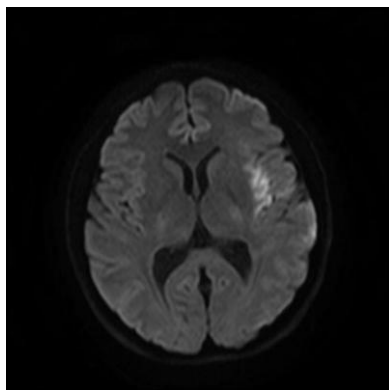
- **Introduction:** Carotid web (CW) is an atypical variant of fibromuscular dysplasia (FMD) located in the internal carotid-bulb. It is a non-inflammatory and nonatherosclerotic disease of the extracranial carotid vasculature. The shelf-like intraluminal protrusion can cause thrombus formation and, as a result, systemic embolism and ischemic strokes can occur in young patients. This intraluminal protrusion commonly affects the posterolateral wall of the proximal





ICA. CW can be managed through carotid endarterectomy, endovascular stenting or conservative medical therapy with antiplatelet or anticoagulant.

- **Purpose:** We report a case to raise awareness of CW in young patients, who have ischemic stroke in MCA territory without any identifiable cause.
- **Materials and Methods:** A 39-year-old male patient was transferred to our facility for left MCA stroke 12 hours after the new onset of aphasia. He was a nonsmoker and nonalcoholic, with no known medical problem. He initially presented to outside facility where diffusion-weighted MRI of the brain revealed acute ischemic infarct involving left MCA territory in the area of left temporoparietal lobe. CTA neck showed a short segment of linear filling defect in proximal left ICA, compatible with a CW. The left MCA was not occluded. Cardiac evaluation was normal. Vasculitis profile was negative. DSA confirmed the presence of a CW in the ipsilateral proximal ICA.
- **Results:** Even though CW can be detected in sonogram or MRI, it's often identified by CTA. DSA is the gold standard test for CW. The patient was treated with dual antiplatelet therapy and carotid stenting. He was discharged from hospital 12 days later.
- **Conclusion:** CW, also known as atypical focal carotid bulb FMD, is an exceedingly rare cause of acute ischemic stroke in young patients. CW is linked with high TIA/stroke recurrence risk regardless of antithrombotic use. Carotid stenting is a safe and effective alternative to surgical resection.





PP 119

ANATOMY AND VARIATIONS OF THE BASILAR ARTERY EXAMINED WITH DIGITAL SUBTRACTION ANGIOGRAPHY

Dodevski A¹, Lazareska M², Aliji V², Stojovska - Jovanovska E², Jakimovska - Dimitrovska M², Kostov M³

¹Institute of Anatomy, Medical Faculty, "Ss. Cyril and Methodius University", Skopje; ²University Clinic of Radiology, Skopje; University Clinic for Neurosurgery, Skopje

Introduction: The basilar artery is formed by the union of the vertebral arteries; it runs over the ventral surface of the pons and terminates at the upper border of the pons by dividing into the posterior cerebral arteries. It gives of many vital branches supplying various parts of the brain. The aim of this study was to determine origin and variations of branches of the basilar artery with DS angiography.

Materials and methods: We examined radiographs of 55 patients who had DS angiography undertaken for a variety of clinical reasons, performed as a part of their medical treatment at the University Clinic for Radiology in Skopje. The study population included 27 male and 28 females, age range from 18-79, mean age 51.09 years.

Results: The AICA originated from the proximal half of the basilar artery in all patients. Most of the SCA arise from the basilar artery as a single vessel (92.7% on right and 94.5% on left). The most common variations of the SCA were duplication (frequency 3.63% on right and 1.81% on left) and origin from PCA (frequency 3.63% bilateral). The PCA was evaluated in all cases. The adult configuration was present in 74.54% of the patients; fetal configuration was present in 20% of the patients and transitional configuration was present in 5.45% of the patients on the left side. On the right side adult configuration was present in 83.63% of the patients; fetal configuration was present in 14.54% of the patients and transitional configuration was present in 1.81% of the patients.

Conclusion: A precise understanding of the basilar artery anatomy is fundamental for planning and performing endovascular procedures and neuro-interventions, as well as for the accurate interpretation of ischemic areas.

Key words: basilar artery, DS angiography, branches





PP 120

BILIARY CYSTADENOMA

Sotiriadou A., Rigkas A., Papaioannou S., Giataganas G.

Radiology Department, General Hospital Papageorgiou, Thessaloniki, Greece

Introduction

Introductal cystic lesions are uncommon findings in abdominal MRI. Most commonly represent choledochal and paracitic cysts. Biliary cystadenomas are rare entities of the biliary tree.

Purpose

Our purpose was to present a biliary cystadenoma in a 66-year-old female patient.

Material and Methods

We present a case of a 66-year-old female patient, who visited our institution in order to have an Magnetic Resonance Imaging (MRI) of the upper abdomen for further investigation of increased abdominal pain and distention during the previous weeks. An ultrasound was performed additionally to the MRI.

Results

Laboratory tests showed elevated liver function enzymes and normal serous neoplastic markers, including carbohydrate antigen 19-9 (CA 19-9).

The MRI examination revealed a large multiloculated cystic lesion in the left bile duct, which was extending to the common and right bile duct, causing biliary distention in the left liver lobe and less in the right liver lobe. The lesion was increased in size compared to the previous examination, with neither solid nor contrast-enhanced components. The common bile duct's diameter was normal.

The ultrasound confirmed the cystic nature of the lesion, the internal septae and the lack of vascularity.

The patient underwent a laparotomy with excision of the cystic lesion. The histological examination confirmed our radiological diagnosis of biliary cystadenoma.

Conclusion

Biliary cystadenomas are rare cystic neoplasms of the liver and frequently occur in the middle-aged women. They are premalignant lesions, characterized by unilocular or multilocular cysts with internal septae and mural nodules. Due to their malignant potential, they should be considered for surgical resection, since they cannot be safely differentiated from cystadenocarcinomas.





PP 121

PREOPERATIVE LOCALIZATION OF OCCULT BREAST LESIONS AND MICROCALCIFICATIONS IN BREAST

Maja Jakimovska-Dimitrovska¹; Elizabeta Stojovska-Jovanovska¹; Ace Dodevski²; Mitko Ilievski¹; Maja Jakimovska³; Tanja Petrovska⁴; Natasha Hadji-Nikolova¹

1. PHI University clinic of Radiology Skopje
2. Institute of Anatomy Skopje
3. CGH 8th September Skopje
4. USC St Naum Ohridski Skopje
- 5.

Introduction: Early detection of occult breast lesion and microcalcifications can reduce mortality of breast carcinoma. The preoperative wire localization of mammographic identified occult breast lesions and microcalcifications is a relatively simple and safe procedure. The wire has been removed at surgery.

Purpose: To present a value of preoperative localization in successful removal of occult breast lesions and microcalcifications.

Materials and methods: A review of locating procedures done for 35 patients during 2017 – May 2019 period. In our institution both symptomatic and asymptomatic patients undergo mammography. The preoperative wire localization was performed only for mammographic identified occult breast lesions and microcalcifications. We used a perforated mammography compression plate and hook wires. The goal of preoperative wire localization is to place the tip of the needle as close to lesion. Local anesthesia is used in the skin and subcutaneous tissue. Our routine mammograms include a craniocaudal view and oblique view. The patient is always seated for the procedure. The specimen was radiographed in all cases.

Results: The study included 35 patients, mean age 52 years. All localizations were performed by radiologists. Surgery was performed by two different surgeons. Reasons for wire localizations were masses (13), calcifications (18) and masses with calcifications (4). Primary malignancy detected in 20 patients, CIS in 5 patients. We were not aware of any infections or other complications that resulted from this procedure in our series. The localization procedure takes approximately 45 minutes.

Conclusion: Preoperative wire localization of breast lesions is an integral component of the early detection of breast carcinoma.





PP 122

MRI OF THE UTERUS IN NON-CONCLUSIVE US

Dimova Julia , Zlatareva Dora, Hadjidekov George, Hadjidekov Vassil

Department of Diagnostic imaging, UMHAT Alexandrovska, Medical University Sofia, Bulgaria

Department of Diagnostic imaging, UMHAT Alexandrovska, Medical University Sofia, Bulgaria

Introduction: Ultrasound (US) is the first choice imaging method in suspected pathology in the female pelvis. Magnetic resonance imaging (MRI) is known to be superior and performed in case of non-conclusive US.

Purpose: The purpose of this review is to share author's observations of unexpected uterus pathology at pelvic MRI in women undergoing non-conclusive US.

Materials and Methods: Fifteen women with untypical complains and unclear US findings underwent MRI examinations. All patients were scanned using 3T MRI (Siemens Verio). The protocol includes T1-weighted and T2-weighted images, Fat sat and Diffusion-weighted images in all three planes plus para-transversal and para-coronal planes of the uterus. Contrast enhancement was performed when required.

Results: In seven out of fifteen women of different age, a uterine pathology was detected. Three of the patients were diagnosed with myoma uteri as in two of them the finding has a non-benign appearance. One of the patients had hysterectomy previously, but a second hypoplastic uterus was found. Benign cystic formations were found in the cervix in another patient. Cervical cancer and endometrial carcinoma were visualized in the remaining two patients.

Conclusion: In case of atypical complaints of gynecological origin and non-conclusive Ultrasound study, MRI remains the method of choice.

PP 123

RIGHT RENAL ARTERY BLEEDING AND PULMONARY EMBOLISM FOLLOWING PERCUTANEOUS NEPHROLITHOTOMY: IMAGING EVALUATION AND MANAGEMENT IN AN UNCOMMON AND LIFE-THREATENING COMPLICATION

Arvaniti M., Daniil G., Kaitartzis C., Nalmpantidou C., Delianidou A., Ouroumidou K.

Radiology Department of General Hospital of Thessaloniki "G. Gennimatas", Greece

Purpose: To present the imaging findings and management in an interesting and uncommon complication of percutaneous nephrolithotomy (PCNL).

Introduction: Renal artery bleeding combined with pulmonary embolism is a rare and potentially lethal combination of post PCNL complications.

Materials and methods: A 56-year-old woman underwent CTA in our Department, due to post PCNL hemodynamic instability. CTA findings obviated subsequent management through angiography. A second thoracic and upper abdominal CTA was performed on the 2nd postoperative day, due to acute respiratory distress, hypoxia and loss of consciousness. Pulmonary embolism was confirmed.

Results: CTA initially performed revealed active hemorrhage of the right renal and a segmental renal arteries. Hemorrhage was managed through angiography, with stenting of the right renal artery and embolization of the segmental right renal artery. On the 2nd postoperative day, thoracic and upper abdominal CTA was performed for suspected pulmonary embolism and to reevaluate renal hemorrhage. CTA confirmed pulmonary embolism, also revealing ongoing hemorrhage of the right renal arteries, despite stenting and embolization. Thrombolysis could not be performed and, on the 3rd postoperative day, the patient died in the ICU, due to hemodynamic instability, hyperpyrexia and multiple organ failure.





Conclusion: Severe and life-threatening post PCNL complications are possible and will occur, due to the increasing prevalence of ourolithiasis and the consequent large number of PCNLs performed. Optimal imaging guidance and treatment is needed, although, in some cases, not enough to save a patient's life.

PP 124

IMAGING INVESTIGATION OF GI TRACT OBSTRUCTION DUE TO EARLY POSTOPERATIVE ADHESIONS IN A 15-MONTH-OLD INFANT

Nalmpantidou C., Katsimba D., Daniil G., Arvaniti M., Kaitartzis C., Vekiou R.

Radiology Department of General Hospital of Thessaloniki "G. Gennimatas", Greece

Introduction: Postsurgical development of adhesions in children is rather rare, with a mean time of occurrence of 1 year post surgery. Several different types of surgery are implicated, with various post-surgery occurrence time and clinical severity.

Purpose: To present the imaging findings in a case of a 15-month-old female infant, with symptoms of GI obstruction 3 months post-surgery for congenital choledochal cyst.

Materials and methods: A 15-month-old female infant presented with jaundice and high conjugated bilirubin. Sonographic evaluation suggested possible choledochal cyst. MRI confirmed the diagnosis and surgery with a choleptic anastomosis was performed. 3 months post-surgery, the infant presented with episodes of vomiting and insufficient nutrition. Further imaging investigation included plain abdominal films, US and fluoroscopic GI tract evaluation.

Results: Plain abdominal films showed distended intestinal loops. US confirmed intestinal distension, with lack of peristalsis and fluid between the distended loops. Upper and lower GI tract fluoroscopy revealed highly distended (>5cm), aperistaltic jejunal loop, with normally appearing colon. Differential diagnosis included internal hernia and adhesions. Surgery confirmed the diagnosis of adhesive obstruction.

Conclusion: Although rare in children, postoperative adhesions should be considered in the differential diagnosis in children presenting with signs and symptoms of GI obstruction, even as early as 3 months post-surgery. Imaging investigation, especially fluoroscopy, plays a major role in determining the cause of obstruction, leading to prompt and proper surgical treatment.

PP 125

SONOGRAPHIC EVALUATION OF PEDIATRIC PAINLESS INGUINAL SWELLING

Papadimitriou A., Daniil G., Katsimba D., Arvaniti M., Vekiou R., Panagasidou L., Eleftheriadou M., Kaitartzis C.

Radiology Department of General Hospital of Thessaloniki "G. Gennimatas", Greece

Introduction: Groin swelling is a relatively common pediatric situation. US evaluation of both inguinal areas is needed, in order to identify possible underlying pathology.

Purpose: To present the spectrum of the sonographic findings in newborns, infants and children evaluated for painless inguinal swelling in our Department.

Materials and methods: we retrospectively studied the sonographic findings in a pediatric population referred to our Department for painless inguinal pain, during a period of 15 years (2003-2018). Ages ranged between 1 month and 15 years. Both inguinal areas were scanned, with a 7-11MHz linear transducer. Color and power Doppler were additionally performed in cases needed.





Results: Underlying pathology was found in 1212 cases. Undescended testis was the most common finding (n=594). In one boy, a supernumerary testis was discovered. Inguinal hernia was present in 303 cases. 198 boys had ascending testis. In 162 boys, hydrocele was the underlying cause. In 29 girls, inguinal ovaries were found. In one case, inguinal uterine and ovary co-existed. Nuck's hydrocele was present in 2 cases. 1 female infant had a cavernous hemangioma. In the rest of the cases, inguinal lymphadenopathy was found, with an equal male:female distribution.

Conclusion: Sonography is the gold standard method for the evaluation of painless pediatric inguinal swelling. Lacking ionizing radiation, sonography provides all the necessary information for the correct diagnosis of possible underlying pathology, leading to prompt and proper treatment and, in many cases, helping to avoid unnecessary surgery.

PP 126

OMENTAL INFARCTION PRESENTING WITH ABDOMINAL PAIN IN A CHILD - IMAGING FINDINGS

Papadimitriou A., Arvaniti M., Daniil G., Torounidis I., Eleftheriadou M., Kaitartzis C.

Radiology Department of General Hospital of Thessaloniki "G. Gennimatas", Greece

Purpose: Omental infarction is a rare cause of abdominal pain in children. We present a case of omental infarction in a child, in order to highlight the imaging findings, especially with abdominal CT.

Materials and methods: An 11-year-old boy presented with left abdominal pain and tenderness. A plain erect abdominal film was obtained, followed by abdominal sonography. Sonographic findings obviated additional CT abdominal evaluation. Abdominal CT was performed, with oral contrast administration, before and after i. v. contrast administration.

Results: Plain abdominal film was normal. Sonographic findings suggested a left abdominal inflammatory lesion. CT was undertaken, revealing a lesion with fat attenuation and surrounding inflammatory changes.

Conclusion: CT findings of omental infarction are characteristic. In cases of suspected omental infarction in children, abdominal CT should be performed, in order to set the correct diagnosis, leading to proper conservative treatment and helping to avoid unnecessary surgery.

PP 127

RARE CASE OF INGUINAL HERNIA CONTAINING AN INFLAMMED EPILOIC APPENDAGE – CT FINDINGS

Papadimitriou A., Arvaniti M., Daniil G., Ouroumidou K., Delianidou A., Kotsidi A.

Radiology Department of General Hospital of Thessaloniki "G. Gennimatas", Greece

Introduction: Epiploic appendagitis within an inguinal hernia is rare. CT is an excellent tool, providing all the necessary information for the correct diagnosis and treatment.

Purpose: To present the CT imaging findings in a rare case of inguinal hernia containing an inflamed epiploic appendage and demonstrate the important role of CT in the diagnosis of this rare pathologic condition.

Materials and methods: An 81-year-old male presented left lower abdominal quadrant pain. A plain erect abdominal film was obtained, followed by abdominal CT, with oral contrast administration, before and after i. v. contrast administration.

Results: Plain abdominal film was normal. Abdominal CT revealed a widened left inguinal canal, containing an oval lesion of fat attenuation, with a peripheral thin hyperdense rim and surrounding inflammatory changes. Surgery confirmed the diagnosis.





Conclusion: CT is an excellent imaging modality for the diagnosis of epiploic appendicitis. It also allows superb anatomic inspection of the inguinal regions. Thus, in the rare case of epiploic appendicitis contained within an inguinal hernia, CT provides all the necessary diagnostic information, leading to proper and prompt treatment.

PP 128

IMAGING OF THE RARE END OF THE SPECTRUM - A RADIOLOGIC - PATHOLOGIC CORRELATION OF THREE RARE INCIDENTALOMAS

Belyanova Magdalena, Dineva Svetla, Ivanova Vesela, Dikov Tihomir, Krupev Martin Department of Diagnostic Imaging, UMHAT Alexandrovska, Medical University Sofia, Sofia, Bulgaria

Introduction: Incidentalomas are a by-product of the more widespread use of sectional methods of imaging. Contrast-enhanced computed tomography (CT) provides a high level of specificity and sensitivity when differentiating between the two most common culprits – adenomas and metastases. At the other end of the spectrum lie rarer entities (such as atypical adenomas, endothelial cysts, and oncocytic adrenocortical neoplasms) whose imaging hallmarks need further elucidation.

Purpose: To find the point of intersection between histologic and radiologic imaging characteristics of these rare entities and allow for better noninvasive diagnostics.

Materials and Methods: We performed a retrospective search of the hospital database and found a total of 66 patients with incidentalomas on CT during the past year. Patients, whose lesions were indeterminate on imaging, were further investigated and their histologic reports were retrieved. A side-by-side comparison of microscopic and imaging features was made. We identified three rare adrenal masses, namely an atypical adenoma, an endothelial cyst and an oncocytic adrenocortical neoplasm, whose imaging characteristics present interest in the light of their rarity.

Results: We present three cases which illustrate the relationship between the imaging findings and the microscopic characteristics of these otherwise indolent incidentalomas.

Conclusion: Familiarity with the imaging characteristics helps radiologists spare patients additional work-up and the associated radiation and stress.





PP 129

A RARE COMPLICATION OF ADVANCED RECTAL CANCER: FISTULA

Troyanova Svetozara

Department of Radiology, MBAL "Sveta Marina", Varna, Bulgaria

Introduction:

Fistula formation is an uncommon complication of rectal cancer which may lead to significant worsening of patients' quality of life. It usually occurs in patients with advanced disease – stages T3 or T4. Fistulous tracts may form as a cosequence of the infiltrating nature of the tumour and the presence of necrosis or as a complication of radiotherapy and surgical treatment. Rectal fistulas have proven to be a diagnostic challenge and multiple imaging modalities are often needed for their detection and characterization.

Purpose:

- to discuss fistula formation as a complication of advanced rectal cancer
- to identify the structures most commonly affected by this complication pre- and post-treatment.
- to review the role of contrast-enhanced computed tomography (CECT) and magnet-resonance tomography (MRT) in the detection and evaluation of pelvic fistulas.

Materials and methods:

Using CECT and MRI for demonstration of different types of fistulas from our practice, that have developed as a complication of advanced rectal cancer – recto-vesical fistula; recto-vaginal fistula; recto-cutaneous fistula; fistula between the rectum and the presacral space; fistula as a result of postoperative abscess formation.

Results:

Both magnetic resonance and computed tomography are excellent imaging tools for asseing the complications such as fistulas. Applying contrast matter into the cavities of pelvis can provide great visualisation of both openings of fistula as well as the affected organs.

Conclusion:

Fistula formation as a complication of rectal cancer have proven to be a diagnostic challenge. CECT and MRI have both shown to be efficient methods for diagnostic assessment of this relatively uncommon complication.





PP 130

DUAL-ENERGY X-RAY ABSORPTIOMETRY AS A FAST, CHEAP, AND EASILY REPRODUCIBLE EVALUATOR OF VISCERAL FAT

Sofiya Chausheva¹, Georgi Valchev^{1,2}, Svetomir Chakarov¹, Summer El Shemeri^{1,2}, Ralitsa Popova³, Boyan Balev^{1,2}

¹ UMHAT "Saint Marina" Varna, Bulgaria

² Medical University of Varna "Prof. D-r Paraskev Stoyanov", Bulgaria

³UMHAT "Heart and Brain Center of Excellence" Pleven, Bulgaria

Introduction: The amount of visceral adipose tissue has been associated with numerous diseases by recent studies. Among these most frequent are the cardiovascular entities and diabetes. For this reason, different non-invasive methods have been employed to accurately quantify visceral fat. Magnetic resonance imaging (MRI) and computed tomography (CT) have both been used for this purpose with success. Semi-automated post processing based either on Hounsfield unit thresholding or fuzzy c-means clustering have led to a substantial reduction in the time necessary to fully evaluate the amount of adipose tissue. Unfortunately, both still require a significant amount of specialized radiologist ov

ersight, as well as often prohibitively expensive proprietary software. Even though accurate, these two modalities may not be the cheapest or fastest methods. To remedy this, we turn our sight to Dual X-Ray Absorptiometry (DXA) as a potential solution.

Purpose: The purpose of this work is to ascertain the value of DXA as a cost-effective, reproducible, and fast method for the evaluation of visceral fat.

Materials and Methods: Based on current literature and in-house experience with a GE Lunar Prodigy DXA device, equipped with relatively cheap additional proprietary software, we have conducted a comparison between the different modalities described above. The scan time in DXA is shorter than in MRI, with the added benefit of relatively little susceptibility to motion artefacts. Additionally, the ionizing dose received by the patient is low, as are the costs for performing the examination. There is no necessity for post-processing of the data obtained from DXA – the finalized information is provided immediately after concluding the scan.

Results and Conclusion: Due to its low cost, its fast and easily reproducible scanning procedure, and its complete automation of data analysis, DXA could rise to be a very useful alternative to CT and MRI in a clinical or research setting.

Keywords: DEXA, visceral fat, diagnostic imaging, fat quantification





PP 131

RETROPERITONEAL LIPOSARCOMA DIAGNOSTIC, TREATMENT, AND MANAGEMENT: CASE REPORT AND LITERATURE REVIEW

Chalcheska Slavica, Kostadinovski Vlatko, Risteski Filip
Skopje, North Macedonia

Retroperitoneal liposarcoma is rare and malignant tumor with incidence of 2 per million individuals. Early diagnosis is difficult by the absence of clinical symptomatology (at the moment of detection the tumor size is over 10cm).

The study analyzed 10 cases which were investigated by ultrasound, CT Scans and MRI, in 3 patients there was a relapse of primary disease, and in 1 patient histopathological modification from liposarcoma in fibrosarcoma.

The mean age of 10 patients was 50-60 years. In management all patients had surgery with complete resection of tumor, in some cases combined resection of adjacent organs (1 patient nephrectomy and adrenalectomy, 1 patient multiple resection of visceral organs)

The present case study is a patient with a retroperitoneal liposarcoma surgically treated complete tumor

resection in 2016, until 2019 we diagnostic recurrence of the primary disease with MRI and CT Scans, treated with 4 complete resection of tumor, combined resection nephrectomy and adrenalectomy, partial hepatic resection, cholecystectomy in a period of 3 years. On the last MRI on 11.06.2019, relapse of the disease was proven mesenterally, in contact of D1 segment of duodenum, with a fibroid component in addition to relapse of primary tumor (fibrosarcoma).

Histopathological analysis of subtypes in 8 cases has been proven as: 4 well-differentiated liposarcoma, 1 dedifferentiated liposarcoma, 3 mixoid liposarcoma.

No patient received chemotherapy or radiation therapy.

Conclusion:

Retroperitoneal sarcoma is a rare malignant tumor with a high incidence of recurrence, and sometimes

histopathological modification.

The basic therapeutic procedure is surgically complete resection of tumor and combined resection of the adjacent organs is also required.





PP 132

CORONARY VARIANTS. THREE CASES REPORT AND REVIEW OF THE LITERATURE

Fagkrezos Dimitris, Masouris George, Tsipra Evaggelia, Alousi Maria, Triantopoulou Charikleia, Maniatis Petros
Konstantopouleio General Hospital Neas Ionias, Athens , Greece

INTRODUCTION

Congenital coronary anomalies are rare and reported to occur in 0.64–1.3% of patients undergoing coronary angiography. Coronary anomalies involving their origin, course and distribution are common with right coronary artery (RCA) circulation but rare with the LAD artery.

Purpose

The variants of the coronary arteries are important in interpretation of coronary angiogram and in interventional procedures. Our aim is to interpret three cases of coronary variants that were studied in our department, as these could be related with serious complications (e.g., myocardial ischemia and sudden cardiac death).

Material and methods

The angiographic data of three cases from three adult patients undergoing 64 slice-MDCT coronary angiography were analyzed retrospectively for identification of anomalous coronary anatomy. The protocol of the study was prospectively electrocardiogram-triggered cardiac CT after rapid intravenous administration at high rate 5ml/s and high density (40%) contrast medium, followed by scanning at optimal opacification. Beta blockers were given typically for heart rate control.

Results

We describe an anomalous origin of the right coronary artery, an absence of the left coronary stem and Dual left Anterior Descending coronary artery. The anomalous origin of the right coronary artery is a rare congenital cardiac malformation. Most patients remain asymptomatic. However, there are cases of sudden cardiac death described in the literature, indicating a potentially malignant course of the disease. The relative absence of the left coronary stem and also dual left anterior descending coronary artery were perfectly evidenced by CT coronary angiography.

Conclusion

When a coronary artery anomaly is found, the exact origin, course and its relationship with other cardiac structures must be described in detail. Coronary CT is currently regarded as the diagnostic standard for the identification and visualization of CAAs. Coronary artery CT offers the best performance in terms of spatial resolution, acquisition time and image contrast.

PP 133

SIMULTANEOUS BILATERAL CAROTID STENTING IN HIGH-RISK PATIENTS

Tzortzis D, Anastasiadou C, Kaperonis E.A., Katsantouris G, Makris N, Papavassileiou V.G., Maltezos C, Zannes N
Kat Hospital Athens, Greece

Introduction: The purpose of our retrospective study is to investigate the efficacy, safety and economics of *simultaneous treatment of bilateral carotid artery disease* (BICAS) compared to unilateral or staged treatment (ST).

Materials/Methods: Between January 2007 and December 2018, we have treated 759 carotid arteries in 662 high-risk patients. Inclusion criteria were symptomatic carotid stenosis > 50%, asymptomatic carotid stenosis > 70%. 97 of them had bilateral carotid artery disease. 58 patients were treated





simultaneously while the rest of them were stented in two different sessions at least a month apart, the symptomatic lesion treated first. The exclusion criteria for BICAS were chronic renal insufficiency in predialysis state and unfavorable aortic arch anatomy. Data were reviewed for stroke risk factors, complications including hyperperfusion syndrome (HPS) and hemodynamic depression (HD), stroke, death, restenosis rate and cost of the intervention.

Results: The stroke, death and restenosis rate at 6 months showed no statistically significant difference between the groups. HPS occurred in 17,2% (10/58) at BICAS group while in only 3,6% (24/662) at unilateral or ST group. HD was more common in BICAS group 10,3% (6/58) compared to 6,9% (46/662) in the other group. BICAS also proved to be cost-effective when compared to the average cost of staged carotid stenting.

Conclusions: BICAS results in higher HPS rate, but without clinical sequelae, and with lower cost compared to bilateral staged treatment. BICAS is a safe option even in patients with high-risk factors and can be considered as the therapeutic option in patients with significant bilateral carotid artery disease.

PP 135

HEMANGIOMA OF THE CUBITAL TUNNEL: A RARE CAUSE OF ULNAR NEUROPATHY

Norman Loberant (1), Hector Isaac Cohen (2),

1. Department of Radiology, Galilee Medical Center, Nahariya, Israel
2. Department of Pathology, Galilee Medical Center, Nahariya, Israel

Purpose: To describe a case of ulnar neuropathy resulting from a rare benign tumor of the cubital tunnel.

Materials and Methods (Case report): A 66 year old male presented with left cubital tunnel syndrome for several weeks duration with numbness and dysesthesia of the fourth and fifth fingers, and incipient hand weakness. On examination there was a palpable mass in the cubital tunnel.

Ultrasound examination showed a well-defined hypoechoic sub-centimeter mass in the cubital tunnel adjacent to the ulnar nerve. Magnetic resonance images confirmed the mass, hypointense on T1W images, and showing central hypointensity and peripheral hyperintensity on PDFS images.

Two weeks later the patient underwent surgery. Upon unroofing the cubital tunnel, a dark purple mass extruded forcefully from the incision, consistent with increased pressure within the cubital tunnel. The mass was partly adhered to the ulnar nerve, and was dissected from it.

Results: Pathology showed a thrombosed vein surrounded by numerous blood vessels, some of which consisted of elongated cells, with no atypia or mitoses, and a significant amount of hemosiderin.

Pathological diagnosis was spindle cell type hemangioma.

Conclusion: Cubital tunnel syndrome is second only to carpal tunnel syndrome as the most common peripheral nerve entrapment syndrome. Most often cubital tunnel syndrome is caused by repetitive occupational trauma leading to a combination of compression, traction and friction within the canal. Rarely, cubital tunnel syndrome may result from a mass lesion. Case reports have documented ganglion, lipoma, metastasis, and hemangioma within the tunnel. The presence of a mass lesion is an indication for surgery.



**PP 137****THE ROLE OF MRI IN DIAGNOSIS OF FOCAL CORTICAL DYSPLASIA IN PATIENT WITH HEADACHE CASE REPORT**

Jovanka Pisarevic-Neskovic, Biljana Georgievski Brkic
Stroke Hospital "Sveti Sava" Radiology Belgrade, Serbia

INTRODUCTION: Headache is one of the most common disorder of the nervous system. Some studies reporting cortical thickness differences in migraine sufferers as a cause or the consequence of migraine. Cortical dysplasia is the leading disease in the group of disease called neuronal migration disorders. These anatomical changes include an increased number and/or density of neuronal and/or glial cells in certain parts of the cortex which render the cortex more excitable. On the other hand, if cortical thickness is a consequence of migraine it could be result from plastic reaction due to repetitive pain processing or could be consequence of the reactive gliosis that often follows brain pathologies.

PURPOSE: The presentation of this case aims to stress if there is any coincidental association between cortical dysplasia and headache.

MATERIAL AND METHODS: A 53-year-old women was sent with symptom of headache to Radiology Department. Brain MRI with contrast agent and cerebral MR angiography were performed. The neurologic deficit was not identified. The blood laboratory tests were within normal limits. Routine EEG was normal.

RESULTS: MR of brain showed subcortical hyperintensity on T2W/FLAIR sequences in the white matter of the left fronto-basal region. The lesion measured 10mm and did not show contrast enhancement. MRI protocols involved thin slice thickness, high resolution, coronal T2WFRFSE and 3DT1W sequences which approved focal cortical dysplasia. There was no restricted diffusion in DWI/ADC sequences. Surrounding brain parenchyma did not reveal any perifocal edema. 3D TOF angiography was normal.

CONCLUSION: Cortical dysplasia is a frequent cause of epilepsy, but also could be associated with headache. The role of MRI with inversion recovery sequences has important role in diagnosis of cortical dysplasia.

PP 138**FOUR- VESSEL PRINCIPLE CERVICOCRANIAL DISSECTIONS AFTER STATUS EPILEPTICUS**

Jasmina Colic, Biljana Georgievski-Brkic, Veljko Maksić
Stroke Hospital „Sveti Sava“ Radiology Belgrade-Serbia

INTRODUCTION: Cervicocranial artery dissection (CCAD) is one of the most important causes of stroke. Arterial dissection occurs when blood enters the media through a tear or ulcer in the intima and tracks along the media, forming a second blood-filled channel within the wall. CCAD can involve a carotid (ICA) or vertebral artery (VA). Cases with involvement of more than two arteries are rare.

Simultaneous dissections of the four principal vessels is extremely rare (01% all dissections)

PURPOSE: CCAD can occur as a result of minor trauma (from hyperextension of the neck during status epilepticus).

MATERIAL AND METHODS: A 60 - year-old men with the symptom of status epilepticus and dysphasia admitted to Stroke Hospital. He had history of longtime epilepsy, hypertension, diabetes mellitus.





Neurological examination, complete laboratory tests, brain CT with CT angiography of neck and head were performed.

RESULTS: CT brain showed ischemic subacute strokes in left temporooccipital region and in right occipitoparietal region, with postcontrast gyral enhancement and multiple acute lacunar infarcts frontoparietal bilateral in white matter. CT angiography showed four principle vessels dissections: right ICA with multicentric stenosis in intracranial segment, 50-80%, as „string sign“ in long cervicocranial segment, occlusion left ICA 18mm from bifurcation, and left VA in the cervicocranial segment with typical dissection flame-like shape in cervical region. Right VA was with luminal narrowing in extracranial segment, with multicentric significant stenosis in V3 and with intracranial occlusion.

CONCLUSION: Minor trauma during status epilepticus could result in CCAD. CT imaging with bilateral acute watershed infarcts and carefully analyzing CT angiography without any calcifications and atherosclerotic signs of vessels, without bifurcations stenosis and occlusion, but with flame like shape occlusion and string signs stenosis could suggests CCAD.

PP 139

PARASPINAL PRIMITIVE NEUROECTODERMAL TUMOR/EWING'S SARCOMA: A CASE REPORT

Eliza Stavride¹, Ioannis Tsitouridis¹

¹Department of Radiology, Papageorgiou General Hospital, Thessaloniki, Greece

Introduction

Primary spinal primitive neuroectodermal tumors (PNET)/spinal extraskeletal Ewing's sarcoma family tumors (ESET) are rare lesions arising from the extradural space of the spine. Ewing's sarcoma is the second most frequent malignant bone tumor of childhood after osteosarcoma. It typically occurs in the 2nd decade of life and has a slight male predilection. PNET/Ewing's sarcoma usually presents as a lesion in the diaphysis of the long bones with large soft tissue component and typical onion skin periostitis. The thoracic Ewing's sarcoma is a rare entity, since only few cases have been reported in the literature.

Purpose

To present the radiological appearance in correlation to the clinical findings of a paraspinal PNET/Ewing's sarcoma extending into the thoracic spinal cord and the posterior thoracic cavity.

Materials & Methods

A 11-year-old female presented in the Paediatric Department of our hospital complaining of motor paraparesis, urinary incontinence and sensory loss for the last 12 hours. Her workup included neurological examination, plain radiograph, computed tomography scan (CT) and magnetic resonance imaging (MRI).

Results

Neurological examination revealed decreased muscle power, loss of sensation below the T6-T7 vertebral level and increased lower limb reflexes. CT revealed a paraspinal lesion extending from T4-T5 to T7-T7 intravertebral disc level. MRI showed a well defined mass arising from the paravertebral region and extending in the spinal canal and the posterior part of the thoracic cavity. The mass was hypointense on T1-weighted images, hyperintense on T2-weighted images and showed heterogeneous enhancement on gadolinium-enhanced images. The surgical biopsy confirmed the diagnosis of Ewing's sarcoma/PNET. The subtotal tumor removal was followed by adjuvant chemo-radiation.

Conclusion

Paraspinal Ewing's sarcoma/PNET is extremely rare and its prompt diagnosis is associated with the best clinical outcome.

The authors declare that there is no conflict of interest.





PP 140

IATROGENIC SPLENIC RUPTURE AFTER SPLENIC ABSCESS TREATMENT AND PERISPLENIC HEMATOMA PROGRESSION

Aydin hasan , Saygili Diba, Akyol , Muazzez Bengi

Health Sciences University Ankara Oncology Research hospital Radiology Department, Ankara Turkey

A 64 year old woman was admitted to emergency unit due to flank left upper abdominal pain. She had worse tenderness on traube and on perisplenic area.

In the IV-contrast enhanced Abdominal CT, 13x7.5x5 cm uniloculated well-lined fluid loculation was observed inside the spleen, subcapsular and parenchymal. We believed that this was a splenic abscess and advised Splenectomy to the General Surgery as a consultation, but however they decided to drain the fluid percutaneously and our Non-vascular intervention unit performed the percutaneous abscess drainage with catheterization.

She got worse during in-patient care and a new Abdominal CT was obtained after 3-4 days later. The spleen was shrinkaged and a wide ruptured area was discovered in the lower lateral pole. A huge perisplenic hematoma and fluid loculation was observed beneath the hilum of the spleen, ascites in the abdomen mostly beyond the parahepatic area was visualized. Bilateral massive pleural effusion with lower lung atelectasis, were also shown in the Thorax CT.

A new percutaneous drainage was performed against the perisplenic hematoma with catheterization and this new interventional procedure got succeeded with total cure and she got all-right during follow-up.

Splenectomy will be performed about 2-4 weeks later.

Figure 1

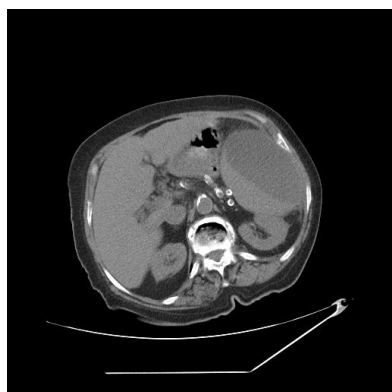
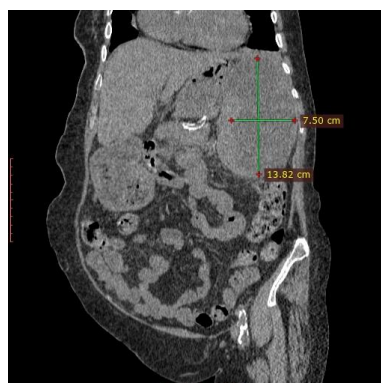

Figure 2





PP 141

ADENOMYOSIS EXTERNA IN THE RIGHT INGUINAL RECESS

Aydin Hasan, Degirmencioglu Ozlem, Kaymak Sumeyye Duran, Akyol Muazzez Bengi, Ankara Turkey
Health Sciences University Ankara Oncology Research hospital Radiology Department

A 29 year old woman was referred to Pelvic CT from Gynecology due to a soft mass in the right lower quadrant and right inguinal area.

In the IV-contrast enhanced CT; A well-lined nodule about 3 cm mass was visualized in the subcutaneous inguinal region of the right lower quadrant, it was closely related and sectioned with the broad ligament of the uterus, had the same density and similar appearance with the uterine myometrium, Uterus was slightly deviated to the right side.

Both adnexes were patent and both ovaries had the normal size. No more suspicious mass or LAP was observed in the pelvic region.

Adenomyosis was considered at first for the differential diagnosis and adenomyosis externa was confirmed histopathologically after surgery.

Figure 1

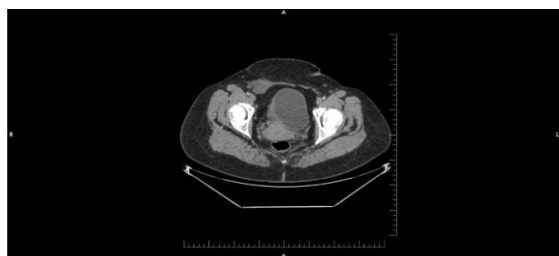


Figure 2

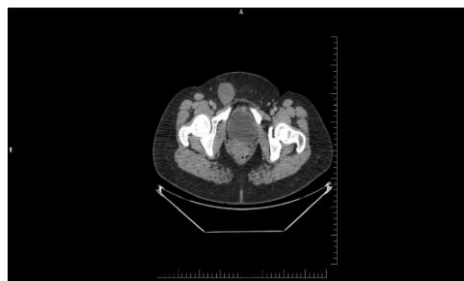

Figure 3

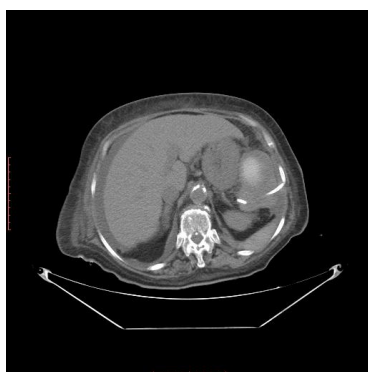
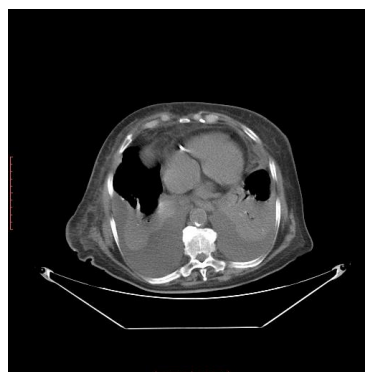
Figure 4





PP 142

MULTIPLE METASTATIC MASSES OF UTERINE LEIOMYOSARCOMA

Aydin Hasan, Degirmencioglu Ozlem, Akyol Muazez Bengi, Tanisman Ozge
Health Sciences University Ankara Oncology Research hospital Radiology Department Ankara Turkey

A 41 year old woman with Abdominal Hysterectomy and bilateral salpingo-oophorectomy (TAH+BSO) due to Uterine Leiomyosarcoma (LMS), was referred to Abdominal CT from Medical Oncology.

In the IV and Oral-contrast enhanced CT; Multiple nix masses were observed in the abdomen, in the pelvic TAH+BSO region-in the right upper and lower quadrant-infraumbilical area midline and left parailiac regions. Masses were almost between 5-15 cm in sizes with central hypodense necrotic areas. They were iso-hyperdense in appearance. She had also metastatic lung nodules with pleural invasions.

After biopsy, these masses were confirmed to be LMS metastasis histopathologically. She was under chemoradiotherapy for cure.

Figure 1

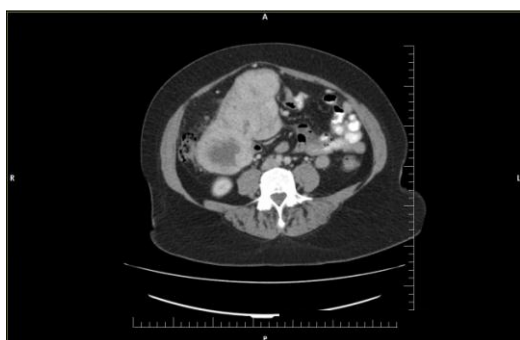
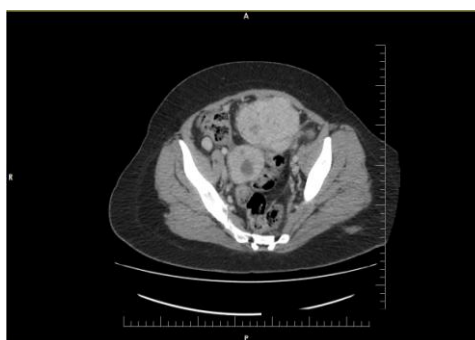
Figure 2



PP 143

COMPARISON BETWEEN CLEFT SIDE AND NON-CLEFT SIDE

T. Petkova, N. Sirakov, P. Kanazirska, I. Angelova, B. Petrova, G. Iordanov
Department Of Imaging Diagnostics, Dental Allergology And Physiotherapy
Faculty Of Dental Medicine, Medical University – Plovdiv

Introduction: Cleft lip and palate (CLP) are relatively common. In 80% of cases they are non-syndromic isolated forms. The clefts of the lip that may affect the alveolar ridge and the premaxilla are formed when the confluence of nasomedial and maxillary process is obstructed. According to another mechanism, it is not only about stopping migration to the center of the face, but the absence and death of cells that obstruct this merger. For complete diagnosis and treatment plan of great importance is cone beam computer tomography (CBCT).





Aim: To investigate the diagnostic possibilities of CBCT in patients with CLP and to compare the side with cleft and the side without.

Material and methods: We present patients with CLP. The study was done with Planmeca Pro Max 3D – 90 kV, 14 mA.

Results: Using CBCT plays a major role in examination patients with CLP.

Conclusion: Unlike orthopantomography (OPG) and Simpson's X-ray, a three dimensional image is obtained using CBCT, which provides precise information about the anomaly and opportunity for more accurate measurements. CBCT provides accurate diagnosis and planning one good treatment in patients with CLP.

Key words: CLP, CBCT

PP 144

THE ADVANTAGE OF CT IN THE DIAGNOSTIC APPROACH OF PNEUMATOSIS CYSTOIDES INTESTINALIS

Sirakov N., Angelova I., Zdravkova T.

Department of Imaging Diagnostics, Medical University – Plovdiv, Bulgaria

Introduction

Pneumatosis cystoides intestinalis (PCI) is a rare condition that can be found as accidental finding or as a complication to other conditions.

Purpose,

The purpose of our study is to present the advantages of the CT in cases of PCI in the early diagnose of this condition.

Materials and methods

We present patients with PCI successfully diagnosed with image diagnostic methods

Results

The characteristic symptoms and features of this disease are presented and the presence of PCI is shown using CT imaging techniques

Conclusion.

The advantages of the CT diagnosis of the PCI is presented in different aspects of the accompanying diseases or conditions.

Key words: Pneumatosis cystoides intestinalis, CT

PP 145

CT GUIDED RFA FOR THE TREATMENT OF LIVER METASTASES ORIGINATING FROM NSCLC

Thanou Ioanna, Tavernaraki Kyriaki, Aspasia Patheodoropoulou, Filippoussis Petros, Arapostathi Styliani, Sidiropoulou Nektaria, Thanos Loukas

Imaging and Interventional Radiology Department, Sotiria General Hospital, Athens, Greece

Introduction: Oligometastatic NSCLC refers to patients with metastases limited in number and organ site(s). These patients have better prognosis compared to those with extensive metastatic disease and





in addition they may benefit from local treatments, such as imaging guided ablation techniques. For liver metastases in particular, CT guided RFA is a local therapeutic treatment which in selected patients may prove effective for local tumor control.

Purpose: To evaluate the safety and efficacy of CT guided RFA in the management of oligometastatic liver disease originating from lung cancer (NSCLC).

Materials and Methods: 40 patients (28 male and 12 female, age range 42-75 years old) with history of NSCLC and 61 liver metastases were treated with CT guided RFA. The majority of liver metastases was single, while the size of the lesions ranged from 2-4cm. Patient selection was based on the size, location and number of lesions as well as the performance status of the patients and the prognosis of the disease. The efficacy of thermal ablation was evaluated by post ablation imaging with CT performed immediately after the procedure and in 1,3,6,9,12 months after.

Results: Technical success rate of RFA was 100%. No major complications occurred. A small subcapsular liver hematoma was observed in one patient, with no further interventions required, and mild post ablation syndrome occurred in 10 patients. Local recurrence was observed in 5 patients (8.2%) in the 6month follow up and in 2 patients (3.3%) in the annual follow up. In these cases subsequent successful RFA was performed.

Conclusion: CT guided RFA is a safe and effective local treatment for the management of liver metastases originating from NSCLC. As a minimally invasive technique, RFA in selected patients with oligometastatic NSCLC is a promising method of local treatment.

PP 146

CASE STUDY: RIGHT AORTIC ARCH ANOMALY (RAAA) AND KOMMERELL'S DIVERTICULUM MAY ASSOCIATED WITH CONSISTENT DYSPHAGIA AND MALNUTRITION

Ibrahim Altindas, Nusret Seher, Mustafa Koplay
 Selcuk university, Faculty of medicine, Department of Radiology

INTRODUCTION

Right-sided aortic arch (RSAA) is a rare congenital abnormality of the aorta. % 50 percent of right-sided aortic arch cases presents with vascular aneurysmatic dilatation (named as Kommerell's diverticulum) where aberrant left subclavian artery begins from.

PURPOSE

The aim of the study was to show that multiple anomalies may cause same symptom in a patient with multiple anomalies.

MATERIALS AND METHODS

This case reports investigated a patient retrospectively from the Selcuk University Enlil patient medical history software and PACS imaging software. Literature was scanned from pubmed for the review of main features of RAAA

RESULTS





4 years old male patient have had various symptoms such as cough, dysphagia and diagnosed many anomalies such as ventricular septal defect, patent ductus arteriosus, proximal esophageal atresia and distal tracheoesophageal fistula. Patient operated one time for esophageal atresia and fistula and many times received esophageal dilatation with bougie for the reason of esophageal obstruction and malnutrition during his childhood. Then cardiac CT angiography planned by Cardiology to see aortic arch structure when there was abnormal descending aorta pressure gradient on routine echocardiography. CT image showed RSAA with Kommerell' s diverticulum and the esophagus were deviated to the right and proximal esophagus was obstructed due to RSAA compression effect. Three main arteries and one aberrant artery which is right and left common carotid artery, right subclavian artery and aberrant left subclavian artery was arising from right-sided aorta respectively.

CONCLUSION

Edwards classification, right-sided aortic arch can be of three types and this patient was type-2.

Symptoms usually starts at forty ages because of the atherosclerosis process of diverticulum. Esophageal or tracheal obstruction can be seen. Presentation in childhood can often be with airway symptoms whereas dysphagia and chest discomfort can be more common in the adult presentation. Various congenital cardiac anomalies are seen to be associated with aortic arch anomalies (present in 5% to 10% of type -2).

PP 147

PIGMENTED VILLONODULAR SYNOVITIS (PVNS) OF THE LEFT KNEE IN A 20-MONTHS-OLD CHILD

Theodorou Marianna, Rigkas Athanasios, Sotiriadou Amalia, Theodorakopoulos Antonios, Bintoudi Antonia.

Radiology Department/General Hospital Papageorgiou/Thessaloniki/Greece

Introduction

Pigmented Villonodular synovitis (PVNS) is an uncommon, benign, proliferative process which is even rarer in infants and young children. Two types are described, diffuse and local type.

Purpose

The purpose of our study is to present a case of 20-months-old infant with an interarticular soft tissue mass. The mass was in the supra-patellar area.

Material/methods

A 20-months-old boy presented at ultrasound department for palpable, painless, soft tissue mass of his left knee. Soft tissue mass was gradually increased in size, in the last few weeks. No skin color changes was noticed. Blood exams were negative for rheumatoid arthritis and septic procedure. A gray-scale and Power Doppler US exam was performed.

Results

Intra-articular, isoechoic, synovial thickening within the supra-patellar and lateral bursa identified. Synovium had characteristic nodular and villous configuration. On Power Doppler examination mild hyperemia of the thickened synovium noted. No obvious bone involvement. Considering negative





rheumatological exams and appearance a diagnosis of PVNS was proposed. Parents refused further evaluation. Arthroscopic incision was considered but was also refused due to child's age.

Conclusion

Although PVNS is much more frequent in adults, in rare cases could be presented in children and infants such as in our case.

Radiologists should be aware of the respective pathology

PP 148 (NO ABSTRACT RECEIVED)

MACRODYSTROPHIA LIPOMATOSA WITH INCIDENTALLY FOUND CHONDROBLASTOMA

DR. Diba Saygılı, DR. Özge Tanişman, DR. Zeynel Yoloğlu

Ankara Oncology Training And Research Hospital, Turkey

PP 149 (NO ABSTRACT RECEIVED)

A RARE POLYSPLENIA CASE: WITH MULTIPLE ANATOMIC VARIATIONS

Dr. Diba Saygılı, Dr. Özge Tanişman, Dr. Özlem Demircioğlu, Dr. Hasan Aydın

Ankara Oncology Training And Research Hospital, Turkey

PP 150 (NO ABSTRACT RECEIVED)

AXILLARY SCHWANNOMA

Özge Tanişman, Diba Saygılı, Almila Coşkun Bilge, Işıl Esen Bostancı, Hale Aydın

Ankara Oncology Training And Research Hospital, Turkey

PP 151

LARGE HIATAL HERNIA WITH FLOPPY FUNDUS - RADIOGRAPHIC FINDINGS

F. Dimitrouli, P. Ambatzis, A. Parlamenti, A. Matzorou, I. Kalogeropoulos

Radiology Department. Evangelismos Hospital. Athens, Greece

Introduction: Patients with large hiatal hernias can develop a floppy fundus, which has a characteristic appearance on barium studies because it droops inferiorly beneath the most superior portion of the herniated gastric body. This phenomenon is relatively common, especially on older persons with large hiatal hernias. Distortion of the gastric anatomy in these individuals can cause mechanical symptoms that usually resolve after surgical repair of the hernia. It is important to establish the diagnosis of a floppy fundus in patients with large hiatal hernias so that appropriate therapy can be instituted.

Purpose: To present imaging findings on barium studies in order to confirm the diagnosis of floppy fundus in patients with large hiatal hernias.

Radiographic studies: Barium studies (esophagography) is the best way to show a hiatal hernia with or without floppy fundus. Floppy fundus is seen as the herniated fundus droops inferiorly as it fills with barium, so that it is located well beneath the most superior portion of the herniated gastric body. The floppy portion of the stomach can be in a posterior or, less more, in an inferior location. Delayed emptying of the hernia was found on barium studies in patients with a floppy fundus.

Conclusion: Radiologists should be aware of the findings associated with a floppy fundus on barium studies and of the potential role of surgery in the treatment of symptomatic patients with this condition.





PP 152

THE ROLE OF RADIOLOGY IN THE INVESTIGATION OF MECKEL DIVERTICULUM

F. Dimitrouli, P. Ambatzis, A. Parlamenti, A. Matzorou, I. Kalogeropoulos
 Radiology Department. Evangelismos Hospital. Athens, Greece

MECKEL DIVERTICULUM

Introduction: Meckel diverticulum is the most common congenital anomaly of the gastrointestinal tract, occurring in 2%–3% of the population. It results from improper closure and absorption of the omphalomesenteric duct. The point of attachment of a Meckel's diverticulum to the bowel varies. Most (75%) Meckel's diverticula are found within 100 cm of the ileocecal valve. The formation of Meckel diverticulum occurs with equal frequency in both sexes. Heterotopic gastric and pancreatic mucosa are frequently found histologically within the diverticula of symptomatic patients. The most common complications are hemorrhage from peptic ulceration, small intestinal obstruction, and diverticulitis.

Purpose: To present imaging findings on barium studies and computed tomography in order to confirm the diagnosis.

Materials and methods: Barium studies (enteroclysis) is the best way to show Meckel diverticulum. It is identified as a saccular, blind-ending structure located on the antimesenteric border of the ileum. The antimesenteric location can be confirmed from the position of the diverticulum, which faces away from the axis of the root of the small intestinal mesentery. The junction of the diverticulum with the ileum may show a mucosal triangular plateau or triradiate fold pattern, which represents the site of omphalomesenteric duct attachment to the ileum. Meckel diverticulum is usually found in the right lower quadrant and pelvic region, but it may have a periumbilical location. Filling defects within the diverticulum may represent enteroliths, fecoliths, or foreign bodies. On CT Meckel's diverticulum is difficult to distinguish from normal small bowel in uncomplicated cases. However, a blind-ending fluid or gas-filled structure in continuity with small bowel may be seen. CT may also show enteroliths, intussusception, diverticulitis, and small bowel obstruction.

Conclusion: While CT findings may be helpful to suspect the presence of Meckel diverticulum, barium studies (enteroclysis) is the procedure of choice to confirm the diagnosis.

PP 153

PROGRESSIVE RADIOGRAPHIC FINDINGS OF CAUSTIC ESOPHAGITIS

F. Dimitrouli, P. Ambatzis, A. Parlamenti, A. Matzorou, I. Kalogeropoulos
 Radiology Department Evangelismos Hospital. Athens, Greece

Introduction: Caustic esophagitis caused by ingestion of caustic substances which cause tissue destruction through liquefaction or coagulation reactions. The intensity of destruction depends on the type, concentration, length of time of tissue contact, pH of the agent and amount of the substance ingested.

Purpose: To analyse the complications in patients who ingested caustic substances and correlate them with the amount of caustic soda ingested.

Material and Methods: A total of 239 patients who ingested caustic soda. The amount of granulated caustic substance ingested was measured as tablespoonfuls and the following complications were





analyzed: esophagitis, esophageal stenosis and progression to cancer, fistulas, perforations, stomach lesions, brain abscesses, and death. Stenosis was classified as mild, moderate or severe according to the radiological findings.

RESULTS: We observed an 89.3% incidence of esophagitis; 72.6% of the cases involved progression to stenosis and 1% died during the acute phase. Stenosis was mild in 17.6% of cases, moderate in 59.3% and severe in 23%. The incidence of stenosis was 80.8% in women and 62.5% in men. The incidence of stenosis was 46.9% in the group that ingested "fragments" and 93.6% in the group that ingested one or more tablespoonfuls of caustic substances. Among subjects who ingested one or more tablespoonfuls, 32.2% developed lesions of the stomach-duodenum, whereas the ingestion of "fragments" was not sufficient to induce these lesions. There was no correlation between the intensity of lesions of the esophagus and of the stomach. Progression to cancer of the esophagus occurred in 1.8% of cases, death during the chronic phase in 1.4%, perforations in 4.6%, fistulas in 0.9%, and brain abscesses in 1.4%.

CONCLUSIONS: The complications were related to the amount of caustic soda ingested. Small amounts caused esophagitis or stenosis while large amounts increased the risk of fistulas, perforations and death.

PP 154

THE ROLE OF RADIOLOGY IN THE INVESTIGATION OF GASTROINTESTINAL STROMAL TUMORS (GIST) OF THE GI TRACT

F. Dimitrouli, P. Ambatzis, A. Parlamenti, A. Matzorou, I. Kalogeropoulos
 Radiology Department. Evangelismos Hospital. Athens, Greece

Introduction: Gastrointestinal tumors (GISTs) account for 90% of mesenchymal tumors in the gastrointestinal tract and 2%–3% of all gastric malignancies. In the stomach, the body is the most common site, followed by the fundus and then the antrum. Clinical manifestations of GISTs depend on their size and location. Patients present with atypical symptoms (hemorrhage, nausea, vomiting, weight loss, abdominal pain etc). Although definitive diagnosis is established by biopsy, barium studies, ultrasound (US), computed tomography (CT) and magnetic resonance (MR) are very helpful during diagnostic work up.

Purpose: To present imaging findings on plain radiographs, barium studies, US, CT and MR from patients with a biopsy-confirmed diagnosis of GIST.

Materials and Methods: Retrospective review of imaging examinations from 28 patients diagnosed with GIST. All patients presented to the emergency department complaining of nausea, vomiting, melena, abdominal distention and pain. They were subjected to clinical, laboratory and imaging investigation, including radiographs, barium study, US, CT or MR.

Results: Barium studies revealed smooth intramural or submucosal mass in all patients. One case was confined to the mid third of the oesophagus, 4 were located in the gastric fundus, 18 in the body, 4 in the antrum and 1 in the caecum. Tumour size ranged from 4 to 14 cm. Bull's eye sign was depicted in 9 cases, suggesting overlying mucosal ulceration. Fistula formation was seen in 1 case, suggesting malignancy. CT revealed soft tissue masses, occasionally with hypodense centers or homogeneous enhancement. Often the tumour bulk was in an extragastric location. Liver metastases and peritoneal spread were noted in 3 patients. All findings were confirmed by MRI. Immunohistochemical tests were positive for c-KIT protein expression in all cases.

Conclusion: Clinical suspicion and identification of GIST findings on simple imaging procedures facilitates referral to further imaging and eventual diagnosis.





PP 155

SCIRRHIOUS GASTRIC CARCINOMA

F. Dimitrouli, P. Ambatzis, A. Parlamenti, A. Matzorou, I. Kalogeropoulos
 Radiology Department Evangelismos Hospital Athens, Greece

Introduction: Scirrhou gastric carcinoma is a diffuse infiltrative adenocarcinoma, predominantly poorly differentiated. In general, tumor cells are predominantly in the submucosa, separated by large areas of abundant connective tissue, making the diagnosis with biopsies challenging. Negative findings at endoscopic biopsy or brushing, delay diagnosis and treatment. Upper GI series can be more accurate than endoscopy.

Purpose: To describe and illustrate the radiological findings of scirrhou gastric carcinoma.

Material and Methods: Barium upper gastrointestinal series (UGIS) in localized scirrhou tumor shows circumferential annular thickening of the affected area with shelf-like proximal borders. If tumor spares the mucosa area, smooth contours can be seen. However, mucosal irregularities, fold thickening or effacement, ulceration, and mucosal nodularity are common. If advanced, it may cause gastric outlet obstruction. With linitis plastica, there is a "leather bottle" appearance of the stomach with irregular narrowing and rigidity. Computed tomography shows markedly enhancing thickened wall. CT is important for the evaluating for peritoneal metastases, hematogenous metastases (liver, lung, bone), or lymphatic spread to perigastric nodes.

Conclusion: In some patients, the upper gastrointestinal series may be more accurate in the diagnosis of scirrhou gastric carcinoma than endoscopy.

PP 156

DIVERTICULITIS, STAGING WITH CT AND TREATMENT

Riga Nikoletta, Nikolentzou Eleni, Stathopoulos Panagiotis, Haralampous Hristofis, Skiada Christina, Spiliopoulou Eustathia, Kolovou Antonia, Mylona Sofia
 Hellenic Red Cross General Hospital Athens, Greece

INTRODUCTION: Diverticular disease is one of the most prevalent diseases in the Western world, the incidence of which increases with age. Colonic diverticula are small outpouchings from the colonic lumen owing to mucosal herniation through the colonic wall at sites of vascular perforation.

Diverticulitis is a common complication of diverticulosis.

PURPOSE: Patients with suspected diverticulitis may require imaging evaluation for definitive diagnosis. Computed tomography has evolved as the gold standard diagnostic test because it is minimally invasive, rapid, and widely available with a sensitivity 93-97% and specificity ~100%. It is used for diagnosis, staging, observation of changes over time, defines the size and location of an abscess and helps with the treatment decisions.

MATERIAL AND METHOD: the last year in our hospital 253 patients were hospitalized with clinical findings of acute diverticulitis.

Ct was performed with a PO dilute iodinated contrast and IV iodinated contrast





RESULTS: According the Hinchev Classification (Wasvary Modification) 72 of them were stage 0 (28,4%), 132 (52,2%), were stage Ia, 41 (16,2%) were stage Ib, 6 (2,4%) were Stage II and 2 (0,8%) were stage III. All patients of stage 0 and Ia, and 15 patients stage Ib (86,5%) were treated conservatively. The rest 26 with stage Ib and 2 with stage II (11%) needed percutaneous CT guided drainage of their abscesses. The rest 4 with stage II and the 2 with stage III had a surgical treatment.

CONCLUSION: CT is the safest and fastest imaging modality to diagnose diverticulitis and assess the extent of inflammation.

CT findings can effectively guide medical or surgical treatment.

PP 157

CT-GUIDED BIOPSY IN CHALLENGING LUNG NODULES

Mylona Sofia, Riga Nikoletta, Pierratou Eustratia, Nikolentzou Eleni, Georgantzi Sofia, Makras Eleutherios, Loubakou Aikaterini, Anagnostara Athina
 Hellenic Red Cross General Hospital Athens, Greece

INTRODUCTION: Lung biopsies are a necessity in our days. Many times the nodules are small and in position difficult to reach or next to critical organs (heart, vessels). We present our experience with such nodules.

PURPOSE: Small and difficult to reach nodules is a diagnostic challenge. CT-guided percutaneous core needle biopsy performed to evaluate the diagnostic accuracy of pulmonary nodules ≤ 2 cm

MATERIAL AND METHOD: the last year in our hospital 60 patients had a Ct guided lung biopsy. 18 of them were challenging because of the size and the position of the nodule. We used a soft tissue semi automatic biopsy needle 18G/10 or 15mm.

RESULTS: one of them (9%) the sample was insufficient, one (9%) necrotizing hemorrhagic fibrotic tissue, 2 (18.2%) were metastases from colon cancer, 2 (18.2%) were well differentiated pulmonary squamous cell carcinoma, 3 (27.4%) were moderate differentiated pulmonary adenocarcinoma, one (9%) insufficient suspected for malignancy, and one (9%) metastasis from pancreatic adenocarcinoma.

CONCLUSION: small nodules (< 2 cm) represent a technical challenge for diagnosis. CT guided lung biopsy is an excellent diagnostic tool with great accuracy.

PP 158

A RARE ETIOLOGY OF ABDOMINAL PAIN IN ADULTS: GASTRIC VOLVULUS

Antonia Parlamenti, Fani Dimitrouli, Pavlos Abatzis, Michaela Pripa, Anastasia Savidou, Ioannis Kalogeropoulos
 Department of Radiology, Evangelismos Hospital, Athens, Greece

Introduction: Gastric volvulus is a rare, potentially life-threatening condition. It is characterised by abnormal rotation of the stomach of more than 180° , resulting in gastric outlet obstruction and an increased risk of gastric strangulation. It is most commonly associated with paraesophageal hernias and carries mortality rates as high as 30-50%. It is classified as organoaxial (59%), mesenteroaxial (29%) or mixed. Organoaxial volvulus accounts for approximately two-thirds of cases. The peak age group of incidence is in the fifth decade, with children less than one year old making up 10–20% of cases. In 30% of cases the volvulus occurs as a primary event, but it is more commonly secondary. The chronic





form of volvulus is more common than the acute. In general, the acuity and severity of symptoms dictate management. Acute and complete gastric volvulus is a surgical emergency because of the increased risk for ischemia and secondary necrosis, perforation, and shock. The clinical symptoms associated with volvulus commonly are nonspecific and include pain, nausea, and vomiting. Because it is rarely diagnosed clinically, clinicians consult radiologists for diagnostic evaluations.

Purpose: To define the types of gastric volvulus and the features of radiography, fluoroscopy and computed tomography.

Materials and Methods: The diagnosis of gastric volvulus is challenging due to the non-specificity of the symptoms and rarity of the condition; it is achieved radiologically in combination with the clinical presentation. A diaphragmatic hernia should be suspected when radiographic findings such as an intrathoracic mass with or without air-fluid level or abdominal contents are found in the chest. A barium meal may be performed to evaluate the rotation of the stomach. Computed tomography is the gold standard to define the complications of gastric volvulus.

Results – Conclusion: Gastric volvulus is a surgical emergency, especially the acute type, which the radiologist should recognize and evaluate with the different imaging techniques.

PP 159

RARE CASE OF BILATERAL ECHINOCOCCOSIS

A. Georgiev; N. Sirakov; L. Chervenkov; K. Doykova

Department of Imaging Diagnostics, Medical University – Plovdiv, Bulgaria

Introduction

Parasitic disease provoked by *Echinococcus granulosus*. Endemic in sheep breeding areas with high prevalence in China and Central Asia, Middle East, East Africa, Australia, New Zealand, Alaska, South America and Europe.

Primary or isolated kidney involvement is rare and occurs in 1% - 5% of all infected patients. Patients usually are asymptomatic for years. Symptoms are nonspecific - such as back pain (40%) and discomfort in the epigastrium (20%). Existence of daughter cysts in urine is observed in 10% of cases (hydaturia).

Purpose

To represent an extremely rare case of double primary renal echinococcosis.

Materials and Methods

We present a male patient – 26y of age who has complaints of back and abdominal pain for several years. The study was performed on a 256 slice spiral computer tomograph with a 5 mm slice thickness with post-reconstruction of 1 mm.

Results

The patient have partially calcified lesions in both kidneys visible on the CT scans.

Conclusion

A rare manifestation of common disease can pose a real challenge in diagnostics. Broad DD. Disc disease, scoliosis, spinal stenosis, osteo-chondrosis, spondylosis. Other kidney diseases - pyelonephritis, glomerulonephritis, polycystic kidney, tumors.





PP 160

A RARE CASE: VON MEYENBURG COMPLEX

Koyun Mustafa, Arda Kemal Niyazi, Akay Sinan, Tasar Mustafa, Bozlar Ugur

Department of Radiology, University of Health Sciences, Gulhane Training and Research Hospital, Ankara, Turkey

PURPOSE

Von Meyenburg Complex, also known as biliary hamartoma, is a benign malformation usually less than 1 cm in length which are histologically composed of cystic-dilated biliary tract surrounded by fibrous stroma (1). In this paper, we aimed to present the magnetic resonance (MR) and magnetic resonance cholangiopancreatography (MRCP) imaging findings of a case with Von Meyenburg Complex, which can be confused with liver metastases.

CASE REPORT

A 60-year-old female patient was admitted to our hospital with long-standing abdominal pain. Abdominal ultrasonography (US) incidentally revealed multiple hyperechoic solid lesions less than 1 cm scattered in the liver parenchyma. MR images showed multiple scattered lesions in the liver parenchyma, hypointense on T1-weighted images, hyperintense on T2 weighted images and fluid-sensitive images, and unenhanced cystic lesions in contrast-enhanced images (a-c). Cystic lesions were unrelated to the biliary tract on MRCP (d). Based on the findings, the patient was diagnosed as Von Meyenburg Complex.

DISCUSSION

VMK is an asymptomatic disease that is rarely encountered and may be confused with metastasis. Its incidence in autopsy series has been reported as 0.69-5.6% in the literature (2, 3). In the US examination, VMK lesions can be seen in hypoechoic, hyperechoic or heterogeneous echoes according to their histological features (1). Comet tail artifact in the posterior of the lesions is helpful in the diagnosis (4). In computed tomography (CT) examination, it has been reported in the literature that they are seen as unenhanced hypodense lesions except for a few cases (5). On MRI, lesions are hypointense in T1-weighted images and hyperintense in T2-weighted images (1). MRCP demonstrated cystic lesions not associated with biliary tract and they are differentiated from Caroli's disease. In conclusion, knowing the characteristic radiological findings of Von Meyenburg Complex will reduce the frequency of unnecessary diagnostic and interventional procedures.

REFERENCES

- Rong-Qin Zheng, Bo Zhang, Masatoshi Kudo, Hirokazu Onda, and Tatsuo Inoue. Imaging findings of biliary hamartomas. *World J Gastroenterol.* 2005 Oct 28; 11(40): 6354-6359. doi: 10.3748/wjg.v11.i40.6354.
- E. B. Chung. Multiple bile-duct hamartomas. *Cancer.* 1970;26:287-296.
- Redston MS, Wanless IR. The hepatic von Meyenburg complex: prevalence and association with hepatic and renal cysts among 2843 autopsies. *Mod Pathol.* 1996;9:233-237.
- Luo TY, Itai Y, Eguchi N, Kurosaki Y, Onaya H, Ahmadi Y, Niitsu M, Tsunoda HS. Von Meyenburg complexes of the liver: imaging findings. *J Comput Assist Tomogr.* 1998;22:372-378.
- Lev-Toaff AS, Bach AM, Wechsler RJ, Hilpert PL, Gatalica Z, Rubin R. The radiologic and pathologic spectrum of biliary hamartomas. *AJR Am J Roentgenol.* 1995;165:309-313.





PP 161

A RARE COMPLICATION: INTRA-UTERINE DEVICE EMBEDDED IN THE ABDOMINAL WALL

Koyun Mustafa, Arda Kemal Niyazi, Akay Sinan, Tasar Mustafa, Bozlar Ugur

Department of Radiology, University of Health Sciences, Gulhane Training and Research Hospital, Ankara, Turkey

PURPOSE

Intrauterine device (IUD) is one of the most common used methods in contraception. Serious complications may occur rarely such as infection, ectopic pregnancy, perforation and bleeding (1). After perforation, IUD may migrate into abdominal cavity, genitourinary tract, gynecological system, gastrointestinal system organs or abdominal wall. In this paper, we aimed to present the direct X-ray and computed tomography (CT) imaging findings of a case with migrated IUD to and embedded in the anterior abdominal wall.

CASE REPORT

A 24-year-old female patient was admitted to our hospital with abdominal pain for 15 days. Physical examination revealed tenderness in the left lower quadrant. Transvaginal and transabdominal ultrasonography showed no urgent pathology. It was noted that the IUD, which had been placed in the endometrial cavity 3 months ago, was not in its normal localization. Direct abdominal X-ray was performed. CT images were obtained in order to determine the localization after superposed IUD (a). The IUD was seen at the left side of the pelvis on the direct X-ray. CT images revealed a 23x8 mm sized collection accompanying IUD and IUD embedded in the anterior abdominal wall of the left lower quadrant (b-e).

DISCUSSION AND CONCLUSION

Perforation is rarely encountered as a IUD complication and it is seen in 1.3-1.6 of 1000 IUD applications (2). Mosley et al. examined 129 patients with IUD-induced perforation and as a result, they showed that 32.5% of the IUDs were free in the pelvis, 31.7% were embedded in the omentum, 10% were attached to the intestine, 6.9% were attached to the uterus, 4.6% were free in the peritoneum, 3.8% were attached to the broad ligament, 3.1% were attached to the intestinal masses, 2.3% were attached to the omentum masses, 2.3% were attached to the rectum, 1.5% attached to the tuboovarian structures and 1.3% were attached to the bladder (3). In our case, IUD migrated to the anterior abdominal wall which is an entity rarely encountered in the literature. Direct X-ray should be our first choice for imaging migrated IUD. CT imaging can successfully show the precise localization of IUD and guide the clinician regarding the treatment.

REFERENCES:

1. Bang Guy Aristide, Nana Oumarou Blondel, Nong Libend Gilles Thierry, Noah Noah Dominique, Savom Eric Patrick. Laparoscopic Removal of a Migrated Intra Uterine Device Embedded in the Anterior Abdominal Wall in Yaounde (Cameroon), a Third World Country. SOJ Gynecol Obstet Womens Health 3(2): 1-3. Doi: 10.15226/2381-2915/3/2/00121.
2. Arslan A, Kanat-Pektas M, Yesilyurt H, Bilge U. Colon penetration by a copper intrauterine device: a case report with literature review. Arch Gynecol Obstet . 2009;279(3):395-397. Doi: 10.1007/s00404-008-0716-2.
3. Mosley FR, Shahi N, Kurer MA. Elective surgical removal of migrated intrauterine contraceptive devices from within the peritoneal cavity: A comparison between open and laparoscopic removal. JSLS. 2012;16(2):236-241.





PP 162

A RARE COMPLICATION OF TRANSCATHETERIAL AORTIC VALVE IMPLANTATION: IATROGENIC MYOCARDIAL RUPTURE

Koyun Mustafa, Bozlar Ugur, Cuce Ferhat, Sanal Hatice Tuba, Tasar Mustafa

Department of Radiology, University of Health Sciences, Gulhane Training and Research Hospital, Ankara, Turkey

PURPOSE

Transcatheter aortic valve implantation (TAVI) is an alternative treatment option for elderly patients with severe aortic valve stenosis and comorbidities. Many complications may occur due to the TAVI procedure. While local vascular complications (hematoma, rupture, thrombus, pseudoaneurysm), atrioventricular conduction disorders, paravalvular leakage and organ damage (stroke, myocardial ischemia, acute renal failure) are common complications associated with TAVI; myocardial rupture, valve dislocation, aortic annulus rupture and aortic dissection are rare ones and their incidence is less than 1% (1). In this paper, we aimed to present the CT angiography findings of a patient with iatrogenic myocardial rupture developed during the TAVI procedure.

CASE REPORT

A 79-year-old female patient underwent TAVI protocol to treat aortic valve stenosis. After the procedure, hemoglobin values decreased to 6.8 g/dl and echocardiography revealed pericardial effusion. Since pericardial effusion increased during follow-up, 150 ml of blood was drained via pericardiocentesis. The patient was referred to our department with a prediagnosis of myocardial rupture. Contrast agent extralumination compatible with rupture was seen in the left ventricular lateral wall and the prediagnosis was confirmed (a-d).

DISCUSSION AND CONCLUSION

Myocardial rupture is a life-threatening condition and it may be developed due to cardiac tamponade. Myocardial rupture is most commonly seen secondary to myocardial infarction. Other causes include endocarditis, trauma, iatrogenic causes, cardiac tumors and aortic dissection. Although TAVI is an effective and safe procedure, it may cause serious complications such as myocardial rupture during the procedure. Contrast agent ponds in the pericardial cavity or in the ventricular wall should suggest the rupture. In addition, myocardial rupture should be considered if the Hounsfield unit (HU) value of the pericardial fluid is as high as the blood. CT angiography is a very beneficial and efficient method used in detecting this complication.

REFERENCES:

1. Jarrah Alfadhli, Mohammed Jeraq, Vikas Singh, and Claudia Martineza. Updates on transcatheter aortic valve replacement: Techniques, complications, outcome, and prognosis. J Saudi Heart Assoc. 2018 Oct; 30(4): 340–348. Doi: 10.1016/j.jsha.2018.07.002.





PP 163

COEXISTENCE OF FISTULIZATION TO PULMONARY TRUNK OF VIEUSSENS ARC WITH AORTIC COARCTATION: CT ANGIOGRAPHY FINDINGS

Koyun Mustafa , Tasar Mustafa, Arda Kemal Niyazi, Cuce Ferhat

Department of Radiology, University of Health Sciences, Gulhane Training and Research Hospital, Ankara, Turkey

PURPOSE

The Vieussens arch represents the collateral connections between the conal branches of the right and left main coronary arteries and was first described by French anatomist Raymond de Vieussens. Although this anatomic variation is seen in 48% of the population, the pathological Vieussens arch is rarely encountered (1). In this paper, we aimed to present the CT angiography findings of a case with coexistence of fistulization to pulmonary trunk of Vieussens arc with aortic coarctation.

CASE REPORT

A 2-year-old male patient with fever was referred to our pediatric cardiology department with incidental cardiac murmur from an external center. Echocardiography revealed antegrade flow to the pulmonary arterial system and coronary CT angiography was performed for further evaluation. CT angiography showed collateral arterial branch between the right coronary artery and the left coronary artery. This connection was consistent with the Vieussens arc (a). There was a fistula between the Vieussens arch and the pulmonary artery (a-b). Aortic coarctation was also observed on CT angiography images (c).

DISCUSSION

Four types of Vieussens arch have been described in the medical literature (2). Type 1A arch; vascular pathology is not accompanied by Vieussens arch. Type 1B arch; Vieussens refers to the coexistence of pathological conditions such as fistula or aneurysm. Type 2 arch; type 4 dual LAD variation. Type 3 arch is seen in the presence of a single coronary artery. In our case, there was a rare Type 1B arch. Although Vieussens arch plays an important role in coronary artery occlusions due to its collateral circulation. Type 1B arch is a rare pathological condition that needs to be treated. With CT angiography, Vieussens arch anatomical variations and associated pathological conditions (such as fistula, aneurysm) can be easily detected.

REFERENCES

8. Yakup Alsancak, Sina Ali, Mustafa Duran, Ayşe Saatci Yaşar, and Mehmet Bilge. An unusual image of Vieussens' arterial ring communicating with the pulmonary artery. *Anatol J Cardiol*. 2015 May; 15(5): E13–E14. Doi: 10.5152/akd.2015.6266.
9. Nurullah Doğan, Aydın Dursun, and Hakan Özkan. Vieussens' arterial ring: a rare coronary variant anatomy. *Diagn Interv Radiol*. 2019 Mar; 25(2): 109–113. Doi: 10.5152/dir.2019.17449.





PP 164

GIANT CSFoma

Koyun Mustafa, Arda Kemal Niyazi, Akay Sinan, Sanal Hatice Tuba, Tasar Mustafa
 Department of Radiology, University of Health Sciences, Gulhane Training and Research Hospital,
 Ankara, Turkey

PURPOSE

Ventriculoperitoneal (VP) shunt is one of the most common treatment modalities in the treatment of hydrocephalus in neurosurgery practice. The VP shunt allows the cerebrospinal fluid (CSF) to drain into the peritoneal cavity. Many complications secondary to VP shunting may occur. These complications include occlusion and fracture of the shunt catheter, inability to insert the catheter correctly, CSF leakage from the catheter entrance, subcutaneous bleeding, hernia, peritonitis, CSF acid, CSFoma (abdominal pseudocyst) (1). CSFoma is a rare complication secondary to shunt and is not a real cyst because it does not have an epithelial wall. In this paper, we aimed to present the radiological findings of CSFoma, a rare complication of VP shunt.

CASE REPORT

A 45-year-old male patient was admitted to our hospital with abdominal pain and abdominal distention. On physical examination, an abdominal mass was palpated. He had a history of VP shunt catheter placement due to hydrocephalus 26 years ago. Transabdominal ultrasonography revealed a 25x20 cm cystic mass with smooth borders and dense content in the abdomen. Non-contrast abdominopelvic CT scan showed a thin-walled cystic density lesion measuring 26x22 cm. The tip of the VP shunt catheter was terminating at the inner border of the right wall of the lesion (a-c). Based on those findings, the patient was diagnosed as CSFoma and percutaneous external drainage catheter was inserted into the cyst for the treatment.

DISCUSSION AND CONCLUSION

CSFoma is a rare complication of VP shunt and is an important entity due to its clinical findings. Its incidence is reported as as high as 4.5% in the literature (3). Patients typically present with abdominal symptoms (abdominal pain, abdominal distension, nausea, vomiting, loss of appetite) and neurological symptoms (headache and lethargy due to shunt dysfunction) (2). On ultrasonographic examination, CSFoma is seen as a well-defined thin-walled anechoic / hypoechoic cystic lesion. When complicated, it may contain debris or septa. In our case, computed tomography examination revealed a smooth-bounded, thin-walled hypoechoic collection adjacent to the tip of the VP shunt catheter. In conclusion, CSFoma should be always included in the differential diagnosis in the presence of abdominal and neurological complaints in patients with VP shunt.

REFERENCES:

1. Samir Kashyap, Hammad Ghanchi, Tanya Minasian, Fanglong Dong, and Dan Miulli. Abdominal pseudocyst as a complication of ventriculoperitoneal shunt placement: Review of the literature and a proposed algorithm for treatment using 4 illustrative cases. *Surg Neurol Int.* 2017; 8: 78. doi: 10.4103/2152-7806.206007.
2. Mohammad Sadegh Masoudi, Marziye Rasafian, Zahra Naghmehsanj, and Fariborz Ghaffarpasand. Intraperitoneal Cerebrospinal Fluid Pseudocyst with Ventriculoperitoneal Shunt. *Afr J Paediatr Surg.* 2017 Jul-Sep; 14(3): 56–58. doi: 10.4103/ajps.AJPS_94_16.
3. Rainov N, Schobess A, Heidecke V, Burkert W. Abdominal CSF pseudocysts in patients with ventriculo-peritoneal shunts. Report of fourteen cases and review of the literature. *Acta Neurochir.* 1994;127(1-2):73-8. doi: 10.1007/BF01808551.





PP 165

GOSSYPIBOMA IN THE PENILE PROSTHESIS, US AND CT FINDINGS.

Aydin Hasan, Basar Halil, Caylak Makbule

Health Sciences University Ankara Oncology Research Hospital Radiology Department

A 62 year old man with penile prosthesis, was admitted to our Radiology unit for US and CT from Urology department. He had a soft subcutaneous tissue swelling and mass lesion beneath the prosthesis, but nevertheless had no complaints, just found out at the routine prosthesis control. In the US; A iso-hyperechoic soft tissue mass with calcifications and acoustic shadowing was observed just at the posterior margin of the left testis. This mass revealed high vascularity with low resistant arterial flow in the Doppler US.

In the Abdominal CT; That mass was also shown with high densities as iso-hypodense appearance (Between 350-500 HU) without any contrast enhancement, the prosthesis was intact without any failure. No fluid between testises and also in the inguinal regions, was analysed.

Gossypiboma, a forgotten sponge beyond the prosthesis and at the posterior border of the left testis, was the first diagnostic identity in the differential diagnosis with those Radiological imaging modalities and was confirmed histopathologically after open surgery.

Figure 1

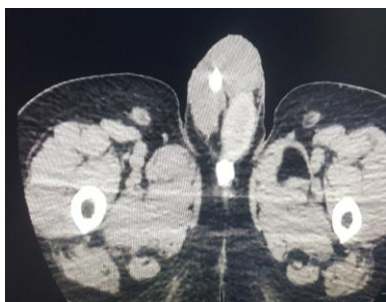

Figure 2

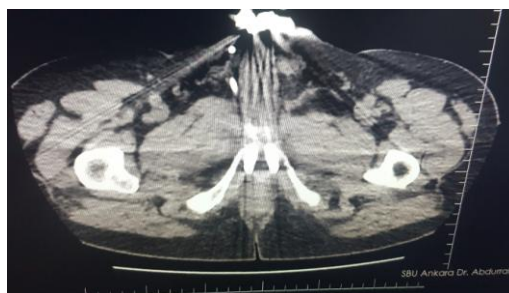

Figure 3

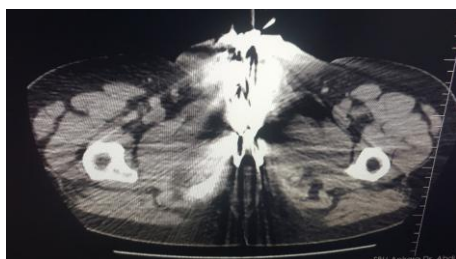
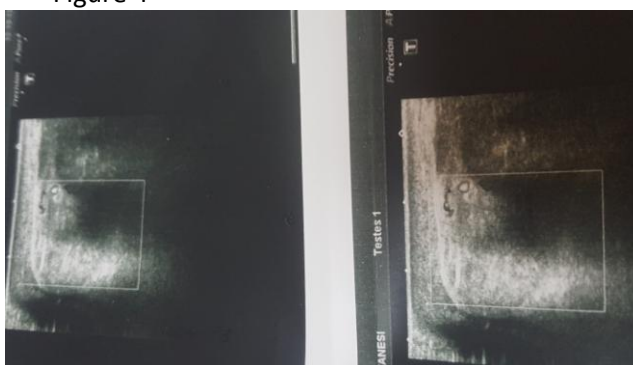

Figure 4





PP 166

ANOMALOUS ORIGIN OF CORONARY ARTERIES: DETECTION WITH CT CORONOGRAPHY

Christiana Chavari, Melpomeni Kosmidou, Konstantina Dimitriadou, Filippos Sarafis, Dimitrios Sidiropoulos, Sofia Papaioannou, Sofia Stratilati

Radiology Department of "Papageorgiou" General Hospital, Thessaloniki, Greece

Introduction

Anomalous origin of the left and right coronary arteries (LCA, RCA) from the opposite coronary sinus (ACAOS) or from the proximal part of the opposite coronary artery, constitute the most frequent type of coronary artery anomalies with a reported incidence 0.35% - 2.1% on CT studies. Clinical manifestations, clinical sequelae and therapeutic options vary widely according to the type of anomaly.

Purpose

The aim of the study was to detect anomalous origin and describe its course and also to differentiate clinically significant from non-significant types.

Materials and Methods

We conducted a retrospective study in 750 patients referred to our department for coronary computed tomography angiography (CCTA) in a two-year period (2017-2019). Most of the patients (who were symptomatic or asymptomatic), were examined in order to exclude or establish coronary artery disease (CAD).

ECG-gated CCTA was performed. MIP and VRT reconstructions in conventional and oblique planes were done in order to obtain optimal visualization of coronary vessels' origin and course. Additional characteristics, that potentially increase the risk of infarction or sudden cardiac death (SCD), including slit-like orifice, acute take-off angle, compression of the intramural segment or interarterial course between aorta and pulmonary artery, were evaluated, too.

Results

The final cohort included 11 patients with anomalous origin, aged 39-81 yrs. Right ACAOS was found in 4 patients and left ACAOS in 4 patients. In one patient RCA originated from the borders of right coronary sinus while left circumflex branch (LCX) originated from RCA. Origin from non coronal sinus was found in two patients. Different courses and other potential factors of increased risk of ischemia or SCD were described in detail.

Conclusion

ECG-gated CCTA is an excellent imaging modality to visualize origin and root of coronary vessels, to point out hemodynamically significant types and to guide the possible need for therapeutic management.





PP 167

METASTATIC HEPATIC HEMANGIOENDOTHELIOMA CASE

Aydin Hasan, Akyol Muazzez Bengi, Degirmencioglu Ozlem, Saygili Diba,
Health Sciences University Ankara Oncology Research Hospital Radiology Department

A 28 year old female with histopathologically confirmed diagnosis of metastatic Hemangioendotelioma, was admitted to Thorax and Abdominal CT for routine 6 months control from Medical Oncology. She had 6 cure Chemotherapy for 2 months before this CT imaging.

In the Abdominal CT, Massive ascites were present through whole abdomen with multiple calcific Lymph nodes and metastatic masses in the portal hilus, greater omentum, mesentery, para-aortic-paracaval areas, right retroperitoneal area and anterior abdominal Wall. Liver was atrophic, mostly left lobe and multiple hypodense subcapsular-parenchymal hepatic metastatic masses, between 2-10 cm in size, were observed in the right liver lobe.

Multiple Lung metastasis were observed in both hemithoraxes, metastatic nodules were almost calcified, localized in parenchyma and subpleural regions.

She will get 4 more cure chemotherapy after these CT results.

Figure 1

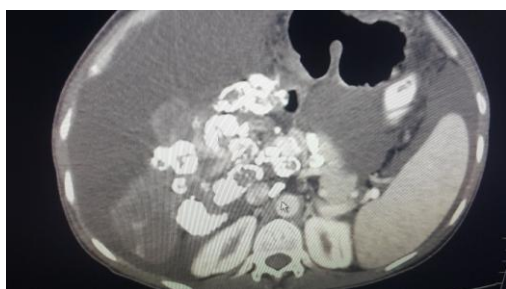


Figure 2

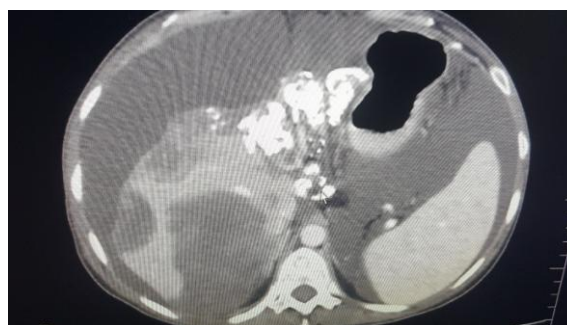
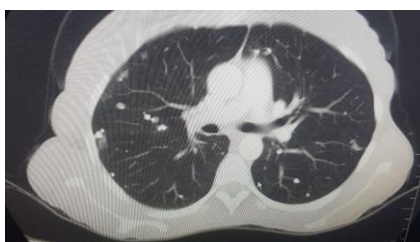
Figure 3





PP 168

CT ANGIOGRAPHY IN NON-TRAUMATIC SUBARACHNOID HEMORRHAGE ON EMERGENCY DEPARTMENT

Riga Nikoletta, Charalambous Christofis, Stathopoulos Panagiotis, Georgantzi Sofia, Lepida Niki, Anagnostara Athina, Loubakou Aikaterini, Mylona Sofia
 Hellenic Red Cross General Hospital Athens, Greece

INTRODUCTION: many patients come to the hospital with headache (the worst headache of their life-as they say), nausea and vomiting, neck pain, seizure, vision changes, as well as weakness. They report no trauma injury. A CT examination without contrast agent was performed which revealed subarachnoid haemorrhage. Then a CTA examination with IV contrast agent followed the initial examination.

PURPOSE: The significance of cranial CT followed by CTA as standard protocol to patients with non-traumatic SAH, in order to evaluate the haemorrhage and decide the further treatment.

MATERIAL AND METHOD: During the past year, 178 patients came to our hospital with the diagnosis of non-traumatic subarachnoid hemorrhage. 33 patients of the total number of 178 (18.5%) had also parenchymal hemorrhage. 42 (26.6%) patients had also intraventricular hemorrhage and 15 (8.4%) patients had both intraventricular and parenchymal hemorrhage. CTA was performed in 158 (88.8%) patients on emergency basis. The decision for the emergency CTA was taken according to the clinical manifestations of the patients and the findings.

RESULTS: The results of the CTA were the following:

67 (42.4%) were negative, 30 (18.9%) - Acom aneursum, 21 (13.4%) - MCA aneursum, 22 (13.4%) - ICA aneursum, CCA Pcom aneursum, 2 (1.3%) - Pericallosal aneursum, 9 (5.7%) - Basal aneursum, 7 (4.4%) - AVM.

CONCLUSION: Cranial CT followed by CTA should be the standard protocol in non traumatic SAH on the emergency department.





PP 169

INCIDENTAL BRAIN FINDINGS DURING AN MR EXAMINATION OF THE PITUITARY GLAND

Malla Houech Intesar-Victoria, Belyanova Magdalena, Zlatareva Dora, Hadjidekov Vassil
Sofia, Bulgaria

Incidental findings nowadays are found more frequently owing that to the newer imaging methods. Whether they are benign or malignant, a further examination needs to be performed for evaluation.

The purpose of this study is to illustrate different incidental brain findings without clinical presentation.

We retrospectively reviewed 301 MRs of the pituitary gland due to hormonal disturbances. All examinations were carried out on a 3T MR machine. MRI of the pituitary was performed using standard imaging protocol. The brain findings were assessed on the T2 axial and T1 postcontrast series or a complete study of the brain was performed for correct evaluation. The contrast medium used was Gadolinium according to the weight of the patient – dose 0.1 mmol/kg. CT scan was done on 64 - slice Aquillion machine when calcified structures were suspected.

Results:

We found pituitary adenomas in 106 patients and in 195 patients the pituitary gland was reported as normal. Incidental brain findings were seen in 22 patients. Of them 32% had meningioma as the most commonly seen additional pathology. Second most frequent finding was pineal gland cyst – in 18% patients. The other pathologies were cavernomas, aneurysm of the carotid arteries, optic nerve atrophy, arachnoid cyst, multiple sclerosis and cerebral vascular diseases. The patients age varied from 5 to 77. There was a prevalence in females - 77.2% of the patients.

Conclusion:

Incidental brain findings always need to be reported as they may alter the therapeutic outcome. The use of modern techniques in imaging diagnostics in daily practice increases the chance of detecting unexpected findings.

PP 170

MULTIPLE METASTASIS OF A COLON CARCINOMA, A HEPATIC FLEXURA TUMOR.

Aydin hasan, kaymak Sumeyye duran, Akyol Muazzez Bengi, Kurt Hulusi Mustafa
Health Sciences University Ankara Oncology Research hospital Radiology Department

A 62 year old male with metastatic colon carcinoma, was admitted to Radiology unit for Thorax and Abdominal CT from Medical Oncology due to severe complaints of patient as dsypnea-flank abdominal pain-nausea-vomit-diarrhea etc.

In the Thorax CT, A hypodense pulmonary thromboemboli was present at the distal tip of right pulmonary artery as a filling defect and multipl metastatic pulmonary nodules were present in both hemithoraxes.

In the Abdominal CT; Hepatic flexura tumor was present with massive ascites in the abdomen, with diffuse-nodular peritoneal metastasis and omental cake like lesions. Descending duodenal invasion and gall bladder invasions were also present, with thickened enhancing Wall of duodenum and bladder, partially contracted gall bladder. Multiple Lymphadenopathies were present, mostly at





mesentery, portal hilus and para-aortic regions. Intra and extrahepatic bile ducts were normal and patent.

He will get 4-6 cure chemotherapy after those CT results and will be under follow-up.

Figure 1

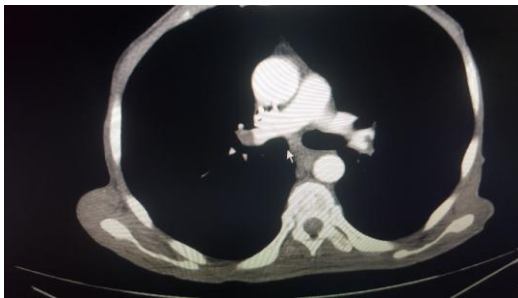
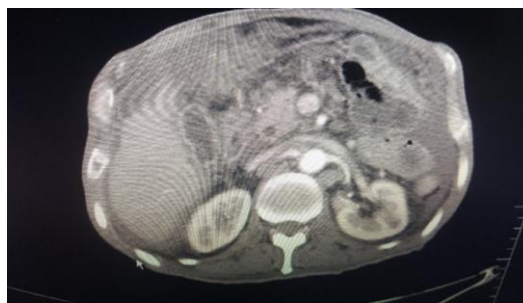


Figure 2

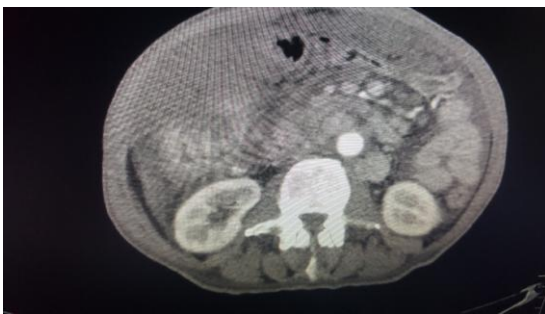

Figure 3



PP 171

PROSTATIC ARTERY EMBOLIZATION FOR BENIGN PROSTATIC HYPERPLASIA. A BALKAN STUDY WITH CONTRAST-ENHANCED SONOGRAPHIC IMAGING PROTOCOL

Hippocrates Moschouris, Andreas Dimakis, Aggeliki Papadatou, Konstantinos Stamatiou, Konstantinos Kladis-Kalantzis, Michail Kiltenis, Nikolaos Papadogeorgopoulos, Nektarios Spanomanolis, Marina Papadaki

1. Radiology Department, General Hospital Tzaneio, Piraeus, Greece
2. Urology Department, General Hospital Tzaneio, Piraeus, Greece

Introduction: Prostatic artery embolization (PAE) is a relatively new endovascular technique for the treatment of symptomatic benign prostatic hyperplasia (BPH).

Purpose: To present our initial experience on PAE for the treatment of BPH and to describe a contrast-enhanced ultrasonography (CEUS) imaging protocol for the evaluation of the procedure.

Materials and methods: Forty-three patients with symptomatic BPH were treated with PAE with microspheres (100–700 μm). International prostate symptom score (IPSS), quality of life (QoL), maximum urinary flow (Q_{max}), prostatic volume (PV) and post void residual volume (PVR) were measured at baseline and at 1, 3, and 6 months post PAE. Prostatic enhancement was studied with transabdominal CEUS at baseline and 1 day, 1, 3, and 6 months post PAE. Follow-up time ranged from 3 to 26 (mean, 9.7) months.

Results: Technical success rate was 93% (40/43 patients). Clinical success rates at 3, 6, 12 and 18 months post PAE were 90%, 84.1%, 84.1% and 73.6% respectively. Improvement of outcome





parameters (baseline vs. 6-month values) was statistically significant: 51% for IPSS ($p=0.003$), 45.7% for QoL ($p<0.001$), 27.4% for PV ($p<0.001$), 55.7% for PVR ($p=0.005$) and 102% for Qmax ($p=0.002$). The most significant complications were bladder ischemia ($n=1$), and ischemic rectal ulcer ($n=1$), both with complete recovery after conservative management. CEUS 1 day post PAE demonstrated prostatic infarcts in 37/40 (92.5%) patients. There was a very strong positive correlation between the extent of prostatic infarction and prostate shrinkage (PV reduction) post PAE ($r=0.82$, $P < 0.001$), but a weak correlation between the extent of prostatic infarction and the improvement of the other outcome parameters.

Conclusion: PAE is a promising interventional technique for the treatment of PAE and CEUS can be utilized to assess the local ischemic effect of PAE. The respective prognostic role of CEUS needs to be further evaluated.

PP 172

COLOURACHAL-CUTANEOUS FISTULA

Oruc Meltem, Garipoglu Cemile, Koc Osman

Department of Radiology, Meram Faculty of Medicine, Necmettin Erbakan University, Konya, Turkey

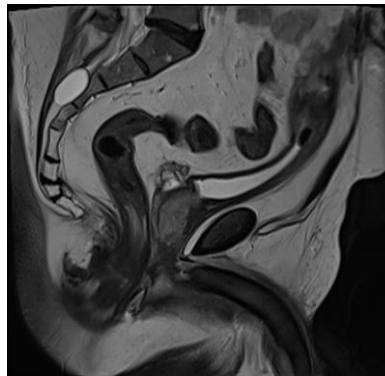
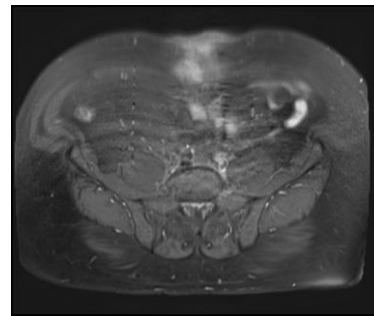
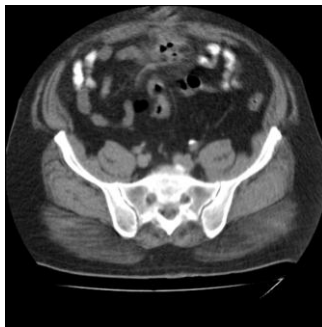
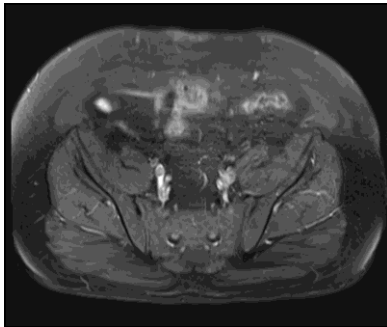
- **Introduction:** The urachus is a remnant of the allantois. It obliterates during gestation, becoming the median umbilical ligament. Urachal anomalies are rare. Four types of urachal anomalies have been described: patent urachus, urachal cyst, urachal-umbilical sinus, and vesicourachal diverticulum.
- **Purpose:** To present a rare case of colourachal-cutaneous fistula with umbilical feculent discharge.
- **Materials and Methods:** A 57-year-old man, with unremarkable previous medical history, was admitted to our hospital with a 2-week history of umbilical feculent discharge. Physical examination showed a fistula from the umbilicus with redness of the surrounding skin. Through the opening feculent discharge was observed. The laboratory data showed leukocytosis with a predominance of granulocytes and an increased level of CRP. No significant findings were present on urinalysis. The patient was evaluated with cystoscopy and edema of the dome wall of the bladder was found. On colonoscopic examination, sigmoid colon was abnormally fixated to abdominal wall but no malignancy was detected. CT and MRI scans revealed a thickened urachal remnant which was distended with fluid and gas pockets. Urachal remnant communicated with the sigmoid colon and the umbilical skin. Wall of the sigmoid colon was thickened.
- **Results:** Laparotomy revealed a patent urachus with a cutaneous umbilical fistula, and a fistula between the patent urachus and sigmoid colon. The mass of urachal complex showed signs of severe inflammation. An en bloc excision of the urachus mass, umbilicus, a bladder cuff were performed. Sigmoid colectomy with Hartmann's procedure was realized. Histology revealed an inflamed patent urachus with an inflamed colon. There was no evidence of malignancy.





Restoration of bowel continuity was performed 3.5 months later and at follow up the patient was symptom free.

- Conclusion:** Colo-urachal-cutaneous fistula is a rare cause of umbilical feculent discharge. It can be diagnosed radiologically by means of an abdominal CT scan. It can be treated with complete surgical excision of the urachal complex.





PP 173

ENDOVASCULAR TREATMENT OF UPPER EXTREMITY ARTERIES OCCLUSION AFTER TRANSRADIAL CAROTID ARTERY STENTING – TR-CAS

Ivona Jovanoska, MD¹, Aleksandar Gjoreski, MD¹, Sandra Dejanova Panev, MD¹, Miranda Ramani MD¹; Gjorgi Dungevski MD¹, Marija Bunda Kalpak, MD²
City General Hospital “8th September” Skopje, MKD¹; PHI Dijagnosticki Centar Skopje, MKD²

Introduction

Endovascular procedures inevitably result in iatrogenic injury in small percentage of patients. Transradial approach is an alternative approach for CAS in the presence of limitations to femoral access. However, some operators prefer transradial access for almost every procedure including CAS. Most common complications of transradial access include asymptomatic radial artery occlusion, injury and spasm. Incidence of radial artery occlusion is reported to be 2-18% after TR catheterization, which should in theory not endanger viability of the hand because of double blood supply. In contrary, brachial artery occlusion is not reported, but can result in acute hand ischemia.

Purpose

We present two cases with acute upper limb ischemia, which is most likely related to the previous TR-CAS, where endovascular repair of the occlusion/stenosis was highly effective.

Materials and Methods

A retrospective analysis of two patients, one diagnosed with brachial and the other with radial and ulnar artery occlusion, treated endovascularly in our hospital was performed. Both had recently undergone TR-CAS at different centers.

Results

The patient with brachial artery occlusion presented with severe pain in the right forearm and hand, discoloration of the 3th, 4th and 5th finger and initial ischemic changes. There was no pulsation on right radial nor ulnar artery. DUS revealed typical monophasic poststenotic flow in distal forearm vessels, and CTA confirmed total occlusion of the right brachial artery.

The other patient presented with right hand pain and ischemic change on the 3rd finger. The CTA showed 60% stenosis of the brachial, subocclusion of the interosseal artery and chronic occlusion of the radial and ulnar arteries.

Both patients were successfully treated at our department with balloon angioplasty of the brachial and interosseal artery with almost immediate clinical improvement.

Conclusion

The cause of upper-limb arteries occlusion for our patients was unclear, but we believe was a possible complication of the previous TR-CAS. However, background atherosclerotic change could also account. Complication rates with transradial procedures in coronary arteries are low, but usage of radial access for other than coronary purposes and placing large bore devices should be very carefully done and can be performed in highly selected cases. Upper-extremity artery occlusions can be effectively treated endovascularly with successful clinical outcome.





PP 174

ULTRASOUND IMAGING IN PALLIATIVE CARE PRACTICE

Petrocheilou Glykeria¹, Chantzopoulos Georgios², Athanasiou Kalomoira³, Chatzistamatiou Evangelos⁴, Dimitrios Kalfountzos⁵, Papadopoulos Angelos⁶, Labiris Evaggelos⁷

1 Radiology Department, Spiliopouleio "Agia Eleni" Hospital, Athens, Greece

2 Department of Microbiology, Spiliopouleio "Agia Eleni" Hospital, Athens, Greece

4 Department of Internal Medicine, Spiliopouleio "Agia Eleni" Hospital, Athens, Greece

3 Cardiologist, Spiliopouleio "Agia Eleni" Hospital, Athens, Greece

5 Department of Internal Medicine, Spiliopouleio "Agia Eleni" Hospital, Athens, Greece

6 Department of Internal Medicine, Spiliopouleio "Agia Eleni" Hospital, Athens, Greece

7 Radiology Department, Spiliopouleio "Agia Eleni" Hospital, Athens, Greece

Introduction

Palliative care aims to relieve symptoms and optimize the quality of life in patients with a life-limiting or terminal illness.

Purpose

The aim of this presentation is to review the potential applications of ultrasound as a dynamic imaging tool in palliative care daily practice.

Materials and Methods

Sonographic images of adult patients referred to the Radiology Department are retrospectively used to present the wide range of ultrasound applications in palliative care.

Results

The additional advantages of ultrasound over other imaging modalities (cost-effectiveness, safety/no radiation exposure, real time visualization, portability/bedside evaluation) make the method valuable in palliative care not only as a diagnostic tool but also as an image accurate guidance for invasive therapeutic procedures. Images **are presented hereby to depict the valuable role of ultrasound.**

Intra-abdominal, cardiac, chest, renal, vascular and musculoskeletal pathology can be investigated while real-time visualization allows palliative procedures guidance with increased safety.

Conclusion

Ultrasound is a safe, rapid, non-invasive imaging technique yielding bedside, real time images. Despite its limitations (highly operator-dependent, images not exactly reproducible, small field of view/large area not in a single image, technical "barriers" such as bone and air) its role in palliative care is expanding aiming to provide relief of distressing symptoms and promote comfort.

PP 175

DEEP VEIN THROMBOSIS: PITFALLS IN EMERGENCY ULTRASOUND IMAGING

Petrocheilou Glykeria¹, Argyriou Panagiotis²

1 Radiology Department, Spiliopouleio "Agia Eleni" Hospital, Athens, Greece

2 Radiology Department, 401 Military General Hospital, Athens, Greece

Introduction

Venous thromboembolism is a major health problem. Because the incidence of this disease is so high and progression from deep vein thrombosis (DVT) to pulmonary embolism (PE) can lead to significant morbidity and mortality, the ability to rule in or rule out DVT in the emergency department with ultrasound is essential.

Purpose



To present and analyze the commonest pitfalls (false negative and false positive findings) in emergency ultrasound for DVT and to indicate possible ways to avoid them.

Materials and Methods

A pictorial review with images from our departments and schematic drawings are used to present the range of pitfalls in emergency ultrasound imaging of DVT with emphasis on key technical and imaging points for correct diagnosis.

Results

Technical parameters (e.g. patient positioning, probe selection, compression technique), anatomy variations, limitations concerning the method or the patient (e.g. obesity, edema) and other pathology (e.g. baker cyst, lymph nodes) are key points for a correct diagnosis. Cases of interpretive difficulty are illustrated and discussed.

Conclusion

Ultrasound is a useful diagnostic tool in the evaluation of patients presenting with signs and symptoms suggestive of a DVT. Given that ultrasound may be performed by emergency physicians or technicians and the radiologist is called for an "expert" opinion, it is crucial for the trainee radiologist to get familiar with the method's strengths and limitations and have a clear understanding of the pitfalls leading to false diagnosis.

PP 176

EOSINOPHILIC GRANULOMATOSIS WITH POLYANGIITIS - CNS INVOLVEMENT AND ATYPICAL CLINICAL COURSE

Aleksandar Ragaji¹, Ivan Adjic¹, Milos Vukovic¹, Nikola Andjelic¹, Dusko Kozic^{1,2}

¹ Oncology Institute of Vojvodine, Diagnostic Imaging Center, Sremska Kamenica, Serbia

² School of Medicine, University of Novi Sad, Serbia

Introduction: Eosinophilic granulomatosis with polyangiitis (EGP, previously Churg-Strauss syndrome) is typically associated with small to medium vessel necrotizing pulmonary vasculitis.

Presentation: A 44-year-old man was admitted to the hospital with severe eosinophilia heart insufficiency and suspected cardiomyopathy. Personality changes and involuntary movements were also evident.

Results: Computed tomography of the lungs and brain revealed no significant abnormalities. No cardiomyopathy was found after heart imaging studies. Numerous, nonenhancing lacunar infarcts with restricted diffusion sign were noted in supratentorial white matter, cerebellum and left caudate nucleus. Laboratory studies confirmed the presence of vasculitis. After the diagnosis of EGP was establish combined corticosteroid and cyclophosphamide treatment was initiated.

Conclusion: EGP without pulmonary involvement is rather rare form of disease. Lacunar cerebral infarcts due to vasculitis might be the main form of this disorder. EGP should not be excluded in patients with unexplained eosinophilia and unremarkable pulmonary findings.





PP 177

EARLY EXPERIENCE WITH CHEMOEMBOLIZATION OF HEPATOCELLULAR CARCINOMA WITH RADIOPAQUE DRUG-ELUTING MICROSPHERES

Hippocrates Moschouris¹, Theodoros Kiakidis², Andreas Dimakis¹, Aggeliki Papadatou¹, Ioannis Kornezos¹, Katerina Malagari³

1. Radiology Department, General Hospital Tzaneio, Piraeus, Greece
2. Radiology Research Unit, Evgenidion Hospital, Athens, Greece
3. 2nd Department of Radiology, University of Athens, Attikon Hospital, Athens, Greece

Introduction: Radiopaque (RO), drug eluting microspheres (DEMs) represent a recent technological advance in transarterial chemoembolization (TACE) of hepatocellular carcinoma (HCC).

Purpose: To present our early clinical experience on the aforementioned field.

Materials and methods: Sixteen HCC patients (13 male, 3 female, age: 52-88 years), not eligible for curative treatment, were retrospectively studied. They were treated with TACE with RO-DEMs (DC-Bead Lumi, BTG), with diameter of 70–150 µm, preloaded with 75mg Doxorubicin/2ml of DEMs. The distribution of RO-DEMs was studied with Digital Radiography (DR) during intervention and with Computed Tomography (CT) immediately post intervention and the next day. Response was evaluated with modified Response Evaluation Criteria in Solid Tumors, on the basis of the findings of Contrast Enhanced Magnetic Resonance (CE-MR), performed one month after each session of TACE and 6 months after the first session. Complications were recorded and graded as per CIRSE Classification System.

Results: A total of 27 TACE sessions were performed (mean: 1.7 sessions per patient) and 28 HCC tumors (n=27 hepatic, and n=1 extrahepatic-adrenal metastasis) with diameter of 30-129mm were embolised with RO-DEMs. Post embolization syndrome (minor, grade 2 complication) was observed in 5/16 patients (31.2%). Six months post treatment initiation, 4/16 patients (25%) had complete response, 5/16 (31.2%) had partial response, 6/16 (37.5%) had stable disease and 1/16 (6.2%) had progressive disease. The varying extent of accumulation of RO-DEMs in the target tumors could be appreciated in all patients with DR during intervention, thus facilitating therapeutic decisions. CT diagnosed complete opacification of 6/28 (21.4%) tumors with RO-DEMs and only these tumors showed complete necrosis on subsequent CE-MR.

Conclusions: TACE of HCC with RO-DEMs appears to have a satisfactory safety and efficacy profile; the straightforward detection of the distribution of the embolic material during and post procedure is an additional advantage with potential clinical relevance.

PP 178

GIANT SCULL BASE SCHWANNOMAS ASSOCIATED WITH PONTINE CAPILLARY TELANGIECTASIA

Milos Vukovic^{1,2}, Igor Nosek^{1,2}, Mladen Bjelan³, Dusko Kozić^{1,2}

¹ Center for Imaging Diagnostics, Institute of Oncology of Vojvodina, Sremska Kamenica, Serbia

² University of Novi Sad Faculty of Medicine, Novi Sad, Serbia

³ Magnetic Resonance Diagnostic Center - MRI System, Zrenjanin, Serbia

Introduction: Neurofibromatosis could be associated with intracranial vascular malformations.

Methods: Magnetic resonance imaging (MRI) study was ordered in a 57-year-old woman with known pontine capillary telangiectasia associated with developmental venous anomaly, detected 20 years before. Right tympanoplasty has been several times performed due to conductive hearing impairment,





without positive outcome. Paresis of right hypoglossal nerve, gustatory dysfunction, paresis of the ipsilateral laryngeal recurrent nerve and right shoulder pain were the main complaints.

Results: Apart from pontine vascular malformation, MRI revealed the presence of giant masses, consistent with schwannomas within the right infratemporal fossa, affecting the branch of the mandibular nerve, innervating musculus tensor tympani and veli palatini, with consequent fluid within the tympanic cavity and right mastoid cells. Schwannoma of the ipsilateral jugular foramen was also found, explaining the symptoms of IX-XII cranial nerves dysfunction. These schwannomas were not evident on retrospective evaluation of prior MRI scans.

Conclusion: Vascular malformations of the brain might be associated with schwannomas of the skull base, however the tumors could appear decades after.

PP 179

THE ROLE OF MR SPECTROSCOPY IN DIFFERENTIATION OF METASTATIC BRAIN LESIONS FROM OTHER TUMORS - A CASE REPORT

Mladen Bjelan, Stefan Stojanoski, Jasmina Boban, Kristina Ivosevic, Dusko Kozic
 University of Novi Sad Faculty of Medicine, Novi Sad, Serbia

Introduction. Solitary brain lesions may have rather atypical imaging characteristics.

Purpose: The aim of this report is to present the role of MR spectroscopy (MRS) in differentiation of atypical brain masses.

Report: Magnetic resonance imaging and MRS were ordered in a 55-year-old man with a history of first seizure in his life. A dural-based mass, hypointense on T2W sequence, measuring 45mm in greatest diameter, was evident in right frontal parafalcine area, showing no significant postcontrast enhancement. Diffusion weighted imaging was inconclusive. Typical enhancement for either meningioma or metastatic lesion was not evident. Primary brain tumor was not considered due to extraaxial localization of the mass. No perifocal vasogenic edema was noted. High choline and lipid concentrations were detected on single voxel MRS sequences with long and short echo, typical for metastatic lesions. The mass was surgically removed. Neuroendocrine lung tumor was the primary source of malignant disorder. Disseminated disease was later evident on positron emission tomography.

Conclusion: Non-enhancing brain metastases are very rare. Both short and long echo MRS may markedly improve the diagnostic accuracy in such circumstances.





PP 180

PERCUTANEOUS CHOLECYSTOSTOMY FOR ACUTE CHOLECYSTITIS: REPORT OF 109 CASES.

Zorbas D., Georgiadou M., Manouvelou S., Bagiazidou E., Liouvarou E., Nikolaou V.

Radiology Department, Nikaia General Hospital, Greece

Introduction

Percutaneous cholecystostomy for acute cholecystitis is a common procedure in Interventional Radiology, performed in high-risk patient groups, such as those with numerous co-morbidities or the critically ill. It is most commonly performed as a temporizing measure, allowing elective cholecystectomy at a later date, when the patient is more stable.

Purpose

The authors evaluated the outcome of 109 hospitalized patients with sepsis who fulfilled criteria of acute cholecystitis, in whom emergency percutaneous cholecystostomy was performed.

Materials and Methods

All cholecystostomy procedures were performed with ultrasound (US) guidance by using either the trocar (n=93) or the Seldinger (n=16) technique, with the latter being reserved for selective cases (ex. obese patients).

Results

In all patients cholecystostomy was performed successfully. 33 patient were lost to follow up, due to reference by other institutions. Out of the remaining 76 patients, 28 (37%) died because of poor clinical condition, with none of the deaths being directly attributed to percutaneous cholecystostomy. 41 patients (54%) underwent surgical cholecystectomy at a later date (ranging from 3 to 47 days post intervention), while 7 patients (9%) demonstrated complete remission of symptoms, with evidence of cystic duct obstruction and were treated with cholecystostomy alone. Patients treated using the trocar technique had no major complications; there were 8 (9%) cases of severe post interventional pain, 6 of them associated with unsuccessful first puncture. Patients treated using the Seldinger technique had 3 major complications (19%), one case of cystic artery hematoma treated with embolization, one case of severe post interventional pain in a third trimester pregnancy -resulting in labor induction - treated pharmaceutically and one case of catheter dislodgement requiring surgery.

Conclusion

Percutaneous cholecystostomy for acute cholecystitis is a low risk procedure that provides adequate time to stabilize and treat hi risk patients.





PP 181

THE ROLE OF BRAIN MRI IN DIAGNOSIS OF HERPES SIMPLEX ENCEPHALITIS

Dajana Veljkovic.

Sveti Sava Hospital

INTRODUCTION: Herpes simplex encephalitis (HSE) is a brain parenchyma inflammation caused by a herpes simplex virus type 1 or type 2. It is the most common diagnosed of fatal sporadic encephalitis. There is no particular age, sex, or seasonal predilection. It is common in immunocompromised patients.

PURPOSE: The aim of study is to show the MR presentation of herpes simplex encephalitis

MATERIAL AND METHODS: A 68-year-old male admitted to the Stroke hospital with symptoms of: fever, severe congestive disorder, left sided hemiparesis, seizure. Brain CT with CT angiography, MR brain, EEG, complete laboratory tests, radiography of chest.

RESULTS: Non contrast brain CT with CT angiography was negative. Radiography of chest was normal. Brain MRI showed bilateral asymmetric hyperintense lesions on T2 / FLAIR sequences with restricted diffusion (cytotoxic edema) in insular region, limbic (parahippocampal region) and gyrus cingulate predominant on left side. Those changes spared basal ganglia and postcontrast enhancement was absent. There were no hemorrhagic changes on T2 GRE sequence. Patients had periodic lateralized epileptiform discharges on EEG. Analyzing of cerebrospinal fluid (CSF) by PCR test confirmed the diagnosis of herpes simplex encephalitis. During the examinations, thyrotoxicosis was also detected by specific hormone and laboratory tests and ultrasound of neck.

CONCLUSION: Based on the anamnesis, the clinical examinations, the MRI imaging method, laboratory and CSF tests, it can be concluded that the patient is suffering from herpes encephalitis, which is frequent in the immunocompromised patients like thyrotoxicosis. Early diagnosis and treatment of HSE is imperative.





INVITED FACULTY AFFILIATIONS



Akata Deniz	Professor of Radiology, Department of Radiology, Abdominal and Noninvasive Vascular Imaging Radiology Section, Hacettepe University School of Medicine, Ankara Turkey
Akhan Okan	Professor of Radiology, Department of Radiology, Hacettepe University, Ankara, Turkey
Andrianaki Aikaterini	Radiologist, Department of Radiology, Axia Iatriki Medical Center, Heraklion , Crete, Greece
Alexiou Evangelos	Directorate Consultant Radiologist CT & MRI Department Larissa General Hospital, Greece
Antevska Grujoska Svetlana	Professor, Radiation therapy/Oncologist, University Clinic for Radiology, Republic of North Macedonia
Arkun Remide	Professor of Radiology, Department of Radiology, Ege University, Turkey
Arvaniti Maria	Director of Radiology Department General Hospital "Georgios Genimatas" Thessaloniki Greece
Bayraktaroglu Selen	Associate Professor of Radiology, Department of Radiology, Ege University, Turkey
Berczi Viktor	Professor and Chairman Department of Radiology, Semmelweis University, Budapest, Hungary
Beslagic Vanesa	Director, Department of Radiology, Institute of Radiology, University Clinical Center, Sarajevo, Bosnia & Herzegovina
Blazic Ivana	Radiologist, Department of Radiology, Clinical Hospital Center Zemun, Belgrade, Serbia
Brountzos Elias	Professor of Interventional Radiology, National and Kapodistrian University of Athens, Greece, Attikon Hospital, Greece
Bulakbasi Nail	Professor of Radiology, Department of Radiology, Near East University Hospital, Nicosia, North Cyprus, Turkey
Calli Cem	Associate Professor of Radiology, Department of Radiology, Ege University Medical School, Izmir, Turkey





- Celebi Irfan** Assistant Professor in Radiology, Radiology Department of the American Hospital, Istanbul, Turkey
- Cengic Anesa** General Radiologist, Radiology Department, General Hospital Sarajevo
- Cevikol Can** Professor of Radiology, Musculoskeletal Radiology, Akdeniz University Hospital, Antalya, Turkey
- Chartampilas Evangelos** Radiologist, Radiology Department, Bioclinic Private Hospital, Thessaloniki, Greece
- Chatziioannou Achilleas** Professor of Radiology, Department of Radiology, Medical School of Athens University, Areteio Hospital, Athens, Greece
- Chlapoutakis Konstantinos** Radiologist, Clinical Radiologist Radiologist, Heraklion Crete, Greece
- Cokkinos Demosthenes** Radiologist, Department of Radiology, Evagelismos Hospital, Athens, Greece
- Courcoutsakis Nikolaos** Associate Professor of Radiology, University Hospital of Thrace, Alexandroupolis, Greece
- Dagdilelis Loukas** Director of Radiology Department General Hospital G. Papanikolaou, Thessaloniki, Greece
- Daskalogiannaki Maria** Radiologist, Department of Radiology, University Hospital of Heraklion Crete, Greece
- Detorakis Stathis** Consultant Radiologist, CT and MRI Department, Affidea Heraklion Crete, Greece
- Dimitropoulos Nickolaos** Breast Radiologist, Athens, Greece
- Dineva Svetla** Diagnostic Imaging Dept, "Alexandrovska" University Hospital, Medical University of Sofia, Bulgaria
- Djilas Dragana** Professor of Radiology, Department of Radiology - Imaging, Diagnostic Imaging Center, Oncology Institute of Vojvodina
- Efremidis Stavros** Emeritus Professor of Radiology University of Ioannina Geniki Kliniki Thessaloniki, Greece





Elmas Nevra Professor of Radiology, Ege University ,Faculty of Medicine, Department of Radiology, Izmir, Turkey

Erturk Mehmet Sukru Chairman and Professor of Radiology, Department of Radiology, Adiyaman University School of Medicine, Adiyaman, Turkey

Fallenberg Eva Maria Assoc.Professor of Radiology ,University Hospital, LMU Munich Department of Radiology, Munich Germany

Filippiadis Dimitrios Assistant Professor of Diagnostic and Intervntional Radiology Medical School, National and Kapodistrian University, Athens Greece

Georgiev Radoslav Associated Professor in Radiology Department, University Hospital "St. Marina" Varna, Bulgaria

Gourtsoyianni Sofia Ass. Professor of Radiology, 1st Department of Radiology, Aretaieion Hospital, Athens Greece

Gourtsoyiannis Nickolas Emeritus Professor of Radiology,University of Hearnklion, Crete, Greece

Groudeva Violeta Assistant Professor of Radiology, Medical University, Radiologist, Diagnostic imaging Department, University Hospital "St Ekaterina", Sofia, Bulgaria

Hadjidekov George Vassilev Professor of Radiology, Department of Radiology, Sofia University Sv.Kl.Ohridski Univ.Hospital Lozenets, , Sofia, Bulgaria

Hatakenaka Masamitsu Professor and Chair, Department of Diagnostic Radiology, Sapporo Medical University, Japan

Hayashi Natsuko Medical Staff in Radiology, Osaka General Hospital of West Japan Railway Company, Osaka, Japan

Hazirolan Tuncay Professor of Radiology, Department of Radiology, Hacettepe University School of Medicine Ankara, Turkey
President of Turkish Society of Radiology

Jefić Svjetlana Radiologist, Department of Radiology, Private Polyclinic "AL-TAWIL", Sarajevo Bosnia and Herzegovina

Karaali Kamil Professor of Radiology Department of Akdeniz University, Antalya, Turkey





- Karaman Can** Professor of Radiology, Head of Radiology Department Adnan Menderes University, Aydın, Turkey
- Karantanas Apostolos** Professor of Radiology, University of Crete, Chairman, Department of Medical Imaging, Heraklion University Hospital, Crete, Greece
- Karlović-Vidaković Marijana** Head of Neuroradiology Department, University Hospital Mostar, Bosnia and Herzegovina
- Karnabatidis Dimitrios** Professor of Interventional Radiology University of Patras, Medical School, Patra Greece
- Kehagias Elias** Radiologist, Department of Interventional Radiology, University Hospital of Heraklion, Crete, Greece
- Kelekis Alexis** Ass. Professor of Radiology, 2nd Dept. of Radiology, University General Hospital "Attikon", National and Kapodistrian University of Athens, Athens Greece
- Kilburn-Toppin Fleur** Radiologist, Addenbrooke's Hospital UK
- Koprivsek Katarina** Professor of Radiology, Medical Faculty, University of Novi Sad, Serbia
- Kozic Dusko** Professor of Radiology, University of Novi Sad, Novi Sad, Serbia
- Kratimenos Theodoros** Director of Interventional Radiology Department, Evaggelismos General Hospital, Athens Greece
- Krokidis Miltiadis** Consultant in Vascular and Interventional Radiology, Cambridge University Hospital, UK
Ass. Professor of Radiology, Medical School of National Kapodistrian University of Athens Greece
- Lazareska Menka** Chief of Neuroradiology and Neurovascular and Vascular Interventional Radiology at the University Institute of Radiology, Skopje, Republic of North Macedonia
- Lucic Silvoja** Assistant Professor of Medical Faculty Oncology Department at the University of Novi Sad. Chief of diagnostic nuclear medicine at the Department of nuclear medicine of the Oncology Institute of Vojvodina in Sremska Kamenica, Serbia





Lucic Milos Professor of Radiology, University of Novi Sad, Chair of Radiology, University of Novi Sad, Serbia, Chairman of Diagnostic Imaging Center, Oncology Institute of Vojvodina, Serbia

Mainta Evgenia Consultant in Radiology NHS Trust St Mark's Hospital, London North West University Healthcare Nhs Trust, Department of Radiology, London, UK

Maksimovic Ruzica Professor of Radiology, President of BSR, University of Belgrade University Clinical Center of Serbia, Center for Radiology and Magnetic Resonance Imaging, Belgrade, Serbia

Mann Ritse Maarten Radiologist, Radboud University Nijmegen Medical Center Department of Radiology, Nijmegen/NL

Mantatzis Michail Ass. Professor of Radiology, Neuroradiology, University Hospital of Thrace, Greece

Marias Konstantinos Associate Professor in Image Processing at the Informatics Engineering Department of the Technological Educational Institute of Crete, Greece

Merhemc Zulejha Associate Professor, Department of Radiology, Poliklinika Sunce Agram Sarajevo, Bosnia & Herzegovina

Michailidis Konstantinos Cardiac Radiologist, Center of Cardiovascular, Affidea, Kozani Greece

Mihai Florin Senior Radiologist, Department of Radiology-Imaging, County Emergency Hospital "St. Spiridon", Assistant Professor of Radiology, University of Medicine and Pharmacy "Gr. T. Popa"

Mitreska Nadica Professor of Radiology, Department of Radiology University Clinic of Radiology, Republic of North Macedonia

Moulopoulos Lia - Angela Professor of Radiology, Chair of 1st Department of Radiology, Aretaieio University Hospital, Athens, Greece

Nakajima Yasuo Professor Director, Radiology Consultation Clinic, Professor Emeritus, St. Marianna University School of Medicine, Tokyo, Japan





Nedevska Maria Associate Professor of Radiology and head of Radiology Department at University Hospital "St.Ekaterina" Sofia, Bulgaria

Negru Dragos Professor of Radiology ,University of Medicine and Pharmacy GrTPopa, Department of Radiology, Iasi, Romania

Njagulj Vesna Radiologist, Diagnostic Imaging Centre, "VAMED & Partners – VMR Novi Sad",Novi Sad Serbia

Obuz Funda Professor of Radiology, Division of Abdominal Imaging, Dokuz Eylul University School of Medicine, Izmir, Turkey

Onur Mehmet Ruhi Associate Professor, University of Hacettepe Faculty of Medicine Department of Radiology, Turkey

Orguc Sebnem Professor of Radiology, Celal Bayar University, Izmir,Turkey

Ozmen Mustafa Professor of Radiology, Hacettepe University,Ankara ,Turkey

Palkó András Professor of Radiology, Department of Radiology, Szeged University Medical School University of Szeged, Szeged Hungary

Papadaki Efrosini Ass. Professor of Radiology, Neuroradiology, University Hospital of Heraklion,Crete Greece

Papaioannou Sofia Consultant Radiologist Papageorgiou Hospital Thessaloniki, Greece

Papanikolaou Nickolas Head of the Computational Clinical Imaging Group Champalimaud Foundation, Centre for the Unknown, Lisbon, Portugal

Peteinarakis Ioannis Radiologist, Head of Imaging Department, University Hospital of Heraklion

Prassopoulos Panos Professor of Radiology Aristotle University of Thessaloniki , Department of Radiology AHEPA Hospital Thessaloniki , Greece

Sabir Nuran Professor of Radiology , Pamukkale University Hospital Radiology, Denizli ,Turkey





Sarajlic Vesna Subspecialist in vascular and interventional radiology, Clinic of Radiology, University Clinical Centre in Sarajevo, Bosnia and Herzegovin

Secil Mustafa Professor of Radiology, Department of Radiology, Dokuz Eylül University School of Meidicine, İzmir, Turkey

Sirakov Staminir Associate Professor of Radiology ,UH St Ivan Rilski, Department of Radiology,Sofia Bulgaria

Sotirović-Seničar Slavica Radiologist, Department of Urological Surgery Poliklinika Euromedica NS,Serbia

Spanakis Konstantinos Radiologist, Department of Medical Imaging, University Hospital, of Heraklion, Crete, Greece

Spirovski Milena Radiologist,Oncology Institute of Vojvodina, Department of Diagnostic Imaging Center, Sremska Kamenica,Serbia

Stojanovic Sanja Professor of Radiology,Head of Department of Interventional Radiology Clinical Center of Vojvodina, Department of Radiology, Novi Sad Serbia

Stojanovska –Jovanovska Elizabeta Radiologist JZU University Institute of Radiology, Department of Uroradiology, Str. Belgradska bb, 1000 Skopje, Republic of North Macedon ia

Tavernaraki Kyriaki Consultant Radiologist, “Sotiria” General And Chest Diseases Hospital Athens,Department of Imaging and Interventional Radiology,Athens Greece

Totev Milan Professor of Radiology, Head of Diagnostic Imaging Clinic, Sofia, Bulgaria

Traykova Nikoleta Associate Professor of Radiology, UMHAT St George, Department of Radiology, Plovdiv, Bulgaria

Triantopoulou Charikleia Radiologist, Head of Radiology Department, “Konstantopouleion” General Hospital, Athens, Greece





Tsetis Dimitrios Professor of Radiology, Head, Unit of Vascular and Interventional Radiology, Department of Radiology, University Hospital of Heraklion, Crete, Greece

Tsili Athina Assistant Professor of Radiology, Department of Clinical Radiology, Medical School, University of Ioannina

Tsitouridis Ioannis Director of Radiology Department, Papageorgiou Hospital of Thessaloniki, Greece

Tunaci Atadan Professor of Radiology; Department of Radiology, Director of Thoracic Imaging Section, Istanbul University, Istanbul Turkey

Uberoi Raman Consultant Interventional Radiologist, The John Radcliffe Hospital Oxford, UK

Vasilevska –Nikodinovska Violeta Professor of Radiology, Medical Faculty, University "Ss.Cyril and Methodius" Skopje, Macedonia
Head of Radiology department, at University Surgical Clinic „St.Naum Ohridski“ Skopje

Vjolca Aliji Neuroradiologist, Neurovascular and Vascular Interventional Radiology, University Institute of Radiology, Skopje, RNM

Vlychou Marianna Professor of Radiology, School of Medicine, Larissa, University of Thessaly, Greece

Vucaj – Cirilovic Viktorija Professor of Radiology Institut of Oncology Vojvodina, Department of Imaging center, Novi Sad Serbia

Xydis Vasileios Lecturer of Radiology, Medical School, Ioannina Greece

Yarmenitis Spyridon Ass. Professor of Radiology, Director, Department of Radiology, Hygeia Hospital, Athens Greece

Zlatareva Dora Professor of Radiology, Department of Diagnostic Imaging, Sofia Bulgaria



PERIPHERAL GUIDEWIRE PORTFOLIO

BELOW THE KNEE

**ABOVE
THE REST**

Empowering you to treat challenging BTK cases with a suite of dedicated guidewires



Raising the Level of
Core Needle Biopsy Since 1987

Proven
Powerful
Precise



BAIRD Biopsy

 **BD** **BAIRD**
has joined BD



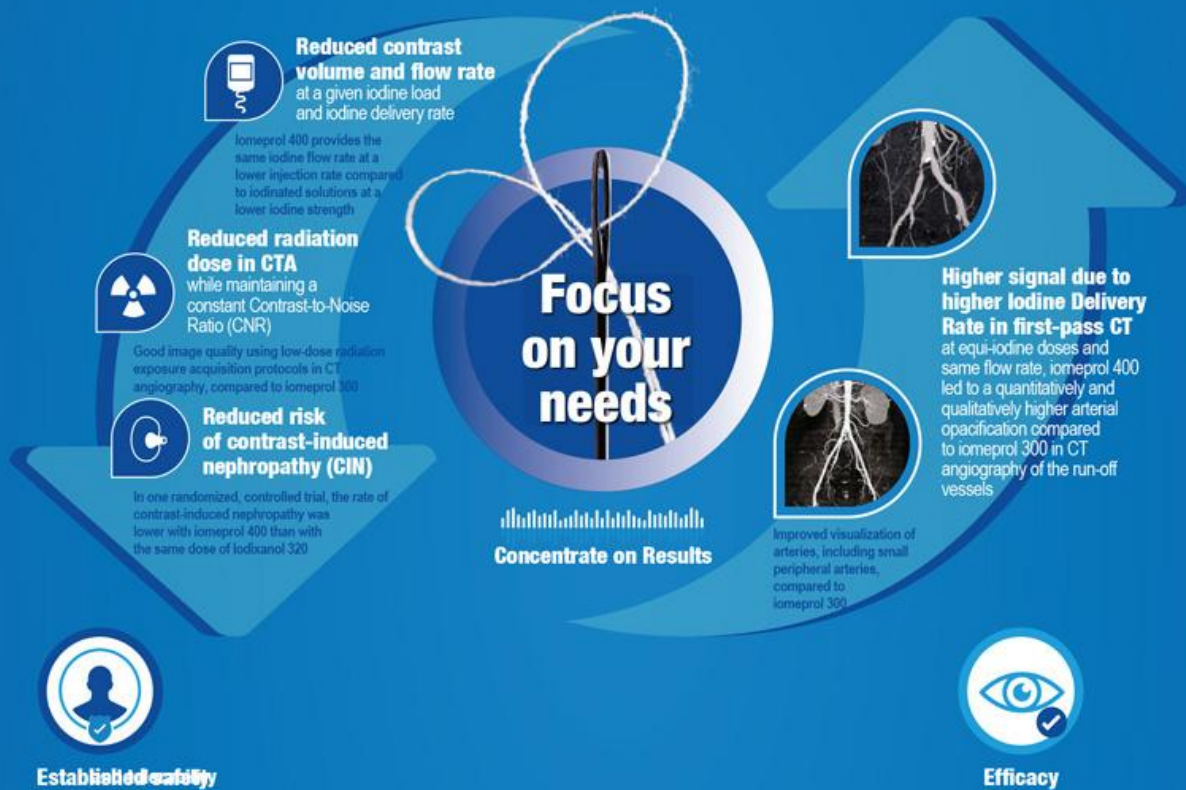


400
iomeron

High concentration,
focus on your needs



LIFE FROM INSIDE



Iomeron[®] is a tri-iodinated non-ionic monomeric contrast medium for radiology.

Iomeron has unique characteristics, such as:

- the lowest viscosity at a given concentration among iso-osmolar contrast media (IOCM) and low-osmolar contrast media (LOCM)
- the lowest osmolality among monomeric LOCM
- one formulation with the highest iodine concentration (400 mgI/mL) available on the market

Α. Πηγής 33 & Αναπήρων Πολέμου 6
151 27 Μελίτσια, Αθήνα
Τ. 210 6199886
www.leriva.com

Leriva
Pharma