

2024-05-09 22:44:09

ESTI 2024 Annual Scientific Meeting, Rome/IT, May 09-11, 2024

Type: Educational Poster
Abstract no.: A-198
Status: submitted
ePoster: submitted

Imaging Insights: Computed Tomography presentation of thoracic hydatid cysts in North Macedonian patients

S. Nikolova

Institute of Radiology, Skopje, North Macedonia, Thoracic and Vascular Radiology, Skopje, North Macedonia

Learning Objectives

This study endeavors to achieve several key objectives to enrich the comprehension and help gain proficiency in identifying and interpreting a spectrum of thoracic hydatid disease manifestations on Computed Tomography, ranging from common to rare presentations. Furthermore, the study aims to enhance practitioners' capability in recognizing potential complications and mastering the intricacies of differential diagnosis in this context.

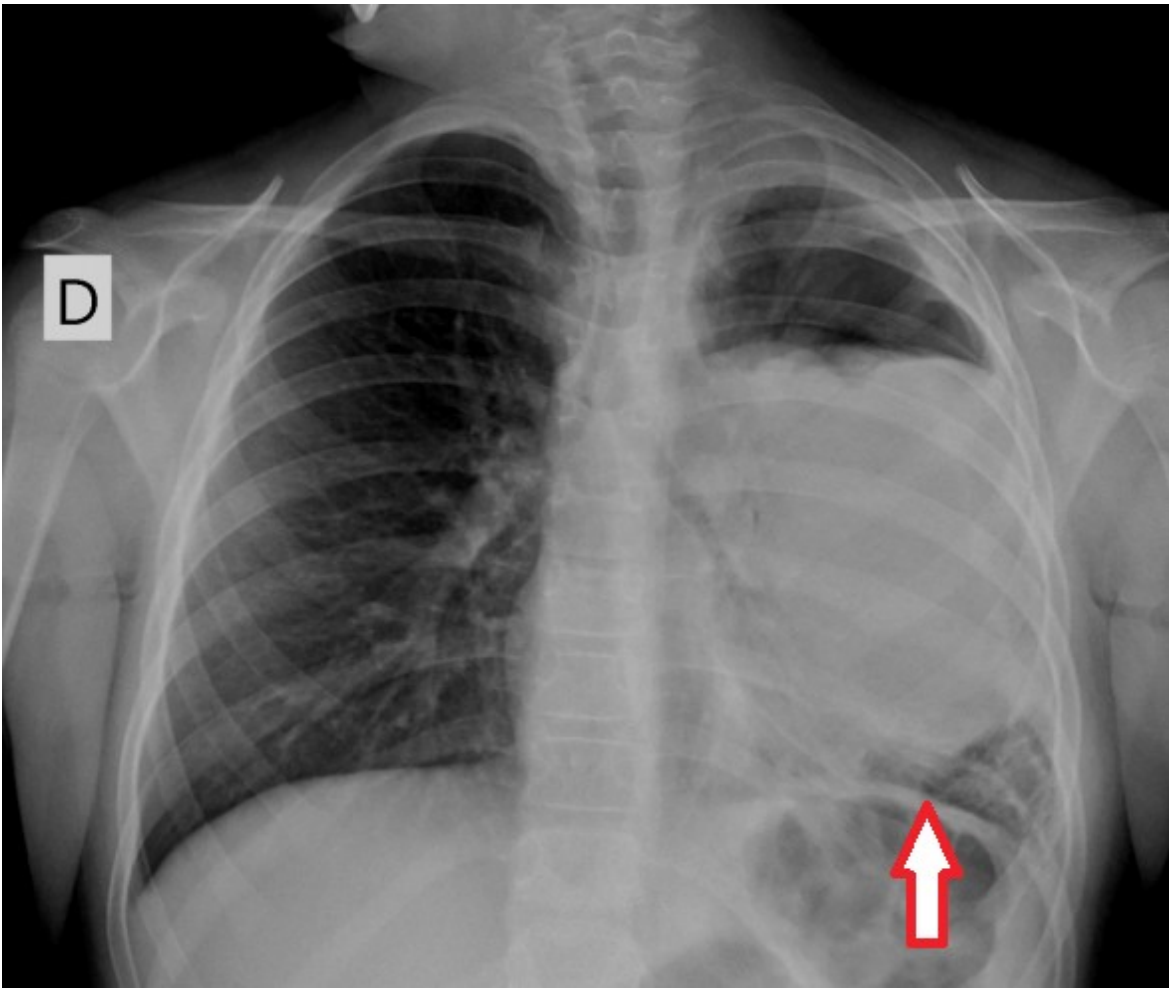
Background

Delving into the complex realm of hydatid cysts, originating from the larval form of Echinococcus, this research addresses a pressing global challenge[1][2]. While traditionally associated with liver parenchyma, the disease's manifestation in atypical thoracic locations, including the mediastinum and pleural space, necessitates a sophisticated diagnostic approach. This article provides a contextual exploration, shedding light on the endemic nature of hydatid disease, particularly prevalent in regions associated with sheep breeding, and underscores the urgency for precise diagnostic tools.

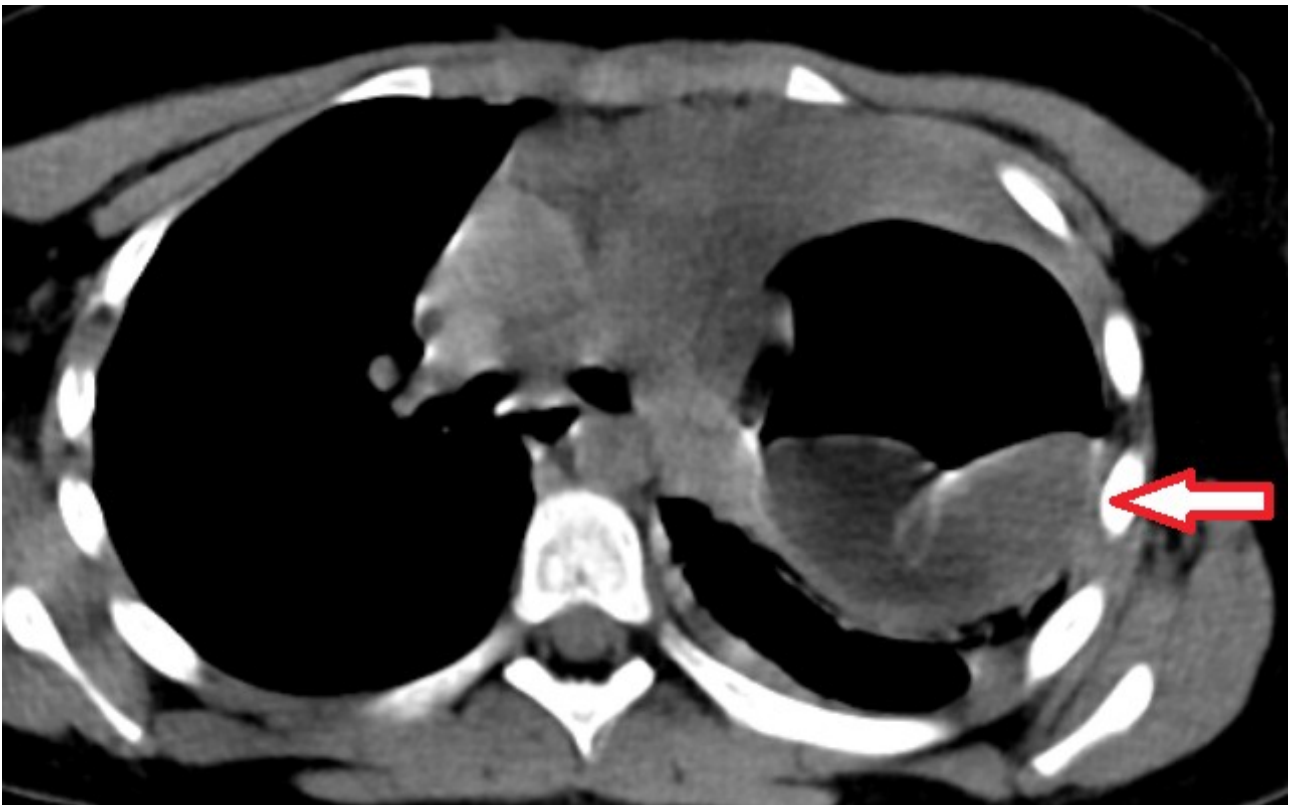
CT not only aids in accurate diagnosis but also provides unparalleled insights into the exact size, location, and internal structure of hydatid cysts, crucial for comprehensive patient management[3]. Moreover, it stands as the primary modality for predicting potential complications, such as cyst rupture, by offering a detailed view of cyst morphology[4][5].

Imaging findings OR Procedure details

In a meticulous analysis of 55 chest CT scans from patients in North Macedonia with thoracic hydatid cysts, this study unveils compelling imaging findings. Categorizing cysts into uncomplicated parenchymal, extra-parenchymal, and complicated or ruptured forms, the research reveals distinct signs, including the air crescent sign, water lily sign, and dry cyst sign

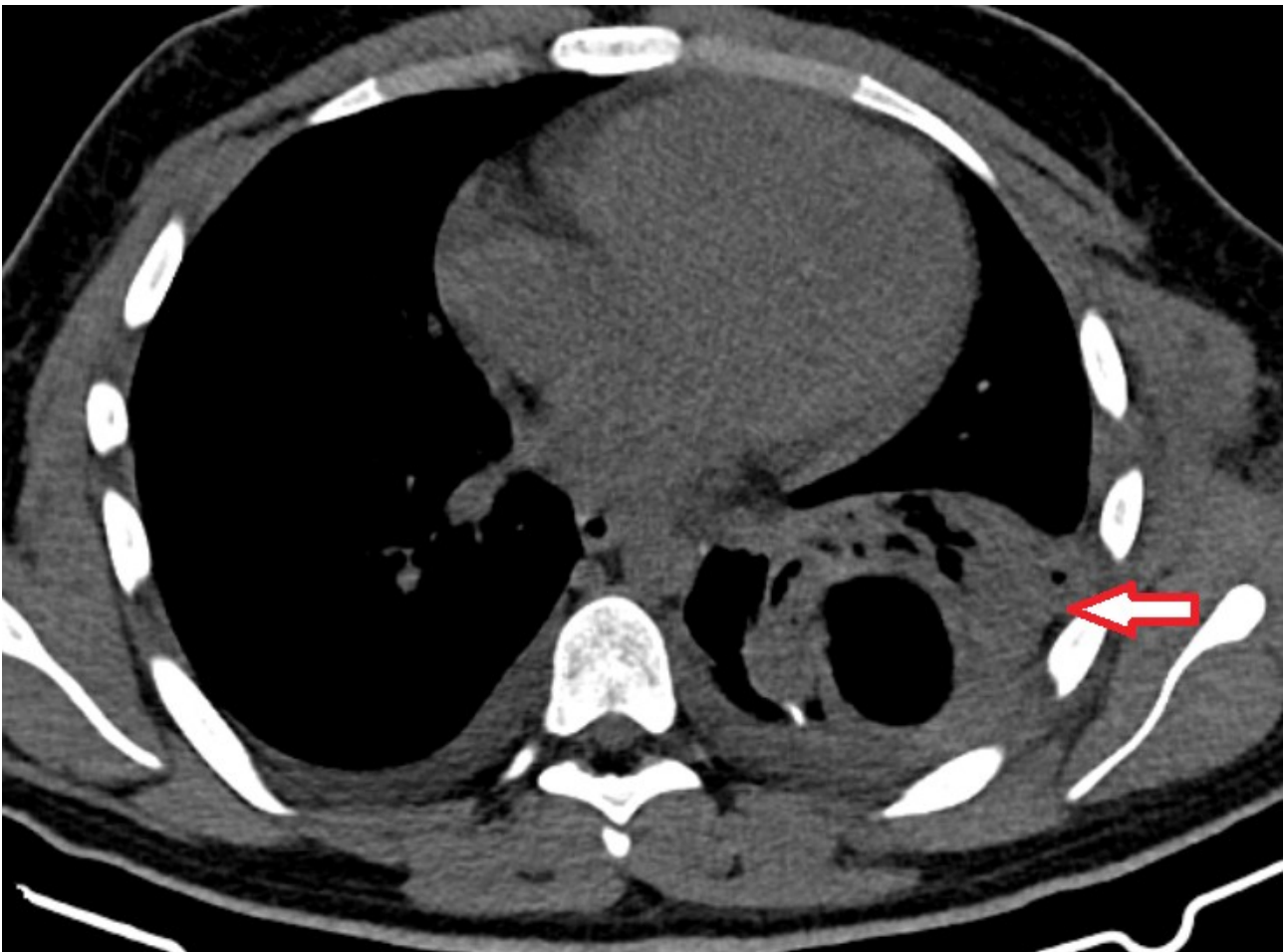


Posterior-Anterior (PA) projection chest x-ray reveals complicated hydatid cyst in the lower left lobe, highlighting cumbus or double arch sign



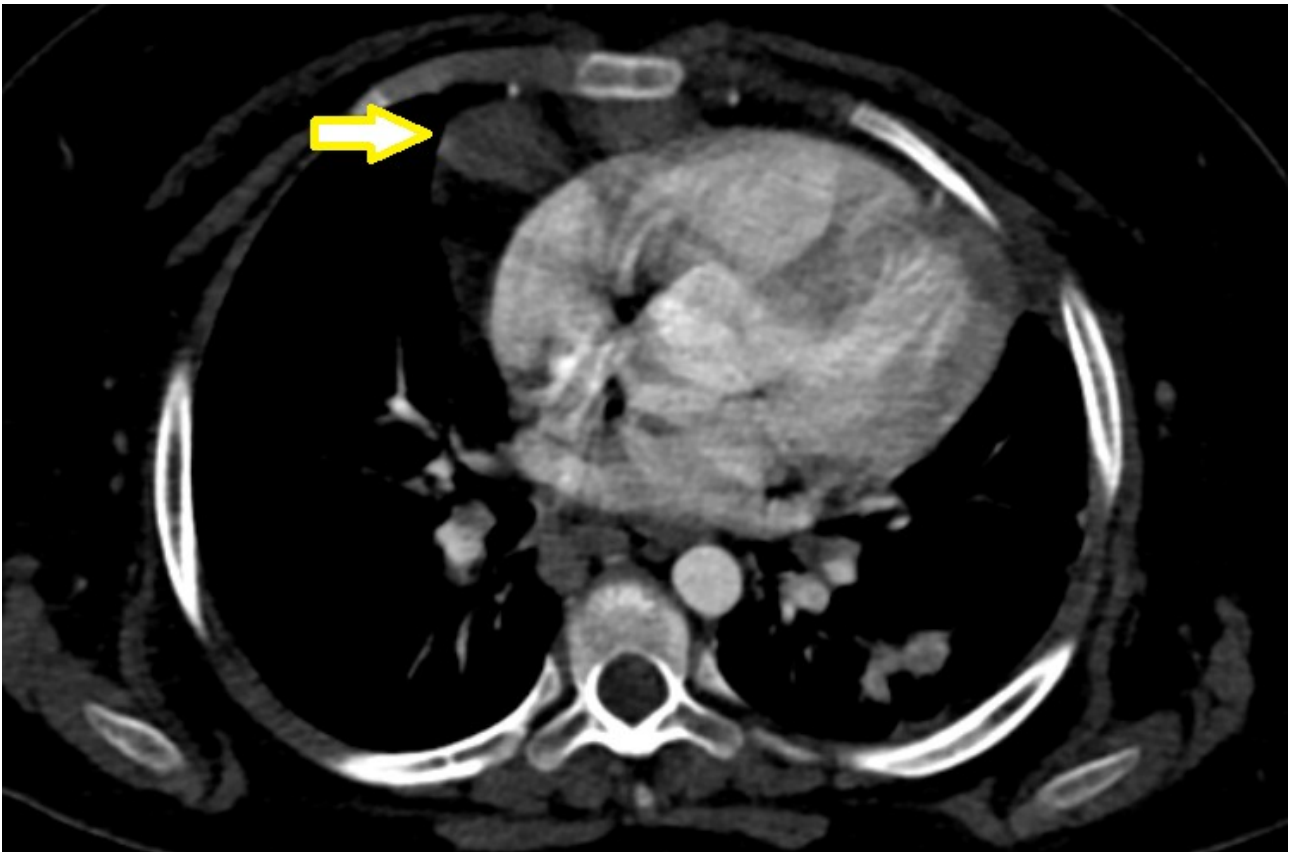
Axial CT image captures complicated, ruptured hydatid cyst in mediastinal window, showcasing the classic 'water lily sign' with ruptured

membranes afloat on fluid surface



Axial CT image displays complicated, ruptured hydatid cyst with fully expectorated fluid, crumpled endocyst settling at the cyst base, resembling a 'mass within a cavity.' Noteworthy surrounding features include reactive pneumonia and mild bilateral pleural effusion

. Uncommon extra-parenchymal locations, such as the mediastinum and pericardium, add a layer of complexity



Unconventional location of an uncomplicated hydatid cysts in inferior anterior mediastinum, attached to the pericardium at the level of the right ventricle, axial CT image

. Emphasizing the pivotal role of CT in diagnosing, sizing, and locating hydatid cysts, this section offers valuable insights into both prevalent and rare scenarios.

Conclusion

In summary, this research underscores the critical role of computed tomography in unraveling the complexities of thoracic hydatid cysts. Beyond its contribution to identifying common manifestations, CT emerges as an indispensable tool for deciphering rare, atypical, and complicated presentations. The information provided by CT scans not only facilitates accurate diagnosis but also deepens our understanding of cyst morphology, aiding in predicting potential complications or rupture. The knowledge derived from this study stands poised to elevate diagnostic practices and enrich the collective understanding of thoracic hydatid disease.

References

- [1] Khuroo, M. S. , (2002), Hydatid disease: current status and recent advances, *Ann Saudi Med*, 56-64, 22
- [2] King, C. H. , (1995), *Cestodes (tapeworms). Principles and practice of infectious diseases*, 4th Ed., Churchill Livingstone, NY, New York, 2544- 2553
- [3] Mehta, P., Prakash, M. & Khandelwal, N. , (2016), Radiological manifestations of hydatid disease and its complications, *Trop Parasitol*, , 103-112, 6, <https://www.ncbi.nlm.nih.gov/pmc/articles/PMC5048696/>, 2024-01-01
- [4] Durhan G, Tan AA, Düzgün SA, Akkaya S, Ariyürek OM. , (2020), Radiological manifestations of thoracic hydatid cysts: pulmonary and extrapulmonary findings., *Insights Imaging.*, 116, 11(1), <https://www.ncbi.nlm.nih.gov/pmc/articles/PMC7658283/>, 2024-01-01
- [5] Garg MK, Sharma M, Gulati A, Gorsli U, Aggarwal AN, Agarwal R, Khandelwal N. , (2016), Imaging in pulmonary hydatid cysts, *World J Radiol.*, 581-7, 8(6), <https://www.ncbi.nlm.nih.gov/pmc/articles/PMC4919757/>, 2024-01-01

Authors

First author: Sonja Nikolova

Presented by:
Submitted by:

Sonja Nikolova
Sonja Nikolova