




# Unusual initial presentation of prostate adenocarcinoma with inguinal lymph nodes metastases: a case report

Maja Sofronievska Glavinov <sup>1,\*</sup>, Rubens Jovanovic <sup>2</sup>, Venjamin Majstorov<sup>3</sup>, Jovo Burneski<sup>4</sup> and Andrej Nikolovski <sup>5</sup>

<sup>1</sup>Faculty of Medical Sciences, University “Goce Delcev”, 2000, Stip, North Macedonia and University Surgery Hospital “St. Naum Ohridski”, Department of Urology, 11 Oktomvri 53, Skopje, North Macedonia

<sup>2</sup>Institute of Pathology, Medical Faculty, University “Ss. Cyril and Methodius University in Skopje”, Skopje, North Macedonia

<sup>3</sup>Institute of Pathophysiology and Nuclear Medicine, Medical Faculty, University “Ss. Cyril and Methodius University in Skopje”, Skopje, North Macedonia

<sup>4</sup>Department of Surgery, General Hospital “Borka Taleski”, Prilep, North Macedonia

<sup>5</sup>Medical Faculty, “Ss. Cyril and Methodius University in Skopje”, 1000 Skopje, North Macedonia and Department of Visceral Surgery, University Surgery Hospital “St. Naum Ohridski”, 11 Oktomvri 53, Skopje, North Macedonia

\*Correspondence address. Faculty of Medical Sciences, University “Goce Delcev”, 2000, Stip, North Macedonia and University Surgery Hospital “St. Naum Ohridski”, Department of Urology, 11 Oktomvri 53, Skopje 1000, North Macedonia. Tel: +38970333958; Fax: +38923235020; E-mail: maja.sofronievska@ugd.edu.mk

## Abstract

The presence of lymph node metastases in prostate adenocarcinoma is a poor prognostic sign, and mortality rates are often high. Inguinal lymph node metastases are an unusual presentation of advanced disease, and they can be easily misinterpreted with other diseases. We present a case of a 63-year-old patient with no previous symptoms and signs of prostate disorder with a right-sided inguinal lump and abdominal pain. The CT scan showed right inguinal and retroperitoneal lymphadenopathy. Elevated PSA serum levels, digital rectal examination, and skeletal scintigraphy with <sup>99m</sup>Tc-MDP favored the diagnosis of metastatic prostate adenocarcinoma. Since the patient denied prostate biopsy, a dissection of the right inguinal nodes was performed. Histopathological findings confirmed metastatic prostate adenocarcinoma. The treatment was hormonal and bisphosphonate therapy, with objective posttreatment improvement. Based on this case, it can be concluded that inguinal and generalized lymphadenopathy are potential initial manifestations of metastatic prostate adenocarcinoma in male patients.

**Keywords:** prostate adenocarcinoma, inguinal lymphadenopathy, metastases, case report

## INTRODUCTION

Prostate adenocarcinoma is the most common cancer in men, with the highest incidence rate in eight decades. It is usually clinically diagnosed through symptoms and routine total PSA serum level measurements, but in some cases, patients may not present with symptoms or signs of the disease. The local spread of prostate adenocarcinoma follows extra-capsular spread to adjacent structures such as the seminal vesicles and/or the bladder. The presence of lymph node metastases is a poor prognostic sign, and mortality rates are often higher in those with nodal involvement [1].

The incidence of enlarged non-regional lymph nodes in patients presenting with prostate adenocarcinoma is the highest of the medial external iliac (obturator) nodes (75%), followed by nodes in the para-aortic region (26%) and anterior internal iliac region (24%). The incidence of enlarged lymph nodes in the lateral external iliac group is 18%, and the incidence of inguinal lymph node involvement is 9% [2]. This unique lymphatic spread of prostate carcinoma can be explained by the involvement of the rectum below the dentate line, which can be the source of metastasis to inguinal lymph nodes [3].

Inguinal adenopathy is most often the result of sexually transmitted diseases, non-venereal infections, and malignancies (lymphoma, melanoma, genital) [4]. Generalized lymphadenopathy with no urinary symptoms can be misinterpreted as malignant lymphoma [1, 5].

We present a case of a 63-year-old patient with no symptoms and signs of prostate disorder presenting with right-side inguinal lymphadenopathy as the first and unusual presentation of metastatic prostate adenocarcinoma.

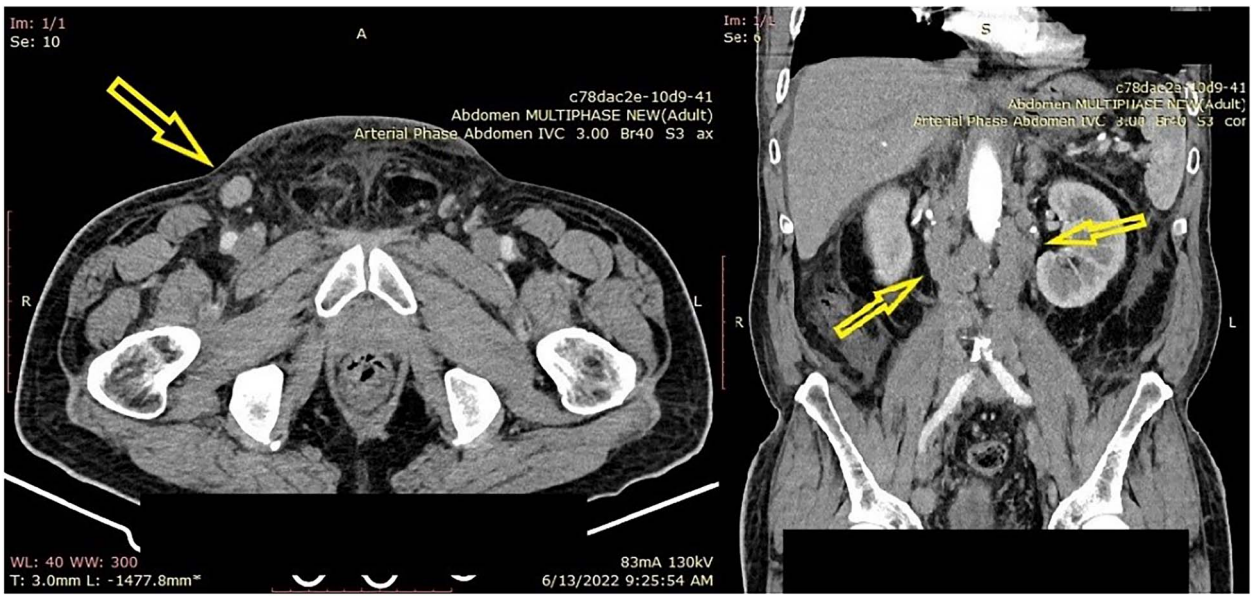
## CASE REPORT

A 63-year-old patient with diffuse abdominal pain and a lump in the right groin was admitted to the digestive surgery ward. The groin lump was present for one month before hospital admission and abdominal pain was sudden and a reason for emergency assessment. He never had urinary problems, never visited a urologist before, and had a negative family history of cancer. The patient has never had surgery on either the abdomen or the right groin. Biochemical analyses of blood and urine were performed, which showed an elevation in the CRP value (10 mg/l)

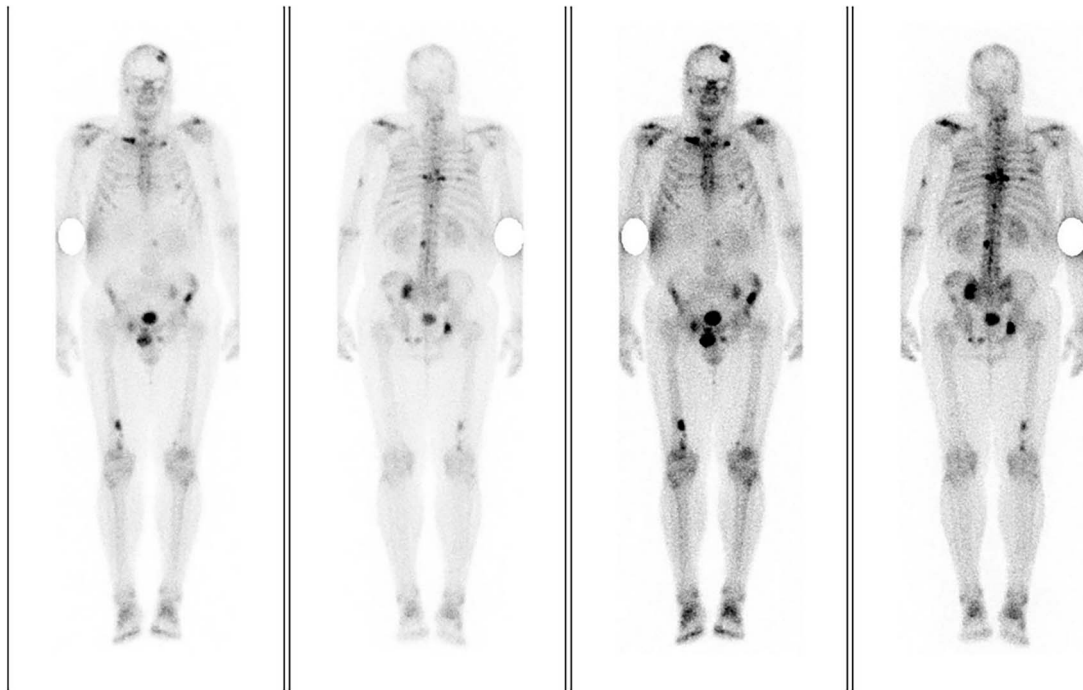
Received: December 29, 2023. Revised: February 15, 2024. Accepted: February 27, 2024

© The Author(s) 2024. Published by Oxford University Press.

This is an Open Access article distributed under the terms of the Creative Commons Attribution Non-Commercial License (<https://creativecommons.org/licenses/by-nc/4.0/>), which permits non-commercial re-use, distribution, and reproduction in any medium, provided the original work is properly cited. For commercial re-use, please contact [journals.permissions@oup.com](mailto:journals.permissions@oup.com)



**Figure 1.** (A) Enhanced computed tomography (CT) scan of the abdomen and pelvis, axial view, showing right inguinal lymphadenopathy (arrow). (B) Coronal view of the enhanced CT scan of the abdomen showing retroperitoneal lymphadenopathy (arrow).



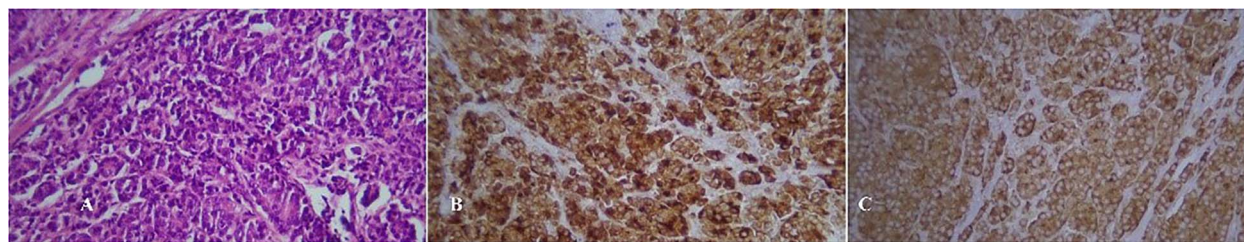
**Figure 2.** Skeletal scintigraphy with  $^{99m}\text{Tc}$ -MDP showing bone metastases (marked dark with concentrated radiotracer).

and serum tumor marker assessment showed an increase in CEA (5.87 ng/ml) and total serum PSA (>400 ng/ml). Findings from the physical examination included a hard, immobile mass in the inguinal region and a soft, painful abdominal wall when deeply compressed. The digital-rectal examination showed hardening of the prostate, especially the right lobe, and the absence of sulci, but the patient declined prostate biopsy. An enhanced CT scan of the abdomen showed generalized lymphadenopathy with enlarged retroperitoneal, para-aortic, para-caval, mesenteric, peripancreatic, iliac, and especially right-sided inguinal lymph nodes (Fig. 1).

Skeletal scintigraphy with  $^{99m}\text{Tc}$ -MDP showed multiple focal pathological accumulations of the radiotracer in the

frontoparietal left and parietal calvaria, in the right zygomatic bone, in both clavicles, in the central diaphysis of the left humerus, in the left scapula, in the 5<sup>th</sup>, 6<sup>th</sup> and 9<sup>th</sup> ribs from left hemithorax, in 7<sup>th</sup>, 8<sup>th</sup> and 9<sup>th</sup> ribs from right hemithorax, in Th-8, Th-11 and L-3 vertebrae, sacroiliac left, in left iliac bone in the crista anterior, in the right and left ischial bones and in the distal meta diaphysis of the right femur (Fig. 2).

A surgical dissection of the right inguinal lymph nodes was performed to establish the final diagnosis. Histopathological analysis revealed a metastasis of prostate adenocarcinoma in the right inguinal lymph nodes (Fig. 3). According to the TNM classification, the patient was in stage IVb (T3N1M1b).



**Figure 3.** (A) Hematoxylin-eosin stain of lymph node metastasis. (B) Immunohistochemical staining positivity for PSA. (C) Immunohistochemical staining positivity for PAP.

**Table 1.** Literature review of reported cases of inguinal lymphadenopathy as initial presentation in prostate adenocarcinoma

Reference number	Author	Year	Patients' age	Sidedness	LUTS	PSA
[5]	Elsaqa et al.	2019	53	Bilateral	Mild obstructive	35 ng/ml
[6]	Tunio et al.	2011	66	Bilateral	Frequency	108 ng/ml
[7]	Doreswamy et al.	2015	66	Left	Frequency, dysuria, weak stream	>50 $\mu$ g/l
[8]	Slavis et al.	1990	60	Left	Not reported	-
[9]	Huang et al.	2003	77	-	Not reported	7.8 ng/mL
[10]	Rosa M et al.	2007	47	-	Not reported	528.90 ng/ml
This report	Sofronievska et al.	2024	63	Right	None	>400 ng/ml

LUTS—lower urinary symptoms; PSA -prostate specific antigen.

The patient underwent treatment by an oncologist with hormonal and bisphosphonate therapy (Goserelin 10.8 mg once daily, Bicalutamide 50 mg once daily, and Zoledronic acid 4 mg once monthly) immediately after surgery discharge. Three weeks after oncological treatment, total PSA serum levels decreased to 43 ng/ml and 5 ng/ml after two months. Post radiation the patient expressed lower urinary symptoms of dribbling and hesitancy, which were treated with alpha one blocker and after two weeks the symptoms were improved. The patient's oncological treatment is ongoing, and an enhanced abdominal CT scan is the further follow-up after 6 and 12 months, and skeletal scintigraphy after 12 months.

## DISCUSSION

In the case presented, right-side inguinal node enlargement with retroperitoneal lymphadenopathy, including the absence of lower urinary tract symptoms, is the uncommon initial presentation of advanced prostate cancer. The manifestation of metastatic prostate adenocarcinoma is seldom associated with metastases to soft tissue or non-regional lymph nodes [1].

The first of three common lymphatic routes of prostate cancer spread is through the lateral route to the obturator nodes (the medial chain of the external iliac) and the middle and lateral chains of the external iliac nodes. The second-line spread is the internal iliac (hypogastric) route. Seldom lymphatic drainage can also occur along an anterior way via nodes located anterior to the urinary bladder and a presacral course anterior to the sacrum and the coccyx [6].

The literature assessment was performed to find similar cases of this unusual presentation of metastatic prostate adenocarcinoma. Using the keywords 'prostate adenocarcinoma,' 'inguinal lymphadenopathy,' and 'initial presentation,' an advanced search of PubMed, Cochrane Library, and Medline revealed six reports in English (Table 1). In two published cases, there was a

bilateral inguinal metastatic lymphadenopathy [7, 8], and two of the published cases had isolated left inguinal node metastases [4, 9]. Lower urinary tract symptoms are not obliged in all cases of metastatic prostate adenocarcinoma. Some patients complain of mild obstructive symptoms [7] and frequency [8, 9] or do not initially present any lower urinary tract symptoms [5, 10]. Besides urinary symptoms assessment, measuring total PSA serum levels and digital rectal examination remains a 'gold standard' in diagnosing prostate adenocarcinoma. In similar reported cases the total PSA serum levels were not equally significantly raised; some patients have had a 'grey zone' PSA [10] and others have had extremely elevated PSA [5, 8] as did the patient in this case report.

Inguinal metastases in prostate adenocarcinoma are unusual initial presentations of metastatic disease, suggesting poor prognosis in which early detection is a favorable factor in patient survival.

## CONCLUSION

The reported case is significant and emphasizes the importance of a thorough clinical search in elderly male patients by a complete physical examination, including palpation of the inguinal region and measuring serum PSA levels. Prostate adenocarcinoma can be initially presented only with inguinal lymphadenopathy in adult male patients that can be easily misinterpreted with other conditions.

## SUPPLEMENTARY MATERIAL

Supplementary material is available at the *Journal of Surgical Case Reports* online.

## CONFLICT OF INTEREST STATEMENT

No conflict of interest.

## FUNDING

None.

## ETHICAL APPROVAL

The publishing of the case report was approved by the Ethical Board of the institution where the patient was referred.

## CONSENT

A written consent of participation and publishing was obtained from the patient.

## GUARANTOR

Andrej Nikolovski (AN), Department of Visceral Surgery, University Surgery Hospital 'St. Naum Ohridski', 11 Oktomvri 53, Skopje 1000, North Macedonia. E-mail: andrejnikolovski05@gmail.com; ORCID: <https://orcid.org/0000-0002-5286-3532>.

## REFERENCES

1. Dattani SMT, Yamada ML, Dhoot NM, Ghazala G, Levene A, Som-sundaram R. Metastatic prostate cancer presenting as incidental pelvic lymphadenopathy—a report of three cases with literature review. *Radiol Case Rep* 2022;**17**:2247–52.
2. Paño B, Sebastià C, Buñesch L, Mestres J, Salvador R, Macías NG. et al. Pathways of lymphatic spread in male urogenital pelvic malignancies. *Radiographics* 2011;**31**:135–60.
3. Jackson ASN, Sohaib SA, Staffurth JN, Huddart RA, Parker CC, Horwich A. et al. Distribution of lymph nodes in men with prostatic adenocarcinoma and lymphadenopathy at presentation: a retrospective radiological review and implications for prostate and pelvis radiotherapy. *Clin Oncol (R Coll Radiol)* 2006;**18**:109–16.
4. Shah VA, Rixey A, Dusing R. Prostate cancer metastases to inguinal lymph nodes detected by attenuation-corrected 11 C-acetate PET/CT. *J Nucl Med Technol* 2016;**44**:46–8.
5. Elsaqa M, Sharafeldeen M, Elabbady A. Metastatic prostate cancer presenting with bilateral inguinal lymphadenopathy. *Clin Genitourin Cancer* 2019;**17**:e1185–7.
6. Tunio M, Hashmi A, Raza SS. Metastatic prostate adenocarcinoma presenting with bilateral inguinal adenopathy. *J Surg Pak* 2011;**16**:85–7.
7. Doreswamy K, Karthikeyan VS, Nagabhushana M, Shankaranand B. Prostatic adenocarcinoma presenting as isolated inguinal lymphadenopathy. *BMJ Case Rep* 2015;**2015**:bcr2015210825.
8. Slavis SA, Golji H, Miller JB. Re: carcinoma of the prostate presenting as inguinal adenopathy. *Cleve Clin J Med* 1990;**57**:97–7.
9. Huang E, Teh BS, Mody DR, Carpenter LS, Butler EB. Prostate adenocarcinoma presenting with inguinal lymphadenopathy. *Urology* 2003;**61**:463.
10. Rosa M, Chopra HK, Sahoo S. Fine needle aspiration biopsy diagnosis of metastatic prostate carcinoma to inguinal lymph node. *Diagn Cytopathol* 2007;**35**:565–7.