



## Unusual Presentation of Vaginal Squamous Cell Carcinoma Mimicking a Cystic Tumor of Wolff Duct or Cyst of Gartner

Antovska Vesna<sup>1</sup>, Dabeski Drage<sup>1</sup>, Zlateska Sofija<sup>1</sup>, Sozovska Eva<sup>1\*</sup> and Ilievski Boro<sup>2</sup>

<sup>1</sup>Department of Gynecology and Obstetrics, Medical School in Skopje, Republic of North Macedonia

<sup>2</sup>Department of Pathology, Medical School in Skopje, Republic of North Macedonia

### Abstract

Primary vaginal cancer is rare, constituting only 1% to 2% of all female genital tract malignancies and only 10% of all vaginal malignant neoplasms. If vaginal malignancy is found in younger women, it is etiologically linked to the persistence of high-risk HPV infections. We report a case of 39-year-old woman presenting with a large cystic inflamed tumor on the left vaginal wall, which open in the lateral vaginal fornix. The biopsy showed the presence of large leukemic papillary carcinoma of the vagina. Unusually, the vaginal mucosa that covered the tumor was intact. According to the localization this structure, clinical presentation and ultrasound picture, this vaginal tumor mimick cystic tumor of Wolff duct or cyst of Gartner.

**Keywords:** Vaginal squamous carcinoma; HPV infection; Wolff duct; Cyst of Gartner

### Introduction

Cancer of the vagina is more common in postmenopausal women. If vaginal malignancy is found in younger women, it is etiologically linked to high-risk HPV infections [1]. Primary vaginal cancer is rare, only 1% to 2% of all female genital tract malignancies and only 10% of all vaginal malignant neoplasms [2]. It is strictly defined as a cancer found in the vagina without clinical or histologic evidence of cervical/vulvar cancer, or a prior history of these cancers within five years [3]. Diagnosis of vaginal cancer is made with directed biopsy of the lesion and clinical assessment that ensures there is no evidence of tumor on the cervix or the vulva. The predominant histological subtype in primary vaginal cancer is squamous carcinoma (90% of cases). In primary vaginal tumors, clinical assessment may be difficult, so MRI is a useful tool, owing to its superior soft tissue resolution. MRI is more sensitive in detecting tumor size, as well as paravaginal or parametrial involvement [4]. A vaginal tumor may extend to the surrounding pelvic soft tissue structures, including paravaginal tissue, parametria, urethra, bladder, and rectum. Most tumors occur in the upper third of the vagina, especially the posterior wall [5].

The role of surgery is limited in primary vaginal cancer since the primary tumor is in close proximity to the bladder, urethra, and rectum. In general, primary treatment with surgery is limited to early and small lesions confined to the vaginal mucosa (less than 2 cm). In the majority of cases, especially in advanced stages, radiation constitutes the cornerstone of treatment, as a combination of External Beam Radiation (EBRT) and Intracavitary Radiotherapy or Brachytherapy (ICRT). The optimal/lower threshold dose is 70 Gy, because doses higher than 70 Gy result in significant grade 3/4 toxicities. Intensity Modulated Radiation Therapy (IMRT) is an advanced form of radiation that allows for higher dosages of radiation to be delivered to the cancer. Although studies in vaginal cancer are limited, this form of radiation may allow improved dosages to the cancer, with fewer adverse effects because dose to the adjacent structures is limited. Modern management of vaginal cancer often combines concurrent chemotherapy with cisplatin or 5FU.

The main determinant of prognoses in carcinoma of the vagina is the stage of disease at the time of diagnosis, independently of subjacent histology. Additional factors influencing prognosis in squamous subtype are the tumor volume (>4 cm), its location outside of the upper third of the vagina, HPV status. A recent review from Gadducci et al. [6], summarized the data for 5-year overall survival, which varies between 35% and 78%, and a severe late complication rate, which varies between 9.4% and 23.1% among cases of squamous vaginal carcinoma treated with radiotherapy.

### OPEN ACCESS

#### \*Correspondence:

Sozovska Eva, Department of Gynecology and Obstetrics, Medical School in Skopje, Bul. Vodnjanska bb. Skopje, Republic of North Macedonia, Tel: +0038971261048; E-mail: esozovska@yahoo.com

Received Date: 20 Sep 2021

Accepted Date: 04 Oct 2021

Published Date: 15 Oct 2021

#### Citation:

Vesna A, Drage D, Sofija Z, Eva S, Boro I. Unusual Presentation of Vaginal Squamous Cell Carcinoma Mimicking a Cystic Tumor of Wolff Duct or Cyst of Gartner. *J Gynecol Oncol.* 2021; 4(4): 1068.

**Copyright** © 2021 Sozovska Eva. This is an open access article distributed under the Creative Commons Attribution License, which permits unrestricted use, distribution, and reproduction in any medium, provided the original work is properly cited.

## Case Presentation

We present a 39-year-old woman with a big palpable swelling in the right side of the vagina. The patient had 3 unsuccessful pregnancies: Two miscarriages and one extra uterine pregnancy, which was treated with Methotrexate. She had not any live child. The main symptoms included: Leaky purulent discharge with a strong-unpleasant odor, fever, bleeding not related to menstrual periods, painful urination, and pelvic pain. They dated from 2 weeks ago. The patient has been receiving antibiotic therapy for the last 10 days. The last PAP from a few months ago did not show the presence of malignant cells. Laboratory tests showed marked leukocytosis and an increase in CRP in addition to the primary infection.

Vaginal examination revealed the presence of a large formation on the right side of the vagina, more located back and in close contact with the rectum, which was cystic on palpation, but in its lower part there are several nodules the size of a walnut. The tumor formation was covered with intact vaginal mucosa with unchanged color, without any erosion. At the level of the right vaginal fornix, a small opening measuring 1 cm with an unchanged edges was shown, from which spontaneously or under pressure on the tumor, a foul-smelling purulent discharge flowed. This opening mimicked the opening of a fistula, so the examination was directed in that direction. To the left of this opening presented unchanged uterine cervix, and the patient was not bleeding from the uterus.

Ultrasound examination with the vaginal probe, at the level of the right lateral wall of the vagina, showed a large cystic formation with a diameter of 8 cm filled with thick fluid, whose walls were up to 2 cm thick and from which thick papillae were projected to the inside of the cyst. According to the localization, this structure best corresponded to cystadenoma/cystadenocarcinoma of the Wolff duct or cyst of Gartner.

On the rectal digital examination, the rectal mucosa was intact. The discharge from the opening in the vaginal fornix did not contain feces. These two abovementioned facts excluded the presence of recto-vaginal fistula. The clinical finding of a fluctuating paravaginal inflammatory tumor was also suspected for presence of pararectal abscess. Therefore, 3 abdominal surgeons were consulted, but they could not rule out the existence of such an abscess. To rule out inflammatory bowel diverticulitis, a colonoscopy was performed, which showed a protrusion of the rectal wall as a result of extraluminal compression. The rectal mucosa was intact. Computed tomography showed the presence of a large infiltrative lesion at the level of the vagina, a conglomerate of lymph nodes paracavally with a diameter of 48 mm × 46 mm.

The microbiological swab from the discharge showed a multitude of bacteria, so antibiotics were given per antibiogram. Papanicolaou cytological swab taken from the edges of the opening in the right vaginal fornix did not show the presence of malignant cells.

To confirm the diagnosis, the patient underwent a biopsy of the vaginal tumor in the operating room. In order to enable easier drainage of the purulent contents, the incision line was made at the lowest point where there was fluctuation. A 1.5 cm long incision was made with a thermocauter and immediately papillomatous crumbly structures began to fall out of the opening, very suspicious of a malignant process. They were sent for histopathological analysis.

The histopathological diagnosis was planocellular papillary carcinoma of the vagina. The description stated: Papillary structures of atypical cells of epithelial origin with sparse pale eosinophilic cytoplasm are present and they are arranged in more than 10 rows. Immunohistochemical analysis showed the following immunoprofile: CK5/6(+), CK AE. AE3(+), CK7(-), CK20(-), p63(+), EMA(+), GATA3(-). According to the described morphology and the performed immunohistochemical analysis, the finding corresponded

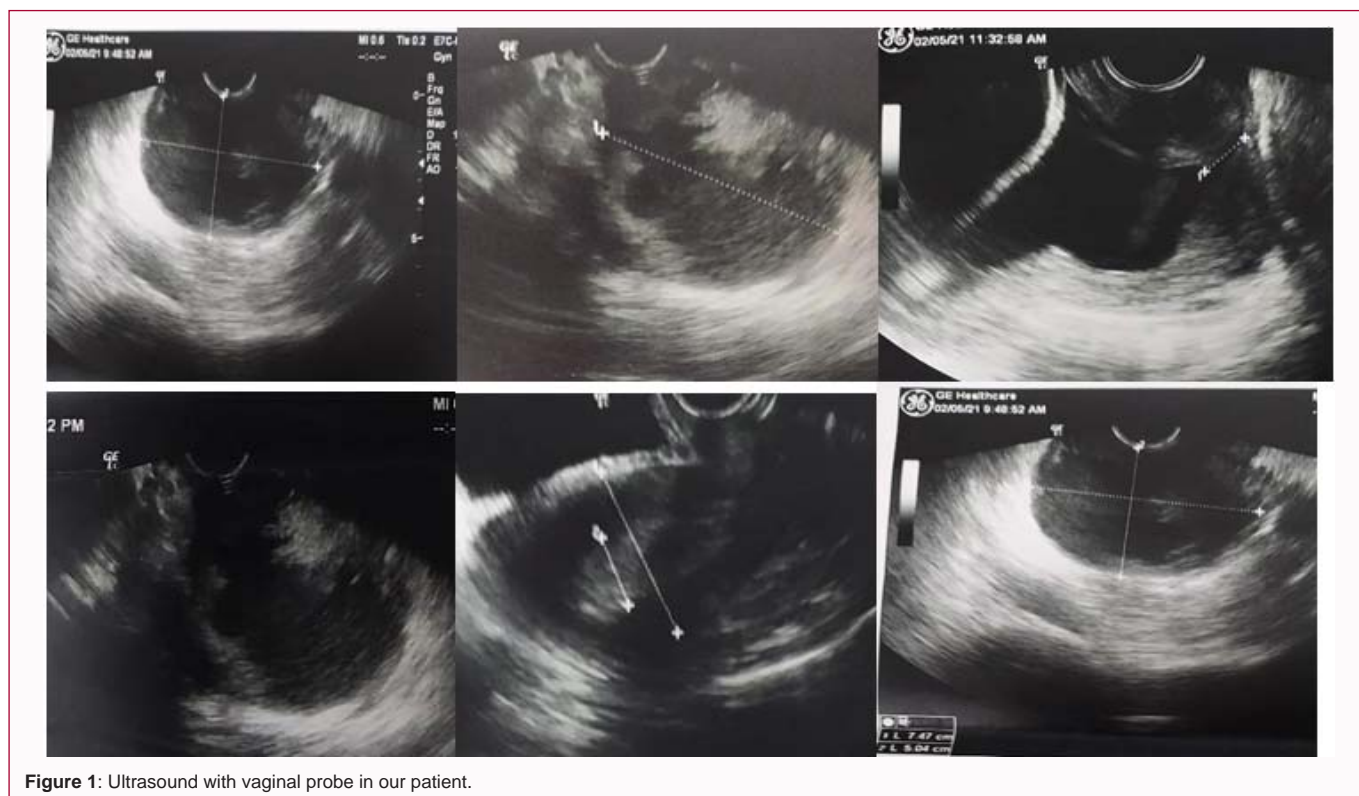
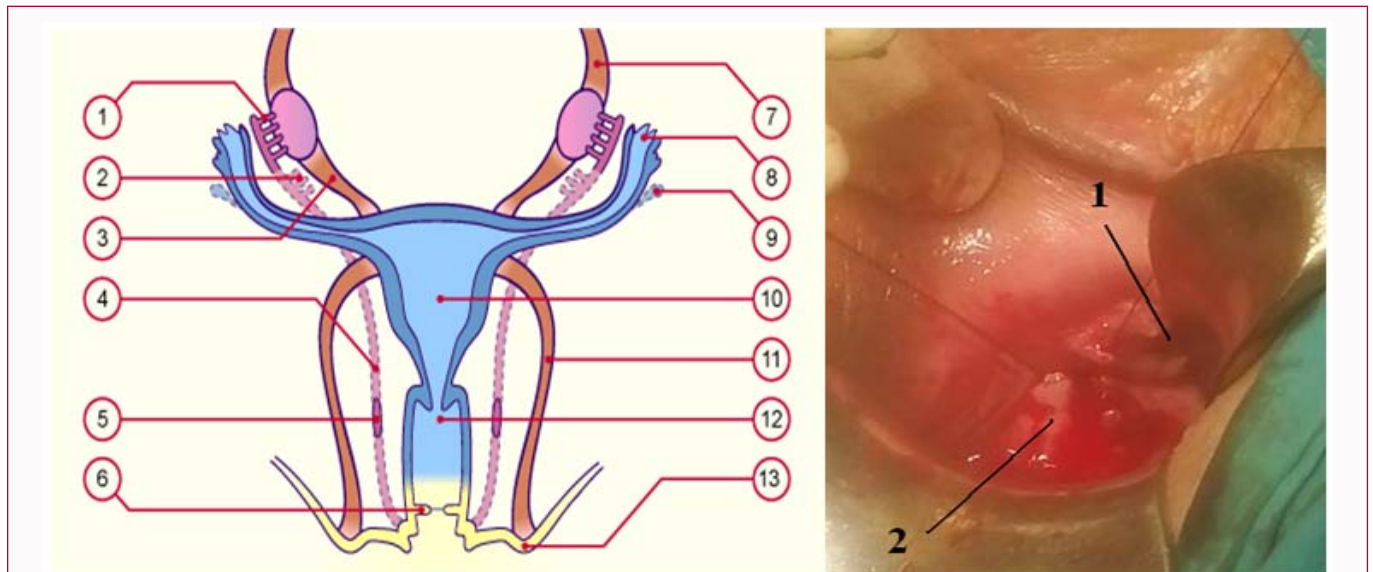


Figure 1: Ultrasound with vaginal probe in our patient.



**Figure 2:** Similarity in paravaginal location of Wolff duct (left) 7 and location of tumor in our patient (right). Legend (of the left picture): 1-epioophoron, 2-paaraophoron, 3-ovaarian ligament, 4-atrofied mesonephric duct (Wolff), 5-cysts of Gartner, 6-hymen, 7-suspensory ligament of ovary, Fallopian tube, 9-vesicular appendage (Morgani), 10-uterus, 11-round ligament of uterus, 12-vagina, 13-lower insertion of the round ligament. Legend (of the right picture): 1-incision site and tumor biopsy, 2-the opening in the right vagina of the vagina. The vaginal mucosa was completely unchanged.

to HPV-associated vaginal cancer. Radio-chemotherapy was suggested to the patient as a line of choice because the tumor size exceeded 4 cm. The patient refused it and went abroad for surgical treatment.

## Discussion

Vaginal cancer often has no noticeable symptoms, meaning it is often advanced by the time it is diagnosed. For this reason, it is important to get regular exams [7], which can sometimes diagnose vaginal and cervical cancer before any symptoms are noticed. Lan-Zhi Zhang et al. [8], report a case of 45-year old woman with adenoid cystic carcinoma. The symptomatology and clinical findings were almost identical to those of our patient. But, immunohistochemical tests were different (P63 were spotted, e.g. focal positive around the glandular cavity) because it was adenocarcinoma. In our case of squamous cell carcinoma, p63 was clearly positive. Ugwu et al. [9], present the case of unusual intestinal-type variant of adenocarcinoma of the vagina in 40-year-old woman with the complaint of a mass in the vagina and recurrent vaginal bright red, foul smelling bleeding. The tumor was presented as friable, non-tender mass measuring about 6 cm × 3 cm at the posterior wall of the lower-third of the vagina and extending to the introitus. This case shows almost identical symptomatology and clinical presentation as the tumor in our patient even though she has a different histological diagnosis. Raś et al. [10] reported a case of primary squamous vaginal carcinoma mimicking decubitus in 69-year-old patient who had vaginal prolapse for several years and incontinence, abdominal pain and actual hematuria. In our case, Papanicolaou cytological swab was negative, and the tumor was covered with an intact vaginal mucosa, which mimicked several other entities, like: Cystadenoma/cystadenocarcinoma of the Wolff duct, cyst of Gartner, fistulated paravaginal abscess or fistulated diverticulitis. The final diagnosis was made by biopsy and histopathological analysis of the tumor.

## Conclusion

Vaginal cancer is a very rare tumor. Diagnosis is particularly

difficult if it presents without a visible vaginal lesion and a negative Pap test, when it may mimic a vaginal cyst of Gartner or cyst/tumor of Wolff duct. In such cases, the gynecologist must take a biopsy to confirm or rule out vaginal cancer.

## References

- Hellman K, Silfversward C, Nilsson B, Hellstrom AC, Frankendal B, Pettersson F. Primary carcinoma of the vagina: Factors influencing the age at diagnosis. The radiumhemmet series 1956-96. *Int J Gynecol Cancer*. 2004;14(3):491-501.
- Adhikari P, Vietje P, Mount S. Premalignant and malignant lesions of the vagina. *Diagn Histopathol*. 2016;23(1):28-34.
- Edge SB, Compton CC. The American joint committee on cancer: The 7<sup>th</sup> edition of the AJCC cancer staging manual and the future of TNM. *Ann Surg Oncol*. 2010;17(6):1471-4.
- Gardner CS, Sunil J, Klopp AH, Devine CE, Sagebiel T, Viswanathan C, et al. Primary vaginal cancer: Role of MRI in diagnosis, staging and treatment. *Br J Radiol*. 2015;88(1052):20150033.
- Adams T, Cuello M. Cancer of the vagina. *Int J Gynecol Obstet* 2018;143(Suppl 2):14-21.
- Gadducci A, Fabrini MG, Lanfredini N, Sergiampietri C. Squamous cell carcinoma of the vagina: Natural history, treatment modalities and prognostic factors. *Crit Rev Oncol Hematol*. 2015;93(3):211-24.
- In females: Differentiation of the canal system in the genital organ.
- Zhang LZ, Huang LY, Huang AL, Liu JX, Yang F. Adenoid cystic carcinoma of the vagina: A case report. *Medicine*. 2019;98(1):e13852.
- Ugwu A, Haruna M, Okunade K, Ohazurike E, Anorlu R, Banjo A. Primary vaginal adenocarcinoma of intestinal-type: Case report of a rare gynaecological tumour. *Oxf Med Case Reports*. 2019;2019(9):omz088.
- Ras F, Ksiazek M, Filipowska J, Kaznowska E, Skret A, Skret-Magierlo J, et al. Primary vaginal squamous cell carcinoma with bladder involvement in uterine prolapsed patient. *Medicine*. 2017;96(50):e8993.