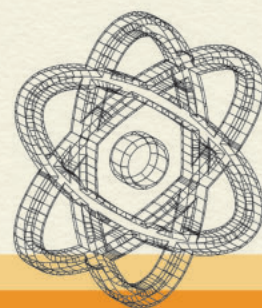

9th BALKAN  
CONGRESS OF  
**NUCLEAR  
MEDICINE**

AND SERBIAN  
CONGRESS OF

May 12-14 **20  
22**



**BOOK  
OF ABSTRACTS**



**Co-funded by  
the European Union**

## Table of Contents

ILP1 Myocardial perfusion stress test: is it worth?.....	20
IL2 Diuresis renography and ultrasonography in children with antenatally detected hydronephrosis can support diagnoses and suggest related surgery treatment.....	21
IL3 Optimization of the radiolabelling method for improved in vitro and in vivo stability of 90 Y- albumin microspheres.....	22
IL4 Title: 99mTc-PYP in patients with suspected ATTR cardiac amyloidosis.....	23
O1 Production and quality control of radiopharmaceuticals in “Vinča” Institute of Nuclear Sciences .....	24
O2 cGMP Manufacturing of I-131 radio labeled small molecules - the Lantheus experience .....	25
O3 10 YEARS OF EXPERIENCE IN LYMPHOSCINTIGRAPHY AND SENTINEL LYMPH NODE BIOPSY IN CUTANEOUS MELANOMA– SINGLE CENTER ANALYSIS .....	26
O4 QUALITY ASSURANCE AND QUALITY CONTROL OF INTRAOPERATIVE GAMMA PROBE FOR SENTINEL LYMPH NODE BIOPSY .....	27
O5 Incidence of Differentiated Thyroid Carcinoma in Bethesda III Classified Nodules .....	28
P1 EVALUATION OF ACCURACY OF 99mTc-DTPA SINGLE-PLASMA SAMPLE METHOD IN ESTIMATION OF GFR VALUES .....	29
P2 The role of perfusion lung scintigraphy in follow-up patients after COVID-19 infection .....	30
P3 SEMIQUANTITATIVE ASSESSMENT OF TUBULAR KIDNEY FUNCTION USING THE INDEX OBTAINED FROM SCINTIGRAPHIC IMAGE .....	31
P4 99mTc-RADIOPHARMACEUTICALS: QUALITY CONTROL OF 99mTc-DPD.....	32
P5 DEDICATED HEAD AND NECK 18F-FDG PET/CT PROTOCOL IN DETECTING CERVICAL LYMPH NODE METASTASIS .....	33
P6 The use of Deauville score in a determination of a need for further treatment in patients with Hodgkin lymphoma and diffuse large B cellular lymphoma (DLBCL) .....	34
P7 F-18-FDG PET/CT in squamous cell carcinoma .....	35
P8 LUNG METASTASES .....	36
P9 F-18-FDG PET/CT scan in patients with suspicion of recurrent pancreatic cancer.....	37
P10 Case report on a patient with neurofibromatosis type 1 diagnosed using FDG PET/CT scanner .....	39
P12 FDG-PET in pre-surgical evaluation of focal pharmaco-resistant epilepsy- How FDG-PET helped us after 180+ epilepsy operations? .....	40
P13 F-18-FDG PET/CT “Milk of Calcium” Gallbladder.....	41
P14 CALIBRATION OF DOSE CALIBRATORS IN THE LABORATORY FOR RADIOISOTOPES.....	42
P15 The relationship between thyroid antibodies and vitamin D level in primary hypothyroidism	43
P16 99mTc-labeled phosphonate-coated magnetic nanoparticles.....	44

P17 Diagnostic role of positron emission tomography/computed tomography with fluorodeoxyglucose in recurrent cervical cancer patients .....	45
P18 Diagnostic role of FDG PET/CT in recurrent uterine corpus cancer.....	46
P19 False positive PETCT finding in breast cancer patient .....	47
P20 DIAGNOSTIC VALUE OF THE PET/CT IN DETECTION OF FEVER OF UNKNOWN ORIGIN, INFECTIONS AND INFLAMMATION.....	48
P21 Synchronous breast and thyroid cancers in young women-unusually case presentation .....	49
P22 99mTc-mibi myocardial perfusion scintigraphy in the prediction of cardiac events in patients with diabetes mellitus type 2, .....	50
P23 Metastatic lung cancer and it's PET/CT findings after therapy – case report .....	51
P24 Radium-223 dichloride therapy in prostate cancer with osseous metastases – clinical case report .....	52
P25 Analysis of Differentiated Thyroid Carcinoma Patients Treated in a Single Center: Is there a Relation Between Hashimoto Thyroiditis and Malignancy?.....	53
P26 Radiotherapy planning on Varian Edge knife with PET/CT imaging: initial management in the Republic of Serbia.....	54
P27 PERFUSION LUNG SCINTIGRAPHY IN POST COVID 19 PATIENTS WITH LIGHT AND MODERATE CLINICAL PICTURE. ACUTE LUNG MICROTHROMBOEMBOLIZATION OR SEQUELAE ? .....	55
P28 PET/CT in the management of primary angiosarcoma of the heart.....	56
P29 Use of lymphoscintigraphy in the diagnosis of lymphedema, case report.....	57
PT1 Peritoneal scintigraphy in assessment of chronic complications of chronic ambulatory peritoneal dialysis (CAPD) - case report. ....	58
PT2 Terapija hipertireoze pomoću I-131 .....	59
PT3 FDG PET i SPECT u prehirurškoj evaluaciji fokalne farmakorezistentne epilepsije .....	60
PT4 IZLOŽENOST OSOBLJA JONIZUJUĆEM ZRAČENJU PRI SEPARACIJI I APLIKACIJI FDG RADIOFARMAKA POLUAUTOMATSKIM I AUTOMATSKIM SEPARATOROM POJEDINAČNIH DOZA- Kontrola kvaliteta .....	61
PT5 PET/CT – КОНТРОЛА КВАЛИТЕТА, ДИЈАГНОСТИЧКИ ПОТЕНЦИЈАЛ, ПРИМЕНА И ЗНАЧАЈ .....	62
PT6 Scintigraphic detection of dialysis solution leakage in patients treated with continuous ambulatory peritoneal dialysis .....	63
PT7 Перфузиона сцинтиграфија миокарда (СПЕКТ), контрола квалитета, садржај и делокруг рада медицинске сестре и струковног радиолога .....	64

Dear friends and colleagues,

We are very pleased to welcome you to the 9<sup>th</sup> Balkan Congress of Nuclear Medicine and the Serbian Congress of Nuclear Medicine, which is holding at the ethno complex in Vrdnik, from May 12-14. 2022.

The meeting is jointly organized by the Serbian Society of Nuclear Medicine, the Section of Nuclear Medicine and Academy of Medical Sciences of Serbian Medical Society, the Department of Nuclear Medicine of the Medical Faculty of the University of Belgrade and the Center for Nuclear Medicine with Positron Emission Tomography of the University Clinical Center of Serbia.

At a time when our globalized world has been unexpectedly and abruptly paralyzed in the pandemic conditions, despite a pause in the organization of the Balkan Congresses, many meetings in virtual or hybrid form have been held in this region that have been highly attended. We are convinced that the 9th Balkan Congress of Nuclear Medicine and the Serbian Congress of Nuclear Medicine is a great occasion to reunite the nuclear medicine community from our country and the region with colleagues from other parts of the world after longer period. Special emphasis will be on the presentation of new ideas, exchange of experiences and discussion based on a multidisciplinary approach to existing problems and the development of nuclear medicine with the latest scientific and educational content.

We hope that you will feel the atmosphere of the live meeting again, that the Congress will meet your expectations and leave unforgettable personal and professional impressions, as well as that you will relax and enjoy the natural beauties of this pleasant environment.

We wish you successful congress and unforgettable memories.

With respect,



Prof. Dr. Vera Artiko

President of Serbian Society of  
Nuclear Medicine  
Head, Center for Nuclear  
Medicine, University Clinical  
Center of Serbia



Prof. Dr. Dragana Šobić Šaranović

Chief of the Chair for Nuclear Medicine Faculty of  
Medicine University of Belgrade  
President, Active for Cardiovascular Imaging Serbian  
Medical Society



Dr Aida Afgan

President, Section for  
Nuclear Medicine  
Serbian Medical Society

## GENERAL INFORMATION

Date: May 12-14, 2022

Place: Vrdnik tower, Vrdnik

Official language: English

Registration fee includes:

- ✓ Access to the sessions;
- ✓ Congress material;
- ✓ Coffee breaks with refreshments;
- ✓ Welcome cocktail on Thursday, May 12;
- ✓ Gala Dinner on Friday, May 13;

CME: Balkan Congress of Nuclear Medicine is accredited by the national CME authority with 15 points for invited speakers, 13 points for oral presentations, 11 points for poster presentations and 10 points for attendees.

## **Congress Presidency**

Vera Artiko  
Dragana Šobić Šaranović  
Aida Afgan

## **Scientific Committee**

Boris Ajdinović, Belgrade  
Lidija Antunović, Milan  
Vojislav Antić, Belgrade  
Slobodanka Beatović, Belgrade  
Pavel Bochev, Varna  
Sabina Dizdarević, Brighton  
Sanja Dugonjić, Belgrade  
Mirela Gherghe, Bucharest  
Francesco Giammarile, IAEA  
Snežana Golubović, Belgrade  
Marko Grahovac, Vienna  
Marcus Hacker, Vienna  
Branislava Ilinčić, Novi Sad  
Drina Janković, Belgrade  
Marija Jeremić, Kragujevac  
Sofia Koukouraki, Heraklion  
John Koutsikos, Athens  
Nevena Manevska, Skopje  
Milovan Matović, Kragujevac  
Jasna Mihailović, Sremska Kamenica  
Ljiljana Mijatović, Belgrade  
Daniela Miladinova, Skopje  
Šejla Cerić, Sarajevo  
Özlem ÖZMEN, Ankara  
Vladimir Obradović, Belgrade  
Diana Paez, IAEA  
Nebojša Petrović, Belgrade  
Dragan Pucar, Belgrade  
Zvezdana Rajkovača, Banja Luka  
Aleksandar Simić, Zlatibor  
Cipriana Stefanescu, Iasi  
Miloš Stević, Niš  
Siniša Stojanoski, Skopje  
Gülin UÇMAK, Ankara  
Marina Vlajković, Niš  
Sanja Vraneš Djurić, Belgrade  
Vladimir Vukomanović, Kragujevac



9th BALKAN  
CONGRESS OF  
**NUCLEAR  
MEDICINE**  
AND SERBIAN  
CONGRESS OF

May 12-14  
**20  
22**  
Fruske terme  
**Vrdnik  
Serbia**

**THURSDAY, MAY 12, 2022**

9:00-19:00

**REGISTRATION**

**Session 1:**

**NUCLEAR MEDICINE ACHIEVEMENTS IN SERBIA DURING 2021**

10:00-10:30

**MILOVAN ANTIC AWARD COMPETITION (FOR 2021)**

Chairpersons: Marija Šišić, Slobodanka Beatović, Drina Janković

10:00-10:10

**Isidora Grozdić Milojević, Beograd**

Grozdic Milojevic I, Tadic M, Sobic-Saranovic D, Milojevic B, Artiko VM.

Myocardial perfusion stress test: is it worth? Int J Cardiovasc Imaging. 2020 Apr;36(4):741-748.

10:10-10:20

**Marija Radulović, Beograd**

Radulović M, Janković MM, Durutović O, Šobić-Šaranović DP, Ajdinović B, Artiko VM, Žeravica R, Beatović SL.

Interobserver reproducibility of mercaptoacetyl triglycine renography in children and adults

with suspected obstruction: parameters of drainage and function calculated by

International Atomic Energy Agency software. Nucl Med Commun. 2020 Feb;41(2):96-103

10:20-10:30

**Aleksandar Vukadinović, Beograd**

Vukadinović A, Janković D, Radović M, Milanović Z, Mirković M, Stanković D, Vranješ-Đurić S.

Optimization of the radiolabelling method for improved in vitro and in vivo stability of <sup>90</sup>Y-albumin microspheres. Applied Radiation and Isotopes 156 (2020) 108984

10:40-10:50

**LJUBOMIR STEFANOVIĆ AWARD**

Chairpersons: Radmila Žeravica, Nebojša Petrović, Ljiljana Mijatović

Dragana Šobić Šaranović. Integrated non-invasive cardiovascular imaging: a guide for practitioner.

International Atomic Energy Agency (IAEA), 2021.

10:50-11:00

**ACADEMICIAN VLADIMIR BOŠNJAKOVIĆ AWARD**

Chairpersons: Lepasava Brajković, Dragan Pucar, Vesna Ignjatović, Milena Rajić, Radmila Ćorović



9th BALKAN  
CONGRESS OF  
**NUCLEAR  
MEDICINE**  
AND SERBIAN  
CONGRESS OF

May 12-14  
**20  
22**  
Fruske terme  
**Vrdnik**  
**Serbia**

- 11:00-11:15      **AWARD CEREMONY**  
Vera Artiko, Marija Šišić, Radmila Žeravica, Leposava Brajković
- 11:30-11:40      **WELCOME MESSAGE**  
Vera Artiko, Dragana Šobić Šaranović, Aida Afgan  
Raluca Mititelu: The announcement of BCNM 2023
- 11:40-12:00      **Clinical Overview and Future of Lu-177 Radiopharmaceuticals**  
Francesco Giammarile, IAEA
- 12:00-12:15      **Discussion**
- 12:30-13:30      **Lunch break-Welcome reception**
- Session 2:**  
**ARTIFICIAL INTELLIGENCE IN NUCLEAR MEDICINE:**  
**POTENTIALS, CHALLENGES AND FUTURE PERSPECTIVES**  
Chairpersons: Marcus Hacker, Milovan Matović, Ana Ugrinska
- 13:30-13:45      **Artificial intelligence in nuclear medicine**  
Marcus Hacker, Vienna
- 13:45-14:00      **AI algorithms in multimodal imaging**  
Marko Grahovac, Vienna
- 14:00-14:15      **Advanced image analysis in breast cancer**  
Lidija Antunović, Milan
- 14:15-14:30      **Radiomics in Nuclear Medicine – from Research to Clinical Practice**  
Ana Uginska, Skopje
- 14:30-14:45      **Artificial intelligence in echocardiography**  
Danijela Trifunović Zamaklar, Belgrade
- 14:45-15:00      **GE Healthcare: Artificial intelligence in nuclear medicine:**  
potentials, challenges and future perspectives. E  
nhance your diagnostic confidence with the new AI-based Xeleris image processing tools.  
Andreas Stratis
- 15:00-15:15      **Discussion**





- 15:15-15:30      Coffee break
- Session 3:  
FROM THE MAGIC BULLET TO THERA(G)NOSTICS  
Chairpersons: John Koutsikos, Marina Vlajković, Doina Pisciu
- 15:30-15:45       $^{223}\text{Ra}$ -dichloride in mCRPC- update  
Sabina Dizdarević, Brighton
- 15:45-16:00      Determination of the Applied Activity of I-131 using 24h and 96h Uptake Values  
Jelena Samac, Novi Sad
- 16:00-16:15      Update in Functional Assessment of Thyroid Nodules According to New Practice Guidelines  
Radmila Žeravica, Novi Sad
- 16:15-16:30      First Results from the Application of  $^{223}\text{Radium}$  in Patients with MCRPC  
in Bulgaria and Future Perspective with  $^{177}\text{Lutetium}$  PSMA  
Valerya Hadjiiska, Sofia
- 16:30-16:45      Intraarterial Radionuclide Therapies for Liver Tumors in the Era of Theranostics  
Murat Fani Bozkurt, Ankara
- 16:45-17:00      GE Healthcare: From the magic bullet to thera(g)nostics,  
GE Starguide: Unlock the potential of Theranostics and highly personalized care  
in Nuclear Medical Imaging;  
Andreas Stratis
- 17:00-17:15      Discussion



17:15-18:30

**Session 4:**

**POSTER SESSION 1**

Milena Dimcheva, Aleksandar Simić, Evangelia Skoura

**Impact of the iterative reconstruction parameters on the PET images interpretation**

Ana Ješić, Dragana Šobić Šaranović, Vera Artiko, Center for Nuclear Medicine with PET, UCCS, Belgrade

**The role of perfusion lung scintigraphy in follow-up patients after COVID-19 infection**

Ana Jakovljević, Dragan Burić, Radmila Žeravica, Branislava Ilinčić, Veljko Crnobrnja, Marija Papuga Vukmirović, University of Novi Sad, Faculty of Medicine Novi Sad, Department of pathophysiology and laboratory medicine, University Clinical Center of Vojvodina, Center for laboratory medicine, Novi Sad

**Semiquantitative assessment of tubular kidney function using the index obtained from scintigraphic image**

Dragan Burić, Tanja Ostojić, Radmila Žeravica, Branislava Ilinčić, Ana Jakovljević, Veljko Crnobrnja, Marija Papuga Vukmirović, University of Novi Sad, Faculty of Medicine Novi Sad, Department of pathophysiology and laboratory medicine, University Clinical Center of Vojvodina, Center for laboratory medicine, Novi Sad

**$^{18}\text{F}$ -FDG PET/CT in squamous cell carcinoma**


Isidora Grozdic Milojevic, Jelena Pantovic, Jelena Crevar Malicevic, Jovana Zivanovic, N. Pantic, Center for Nuclear Medicine with PET, University Clinical Center of Serbia, Belgrade, Serbia, Faculty of Medicine University of Belgrade, Belgrade

**Dedicated head and neck  $^{18}\text{F}$ -FDG PET/CT protocol in detecting cervical lymph node metastasis**

Todorova-Stefanovski, D, Spirov G, Tasevski S, Besliev S, Angjeleska M, Ugrinska A, University Institute for Positron Emission Tomography Skopje

**Follow up of appendiceal neuroendocrine tumors using  $^{99\text{m}}\text{Tc}$ -Tektrotyd scintigraphy**

Petrovic Jelena, Sobic-Saranovic Dragana, Petrovic Nebojša, Stojiljkovic Milica, Artiko Vera, Center for Nuclear medicine with PET, University Clinical Centre of Serbia, Faculty of medicine, University of Belgrade, Belgrade



**FDG-PET in pre-surgical evaluation of focal pharmaco-resistant epilepsy**

**- How FDG-PET helped us after 180+ epilepsy operations?**

**L. Brajkovic, D. Sokic, N. Vojvodic, A. Ristic, V. Baščarevic, A. Parojčić, M. Stojiljkovic,  
A. Ješić, A. Pejovic, D. Šobić-Šaranović, V. Artiko.**

**Center for Nuclear medicine with PET, University Clinical Center of Serbia,  
Clinic for Neurology, University Clinical Center of Serbia,  
Clinic for neurosurgery, University Clinical Center of Serbia,  
Faculty of Medicine University of Belgrade, Belgrade**

**The relationship between thyroid antibodies and vitamin D level in primary hypothyroidism**

**Maja Sulejmanović, Fatima Mujarić-Bousbia, Clinic for Radiology and Nuclear medicine,  
University Clinical Centre Tuzla, Tuzla**

**<sup>99m</sup>Tc-labeled phosphonate-coated magnetic nanoparticles**

**Marija Mirković, Zorana Milanović, Sanja Vranješ-Đurić, Drina Janković,  
Aleksandar Vukadinović, Marko Perić, Đorđe Petrović, Dragana Stanković,  
Magdalena Radović, „VINČA” Institute of Nuclear Sciences - National Institute of the Republic of Serbia,  
University of Belgrade, Belgrade**

**Diagnostic role of positron emission tomography/computed tomography with  
fluorodeoxyglucose in recurrent cervical cancer patients**

**Stojiljković Milica, Odalović Strahinja, Popović Marina, Petrović Jelena,  
Pantović Jelena, Ranković Nevena, Veljković Miloš, Brajković Lepsava,  
Šobić Šaranović Dragana, Artiko Vera, Center for Nuclear Medicine with PET,  
University Clinical Centre of Serbia, Belgrade, Faculty of Medicine,  
University of Belgrade, Institute for Oncology and Radiology of Serbia, Belgrade**

**Dedicated head and neck <sup>18</sup>F-FDG PET/CT protocol in detecting cervical lymph node metastasis**

**Todorova-Stefanovski, D, Spirov G, Tasevski S, Besliev S, Angjeleska M,  
Ugrinska A, University Institute for Positron Emission Tomography Skopje**

**Diagnostic role of FDG PET/CT in recurrent uterine corpus cancer**

**Stojiljković Milica, Odalović Strahinja, Popović Marina, Petrović Jelena, Pantović Jelena,  
Ranković Nevena, Veljković Miloš, Brajković Lepsava, Šobić Šaranović Dragana, Artiko Vera,  
Centre for Nuclear Medicine with PET, University Clinical Centre of Serbia, Belgrade,  
Faculty of Medicine, University of Belgrade,  
Institute for Oncology and Radiology of Serbia, Belgrade**



9th BALKAN  
CONGRESS OF  
**NUCLEAR  
MEDICINE**  
AND SERBIAN  
CONGRESS OF

May 12-14  
**20  
22**  
Fruske terme  
**Vrdnik  
Serbia**


**Analysis of Differentiated Thyroid Carcinoma Patients Treated in a Single Center:  
Is there a Relation Between Hashimoto Thyroiditis and Malignancy?**  
Cimbaljević V, Roganović J, Stojanović D, Mihailović J. Center of nuclear medicine,  
Oncology institute of Vojvodina Sremska Kamenica, Sremska Kamenica, Serbia,  
Faculty of Medicine, University of Novi Sad, Novi Sad,

**Case report on a patient with neurofibromatosis type 1 diagnosed using FDG PET/CT scanner**  
Jelena Pantovic, Nevena Rankovic, Jovana Zivanovic.  
Center for Nuclear medicine with PET,  
University Clinical Center of Serbia, Belgrade

**$^{99m}\text{Tc}$ -Radiopharmaceuticals: Quality control of  $^{99m}\text{Tc}$ -DPD**  
Dragana Stanković, Marija Mirković, Magdalena Radović, Drina Janković,  
Olivera Laban-Božić, Milovan Matović, Marija Jeremić, Sanja Vranješ-Đurić,  
Laboratory for radioisotopes, Vinča Institute of Nuclear Sciences,  
National Institute of the Republic of Serbia, University of Belgrade,  
Centre of Nuclear Medicine, Clinical Centre Kragujevac, Kragujevac

**Calibration of dose calibrators in the laboratory for radioisotopes**  
Magdalena Radović, Marija Mirković, Drina Janković, Aleksandar Vukadinović,  
Marko Perić, Đorđe Petrović, Zorana Milanović, Sanja Vranješ-Đurić,  
Laboratory for radioisotopes, Vinča Institute of Nuclear Sciences,  
National Institute of the Republic of Serbia, University of Belgrade, Belgrade

**Perfusion lung scintigraphy in post COVID 19 patients with light and moderate clinical picture.  
Acute lung microthromboembolization or sequelae?**  
Milos Stevic, Marina Vlajkovic, Nina Topic, Filip Velickovic,  
Tamara Andjelkovic. Faculty of Medicine, University of Nis,  
Center for Nuclear Medicine, University Clinical Center Nis



9th BALKAN  
CONGRESS OF  
**NUCLEAR  
MEDICINE**  
AND SERBIAN  
CONGRESS OF

May 12-14  
**20  
22**  
Fruske terme  
**Vrdnik  
Serbia**

FRIDAY, MAY 13, 2022

9:00-19:00	<b>REGISTRATION</b>
	<b>Session 5: ONCOLOGY 1</b> Chairpersons: Jasna Mihailović, Sonya Sergieva, Raluca Mititelu
10:00-10:15	<b>Clinical Impact of Metabolic Imaging in Breast Carcinoma</b> Tevfik Fikret ÇERMİK, Istanbul
10:15-10:30	<b>Lymphoscintigraphy in Malignant Melanoma.</b> Raluca Mititelu, Bucharest
10:30-10:45	<b>Clinical Application of SPECT-CT Imaging with New <sup>99m</sup>Tc-PSMA Tracer in Patients with Recurrent Prostate Cancer</b> Sonya Sergieva, Sofia
10:45-11:00	<b>Neolife Istanbul +MNT Healthcare group: PSMA PET/CT Imaging in Prostate Cancer</b> Nesrin Aslan
11:00-11:15	<b>Discussion</b>
	<b>Session 6: ONCOLOGY 2</b> Vasilios Prasopoulos, Zvezdana Rajkovića, Slobodanka Beatović
11:15-11:30	<b>PET/CT in Endocrinology</b> Doina Pisciu, Cluj
11:30-11:45	<b><sup>18</sup>F-DG-PET/CT in assessing response to checkpoint blockade immunotherapy</b> Evangelia Skoura, Athens
11:45-12:00	<b>Combined radionuclide and hyperthermia cancer therapy with aminosilanized magnetic nanoparticles coupled to <sup>131</sup>I-labeled CC49 antibody</b> Aljoša Stanković, Banja Luka
12:00-12:15	<b>Discussion</b>



9th BALKAN  
CONGRESS OF  
**NUCLEAR  
MEDICINE**  
AND SERBIAN  
CONGRESS OF

May 12-14  
**20  
22**  
Fruske terme  
**Vrdnik  
Serbia**

12:15-12:30

Coffee Break

**Session 7:**

**INFECTIONS, INFLAMMATIONS, METABOLIC, DEGENERATIVE DISEASES, THERANOSTICS**

**Chairpersons: Amela Begić, Branislava Ilinčić, Venjamin Majstorov**

12:30-12:45

**Pneumoniae-Ventilation/Perfusion Tomography V/P SPECT**

**Amela Begić, Sarajevo**

12:45-13:00

**Neuroimaging in Dementia**

**Varvara Valotassiou, Larissa**

13:00-13:15

**<sup>99m</sup>Tc-PYP in Patients with Suspected ATTR Cardiac Amyloidosis**

**Venjamin Majstorov, Skopje**

13:15-13:30

**Pfizer : The role of Nuclear Medicine in Diagnosis and Follow up of Cardiac Amyloidosis**

**Dragana Sobic Saranovic**

13:30-13:45

**Discussion**

13:45-14:45

**Lunch break**

14:15-15:00

**MEETING OF THE DELEGATES OF THE BALKAN COUNTRIES (meeting room X)**

**Session 8:**

**ORAL PRESENTATIONS (Quality control, Quality assurance, Oncology)**

**Chairpersons: Sanja Vraneš Đurić, Dragan Pucar, Vladimir Vukomanović**

15:00-15:10

**Production and quality control of radiopharmaceuticals in "Vinča" Institute of Nuclear Sciences  
Aleksandar Vukadinović, Marija Mirković, Drina Janković, Olivera Laban-Božić, Marko Perić,  
Đorđe Petrović, Dalibor Stanković, Zorana Milanović, Sanja Vranješ-Đurić.**

**Laboratory for radioisotopes, 1Vinča Institute of Nuclear Sciences, University of Belgrade, Serbia**



9th BALKAN  
CONGRESS OF  
**NUCLEAR  
MEDICINE**  
AND SERBIAN  
CONGRESS OF

May 12-14  
**20  
22**  
Fruske terme  
**Vrdnik  
Serbia**

- 15:10-15:20      cGMP Manufacturing of I-131 radiolabeled small molecules - the Lantheus experience  
Alexander T. Yordanov
- 15:20-15:30      Quality assurance and quality control of intraoperative gamma probe  
for sentinel lymph node biopsy  
Milena Dimcheva, Teodor Sofiyanski, Sonya Sergieva, Aleksandra Jovanovska,  
Department of Nuclear Medicine, Sofia Cancer Center, Sofia, Bulgaria
- 15:30-15:40      10 Years of experience in lymphoscintigraphy and sentinel lymph node biopsy  
in cutaneous melanoma – single center analysis  
Ljiljana Radosavcev, M.Rajović , L. Kandolf Sekulovic, M. Radulovic Z. Mijuskovic, N. Petrov.  
Institute of Nuclear Medicine, Clinic for Plastic and Reconstructive Surgery,  
Clinic for Dermatology, Center of Pathology and Forensic Medicine  
Military Medical Academy, Belgrade, Serbia
- 15:40-15:50      Incidence of Differentiated Thyroid Carcinoma in Bethesda III Classified Nodules  
Emil Matovina. Clinic for Nuclear Medicine, Oncology Institute of Vojvodina, Sremska Kamenica
- 15:50-16:10      Discussion
- 16:10-17:10      ASSEMBLY OF THE SERBIAN SOCIETY OF NUCLEAR MEDICINE
- 17:00-18:30      Session 9:  
POSTER PRESENTATIONS 1 (Quality control, Theranostics)  
Ljiljana Radosavčev, Miloš Stević, Branislava Radović
- False positive PET/CT finding in breast cancer patient  
Prvulovic Bunovic N, Trifunović J, Mihailovic J,  
Faculty of Medicine, University of Novi Sad, Novi Sad,  
Diagnostic Imaging Center, Oncology Institute of Vojvodina,  
Sremska Kamenica, Clinic for Internal Oncology,  
Oncology Institute of Vojvodina, Sremska Kamenica,  
Clinic for Nuclear Medicine, Oncology Institute of Vojvodina, Sremska Kamenica,



Synchronous breast and thyroid cancers in young women-unusually case presentation  
Roganović J, Prvulovic Bunovic N, Salma S, Mihailovic J.  
Faculty of Medicine, University of Novi Sad, Novi Sad, Serbia,  
Diagnostic Imaging Center, Oncology Institute of Vojvodina, Sremska Kamenica,  
Clinic for Internal Oncology, Oncology Institute of Vojvodina, Sremska Kamenica,  
Clinic for Nuclear Medicine, Oncology Institute of Vojvodina, Sremska Kamenica

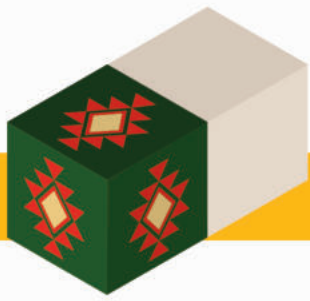
Diagnostic value of the PET/CT in detection of fever of unknown origin,  
infections and inflammation  
Nevena Ranković, Dragana Šobić- Šaranović, Vera Artiko, Jelena Petrović, Milica Stojiljković,  
Nebojša Petrović,  
Center for Nuclear medicine with PET, University  
Clinical Centre of Serbia,  
Faculty of medicine, University of Belgrade, Belgrade

<sup>99m</sup>Tc-mibi myocardial perfusion scintigraphy in the prediction of cardiac events  
in patients with diabetes mellitus type 2  
Siniša Stanković, Dragana Šobić-Šaranović, Valentina Soldat-Stanković, Vera Artiko,  
Zvezdana Rajkovača, Gostimir Mikač, Nataša Egeljić-Mihailović, Marina Majkić,  
Faculty of medicine, University of Belgrade, Belgrade,  
Faculty of Medicine University of Banja Luka, Banja Luka,  
Institute of Nuclear Medicine and Thyroid Gland Disease,  
University Clinical Centre of the Republic of Srpska, Banja Luka

Radium-223 dichloride therapy in prostate cancer  
with osseous metastases – clinical case report  
Teodor Sofiyanski, Milena Dimcheva, Sonya Sergieva, Rossitza Krasteva, Zahary Zahariev,  
Department of Nuclear Medicine, Sofia Cancer Center, Sofia, Bulgaria,  
Department of Medical Oncology, Uni Hospital, Panagyurishte,  
Department of Radiotherapy, Uni Hospital, Panagyurishte

Radiotherapy planning on Varian Edge knife with PET/CT imaging:  
initial management in the Republic of Serbia  
Vojislav Antic. Center for Nuclear Medicine with PET, University Clinical Center of Serbia





Evaluation of accuracy of  $^{99m}\text{Tc}$ -DTPA single-plasma sample method in estimation of GFR values  
Peshevska A, Makazlieva T, Majstorov V, Milenkova M, Rambabova Bushljetikj I, Miladinova D,  
Institute of Pathophysiology and Nuclear Medicine, Medical Faculty,  
University Ss Cyril and Methodius, Skopje, University Clinic of Nephrology,  
University Clinic "Mother Teresa", University Ss Cyril and Methodius, Skopje

Aseptic Process Validation of [ $^{18}\text{F}$ ]Fluorodeoxyglucose Production  
Marija Atanasova Lazareva, Katerina Kolevska, Maja Chochevska, Maja Velichkovska,  
Filip Jolevski, Ana Ugrinska, University Institute of Positron Emission Tomography, Skopje,  
North Macedonia

Metastatic lung cancer and it's PET/CT findings after therapy - case report  
Sonja Bobić Zrač, Ivana Pavković,  
Institute of Nuclear Medicine and Thyroid Gland Disease,  
University Clinical Centre of the Republic of Srpska, Banja Luka

$^{18}\text{F}$ -FDG PET/CT scan in patients with suspicion of recurrent pancreatic cancer  
J. Maličević Crevar, V.Artiko, M.Veljковиć, N.Pantić, J.Živanović, S.Beatović, D.Šobić Šaranović;  
Center for Nuclear medicine with PET, University Clinical Centre of Serbia,  
Faculty of medicine, University of Belgrade, Belgrade

Lung metastases  
Ivana Pavković, Sonja Bobić-Zrač, Dragi Stanimirović, Jasenka Mijatović.  
University Clinical Centre of the Republic of Srpska, Banja Luka

$^{18}\text{F}$ -FDG PET/CT "Milk of Calcium" Gallbladder  
Ljiljana Zivgarević.  
Center for Nuclear Medicine with PET, University Clinical Centre of Serbia, Belgrade

The use of Deauville score in a determination of a need for further treatment  
in patients with Hodgkin lymphoma and diffuse large B cellular lymphoma (DLBCL)  
Nikola Pantić, Jovana Živanović, Jelena Maličević.  
Center for Nuclear Medicine with PET, University Clinical Center of Serbia



9th BALKAN  
CONGRESS OF  
**NUCLEAR  
MEDICINE**  
AND SERBIAN  
CONGRESS OF

May 12-14  
**20  
22**  
Fruske terme  
**Vrdnik  
Serbia**

**SATURDAY, MAY 14, 2022**

9:00-19:00

**REGISTRATION**

10:00-11.00

**Session 10:**

**POSTER PRESENTATION TECHNOLOGISTS (Quality control, Theranostics)**

**Chairpersons: Tatjana Krkalović, Sami Issa, Darko Maričić**

**Peritoneal scintigraphy in assessment of chronical complications of chronical ambulence peritoneal dialysis (CAPD) - case report**  
**Darko Maričić, Milica Ilić, Branislava Đorđević, Dora Sabo, Milica Šatara.**  
**Clinical Center of Vojvodina, Department of Nuclear Medicine, Novi Sad**

**Radionuclide therapy of hyperthyreosis with I-131**  
**I.Mihailović, J. Aćimović, A. Afgan.**  
**Center for Nuclear Medicine with PET, University Clinical Center of Serbia, Belgrade**

**FDG PET and SPECT in presurgical evaluation of focal pharmaco-resistant epilepsy**  
**M.Marković, J. Danicic, J. Zivojinovic, B. Radulović.**  
**Center for Nuclear Medicine with PET, University Clinical Center of Serbia, Belgrade**

**Radiation exposure of staff during separation and application of FDG semiautomatic and automatic separator of the individual doses – quality control**  
**Issa Sami, Ješić Ana, Milošević Igor, Stojiljković Milica.**  
**Center for Nuclear Medicine with PET, University Clinical Center of Serbia, Belgrade**

**PET/CT – quality control, diagnostic potential, application and value**  
**Tatjana Krkalović, Biljana Janjić, Anja Spasić,**  
**University Clinical Center of Serbia, Belgrade**

**Perfusion myocardial scintigraphy (SPECT): quality control, content and scope of work, radiation technologists and nurse**  
**Zorica Milovanović, Vesna Nedeljković,**  
**University Clinical Center of Serbia, Belgrade**



9th BALKAN  
CONGRESS OF  
**NUCLEAR  
MEDICINE**  
AND SERBIAN  
CONGRESS OF

May 12-14  
**20  
22**  
Fruske terme  
**Vrdnik**  
**Serbia**

Scintigraphic detection of dialysis solution leakage in patients treated with continuous ambulatory peritoneal dialysis

Lela Vranić, Ljiljana Kojić, Jelica Vidojević, Marina Vlajković, Milena Rajić,  
Center of Nuclear Medicine, University Clinical Center Niš, Niš

11:00-11:10

Closing the Congress

TBD

Trip (optional)



## **ILP1**

### **Myocardial perfusion stress test: is it worth?**

Isidora Grozdic Milojevic Center of Nuclear Medicine with PET, University Clinical Center of Serbia,  
E-mail address of the presenting author: drisidora.grozdic@yahoo.com.

To test the utility of the Tc99m-sestaMIBI myocardial perfusion stress test (MPS) over stress echo test (SEHO) in dyslipidemic patients with intermediate pre-test probability score. 56 dyslipidemic patients (42 males and 14 females) with a suspected/known ischaemic heart disease and intermediate pre-test probability score underwent MPS and SEHO. They were followed for  $25.77 \pm 6.19$  months. The data about the new-onset cardiac events and possible coronary angiography (CA) were collected. MPS was positive in 80% of the patients, SEHO in 68% of the patients. Results of the SEHO and MPS showed a good correlation ( $p < 0.001$ ,  $\mu = 0.505$ ). Both procedures had a good correlation with CA findings in the follow-up. Cardiac events occurred in 57% of the patients. The MPS result, SSS, SDS were significantly associated with the new-onset cardiac events ( $p < 0.05$ ). The patients with higher SDS had more chance to get a cardiac event in the follow-up (ROC curve area = 0.719,  $p = 0.003$ ). MPS sensitivity was 91%, specificity 56%; SEHO sensitivity 85% and specificity 61%. MPS may be useful in predicting a future cardiovascular event. It is sufficiently informative, objectified by quantification software, and with correspondingly reduced radiation doses it may be the method of choice in patients with intermediate pre-test probability score.

Keywords: Intermediate pre-test probability score; Myocardial perfusion stress test; SPECT; Stress echo test; Usefulness.



## IL2

### **Diuresis renography and ultrasonography in children with antenatally detected hydronephrosis can support diagnoses and suggest related surgery treatment**

M Radulović, Institute of Nuclear Medicine, Military Medical Academy, Belgrade, E mail address of the presenting author: mradulovic.79@gmail.com.

**Objective:** Prenatal ultrasound (US) screening detects the hydronephrosis (HN)-dilatation of fetal renal collecting system in 1%-5% of all pregnancies. In most children, HN is detected by prenatal US screening between 18-20 gestational week. Pelvi- ureteric junction (PUJ) stenosis is the most common etiological factor of prenatal HN and requires postnatal follow-up. Diuresis renography plays important role in the follow-up by complementing morphological information obtained by US with the data about differential renal function (DRF) and drainage. We studied the association between ultrasound parameters and results of diuresis renography in first diagnosed PUJ stenosis and the predictive factors of pyeloplasty in order to evaluate the usefulness of diuresis renography in these children postnatally. **Patients and methods:** Children with antenatally detected HN attributed to presumed PUJ stenosis were investigated with mercapto-acetyltriglycine (MAG3) diuresis renography. Parents gave informed consent for the procedure. The inclusion criteria were: age up to 4 years, diagnosis of prenatal HN determined by US during pregnancy based on the antero-posterior diameter (APD) of renal pelyon and at least one post-natal US which confirmed diagnosis. Exclusion criteria were: APD of pelyon <10mm, previous surgical treatment of HN, vesicoureteral reflux excluded by micturating cystourethrography, and patients having any anomaly of the contralateral kidney. Sixty two patients 43 boys, 19 girls, median age 16 months were selected. They were divided into three groups based on the size of pelyon, three groups based on the calyceal size and two groups according to thickness of parenchyma. Renography was performed for 24 minutes after the iv. application of 99mTc MAG3, 144 ten-sec images were applied. Furosemide was administered after 2 min. (F+2). Post-void static images were acquired at 60min. The non-commercial software developed by International Atomic Energy Agency was applied to process the studies. The criteria for pathological findings (poor or no drainage) were the renographic curve maintaining a plateau, Normalized Residual Activity (NORA) at 20. min.>1.62, Output efficiency (OE) at 20. min.<71%, postmicturating NORA >0.11. The DRF was considered normal within the range of 45%-55%.

**Results:** Good drainage had 74% of children, partial drainage 11%, and poor 15%. There was a clear association between the size of pelyon, calyces, parenchyma thickness and drainage. There was also a clear association between the calyceal size, parenchyma thickness and DRF. Differential renal function was <45% in 18% of children. A relation between the type of drainage and DRF was not determined. Thus, 66.7% of those with poor drainage had preserved DRF. Seven out of nine children with poor drainage underwent pyeloplasty. The threshold for pyeloplasty was the pelyon of 18mm and calyces of 10mm. The model of the multivariate logistic regression which included ultrasound parameters (APD of pelyon, calyces size and parenchymal thickness), drainage and DRF, which were significant predictors in univariate analysis, showed that only drainage was an independent predictor for the need of pyeloplasty.

**Conclusion:** Antero-posterior diameter of the pelyon <15mm indicates a favorable course of congenital HN in most children. Pattern of drainage obtained by diuresis renography was the only independent predictor for the need of pyeloplasty



### IL3

#### **Optimization of the radiolabelling method for improved in vitro and in vivo stability of $^{90}\text{Y}$ -albumin microspheres**

Vukadinović Aleksandar , Laboratory for radioisotopes, Vinča Institute of Nuclear Sciences, National Institute of the Republic of Serbia, University of Belgrade, Belgrade, E-mail address of the presenting author: vukadinovic@vin.bg.ac.rs

Biologically stable  $^{90}\text{Y}$ -labelled albumin microspheres (AMS) were developed by optimizing the process of their preparation. Three formulations of  $^{90}\text{Y}$ -AMS were initially prepared with high radiolabelling yield but depending on the step when the radionuclide  $^{90}\text{Y}$  and DTPA chelator were added, radiolabelled microspheres with different in vitro and in vivo stability were obtained. DTPA was proved as a useful chelating agent that tightly links radionuclide  $^{90}\text{Y}$  to albumin. Also, AMS radiolabelled via DTPA during preparation and before microspheres stabilization, showed significant in vitro and in vivo stability ready for the potential use in selective internal radiation therapy.

Keywords: ( $^{90}\text{Y}$ ); DTPA; Human albumin microspheres; In vivo stability; Radiolabelling.



#### **IL4**

##### **Title: $^{99m}\text{Tc}$ -PYP in patients with suspected ATTR cardiac amyloidosis**

Venjamin Majstorov, Institute of Pathophysiology and Nuclear Medicine, Faculty of Medicine, UKIM Skopje, North Macedonia; E-mail address of the presenting author: venjamin.majstorov@gmail.com

Amyloidosis represents rare heterogeneous group of diseases characterized by excessive building up and tissue deposition of various abnormal proteins. It could affect one organ when in localized form or multiple organs when in systemic form. In case of cardiac involvement (cardiac amyloidosis) leads to restrictive cardiomyopathy and congestive heart failure and is associated with unfavorable outcome. Significant cardiac involvement is most often present in familial and senile transthyretin amyloidosis (ATTR) and light-chain amyloidosis (AL). ATTR is caused by many different gene mutations for transthyretin protein that turns normally soluble form into misfolded forms that are deposited in myocardium and other organs leading to subsequent structural and functional changes.

Several SPECT as well as PET radiotracers can be offered today with different success in the diagnosis of amyloidosis, most widely being used two bone-seeking phosphate derivatives labeled with  $^{99m}\text{Tc}$ :  $^{99m}\text{Tc}$ -DPD and  $^{99m}\text{Tc}$ -PYP. We present our experience with  $^{99m}\text{Tc}$ -PYP SPECT in patients with suspected ATTR cardiac amyloidosis by using semi-quantitative visual score as well as quantitative analysis by drawing region of interest over heart and corrected for contralateral counts to calculate heart-to-contralateral ratio (H/CL). We confirmed that  $^{99m}\text{Tc}$ -pyrophosphate is avidly taken up in ATTR patients.  $^{99m}\text{Tc}$ -PYP scintigraphy presents simple, readily available and accurate nuclear method for both diagnosis and confirmation of ATTR subtype of c



9th BALKAN  
CONGRESS OF  
**NUCLEAR  
MEDICINE**  
AND SERBIAN  
CONGRESS OF

May 12-14  
**20  
22**  
Fruske terme  
**Vrdnik  
Serbia**

## O1

**Production and quality control of radiopharmaceuticals in “Vinča” Institute of Nuclear Sciences**  
Aleksandar Vukadinović<sup>1</sup>, Marija Mirković<sup>1</sup>, Drina Janković<sup>1</sup>, Olivera Laban-Božić<sup>1</sup>, Marko Perić<sup>1</sup>, Đorđe Petrović<sup>1</sup>, Dalibor Stanković<sup>1</sup>, Zorana Milanović<sup>1</sup>, Sanja Vranješ-Đurić<sup>1</sup>, Laboratory for radioisotopes, <sup>1</sup>Vinča Institute of Nuclear Sciences, University of Belgrade, P. O. Box 522, 11001 Belgrade, Serbia; E-mail address of the presenting author: vukadinovic@vinca.rs

During the long-term scientific research and in cooperation with nuclear medicine centers, the Laboratory for Radioisotopes has developed a wide range of radiopharmaceuticals used in diagnosis and therapy.

Since its founding in 1959, the Laboratory for Radioisotopes has been producing all major categories of radiopharmaceuticals, including ready-for-use radiopharmaceuticals, radionuclide generators, and radiopharmaceutical kits.

One of the first radiopharmaceuticals produced in our Laboratory are Sodium iodide <sup>131</sup>I capsules used to treat hyperthyroidism and papillary and follicular thyroid carcinoma, including metastatic disease.

<sup>99</sup>Mo/<sup>99m</sup>Tc generator and a wide range of kits for labeling with <sup>99m</sup>Tc have been produced in our Laboratory for over 40 years. Sodium pertechnetate (<sup>99m</sup>Tc) is used for the imaging and functional studies of the thyroid, brain, salivary glands, gastrointestinal tract, while in the form of compounds labeled with <sup>99m</sup>Tc, it is used for the imaging of the different organs and tissues.

Special attention is paid to radiopharmaceuticals' quality control (QC), ensuring the purity, potency, product identity, biologic safety, and efficacy of our radiopharmaceuticals. All quality control procedures applied to nonradioactive pharmaceuticals are equally applicable to radiopharmaceuticals; in addition, tests for radionuclidic and radiochemical purity have to be carried out.

Quality assurance (QA) is essential. It includes planned and systematic actions needed to provide adequate confidence that a product, service, or result will satisfy given requirements for quality and be fit for the intended use. Quality Assurance includes final laboratory testing (QC) and covers all the factors that may affect the quality of the radiopharmaceutical preparation.

Today, the Laboratory for Radioisotopes is the unique center in the Balkan region registered for the production of radiopharmaceuticals.





**O2**

**cGMP Manufacturing of I-131 radio labeled small molecules - the Lantheus experience**

Alexander T. Yordanov; E-mail address of the presenting author: yordanov.radiochemistry@gmail.com

Sodium I-131 iodide is one of the oldest radiopharmaceuticals known. Traditionally, it has been used for dosimetry and therapy of thyroid malignant disease for more than half a century. More recently, a I-131 radio labeled antibody (Bexxar) was approved for patient use and placed on the market only to be discontinued a decade later, due to persistent manufacturing and supply issues. Currently, AZEDRA (no carrier added I-131 MIBG, Ultratrace Iobenguane 131 I) is a I-131 radio labeled small molecule approved by the U.S. Food and Drugs Administration (FDA) and available on the North American Market. Another small molecule, I-131 1095, is in clinical studies with patients and if approved by the FDA, could be commercially available by 2025. This presentation will discuss the challenges of scaling up small I-131 radio labeled molecules commercial manufacturing, and how Lantheus Medical Imaging has overcome them. AZEDRA (Iobenguane I-131) has a radioactivity concentration of 555 MBq/mL (15 mCi/mL) injection is a sterile, clear, colorless to pale yellow solution. Each single dose vial contains iobenguane (0.006 mg/mL), sodium ascorbate (58 mg/mL) and sodium gentisate (23 mg/mL) in Water for Injection, USP. The pH range of the solution is 4.5 to 5.5, with specific activity of appr. 2,500 mCi/mg (92,500 MBq/mg). Quality Control analysis (performed by radioanalytical HPLC) shows at least 97% radiochemical purity of the final drug product.



O3

**10 YEARS OF EXPERIENCE IN LYMPHOSCINTIGRAPHY AND SENTINEL LYMPH NODE BIOPSY IN CUTANEOUS MELANOMA– SINGLE CENTER ANALYSIS**

Ljiljana Radosavcev<sup>1</sup>, M.Rajović<sup>2</sup>, L. Kandolf Sekulovic<sup>3</sup>, M. Radulovic<sup>1</sup>, Z. Mijuskovic<sup>3</sup>, N. Petrov

<sup>4</sup> <sup>1</sup>Institute of Nuclear Medicine <sup>2</sup>Clinic for Plastic and Reconstructive Surgery <sup>3</sup>Clinic for Dermatology

<sup>4</sup>. Center of Pathology and Forensic Medicine Military Medical Academy, Belgrade, Serbia; E-mail address of the presenting author: lilaj2805@gmail.com

**OBJECTIVE:** Sentinel lymph node biopsy (SLNB) is the most important tool for nodal staging in clinically node negative melanoma patients. The aim of this study was to present the 10 year`s results on SLNB in our Institution. **METHODS:** A cohort comprised 420 patients identified for SLNB between 2010-2020. We examined the association of clinical and histological characteristic on SLN metastatic involvement in patients with cutaneous melanoma. Regarding the SLN nuclear medicine imaging characteristics, SLN positivity was linked to number of draining basins, SLN location, number of SLN visualized on scintigraphy and excised for patients. The significance level was determined at p value less than 0.05. **RESULTS:** the overall detection rate of SLN was 97.6% of which 19.3% were metastatic. In ten patients, sentinel lymph node was not found, on imaging in 3 patients, and intraoperatively in 7 patients. Drainage to one regional basin was seen in 344 (81.9 %) and multiple drainage regions (up to three) - in 71 patients (17%). In transit lymph nodes were detected in 20 patients. The mean number of lymph nodes visualized on scintigraphy was 1.83, compared with 2.45 excised per patients. Primary tumor thickness and nodular histology, acral location and male gender were significantly associated with SLN status (p<0.05). **CONCLUSION:** Beside the well established primary tumor thickness as the predictor of SLN positivity; we observed acral body site location and nodular melanoma subtype to significantly enhance the risk for regional metastases. Lymphoscintigraphy imaging characteristics were not significantly associated with SLN status.



#### O4

### **QUALITY ASSURANCE AND QUALITY CONTROL OF INTRAOPERATIVE GAMMA PROBE FOR SENTINEL LYMPH NODE BIOPSY**

Milena Dimcheva<sup>1</sup>, Teodor Sofiyanski<sup>1</sup>, Sonya Sergieva<sup>1</sup>, Aleksandra Jovanovska<sup>1</sup>, Bozhil Robev<sup>2</sup>

<sup>1</sup>Department of Nuclear Medicine, Sofia Cancer Center, Sofia, <sup>2</sup>Department of Medical Oncology, University Hospital St. Ivan Rilski, Sofia; E-mail address of the presenting author: m.dimcheva@gmail.com

**Introduction:** Intraoperative gamma probes are used to detect the radioactive uptake in surgical procedures called intraoperative lymphatic mapping or sentinel lymph node biopsy, a minimally invasive technique for evaluating the potential spread of cancer to lymph node tissues and organs. The objective of Quality Assurance (QA) is to ensure the safety and diagnostic accuracy of the equipment during surgical use. The Quality Control (QC) measurements of intraoperative gamma probe are based on procedures described in the standards publication NU 3-2004 published by the US National Electrical Manufacturers Association (NEMA). The aim of this work is to present a comprehensive set of test procedures including acceptance testing and regular quality control procedure for intraoperative gamma probes. **Materials and Methods:** The measurements were performed with a CsI(Tl) detector of intraoperative gamma probe CXS-SG04 Crystal Photonics. The tests were done with a small amount of activity of Tc-99m (18.5 MBq) and reference source of Co-57 (3.5 MBq). **Results:** The sensitivity of the gamma probe at distances of 10 mm, 30 mm and 50 mm is 19,175, 3374 and 1628 cps/MBq. Better results were obtained with Co-57 radioactive source. Sensitivity through side shielding in air at 50 mm lateral distance is lower for Co-57 compared to Tc-99m due to lower penetrating ability at 122 keV. The spatial and angular resolutions were  $17,0 \pm 4,0$  mm FWHM and  $36,0^\circ \pm 4,0^\circ$  FWHM at 30 mm distance from the probe. The energy resolution is poorer at Co-57, since less energy deposited. The shielding effectiveness and leakage sensitivity are  $99.92 \% \pm 0.06 \%$  and  $0.06 \% \pm 0.03 \%$ , respectively. **Conclusion:** The results of the measurements performed on the intraoperative gamma probe meet the NEMA NU 3-2004 requirements. Clinically used equipment should be object for quality control to ensure the correctness of the measured values. It is an essential part of quality assurance programme.



## O5

### **Incidence of Differentiated Thyroid Carcinoma in Bethesda III Classified Nodules**

Emil Matovina, Center for Nuclear Medicine, Institute for Oncology and Radiology, Sremska Kamenica; E-mail address of the presenting author: donemilions@gmail.com

#### Background:

Fine needle aspirations has important role in evaluation of thyroid nodules by estimating the risk of malignancy. Bethesda classification is standardized, category-based reporting system for thyroid fine-needle aspiration (FNA) specimens. Atypia of Undetermined Significance, categorized as Bethesda III, according to literature implies the risk of malignancy between 6 and 18%, however this assessment varies between institutions.

#### Methods:

This is retrospective study of 97 patients with thyroid nodules categorized as Bethesda III, resected on Oncology Institute of Vojvodina between January 2017 and January 2019. Patients were divided in four groups according to ultrasonographic findings and level of atypia reported on cytology finding. In first group were patients with ultrasonographically suspicious nodules and intermediate atypia, in second group were patients with ultrasonographically suspicious nodules and mild atypia, in third group were patients with non ultrasonographically suspicious nodules and intermediate atypia and in fourth group were patients with non ultrasonographically suspicious nodules with mild atypia. Incidence of malignancy was calculated in all operated patients and in each group separately.

#### Results:

Among 1887 patients with thyroid nodules who undergone FNA, in 6% were found nodules categorized as Bethesda III (113 of 1887) and 97 of them underwent surgery in within 12 months after FNA. Malignancy was found in 27% of the patients (26 of 97). In 93% of malignancies was found papillary cancer and in 7% was found follicular cancer. In the first group of patients, with ultrasonographically suspicious nodules and intermediate atypia, incidence of malignancy was highest and it was found in 36% of the patients (13/36). In the second group of patients, with ultrasonographically suspicious nodules but mild atypia, incidence of malignancy was slightly lower, and it was found in 31% of patients (10/32). In third groups of patients incidence of malignancy was significantly lower, and it was found in 15% of patient (2/13) and in fourth group malignancy was found in only 6% of patients (1/16).

#### Conclusions:

Thyroid nodules classified as Bethesda III are heterogeneous group of nodules with incidence of malignancies that varies between institutions. In this study incidence of malignancy was 27%. Most guidelines recommend repeat of FNA, molecular testing, or lobectomy. Significantly higher incidence of malignancy in nodules which are ultrasonographically suspicious and with higher level of atypia reported in cytopathology finding, shows that those two criteria can help in making decision of further treatment this group of patients.



## P1

### EVALUATION OF ACCURACY OF $^{99m}\text{Tc}$ -DTPA SINGLE-PLASMA SAMPLE METHOD IN ESTIMATION OF GFR VALUES

Peshevska A<sup>1</sup>, Makazlieva T<sup>1</sup>, Majstorov V<sup>1</sup>, Milenkova M<sup>2</sup>, Rambabova Bushljetikj I<sup>2</sup>, Miladinova D<sup>1</sup>

<sup>1</sup> Institute of Pathophysiology and Nuclear Medicine, Medical Faculty, University Ss Cyril and Methodius, Skopje

<sup>2</sup> University Clinic of Nephrology, University Clinic "Mother Teresa", University Ss Cyril and Methodius, Skopje; E-mail address of the presenting author: a.peshevska@medf.ukim.edu.mk

**Introduction:** Nuclear medicine (NM) methods are simple and non-invasive and play important role in GFR determination especially in evaluation of living kidney donor acceptability. Different methods are available, but most reliable and practically easy applicable are NM methods.

**Aim:** The aim of our study was to evaluate the correlation between measured GFR (mGFR) obtained by the three-plasma sample (TPS) slope–intercept NM method (reference method) v.s. estimated GFR (eGFR) using single plasma sample method (SPSM) at 120 min, 180 min, 240 min and Gates method using two different background regions of interest.

**Material and methods:** 82 subjects (33 male/49 female) were included and were divided in three groups based on their mGFR with TPS slope–intercept method. In all patients, eGFR was quantified with SPSM at 120 min, 180 min, 240 min and eGFR with Gates method using two different background regions of interest.

**Results:** In all three group of patients, our study revealed very strong positive significant correlation between SPSM at 120 min, 180 min, 240 min with the reference method. On the contrary, our analyses revealed that Gates method underestimate GFR and shows high bias and moderate to strong correlation. Exception was the group of patients with mGFR  $<60 \text{ mL/min/1,73 m}^2$  where we found very strong positive significant correlation between Gates method with the reference.

**Conclusion:** SPSM method shows very strong correlation with the reference and low bias in all three group of patients. Furthermore, best correlations with the reference is observed for SPSM\_240 in the group of patients with GFR  $<60 \text{ mL/min/1,73 m}^2$ , for SPSM\_180 in the group of patients with GFR values 60-84 mL/min/1,73 m<sup>2</sup> and for SPSM\_120 in the group of patients with GFR  $\geq 85 \text{ mL/min/1,73 m}^2$ . Our analyses revealed that SPSM method can be a useful substitution in exact estimation of GFR values in clinical practice.



## P2

### **The role of perfusion lung scintigraphy in follow-up patients after COVID-19 infection**

Ana Jakovljević<sup>1,2</sup>, Dragan Burić<sup>1,2</sup>, Radmila Žeravica<sup>1,2</sup>, Branislava Ilinčić<sup>1,2</sup>, Veljko Crnobrnja<sup>1,2</sup>, Marija Papuga Vukmirović<sup>2</sup>. <sup>1</sup>University of Novi Sad, Faculty of Medicine Novi Sad, Department of pathophysiology and laboratory medicine <sup>2</sup>University Clinical Center of Vojvodina, Center for laboratory medicine, Novi Sad; E-mail address of the presenting author: jakovana@gmail.com

Introduction: Perfusion lung scintigraphy play an important role in early detection of pulmonary thromboembolism and the aim of this study was to investigate scintigraphy findings of lung perfusion defects in patients after Covid-19 infection, with persistent elevation of D-dimer, from the beginning of infection or time after the end of acute infection. Material and methods: Retrospectively, 56 patients who underwent perfusion lung scintigraphy (<sup>99m</sup>Tc-MAA radiopharmaceutical) with high levels of D-dimer were analyzed. All patients included in this study had negative C-reactive protein, and conditions that could affect level of D-dimer are excluded (secondary infection, myocardial infarction, renal failure, coagulopathy etc.). All patients were scheduled for laboratory analysis (D-dimer, C-reactive protein, liver enzymes AST, ALT, urea and creatinine) and chest radiography on the same day with performance of perfusion lung scintigraphy. Only patients with chest x-ray mismatch were included. Results: We found 22/56 perfusion scintigraphy with subpleural small defects, 17/56 with small subsegmental defects, 7/56 with large segmental defects and 10/56 with no perfusion defects. We found significantly lower values of D dimer in a group with no defects compared to group 1. with subpleural defects [1,53 ± 0.88] vs. (3,22 ± 0.55), P <0.001] and group with large segmental defects [1,53 ± 0.88] vs. (4,01 ± 0.73), P <0.001]. Conclusion: Perfusion lung scintigraphy have significant role in detection chronic thromboembolic and microvascular complication after Covid-19 infection.



### P3

#### **SEMICQUANTITATIVE ASSESSMENT OF TUBULAR KIDNEY FUNCTION USING THE INDEX OBTAINED FROM SCINTIGRAPHIC IMAGE**

Dragan Burić<sup>1,2</sup>, Tanja Ostojić<sup>1,2</sup>, Radmila Žeravica<sup>1,2</sup>, Branislava Ilinčić<sup>1,2</sup>, Ana Jakovljević<sup>1,2</sup>, Veljko Crnobrnja<sup>1,2</sup>, Marija Papuga Vukmirović<sup>2</sup>, <sup>1</sup>University of Novi Sad, Faculty of Medicine Novi Sad, Department of pathophysiology and laboratory medicine<sup>2</sup>University Clinical Center of Vojvodina, Center for laboratory medicine, Novi Sad, E-mail address of the presenting author: buric.dragan91@gmail.com

Introduction. Radionuclide methods have significant role in the examination of renal function. The aim was to define and apply the index obtained from the scintigraphic image and to compare its values with the obtained values of ortho-iodo-hippuran clearance as an indicator of the total effective renal plasma flow. Material and methods. Retrospectively, 70 patients who underwent static renal scintigraphy and hippuran clearance were analyzed. The index we calculated represents the ratio of the mean values of the number of detections per pixel in the background regions with the mean values of the number of detections per pixel in the kidney regions. Patients were divided into three groups in relation to the obtained value of effective renal plasma flow: group 1 - mild renal impairment (reduction of effective renal plasma flow  $\leq 20\%$ , N = 18), group 2 - moderate renal impairment (reduction of effective renal plasma flow) plasma 20–50%, N = 26) and group 3 - severe renal impairment (reduction of effective renal plasma flow 50–70%, N = 26). Results. Significantly lower background-to-renal index values were observed in patients with mild reduction in effective renal plasma flow, compared with patients with moderate and severe reduction [ $0.105 \pm 0.05$ ] vs. ( $0.134 \pm 0.056$ ) vs. ( $0.275 \pm 0.154$ ), P <0.001]. A significant linear correlation was observed between background-to-renal index and effective renal plasma flow ( $r = 0.60$ , p <0.0001). A background-to-renal index of 1.3 with 62% sensitivity and 100% specificity differentiates patients with mild or moderate renal impairment. Conclusion. Background to-renal index is a simple method for assessing total tubular renal function and may be useful tool when determining whether the patient should be appointed for further in-vitro assessment of global renal function.



#### P4

##### **<sup>99m</sup>Tc-RADIOPHARMACEUTICALS: QUALITY CONTROL OF <sup>99m</sup>Tc-DPD**

Dragana Stanković<sup>1</sup>, Marija Mirković<sup>1</sup>, Magdalena Radović<sup>1</sup>, Drina Janković<sup>1</sup>, Olivera Laban-Božić<sup>1</sup>, Milovan Matović<sup>2</sup>, Marija Jeremić<sup>2</sup>, Sanja Vranješ-Đurić<sup>1</sup>, <sup>1</sup>Laboratory for radioisotopes, <sup>1</sup>Vinča Institute of Nuclear Sciences, National Institute of the Republic of Serbia, University of Belgrade, P. O. Box 522, 11001 Belgrade, Serbia, <sup>2</sup>Centre of Nuclear Medicine, Clinical Centre Kragujevac, Zmaj Jovina 30, 34000 Kragujevac, Serbia; E-mail address of the presenting author: dragana.s@vinca.rs

DPD is a diphosphonate which is widely used in nuclear medicine bone scintigraphy as a noninvasive tool. <sup>99m</sup>Tc-DPD is one of the first radiopharmaceuticals which the Laboratory for Radioisotopes of the Vinča Institute has developed in a wide range of radiopharmaceuticals used in diagnosis and therapy. Although used exclusively as a diagnostic tool, most often only once, this radiopharmaceutical, from a pharmaceutical point of view, is subject to the same legal regulations in terms of quality control as drugs.

The production of <sup>99m</sup>Tc-DPD in the Laboratory for Radioisotopes of the Vinča Institute is carried out in accordance with national Medicines law, the principles of the Guidelines for Good Manufacturing Practice and the Directive 2001/83.

The quality control of a radiopharmaceutical kit includes tests performed in the Laboratory for Radioisotopes, as well as tests that need to be done in nuclear medicine centers, immediately before application to the patient.

Quality control of <sup>99m</sup>Tc-DPD in the Laboratory for Radioisotopes of the Vinča Institute of Nuclear Sciences includes 2 groups of tests: those performed before radiolabeling and tests performed after labeling with <sup>99m</sup>Tc. Before labeling with <sup>99m</sup>Tc, tests are performed to determine the uniformity of the dosage form, to test the uniformity of the active substance content and to determine the tin (II) ion content, while after labeling the clarity and degree of opalescence of the solution are determined, pH values, sterility, impurities <sup>99m</sup>TcO<sub>4</sub><sup>-</sup> and <sup>99m</sup>Tc colloid. Biodistribution tests on experimental animals (rats) are also performed. This type of testing is of particular importance because it determines the distribution of radiopharmaceuticals to organs, in order to confirm the behavior of the drug in vivo.

Before administration to the patient, in nuclear medicine centers, it is necessary to check the yield of labeling DPD with technetium-99m to confirm the radiochemical purity of the obtained radiopharmaceutical drug. This test is performed by chromatography, using ITLC-SG as chromatography strips, and acetone and physiological solution as mobile phases. The drug can be used only if the radiochemical purity of the radiopharmaceutical is not less than 95%, or the content of radiochemical impurities is not more than 5%.





**P5**

**DEDICATED HEAD AND NECK  $^{18}\text{F}$ -FDG PET/CT PROTOCOL IN DETECTING CERVICAL LYMPH NODE METASTASIS**

Todorova-Stefanovski,D.<sup>1</sup>, Spirov,G.<sup>1</sup>, Tasevski,S.<sup>1</sup>, Besliev,S.<sup>1</sup>, Angjeleska,M.<sup>1</sup>, Ugrinska,A.<sup>1</sup>

<sup>1</sup>University Institute for Positron Emission Tomography Skopje; E-mail address of the presenting author: dusicastefanovski@gmail.com

**PURPOSE:** The purpose of this study is to compare dedicated head and neck PET/CT protocol to standard torso PET/CT protocol in detecting cervical lymph node metastasis in patients with head and neck cancer.

**MATERIALS AND METHODS:** Retrospective study consisted of patients with head and neck cancer who underwent  $^{18}\text{F}$ -FDG PET-CT examination in the last six months in our institution after chemo or/and radiotherapy. All of the PET/CT examination consisted of dedicated head and neck scanning (cranial base to the thoracic inlet in an arm-down position, three bed positions - 3 min per bed position), followed by standard torso scanning (skull base through the proximal thighs with arms in a raised position - 2 min per bed position). CT scan parameters were identical in both scanning: 120 kVp, 30 mAs (reference, Siemens CareDose), 5 mm slice thickness and FOV of 50 cm. FDG uptake was evaluated visually and number of lesions were compared.

**RESULTS:** 30 patients (21 men, 9 women; age range, 23-72 years) underwent  $^{18}\text{F}$ -FDG PET-CT. In 9 patients (9/30, 30%) increased metabolic activity was detected in lymph nodes suggestive of metastasis. 26 metastasis were detected using dedicated head and neck scanning, compared to 23 with standard torso scanning (26 vs 23). Only in two patients (2/30, 6%) additional lesions was seen with the dedicated head and neck scanning.

**CONCLUSION:**

Dedicated head and neck scanning helped us detect additional lesions in only 6% of the patients and consequently did not influenced the treatment plan.

Key words: head and neck cancer, PET/CT, protocol



## P6

### **The use of Deauville score in a determination of a need for further treatment in patients with Hodgkin lymphoma and diffuse large B cellular lymphoma (DLBCL)**

Nikola Pantić, Jovana Živanović, Jelena Malićević, Center for Nuclear Medicine with PET, University Clinical Center of Serbia; E-mail address of the presenting author: nikolapantic944@gmail.com

**Objective:** The Deauville 5-point scoring system is a scale which uses fluorine-18 fluorodeoxyglucose Positron Emission Tomography/Computed Tomography ( $^{18}\text{F}$ -FDG PET/CT) in the initial staging and assessment of treatment response in Hodgkin lymphoma and diffuse large B cellular lymphoma (DLBCL). The scale ranges from 1 to 5. Scores of 1 and 2 are considered to be negative, while scores 4 and 5 are considered to be positive. Deauville score 3 is, on the other hand, most frequently considered inconclusive and should be interpreted according to clinical context. **Aim:** Evaluation of the role of Deauville score in a decision making regarding further therapeutic approach in patients with Hodgkin lymphoma and DLBCL. **Material and methods:** Eighteen patients with histopathological confirmation of DLBCL and thirty patients with histopathological confirmation of Hodgkin Lymphoma were included in this study. Indications for  $^{18}\text{F}$ -FDG PET-CT were initial staging, restaging after therapy and suspected recurrence. Deauville score was determined based on the maximum standardized uptake value (SUVmax) of lymph nodes or other affected organs, on one side, and SUVmax of two reference organs (mediastinal blood pool and liver), on the other side. **Results:** Eight patients with DLBCL and eighteen patients with Hodgkin lymphoma (54.2% of a total number of patients) were found to be positive. Five patients with DLBCL and seven patients with Hodgkin lymphoma (25%) were found to be negative. Findings were inconclusive in five patients with DLBCL and five patients with Hodgkin lymphoma (20.8%). **Conclusion:** Deauville score is a useful tool in the assessment of a need for further therapy in patients with Hodgkin lymphoma and DLBCL.



**P7**

**F-18-FDG PET/CT in squamous cell carcinoma**

Isidora Grozdic Milojevic<sup>1</sup>, Jelena Pantovic<sup>2</sup>, Jelena Crevar Malicevic<sup>2</sup>, Jovana Zivanovic<sup>2</sup>, Nikola Pantic<sup>2</sup>, Center for Nuclear Medicine with PET, University Clinical Center of Serbia; E-mail address of the presenting author: drisidora.grozdic@yahoo.com

Background: Squamous cell carcinomas (SCC), are a number of different types of cancer that result from squamous cells. These cells form on the surface of the skin, on the lining of the respiratory and digestive tracts etc.

Aim: To evaluate SCC and frequencies of their localizations based on the findings of <sup>18</sup>F-FDG PET/CT.

Material and methods: This study included 343 consecutive patients with SCC who were sent for the <sup>18</sup>F-FDG PET / CT. Inclusion criteria were: pathohistologically verified SCC; the existence of clinical, biochemical or radiological indicators of disease activity; absence of malignancy of any other localization, as well as absence of infection; and glycemia  $\leq 11$  mmol/l.

Results: The pathological findings on <sup>18</sup>F-FDG PET / CT were present in 86% of patients. There was statistically significant difference in the finding of <sup>18</sup>F-FDG PET / CT in relation to gender ( $p > 0.006$ ). The disease was more often present in women. The most common localizations of disease were: lungs (70%), vagina/cervix (18%), gastrointestinal tract (18%), head and neck (5%). Highest SUV max levels were seen in the lungs  $11.78 \pm 8.38$ , vagina/cervix  $11.21 \pm 8.10$ , and skin changes in head and neck area  $6.32 \pm 3.96$ .

Conclusion: <sup>18</sup>F-FDG PET/CT can be informative in evaluation of SCC. Disease is present usually in women, although it is the same pathohistological type of disease, different organs accumulate this radioactive contrast differently.



## **P8**

### **LUNG METASTASES**

Ivana Pavković, Sonja Bobić-Zarač, Dragi Stanimirović, Jasenka Mijatović, Clinical Center of Republika Srpska, Banja Luka; E-mail address of the presenting author: ivanapavkovicbanjaluka@gmail.com

**Aim:** The aim of this paper is to present the case of a patient with suspected lung metastases from leiomyoma / leiomyosarcoma.

**Case report:** I present the case of a 43-year-old patient who have had uterine leiomyoma 10 years ago. In December 2021, recurrence was suspected, and myomectomy was performed. The PH finding was Leiomyosarcoma epitheloides uteri G2 (diameter 2 cm) with a tumor localized in the myometrium of the left uterine horn. After a month, reoperation was performed - hysterectomy with bilateral adnexectomy and omentectomy. On PH findings the diagnose of Leiomyosarcoma epitheloides uteri G2 was confirmed and it was without tumor cells in any other surgically removed structures. Then the CT of the thorax, abdomen and pelvis was performed due to a staging of the disease. The CT showed multiple circular soft tissue changes of the lung parenchyma (the largest was 3 cm in diameter), without significant post-contrast enhancement of density. The described changes could correspond to benign metastases of uterine leiomyoma. Due to this suspicion, PET/CT was performed, which showed multiple lung changes with a mild accumulation of the  $^{18}\text{F}$ -FDG (SUVmax up to 1,3).

The conclusion was that this lung changes were most likely to correspond to benign leiomyoma metastases, less likely to leiomyosarcoma metastases. Biopsy was recommended, and in March 2022 it was performed a minimally invasive biopsy of changes in the lungs. PH finding is in progress.

**Conclusion:** Our patient is presented as an interesting case due to the suspicion of benign lung metastases of leiomyoma and it's differentiation from leiomyosarcoma metastases using PET / CT.

**Key words:** PET / CT, leiomyoma, leiomyosarcoma



**P9**

**F-18-FDG PET/CT scan in patients with suspicion of recurrent pancreatic cancer**

J. Maličević Crevar<sup>1</sup>, V.Artiko<sup>1,2</sup>, M.Veljković<sup>1</sup>, N.Pantić<sup>1</sup>, J.Živanović<sup>1</sup>, S.Beatović<sup>1,2</sup>, D.Šobić Šaranović<sup>1,2</sup>; Centre of Nuclear Medicine with PET, Clinical Centre of Serbia; E-mail address of the presenting author: malicevicjelena@gmail.com

**Objective:** Pancreatic cancer remains one of the most aggressive tumor with the lowest survival of all common cancer. The five-year survival rate for people with pancreatic cancer is 5- 10%. After treatment and removal of pancreatic cancer, its recurrences are frequent and their early detection is importance for further treatment.

**Aim:** The aim of this study was to investigate the value of (<sup>18</sup>F) fluoro-2-deoxy-D-glucose positron emission tomography (<sup>18</sup>F-FDG PET)/computed tomography (CT) in therapy monitoring, especially in detecting recurrent pancreatic cancer. Correlation between results of <sup>18</sup>F-FDG PET/CT scan and diagnostic contrast-enhanced CT scan has been tested.

**Methods:** A total of 25 patients, 14 men and 11 women, mean age 68.9±10.7 years, who had undergone <sup>18</sup>F-FDG PET/CT studies for suspected recurrent pancreatic carcinoma were retrospectively analyzed. Correlation between results of <sup>18</sup>F-FDG PET/CT scan and diagnostic contrast-enhanced CT scan has been tested. The degree of metabolic activity was examined visually and semi-quantitatively using maximum standardized uptake value (SUVmax).

**Results:** 24 patients out of 25 PET/CT subjects were positive for recurrence 96% (24/25). CT examination was less successful 7 patients were positive 63.6% (7/11) for recurrence and 4 negative 36.3% (4/11). Chi test p< 0.01.

**Conclusions:** <sup>18</sup>F-FDG PET/CT is superior to CT in evaluation for detecting recurrent pancreatic carcinoma, and may thus contribute to improving patient treatment.



## P10

### **Case report on a patient with neurofibromatosis type 1 diagnosed using FDG PET/CT scanner**

Jelena Pantovic, Nevena Rankovic, Jovana Zivanovic, Centre of Nuclear Medicine with PET, Clinical Centre of Serbia; E-mail address of the presenting author: drjelena.pantovic@gmail.com

#### Introduction:

Neurofibromatosis type 1 (NF-1) is an inherited disease affecting about 1 in 3000 people worldwide. It is characterized by a range of symptoms and signs, one of which is the tendency to develop both benign and malignant tumours. PET/CT scanners have had a role in aiding in the diagnosis of NF-1 using fluorine-18-fluorodeoxyglucose (FDG).

#### Case:

Patient MM was diagnosed with NF-1 during their childhood, with no specific symptoms. An incidental finding of a mediastinal mass was discovered during a routine preoperative chest radiography. A CT scan was ordered in which the mass was identified and the working diagnoses were Burkitt's Lymphoma or a primary mediastinal tumour. Patient MM was then referred to do a PET/CT scan.

A PET/CT scan using FDG was performed in which the patient received 191MBq of FDG and had a low dose CT scan (40mA) without contrast.

The mediastinal mass was visualized on the PET/CT scanner with an intense inhomogeneous increased accumulation of FDG with a SUVmax (maximum standard uptake value) of 13.9. The mass was measured to be 36x44x67mm extending from the lower left lobe of the thyroid gland along the trachea and other large blood vessels in the upper mediastinum until the aortic arch.

Patient MM was thereafter referred to perform a video-assisted thoracic surgery (VATS) where the mass was removed and sent for histological testing. The results came back positive for benign neurofibroma.

#### Discussion:

The initial diagnostics and parameters obtained using the PET/CT scanner all pointed towards a malignant diagnosis. Furthermore, the SUVmax value was much higher for a benign tumour than the other described values in NF case reports (ranging from 3 to 5). Finally, indeed the diagnosis of a benign neurofibroma was made. This case report highlights the importance of a multidisciplinary approach in following up, diagnosing, as well as predicting future outcomes of NF-1.



9th BALKAN  
CONGRESS OF  
**NUCLEAR  
MEDICINE**  
AND SERBIAN  
CONGRESS OF

May 12-14  
**20  
22**  
Fruske terme  
**Vrdnik  
Serbia**

## P11

### **FOLLOW UP OF APPENDICEAL NEUROENDOCRINE TUMORS USING <sup>99m</sup>Tc-TEKTROTYD SCINTIGRAPHY**

Petrovic J.<sup>1,2</sup>, Sobic-Saranovic D.<sup>1,2</sup>, Petrovic N.<sup>1,2</sup>, Stojiljkovic M.<sup>1,2</sup>, Artiko V.<sup>1,2</sup> <sup>1</sup>Center for Nuclear medicine with PET, University Clinical Centre of Serbia, <sup>2</sup>Faculty of medicine University of Belgrade

**INTRODUCTION:** Neuroendocrine tumors of appendix (ANETs) known as carcinoids, even though rare, are the third most frequent (16.7%) gastrointestinal neuroendocrine tumors. Incidental ANETs occur in 0.2%-0.7% of emergency surgical resections due to suspected appendicitis, which is usually the first manifestation of ANET.

**AIM:** To establish the role of somatostatin receptor scintigraphy (SRS) in the management of patients with ANET.

**MATERIAL AND METHODS:** In total 35 patients was investigated (23 females, 12 males), average age  $43.7 \pm 17.3$  years, with histological diagnosis of ANET. Indication for SRS was restaging after surgery, and it was done in all patients early (2 h) and late (24 h), after i.v. application of 740 MBq <sup>99m</sup>Tc-Tektrotyd.

**RESULTS:** There were 12 true positive (TP), 19 true negative, 3 false positive and 1 false negative SRS results. In 10 patients Krenning score was 4, and in 2 was 3. Sensitivity of the method was 92.31%, specificity was 86.36%, positive predictive value was 80.00%, negative predictive value was 95.00% and accuracy 88.57%. Receiver operating characteristics analysis showed that SRS scintigraphy is a good test for detection TP cases [area under the curve of 0.850, 95% confidence interval (CI): 0.710-0.990,  $P < 001$ ]. Single photon emission computed tomography contributed diagnosis in 7 TP findings. In 8 patients SRS significantly changed the management of the patients (in two surgery was repeated, in 4 somatostatin analogues and in two peptide receptor radionuclide therapy). Median progression-free survival in SRS positive patients was 52 months (95%CI: 39.7-117.3 mo), while in SRS negative patients it was 60 months (95%CI: 42.8-77.1 mo), without statistically significant difference between the two groups ( $P = 0.434$ ).

**CONCLUSION:** Our results confirmed the value of SRS in the follow-up of the patients with ANET after surgery, if recurrences or metastases are suspected.

**Keywords:** Somatostatin receptor scintigraphy, Carcinoid, Appendix, Follow up, Radionuclide



## P12

### **FDG-PET in pre-surgical evaluation of focal pharmaco-resistant epilepsy- How FDG-PET helped us after 180+ epilepsy operations?**

L. Brajkovic<sup>1</sup>, D. Sokic<sup>3,2</sup>, N. Vojvodic<sup>3,2</sup>, A. Ristic<sup>3,2</sup>, V. Baščarevic<sup>4,2</sup>, A. Parojčić<sup>3,2</sup>, M. Stojiljkovic<sup>1,2</sup>, A. Ješić<sup>1</sup>, A. Pejovic<sup>3,2</sup>, D. Šobic-Šaranovic<sup>1,2</sup>, V. Artiko<sup>1,2</sup>, <sup>1</sup> Center for Nuclear medicine with PET, University Clinical Center of Serbia, <sup>3</sup>Clinic for Neurology, University Clinical Center of Serbia, <sup>4</sup>Clinic for Neurosurgery, University Clinical Center of Serbia, <sup>2</sup> Faculty of Medicine University of Belgrade, Belgrade; E-mail address of the presenting author: lelabrajko62@gmail.com

FDG-PET is a standard used in noninvasive stage of presurgical evaluation of patients with focal pharmaco-resistant epilepsy. Epileptogenic focus visualizes as hypometabolic zone interictally and as hypermetabolic zone ictally.

Objective: Evaluation of FDG-PET imaging in the presurgical lateralization and localization of epileptogenic foci

Patients and methods: FDG-PET scan was performed for 566 patients (ages 5-65 y) with focal temporal end extratemporal intractable epilepsy. The images were evaluated by visual (SPM) analyses and findings were compared with the epileptogenic zone determined by scalp video-EEG monitoring and MRI results.

Results: The epileptogenic focus manifested as hypometabolic zone interictally in 555 (98%) patients in following regions: temporal unilateral 325, temporal bilateral 45, frontal 92, parietal 39, occipital 7, insular 3, multiple zones 44. Eleven patients had ictal PET findings (2 nonconvulsive status, 2 epilepsy partialis continua, 7 complex partial seizures), with epileptogenic lesion presented as hypermetabolic region. Out of 184 operated patients (87% with temporal, 9,4% with extratemporal focus), 94(51%) were needed FDG-PET. In patients with the MRI-identified lesions less hypometabolic area on FDG-PET suggested better prognosis of surgery. In patients with MRI suspected bilateral hippocampal sclerosis or discordant video-EEG and MRI findings, PET helped in lateralization of foci. In patients with normal MRI initially (especially extratemporal epilepsy), FDG-PET hypometabolic zone pointed to a possible localization of focus. Detailed analysis of MRI findings and additional MRI sequences and coregistration of MRI and PET findings confirmed localization of epileptogenic foci, and according to that, patients were successfully operated. PET findings in neocortical temporal lobe epilepsy contributed to the decision of extensiveness of surgery-lesiectomy if there was maintained metabolism in mesiotemporal structure.

Conclusion: FDG-PET may help in precise determination of epileptogenic foci, especially in patients with normal-nonlesional MRI or discordant MRI and video-EEG findings. Size and localization of hypometabolic zone can help in the decision of resective surgery strategy





**P13**

**F-18-FDG PET/CT “Milk of Calcium” Gallbladder**

Ljiljana Zivgarević, Center for Nuclear Medicine with PET, University Clinical Center of Serbia, Belgrade; E-mail address of the presenting author: ljzivgarevic@gmail.com

**Introduction:** Milk of calcium bile or limy bile is a rare disorder in which the gallbladder is filled with a thick, paste-like, radiopaque material. Limy bile is present in 1 to 3% of patients operated on for gall stones in Western countries. It is a rare disorder predominantly of the adults with male/female ratio of 1/3. The etiology is unknown although gallbladder stasis is believed to be a prerequisite.

**Case report:** A 65-year-old patient was referred for a positron emission tomography/computed tomography (PET/CT) examination with a referral diagnosis of non-Hodgkin lymphoma (NHL), diffuse large B-cell lymphoma (DLBCL), after biopsy of tumor changes in both breasts, nodular skin changes in the neck, right axillary lymph nodes, and after 6 cycles of R-CHOEP of chemotherapy. The abdominal ultrasound performed 5 months before PET/CT examination, shows multiple calcified gallstones diameter less than 4mm with bill sludge. One month after the ultrasound examination, multi-slice computed tomography (MSCT) examination of the abdomen was performed, describing a normal-sized gallbladder with hyper-dense content. PET/CT imaging of the entire body (ranging from the skull base to the mid-thigh) was performed 90 minutes after tracing an intravenous application of 244 MBq <sup>18</sup>F-fluorodeoxyglucose labeled with fluorine-18 (<sup>18</sup>F-FDG). The PET/CT finding on standard soft tissue windows shows a gallbladder of appropriate size. Hyper-dense content in the gallbladder's dependent part (128 HU) with a fluid level in the gallbladder, without pathological accumulation of radiopharmaceuticals.

**Conclusion:** The present study describes a rare disorder “Milk of Calcium” gallbladder in all three planes in a patient with non-Hodgkin lymphoma, diffuse large B-cell lymphoma.



**P14**

**CALIBRATION OF DOSE CALIBRATORS IN THE LABORATORY FOR RADIOISOTOPES**

Magdalena Radović, Marija Mirković, Drina Janković, Aleksandar Vukadinović, Marko Perić, Đorđe Petrović, Zorana Milanović, Sanja Vranješ-Đurić, Laboratory for radioisotopes, Vinča Institute of Nuclear Sciences, National Institute of the Republic of Serbia, University of Belgrade, Belgrade; E-mail address of the presenting author: magdalena.lazarevic@vin.bg.ac.rs

A dose calibrator is an essential device in nuclear medicine, utilized to measure the activity of radiopharmaceuticals administered to patients both for diagnostic and therapeutic purposes. The estimation of measurement uncertainty performed within the measurements of the activity of radiopharmaceuticals in a dose calibrator is regularly conducted as part of the quality control of radiopharmaceuticals in the Laboratory for Radioisotopes. Identification of the source of uncertainty and application of appropriate correction factors may minimize inaccurate measurements.

Accurate, calibrated or internally tested measuring equipment is used for all measurements, while environmental conditions are regularly monitored. Quality control of dose calibrator should include several tests: precision, accuracy, linearity of activity response, reproducibility, and background. The background should be checked before each measurement. Reproducibility should be checked once a week, while the other tests may be performed at longer intervals (monthly, quarterly or yearly) depending on the condition of the instrument and previously recorded variations. The sources needed to perform the tests should include a sealed reference source (Co-57, Ba-133, Cs-137, and Co-60) certified to  $\pm 5\%$  overall uncertainty or less. Based on these measurement results, mean values and standard deviations were calculated and X-control charts were drawn based on individual radioactivity measurement results of certified reference materials Cs-137 and Co-60 over a period of one year (60 measurements). Based on the results shown on the control chart, it can be concluded that the measured values are within the warning limits, i.e. that the CRC-15 beta calibrator dose may be applied for the scheduled radioactivity measurements.



## P15

**The relationship between thyroid antibodies and vitamin D level in primary hypothyroidism**  
Maja Sulejmanović, Fatima Mujarić- Bousbia, Clinic for Radiology and Nuclear medicine, University Clinical Centre Tuzla, Tuzla; E-mail address of the presenting author: majasulejmanovic@yahoo.com

Prevalence of vitamin D deficiency or insufficiency is over billion worldwide. Autoimmune thyroid diseases (AITD), including Haschimoto (HT) and Graves (GD), are the most common organ-specific autoimmune diseases. Both vitamin D and thyroid hormone bind to the steroid hormone receptors. Few studies were conducted to find any significant association between the levels of vitamin D and hypothyroidism and its pathogenesis but yielded conflicting results. The aim of this study was to evaluate the relation between vitamin D level, thyroid-stimulation hormone (TSH) and thyroid antibodies in primary hypothyroidism. The study is of a retrospective-prospective character, and it included a total of 150 individuals and conducted at the Radiology and Nuclear Medicine Clinic, Department for Thyroid Diseases, University Clinical Centre Tuzla. Participants were divided into the following groups: group I included 50 patients with autoimmune thyroid disease (AITD), group II included 50 patients without autoimmune thyroid disease (non-AITD). Group III included 50 apparently healthy participants representing a control group. Total amount of 150 participants were included in our research, aging 11 to 83, and 89,33% were women. Serum levels of 25(OH) vitamin D recorded a significant difference between the studies group (20.76 ng/ml) in group I vs. 24.37ng/ml in group II vs. 24.57 ng/ml in group III. Regarding anti-TPO level and anti-TG level, there was a significant difference between patients with AITD and patients with non-AITD (1715 IU/ml; 293 IU/ml vs. 25 IU/ml; 16,56 IU/ml) and between patients with AITD and control group (1715 IU/ml; 293 IU/ml vs. 45 IU/ml; 20,92 IU/ml), but no significant difference between patients with non-AITD and control group. Vitamin D deficiency was more frequent in patients with AITD (68%) versus in patients without AITD (38%).

Significantly lower levels of vitamin D were documented in patients with AITD. Vitamin D as a therapeutic tool for AITD.



9th BALKAN  
CONGRESS OF  
**NUCLEAR  
MEDICINE**  
AND SERBIAN  
CONGRESS OF

May 12-14  
**20  
22**  
Fruske terme  
**Vrdnik  
Serbia**

## P16

### **<sup>99m</sup>Tc-labeled phosphonate-coated magnetic nanoparticles**

Marija Mirković, Zorana Milanović, Sanja Vranješ-Đurić, Drina Janković, Aleksandar Vukadinović, Marko Perić, Đorđe Petrović, Dragana Stanković, Magdalena Radović, „VINČA” Institute of Nuclear Sciences - National Institute of the Republic of Serbia, University of Belgrade, Serbia; E-mail address of the presenting author: mmarija@vin.bg.ac.rs

#### Introduction

MNPs coated with two hydrophilic bisphosphonate ligands, methylene diphosphonate (MDP) and 1-hidroksietan diphosphonate (HEDP), were prepared, characterized, and labeled with <sup>99m</sup>Tc. The aim was to investigate if the <sup>99m</sup>Tc-phosphonate-coated MNPs, can be used as theranostic agents for both diagnostic imaging and magnetic hyperthermia application.

#### Material and Methods

Fe<sub>3</sub>O<sub>4</sub> MNPs are synthesized by the co-precipitation method. MDP and HEDP have been used as coatings due to their strong chelating ability with metal ions, especially iron, and also due to their proven biocompatibility. The phosphonate-coated MNPs were labeled with <sup>99m</sup>Tc. Additionally, <sup>99m</sup>Tc-MNPs were used for in vitro stability studies in saline and human serum and in vivo biodistribution studies in healthy Wistar rats.

#### Results

The SPA values obtained for synthesized MNPs (55–183 Wg-1) indicated their possible application in hyperthermia treatment. Both types of coated MNPs were <sup>99m</sup>Tc-labeled in a reproducible high yield (>95%) and exhibit high in vitro stability in saline and human serum with only 10 and 15% of <sup>99m</sup>Tc detaching from the iron oxide after 24 h, respectively. As expected, the results of biodistribution showed the most liver and spleen uptake almost immediately after i.v. administration due to their colloidal nature.

#### Conclusion

The obtained results of specific power absorption, high radiolabeling yield, and in vivo stability of <sup>99m</sup>Tc-bisphosphonate-coated MNPs, demonstrate their high potential to be used as theranostic agents for therapeutic magnetic hyperthermia and diagnostic imaging applications.



**P17**

**Diagnostic role of positron emission tomography/computed tomography with fluorodeoxyglucose in recurrent cervical cancer patients**

Stojiljković Milica<sup>1,2</sup>, Odalović Strahinja<sup>1,2</sup>, Popović Marina<sup>3</sup>, Petrović Jelena<sup>1,2</sup>, Pantović Jelena<sup>1</sup>, Ranković Nevena<sup>1</sup>, Veljković Miloš<sup>1</sup>, Brajković Leposava<sup>1</sup>, Šobić Šaranović Dragana<sup>1,2</sup>, Artiko Vera<sup>1,2</sup>

<sup>1</sup>Centre for Nuclear Medicine with PET, University Clinical Centre of Serbia, Belgrade, Serbia, <sup>2</sup>Faculty of Medicine, University of Belgrade, Serbia <sup>3</sup>Institute for Oncology and Radiology of Serbia, Belgrade, Serbia, E-mail address of the presenting author: milica\_stoji@yahoo.com

**Background:** The aim of this study was to evaluate diagnostic role of FDG PET/CT in patients with suspected recurrent cervical cancer and compare it to MRI performances.

**Methodology:** We evaluated FDG PET/CT findings of 104 patients who were referred to National PET centre, University Clinical Centre of Serbia, from 2014 to 2019. All patients previously received treatment for cervical cancer in form of chemoradiotherapy, surgery or combination of two, and underwent MRI for follow-up or clinical suspicion of recurrence prior to FDG PET/CT.

**Results:** FDG PET/CT made the correct diagnosis in 84/104 (81%) patients (56 true positive and 28 true negative) with 20 false positive findings on PET. On MRI, there were 47 TP, 15 TN, 33 FP and 9 FN findings. Overall sensitivity, specificity and diagnostic accuracy for recurrent cervical cancer were 100%, 58% and 81% for PET/CT and 84%, 31% and 60% for MRI, respectively. Correlation between PET/CT and MRI was 70/104 (67%). In 33 out of 47 TP patients on MRI, FDG PET/CT detected additional lesion not seen on morphological imaging.

**Conclusion:** FDG PET/CT may have an important role in the management of recurrent cervical cancer patients, showing higher accuracy compared to MRI. Another contribution of hybrid imaging could be the ability to detect a greater number of active lesions compared to MRI, potentially influencing further treatment.



## P18

### **Diagnostic role of FDG PET/CT in recurrent uterine corpus cancer**

Stojiljković Milica<sup>1,2</sup>, Odalović Strahinja<sup>1,2</sup>, Popović Marina<sup>3</sup>, Petrović Jelena<sup>1,2</sup>, Pantović Jelena<sup>1</sup>, Ranković Nevena<sup>1</sup>, Veljković Miloš<sup>1</sup>, Brajković Leposava<sup>1</sup>, Šobić Šaranović Dragana<sup>1,2</sup>, Artiko Vera<sup>1,2</sup>

<sup>1</sup>Centre for Nuclear Medicine with PET, University Clinical Centre of Serbia, Belgrade, Serbia, <sup>2</sup>Faculty of Medicine, University of Belgrade, Serbia <sup>3</sup>Institute for Oncology and Radiology of Serbia, Belgrade, Serbia, E-mail address of the presenting author: milica\_stoji@yahoo.com

**Background:** The aim of this study was to evaluate diagnostic role of FDG PET/CT in patients with suspected recurrent malignancy of uterine corpus and compare it to conventional imaging modalities (CT/MRI).

**Methodology:** We evaluated FDG PET/CT findings of 37 patients who were referred to National PET centre, University Clinical Centre of Serbia, from 2014 to 2019. All patients previously received treatment for uterine cancer in form of chemoradiotherapy, surgery or combination of two, and underwent CT or MRI for follow-up or clinical suspicion of recurrence prior to FDG PET/CT.

**Results:** FDG PET/CT made the correct diagnosis in 33/37 (89%) patients (26 true positive and 7 true negative) with 3 false positive and 1 false negative finding on PET. On CT/MRI, there were 25 TP, 4 TN, 6 FP and 2 FN findings. Overall sensitivity, specificity and diagnostic accuracy for recurrent uterine cancer were 96%, 70% and 89% for FDG PET/CT and 93%, 40% and 78% for CT/MRI, respectively. Correlation between PET/CT and CT/MRI was 29/37 (78%). In 13 out of 25 TP patients on CT/MRI, FDG PET/CT detected additional lesion not seen on morphological imaging.

**Conclusion:** FDG PET/CT can have an important role in management of recurrent cancer of uterine corpus. Specific contributions of hybrid imaging may be its higher specificity and the ability to detect a greater number of active lesions compared to conventional imaging modalities.



## **P19**

### **False positive PETCT finding in breast cancer patient**

Prvulovic Bunovic N<sup>1,2</sup>, Trifunović J<sup>1,3</sup>, Mihailovic J<sup>1,4</sup>, Faculty of Medicine, University of Novi Sad, Novi Sad, Serbia<sup>1</sup> Diagnostic Imaging Center, Oncology Institute of Vojvodina, Sremska Kamenica, Serbia<sup>2</sup>Clinic for Internal Oncology, Oncology Institute of Vojvodina, Sremska Kamenica, Serbia<sup>3</sup> Clinic for Nuclear Medicine, Oncology Institute of Vojvodina, Sremska Kamenica, Serbia<sup>4</sup>, E-mail address of the presenting author: prvulovicn@gmail.com

**Introduction:** Breast cancer (BC) is the leading cancer in women worldwide . If treatment does not occur, breast cancer will metastasize. Very often the first area that cancer usually spreads to is the lymph nodes in the underarm area, to the axilla. Once cancer enters the lymphatic system, it can and usually does spread to other areas of the body. Mammography is the first imaging modality in breast cancer detection, followed with ultrasound guided core biopsy. CT and/or MR imaging is suggested according to necessarily staging, PETCT is indicated in staging of BC starting from the stage IIIA.

**Case presentation:** We presented case of a 41y/o lady with 5cm palpable mass in RUQ of the left breast, after core biopsy proved as ductal invasive cancer gr II, Her2+ and negative lymph node in ipsilateral axilla. Neoadjuvant hemotherapy was indicated: 4 courses of AC followed by 4 series of docetaxel + trastuzumab. Cancer showed complete radiological regression after hemotherapy treatment and subcutaneous mastectomy was performed. In restaging plan PETCT was indicated. PETCT showed only bilateral inguinal node enlargement with highest SUVmax of 7.20. Ultrasound showed usually appeared but enlarged lymph nodes in the both inguinal regions, with average shortest dimension of nodes up to 2.5cm. Core biopsy confirmed normal lymph node tissue. Ultrasound presentation of this nodes was stable in to 2 years followed up.

**Conclusion:** This case presented the high specificity of ultrasound in lymph node characterisation and differentiation. Value of 7,20 SUVmax suggested malignant nature of superficial inguinal lymph nodes. We do not have explanation of false positive result of high glucose metabolism of inguinal lymph node in this case, because histology did not shows inflammatory or infiltrative process within it.



## P20

### DIAGNOSTIC VALUE OF THE PET/CT IN DETECTION OF FEVER OF UNKNOWN ORIGIN, INFECTIONS AND INFLAMMATION

Nevena Ranković<sup>1</sup>, Dragana Šobić Šaranović<sup>1,2</sup>, Vera Artiko<sup>1,2</sup>, Jelena Petrović<sup>1,2</sup>, Milica Stojiljković<sup>1,2</sup>, Nebojša Petrović<sup>1</sup>. <sup>1</sup>Center for Nuclear Medicine with PET, University Clinical Centre of Serbia, Belgrade, Serbia, <sup>2</sup>Faculty of Medicine, University of Belgrade, Belgrade

**INTRODUCTION:** Fever of Unknown Origin (FUO) and Inflammation of Unknown Origin (IUO) are rare but diagnostically very challenging clinical problems. Because of an abundance of differential diagnosis, a widely accepted diagnostic golden standard has not yet been established.

Beside thorough medical anamnesis, physical examination and laboratory tests, diagnostic methods are also of great importance.

In the last several years, <sup>18</sup>F-FDG-PET / CT has been a reliable diagnostic method for finding the cause for the FUO and IUO because it can detect inflammatory and malignant processes in high spatial resolution. PET/CT is a nuclear medical diagnostic method that can detect increased glucose metabolism in cells (tumor cells and inflammations) as well as morphological changes.

**AIM:** Aim of this Study was a evaluation of diagnostic value of the PET/CT in detecting the causes of infections and inflammation as well as unclear febrile conditions.

**MATERIAL and METHODS** The Study has been conducted at the National PET Center in the Center for Nuclear Medicine, of the University Clinical Center of Serbia. The study included all patients with a referral diagnosis of unclear febrile condition that have undergone PET / CT examination between mid-November 2009 and the end of April 2021.

This cohort retrospective study included 111 patients (77 men, 34 women) with persistent symptoms of inflammatory syndrome.

Criteria for inclusion in the study and indications for the PET/CT examination were patients sent with a diagnosis of unclear febrile condition, inflammatory syndrome without them being diagnosed with malignancy, that are not on chemotherapy, with clinically clear signs of inflammatory syndrome and biochemical markers indicating an inflammatory process (CRP, SE, leukocyte formula).

Exclusion criteria was the presence of malignancy and blood glucose levels above 11 mmol/l. PET/CT examination was performed on a hybrid PET/CT scanner. The degree of metabolic activity (FDG uptake) was assessed visually and quantitatively using the maximum standardized uptake value (SUV<sub>max</sub>). The findings were considered positive in the case of increased glucose metabolism anywhere in the patient's body that is not physiological and which is greater in relation to the accumulation of radiopharmaceuticals in the liver parenchyma and in the large blood vessels of the mediastinum.

**RESULTS:** In 89 patients, zones of increased FDG uptake were found (average value of SUV<sub>max</sub> 7 + -). Vasculitis (31.46%) was detected in 28 patients, regional lymphadenopathy in 23 (25.84%), arthritis in 13 (14.61%), tumor changes in 13 (lung CA, prostate CA... 14.61%) and in 12 patients inflammation in the gastrointestinal tract (13.48%). In 21 patients no zones of increased glucose metabolism were detected — FDG uptake was within physiological limits, 1 patient was false positive due to right axillary biopsy performed five days before PET/CT imaging. The sensitivity of this method is 98.0%, specificity 95.4%, positive predictive value 91.3%, negative predictive value 91.3% and accuracy 95.8%.

**KEY WORDS:** F-18-FDG PET / CT, SUV<sub>max</sub>, infections, inflammation, fever of unknown origin





## P21

### **Synchronous breast and thyroid cancers in young women-unusually case presentation**

Roganović J<sup>4</sup>, Prvulovic Bunovic N<sup>1,2</sup>, Salma S<sup>3</sup>, Mihailovic J<sup>1,4</sup>, Faculty of Medicine, University of Novi Sad, Novi Sad, Serbia<sup>1</sup>, Diagnostic Imaging Center, Oncology Institute of Vojvodina, Sremska Kamenica, Serbia<sup>2</sup>, Clinic for Internal Oncology, Oncology Institute of Vojvodina, Sremska Kamenica, Serbia<sup>3</sup>, Clinic for Nuclear Medicine, Oncology Institute of Vojvodina, Sremska Kamenica, Serbia<sup>4</sup>

**Introduction:** Thyroid and breast cancers, that are not so rare conjoined, are usually detected during the follow-up of both malignancies, but synchronous presentation of these tumors is rare.

**Case presentation:** This is a case of a 38year-old woman with a 2cm mass of the left breast. Ultrasonography showed a round, well defined, inhomogeneous, dominantly hypoechoic mass in UUQ, categorised as suspicious without pathologically enlarged lymph nodes in axilla. Sonography of the neck, supra and infraclavicular regions was also performed, according to locoregional staging. On the right side of the neck, in groups III and IV, several small, 0.5-0.8cm, round and hypoechoic lymph nodes were noted and categorised as suspicious. In the right thyroid lobe ill-defined, hypoechoic nodes up to 1cm were detected. Mammography reported dense breast without obvious breast mass and was followed with sonography-guided core biopsy. Afterwards, the fine needle aspiration of thyroid node and largest neck lymph node was performed. Histology confirmed medullary breast cancer and papillary thyroid gland cancer with lymph node metastases. Since two different malignancies synchronously detected, PETCT was planned as the fastest way to reach correct staging and therapy planning. PETCT showed mass in left breast without any FDG uptake in the neck or other site in the body.

**Conclusion:** When there is synchronous presentation of both malignancies and lymphogenous spread, sonography showed highest diagnostic accuracy. Due to small dimensions of thyroid mass and neck lymph nodes PETCT revealed no pathologic finding in the neck and other predilection region for secondary dissemination. Dense breast structure (due to the patient age) generated false negative mammography finding. Sonography remains the method with highest diagnostic accuracy for breast mass detection and characterisation in young patient with dense breast, and also for thyroid node detection and superficial lymph node evaluation.

**Key words:** synchronous malignance, breast cancer, thyroid cancer, sonography, PETCT



**P22**

**<sup>99m</sup>Tc-mibi myocardial perfusion scintigraphy in the prediction of cardiac events in patients with diabetes mellitus type 2,**

Siniša Stanković<sup>1,2</sup>, Dragana Šobić-Šaranović<sup>3,4</sup>, Valentina Soldat-Stanković<sup>1,5</sup>, Vera Artiko<sup>3,4</sup>, Zvezdana Rajkovača<sup>1,2</sup>, Gostimir Mikač<sup>6</sup>, Nataša Egeljić-Mihailović<sup>1,2</sup>, Marina Majkić<sup>1,2</sup>, 1. University of Banja Luka, Faculty of Medicine, Banja Luka, 2. University Clinical Center of the Republic of Srpska, Department of Nuclear Medicine and Thyroid Gland Diseases, Banja Luka, 3. University of Belgrade, Faculty of Medicine, Belgrade, 4. University Clinical Center of Serbia, Center for Nuclear Medicine with PET, Belgrade, 5. University Clinical Center of the Republic of Srpska, Clinic of Internal Medicine, Banja Luka, 6. Specialist Center for Thyroid Gland Diseases, Banja Luka; E-mail address of the presenting author: sinisa.stankovic@med.unibl.org

**Introduction/Objective:** Myocardial perfusion imaging (MPI) is clinically useful for the evaluation of coronary artery disease (CAD) in patients with diabetes mellitus (DM). However, the prevalence of ischemia and its ability to predict future cardiac events is less clear. The aim was to determine the incidence of cardiac events in diabetic patients and relationship between them and MPI findings.

**Methods:** Two cohorts of patients, 98 diabetics and 100 non-diabetics, with medium- to high-risk of CAD without previous coronary revascularization were studied prospectively. All of them were outpatients underwent <sup>99m</sup>Tc-mibi MPI with dipyridamole. The data about cardiac events were collected during follow-up period of two years.

**Results:** Cardiac events occurred in 17.3% diabetics and in 8.0% non-diabetics (p=0.048). Diabetics had shorter estimated event-free time 24.7 months (95% CI 23.2-26.2) versus non-diabetics 28.5 months (95% CI 27.4-29.5) (p=0.046). The independent predictors of cardiac events were male sex (p=0.010), previous myocardial infarction (p<0.001), presence of the symptoms of angina (p=0.014) and all variables derived from MPI findings. After adjustment for variables derived from MPI findings, the significant predictors in diabetics were size of stress perfusion defect (p=0.022), summed stress score (p=0.011) and summed difference score (p=0.044).

**Conclusion:** In diabetic patients, the cumulative rate of cardiac events was higher and the event-free survival was worse. MPI could help in prediction of cardiac events in diabetics and the most important predictors were size of stress perfusion defect, summed stress score and summed difference score.

**Key words:** Myocardial perfusion imaging, diabetes mellitus, coronary artery disease, cardiac events



## P23

### **Metastatic lung cancer and it's PET/CT findings after therapy – case report**

Sonja Bobić Zrač, Ivana Pavković, Institute of Nuclear Medicine and Thyroid Gland Disease, University Clinical Centre of the Republic of Srpska, Banja Luka; E-mail address of the presenting author: sonjeta83@yahoo.com

**Aim:** The aim of this study is to present a case of a patient with metastatic lung cancer and it's findings on the control PET/CT with metabolically active axillary lymphadenopathy as a post-treatment result and with no other secondary deposits after receiving chemotherapy and non-conventional therapy.

**Case report:** I present the case of a 39-year-old patient which started with intense headache, which were not relieved by analgetics. As part of the treatment, NMR of the head was performed and one metastatic change in the cerebellar was found that was origin from the lung cancer. That was confirmed postoperatively by a PH finding (lung adenocarcinoma). At the first PET / CT finding, a subpleural node diameter of 11x14mm (APxLL) was seen in S1 of the right lung, with increased accumulation of the  $^{18}\text{F}$ -FDG (SUVmax up to 6,8). The rest of the PET/CT finding was within physiological distribution of the  $^{18}\text{F}$ -FDG. He received II cycles of chemotherapy (CDDP / paclitaxel). The patient then received the Cuban vaccine (CIMAvax-EGF) on his own initiative. The control PET/CT examination (march/2022) showed hypodense zones with increased accumulation of the  $^{18}\text{F}$ -FDG (SUVmax up to 4,6) in both deltoid muscles, as well as in both large gluteal muscles, as a result of receiving Cuban therapy. Beside that, in the right axillary two lymphatic nodes were found with a diameter of 27x13 mm and 18x7 mm and with increased accumulation of the  $^{18}\text{F}$ -FDG (SUVmax up to 4), as well as two left axillary lymphatic nodes with a diameter of 27x14 mm and 21x10 mm with moderate accumulation of  $^{18}\text{F}$ -FDG (SUVmax up to 2,5) - post-therapeutic. The remaining PET/CT finding was within physiological distribution of the  $^{18}\text{F}$ -FDG.

**Conclusion:** Our patient is presented as an interesting case worth showing, because together chemotherapy with CIMAvax-EGF vaccine on control PET/CT findings showed metabolically active axillary lymphadenopathy and post-treatment altered muscles of the deltoid and gluteal region, without any other secondary deposits. Possible post-therapeutic manifestations of the disease should be kept in mind when reading PET/CT findings.



**P24**

**Radium-223 dichloride therapy in prostate cancer with osseous metastases – clinical case report**

Teodor Sofiyanski<sup>1</sup>, Milena Dimcheva<sup>1</sup>, Sonya Sergieva<sup>1</sup>, Rossitza Krasteva<sup>2</sup>, Zahary Zahariev<sup>3</sup>,

<sup>1</sup>Department of Nuclear Medicine, Sofia Cancer Center, Sofia <sup>2</sup>Department of Medical Oncology, Uni Hospital, Panagyurishte, <sup>3</sup>Department of Radiotherapy, Uni Hospital, Panagyurishte; E-mail address of the presenting author: teodor.sofianski@gmail.com

Background: Prostate cancer is the most frequently diagnosed cancer among men in almost all European countries and North America. Bones are the most commonly affected in metastatic castration-resistant prostate cancer, which is associated with pain and pathological fractures.

Case presentation: We report the results of an athletic 47-year old man, initially diagnosed in 2014 with prostate cancer, presented with increasing bone pain, which has been treated with surgery, radiation and hormonal therapy but still developed symptomatic osseous metastases. He received Radium-223 dichloride, a therapeutic radiopharmaceutical for bone metastases castration-resistant prostate cancer. He tolerated the therapy well with no significant adverse effects. He had an excellent response with significant pain relief, preventing the use of analgesics. However his tumor markers gradually increased. A <sup>68</sup>Ga-PSMA PET-CT was performed in order to exclude visceral involvement. The osseous metastases were assessed with a <sup>99m</sup>Tc-MDP whole body bone scan with subsequent targeted SPECT/CT before the initial Radium-223 dichloride therapy and after the third application. Our patient underwent a <sup>68</sup>Ga-PSMA PET-CT to assess the impact of Ra-223 after the fourth application.

Conclusion: Nuclear medicine imaging plays a pivotal role in the division of patients appropriate for radium-223 therapy, for the detection and distribution of bone metastases, follow-up and the provisional assessment of response to Radium-223.



**P25**

**Analysis of Differentiated Thyroid Carcinoma Patients Treated in a Single Center: Is there a Relation Between Hashimoto Thyroiditis and Malignancy?**

Cimbaljević V<sup>1</sup>, Roganović J<sup>1</sup>, Stojanović D<sup>1</sup>, Mihailović J<sup>1,2</sup>. Center of nuclear medicine, Oncology institute of Vojvodina Sremska Kamenica, Sremska Kamenica, Serbia<sup>1</sup>, Faculty of Medicine, University of Novi Sad, Novi Sad; E-mail address of the presenting author: cimbaljevicvanja@gmail.com

**Aim:** Nodular goiter of the thyroid gland is frequent disease, however incidence of malignancy in thyroid nodes is small. Thyroid node diagnostics include ultrasonography and fine needle aspiration (FNA) with cytological report.

**Materijal and methods:** This retrospective study analyzed 4.458 patients with thyroid nodes that were operated in our institution between 2007 and 2019. All patients with suspicious malignant cytology (Bethesda IV, V and VI) as well as patients with large thyroid nodes underwent surgery. In 901/4458 (20.21%) patients, diagnosis of Hashimoto thyroiditis was histologically confirmed. Patients' files (including clinical examination, lab analyses) were compared with histological reports. Statistical analysis of predicting factor was done with Kaplan Meyer method and log rank test.

**Results:** Among 901 patients with Hashimoto disease, there were 849 (94.2%), females and 52 (5.77%) males. Malignancy was confirmed in 197/901 (21.86%) patients: 178 (90.36%) females and 19 (9.64%) males. Histologically, there were 164 (67.92%) patients with papillary carcinoma, 10 (1.10%) patients with follicular carcinoma, 15 (1.66%) patients with poorly differentiated carcinoma, 8 (0.88%) patients with metastatic cancers including 2 (0.22%) patients with Malt lymphoma, 5 (0.55%) patients with NHL and 1 (0.11%) patient with breast cancer.

**Conclusions:** Hashimoto disease is frequent in thyroid nodes. It is predicting factor for thyroid malignancy. Therefore, thyroid diagnostics algorithm should include FNA and cytological analysis.



## P26

### **Radiotherapy planning on Varian Edge knife with PET/CT imaging: initial management in the Republic of Serbia**

Vojislav Antic, Center for Nuclear medicine with PET, University Clinical Center of Serbia;

E-mail address of the presenting author: antic.vojislav@gmail.com

Radiotherapy planning uses data from CT and MRI modalities, but in many cases, improvement can be achieved with complementary, functional PET information. Compared with MRI, PET can precisely define the metabolically active part of the tumor but PET may maximize a target volume that is underestimated on MRI images, or in the case when MRI yields no useful information, PET can be used for target definition.

Integration of PET in treatment planning requires standardization of geometrical accuracy, image acquisition, image fusion, dose calculation, and comprehensive quality control. PET images must be acquired in the therapy treatment position, which takes into consideration a flat patient bed, vacuum mattresses, and fixation devices such as masks. When changes in patient anatomy are present, deformable image registration may be required in order to match PET image voxels to the basic radiotherapy planning CT images.

In order to accurately deliver the prescribed dose of radiation, the Varian Edge knife beam treats each part of the tumor from different angles. Tumor position is tracked in real time while patient movement is calculated and respiratory motion is tracked, with accuracy checking. PET image information can be used in order to shape the radiation dose according to metabolic activity and to adapt the treatment plan during irradiation, with beam sculpting and dose escalation to relatively small boost volumes. This is of importance in the head and neck region, where swallowing, for example, can significantly alter the tumor position and affect image resolution in anatomical regions containing many organs at risk.

Considering installation of the Varian Edge knife, the opportunity for cooperation with the Nuclear medicine and PET Center within same institution - University Clinical Center of Serbia has been analyzed in detail and has become topical through the hospital reconstruction and one new GE MI PET-CT mainly dedicated for treatment planning. In addition to equipment related to geometric positioning, a PET/CT simulation laser system (with QC phantom) was included. Necessary hardware and software on the acquisition workstation was defined. Finally, to eliminate breathing artifacts, RGSC (respiratory gating for scanners) was provided with wall/ceiling mounts. At the same time, staff in both centers are preparing for collaboration. The aim is to achieve the first plans on Varian Edge, with PET functional information, as soon as possible.



**P27**

**PERFUSION LUNG SCINTIGRAPHY IN POST COVID 19 PATIENTS WITH LIGHT AND MODERATE CLINICAL PICTURE. ACUTE LUNG MICROTHROMBOEMBOLIZATION OR SEQUELAE ?**

Milos Stevic<sup>1,2</sup>, Marina Vljakovic<sup>1,2</sup>, Nina Topic<sup>2</sup>, Filip Velickovic<sup>2</sup>, Tamara Andjelkovic<sup>2</sup>

<sup>1</sup>Faculty of Medicine, University of Nis,

<sup>2</sup>Center for Nuclear Medicine, University Clinical Center Nis

E-mail address of the presenting author: mlsstvc@gmail.com

**Background**

Elevated D-dimer values may indicate pulmonary microthrombosis (PMT) in reconvalescence post COVID 19 patients with breathing difficulties.

**Methodology**

In the period from 01.05.2021. to 02.01.2022., 52 patients with dyspnoea, elevated D-dimer values and negative MSCT after Covid 19 were referred for perfusion scintigraphy of the lungs (PLS). Thirty four men and 18 women. The mean age was  $57 \pm 11$  years. PLS was done according to a standard protocol. In patients with PMT, control PLS and D-dimer analysis were performed after four weeks. Patients with PMT undergone anticoagulant therapy (AT) with low molecular weight heparin in the period from the first to the control PLS.

**Results**

In 42 (80.7%) patients PMT was found on PLS. All patients with PMT had elevated D-dimer values of  $1030 \pm 530$   $\mu\text{g/mL}$ . Control PLS showed recovery of perfusion in 12 (28,6%) patients. Thirty (71.4%) patients had unchanged findings. A decrease of D-dimer values of  $350 \pm 160$   $\mu\text{g/mL}$  was observed in all patients.

**Discussion**

Elevated D-dimer values and clinical signs in reconvalescence patients after Covid 19 may indicate PMT that can be detected with PLS. Covid 19 is accompanied by coagulation disorder, often causing PMT, with negative MSCT. Subsegmental perfusion defects indicate the existence of PMT with normal MSCT. We consider persistent PMT on control PLS and with decreasing D-dimer values, as sequelae.

**Conclusion**

PLS is a valuable method for detecting PMT. Symptomatology, elevated D-dimer and negative MSCT in patients after Covid-19 indicate PMT. Persistence of PMT on PLS with a decrease in D-dimer values, after AT considers as PMT sequelae caused by Covid-19 disease.

**Keywords:** Covid - 19; Perfusion scintigraphy of the lungs; Microthrombosis



**P28**

**PET/CT in the management of primary angiosarcoma of the heart**

Todorova-Stefanovski D.<sup>1</sup>, Spirov G.<sup>1</sup>, Tasevski S.<sup>1</sup>, Beshliev S.<sup>1</sup>, Angeleska M.<sup>1</sup>, Ugrinska A.<sup>1</sup>,

<sup>1</sup>University Institute for Positron Emission Tomography, Skopje, Republic of N.Macedonia

**INTRODUCTION** Primary cardiac tumors are rare and mostly benign, with only 30% of them being malignant. The most common pathological type is angiosarcoma, which mainly affects the right atrium and has a fatal prognosis with survival of 3-11 months. It is very important to make a difference pathohistologically with epithelioid hemangioendothelioma, which has low to medium potential to metastasize and better prognosis from the angiosarcoma.

**CASE REPORT** 35 years old, 9 months pregnant woman was diagnosed with a tumor in the right atrium. The tumor was surgically removed and the baby delivered in one instance. The first histopathology reported epithelioid hemangioendothelioma. The patient was referred for a PET/CT scan. The results showed increased FDG uptake in the right atrium (SUV<sub>max</sub>=7.3), consistent with residual tumor or postoperative inflammation, and multiple bone metastases (SUV<sub>max</sub>=5.4). After the PET scan histopathology was reviewed once again and the second report was in concordance with angiosarcoma of the heart. After 4 cycles of chemotherapy, PET/CT was performed for restaging and treatment response assessment and it showed progression of the disease with local recurrence (SUV<sub>max</sub>=5.8), lymph nodes, bilateral adrenal (SUV<sub>max</sub>=6.1) and hepatic metastases (SUV<sub>max</sub>=4.6). Despite haemotherapy the disease rapidly progressed and patient died 11 months after the diagnosis.

**CONCLUSION** The imaging diagnostic workup in cardiac tumors is not well established yet. The case report that we've presented illustrates the role of FDG /PET in the assessment of malignant potential of the primary tumor, and in staging and restaging of the disease.





## **P29**

### **Use of lymphoscintigraphy in the diagnosis of lymphedema, case report**

Dragan Burić<sup>1,2</sup>, Branislava Ilinčić<sup>1,2</sup>, Radmila Žeravica<sup>1,2</sup>, Ana Jakovljević<sup>1,2</sup>, Veljko Crnobrnja<sup>1,2</sup>, Marija Papuga Vukmirović<sup>2</sup>; Jelena Samac<sup>2</sup>. 1University of Novi Sad, Faculty of Medicine Novi Sad, Department of pathophysiology and laboratory medicine, 2University Clinical Center of Vojvodina, Center for laboratory medicine, Novi Sad

Lymphedema is a chronic disease of the lymphatic system that often remains undiagnosed or poorly diagnosed and can lead to severe limb swelling and reduced quality of life. Lymphedema can be primary and secondary. Primary lymphedema may be caused by agenesis, hypoplasia, hyperplasia, or lymphatic obstruction. Secondary lymphedema is an acquired condition that occurs as a result of injury or obstruction of lymph vessels that were previously normal. The most common cause of secondary lymphedema in the world is lymphatic filariasis. In the presented case, lymphoscintigraphy performed using the radiotracer <sup>99m</sup>Tc-Antimony sulfide (<sup>99m</sup>Tc-SbSC) diagnosed functional obstruction of the lymphatic pathways in the lower extremities. A 35 year old female patient was referred for lymphoscintigraphy due to swelling of the right lower leg. The vascular surgeon and color Doppler examination of the lower extremities ruled out the vascular etiology of the swelling, then laboratory findings and ultrasound examination of the abdomen ruled out liver and kidney pathology and gynecological examination ruled out the possibility of gynecological pathology and pregnancy. The patient is a long-term athlete, and the internist's examination ruled out the possibility of heart failure and pulmonary hypertension. Lymphoscintigraphic findings showed a reduced number of lymph vessels in the right lower leg and slower kinetics of radiotracer in the right leg. Lymphoscintigraphy is a safe and reliable method in the diagnostic algorithm of patients with lymphedema, it is also valuable in order to monitor the condition after the applied therapeutic modalities.

Key words: radiotracer <sup>99m</sup>Tc-Antimony sulfide, leg swelling, lymphatic system, scintigraphy



#### **PT1**

#### **Peritoneal scintigraphy in assessment of chronical complications of chronical ambulence peritoneal dialysis (CAPD) - case report.**

Darko Maričić, Milica Ilić, Branislava Đorđević, Dora Sabo, Milica Šatar. Clinical Center of Vojvodina, Department of Nuclear Medicine; E-mail address of the presenting author: darinho.darko@gmail.com

Introduction: Encapsulated peritoneal sclerosis (EPS) is rare complication of long lasting peritoneal dialysis in patients with end-stage renal disease, resulting in thickening and fibrosis of the peritoneum, causing increased intraabdominal pressure, hydrothorax, hernia, etc. Peritoneal scintigraphy is non common in daily nuclear medicine practice, but useful non-invasive method in the evaluation of chronic peritoneal dialysis patients who develop complication of long lasting peritoneal dialysis. Our case is 61 years old female patient, suffering from CKD, with placed peritoneal catheter and started continuous ambulatory peritoneal dialysis (CAPD) program in 2016. Scintigraphy was performed by using activity of 2 mCi of <sup>99m</sup>Tc-Anthimony-Sulphide colloid placed in two liters of 2.5% dextrose peritoneal dialysis solution. Multi-view planar imaging was performed with a dual-head gamma camera (LEHR collimator, matrix size 512x512, energy window 140 keV, photopeak with a 20% window). The first part of study included dynamic acquisition (1frame/min) of upper abdomen and pelvis immediately after instillation of dialysis solution for the first 20 minutes. Delay planar and SPECT images of abdomen and lung were also obtained. The second part was performed after effusion of dialysis solution and encompassed static acquisition in antero-posterior projection and as well as SPECT study of abdomen. Images showed existence of small area of remaining activity in the region of peritoneal space after effusion of dialysis solution which can be in favour of some pathological process. Conclusion: Peritoneal scintigraphy is a cheap, safe, and non-invasive diagnostic tool in the management of complications of CAPD.



## PT2

### Terapija hipertireoze pomoću I-131

I.Mihailović, J. Aćimović, A. Afgan, Centar za nuklearnu medicinu sa PET, Univerzitetski klinički centar Srbije, E-mail address of the presenting author: ivanapaunovic@live.com

UVOD: Radiojodna terapija se najčešće koristi za terapiju difuzne toksične strume-Grejevsove bolesti(GB), toksičnog adenoma, Plamerove bolesti, tireotoksične krize, za smanjenje volumena netoksične polinodozne strume(ređe), terapiju subkliničke hipertireoze. Radiojod svojim  $\beta$ -česticama dovodi do ireverzibilnog oštećenja DNK, čime počinje destrukcija tkiva štitaste žlezde i u krajnjem ishodu dovodi do smanjenja funkcije i/ili veličine žlezde.

CILJ: Procena efikasnosti i bezbednosti primene radiojodne terapije

MATERIJAL I METODE: U Centru za nuklearnu medicinu-KCS, u periodu 2006.-2013. godine, evaluirano je 1113 pacijenata. Nakon konsultacije sa endokrinologom i endokrinim hirurgom odlučivalo se o primeni terapijske doze u cilju lečenja hipertireoze. Oralna aplikacija se radi naste, uz malo vode. Na prvi kontrolni pregled pacijent se poziva posle 3 meseca od aplikacije radiojodida

REZULTATI: Analizirani su rezultati pacijenata lečenih 2006.-2013.godine, koji su primili individualnu dozu. Od 1113, najveći broj su činile žene sa GB bolešću (504), i 97 muškaraca. Od toksičnog adenoma lečeno je 271 osoba (223 žene, 48 muškarca); polinodozne strume 231 (199 žena, 32 muškarca), 10 pacijenata zbog subkliničke hipertireoze. Godinu dana nakon aplikacije terapijske doze 131I 468 pacijenata bilo eutireoidno (406 žena, 62 muškarca). Hipotireozu ih je imalo 341 (278 žena, 63 muškarca). Samo jednu dozu u toku lečenja primilo je 809 pacijenata (610 žena, 199 muškarca), hipertireoidnih je ostalo 304 pacijenta koji su lečeni sa dve/vise doza (241 žena, 63 muškarca).

ZAKLJUČAK: Terapija I-131 još jednom potvrđuje efikasnost, bezbednost i jednostavnost primene u lečenju benignih bolesti štitaste žlezde



9th BALKAN  
CONGRESS OF  
**NUCLEAR  
MEDICINE**  
AND SERBIAN  
CONGRESS OF

May 12-14  
**20  
22**  
Fruske terme  
**Vrdnik  
Serbia**

### PT3

#### **FDG PET i SPECT u prehirurškoj evaluaciji fokalne farmakorezistentne epilepsije**

M.Marković, J. Danicic, J. Zivojinovic, B. Radulović, Centar za nuklearnu medicinu sa PET, Univerzitetski klinički centar Srbije; E-mail address of the presenting author: marijammarkovic@hotmail.com

**UVOD:** Multimodalne imidzinig tehnike daju informaciju o odnosu epileptogene lezije (morfoloska MR), iritativne zone (interiktalni EEG), zone iktalnog pocetka (iktalni EEG, SPECT, FDG-PET), zone funkcionalnog deficita (interiktalni FDG-PET), elokventnog korteksa (funkcionalna MR) i predstavljaju standard za neinvazivnu fazu prehirurške evaluacije pacijenata sa farmakorezistentnom fokalnom epilepsijom..

**CILJ:** CILJ Ukazati na značaj FDG-PET i SPECT imidžinga u prehirurškoj lateralizaciji i lokalizaciji epileptičnog fokusa.

**MATERIJAL I METODE:** Kod 83 pacijenta (5-65g) sa fokalnom temporalnom i ekstratemporalnom farmakorezistentnom epilepsijom uradjen je FDG-PET, a kod 8 pacijenata iktalni i interiktalni HMPAO-SPECT. Nalazi su vizuelno analizirani i poredjeni sa epileptogenom zonom detektovanom video EEG monitoringom i nalazom MR.

**REZULTATI:** Interiktalni FDG-PET je pokazao hipometaboličnu zonu: temporalno unilateralno (44 pacijenta), bilateralno (5), frontalno (14), parijetalno (4), frontoparijetalno medijalno (1), multifokalno (7 pacijenata). Kod 4 pacijenta dobijen je iktalni PET (2 nekonvulzivni status epilepticus, 1 eplepsia partialis continua, 1 kompleksni parcijalni napadi), epileptogena zona je prikazana kao hipermetabolični region. Epileptogeni fokus je detektovan kod 69 pacijenata (84%) pomocu FDG-PET. SPECT je pokazao iktalno hiperperfuziju a interiktalno hipoperfuziju u temporalnom regionu sa epileptičnim fokusom

**ZAKLJUČAK:** Zaključak SPECT i FDG-PET mogu vizualizovati epileptogeni fokus kao zonu hiperperfuzije i hipermetabolizma iktalno, hipoperfuzije i hipometabolizma interiktalno i značajne su metode u prehirurškoj evaluaciji pacijenata sa fokalnom farmakorezistentnom epilepsijom, posebno ako je MR nalaz normalan ili su MR i video EEG nalaz diskordantni.



9th BALKAN  
CONGRESS OF  
**NUCLEAR  
MEDICINE**  
AND SERBIAN  
CONGRESS OF

May 12-14  
**20  
22**  
Fruske terme  
**Vrdnik  
Serbia**

#### **PT4**

#### **IZLOŽENOST OSOBLJA JONIZUJUĆEM ZRAČENJU PRI SEPARACIJI I APLIKACIJI FDG RADIOFARMAKA POLUAUTOMATSKIM I AUTOMATSKIM SEPARATOROM POJEDINAČNIH DOZA-Kontrola kvaliteta**

Issa Sami, Ješić Ana, Milošević Igor, Stojiljković Milica, Centar za nuklearnu medicinu sa PET, Univerzitetski klinički centar Srbije; E-mail address of the presenting author: sami.issa.bg@gmail.com

**UVOD:** : Uvođenje najnovije opreme u radu sa otvorenim izvorima jonizujućeg zračenja ima veliki značaj u smanjivanju izloženosti medicinskog osoblja. Najveća izloženost osoblja je pri separaciji i aplikaciji pojedinačnih pacijent-doza..

**CILJ:** poređenje ekspozicionih doza osoblja pri radu sa poluautomatskim i automatskim separatorom doza.

**MATERIJAL I METODE:** Poluautomatski separator se koristi u nacionalnom PET centru od 2010.godine, a automatski separator se koristi počevši od 2015. Ekspozicione doze osoblja su merene elektronskim dozimetrom i računane na period od godinu dana pri upotrebi oba separatora doza.

**REZULTATI:** Rezultati su dati kao srednja vrednost rezultata dobijenih očitavanjem elektronskih dozimetara osoblja koje je radilo sa poluautomatskim i automatskim separatorom, u periodu od godinu dana. Ekspoziciona doza tehničara pri radu sa poluautomatskim separatorom, po jednom pacijentu, iznosi 0,1-0,2  $\mu\text{Sv}$  pri separaciji, 0,7-0,9  $\mu\text{Sv}$  pri aplikaciji, i 0,8.-1,0  $\mu\text{Sv}$  ukupno. Vrednosti u radu sa automatskim separatorom, po pacijentu, iznose: 0,07-0,1  $\mu\text{Sv}$  pri separaciji, 0,08-0,13  $\mu\text{Sv}$  pri aplikaciji, i 0,15-0,23  $\mu\text{Sv}$  ukupno.

**ZAKLJUČAK:** Automatski separator aktivnosti pokazuje veću tačnost i preciznost u separaciji i aplikaciji pojedinačnih doza i redukuje vreme ekspozicije osoblja, što rezultuje manjom ekspozicionom dozom osoblja u radu sa automatskim separatorom u odnosu na poluautomatski separator doza.



**PT5**

**PET/CT – КОНТРОЛА КВАЛИТЕТА, ДИЈАГНОСТИЧКИ ПОТЕНЦИЈАЛ, ПРИМЕНА И ЗНАЧАЈ**

Krkalović Tatjana, Janjić Biljana, Spasić Anja

Centar za nuklearnu medicinu sa PET, Univerziteti klinički centar Srbije; E-mail address of the presenting author: t.krkalovic@gmail.com

UVOD PET/CT je hibridna mašina koja ima dvostruku perspektivu, jer u istom ispitivanju dobijamo morfologiju i odnos između različitih struktura i organa, ali i procenu funkcije organa i njihove različite fizio-patološke procese. PET/CT je zasnovan na detekciji koincidencije dva 511 KeV anihilaciona fotona. Na dobijenoj slici možemo videti koncentraciju trejsera kao trodimenzionu sliku metaboličkog procesa u telu. FDG-fluorodeoksiglukoza (FDG) je jedinjenje glukoze obeležene fluorom-18, pozitronskim emiterom, sa vremenom poluraspada 110 min, i visoke energije od 511KeV. FDG je najčešće korišćen radiofarmak

ZAKLJUČAK Zahvaljujući velikom dijagnostičkom potencijalu PET/CT-a značajno se ubrzava uspostavljanje tačne dijagnoze, dobijaju se precizniji rezultati toka lečenja, unapređuje se planiranje radioterapije. Bolesnici se lišavaju nepotrebnih, manje korisnih, invazivnih dijagnostičkih procedura. Cilj je da se poboljša nečije zdravstveno stanje i produži ljudski život.



## PT6

### **Scintigraphic detection of dialysis solution leakage in patients treated with continuous ambulatory peritoneal dialysis**

Lela Vranić, Ljiljana Kojić, Jelica Vidojević, Marina Vlajković, Milena Rajić, Center of Nuclear Medicine, University Clinical Center Niš, Serbia. E-mail address of the presenting author: milenarajic55@gmail.com

**Background and aim:** Leakage of the peritoneal dialysis solution is the main complication of peritoneal dialysis which is not caused by infection. It includes any loss of dialysate from the peritoneal cavity. This leakage is clinically important because it can lead to a reduction of ultrafiltration and significant fluid retention. The aim of this work was to assess the significance of peritoneal scintigraphy (PS) for the detection of dialysate leakage in patients treated with continuous ambulatory peritoneal dialysis (CAPD).

**Patients and Methods:** PS was performed in four patients (two males and two females) on CAPD, aged 34 to 69 yrs., with suspected dialysis fluid loss. Scintigraphy was performed after infusion of  $99\text{mTc-Sn}$  colloid (74 MBq) mixed with 2 liters of the peritoneal fluid through dialysis catheter in the peritoneal cavity. Prior to the scintigraphy, the abdominal cavity was drained of all dialysis solution. Multiphase imaging included: dynamic scintigraphy starting from initiation of radiolabeled infusion during 15 min; postinfusion phase; postambulatory phase (after walking for 30 to 60 min), and postdrainage phase (after drainage of radiolabeled dialysate). The finding, which indicates the leakage of dialysate, is the appearance of radioactivity outside the peritoneal cavity.

**Results:** Leakage of dialysate was detected in three of four patients. In the two patients peritoneal-pleural and in one patient vaginal leak was demonstrated. In patient with vaginal leakage, which is otherwise very rare, radioactivity was detected in the projection of the left fallopian tube and vagina. Two patients with proven dialysis solution leakage were transferred to hemodialysis, while one patient continued treatment with CAPD after pleurodesis.

**Conclusion:** Obtained results showed that peritoneal scintigraphy is useful non-invasive method for the detection and localization of dialysate leakage. Based on the PS findings, further treatment of patients may be planned. Considering complex methodology, nuclear-medicine technologists play an important role in the performing of this method.

**Keywords:** dialysate leakage, peritoneal dialysis, scintigraphy



## PT7

### **Перфузиона сцинтиграфија миокарда (СПЕКТ), контрола квалитета, садржај и делокруг рада медицинске сестре и струковног радиолога**

Зорица Миловановић, Весна Недељковић, Центар за нуклеарну медицину са ПЕТ, Универзитетски клинички центар Србије, E-mail address of the presenting author: [vesna.nedeljkovic1984@gmail.com](mailto:vesna.nedeljkovic1984@gmail.com)

Ова техника на бази интерно унетог обележивача тј. емисије зрачења из организма подразумева рачунарску реконструкцију ткзв. пројекционих података на одређеним телесним нивоима. Пројекциони подаци добијају се ротирањем гама камере око сагиталне осовине болесника за 180 степени. Реконструкцијом се добијају попречни и уздужни пресеци (хоризонтални и вертикални). Техника СПЕКТ-а помоћу обележеног радиофармака Тц99М омогућава прецизнију процену коронарне исхемије или акутног и хроничног инфаркта, с обзиром на одсуство преклапања срчаних структура.

Индикације за сцинтиграфију миокарда: 1. Акутни инфаркт миокарда, 2. Нестабилна ангина пекторис, 3. Хронична стабилна коронарна болест

Припрема болесника пре испитивања

1. Не доручковати, узети терапију (важи за пацијенте који узимају терапију) дијабетичари могу узети лаган доручак
2. Не узимати кафу, кока колу, чај и слично, не пушити
3. Упозорити лекара и пацијента на могућност трудноће или на дојење!
4. Дан раније избегавати тешка физичка оптерећења
5. Накит и остале металне украсе оставити коде куће или их уклонити пре снимања
6. Након снимања болесник треба пити што више воде и што чешће мокрити

Поступак испитивања

Испитивање се изводи у два дана у амбулантним условима

Први дан испитивање се састоји у вожњи бицикла (ергометрија), где се на свака 2-3 мин. повећава оптерећење; током оптерећења лекар мери крвни притисак и прати срчани рад. У максималном оптерећењу болеснику се у постављену браунилу иницира радиофармак.

Затим следи снимање срца под гама камером 45-60 мин. после интра венског давања радиофармака. Снимање траје око 20 минута.

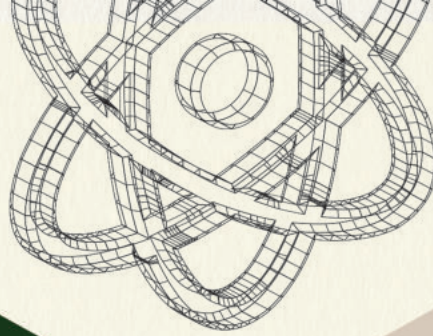
Други дан испитивање се састоји у убризгавању радиофармака у миру. Након 45-60 мин. Пацијент се снима испод гама камере, 20 минута. После снимања пацијент иде кући. Обавестити га да треба избегавати блиски контакт са другим особама, нарочито са децом и трудницама.



M A G N A  
P H A R M A C I A



ARIA | Conference & Events



KLINIČKI CENTAR SRBIJE



UNIVERZITET u BEOGRADU  
MEDICINSKI FAKULTET



SRPSKO FARMACEVTSKO DRUŠTVO  
18 72



SRPSKI VEŠTAČKI MEDICINSKI SVEZ  
SRPSKOSRPSKI VEŠTAČKI MEDICINSKI SVEZ

[nucmedai.com](http://nucmedai.com)