

## TREATMENT OF VENOUS MALFORMATIONS IN PEDIATRIC POPULATION – THREE- YEAR EXPERIENCE

Roza Sokolova<sup>1</sup>, Shaban Memeti<sup>1</sup>, Toni Risteski<sup>1</sup>, Biljana Andonovska<sup>1</sup>, Njomza Lumani-Bakiji<sup>1</sup>, Aleksandar Stepanovski<sup>1</sup>, Borche Kocevski<sup>2</sup>

<sup>1</sup> University Clinic of Pediatric Surgery; Ss. Cyril and Methodius University in Skopje, Faculty, of Medicine, Republic of North Macedonia.

<sup>2</sup> Clinical Hospital Tetovo, Surgical department, Republic of North Macedonia

### Abstract

**Citation:** Sokolova R, Memeti S, Risteski T, Andonovska B, Lumani-Bakiji N, Stepanovski A, Kocevski B. Treatment of venous malformations in pediatric population – three- year experience.

Arch Pub Health 2022; 14(2) Online first:

doi.org/10.3889/aph.2022.6052

**Key words:** congenital vascular malformations; pediatric venous malformations; sclerotherapy; bleomycin; phleboliths.

**\*Correspondence:** Roza Sokolova, University Clinic of Pediatric Surgery Skopje, North Macedonia

Email: sokolovaroz@yahoo.com

**Received:** 15-Mar-2022; **Revised:** 20-Apr-2022; **Accepted:** 27-June-2022; **Published:** 1-July-2022

**Copyright:** © 2022. Roza Sokolova, Shaban Memeti, Toni Risteski, Biljana Andonovska, Njomza Lumani-Bakiji, Aleksandar Stepanovski, Borche Kocevski. This is an open-access article distributed under the terms of the Creative Commons Attribution License, which permits unrestricted use, distribution, and reproduction in any medium, provided the original author(s) and source are credited.

**Competing Interests:** The author have declared that no competing interests

Venous malformations (VMs) are a type of vascular malformations that result in abnormal development of veins that become extensible over time due to an error in vascular morphogenesis. They usually appear in newborns or in early adulthood as a bluish, soft, swollen and eventually painful skin formation. Treatment includes conservative therapy, sclerotherapy, and surgical excision. Aim of the paper is to evaluate the therapeutic effect of sclerotherapy in pediatric patients with venous malformations. Material and methods: In a three-year period, from 2019 to 2021, venous malformations were found in 33 patients aged 4 to 14 years (average age: 8 years). Pain as a symptom occurred in 8 patients. Two patients had lesions measuring up to 5 cm and 5 cm, respectively, while in the remaining subjects the lesion was over 5 cm. Ultrasound was performed routinely in all subjects, and MRI in two patients. Conservative treatment was instituted in 13 patients with venous malformations of the extremities; surgical excision with local reconstruction was performed in 11 patients, and sclerotherapy with bleomycin under general anesthesia was performed in 8 patients. Combined treatment was used in one patient that presented with venous malformation of the upper arm that underwent partial sclerotherapy with subsequent operative excision due to a phlebolith. Follow-up examinations revealed regression of the change not only from functional but from aesthetic aspect as well. Conclusion: Sclerotherapy is the established golden standard, first-line treatment for venous malformations. Excellent results were achieved as the reduction of the lesions was below 50% of the initial size. However, the modality of treatment should be individualized to each patient as it can sometimes require a combination of more than one treatment option. Venous malformations are best treated early, but they usually recur over time. Treatment helps relieve symptoms and control the growth of vascular malformations.

### КЛИНИЧКИ ИСТРАЖУВАЊА

## ТРЕТМАН НА ВЕНСКИ МАЛФОРМАЦИИ КАЈ ПЕДИЈАТРИСКА ПОПУЛАЦИЈА – ТРИ-ГОДИШНО ИСКУСТВО

Роза Соколова<sup>1</sup>, Шабан Мемети<sup>1</sup>, Тони Ристески<sup>1</sup>, Биљана Андоновска<sup>1</sup>, Њомза Љумани-Бакији<sup>1</sup>, Александар Степановски<sup>1</sup>, Борче Коцевски<sup>2</sup>

<sup>1</sup> Универзитетска клиника за детска хирургија; Универзитет „Св. Кирил и Методиј“ во Скопје, Медицински факултет, Република Северна Македонија

<sup>2</sup> Клиничка болница – Тетово, Хируршки оддел, Република Северна Македонија

### Извадок

**Цитирање:** Соколова Р, Мемети Ш, Ристески Т, Андоновска Б, Љумани-Бакији Њ, Степановски А, Коцевски Б. Третман на венски малформации кај педијатриска популација – три-годишно искуство.

Arch J Здравје 2022;14(2): Online First

doi.org/10.3889/aph. 2022. 6052

**Клучни зборови:** конгенитални васкуларни малформации; венски малформации; склеротерапија; блеомицин; флеболит.

**\*Кореспонденција:** Роза Соколова, Универзитетска клиника за детска хирургија, Универзитет „Св. Кирил и Методиј“ во Скопје, Медицински факултет, Република Северна Македонија. E-mail: sokolovaroz@yahoo.com

**Примено:** 15-мар-2022; **Ревидирано:** 20-апр-2022; **Прифатено:** 27-јуни-2022; **Објавено:** 1-јули-2022

**Печатарски права:** ©2022 Роза Соколова, Шабан Мемети, Тони Ристески, Биљана Андоновска, Њомза Љумани-Бакији, Александар Степановски, Борче Коцевски. Оваа статија е со отворен пристап дистрибуирана под условите на нелокализирана лиценца, која овозможува неограничена употреба, дистрибуција и репродукција на било кој медиум, доколку се цитираат оригиналните автор(и) и изворот.

**Конкурентски интереси:** Авторот изјавува дека нема конкурентски интереси.

Венските малформации се тип на васкуларни малформации што резултираат со патолошки развој на вените, кои стануваат проширени со тек на време како резултат на нарушување во морфогенезата. Обично се манифестираат во новороденечка или рана адолтна возраст како сини, меки, отечени и болни на палпација кожни формации. Третманот вклучува: конзервативна терапија, склеротерапија и хируршка ексцизија. Цел на трудот е да се евалуираат терапевтските ефекти од склеротерапијата кај педијатриски пациенти со венски малформации. Материјали и методи: Во 3-годишен период (2019-2021), венските малформации беа дијагностицирани кај 33 пациенти на возраст од 4 до 14 години (средна возраст: 8 години). Болка како симптом се јави кај 8 пациенти. Кај двајца пациенти лезијата беше поголема од 5 cm и еднаква на 5 cm соодветно, додека кај останатите пациенти лезиите беа под 5 cm. Ултрасонографија беше ординирана рутински кај сите пациенти и МРИ кај двајца пациенти. Конзервативниот третман беше ординиран кај 13 пациенти со венски малформации на екстремитетите, хируршка ексцизија со локална реконструкција кај 11 пациенти, додека кај 8 пациенти беше изведена склеротерапија со блеомицин во услови на општа анестезија. Комбинирана терапија се употреби кај еден пациент со клиничка слика на венска малформација на надлактица, кај кого третманот вклучуваше парцијална склеротерапија со последователна оперативна ексцизија заради флеболит. Контролните прегледи покажаа регресија на промената, не само од функционален туку и од естетски аспект. Заклучок: Склеротерапијата е воспоставен „златен стандард“ и прва линија на третман на венските малформации. Беа постигнати одлични резултати, со оглед на редукција на лезијата под 50% од иницијалната големина. Сепак овој тип на третман потребно е да се индивидуализира за секој пациент, со оглед на тоа што побарува комбинација на повеќе од еден тераписки модалитет. Венските малформации најоптимално се лекуваат рано заради тенденцијата за рекурентност. Со помош на третманот се подобруваат симптомите и се контролира растот на венските малформации.

## Introduction

Vascular anomalies account for 5% of pathological conditions in the pediatric population. The presence of a vascular anomaly means abnormal growth and development of capillaries, veins, arteries, and/or lymphatic vessels.

Venous malformations (VMs) are a type of vascular malformations that result in abnormal development of veins that become extensible over time due to an error in vascular morphogenesis. They belong to the group of slow-flow or low-flow malformations with lesions composed of capillaries, veins and/or lymphatic blood vessels. Venous malformations usually appear in newborns or in early adulthood as a bluish formation of the skin that is soft on palpation, swollen and eventually painful<sup>1-3</sup>. They are characterized by irregular blood flow and an increased risk of intralesional and/or systemic thrombosis. The presence of thrombosis is manifested by episodes of pain and small palpable superficial thrombi. The very presence of thrombi leads to a loss of elasticity of the vessel wall. The walls of the veins that make up the venous malformation lack smooth muscle compared to normal veins. The cause of this type of malformation is unknown, but research shows the involvement of certain genetic mutations<sup>4</sup>.

VMs can be quite sensitive and accompanied by pain. These types of malformations appear as bluish skin discoloration and can express as a simple or multiple lesions. In terms of depth, the lesions can be deep or superficial. VMs can cover one or more areas of the body with

focal, multifocal or diffuse distribution. The most common occurrence is on the extremities (40%), followed by the neck, mouth, part of the face, scalp etc. Superficial VMs range from small dots to more extensive changes<sup>5</sup>. The grading is based on the findings of MR with VMs less than 5 cm, equal to 5 cm and those larger than 5 cm.

The symptoms of venous malformations depend on their location. By growing larger they can exert compressive effect on the surrounding tissues and organs.

The International Society for the Study of Vascular Anomalies (ISSVA) is used as a standard nomenclature for diagnosis and treatment of vascular anomalies<sup>6</sup>. According to this classification vascular anomalies are divided into vascular tumors and vascular malformations. It was approved in 2014 and further updated in 2018 with the incorporation of new anomalies and causal genes.

The diagnosis is made by clinical examination, ultrasonography, magnetic resonance imaging or magnetic resonance imaging with venography. Ultrasonography can help if the VM is superficial. It is a useful non-invasive technique. Color Doppler is recommended for a more accurate diagnosis. MRI or MR venography as a method for further evaluation shows the relationship of surrounding tissues with the pathological change, depth of lesion, blood flow, presence of phleboliths etc.

Positive clinical signs include bluish discoloration of skin, soft and compressible formation, pain, swelling and the involvement of superficial or deeper structures. Negative clinical

cal signs include pulsation, thrill and hyperemia.

Asymptomatic venous malformations do not require treatment.

The basic non-surgical treatment consists of appropriate elastic compression with socks or gloves, depending on whether the VM is located on the leg or arm, so as to alleviate the symptoms of swelling and pain. Minimal doses of aspirin are administered to prevent phleboliths. Other modalities of treatment include sclerotherapy, laser therapy, embolization and surgical intervention.

Sclerotherapy is a minimally invasive method that is used as monotherapy or in combination with surgical treatment. Ethanol and bleomycin are commonly used sclerosing agents. Direct percutaneous puncture (DPP) is a method of injecting a fluid under fluoroscopic control. The volume of ethanol injected is 0.15-1mL/kg of body weight every 10 minutes. General anesthesia is required due to the pain and the treatment is repeated as needed after 3 to 4 weeks. Bleomycin as a sclerosing agent is administered at 1 mL/kg of body weight with no more than 15 mL per sclerosing intervention<sup>7</sup>. It is performed under ultrasonographic control and general anesthesia. The treatment can be repeated after 3 to 4 months. Sclerotherapy with sodium decyl sulfate. Several treatments are usually needed for complete withdrawal. Extensive lesions are usually treated with 95% ethanol, whereas smaller lesions could be treated with sodium tetradecyl sulfate. Sclerotherapy is usually performed by an experienced pediatric surgeon.

Aim of the paper is to evaluate the therapeutic effect of sclerotherapy in pediatric patients with venous malformations.

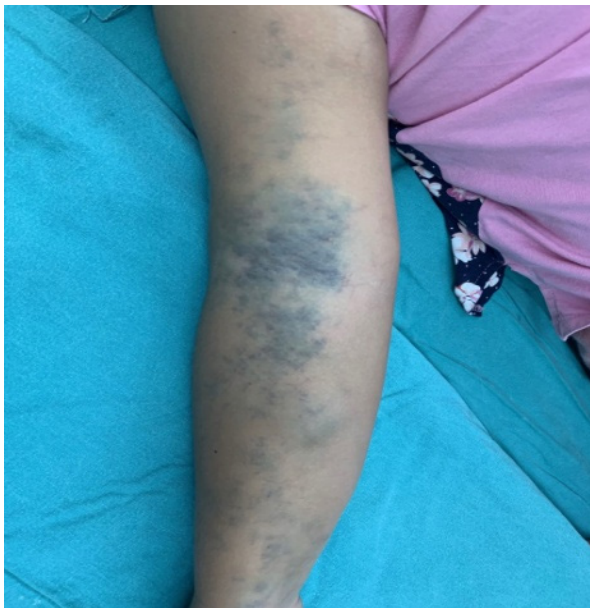## Material and methods

During a 3-year period, from 2019 to 2021, at the Clinic for Pediatric surgery - Skopje, 33 patients with venous malformation were treated. The patients were initially presented to the outpatient department with a diagnosis of hemangioma. A history carefully taken revealed that the lesion had been present since birth in all patients. It increased with crying and exertion with no signs of regression over time. The diagnosis was reached by ultrasonography examination, and MRI was performed in two children. The latter imaging modality was used to rule out the presence of arteriovenous malformation. Our series included 17 males and 16 female patients, in the age range from 4 to 14 years, with mean age of 8.6 years. The venous malformation was located on the extremities in 24 patients (12 patients with lesions on the upper and lower extremity respectively), on the back in 3 patients and the neck region was affected in 2 patients. In the remaining 4 patients the lesion was noticed in other areas (face, inguinal region etc.). Predominant symptom was pain and swelling in the affected area reported by almost all subjects. In terms of size, two patients had lesions measuring up to 5 cm and 5 cm, while in the remaining subjects the lesion was over 5 cm. Conservative treatment was instituted in 13 patients.

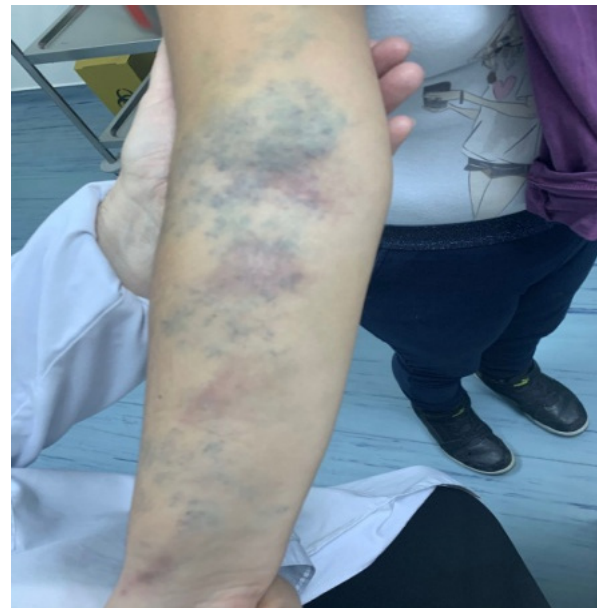## Results

In 8 patients sclerotherapy with bleomycin was performed due to the presentation with pain (Fig.1,2). Side effects included local skin rash and swelling that were alleviated by topically applied dressings with boric acid solution and oral analgesics. Sclerotherapy was also performed in a child with venous malforma-

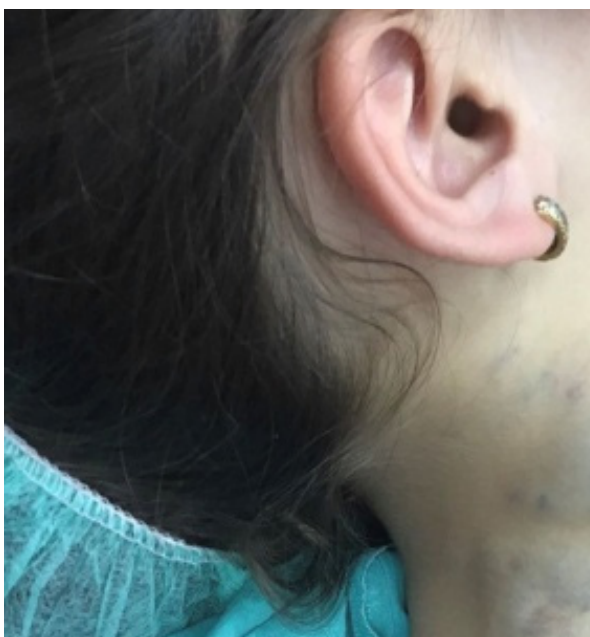tion on the neck due to an intermittent pain that limited mobility of the neck (Fig.3). The procedure with bleomycin as sclerosing agent was performed in the operative theater under general anesthesia. Follow-up examinations revealed regression of the change not only from functional but from aesthetic aspect as well (Fig.4).



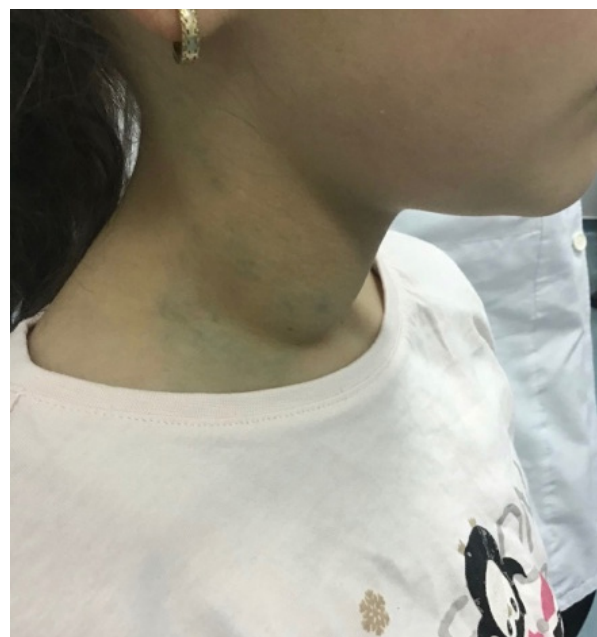**Fig 1.** VM on the arm before sclerotherapy



**Fig 2.** Outcome after one session of sclerotherapy



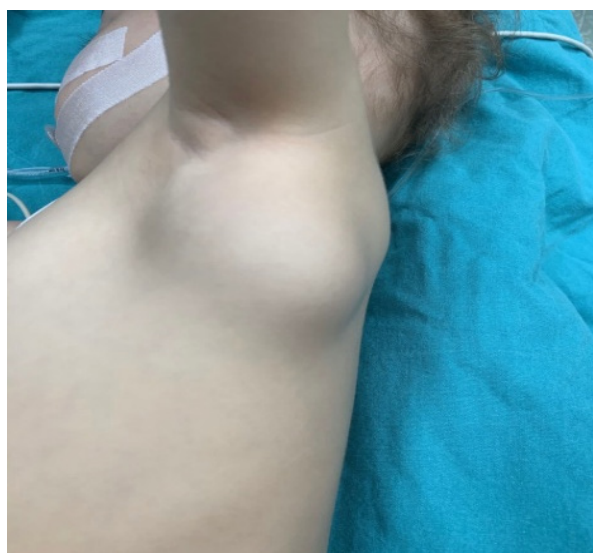**Fig 3.** VM on the neck before sclerosing intervention



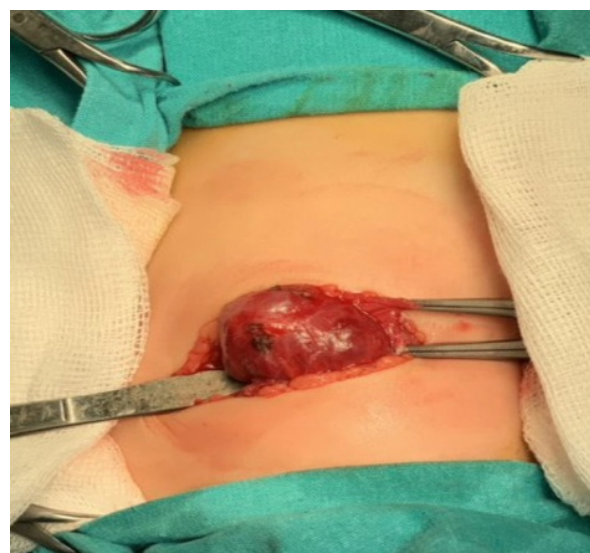
**Fig 4.** VM after two sessions of sclerotherapy

Surgical treatment was indicated in 11 patients as a result of palpable phleboliths and painful local lesion. Surgical excision with local reconstruction was performed (Fig.5,6). In two of the surgically treated children the lesion was located on the back and limb respectively. Intraopera-

tive phleboliths were found in all children. No postoperative complications were reported with normal findings at the follow-up ultrasonographic studies. The histopathologic findings described: “benign formation of widened venous vessels with no signs of malignancy”.



**Fig 5.** VM of left axillar region, preoperative



**Fig 6.** VM of left axillar region, intraoperative finding

Combined treatment was used in one patient that presented with venous malformation of the upper arm that underwent partial sclerotherapy with subsequent operative

excision due to a phlebolith.

Klippel-Trenaunay syndrome was diagnosed in 3 patients that were presented to us.

**Table 1.** Types of treatment in all patients

Treatment	Conservative	Sclerotherapy	Operative	Combined
Number of patients	13	8	11	1

In children with venous malformations of the extremities, a conservative treatment was initiated by applying an elastic bandage (sock or glove) in 6 patients, heparin-sodium ointment topically in 6 patients and application of minimal doses of anti-coagulant therapy in 1 patient. The conservative treatment was institut-

ed in 13 patients. They all achieved good results at the 2-month follow-up examination (Table 1).

Eight patients were treated with sclerosing agent bleomycin. In VMs less than 5 cm in size, sclerotherapy in one session in 3 patients yielded excellent results at the 2 month follow-up. The remaining 5 patients

had VMs more than 5 cm. In 2 of them sclerotherapy was performed in one session and in 3 patients in more than one session. They achieved good and excellent results respectively at the 2-month follow-up. Small lesions required only one sclerotherapy treatment, while widespread bulky lesions required second treatment after 3 months (Table 2).

Surgical treatment was used in 11 patients. In 7 of them the lesion was less than 5 cm and in the remaining 4 patients the lesion was more than 5 cm. Both groups showed good results in the reduction of the venous malformations and the combined treatment was used in one patient that presented with venous malformation of the upper arm that underwent partial sclerotherapy with subsequent operative excision due to a phlebolith.

**Table 2.** Patients treated with sclerotherapy

Category	Treatment	Patients	Results
Group I Venous malformations (less than 5 cm in size)	Sclerotherapy as monotherapy	3	Excellent
Group II Venous malformations (more than 5 cm in size)	Sclerotherapy as monotherapy	2	Good
Group III	Sclerotherapy as monotherapy - repetitive after 3 to 4 months	3	Good

Excellent results can be considered having in regard that the reduction of the lesion is below 50% of the initial size. Good results can be considered having in regard that the reduction of lesion is up to 50%, with unsatisfactory result meaning less than 20% of the initial size. In terms of long-term outcomes, further research and follow-up is required to investigate the durability of the amelioration of pain and the rates of recurrence following treatment after 2-month follow up.

## Discussion

Venous malformations occur with an incidence of 1-5 in 10.000 births and prevalence of 1% and constitute two thirds of all congenital vascular

malformations. They arise at different body regions including the head and neck (40%), extremities (40%) and trunk (20%), and their size varies from superficial asymptomatic to extensive and disfiguring lesion<sup>8</sup>. VMs are soft-tissue formations, characterized by slow blood circulation, which can cause blood clots to form calcifications. These are the so-called phleboliths or venous stones, they tend to grow without spontaneous regression. One of the features of VM is that it becomes larger during effort when the child cries. The symptoms of venous malformations depend on their location. By growing larger, they can exert compressive effect on the surrounding tissues and organs. Extremely large venous malformations can cause inflammation with activa-

tion of endothelial cells, intravascular coagulation with many blood clots of proteins resulting in the so-called local intravascular coagulation characterized by disturbance of plasma fibrinogen, factor V, factor VII and factor VIII levels of coagulation and elevation of D-dimers. They present mostly as sporadic cases, although familial inheritance is possible. Complex combined vascular malformations include several syndromes such as Klippel-Trenaunay syndrome, Parkes Weber Syndrome, extensive diffuse low-flow venous malformations, Bannayan-Riley syndrome, Maffucci's syndrome, cutis marmorata teleangiectatica congenita, CLOVES syndrome, Proteus syndrome etc<sup>9,10</sup>.

The ISSVA classification system first distinguishes CVMs between vascular tumors and vascular malformations. This is especially important as vascular malformations are frequently misdiagnosed as hemangiomas. The Hamburg Classification classifies vascular malformations into five main categories: arterial, venous, arteriovenous, lymphatic, and combined vascular malformations. Furthermore, it divides these categories into two embryological based subcategories, extratruncular or truncular lesions. Extratruncular malformations occur in earlier embryonic stages, while truncular anomalies form during the later stages of embryonic development<sup>11</sup>.

According to their vascular hemodynamics, vascular malformations are divided into high-flow malformations which include arteriovenous malformations, and low-flow malformations that include lymphatic malformations, capillary-venulous malformations, venous malforma-

tions, glomovenous malformations, and non-shunting mixed lesions<sup>12</sup>. The most common type of low-flow vascular lesions are VMs, subdivided into sporadic VMs (94%), dominantly inherited cutaneomucosal VMs (1%) and, dominantly inherited and non-inherited glomuvenous malformations (5%) first described by Vikkula et al<sup>13</sup>.

Accurate diagnosis has been a limiting factor in vascular malformation management. Non-invasive imaging methods are preferred. Doppler ultrasound and magnetic resonance imaging are key imaging methods used to diagnose vascular malformations. Contrast-enhanced MRI and MRA are the preferred imaging modalities for pre-procedure diagnosis and interventional planning as well as post-procedure evaluation of the vascular malformation. Conventional MRI has 100% sensitivity and 24% to 33% specificity in differentiating VMs from non-VMs<sup>14</sup>. Dynamic contrast MR angiography increases specificity to 95%. Direct percutaneous puncture with contrast injection or phlebography (DPP) is the fine-needle puncture of the VM with subsequent contrast injection under fluoroscopy. It is the gold standard diagnostic tool for specificity when confirmation of a VM is required after alternative imaging approaches have not yielded definitive results, in cases when treatment planning is required or when a neoplasm must be ruled out.

Prior to treatment, the surgeon should consider lesion's pathophysiology, etiology, and consequences of the procedure. There may be instances when it is prudent to delay intervention in favor of observation, or to avoid intervention if there are

no significant symptoms and risks. Lesions with severe symptoms and/or potential complications should be treated. Extratruncular subtype of venous malformation is more likely to require treatment, as they display worse symptoms and higher recurrence rate than truncular forms.

Treatment includes conservative therapy, sclerotherapy and surgical excision. Surgical intervention was traditionally considered to be the initial form of treatment if the lesion could be completely resected and had minimal anatomic and functional consequences. However, the emergence of sclerotherapy as a viable yet cost-effective and minimally invasive technique has spurred its use as mono-therapy or in conjunction with surgery<sup>15</sup>. As excision of complex lesions remains difficult due to secondary intraoperative bleeding, the favored approach is now sclerotherapy. Therefore, sclerotherapy is the established golden standard, first-line treatment for VMs<sup>16</sup>. Bleomycin is derived from *Streptomyces verticillus* as antibiotic with cytotoxic and antineoplastic features and induces both single- and double-stranded DNA break down in endothelial sclerosants. It has also been found that it elicits the least inflammatory response<sup>17</sup>. It shows similar efficacy as alcohol in superficial venous malformations but with fewer side effects. The overall response of bleomycin treatment is reported in range from 70-100% with a complication rate of 6%. Mucositis, alopecia, pulmonary toxicity and hyperpigmentation have been mentioned as adverse effects<sup>8</sup>. The reported effectiveness of bleomycin is between 43–82.7%<sup>18-20</sup>. However, the modality of treatment should be individualized to each patient as it can

sometimes require a combination of more than one treatment option and the application of appropriate sessions. Ahmad et al. in his case series of seven patients with venous malformations in the orbital and paraorbital region treated with percutaneous sclerotherapy with bleomycin reported higher efficacy of bleomycin than other sclerosing agents, no major systemic adverse effects and emphasised the safeness of this procedure. In the reported 2 female children of 5 and 7 years of age, he noticed improvement in the outcome at 9 and 12 months of follow-up respectively<sup>17</sup>. Shigematsu et al. in his retrospective review of 18 patients with VM of the eyelid reported more than 80% reduction and 50-80% reduction in seven and eight patients respectively by using bleomycin sclerotherapy. Recurrence was reported in one patients, with no complication related to the procedure. He concluded that the use of bleomycin appeared to be a simple, safe and effective treatment for VM affecting the eyelid and that it avoided the more complex procedures of surgery and laser interventions<sup>21</sup>. Mohan et al. came to the similar conclusion in their retrospective study of the outcome of 32 children with proven VM treated with intralesional bleomycin injection<sup>22</sup>. Although Zhang et al. in their large randomised study involving 138 children demonstrated superior curative effects of absolute ethanol in comparison to bleomycin, ethanol therapy showed greater incidence of adverse effects compared to bleomycin, in first place skin necrosis, localized swelling, muscle fibrosis and even brain embolism<sup>23</sup>. Some studies demonstrated more successful results of a combined sclerotherapy with laser or surgical therapy in



the cervicofacial venous malformations<sup>24,25</sup>.

Post therapy follow up assessment is vital in a clinical setting. A significant percentage of patients will suffer from their VMs again after treatment. In particular female patients who undergo pregnancy or younger patients undergoing puberty as hormonal changes trigger recurrence or proliferation. MRI is most suited to evaluate clinical outcomes after successful sclerotherapy. There is not enough evidence to the superior effect of one treatment over the other in terms of obtaining favorable results.

## Conclusion

Our series showed that there are different treatment approaches in the management of venous malformations in children. The modality of treatment depends on the location of lesion, accompanying symptoms, size of formation, presence of phlebolith etc. The study determines the prevalence of this pathology by sex, age and associated syndromes if present. It emphasizes the importance of monitoring these children for a certain period of time for possible additional treatment. A multidisciplinary approach is important for the management of pediatric vascular abnormalities especially for venous malformations. For proper treatment it is recommended to include a team of pediatric hematologist, interventional radiologist, surgeon and anesthesiologist. US and MRI are the two central imaging techniques in the work-up of VMs. DPP is a golden standard diagnostic tool utilized when other imaging is equivocal. It also plays a central role in aiding decisions during sclerotherapy.

In our series almost all of the patients in the sclerotherapy group achieved excellent results i.e. reduction for more than 50% of the initial size either by monotherapy or repetitive therapy in comparison to the conservative and surgical therapy group. Sclerotherapy is the gold standard for treating these malformations and is the first line of treatment. The usage of preoperative sclerosing therapy with N-butyl cyanoacrylate (n-BCA) has been described in literature 24 to 48 hours before the surgical excision. Combined therapy is sometimes necessary in order to achieve satisfactory results.

Venous malformations are best treated early; however, they usually recur over time. It is important to note that treatment helps relieve symptoms and control the growth of VMs.

## References

1. Redondo P, Aguado L, Martínez-Cuesta A. Diagnosis and management of extensive vascular malformations of the lower limb: part II. Systemic repercussions, diagnosis, and treatment. *Journal of the American Academy of Dermatology* 2011; 65: 909-923.
2. Lobo-Mueller E, Amaral JG, Babyn PS, Wang Q, John P. Complex combined vascular malformations and vascular malformation syndromes affecting the extremities in children. *Semin Musculoskelet Radiol* 2009; 13(3):255-276.
3. Lee MS, Liang MG, & Mulliken JB. Diffuse capillary malformation with overgrowth: a clinical subtype of vascular anomalies with hypertrophy. *Journal of the*

- American Academy of Dermatology 2013; 69: 589-594.
4. Mazoyer E, Enjolras O, Laurian C, Houdart E, & Drouet L. Coagulation abnormalities associated with extensive venous malformations of the limbs: differentiation from Kasabach–Merritt syndrome. *Clinical & Laboratory Haematology* 2002; 24: 243-251.
  5. Enjolras O, Ciabrini D, Mazoyer E, Laurian C, Herbreteau D. Extensive pure venous malformations in the upper or lower limb: a review of 27 cases. *Journal of the American Academy of Dermatology* 1997; 36: 219-225.
  6. ISSVA classification for vascular anomalies. (n.d.). Retrieved March 10, 2022, from <https://www.issva.org/UserFiles/file/ISSVA-Classification-2018.pdf>
  7. Ernemann U, Kramer U, Miller S, Bisdas S, Rebmann H, Breuninger H, et al. Current concepts in the classification, diagnosis and treatment of vascular anomalies. *European journal of radiology* 2010; 75: 2-11.
  8. Hage A N, Chick J, Srinivasa R N, Bundy J J, Chauhan N R, Acord M, Gemmete JJ. Treatment of venous malformations: The data, where we are, and how it is done. *Techniques in vascular and interventional radiology* 2018; 21(2): 45–54.
  9. Glovckzki P, & Driscoll D (2007). Klippel-Trenaunay syndrome: current management. *Phlebology* 22: 291-298.
  10. Noel AA, Gloviczki P, Cherry Jr KJ, Rooke TW, Stanson AW, & Driscoll DJ (2000). Surgical treatment of venous malformations in Klippel-Trenaunay syndrome. *Journal of vascular surgery* 32: 840-847.
  11. Lee BB, Baumgartner I, Berlien P, et al. Diagnosis and Treatment of Venous Malformations. Consensus Document of the International Union of Phlebology (IUP); updated 2013. *Int Angiol* 2015
  12. Richter GT, Friedman AB. Hemangiomas and vascular malformations: current theory and management. *Int J Pediatr* 2012; 2012:645678.
  13. Vikkula M, Boon LM, Mulliken JB. Molecular genetics of vascular malformations. *Matrix Biol* 2001;20:327-335.
  14. Van Rijswijk CS, van der Linden E, van der Woude HJ, et al. Value of dynamic contrast-enhanced MR imaging in diagnosing and classifying peripheral vascular malformations. *AJR Am J Roentgenol* 2002; 178(5):1181-1187.
  15. Legiehn GM, Heran MK. Venous malformations: classification, development, diagnosis, and interventional radiologic management. *Radiol Clin North Am* 2008;46 (3):545-597.
  16. Horbach SE, Lokhorst MM, Saeed P, et al. Sclerotherapy for low-flow vascular malformations of the head and neck: A systematic review of sclerosing agents. *J Plast Reconstr Aesthet Surg* 2016; 69(3):295-304
  17. Ahmad S, Akhtar FK. Percutaneous sclerotherapy of para-orbital and orbital venous malformation: A single center, case series. *Phlebology* 2019; 34(5), 355–361.

18. Bai Y, Jia J, Huang XX, et al. Sclerotherapy of Microcystic Lymphatic Malformations in Oral and Facial Regions. *J Oral Maxillofac Surg* 2009; 67(2):251-256.
19. Hassan Y, Osman AK, Altyeb A. Noninvasive management of hemangioma and vascular malformation using intralesional bleomycin injection. *Ann Plast Surg* 2013; 70(1):70-73.
20. Yang Y, Sun M, Ma Q, et al. Bleomycin A5 sclerotherapy for cervicofacial lymphatic malformations. *J Vasc Surg* 2011; 53(1):150-155.
21. Shigematsu T, Sorscher M, Dier E C and Berenstein A. Bleomycin sclerotherapy for eyelid venous malformations as an alternative to surgery or laser therapy. *Journal of neurointerventional surgery* 2019; 11(1), 57-61.
22. Mohan A T, Adams S, Adams K, Hudson D A. Intralesional bleomycin injection in management of low flow vascular malformations in children. *Journal of plastic surgery and hand surgery* 2015; 49(2), 116 -120.
23. Zhang J, Li HB, Zhou SY, Chen KS, Niu CQ, Tan XY, Jiang YZ, Lin QQ. Comparison between absolute ethanol and bleomycin for the treatment of venous malformation in children. *Exp Ther Med* 2013;6(2):305-309.
24. Gregory S, Burrows P E, Ellinas H, Stadler M, Chun R H. Combined Nd:YAG laser and bleomycin sclerotherapy under the same anesthesia for cervicofacial venous malformations: A safe and effective treatment option. *International journal of pediatric otorhinolaryngology* 2018; 108: 30-34.
25. MacArthur CJ, Nesbit G. Simultaneous intra-operative sclerotherapy and surgical resection of cervicofacial venous malformations. *International journal of pediatric otorhinolaryngology* 2019; 118: 143 -146.