

MORPHOMETRIC ANALYSIS OF THE CERVICAL SPINAL CANAL ON MRI

Niki Matveeva¹, Petar Janevski², Natasha Nakeva¹, Julija Zhivadinovik¹, Ace Dodevski¹

¹Institute of Anatomy, Faculty of Medicine, Ss. Cyril and Methodius University, Skopje, R. Macedonia

²Institute of Radiology, Faculty of Medicine, Ss. Cyril and Methodius University, Skopje, R. Macedonia

Corresponding Author: Niki Matveeva, Medicinski fakultet, 50 Divizija 6, Skopje, R. Macedonia,
Tel. 389 (0)2 2 55 74 25, Mobil: +389 (0)2 78 30 14 57, E-mail: nikimatveeva@gmail.com

Abstract

Two useful numerical values, called the Torg ratio and the spinal canal diameter (SC diameter) are widely accepted as reliable morphometric determinants of spinal stenosis. The aims of the study were to examine morphometric determinants of the cervical spinal canal on MRI in both sexes and analyse them as reliable indicators of spinal stenosis. Measurements were made on 50 MR images (sagittal T₂ weighted images from C3 to C7) of the cervical spine of patients from the Emergency Centre who had undertaken MRI of the cervical spine in addition to CT for various diagnostic indications. Torg ratio, used in evaluation of the spinal canal stenosis on plain x-ray radiographs, cannot be used as a spinal canal stenosis indicator due to the gender differences in the vertebral bodies' width. Sagittal canal diameters were more spread out in males than in females. MRI enables the value of the space available for the spinal cord, (SAC) to be determined, by subtracting the sagittal diameter of the spinal cord from the sagittal diameter of the spinal canal. Not gender, but individual and level differences in the SAC values were evident (cervical cord enlargement). SAC values relied more on the spinal canal than on the spinal cord, so that the differences in the dimensions of the spinal cord accounted for less variability in the SAC values. MR imaging of the cervical spine provides more accurate cervical canal and spinal cord measurements that could serve as morphometric determinants of the cervical canal stenosis.

Key words: morphometry, spinal canal, spinal cord, MRI.

Introduction

Stenosis, or narrowing, of the spinal canal has been previously associated with neurological injury and has been established as an important risk factor for the development of cervical spondylotic myelopathy (CSM), [7–9]. The size of the cervical spinal canal is clinically important especially in traumatic and degenerative conditions. The spinal canal was measured on plain laterolateral radiographs of the cervical spine from the posterior surface of the vertebral body to the closest point on the spinolaminar line at the pedicle level. In order to avoid variations in magnification with plain radiographs, Pavlov and Torg [16] used the ratio of the sagittal diameter of the spinal canal to the sagittal diameter of the vertebral body at the

same spinal level, as a method that can be a reliable indicator of cervical spinal canal stenosis. Plain radiographs have only the ability to evaluate osseous structures, but soft-tissue abnormalities may also contribute to the development of cervical spinal canal stenosis. MRI enables detection of subtle abnormalities in both soft-tissue and bones, so that the cervical spinal canal and cord can be accurately measured using MRI.

However, the Torg ratio is a more accurate indicator of spinal stenosis when plain laterolateral radiographs are used, because this method avoids measurement differences caused by different object-to-film distances, and magnification errors. MRI enables the value of the space available for the spinal cord (SAC) to be

determined, by subtracting the sagittal diameter of the spinal cord from the sagittal diameter of the spinal canal. As stenosis is the spinal canal's encroachment on the spinal cord and both components are included in the SAC value, this measurement technique may be adequate for identifying stenosis. The spinal-cord size varies among individuals, and between different vertebral levels (cervical cord enlargement) [12, 18]. Sagittal canal diameter < 12 mm and Torg ratio < 0.80 were widely accepted as indicative of cervical spinal stenosis. A SAC value indicative of stenosis was not determined in the previous studies.

The aims of our study were to examine morphometric determinants of the cervical spinal canal on MRI in both sexes and analyse them as reliable indicators of spinal canal stenosis.

Subjects and methods

This retrospective study included 50 subjects (21 males, 29 females), 19 to 64 years of age (average age 47.8 Standard Deviation 11.44). Subjects with evidence of traumatic, infectious or neoplastic spinal disorders, or congenital spine anomalies were excluded from the study. Sagittal diameters of the vertebral body, spinal canal, and spinal cord were traced and measured. The sagittal vertebral body diameter was measured at the level of the midpoints between the superior and inferior endplates. The sagittal spinal canal diameter was measured as the shortest distance from the midpoint between the vertebral body's superior and inferior endplates to the spinolaminar line. The sagittal spinal-cord diameter was measured at the transversal midline of the vertebral body at the appropriate level. The Torg ratio was determined by dividing the sagittal diameter of the spinal canal by the sagittal diameter of the vertebral body. The space available for the spinal cord (SAC) was determined by subtracting the sagittal cord diameter from the corresponding sagittal canal diameter, Fig. 1.

MR imaging examination of the cervical spine was preformed with 1.5 T MR unit (Signa HDi) with a spinal coil and a standardized neutral head position. The imaging protocol consisted of a sagittal T1-weighted fast spin-echo sequence (FSE) (repetition time msec/echo time msec, 800/14; section thickness, 4 mm; field of view, 360×360 mm; matrix, 448×224), sagittal T2-weighted turbo spin-echo sequence (3520/102; section thickness, 4 mm; intersection gap, 10 mm;

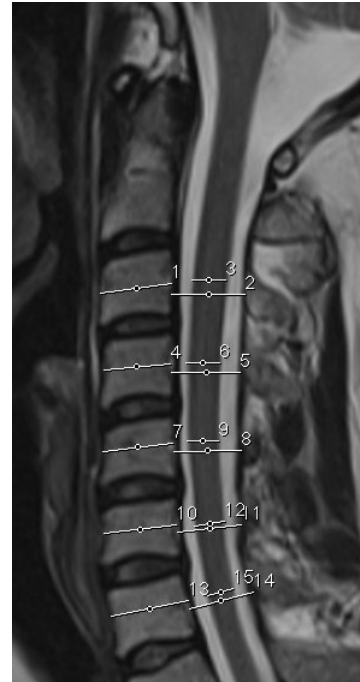

Figure 1 – Midsagittal T2 weighted pulse sequence of cervical spine in 55 years old man. Sagittal-diameter measurements of the spinal-cord, spinal-canal, and vertebral-body
3, 6, 9, 12, 15 = sagittal spinal-cord diameter,
2, 5, 8, 11, 14 = sagittal spinal-canal diameter;
1, 4, 7, 10, 13 = sagittal vertebral-body diameter.

echo train length of 24), and a transverse T2-weighted fast recovery fast spin-echo (FRFSE) sequence at one or multiple levels (4,660/120; section thickness, 4 mm; intersection gap, 0.6 mm; echo train length of 27; field of view, 200×200 mm; matrix 320×256). All imaging was performed and evaluated by a diagnostic radiologist. Measurements were made by another diagnostic radiologist on the sagittal T2 weighted images of the cervical spine, midsagittally at each spinal level from C3 to C7. The distances were measured in millimetres, repeated, and the mean value of three measurements was calculated. An institutional board approved this study.

Statistical Analyses

To test the differences between the two independent groups, the Mann Whitney test was used. Regression analyses were performed with the Torg ratio and SAC scores as criterion variables. A Pearson product moment correlation was calculated to determine if a significant relationship existed among the selected variables. A p value of 0.05 was considered as stati-

stically significant. The Statistical Package for the Social Sciences (version 13.0, SPSS Inc, Chicago, IL) was used for all statistical analyses.

Results

In 50 subjects (21 males, average age $48.43 \pm$ Standard Deviation 10.3; 29 females, average age $47.41 \pm$ Standard Deviation 12.36), 19 to 64 years of age, all morphometric determinants were reported from C₃ to C₇.

The average sagittal vertebral bodies diameters were $16.55 \text{ mm} \pm 1.26$ (average \pm standard deviation) in males and $14.03 \text{ mm} \pm 1.04$ in females. The sagittal vertebral bodies diameters were significantly larger in males ($p = .000$,

Mann Whitney). Sagittal canal diameters ranged from 11.20 mm to 17.80 mm in males and from 12.90 mm to 17.60 mm in females. Average sagittal spinal canal diameters were $14.59 \text{ mm} \pm 1.01$ in males and $15.26 \text{ mm} \pm 1.11$ in females. There were no significant gender differences in the average sagittal spinal canal diameters, although at C₆ and C₇ males had a greater spinal canal. The average sagittal spinal canal diameters were the least at C₅ in both sexes. The overall and interquartile ranges of the sagittal canal diameters were greater in males than in females. Sagittal canal diameters of less than 12 mm were evaluated in 8 males, Fig. 2.

INTERQUARTILE RANGES OF SAGITTAL CANAL DIAMETERS IN MALES AND FEMALES

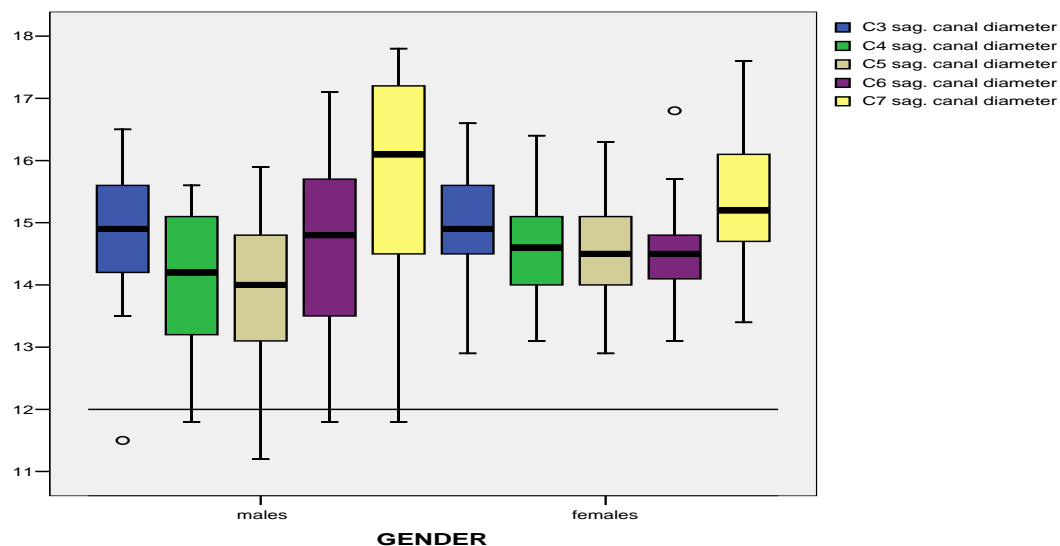


Figure 2 – Interquartile ranges of sagittal canal diameters by cervical spinal level in both sexes

Average sagittal spinal cord diameters were the greatest from C₃ to C₅ because of the cervical cord enlargement, $7.57 \text{ mm} \pm 0.42$ in males and $7.67 \text{ mm} \pm 0.95$ in females at C₃. At C₆ and C₇ the average sagittal spinal cord diameters were of lower values, $6.43 \text{ mm} \pm 0.72$ in males and $6.66 \text{ mm} \pm 0.73$ in females.

Torg ratio scores ranged from 0.62 to 1.19 in males and from 0.82 to 1.34 in females. The average Torg ratio scores were 0.89 ± 0.09 in males, and 1.1 ± 0.11 in females. Torg ratio

scores were greater in females ($p = .000$, Mann Whitney), due to the larger vertebral bodies in males, Fig. 3. A Torg ratio $\leq .80$ indicative of spinal stenosis existed in at least one vertebral level in all male subjects but in only one female and in 26 (10%) of 250 evaluated cervical levels, most frequently at C₄ and C₅ in males. Regression analyses revealed that the vertebral body ($r^2 = .58$) explained more of the variance in the Torg ratio in males than in females ($r^2 = .50$), while the spinal canal contributed for

nearly the same variance in the Torg ratio in both sexes, ($r^2 = .49$) in males and ($r^2 = .47$) in females. The Torg ratio relied more on the vertebral bodies than on the spinal canal. Gender differences in vertebral body sizes limit the

Torg ratio's value as an indicator of spinal stenosis, or may result in overdiagnosis of stenosis in males. Torg ratio scores $\leq .80$ corresponded with SAC data ranged from 4.8 to 8.5 mm at the same level.

INTERQUARTILE RANGES OF TORG RATIOS IN MALES AND FEMALES

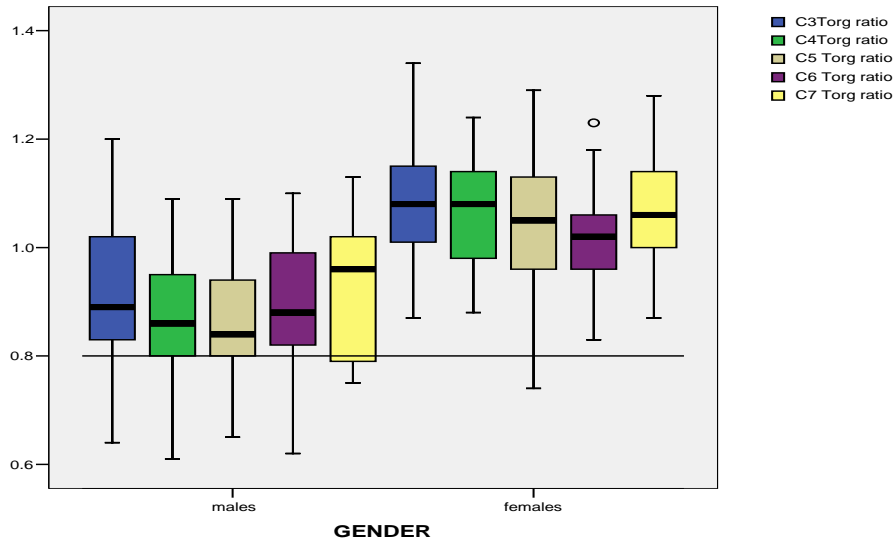


Figure 3 – Interquartile ranges of Torg ratios by cervical spinal level in both sexes

SAC data ranged from 4.82 to 12.36 mm in males and from 5.15 to 11.5 mm in females. The average SAC were the least from C₃ to C₅ in both sexes, 6.47 mm \pm 0.94 in males and 7.04 mm \pm 1.28 in females at C₄; but at C₇ the average SAC was greatest, 9.25 mm \pm 1.76 in

males, and 8.9 mm \pm 1.38 in females. There was no significant difference in the SAC values between the sexes, Fig. 4. The spinal canal ($r^2 = .90$) accounted for more variance in the SAC values than the spinal cord ($r^2 = .35$) in both sexes.

INTERQUARTILE RANGES OF SAC VALUES IN MALES AND FEMALES

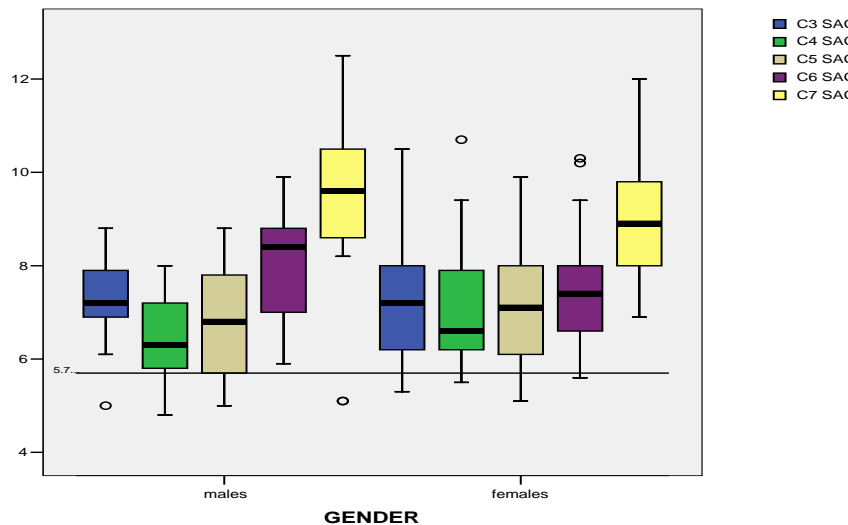


Figure 4 – Interquartile ranges of SAC data by cervical spinal level in both sexes

The relationship between the Torg ratio and the SAC was investigated using the Pearson product moment correlation coefficient. There was a stronger positive relationship ($P < .01$) between the Torg ratio and the SAC in females, ($r = .482$), than in males ($r = .338$).

SAC data < 5.7 mm (Fig. 4) in at least one vertebral level existed in 14 subjects, and in 19 (7.6%) of 250 evaluated vertebral levels, the corresponding Torg ratios at the same levels ranged from .61 to 1.16. In order to define the SAC value indicative of spinal stenosis the correspondence of all indicators of spinal stenosis was analysed at these levels. SAC values of less than 5 mm corresponded with sagittal canal diameters < 12 mm and Torg ratio $\leq .80$ at 6 levels.

Discussion

Morphometric studies of the vertebral canal reported racial and ethnic variation, apart from age and sex differences in the canal size. There was a considerable variation in the transverse diameter of the spinal canal between different races. The canal size in Indians was much smaller than that in other races [1, 5, 17]. Many authors have reported level differences in the mean sagittal osseous spinal canal diameter, as we did in our study, but our sagittal vertebral body and spinal canal diameters were 1 to 3 mm different from measurements reported in several studies. These differences are due to the fact that we used MRI in determining measurements, and some authors used radiographs or computed tomography scans [10]. Tierney et al. [19, 20] used MRI and reported average spinal canal diameter $13.28 \text{ mm} \pm 1.47$ and average sagittal vertebral body diameter $17.7 \text{ mm} \pm 2.18$. The reported average sagittal cervical canal diameter (C3–C7) by Lee [13] was 14.1 ± 1.6 mm. These results were obtained by direct measurements using cadaver specimens and men had significantly larger diameters than women at all the levels. In the study of Morishita et al. [14] the reported average sagittal canal diameter from C3 to C7 was 13.73 ± 1.37 mm. These measurements were obtained using MRI, as we used in our study, so some soft-tissue structures might have influenced these results.

Torg ratios of less than .80 on at least one vertebral level was a common finding in men

in our study. Our results suggest that gender variability between the relative dimensions of the canal and the vertebral body in the cervical spine decrease the reliability of the Torg ratio and make it a poor screening tool. In Lim's study [11], women had smaller sagittal canal diameters at all levels of the cervical spine, but men had larger vertebral bodies when compared with corresponding sagittal canal diameters which resulted in smaller Torg ratios in men. Blackley et al. [3] also reported a poor correlation between the true diameter of the canal and the ratio of its sagittal diameter to that of the vertebral body.

Anderson et al. [2], published the average spinal cord's sagittal diameter in adults as approximately 8 mm from C₃ to C₇. Tierney et al. [19] reported SAC values by cervical segments (ranging from 2.5 to 10.4 mm), at C3 and C5 the means of the SAC were the least, 5.3 mm. Individual and level differences in the SAC values were evaluated in our study as well.

Previous research reported an increased risk of recurrence of a cervical-cord neuropraxia episode in individuals with less SAC, [21, 22]. Also, Herzog et al. [10] recommended that SAC should be analysed if symptomatic athletes had a Torg ratio less than 0.80 or a sagittal spinal-canal diameter value less than 12.5 mm. SAC values of less than 5 mm were indicative of stenosis in our study. Subjects with limited space available for the spinal cord may be more susceptible to spinal cord compression with less pathological changes, such as herniated discs, osteophytic spurs, and hypertrophy of the ligamentum flavum or facet joints. Morishita et al. [14] suggested that a cervical spinal canal diameter of less than 13 mm may be associated with an increased risk of development of pathological changes in cervical intervertebral discs. Okada et al. [15] identified no factor related to progression of degeneration of cervical spine except for age. Progression of anterior compression of dura and spinal cord with ageing was evaluated in this study, results that indicate the trend of progressive decrease in the space available for the spinal cord with aging. Boden et al. [4] interpreted MR scans of the cervical spine in asymptomatic subjects; 28 percent of those who were older than forty demonstrated

abnormalities of the cervical spine, compared with 14 percent of those who were less than forty. The limitation of our study was the small number of subjects included. The head position of the subjects should be standardized as neutral because this affects the spinal cord's size [6, 20]. A stronger positive relationship between the Torg ratio and SAC was found in females, although this relationship could be stronger because the spinal canal is a component of both measures. Critical SAC values may predict development of significant stenosis or may indicate an increased risk of neurological injury. This is especially important for prevention and counselling on the possible risks for athletes or people with occupations that expose individuals to a greater risk of traumatic injury of the cervical spine. The size of the cervical spinal canal and its space available for the cord is clinically important to decide on the therapeutic treatment in traumatic, degenerative, and inflammatory conditions of the cervical spine.

Conclusions

MR imaging can provide more accurate cervical canal and cord measurements that could serve as morphometric determinants of cervical canal stenosis. The Torg ratio used in evaluation of spinal canal stenosis on plain x-ray radiographs of the cervical spine cannot be used as a spinal canal stenosis indicator on MRI images of the cervical spine. The gender variability in the anatomical morphology of the cervical spine limit the Torg ratio's value as an indicator of spinal stenosis, or result in overdiagnosis of stenosis in males. The Torg ratio relied more on the vertebral bodies than on the spinal canal. Sagittal canal diameters were more spread out in males than in females. Not gender, but individual and level differences in the SAC values were evident (cervical cord enlargement). SAC values relied more on the spinal canal than on the spinal cord, so that the differences in the spinal cord's dimensions accounted for less variability in the SAC values.

REFERENCES

1. Amonoo-Kuofi HS, Patel PJ, Fatani JA. Transverse diameter of the lumbar spinal canal in normal adult Saudis. *Acta Anat.* 1990; 137: 124–8.
2. Anderson PA, Steinmetz MP, Eck JC. Head and neck injuries in athletes. In: Spivak JM, Connolly PJ (eds) *Orthopaedic Knowledge Update, Spine.* 3 2006; AAOS 28: 259–69.
3. Blackley HR, Plank RD, Robertson PA. Determining the sagittal dimensions of the canal of the cervical spine. *J Bone Joint Surg Br.* 1999; 81(1): 110–2.
4. Boden SD, McCowin PR, Davis DO, et al. Abnormal magnetic-resonance scans of the cervical spine in asymptomatic subjects. A prospective investigation. *J Bone Joint Surg Am.* 1990; 72: 1178–84.
5. Chhabra S, Gopinathan K, Chibber SR. Transverse diameter of the lumbar vertebral canal in north Indians. *Anat.* 1991; 41 (1): 25–32.
6. De Lorenzo RA, Olson JE, Boska M, et al. Optimal positioning for cervical immobilization. *Ann Emerg Med.* 1996; 28: 301–8.
7. Edwards WC, LaRocca. The developmental segmental sagittal diameter of the cervical spinal canal in patients with cervical spondylosis. *Spine.* 1983; 8: 20–7.
8. Gore DR. Roentgenographic findings in the cervical spine in asymptomatic persons: a ten-year follow-up. *Spine.* 2001; 26: 2463–6.
9. Hayashi H, Okada K, Hamada M, Tada K, Ueno R. Etiologic factors of myelopathy: a radiographic evaluation of the aging changes in the cervical spine. *Clin Orthop Relat Res.* 1997; 214: 200–9.
10. Herzog RJ, Wiens JJ, Dillingham MF, Sontag MJ. Normal cervical spine morphometry and cervical spinal stenosis in asymptomatic professional football players: plain film radiography, multiplanar computed tomography, and magnetic resonance imaging. *Spine.* 1991; 16(suppl): 178–86.
11. Jit-Kheng Lim, Hee-Kit Wong. Variations of the Cervical Spinal Torg Ratio with Gender and Ethnicity. *The Spine Journal.* 2004; 4: 396–401.
12. Kameyama T, Hashizume Y, Ando T, Takahashi A. Morphometry of the normal cadaveric cervical spinal cord. *Spine.* 1994; 19: 2077–81.
13. Lee MJ, Cassinelli EH, Riew KD. Prevalence of cervical spine stenosis: anatomic study in cadavers. *J Bone Joint Surg Am.* 2007; 89: 376–80.
14. Morishita Y, Naito M, Hymanson H, Miyazaki M, Wu G, Wang C. J. The relationship between the cervical spinal canal diameter and the pathological changes in the cervical spine. *Eur Spine J.* 2009; 18: 877–83.
15. Okada E, Matsumoto M, Ichihara D, et al. Aging of cervical spine in healthy volunteers: a 10-year longitudinal magnetic resonance imaging study. *Spine.* 2009; 34(7): 706–12.
16. Pavlov H, Torg JS, Robie B, Jahre. Cervical spinal stenosis: determination with vertebral body ratio method. *Radiology.* 1987; 164: 771–7.
17. Rema Devi, N Rajagopalan. Dimensions of the lumbar vertebral canal. *Indian Journal of Orthopaedics.* 2003; 37: 13.
18. Ros L, Mota J, Guedea A, Bidgood D. Quantitative measurements of the spinal cord and canal by MR imaging and myelography. *Eur Radiol.* 1998; 8: 966–70.
19. Tierney TR, Maldjian C, Mattacola GC, Straub JS, Sitler RM. Cervical Spine Stenosis Measures in Normal Subjects. *Athl Train.* 2002; 37(2): 190–3.

20. Tierney RT, Mattacola CG, Sitler MR, Maldjian C. Head position and football equipment influence cervical spinal-cord space during immobilization. *J Athl Train.* 2002; 37: 185–9.
21. Torg JS, Corcoran TA, Thibault LE, et al. Cervical cord neurapraxia: classification, pathomechanics, morbidity, and management guidelines. *J Neurosurg.* 1987; 87: 843–50.
22. Torg JS, Pavlov H, Genuario SE, et al. Neurapraxia of the cervical spinal cord with transient quadriplegia. *J Bone Joint Surg Am.* 1986; 68: 1354–70.

Резиме

МОРФОМЕТРИСКА АНАЛИЗА НА ВРАТНИОТ 'РБЕТЕН КАНАЛ СО МАГНЕТНА РЕЗОНАНЦА

Ники Матвеева¹, Петар Јаневски²,
Наташа Накева¹, Јулија Живадиновиќ¹,
Аце Додевски¹

¹ Институт за анатомија, Медицински факултет,
Универзитет „Св. Кирил и Методиј“,
Скопје, Р. Македонија

² Институт за радиологија, Медицински факултет,
Универзитет „Св. Кирил и Методиј“,
Скопје, Р. Македонија

Две корисни нумерички вредности, Торгов сооднос и сагитален дијаметар на 'рбетниот канал, се широко прифатени како веродостојни морфометриски параметри за дијагноза на стеноза на 'рбетниот канал. Целта на оваа студија беше да се испитаат морфометриските детерминанти на вратниот 'рбетен канал како веродостојни индикатори за

канална стеноза кај обата пола со помош на магнетна резонанца. Мерењата беа направени на 50 МР снимки на вратниот 'рбетен столб (сагитална T₂ пулс секвенца) од пациенти во Ургентниот центар кои биле упатени на МР снимање на вратниот 'рбет поради различни дијагностички индикации. Торговиот сооднос користен за евалуација на канална стеноза на нативни рентген снимки на вратниот 'рбет не може да се користи како валиден индикатор за канална стеноза заради половите разлики во големината на прешленските тела. Опсегот на вредности на сагиталниот дијаметар на вратниот 'рбетен канал кај мажите беше поголем отколку кај жените. Магнетната резонанца овозможува просторот достапен на 'рбетниот мозок (ПРМ) да биде детерминиран, како разлика меѓу сагиталниот дијаметар на 'рбетниот канал и сагиталниот дијаметар на 'рбетниот мозок. Евидентни беа индивидуалните и сегментални разлики, а не половите во вредностите на овој параметар (цервикална интумесценција на 'рбетниот мозок). Вредностите на просторот достапен на 'рбетниот мозок се должат повеќе на големината на 'рбетниот канал отколку на 'рбетниот мозок, така што разликите во големината на 'рбетниот мозок помалку придонесуваат за варијабилноста на овој простор. Магнетната резонанца обезбедува поточни мерења на 'рбетниот канал и 'рбетниот мозок кои може да служат како морфометриски детерминанти на вратната спинална стеноза.

Клучни зборови: морфометрија, 'рбетен канал, 'рбетен мозок, магнетна резонанца.