

Available online at [www.sciencedirect.com](http://www.sciencedirect.com)
**ScienceDirect**
journal homepage: [www.elsevier.com/locate/radcr](http://www.elsevier.com/locate/radcr)

## Case report

# Incarcerated multiple recurrent inguinal hernia with incidental finding of textiloma in the abdominal wall from previous hernia repair

Andrej Nikolovski, MD, Ph.D<sup>a,\*</sup>, Shqipe Misimi, Student of General Medicine<sup>b</sup>,  
Edita Minova, MD<sup>c</sup>

<sup>a</sup> Department of Visceral Surgery, University Clinic of Surgery “Sv. Naum Ohridski”, Bul. 11 Oktomvri 53, Skopje 1000, North Macedonia

<sup>b</sup> Medical Faculty Skopje, University, Skopje, North Macedonia

<sup>c</sup> General Hospital, Kocani, North Macedonia

## ARTICLE INFO

### Article history:

Received 26 December 2021

Accepted 1 January 2022

### Keywords:

Inguinal hernia

Recurrence

Incarceration

Textiloma

Hernia classification

## ABSTRACT

Multiple recurrent inguinal hernia is a diagnostic and surgical challenge. In terms of additional incarceration of the recurrent hernia, few options for the surgeon are available. We present a case of multiple recurrent left sided inguinal hernia in female patient presented with clinical signs of mechanical bowel obstruction. Preoperative computed tomography of the abdomen presented the hernia defect and also revealed the presence of textiloma in the abdominal wall from previous hernia repair. Intraoperatively there were no signs of bowel ischemia. Hernia defect was closed with resorbable mesh (bridging “in – lay” repair). Postoperative surgical site infection of the wound occurred. Patient was discharged from hospital on day 17.

© 2022 The Authors. Published by Elsevier Inc. on behalf of University of Washington.

This is an open access article under the CC BY-NC-ND license

(<http://creativecommons.org/licenses/by-nc-nd/4.0/>)

## Introduction

The recurrence rate after groin hernia repair in the pre-mesh era is reported to be as high as 30% and the rate for recurrent hernia repairs was 35% [1]. New data on recurrence rate for inguinal hernia repair, regardless of the used technique, in large national registers is reported to be between 4.3% and 11.7 % [2–4]. Proposed etiology factors for inguinal hernia recurrence are: experience of the surgeon, infection, tension, su-

turing material and technique and the patients’ general condition [5].

## Case presentation

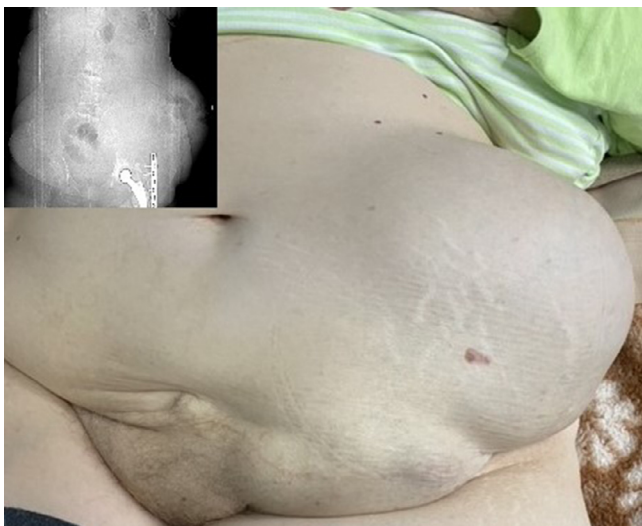A 79 years old female patient was admitted in our hospital with large left sided multiple recurrent incarcerated inguinal hernia, accompanied with diffuse abdominal pain, vomiting

\* Corresponding author. A. Nikolovski.

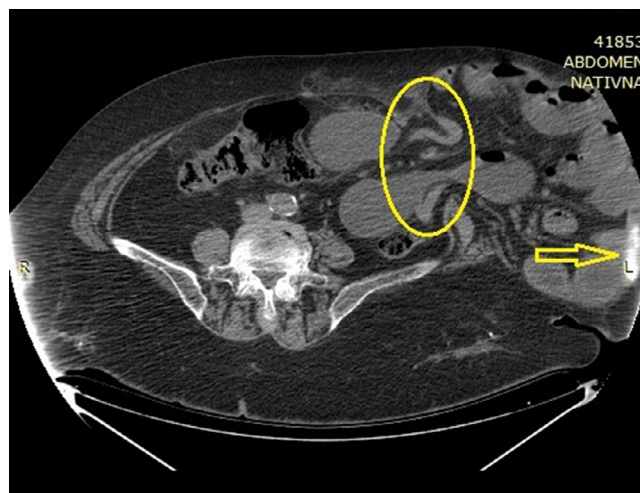
E-mail address: [andrejn Nikolovski05@gmail.com](mailto:andrejn Nikolovski05@gmail.com) (A. Nikolovski).

<https://doi.org/10.1016/j.radcr.2022.01.001>

1930-0433/© 2022 The Authors. Published by Elsevier Inc. on behalf of University of Washington. This is an open access article under the CC BY-NC-ND license (<http://creativecommons.org/licenses/by-nc-nd/4.0/>)



**Fig. 1 – Clinical presentation of the patient in supine position with CT – topogram (insertion).**



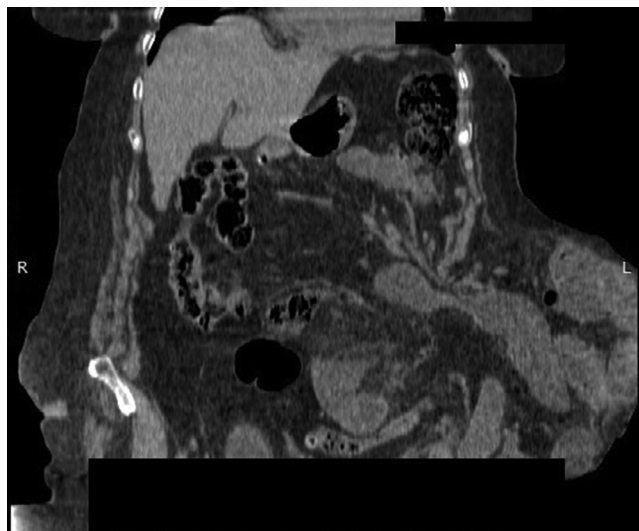
**Fig. 2 – Axial CT scan of the abdomen demonstrates hernia sac with incarcerated intestinal loops and signs of mechanical obstruction. The hernia defect shows intestinal incarceration (yellow ellipse). Calcified foreign body is visible in the abdominal wall (yellow arrow).**

and absence of flatulence. Previous anamnestic history (no medical data available) related to surgical interventions included surgery for uterine suspension, open cholecystectomy, 2 orthopedic interventions on the left hip and 3 operations for left sided hernia repair with mesh. Complete laboratory blood test and computed tomography (CT) were performed. The laboratory results showed leucocyte levels of  $13.0 (3.5-10.0 \times 10^9/L)$ , thrombocyte levels of  $456 (150.0-390.0 \times 10^9/L)$ , neutrophil levels of  $10.2 (2.0-8.0 \times 10^9/L)$ , serum glucose levels of  $6.0 (3.9-5.8 \text{ mmol/L})$ , C reactive protein (CRP) of  $19.20 (0.0-5.0 \text{ mg/L})$ , serum creatinine level of  $108.10 (50.0-98.0 \text{ mmol/L})$ , chlorides  $107.6 (98-107 \text{ mmol/L})$ .

The hernia on inspection presented as left lumbar hernia (Fig. 1). Computed tomography (native series) revealed hernia sac on the left side of the anterior-lateral abdominal wall with present incarcerated intestinal loops with signs of small bowel obstruction and a small amount of free intra-abdominal fluid. The hernia neck with present inguinal eventration was measured to be with dimensions of 72 mm. The hernia sac itself was measured to be: anterior-posterior diameter of 196 mm, lateral-lateral diameter of 170 mm and cranial-caudal diameter of 230 mm. Incidental finding of a present foreign body (possible textiloma) in the abdominal wall was noted (Figs 2 and 3).

Indication for emergency surgery was set. Intraoperatively, the incarcerated small intestine was without signs of bowel ischemia. Hernia defect was closed with the use of polyglactin 910 mesh. No attempt for removal of the previously implanted mesh was performed (Fig. 4). The presence of foreign body (textiloma) in the abdominal wall was proved and it was removed (Fig. 5).

In the postoperative period the intestinal function was established and oral feeding was started. Superficial surgical site infection (SSI) of the operative wound occurred and was treated with local wound care on routine daily basis. The patient was discharged from hospital on postoperative day 17.

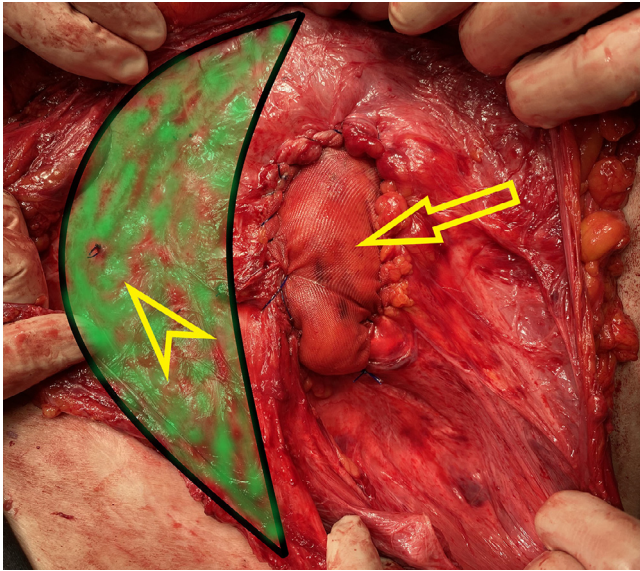


**Fig. 3 – Coronal CT scan of the abdomen presenting the inguinal eventration.**

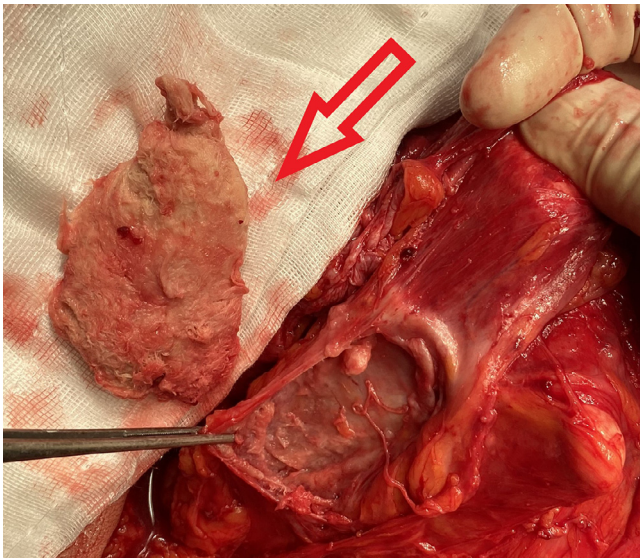
## Discussion

Different hernia classification systems include recurrent inguinal hernias (EHS, Aachen) [6,7]. The only published classification and approach proposed for inguinal hernia recurrence is the one of Campanelli [8]. According to his classification, our case presented as R3 type of inguinal hernia recurrence (multi recurrent non-reducible hernia, with big defect >2 cm and inguinal eventration).

Although, rarely needed for inguinal hernia diagnosis [9], the CT of the abdomen proves its diagnostic value in the detection of the hernia defect and its dimensions. In our case,



**Fig. 4 – Intraoperative finding with previously implanted mesh (highlighted in green) with visible knot (yellow arrowhead). Polyglactin 910 mesh in position of the hernia defect (yellow arrow).**



**Fig. 5 – Removed textiloma from the abdominal wall (red arrow).**

the presence of recurrent incarcerated hernia was clinically evident. However, it was impossible to detect the hernia defect on physical examination due to the moment of incarceration.

The proper treatment for multiple recurrent incarcerated inguinal hernia is challenging [10]. Campanelli proposes the preperitoneal Stoppa operation, Wantz technique for unilateral inguinal recurrence or the laparoscopic approach [8]. Because of the lack of standard treatment for incarcerated recurrent inguinal hernia repair, there is various heterogeneity of the reported cases [11–13]. One should have in mind that the choice of treatment for incarcerated inguinal hernia should

be fit to the patient- and hernia-related factors, the surgical skills, the available type of mesh and surgical equipment [14].

In our case, laparoscopy was not reliable option due to the surgeons' experience level in this type of surgical entity and priority was given to the anterior approach. The anatomic landmarks of the inguinal canal in case of multiple previous hernia repairs are often unrecognizable, therefore the “gold standard” Lichtenstein procedure was unfeasible. The hernia defect was closed with bridging mesh implantation (“in lay” repair). Contact between the mesh and the intestines was inevitable and the use of resorbable mesh was forced.

### Declaration of Competing Interest

The authors have declared that no competing interests exist.

### Patient consent

An informed consent was obtained from the patient.

### Supplementary materials

Supplementary material associated with this article can be found, in the online version, at doi:[10.1016/j.radcr.2022.01.001](https://doi.org/10.1016/j.radcr.2022.01.001).

### REFERENCES

- [1] Schumpelick V, Treutner KH, Arlt G. Inguinal hernia repair in adults. *Lancet* 1994;344(8919):375–9.
- [2] Köckerling F. Data and outcome of inguinal hernia repair in hernia registers - a review of the literature. *Innov Surg Sci* 2017;2(2):69–79.
- [3] Maneck M, Köckerling F, Fahlenbrach C, Heidecke CD, Heller G, Meyer HJ, et al. Hospital volume and outcome in inguinal hernia repair: analysis of routine data of 133,449 patients. *Hernia* 2020;24(4):747–57.
- [4] Han SR, Kim HJ, Kim NH, Shin S, Yoo RN, Kim G, et al. Inguinal hernia surgery in Korea: nationwide data from 2007-2015. *Ann Surg Treat Res* 2019;97(1):41–7.
- [5] Gopal SV, Warriar A. Recurrence after groin hernia repair-revisited. *Int J Surg* 2013;11(5):374–7.
- [6] Miserez M, Alexandre JH, Campanelli G, Corcione F, Cuccurullo D, Pascual MH, et al. The European hernia society groin hernia classification: simple and easy to remember. *Hernia* 2007;11(2):113–16.
- [7] Schumpelick V, Treutner KH, Arlt G. Klassifikation von Inguinalhernien [Classification of inguinal hernias]. *Chirurg* 1994;65(10):877–9.
- [8] Campanelli G, Pettinari D, Cavalli M, Avesani EC. Inguinal hernia recurrence: classification and approach. *J Minim Access Surg* 2006;2(3):147–50.
- [9] HerniaSurge Group. International guidelines for groin hernia management. *Hernia*. 2018;22(1):1-165.
- [10] Burcharth J. The epidemiology and risk factors for recurrence after inguinal hernia surgery. *Dan Med J* 2014;61(5):B4846.

- 
- [11] Ooe Y, Horikawa N, Miyanaga S, Kobiyama R, Iida Y, Kanamoto A, et al. Management of an obstructed recurrent inguinal hernia using a hybrid method: a case report. *BMC Surg* 2021;21(1):48.
- [12] McLellan J, Mir ZM, Di Lena M, Nanji S, Beiko D. Case - Recurrent incarcerated inguinal bladder hernia with small bowel obstruction. *Can Urol Assoc J* 2019;13(11):E382–4.
- [13] Merali N, Verma A, Davies T. An innovative repair for a re-recurrence of an incarcerated inguinal hernia. *Ann R Coll Surg Engl* 2014;96(8):e18–19.
- [14] . International guidelines for groin hernia management, 22. *Hernia*; 2018. p. 1–165.