

Evaluation of Soft Tissue Defects' Reconstruction Using Flaps or Skin Grafts

Elizabeta Mirchevska¹, Igor Peev¹, Margarita Peneva¹, Boro Dzonov¹, Marija Marchevska², Vladimir Mirchevski³

¹Clinic for Plastic and Reconstructive Surgery, Faculty of Medicine, University "Ss Kiril and Metodij", Skopje, Republic of Macedonia; ²Clinic for Anesthesiology and Reanimation with Intensive Care, Faculty of Medicine, University "Ss Kiril and Metodij", Skopje, Republic of Macedonia; ³Clinic for Neurosurgery, Faculty of Medicine, University "Ss Kiril and Metodij", Skopje, Republic of Macedonia

Abstract

Key words:

defect; skin graft; flap; plastic surgery; skin.

Correspondence:

Mirchevska Elizabeta, MD
Clinic for Plastic and Reconstructive Surgery, Faculty of Medicine, University "Ss Kiril and Metodij",
Skopje, Republic of Macedonia
E-mail: elizabetamircevska@yahoo.com

Received: 19-Apr-2009

Revised: 20-Aug-2009

Accepted: 20-Aug-2009

Online first: 07-Sep-2009

Background. Removal of damaged tissue and organs followed by replacement with appropriate substitutes was a long-lasting tendency since the ancient times. Skin defects of any aetiology, can be replaced either with skin grafts or flaps. Skin graft or skin transplant is a skin patch completely detached out of a donor site, having no blood vessels to nourish, neither nerve supply to innervate. Its survival, in general, depends on the quality and vascularisation of the recipient site. On the other hand, skin flap refers to a tissue segment that covers the defect, but in the contrary to the skin graft, keeps its original blood supply.

Aim. The aim of this study was to evaluate both reconstructive methods (replaced either with skin grafts or flaps) in two distinct periods – within 7 – 10 days and secondly, about 30th day after surgery.

Material and Methods. This study comprises 1512 patients with soft tissue defects, treated on Clinic for Plastic and Reconstructive Surgery in period of 6 years (2001 -2007). Patients are divided in two groups. First group that consists of 774 patients was treated with skin flaps. In the second group that consists of 738 patients, skin grafts were utilized.

Results. We compared the two groups in several parameters: colour, elevation/depression of the flap/graft, sensibility, aesthetic outcome and duration of patients' hospitalization. The results are presented.

Conclusion. As conclusion, it can be pointed out, that skin flaps are preferable and first method of choice when covering skin defects regarding the better results in all criteria that were estimated and compared.

Introduction

Replacement of the damaged tissue and organs after their removal with healthy ones, was considered as eternal longing for many generations since the early past in antic centuries. Skin defects following after trauma, thermal injury, pathologic processes and other reasons, could be covered both by skin flaps or free skin grafts (transplants). Skin transplant refers to complete detachment of skin slice from the donor site with absolute interruption of the blood vessel and nerves and its placement on the

surface of the recipient site in order to be incorporated on the new location resulting in coverage of the soft tissue defect. Survival of the graft, totally depends on quality of the blood supply of the recipient site. Revascularization of the grafts, seems to develop through one or combination of the following three processes:

- direct reconnection between blood vessels of the recipient site and the ones from the skin graft, so called "inoculation";

- growth of recipient blood vessels into endothelial channels of the transplant – so called “ingrowth”;
- infiltration of the recipient site blood vessels into lying site of the graft and formation of new endothelial channels – so called “penetration” (1-3).

Conditions that determinate the success of acceptance and survival of the grafts are: qualitative and clean wound bed with good vascularisation and innervation, absence of infection and immobility of attached graft to the base of the recipient site. There are several classifications concerning grafts' characteristics, but the one that involves the grafts' thickness and anatomical level of harvesting is found to be most prominent. We defer split- thickness grafts and full- thickness grafts. Split - thickness grafts are composed of epidermis and a layer of dermis. They can be thin (according to Thiersch) with average thickness of 0.25-0.30 mm, intermediate (according to Blair) with average thickness of 0.40 -0.45 mm and thick (three - quarters) of about 0.55 -0.60 mm thickness. Full-thickness grafts include epidermis and whole dermis in their integrity and their average thickness is about 1 mm (3-6).

While surviving and healing, a skin graft passes through 4 phases of complete acceptance on the recipient site: phase of vascularisation, which lasts from 2nd till 8th day; phase of stabilization which comprises complete attachment to the base of the recipient site and ends in about 30 days after skin graft application ; phase of reinnervation which begins in 2nd month with monthly or even yearly duration and finally, phase of protective function comprising skin ability to protect from and resist to external and harmful influences, which ends after complete and qualitative reinnervation of the transplant.

Despite free skin grafts, for covering soft tissue defects we can apply coetaneous flaps as well. A flap refers to tissue segment that is displaced from its original site (so called donor site or secondary defect) in order to cover the defect (recipient site or primary defect), but on a contrary to grafts, keeps its own vascularisation. The flap could contain dermis, sup dermal tissue, fascia, muscle, tendon, bones, nerves and blood vessels. Furthermore, when applying flap surgery, several basic principles must be considered in order to prevent possible complications, some of them with catastrophic consequences (5). The principles are:

1. Change similar with similar. When defect is

under reconstruction we tend to camouflage it as much as possible; for example, applying skin flap that has similar characteristics with the normal skin surrounding the defect.

2. Reconstruction always depends on division of the human body into regions (head, neck, torso, extremities) and always keep that in mind while reconstructing.
3. Always make the plan of reconstruction in advance and have another as alternative.
4. “Still from Peter, give to Paul”, means: to take from one site and to give to another, when possible. Keep in mind the suture tension which underestimated, can lead to flap necrosis.
5. Never forget to treat the donor site equally as the recipient site.

Flaps are accepted from the new site due to reestablishment of the circulation between them. It takes about 4 weeks, novel homeostasis to be arranged. Chronologically, happening changes progress as following:

- first 24 hours, due to decreased arterial blood-flow and subsequent dilatation of the arterioles and capillaries, congestion and oedema are clinically evident ;
- in next 1-3 days, number of small – vessel anastomosis between the flap and the recipient site rapidly increases as well as the number of the blood vessels in the flap's base.
- till the end of first week, there is reorientation of the blood vessels in longitudinal axis of the flap; furthermore previous established anastomosis start to function significantly.

There are many different types of flaps. They can be classified according to:

- Donor site
 - local flaps (advancement, rotation, transposition, bipendicular, rhomboid, “V”, “Z”, “W”, bilobular flaps e.t.c)
 - distant flaps (crossed, tubular, cylindrical, jumping flaps e.t.c.)
- Blood supply
 - flaps with random blood supply
 - flaps with axial blood supply

- flaps with arterial or venous blood supply
- island flaps
- free micro-vascular flaps
- Composition
 - coetaneous, fascio-cutaneous, mio-cutaneous,
 - osteo-facio-cutaneous, osteo-facio-mio-cutaneous
 - compound, complex flaps (4-9).

The aim of this study was to evaluate both reconstructive methods in two distinct periods – within 7 – 10 days and secondly, about 30th day after surgery. Skin colour, skin appearance, skin level in comparison to surrounding normal skin, skin sensibility and aesthetic effect were subjects of assessment.

Material and Methods

This is a retrospective – prospective analytic study. It involves 1512 patients treated on our Clinic in six-year period (2001 -2007), due to any reason that indicated utilization of defect closure techniques. Inclusion criteria were soft tissue defects of any reason that could not be directly closed. Patients with defects that were directly closed and patients with defects that were left to heal by second intention were excluded from the study. Each patient was followed-up within 6 months after surgery. Patients were divided in two major groups depending on clinical per operative findings: first group which included 774 patients where skin grafting was used and second group which included 738 patients treated

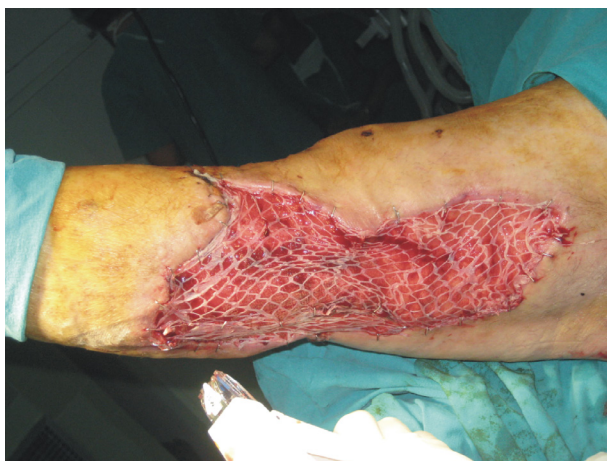

Figure 1: Defect closure of crural region with skin graft (mesh graft).

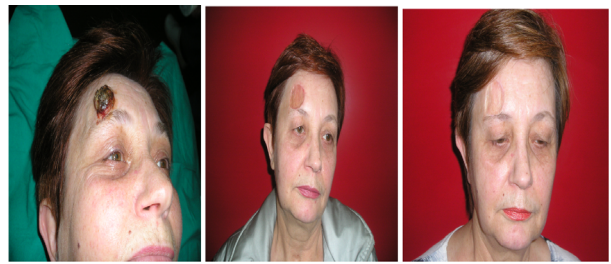

Figure 2: Soft tissue defect on the face, after radical skin cancer removal, solved with skin grafting. From left to right: before operation, one month after operation, a year after operation.

with flap surgery. Patients were in age range of 16 – 70 years. Skin defects were consequences of combustions, injuries, sequels of injuries, tumour removal and other reasons. Patients are divided into groups according to sex, region where the primary defect is and duration of hospital admittance.

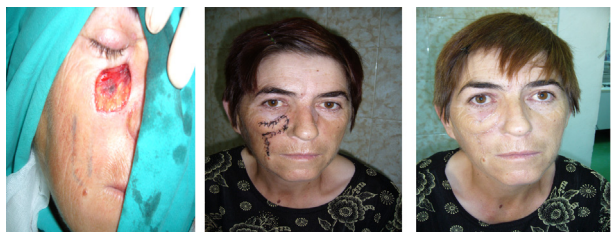

Figure 3: Defect closure after radical skin cancer removal on the face, solved with local transposition flap. From left to right: Intraoperative view, one week after operation, a month after operation.

Skin grafts used in the first group were split thickness skin grafts sec. Thiersch (thin skin grafts with average thickness of 0.25 – 0.30 mm) and split thickness skin grafts sec. Blair (intermediate skin grafts with average thickness of 0.40 – 0.45 mm).

Flap techniques applied in the second group were random flaps and composite fascio –cutaneous and fascio –mio – cutaneous flaps. Advancement flaps were considered as direct closure with undermining and were used to close smaller soft tissue defects, thus were not counted in this group or in the study at all.

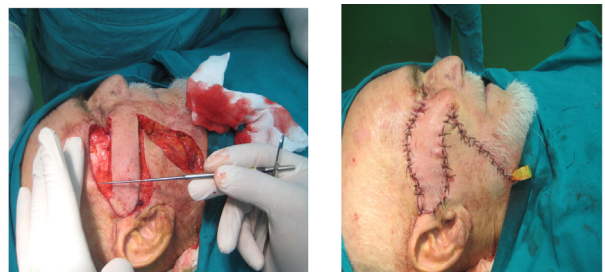


Figure 4: Defect closure after radical skin cancer removal on the face, solved with local skin transposition flap, width length ratio 1:4.

The results of both reconstructive methods were evaluated in two distinct periods – within 7 – 10 days and secondly, about 30th day after surgery. Skin colour, skin appearance, skin level in comparison to surrounding normal skin, skin sensibility and aesthetic effect were subjects of assessment.

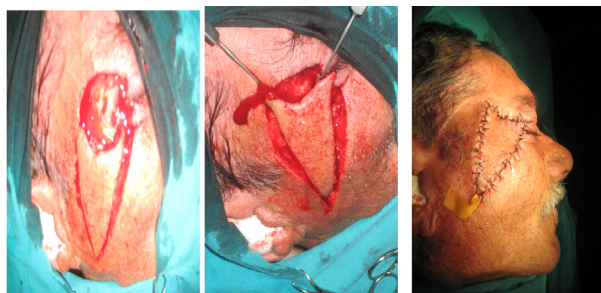

Figure 3: Defect closure after radical skin cancer removal on the mid face, treated with local "V-Y" flap.

Results

As seen in the Table 1, men dominate in both groups.

Table 1: Gender distribution in two investigated groups.

First group			Second group		
Males	Females	TOTAL	Males	Females	TOTAL
528 (68%)	246 (32%)	774	493 (67%)	245 (33%)	738

Distribution of the defects regarding body regions, as shown in Table 2, point out that most of the defects were located on head and neck, followed by the defects of extremities in number.

Table 2: Distribution of the defects regarding body regions.

Region	First group	Second group	Total
Head and neck	583	512	1095
Trunk	122	109	231
Limbs	69	117	186

Average hospitalization is longer in the first group; skin grafts need more time to be accepted by the recipient site.

Skin colour of the flaps is almost the same as the skin colour of the surrounding skin. No skin depression present and sensibility is satisfactory. Flaps that were used, regarding their frequency, is shown in Table 3.

Table 3: Frequency and types of used flaps.

Type of flaps	Number of patients
"Z", "V-Y", "W"	77
Transposition	314
Rotation	347
Bipedicular	7
Distant	16
Fasciocutaneous	10
Adiposofascial	3

In skin grafts, there is skin discoloration comparing to neighbouring skin, evident level depression and lack of sensibility. Better aesthetic effect is achieved in second group.

Accompanying flap surgery complications are partial or total necrosis, haematomas, seroma, wound opening and infection out of which total flap necrosis is most devastating. We advocate partial necrosis in 12 cases (1.62%), wound opening in 7 cases (0.95%), infection in 19 cases (2.57%) and haematoma in 14 cases (1.89%).

Table 4: Frequency and types of complications in two investigated groups.

Complications in first group (grafting)		Complications in second group (flaps)	
Partial necrosis	39 (5.04%)	Partial necrosis	12 (1.62%)
Total necrosis	4 (0.52%)	Wound disjunctions	7 (0.95%)
Infections	9 (1.16%)	Infections	19 (2.57%)
		Haemathoma	14 (1.89%)
TOTAL	52 (6.72%)	TOTAL	52 (7.03%)

Complications in skin grafting are partial or total graft necrosis and infection. In this group, we found partial necrosis in 39 cases (5.04%), total necrosis in 4 cases (0.52%) and infection in 9 cases (1.16%).

Discussion

Taking the above-mentioned in consideration, we can point out the fact that introduction of the skin flaps is a crucial moment in skin defects closure. First of all, distinction of flap and graft definition must be made as they belong to two different reconstructive techniques (6). Furthermore, each flap should be planned and fashioned prior operation, concerning structure, size, donor site, blood supply est. When reconstructing soft tissue defect, it is imperative to use tissue, at least similar to the original. Nevertheless, patient benefit from the operation and the surgical plans of the surgeon should be adjustable to the situation and it is case sensitive (1, 2, 5, 7-9). Skin flaps can be used to cover skin defect, subcutaneous tissue, bare bone, tendon, cartilage or larger blood

vessel. On the other hand, skin grafts are applicable only and exclusively to clean, granulated wound bed. Also, long time result after grafting always actuates skin depression in comparison to the surrounding level, discoloration with Para focal skin, decreased sensibility and eventually, unacceptable aesthetic result. On a contrary, there are neither depressions, nor discolorations when flaps are utilized. Furthermore, skin sensibility is not compromised and the result from aesthetic point of view is much better. Finally, duration of hospital admittance is shorter.

Skin defects caused by any pathological disturbance are serious problem if not treated properly. There are two different ways to cover skin defects: free skin transplants and skin flaps, the second been method of choice because of the similarity with the tissue, absence of discoloration, appropriate skin sensibility and acceptable aesthetic result.

References

1. Brunicaardi FC et al. *Schwartz's Principles of Surgery*, Eight edition, McGraw-Hill Companies, Inc ; p. 432-433;1852-1826, 2005.
2. Chrysopoulo Minas T. Flaps, Classification, article available from www.emedicine.medscape.com, last updated January 11, 2008.
3. Converse JM. *Reconstructive plastic surgery*. 1977;2:3749-3763.
4. Converse JM, Mc Carthy JG. Transplantation of skin grafts and flaps.
5. Fisher J, Gingrass M. Basic principles of skin flaps. In: Georgiade GS, ed. *Georgiade Plastic, Maxillofacial and Reconstructive Surgery*. Waverly Co; 20- 22,1992.
6. Krizek TJ. Grafts and flaps. In: Ruberg RC, Smith DJ, eds. *Plastic surgery: A Core Curriculum* Louis: Mosby-Yearbook, Inc. 1994:31-64.
7. Biemer E. Duspiva W. *Reconstructive Mikrogefasschirurgie*, Springer-Verlag, Berlin, Heidelberg, New York, 1980.
8. Nezbit DR. Flaps, random Skin Flaps, article available from www.emedicine.medscape.com, last updated June 26, 2009.
9. Keith MR. Flaps, Fasciocutaneous Flaps, article available from www.emedicine.medscape.com, last updated January 27, 2009.