

Pasteurella Canis as a Cause of Soft-Tissue Infection after Dog Bite: a Case Report

Ana Kaftandzieva^{1*}, Margarita Peneva², Branka Petrovska¹, Zhaklina Cekovska¹

¹Institute of Microbiology and Parasitology, Medical Faculty, University Ss Cyril and Methodius of Skopje, Skopje, Republic of Macedonia; ²University Clinic of Plastic Surgery, Medical Faculty, University Ss Cyril and Methodius of Skopje, Skopje, Republic of Macedonia

Abstract

Citation: Kaftandzieva A, Peneva M, Petrovska B, Cekovska Z. *Pasteurella Canis* as a Cause of Soft-Tissue Infection after Dog Bite: a Case Report. Maced J Med Sci. 2013 Mar 15; 6(1):74-78. http://dx.doi.org/10.3889/MJMS.1857-5773.2013.0279.

Key words: *Pasteurella canis*; dog bite; soft-tissue infections; antimicrobial susceptibility; surgical debridement.

Correspondence: Kaftandzieva Ana, MD. Institute of Microbiology and Parasitology, Medical Faculty, Skopje, Republic of Macedonia. Ul. 50 Divizija br.6, 1000 Skopje, Republic of Macedonia. Tel: ++ 389 2 30109829. Fax: ++ 389 2 30214317. E-mail: akaftandzieva@yahoo.com

Received: 28-Jan-2013; **Accepted:** 05-Feb-2013; **Online first:** 20-Feb-2013

Copyright: © 2013 Kaftandzieva A. This is an open-access article distributed under the terms of the Creative Commons Attribution License, which permits unrestricted use, distribution, and reproduction in any medium, provided the original author and source are credited.

Competing Interests: The author have declared that no competing interests exist.

Pasteurella spp are the first organisms to consider in any patient who presents with a soft tissue infection following cat scratches, or cat or dog bites or licks. *Pasteurella canis* is most common isolate of dog bites. A case of a 55- year- old woman with symptoms of infected right leg after a dog bite was described. Microbiological examination of the wounds was performed. The collected specimen was used for Gram stain and culture. No bacteria were detected on a direct gram-stained smear from wound specimens. Both aerobic and anaerobic cultures were performed. After 24 hours, growth of smooth, greyish-white colonies was observed only on Columbia agar. Another Gram stained slide was performed from those colonies and Gram-negative coccobacilli to short rodshaped morphology with bipolar staining was observed. They demonstrate positive catalase and oxidase positive reaction. The bacterium was susceptible to all tested antimicrobial agents. Although systemic forms of *Pasteurella* are possible, cutaneous infections from animal bites is the most common presentation. Most animal-bite injuries can be treated with oral antimicrobials on an outpatient basis. This patient had been managed aggressively at the very early stage, including surgical debridement and peroral antibiotic, which most likely contributed to the absence of further complications.

Introduction

Approximately half of animal bites occur on the hands and one fourth on the forearm, arm or legs. In children younger than age 10, bites are usually around the head and neck because the child's head is near the level of the large dog's mouth. The jaws of large dogs are meant for tearing: they can exert more than 450 pounds of pressure per square inch, resulting in a crush injury that may include avulsions, lacerations, and puncture wounds [1]. Nonfatal bites still pose the risks of infection and disease. Between 5% and 60% of all bite wounds are complicated by infection. Among the various wound types, puncture wounds have the highest incidence of infection.

Zoonotic diseases are especially dangerous in immunocompromised patients. Infections related to dog bites are often polymicrobial. *Pasteurella multocida* and *Staphylococcus aureus* are the most common aerobic pathogens and *Bacteroides spp.* is the most common anaerobic pathogen causing infection from dog bites. Infected bites presenting less than 12 h after injury are particularly likely to be infected with *Pasteurella spp.*, whereas those presenting more than 24 h after the event are likely to be infected predominantly with staphylococci or anaerobes. It is important to seek a history of animal contact when *Pasteurella* is isolated [2].

Pasteurella species are small, nonmotile, gram-negative, facultative anaerobes that are primarily natural inhabitants of the oropharynx of healthy dogs and cats. These organisms can cause a variety of infections in humans (pasteurellosis), usually as a result of dog or cat bites or scratches, although licks from these animals have also been associated with infection [3, 4]. Human-to-human transmission has been documented, including transmission via close contact with colonized individuals and transmission via contaminated blood products. Vertical transmission can occur via transplacental infection, endometritis, or genital tract colonization [5]. Human infections have been reported from *P. multocida* (the most common pathogen and type species for the genus). The genus *Pasteurella* subsequently underwent taxonomic reclassification based on DNA hybridization, resulting in several subspecies of *P. multocida* and five new species, including *P. multocida subsp multocida*, *P. multocida subsp septica*, and *P. multocida subsp gallicida*; *P. canis*; *P. dagmatis*; and *P. stomatis* [6, 7]. All except *P. canis* (associated only with dogs) are associated with dogs and cats. Although systemic forms of *Pasteurella* (septicemia, arthritis, endocarditis, osteomyelitis, meningitis) are possible, cutaneous infections, frequently resulting from animal bites, is the most common presentation. Such infections are characterized by rapid onset and an intense inflammatory response, similar to group A streptococcal (*Streptococcus pyogenes*) soft tissue infections [8-10].

Case report

A 55-year-old woman presented with symptoms of infected right leg after a dog bite. The dog belonged to her employer and it has been properly vaccinated. It attacked our patient accidentally during their first contact. There has been no history of such dog behaviour previously.

Patient stated that the first symptoms, redness, swelling and pain appeared about 10-12 hours after the dog bite emphasizing that over time they became worse.

Clinical examination revealed two lacerations on the anterolateral surface of the proximal third of the right leg, one of the lacerations being near the fibular head and the other just below the knee region. The wounds were irregular in shape and had nonvital edges. The tissue between the wounds was undermined from the injury, by the dog's teeth, so both wounds were communicating. The tissue below the under the knee laceration was additionally undermined and there a tissue pocket was formed. The crural fascia was creating the bottom of both of the wounds and it was intact. The leg was painful, red, and oedematous and there was purulent drainage with odour from the wounds, especially from below the knee tissue pocket.

On the anterior surface of the proximal third of her left leg there was another laceration that showed no clinical signs of infection. It was also irregular in shape and had nonvital edges.

Clinical examination of both legs revealed no tendon, nerve nor vascular injury. All range of motion and neurological function were present. There was no evidence of conditions and past procedures that may put the patient at greater risk, such as diabetes, liver disease, immunosuppression, and splenectomy. The patient had no temperature and she was feeling well. There were no clinical signs of systemic infection.

Microbiological examination of the wounds was performed. So were standard laboratory examinations. The latter showed no irregularities.

After the wound was thoroughly washed with normal saline, removal of the necrotic tissue and drainage was performed. Afterwards a dressing was applied. Our patient was provided with analgesics and broad spectrum antibiotics (amoxicillin-clavulanate) until the results of microbiological examination were done. She was asked for examinations on daily basis.

Two days later, during the control examination, there were signs of local condition improvement. By that time the microbiological examination was ready and since the administered antibiotic therapy was satisfying we suggested the patient to proceed with it.

The next control (after 4 days) showed even greater progress (Figure 1).

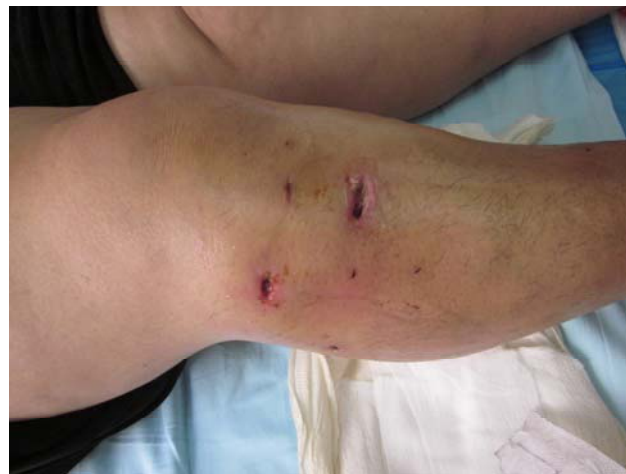

Figure 1: Wound presentation 4 days after dog-bite.

About 10 days later we were free to say that there were no more signs of soft tissue infection and the wounds were left to heal by second intention.

Microbiological examination

From two puncture wounds (which reflected the anatomy of dog's teeth) a pus was collected with a swab, put in a sterile tube and taken to the Institute of Microbiology and Parasitology, Medical Faculty in

Skopje. Blood cultures were not considered because the patient was not febrile.

The collected specimen was used for Gram stain and culture. A direct gram-stained smear from wound specimens was performed at the time of culturing, and only 5-10 leukocytes per field were observed. No bacteria were detected. Gram stain didn't correlate with culture results. Both aerobic (Columbia agar) and anaerobic cultures (Schaedler

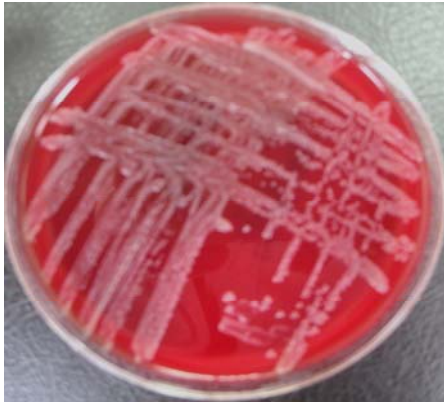

Figure 2: Culture on Columbia agar.

agar) were performed, including Sabouraud agar (for the isolation of yeasts). After 24 hours, the growth was observed only on Columbia agar. Colonies were grayish white and smooth in shape and resembled *Enterococcus* species (Figure 2). There was no evidence of biochemical activity (performing standard biochemical series- indol, methyl rot, Voges-Proskauer, citrate and urea reactions). There was also no growth on homogenic media such as UTI (Oxoid, UK). Another Gram stained slide was performed from those colonies and Gram-negative cocobacilli to short rodshaped morphology with bipolar staining was observed. *Pasteurella* spp. may be mistaken morphologically for *Neisseria* spp. or *Haemophilus influenzae* (Figure 3).

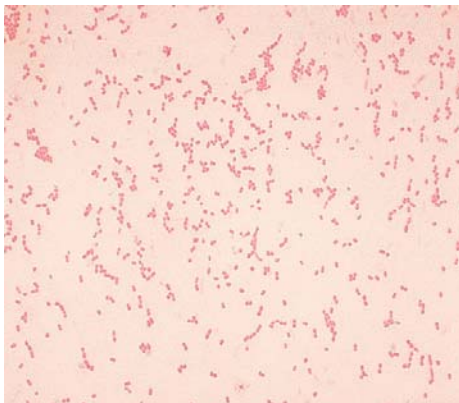


Figure 3: Gram-stained slide.

They demonstrate positive catalase reactions with formation of oxygen gas bubbles after emulsifying a fresh colony in a drop of 5% H₂O₂ on a slide-glass,

and were also oxidase positive with the paper strip (Oxoid, UK) method. Antibiotic susceptibility testing was performed on Mueller-Hinton agar and very poor growth was observed. Another susceptibility testing was performed on Columbia agar (Oxoid, UK) and the growth of greyish colonies was observed. The bacterium was susceptible to all tested antimicrobial agents (beta-lactams: amoxicillin-clavulanate, piperacillin-tazobactam, imipenem, meropenem, cefuroxime, ceftriaxone, cefotaxime, ceftazidime, cefixime, cefepime; aminoglycosides: gentamicin, amikacin; quinolones: ciprofloxacin and co-trimoxazole) (Figure 4). After 48 and 72 hours anaerobic cultures was checked if the growth of some anaerobic organisms appear. Sabouraud medium was also observed after 3 days of incubation. Neither anaerobic bacteria nor yeasts were present in both media. On anaerobic cultures only the identical colonies as on Columbia agar had grown.

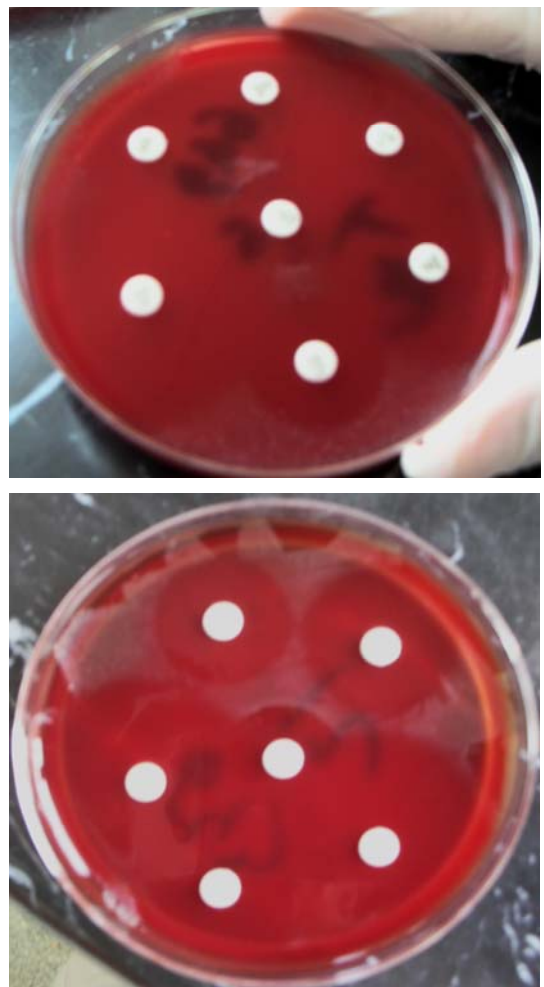

Figure 4: Susceptibility testing on Columbia agar.

Automated Vitek 2 system using GN card (bioMérieux, France) was used for exact identification of *Pasteurella* species. This card has identified the causative isolate as 96% *P. canis* with excellent identification confidence level after an incubation of 8 hours.

Discussion

Early studies suggested that the most common organisms causing dog bite infections were streptococci and staphylococci. With improvement in anaerobic culture techniques investigators realized that other organisms were more frequently implicated in infected bite wounds. In a prospective study of 107 infected dog and cat bite wounds, mixed aerobic and anaerobic bacteria were present in 56% of all wounds [11]. Thirty-six percent of the wounds demonstrated purely aerobic growth. *Pasteurella* spp. was the most common pathogen isolated from both dog and cat bites (50% and 75% respectively). *Pasteurella canis* was the most common isolate of dog bites (as in this case, infections occurred after dog bite injury on the left leg. Further history revealed the direct contact with the dog). *Pasteurella multocida* subspecies *multocida* and *septica* were the most common isolates of cat bites. The next more frequently encountered aerobic organisms were streptococci, and staphylococci. Other common organisms were *Neisseria* spp., *Corynebacterium* spp., and *Moraxella* spp. The most common anaerobic organisms isolated were *Fusobacterium* spp., *Bacteroides* spp. (in particular *B. tectum*), *Porphyromonas* spp., *Prevotella* spp., *Propionibacterium acnes*, and *Peptostreptococcus* spp. [12].

Severe human infections caused by the *Pasteurella* species are typically seen following animal bites. Septicaemia and other serious infections are only associated with the *P. multocida*. *P. canis* is a species that rarely affects humans and has never been found in systemic infections. Two reported cases, one of *P. canis* bacteremia and one of fatal *P. dagmatis* septicaemia found in the literature, suggests that serious infections can occur with other *Pasteurella* species [13, 14].

Pasteurella spp, including *P. multocida*, are usually susceptible to a number of antibiotics including penicillin G, amoxicillin-clavulanate, piperacillin-tazobactam, doxycycline, fluoroquinolones (eg, levofloxacin, moxifloxacin), advanced cephalosporins (eg, cefpodoxime, cefixime, ceftriaxone), and carbapenems (e.g., imipenem, meropenem, doripenem) [15, 16]. Current standard clinical practice does not usually include extensive susceptibility testing as *Pasteurella* spp. are thought to be widely susceptible [17]. Clinical failures have been noted in patients treated with oral macrolides (eg, erythromycin), semi-synthetic penicillins (eg, oxacillin, dicloxacillin), first-generation cephalosporins (eg, cephalothin, cephalexin, cefadroxil), and clindamycin. These agents have poor in vitro activity against *P. multocida* and should be avoided. Moreover, penicillin resistance should be considered in future evaluations of patients with *P. canis* [18-20].

Most animal-bite injuries can be treated with oral antimicrobials on an outpatient basis. Severe or partially responding infections may necessitate

hospitalization and parenteral antimicrobial administration, along with surgical intervention [21].

This patient had been managed aggressively at the very early stage, including surgical debridement and peroral antibiotic (empiric coverage with amoxicillin-clavulanate was initiated), which most likely contributed to the absence of further complications. Based on drug sensitivity test, the organism showed sensitivity towards all the antibiotics tested, including penicillin-clavulanate. Since the administered antibiotic therapy was satisfying, patient has been suggested to proceed with it in the following 10 days. The final results were very satisfying. Perhaps, immediate and prompt treatment that had been carried out prevented the spread of infection.

Pasteurella spp are the first organisms to consider in any patient who presents with a soft tissue infection following cat scratches, cat or dog bites or licks. *Pasteurella canis* is a possible cause of soft tissue infection especially following dog bite injury. Early treatment with empirical antibiotic may prevent further complication.

References

1. Shari J. Lynn. Dealing with the dangers of dog bite. American nurse today. 2009; 4(9): 52-54.
2. Dryden MS. Skin and soft tissue infection: microbiology and epidemiology. International Journal of Antimicrobial Agents. 2009; 34 (51): 52-57.
3. Chang K, Siu LK, Chen YH, et al. Fatal *Pasteurella multocida* septicemia and necrotizing fasciitis related with wound licked by a domestic dog. Scand J Infect Dis. 2007; 39:167.
4. Chun ML, Buekers TE, Sood AK, Sorosky JI. Postoperative wound infection with *Pasteurella multocida* from a pet cat. Am J Obstet Gynecol. 2003;188:1115.
5. Nakwan N, Nakwan N, Atta T, Chokeyhaibulkit K. Neonatal pasteurellosis: a review of reported cases. Arch Dis Child Fetal Neonatal Ed. 2009; 94:F373.
6. Mutters R, Ihm P, Pohl S, Frederiksen W, Mannheim W. Reclassification of the genus *Pasteurella* Treevisan 1887 on the basis of the deoxyribonucleic acid homology, with proposal for the new species *Pasteurella dagmatis*, *Pasteurella canis*, *Pasteurella stomatis*, *Pasteurella analis*, and *Pasteurella langaa*. Int J Syst Bacteriol. 1985;35:309-22.
7. Von Graevenitz, A, Zbinden, R, Mutters, R. Actinobacillus, Capnocytophaga, Eikenella, Kingella, Pasteurella, and other fastidious or rarely encountered Gram-negative rods. In: Manual of Clinical Microbiology, 9th ed, Murray, PR (Ed), American Society for Microbiology, Washington, D.C., 2007:p. 621.
8. Pomerville CJ. Animal bite diseases. 400-401 In: Alcamo's Fundamentals of Microbiology. 7th ed. Boston: Jones and Bartlett Publishers, 2004.
9. Smith AL. Pasteurella. 408-409 In: Mahon RC, Lehman CD, Manuvelis G. Textbook of Diagnostic Microbiology. Maryland: W. B. Saunders Company, 2011.
10. Akahane T, Nagata M, Matsumoto T, Murayama N, Isaka A, Kameda T, Fujita M, Oana K, Kawakami Y. A case of wound dual infection with *Pasteurella dagmatis* and *Pasteurella canis* resulting from a dog bite- limitations of Vitek-2 system in exact identification of *Pasteurella* species. Eur J Med Res. 2011; 16: 531-536.

11. Talan DA, Citron DM, Abrahamian FM, Moran GJ, Goldstein EJC. Bacteriologic analysis of infected dog and cat bites. *N Engl J Med.* 1999;340:85-92.
12. Martin Rodriguez. Bite wound infections. http://www2.massgeneral.org/id/hms/handouts20032004/martin_4_04.pdf.
13. Albert TJ, Stevens DLK. The first case of *Pasteurella canis* bacteremia: a cirrhotic patient with an open leg wound. *Infection.* 2010; 38:483-485.
14. Ashley BD, Noone M, Dwarakanath AD, Malnick H. Fatal *Pasteurella dagmatis* peritonitis and septicaemia in a patient with cirrhosis: a case report and review of the literature. *J Clin Pathol.* 2004; 57(2):210-2.
15. Goldstein EJ, Citron DM, Merriam CV, et al. Comparative in vitro activity of ertapenem and 11 other antimicrobial agents against aerobic and anaerobic pathogens isolated from skin and soft tissue animal and human bite wound infections. *J Antimicrob Chemother.* 2001; 48:641.
16. Goldstein EJ, Citron DM, Merriam CV, et al. Comparative in vitro activity of faropenem and 11 other antimicrobial agents against 405 aerobic and anaerobic pathogens isolated from skin and soft tissue infections from animal and human bites. *J Antimicrob Chemother.* 2002; 50:411.
17. Weber DJ, Wolfson JS, Swartz MN, Hooper DC. *Pasteurella multocida* infections. Report of 34 cases and review of the literature. *Medicine (Baltimore).* 1984; 63(3):133-54.
18. Stevens DL, Bisno AL, Chambers HF, et al. Practice guidelines for the diagnosis and management of skin and soft-tissue infections. *Clin Infect Dis.* 2005; 41:1373.
19. Westling K, Farra A, Cars B, et al. Cat bite wound infections: a prospective clinical and microbiological study at three emergency wards in Stockholm, Sweden. *J Infect.* 2006; 53:403.
20. American Academy of Pediatrics. *Pasteurella* infections. In *Red Book: 2009 Report of the Committee on Infectious Diseases*, 28th ed, Pickering, LK (Ed), American Academy of Pediatrics, Elk Grove Village, IL, 2009:p. 493.
21. Alexandre L, Michael G, Thomas L et al. *Pasteurella multocida* infection medication. <http://emedicine.medscape.com/article/224920-medication>, Updated January 2012.