

Significant factors in rectal cancer recurrence

Ana Lazarova

University clinic of surgery St.Naum Ohridski Skopje, Department of radiology

Abstract

INTRODUCTION

The incidence of recurrence of rectal cancer worldwide has shown a significant decline in the last ten years due to the progress of neoadjuvant preoperative chemoradiotherapy and the improvement of surgery. The recurrence rate is 4% - 8% usually in the first 3 years after surgical treatment.

AIM OF THE STUDY

This paper demonstrate the importance of the significant factors which has influence in the recurrence of rectal cancer in order to provide increase in 5-year survival rate and decrease in recurrence rate in operated patients from rectal cancer.

MATERIAL AND METHODES

This is a prospective study which include a 82 patients aged from 43 to 87 years, with an average age of 66 years with previously colonoscopy proven rectal cancer. Before the operation magnetic resonance images (MRI) was made at - 1.5 T magnet for MRI staging preoperatively. In the three years fallow up period after the operation when suspicion of local recurrence was established control MRI was done. Waited images which were made are: SAG T2 WI, AX T1WI, AX T2WI, AX DWI, and SAG and AX waited images after intra venous contrast medium administration - Gadolinium.

RESULTS

In three years fallow up period after the operation 13.4% (11) patients had a recurrence of the disease. The disease recurred in 14.6% (7) male patients, and in 11.8% (4) female patients.

The occurrence of recurrence of the disease was not significantly related to the age of the subjects ($p = 0.28$). Patients with relapse were on average insignificantly older than patients without relapse (69.6 ± 8.5 vs. 66.2 ± 9.9).

The results of the study showed that the occurrence of recurrences was significantly associated with extra mural vascular invasion (EMVI) determined pathohistologically ($p = 0.018$). With recurrence were registered 81.8% (9) patients EMVI positive and 18.2% (2) patients EMVI negative.

In the group of patients without relapse, 43.7% (31) patients were EMVI positive, 56.3% (40) were EMVI negative patients. Five from the patients with recurrence were at patohistology T3 stage and four were at T4 stage, and only two of them were at T2 stage but with positive EMVI. Depending on the nodal stages there were 14.6 % (6) patients with rectal cancer recurrence in N0 stage, 16 % (4) patients in N1 stage and one patient in N2 stage of the disease

CONCLUSION

The results of the study showed that the occurrence of recurrences of rectal cancer was significantly associated with extra mural vascular invasion determined pathohistologically ($p = 0.018$). Risk factors for local recurrence included: positive circulatory resection margins, lack of preoperative neoadjuvant treatment in advanced disease, positive extramural vascular invasion, tumor perforation during surgical treatment, tumor localized next to the anal verge.

Correspondence to: Ana Lazarova , University clinic of surgery St.Naum Ohridski Skopje, Department of radiology,
E-mail: anidinamita@gmail.com

Received date: November 11, 2020; **Accepted date:** November 24, 2020; **Published date:** December 20, 2020

Copyright: © © 2020 Ana Lazarova, This is an open-access article distributed under the terms of the Creative Commons Attribution License, which permits unrestricted use, distribution, and reproduction in any medium, provided the original author and source are credited.

INTRODUCTION

The incidence of local recurrence of rectal cancer has begun to decline in the last 10 years worldwide, due to the preoperative neoadjuvant treatment, chemo-radiotherapy before surgery in advanced stages of rectal cancer and also the improvement of surgery. The recurrence rate occurs at 4-8% of all patients usually in the first 3 years of treatment. [1]

The risk of recurrence of rectal cancer includes advanced stage (T3 and T4), without prior chemo-radiotherapy. Extra mural vascular invasion (EMVI) is an important prognostic indicator of possible recurrence of rectal cancer after surgery. [2]

It should be noted that in addition to the venous mural canals in the submucosa and muscularis propria, tumor cells may migrate and change their morphology and structure, so they become irregular, thickened, with altered signal and after contrast administration shows amplification. Although it does not directly affect the tumor stage, EMVI suggests a high-risk status of the disease. [3]

Other risk factors include tumor stage, the distance of the tumor to the anal verge, presence of EMVI, anastomotic dehiscence, and tumor perforation during surgery. In some cases, complete resection may prolong survival. [4]

In fact, the surgical risks may be unacceptably high for an advanced tumor stage and thus require radical surgery (partial sacrectomy, pelvic exenteration).

Local recurrence is most often visualized on resection margins, which may be abdominal-peritoneal, low anterior or superficial resection margins, depending on the type of surgical technique performed. [5, 6]

The tumor may also originate from the rectal wall and may be with extraluminal or intraluminal localization.

Intraluminal recurrences are less common and most commonly occur at the anastomosis line. Cancer can also develop in the pelvic organs and is classified according to localization (central, lateral-pelvic, and sacral). [7]

Central recurrence (bladder, prostate, seminal vesicles, uterus, vagina, or small intestine) is the most common and has the best prognosis. The sacrum is the rarest site for local recurrence, while the lateral pelvis has the worst survival rate. [8, 9]

Magnetic resonance imaging (MRI) is the most sensitive and specific tool in detecting local recurrence. The appearance varies depending on the histology of the primary tumor, but the lesion is mainly intermediate to high signal intensity on the T2 waited images, and shows marked post-contrast amplification. [10, 11]

If a fibrous component is present, the tumor may show hyposignal intensity, and little or no post-contrast amplification. This mainly occurs in small lesions after complications such as anastomotic likige or hemorrhage. It is difficult to distinguish tumor recurrence from post-radiation changes. [12]

Morphologically characteristics of recurrence are commonly referred to as an irregular globular mass that grows in size or changes shape over time. Central necrosis may be present. In contrast, postoperative inflammation produces soft tissue thickening with fatty tissue that disappears over time. [13]

Radiation produces early thickening of the intestinal wall, edema, and ulceration. Later changes may be strictures, fistulas, muscle atrophy. [14]

On MRI fibrosis is differentiated from relapse based on hyposignal in the T1 and T2 waited images, but an acute or subacute tumor reaction may not be distinguishable from the tumor and may persist for up to 12 months after surgery. [15]

Granulation tissue, hematoma, and radiation-induced inflammation may cause mural thickening, hypersignal in the T2 waited images, and post contrast amplification. [16]

Some authors suggest that the shape of the mass may help differentiate a tumor from fibrosis. The oval appearance favors recurrence, while flat margins suggest fibrosis. [17]

The combination of these criteria with a hypersignal in the T2 waited images and contrast enhancement over 40% is highly sensitive and specific for local recurrence.

Another criterion is annular post-contrast staining, in which the tumor presents with a central hyposignal intensity surrounded by hypersignal margins of varying thickness. [18]

Postoperative abscess may show a similar appearance. Post contrast enhancement may also occur in fibrosis, but not annular post contrast enhancement. [19] Recurrence is most commonly diagnosed by digital examination or rectosigmoidoscopy, but MRI is required for extramural spread. [20]

Although the T2 waited images is necessary for the initial staging of rectal cancer, its use is not adequate without waited images after contrast administration in the presence of local recurrence. [17]

On the T2 waited images rectal cancer recurrence is hypersignal and indistinguishable from inflammation and edema, which may persist for several months after radiotherapy and surgery. [16]

On the other hand, fibrous tissue can be displayed homogeneously, with hyposignal intensity on the T2 waited images even though it might contains micro tumor foci. This results in lower MRI sensitivity in post radio-chemotherapy MRI.

Mainly, the analyzes after the radio-chemotherapy are based with the help of DWI waited images and ADC map. [21] Intermediate signal intensity, slightly higher than that of the muscle, suggests that the tumor is active. Decreased or increased tumor signal, corresponding to the post-therapy response.

Complete disappearance of the tumor and clear visualization of the hyposignal wall of the rectum suggest a low stage of rectal cancer. Higher signal intensity than that of the surrounding mus-

cles and spread to the perirectal fat tissue is in favor of T3, or for T4 stage of rectal cancer. [15] Therefore, post-contrast sequences must be used, with post-contrast enhancement occurring early and with a much stronger signal and homogeneous compared to normal fibrosis. [20]

MATERIAL AND METHODES

This is a prospective study which includes 82 patients aged from 43 to 87 an average age of 66 with previously colonoscopy proven rectal cancer and preoperatively MRI staging was done.

All 82 operated patients were following up in three years period and when suspicion of local recurrence was established by laboratory parameters, CT scan or local examination, MRI images were done in order to confirm the possibility of local recurrence of rectal cancer after operation.

Whiles in the primary MRI staging before the operation standard T1, T2 and DWI waited images were done in the MRI examination for suspicion of local recurrences additional waited images after intra venous application of Gadolinium were required in order to differ viable tumor from fibrosis or desmoplastic reaction. Waited images which were made are: SAG T2 WI, AX T1WI, AX T2WI, AX DWI, and SAG and AX waited images after intra venous contrast medium administration - Gadolinium.

Table 1: Distribution of the patients with or without recurrence

Recurrence	n (%)
yes	11 (13.41)
no	71 (86.59)

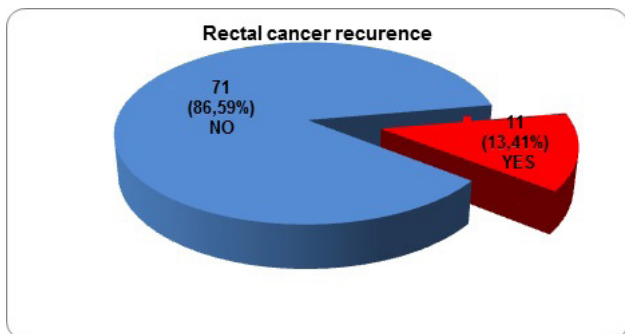


Figure 1: Graphic presentation of the patients with or without recurrence

Table 2: Rectal cancer recurrence in male and female

Recurrence	n	man	woman	p = level
yes	11	7 (14.58)	4 (11.76)	p=0.7 ns
no	71	41 (85.42)	30 (88.24)	

Chi-square=0.14 df=1 p=0.71

There was no statistical significance in rectal cancer recurrence depending on the patient's gender. There was rectal cancer recurrence in 14.6% (7) patients mail gender and 11.8% (4) patients female gender.

There was no statistical significance in rectal cancer recurrence associated with the age of the patients. (p=0.28) Patients with rectal cancer recurrence were no significantly older than the patients without rectal cancer recurrence (6.6±8.5 contrary 66.2 ±9.9).

Table 3: Age of the patients with or without rectal cancer recurrence

Recurrence	Descriptive Statistics (age)			p = level
	n	mean ± SD	range	
yes	11	69.6 ± 8.5	56 – 82	p=0.28 ns
no	75	66.2 ± 9.9	43 – 87	

Student t=1.09 p=0.28

The results of this study have shown that rectal cancer recurrence was significantly associated with patohistological extra mural vascular invasion (EMVI) (p=0.018).With rectal cancer recurrence were found 81.8 % (9) patients with positive EMVI, and 18.2% (2) patients were EMVI negative. In the group of patients without recurrence 43, 7 % (31) patients were EMVI positive, 56.3% (40) patients were EMVI negative. (Table 4)

Table 4: EMVI status in rectal cancer with or without recurrence

Recurrence	EMVI status by patohistology			p = level
	EMVI+ n (%)	EMVI- n (%)	total	
yes	9 (22.5)	2 (4.76)	11	p=0.018 sig
no	31 (77.5)	40 (95.24)	71	

Chi-square=5.55 df=1 p=0.018

Table 5: Rectal cancer recurrence with correlation of T stage

recurrence	patohistology					p = level
	n	stage 1 n (%)	stage 2 n (%)	stage3 n (%)	stage 4 n (%)	
да	11	2 (28.57)	0	5 (9.09)	4 (33.33)	p=0.048 sig
не	71	5 (71.43)	8 (100)	50 (90.91)	8 (66.67)	

Fisher exact test, two tailed, p=0.048

Table 6: Intergroup comparison of rectal cancer recurrence in correlation of T stage

	stage 2	stage 3	stage 4
stage 1	Fisher p=0.2	Fisher p=0.17	Fisher p=1.0
stage 2		Fisher p=1.0	Fisher p=0.12
stage 3			Fisher p=0.047

Positive correlation between rectal cancer recurrence was found in the T3 and T4 stage (p=0.047) Five from the patients with recurrence were at patohistology T3 stage and four were at T4 stage, and only two of them were at T2 stage but with positive EMVI.

Depending on the nodal stages there were 14.6 % (6) patients with rectal cancer recurrence in N0 stage, 16 % (4) patients in N1 stage and one patient in N2 stage of the disease. (Table 6)

Table 7: Intragroup comparison of rectal cancer recurrence depending on LGL stage

	N0	N1	N2	N3
no	Fisher p=1.0	Fisher p=1.0	Fisher p=1.0	
N0		Fisher p=1.0	Fisher p=1.0	Fisher p=1.0
N1			Fisher p=1.0	Fisher p=1.0
N2				Fisher p=1.0

DISCUSSION

As for the incidence of recurrence of rectal cancer worldwide, it shows a significant decrease in the last ten years due to the progress of neoadjuvant chemo-radiotherapy and the improvement of surgery. The recurrence rate is 4% - 8% usually in the first 3 years after surgical treatment. [22] Risk factors for local recurrence included: positive circumferential resection margins, lack of preoperative neoadjuvant treatment in advanced disease, positive extramural vascular invasion, tumor perforation during surgical treatment. [23]

Intraluminal tumor recurrences are most commonly diagnosed by digital examination if they are localized in the lower part of the rectum or by colonoscopy or rectosigmoidoscopy. [24]

Detection of tumor recurrence and differentiation of tumor recurrence from postoperative changes can only be seen by imaging methods. MRI is the most accurate imaging modality for evaluating these patients, but due to the cost of the examination is not adequate for routine controls. According to some recommendations, in some centers, computed tomography (CT) is used as the main screening method to control patients after surgical treatment of rectal cancer, while in other centers indication for MRI is established only with positive clinical or laboratory parameters. [25]

Although the T2 pulse sequence is major in the initial staging of rectal cancer, its potency is less than that of relapse detection. On the T2 pulse sequence, the local recurrence is presented as hypersensitive and difficult to distinguish from inflammation or edema, which may persist for several months after radiotherapy or surgery. On the other hand, fibrous tissue may present as homogeneous hypointense and yet contain microscopically viable tumor cells. Because of this, the most adequate waited images in the differentiation of treatment-related changes from the relapse process are the post-contrast waited images. Post contrast enhancement in tumor tissue is much more intense and occurs earlier than benign post inflammatory fibrosis. [26]

Biopsy is recommended whenever clinical findings are ambiguous and the diagnosis of tumor recurrence cannot be confirmed with certainty. Negative marginal surgical resection has been established as the most effective treatment for rectal cancer leading to greater survival and a lower rate of local recurrence of rectal cancer. [27]

Assessing local extension in adjacent structures is a challenge because pelvic fat lines are absent or non-intact after surgery or radiotherapy. Because of this, suspicion of local invasion may be raised by a change in MR signal intensity or anatomical destruction seen in adjacent tissues. Detection of sacral invasion is crucial in achieving clean posterior margins after resection. [28]

Whether radical sacral surgery will be the treatment of choice depends very much on the level of sacral involvement. In most institutions invasion above the S2-S3 level is relatively contraindicated for resection, although high sacrectomy is also practiced in some centers.

Recent studies show that colorectal surgeons rely heavily on MR findings compared to other imaging modalities to determine the convenience of negative margin resection in patients with recurrent rectal cancer. [29]

In our study, 13.4% (11) patients had a recurrence of the disease.

The results of the study showed that the occurrence of relapses was significantly associated with extra mural vascular invasion determined pathohistologically ($p = 0.018$). With recurrence were registered 81.8% (9) patients EMVI positive and 18.2% (2) patients EMVI negative. In the group of patients without relapse, 43.7% (31) patients were EMVI positive, 56.3% (40) were EMVI negative patients.

These results reaffirm the importance of extramural vascular invasion as a prognostic indicator in the development of the disease as well as an indication for appropriate and correct treatment of rectal cancer.

No statistically significant difference was found in the recurrence rate depending on the sex of the patients ($p = 0.7$). The disease recurred in 14.6% (7) male patients, and in 118% (4) female patients.

The occurrence of recurrence of the disease was not significantly related to the age of the subjects ($p = 0.28$). Patients with relapse were on average insignificantly older than patients without relapse.

CONCLUSION

The results of the study showed that the occurrence of recurrence was significantly associated with extra mural vascular invasion determined pathohistologically ($p = 0.018$).

Risk factors for local recurrence included: positive circulatory resection margins, lack of preoperative neoadjuvant treatment in advanced disease, positive extramural vascular invasion, tumor perforation during surgical treatment, tumor localized next to the anal verge.

References

1. Kapiteijn E, Marijnen CAM, Nagtegaal ID, et al. Preoperative radiotherapy combined with total mesorectal excision for resectable rectal cancer. *New England Journal of Medicine*. 2001;345(9):638-646
2. Bozzetti F, Bertario L, Rossetti C, et al. Surgical treatment of locally recurrent rectal carcinoma. *Diseases of the Colon and Rectum*. 1997;40(12):1421-1424
3. Heriot AG, Byrne CM, Lee P, et al. Extended radical resection: the choice for locally recurrent rectal cancer. *Diseases of the Colon and Rectum*. 2008;51(3):284-291
4. Kodeda K, Derwinger K, Gustavsson B, Nordgren S. Local recurrence of rectal cancer: a population based cohort study of diagnosis, treatment and outcome. *Colorectal Disease*. 2012;14(5):e230-e237

5. Salo JC, Paty PB, Guillem J, Minsky BD, Harrison LB, Cohen AM. Surgical salvage of recurrent rectal carcinoma after curative resection: a 10-year experience. *Annals of Surgical Oncology*. 1999;6(2):171-177
6. Bakx R, Visser O, Jossen J, Meijer S, Slors JFM, van Lanschot JB. Management of recurrent rectal cancer: a population based study in greater Amsterdam. *World Journal of Gastroenterology*. 2008;14(39):6018-6023
7. Camilleri-Brennan J, Steele RJC. The impact of recurrent rectal cancer on quality of life. *European Journal of Surgical Oncology*. 2001;27(4):349-353
8. Thaysen HV, Jess P, Laurberg S. Health-related quality of life after surgery for primary advanced rectal cancer and recurrent rectal cancer: a review. *Colorectal Disease*. In press
9. Yamada Y, Arao T, Matsumoto K, et al. Plasma concentrations of VCAM-1 and PAI-1: a predictive biomarker for post-operative recurrence in colorectal cancer. *Cancer Science*. 2010;101(8):1886-1890
10. Pacelli F, Tortorelli AP, Rosa F, et al. Locally recurrent rectal cancer: prognostic factors and long-term outcomes of multimodal therapy. *Annals of Surgical Oncology*. 2010;17(1):152-162
11. Bouchard P, Efron J. Management of recurrent rectal cancer. *Annals of Surgical Oncology*. 2010;17(5):1343-1356
12. Mirnezami AH, Sagar PM. Surgery for recurrent rectal cancer: technical notes and management of complications. *Techniques in Coloproctology*. 2010;14(3):209-216
13. Nielsen MB, Laurberg S, Holm T. Current management of locally recurrent rectal cancer. *Colorectal Disease*. 2011;13(7):732-742
14. Maslekar S, Sagar PM, Mavor AID, Harji D, Bruce C. Resection of recurrent rectal cancer with encasement of external iliac vessels. *Techniques in Coloproctology*. In press
15. Wiig JN, Larsen SG, Dueland S, Giercksky KE. Preoperative irradiation and surgery for local recurrence of rectal and rectosigmoid cancer. Prognostic factors with regard to survival and further local recurrence. *Colorectal Disease*. 2008;10(1):57-58
16. Moriya Y. Treatment strategy for locally recurrent rectal cancer. *Japanese Journal of Clinical Oncology*. 2006;36(3):127-131
17. Dozois EJ, Privitera A, Holubar SD, et al. High sacrectomy for locally recurrent rectal cancer: can long-term survival be achieved? *Journal of Surgical Oncology*. 2011;103(2):105-109
18. Rao SX, Zeng MS, Chen CZ, et al. The value of diffusion-weighted imaging in combination with T2-weighted imaging for rectal cancer detection. *Eur J Radiol*. 2008;65:299-303
19. Gollub MJ, Gultekin DH, Akin O, et al. Dynamic contrast enhanced-MRI for the detection of pathological complete response to neoadjuvant chemotherapy for locally advanced rectal cancer. *Eur Radiol*. 2012;22:821-831
20. Bokey EL, Chaptuis PH, Dent OF, et al. Factors affecting survival after excision of the rectum for cancer: a multivariate analysis. *Dis Colon Rectum* 1997; 40:3-10
21. Horn A, Dahl O, Morild I. Venous and neural invasion as predictors of recurrence in rectal adenocarcinoma. *Dis Colon Rectum* 1991; 34:798-804
22. Young PE, Womeldorph CM, Johnson EK, et al. Early detection of colorectal cancer recurrence in patients undergoing surgery with curative intent: current status and challenges. *J Cancer* 2014; 5:262-271
23. Krestin GP, Steinbrich W, Friedmann G. Recurrent rectal cancer: diagnosis with MR imaging versus CT. *Radiology* 1988; 168:307-311
24. Blomqvist L, Fransson P, Hindmarsh T. The pelvis after surgery and radio-chemotherapy for rectal cancer studied with Gd-DTPA-enhanced fast dynamic MR imaging. *Eur Radiol* 1998; 8:781-787
25. Glazer HS, Lee JK, Levitt RG, et al. Radiation fibrosis: differentiation from recurrent tumor by MR imaging. *Radiology* 1985; 156:721-726
26. Kinkel K, Tardivon AA, Soyer P, et al. Dynamic contrast-enhanced subtraction versus T2-weighted spin-echo MR imaging in the follow-up of colorectal neoplasm: a prospective study of 41 patients. *Radiology* 1996; 200:453-458
27. Torricelli P, Pecchi A, Luppi G, Romagnoli R. Gadolinium-enhanced MRI with dynamic evaluation in diagnosing the local recurrence of rectal cancer. *Abdom Imaging* 2003; 28:19-27
28. Tamakawa M, Kawai Y, Shirase R, et al. Gadolinium-enhanced dynamic magnetic resonance imaging with endorectal coil for local staging of rectal cancer. *Jpn J Radiol* 2010; 28:290-298
29. Ohta K, Ikeda M, Kagawa Y, et al. Two cases of curative resection for locally recurrent rectal cancer with high-level sacrectomy after preoperative chemoradiation therapy (CRT) Gan to Kagaku Ryoho. 2011;38(12):1992-1994